

AD _____

Award Number: DAMD17-99-1-9540

TITLE: Alpha Synuclein Aggregation in a Neurotoxic Model of
Parkinson's Disease

PRINCIPAL INVESTIGATOR: Neil W. Kowall, M.D.

CONTRACTING ORGANIZATION: Boston University School of Medicine
Boston, Massachusetts 02118

REPORT DATE: August 2000

TYPE OF REPORT: Annual

PREPARED FOR: U.S. Army Medical Research and Materiel Command
Fort Detrick, Maryland 21702-5012

DISTRIBUTION STATEMENT: Approved for public release;
Distribution unlimited

The views, opinions and/or findings contained in this report are those of the author(s) and should not be construed as an official Department of the Army position, policy or decision unless so designated by other documentation.

20010524 042

REPORT DOCUMENTATION PAGEForm Approved
OMB No. 074-0188

Public reporting burden for this collection of information is estimated to average 1 hour per response, including the time for reviewing instructions, searching existing data sources, gathering and maintaining the data needed, and completing and reviewing this collection of information. Send comments regarding this burden estimate or any other aspect of this collection of information, including suggestions for reducing this burden to Washington Headquarters Services, Directorate for Information Operations and Reports, 1215 Jefferson Davis Highway, Suite 1204, Arlington, VA 22202-4302, and to the Office of Management and Budget, Paperwork Reduction Project (0704-0188), Washington, DC 20503

1. AGENCY USE ONLY (Leave blank)		2. REPORT DATE August 2000	3. REPORT TYPE AND DATES COVERED Annual (1 Aug 99 - 31 Jul 00)	
4. TITLE AND SUBTITLE Alpha Synuclein Aggregation in a Neurotoxic Model of Parkinson's Disease			5. FUNDING NUMBERS DAMD17-99-1-9540	
6. AUTHOR(S) Neil W. Kowall, M.D.				
7. PERFORMING ORGANIZATION NAME(S) AND ADDRESS(ES) Boston University School of Medicine Boston, Massachusetts 02118 E-MAIL: nkowall@bu.edu			8. PERFORMING ORGANIZATION REPORT NUMBER	
9. SPONSORING / MONITORING AGENCY NAME(S) AND ADDRESS(ES) U.S. Army Medical Research and Materiel Command Fort Detrick, Maryland 21702-5012			10. SPONSORING / MONITORING AGENCY REPORT NUMBER	
11. SUPPLEMENTARY NOTES Report contains color graphics.				
12a. DISTRIBUTION / AVAILABILITY STATEMENT Approved for public release; Distribution unlimited				12b. DISTRIBUTION CODE
13. ABSTRACT (Maximum 200 Words) The cause of Parkinson's disease (PD) is not known but the pattern of neurodegeneration found in PD can be replicated in some animals species, including primates and mice, by the systemic administration of the neurotoxin 1-methyl-4-phenyl-tetrahydropyridine (MPTP). MPTP inhibits mitochondrial oxidative phosphorylation and causes oxidative injury leading to cell death. Neurons that degenerate in PD develop characteristic inclusions called Lewy bodies that are composed of aggregates of a synaptic protein, alpha synuclein. The purpose of this study is to determine how MPTP affects cytoskeletal and synaptic proteins and to study the relationship between oxidative damage and the formation of synuclein aggregates within neurons. In the first year of this three-year funding period, we have shown that MPTP treated primates and mice develop synuclein aggregates in neurons that are degenerating in the substantia nigra. Degenerating neurons were identified using tyrosine hydroxylase and dopamine transporter immunocytochemistry. The neurodegenerative process is associated with increased levels of oxidative markers for DNA, protein and lipids as indicated by immunocytochemistry for 8-hydroxydeoxyguanosine, 3-nitrotyrosine and malondialdehyde respectively. Over the next 2 years, we plan to study the time course of these changes and precisely define the cytoskeletal and synaptic changes associated with synuclein aggregate formation.				
14. SUBJECT TERMS Parkinson's, neurotoxin, synuclein, cytoskeleton, synapse, oxidation, free-radical, neuropathology				15. NUMBER OF PAGES 20
				16. PRICE CODE
17. SECURITY CLASSIFICATION OF REPORT Unclassified	18. SECURITY CLASSIFICATION OF THIS PAGE Unclassified	19. SECURITY CLASSIFICATION OF ABSTRACT Unclassified	20. LIMITATION OF ABSTRACT Unlimited	

NSN 7540-01-280-5500

Standard Form 298 (Rev. 2-89)
Prescribed by ANSI Std. Z39-18
298-102

Table of Contents

Cover.....	1
SF 298.....	2
Table of Contents	3
Introduction.....	4
Body.....	4
Key Research Accomplishments.....	11
Reportable Outcomes.....	12
Conclusions.....	12
References.....	13
Appendices.....	14-20

Introduction

The cause of Parkinson's disease (PD) is not known but the pattern of neurodegeneration found in PD can be replicated in some animal species, including primates and mice, by the systemic administration of the neurotoxin 1-methyl-4-phenyl-tetrahydropyridine (MPTP). MPTP inhibits mitochondrial oxidative phosphorylation and causes oxidative injury leading to cell death. Neurons that degenerate in PD develop characteristic inclusions called Lewy bodies that are composed of aggregates of a synaptic protein, alpha synuclein. The purpose of this study is to determine how MPTP affects cytoskeletal and synaptic proteins and to study the relationship between oxidative damage and the formation of synuclein aggregates within neurons. Two important studies showed that overexpression of mutant forms of synuclein associated with familial PD can lead to aggregate formation in both transgenic mice (1) and fruit flies (2).

Body

In the approved Statement of Work we proposed to complete two series of experiments in the three-year funding period. The purpose of the first series of experiments is to define changes in the distribution and morphology of alpha synuclein immunoreactivity produced by systemic treatment of MPTP in mice. Both the time course of these changes and their relationship to synaptic (synaptophysin) and neurofilament proteins (NF-M) are being studied. The second series of experiments focuses on defining the spatial and temporal relationship between synuclein aggregation and oxidative injury at the cellular level. Patterns of cell death and apoptosis associated with MPTP toxicity are to be determined and related to the changes in synuclein and oxidative damage. Changes in the regional and cellular distribution of oxidative markers (3-nitrotyrosine, 8-hydroxydeoxyguanosine (8OHdG), and malondialdehyde (MDA)), DNA fragmentation (in situ end labeling, ISEL), and stress response (ubiquitin) with

respect to synuclein in the substantia nigra and striatum of mice treated with MPTP are being examined. Last year we published a preliminary study showing that synuclein aggregation is produced in the primate brain after MPTP administration (see manuscript in appendix). We have completed a study on 72 adult male C57BL mice treated with intraperitoneal MPTP followed by sacrifice after a 7-10 day survival period.


Two different MPTP toxicity models have been tested. Histological results are summarized below and in the color photographs attached as appendix materials. For the "acute" model 88 day old mice were given a single IP injection of 20 mg/kg MPTP every 2 hours until symptoms appeared. Animals were given five injections of MPTP on day one and four injections on day two, a total of 9 injections of MPTP. Control mice were given an equivalent volume of PBS according to the same schedule. The mice were perfused with paraformaldehyde 11 days after the last injection at a final age of 100 days. Serial sections of the brains were cut @ 50um into 8 wells. With this acute regimen, the mice were mildly symptomatic after the first day of five injections. It was not until the second day, at the time of the 8th injection that they were very symptomatic. For the "chronic" model, 88-day-old mice were given daily IP injections of 30 mg/kg MPTP. Control mice were given an equivalent volume of PBS at the same time (12PM daily). This regimen continued for 10 days. The mice were perfused 11 days after the last injection at the age of 108 days. Serial sections of their brains were also cut @ 50um into 8 wells. With this chronic regimen mice show little or no symptomatology for the first three days. On the fourth day, one hour after the injection, they became lethargic for 90 to 120 minutes. This behavioral response recurred daily after each injection. By the sixth day, the animals developed quickened respirations and hyperactivity immediately after the injection that lasted 15-20 min. This pattern of behavior also continued until the final injection.

Histological results presented below are also illustrated in color photographs in the appendix (figures 1-3). The extent of MPTP-induced neurodegeneration is defined immunocytochemically using a monoclonal antibody against the dopamine transporter (DAT). In our hands this is a very reliable method to define dopaminergic neurons and their projections. The illustrations below show a low power view of control, acute MPTP- and chronic MPTP-induced changes in DAT immunoreactivity in the striatum and the substantia nigra.



In the normal mouse striatum, DAT immunoreactivity is uniformly distributed (left, above). The substantia nigra (middle frame) is defined by a dense collection of DAT positive neurons. A higher power view of neurons in the caudal nigra (right, above) shows the extensive arborization of individual dendrites and axons in the control animals.


This picture is in striking contrast to the pattern of immunoreactivity in MPTP treated animals:



In the acute MPTP treated animal, there is a clear reduction in the intensity of immunoreactivity in the striatum (left, above). This depletion is more severe in the caudal and dorsal aspects of the striatum. The ventral striatum is less affected. There is also depletion of

neurons in the substantia nigra, especially in the middle third of the nigra (A8 field) with relative sparing of the medial ventral tegmental area (A10) (middle frame). Higher power examination of individual DAT positive neurons shows dendritic and axonal pruning and fragmentation and distortion of immunoreactive processes (right, above).

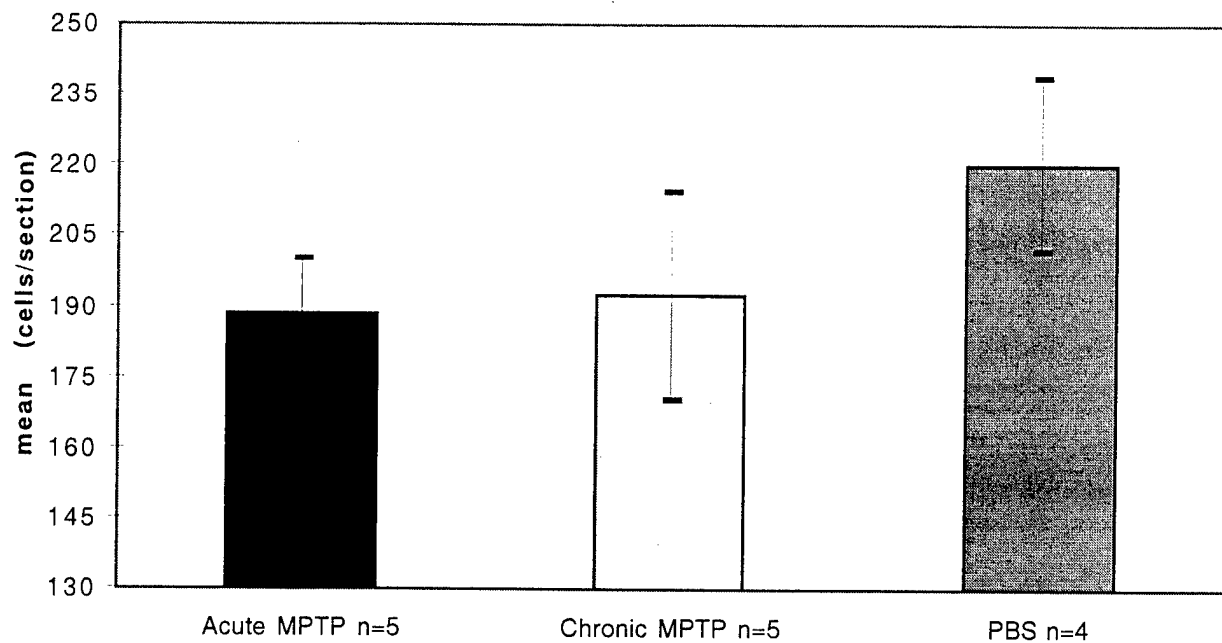
Similar changes are seen in the chronic MPTP model but they are generally somewhat less severe:




The depletion of striatal DAT terminals is evident with relative sparing of the ventral striatum (left, above). This is accompanied by a depletion of DAT neurons in the nigra (middle, above) that is somewhat less severe than in the acute MPTP model. Similar morphological changes also affect dendritic and axonal processes (right, above).


The extent of the lesion produced by MPTP varies from animal to animal. This is illustrated by the quantitative analysis of DAT neurons that we performed in a series of animals (see graph below, original color copy in appendix). We counted all DAT immunoreactive neurons in a series of 300 micron spaced step-sections of the midbrain. The mean reduction in DAT positive neurons was approximately 15% in the acute model and 13% in the chronic model but the variability of lesion extent, as shown by the large standard error bars, results in a lack of statistically significant difference when an analysis of variance is performed ($p > 0.05$). Further cell counts will be performed on a larger series of lesioned animals and quantitative analysis of branching patterns and fragmentation will be performed.

DAT Immunopositive Cells In The Substantia Nigra of MPTP Treated Mice



The lesions induced by MPTP are also evident in cresyl violet stained sections of the substantia nigra (below). In the normal nigra neurons are clearly visible (left, below). Neuronal depletion and glial increase is seen in both the acute MPTP (middle, below) and chronic MPTP (right, below) models.




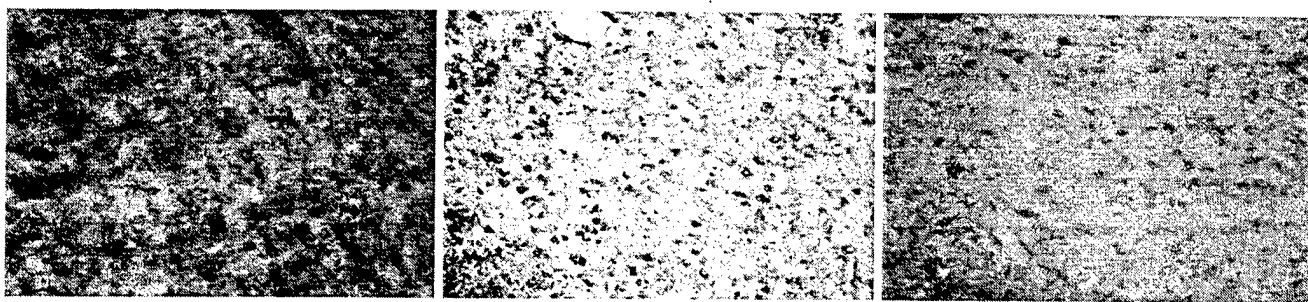


Glial fibrillary acidic protein (GFAP) immunocytochemistry (above) discloses astrocytes in brain tissue. In the normal substantia nigra (left, above) there are some astrocytes in the cerebral peduncle (lower part of frame). In the acute (middle, above) and chronic (right, above) MPTP lesioned nigra the number and intensity of GFAP-positive astrocytes is clearly increased.

In the following series of photographs, changes in the immunocytochemical localization of relevant biomarkers in the substantia nigra of representative animals lesioned with the acute and the chronic MPTP protocol are depicted.

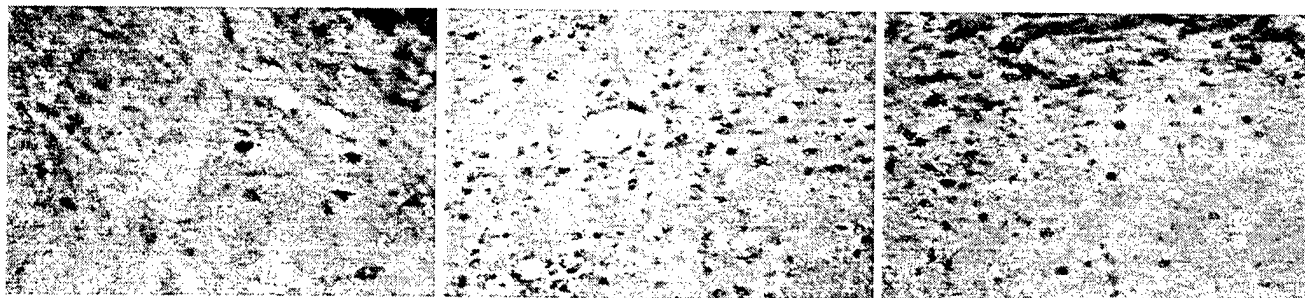
Calbindin is a calcium binding protein enriched in a subset of neurons in the substantia nigra. In the normal substantia nigra immunoreactive neurons are defined (left, below). In both the acute and chronic MPTP lesioned animals there is striking depletion of calbindin immunoreactivity (below, middle and right panels).






Alpha synuclein immunoreactivity in the substantia nigra of the normal mouse is punctate and resembles synapses (left above). The loss of calbindin and DAT immunoreactive neurons is associated with increased synuclein immunoreactivity in both the acute (middle, above) and chronic (right above) MPTP models. Quantitative analysis of this increased immunoreactivity is being performed.

Similar changes are seen with ubiquitin immunocytochemistry (below). A few ubiquitin positive cellular profiles are seen in the control substantia nigra (below, left). In the acute and chronic MPTP lesions (below, middle and right panels respectively) there is a clear increase in the number of ubiquitin positive profiles.




In contrast to the striking changes seen with alpha synuclein and ubiquitin staining, the staining pattern of synaptophysin, a synaptic protein, and neurofilament (medium chain), a marker of cell bodies and dendrites, changes minimally (below).


Synaptophysin immunoreactivity (control, left; acute MPTP, middle; chronic MPTP, right):



Neurofilament (in control, left below, and acute MPTP model, right below)



Markers of oxidative damage, such as 8-hydroxydeoxyguanosine, a marker of DNA oxidation, are increased in neurons in the substantia nigra of MPTP-treated animals (below).



Key Research Accomplishments:

- 1) Acute and chronic MPTP treatment, which cause nigral dopaminergic neurons to degenerate, are associated with the displacement of alpha synuclein from its normal

synaptic location into neuronal cell bodies. Neuronal degeneration is evident with DAT and calbindin immunocytochemistry and glial reaction is evident with GFAP immunocytochemistry.

- 2) The redistribution of synuclein is associated with increased ubiquitin immunoreactivity and increased levels of oxidative markers in the substantia nigra.
- 3) The redistribution of synuclein does not appear to be associated with changes in distribution of synaptophysin or neurofilament proteins.

Reportable Outcomes

- 1) A paper has been published (see appendix)
- 2) A database of histological materials has been developed and a large number of specimens have been catalogued that will be available for future research.
- 3) An abstract reporting the preliminary observations on MPTP treated mice described above is being submitted in January 2001 for presentation at the American Association of Neuropathologists in June 2001. Data will also be reported at the DoD-sponsored workshop in Maryland in March 2001
- 3) As data analysis progresses, further abstracts and manuscripts will be published.

Conclusions

MPTP treated mice develop alpha synuclein and ubiquitin immunoreactive aggregates in neurons that are degenerating in the substantia nigra 7-10 days after MPTP administration in both the acute and chronic MPTP models. Lesions are more extensive in the acute model. Degenerating neurons are identified using dopamine transporter and calbindin immunocytochemistry and glial reaction is identified with glial acidic fibrillary protein. Synaptophysin and neurofilament immunoreactivity are not strikingly altered. The neurodegenerative process is associated with increased levels of oxidative markers for DNA,

protein and lipids as indicated by immunocytochemistry for 8-hydroxydeoxyguanosine, 3-nitrotyrosine and malondialdehyde respectively. Our observations validate the MPTP model of PD by demonstrating that MPTP causes synuclein aggregation in degenerating neurons even though classical Lewy bodies are not produced. We will now be able to determine how synuclein aggregation evolves over time and how it relates to the process of cell death. Therapeutic strategies targeted at interfering with the process of synuclein aggregation that we have demonstrated may lead to novel therapeutic approaches to the treatment of PD.

References

- 1) Masliah E, Rockenstein E, Veinbergs I, Mallory M, Hashimoto M, Takeda A, Sagara Y, Sisk A, Mucke L. Dopaminergic Loss and Inclusion Body Formation in α -Synuclein Mice: Implications for Neurodegenerative Disorders. *Science* 2000; 287:1265-69
- 2) Feany MB, Bender WW. A *Drosophila* model of Parkinson's disease. *Nature* 2000;404:394-8

Appendices

Journal article (Kowall NW, Hantraye P, Brouillet E, Beal MF, McKee AC and Ferrante RJ. MPTP induces α -synuclein aggregation in the substantia nigra of baboons. *Neuroreport* 2000;11(1):211-213.

Color Photographs (3)

Graph showing quantitation of dopamine transporter positive neurons in control and MPTP treated mice.

MPTP induces alpha-synuclein aggregation in the substantia nigra of baboons

Neil W. Kowall,^{CA} Philippe Hantraye,¹ Emmanuel Brouillet,¹ M. Flint Beal,² Ann C. McKee and Robert J. Ferrante

Geriatric Research Education Clinical Center, Veterans Affairs Medical Center, Bedford, MA 01730, and the Departments of Neurology and Pathology, Boston University School of Medicine, USA; ¹Unité de Recherche Associé Commissariat à l'Energie Atomique, Centre National de la Recherche Scientifique 2210, Service Hospitalier Frederic, Joliot, Orsay, France;

³Neurochemistry Laboratory, Neurology Service, Massachusetts General Hospital and Harvard Medical School, Boston, MA, USA

^{CA}Corresponding Author

Received 13 October 1999; accepted 3 November 1999

Published online by xx xxxx 2000

Acknowledgements: Thanks to David Clayton for the generous gift of α -synuclein antibody and to Karen Smith for expert technical assistance. This work was supported by the US Department of Veterans Affairs, US Department of Defense, American Parkinson's Disease Association and by the National Institutes of Health (AG13846, NS37102, NS16367 and NS31579).

1-Methyl-4-phenyl-1,2,3,6-tetrahydropyridine (MPTP) neurotoxicity reproduces many of the features of Parkinson's disease (PD). α -Synuclein has been identified as a prominent component of the Lewy body (LB), the pathological hallmark of PD. MPTP-treated primates have been reported to develop intraneuronal inclusions but not true Lewy bodies. We administered MPTP to baboons and used a monoclonal α -synuclein antibody to define the relationship between neuronal degeneration and (α -synuclein immunoreactivity in the substantia nigra. MPTP-induced neuronal degeneration was associated with the redistribution of α -synuclein from its normal synaptic location to aggregates in degenerating neuronal cell bodies. α -Synuclein aggregation induced by MPTP models the early stages of Lewy body formation and may be a fundamental step in the evolution of neuronal degeneration in PD. *NeuroReport* 11:1–3

© 2000 Lippincott Williams & Wilkins.

Key words: Baboon; MPTP; Synuclein; Substantia nigra

INTRODUCTION

α -Synuclein is a 143 amino acid protein localized to axons and synapses in the normal human brain [1]. The important role of α -synuclein in the pathogenesis of PD has been recently discovered. α -Synuclein mutations cause familial PD (A53T and A30P) [2,3] and α -synuclein is a major constituent of the LB, the pathological hallmark of idiopathic PD [1,4]. In human and non-human primates, 1-methyl-4-phenyl-1,2,3,6-tetrahydropyridine (MPTP) produces clinical, biochemical and neuropathological changes similar to those found in idiopathic Parkinson's disease [5]. Aged primates exposed to MPTP develop intraneuronal inclusions similar, but not identical, to Lewy bodies [6]. In the present study we examined the distribution of α -synuclein in baboons (*Papio anubis*) treated with MPTP to determine whether neurodegeneration produced by MPTP is associated with redistribution and aggregation of α -synuclein as seen in humans with idiopathic PD.

MATERIALS AND METHODS

Tissue sections from six male *P. anubis* were used in these experiments. The three baboons in the treatment group

received one or two i.m. injections of 0.4 mg/kg MPTP (MPTP-HCl, Sigma) daily at 11:00 h (and 18:00 h) for 6 days followed by an injection of 0.27 mg/kg at 11:00 h on day 7. Ten days after the first injection the three treated animals and three untreated controls were placed under chemical restraint (ketamine 10 mg/kg) and euthanized by an overdose of sodium pentobarbital (120 mg/kg). Fresh whole brains were hemisected by a midline sagittal cut. One hemisphere and brain stem half was flash frozen for neurochemical studies, while the other half was immersion fixed overnight in cold (4°C) 4% paraformaldehyde/lysine/sodium m-periodate solution for histopathological evaluation. The brain stem and cerebellum were separated by a midbrain cut at the level of the mammary bodies. The tissue specimens were cryoprotected in 15% glycerol solution made in 0.1 M phosphate buffer. The brainstem was sectioned coronally at 50 μ m and subsequently stained for routine cell identification using cresyl violet and immunocytochemically for tyrosine hydroxylase (TH) activity (TH antisera; 1:1000 dilution; Protos Biotechnology, New York, NY) and α -synuclein staining using a well-characterized α -synuclein monoclonal antibody (H3C), which recognizes

the C-terminus of α -synuclein [7] (1:1000 dilution, courtesy of Dr David Clayton). The immunocytochemical methods used have previously been reported [8]. All animals used in these procedures were in strict compliance with the NIH Guide for the Care and Use of Laboratory Animals and were approved by all local Animal Care Committees.

RESULTS

Nissl-stained sections of the substantia nigra from MPTP-treated animals showed marked neuronal loss and gliosis, as reported previously (Fig. 1A,B) [8,9]. Neuronal degeneration was most severe in the central A9 region of the substantia nigra with less involvement of medial (A10) and lateral (A8) regions. The pattern of loss of tyrosine hydroxylase positive neurons was essentially identical to that seen in Nissl stained sections.

In control animals, α -synuclein immunoreactivity was confined to fine punctae throughout all regions (A8–10) of the substantia nigra (Fig. 1C). In MPTP-treated animals, synuclein immunoreactivity was depleted in the most severely affected (middle third) region of the substantia nigra, where no neurons remained. In regions with neuronal degeneration and pyknosis, there was a striking redistribution of α -synuclein from synaptic profiles into neuronal cell bodies and dendrites (Fig. 1D). Fine immunoreactive granular intraneuronal accumulations and larger aggregates were prominent in many neuronal somata.

DISCUSSION

MPTP causes α -synuclein aggregation in degenerating neurons of the primate substantia nigra. The redistribution of synuclein from its normal synaptic and axonal location to cell bodies and dendrites associated with MPTP toxicity is very similar to the redistribution of α -synuclein found in idiopathic PD and dementia with Lewy bodies [1,4] (personal observations). The impact of α -synuclein redistribution on neuronal function is unclear. α -Synuclein aggregates have been reported to induce apoptotic cell death in human neuroblastoma cell lines [10]. Expression of α -synuclein in songbirds is related to song learning [7], suggesting that it may play a role in neuronal plasticity potentially involving pre-synaptic vesicle function [11], but its normal function in the human brain is unknown.

How MPTP toxicity leads to α -synuclein aggregation is not known. Oxidative mechanisms may be involved because the active metabolite of MPTP, MPP⁺, inhibits the electron transport chain initiating a vicious cycle of oxidative damage that causes cellular injury and death [12]. Oxidizing conditions favor self-aggregation of the microtubule protein tau to form neurofibrillary tangles in Alzheimer's disease [13]. Oxidative injury is associated with the development of neuronal inclusions in transgenic mice expressing human superoxide dismutase-1 with the G93A mutation. These mice show evidence of increased oxidative injury [14] and develop Lewy-like bodies in degenerating

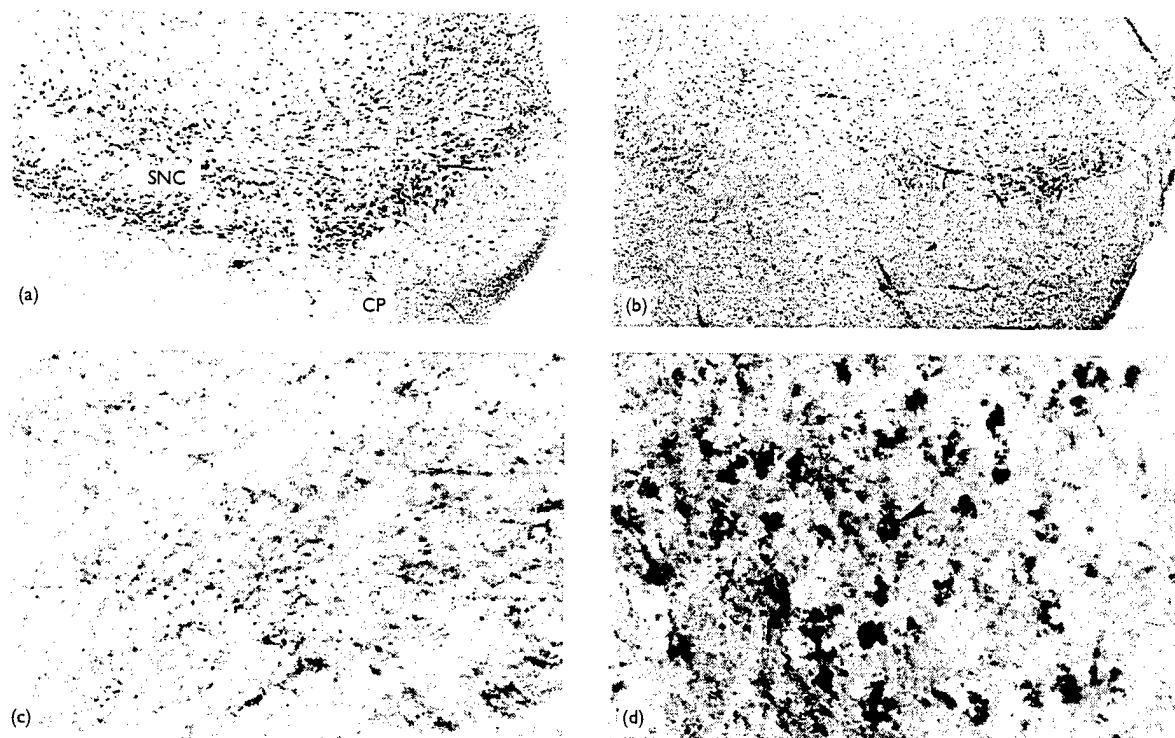


Fig. 1. α -Synuclein immunoreactivity in MPTP treated monkeys. General cell stains (A,B) show that systemic MPTP treatment causes marked neuronal loss within the middle third of the substantia nigra pars compacta (SNC) of baboons (B) compared with untreated controls (A) (cresyl violet stain). (α -Synuclein immunoreactivity was distributed in fine terminal-like structures within the SNC of untreated animals (C). Punctate staining was reduced and deposits of α -synuclein immunoreactivity were prominent in the SNC of animals treated with MPTP (D, arrowhead). CP: cerebral peduncle.

motor neurons [15]. Patients with amyotrophic lateral sclerosis (ALS), who show evidence of oxidative injury postmortem [16], also develop Lewy body-like intraneuronal inclusions. Oxidative injury is very prominent in PD brain [17] and in MPTP-treated primates [9]. *In vitro* studies suggest that oxidative stress can also induce α -synuclein aggregation *in vitro* [18]. Oxidative injury induced by MPTP toxicity could therefore cause α -synuclein aggregation in our experimental animals. Transglutaminase, a cross-linking enzyme involved with signal transduction and apoptosis, catalyses the formation of the covalent synuclein polymers *in vitro* [19]. This enzyme also cross-links tau [20], beta amyloid [21] and mutant huntingtin [22], and may contribute to inclusion formation in Alzheimer's and Huntington's disease. There is also evidence that synuclein mutations associated with PD accelerate synuclein aggregation [23–25]. Whatever the mechanisms involved, our results support the notion that α -synuclein aggregation is the initial event leading to Lewy body formation.

CONCLUSION

MPTP neurotoxicity causes the redistribution and aggregation of α -synuclein within degenerating neurons of the primate substantia nigra. This may reflect the initial stages in the formation of Lewy bodies, the pathological hallmark of idiopathic PD in humans. Therapies that successfully prevent this process in the MPTP animal model may suppress Lewy body formation and cell death in patients with PD.

AQ: Ref 3. Vol no missing

REFERENCES

1. Irizarry M, Growdon W, Gomez-Isla T et al. *J Neuropathol Exp Neurol* 57, 334–337 (1998).
2. Polymeropoulos MH, Lavedan C, Leroy E et al. *Science* 276, 2045–2047 (1997).
3. Kruger R, Kuhn W, Muller T et al. *Nature Genet* 106–108 (1998).
4. Trojanowski JQ and Lee VM. *Arch Neurol* 55, 151–152 (1998).
5. Bloem BR, Irwin I, Buruma OJ et al. *J Neurol Sci* 97, 273–293 (1990).
6. Forno LS, DeLanney LE, Irwin I et al. *Adv Neurol* 60, 600–608 (1993).
7. George JM, Jin H, Woods WS et al. *Neuron* 15, 361–372 (1995).
8. Hantraye P, Brouillet E, Ferrante R et al. *Nature Med* 2, 1017–1021 (1996).
9. Ferrante RJ, Hantraye P, Brouillet E et al. *Brain Res* 823, 177–182 (1999).
10. El-Agnaf OM, Jakes R, Curran MD et al. *FEBS Lett* 440, 71–75 (1998).
11. Davidson WS, Jonas A, Clayton DF et al. *J Biol Chem* 273, 9443–9449 (1998).
12. Hung HC and Lee EH. *Free Radic Biol Med* 24, 76–84 (1998).
13. Schweers O, Mandelkow EM, Biernat J et al. *Proc Natl Acad Sci USA* 92, 8463–8467 (1995).
14. Ferrante RJ, Schulz JB, Matthews RT et al. *Ann Neurol* 42, 326–334 (1997).
15. Tu PH, Raju P, Robinson KA et al. *Proc Natl Acad Sci USA* 93, 3155–3160 (1996).
16. Ferrante RJ, Browne SE, Shinobu LA et al. *J Neurochem* 69, 2064–2074 (1997).
17. Good PF, Hsu A, Werner P et al. *J Neuropathol Exp Neurol* 57, 338–342 (1998).
18. Hashimoto M, Hsu LJ, Xia Y et al. *Neuroreport* 10, 717–721 (1999).
19. Jensen PH, Sorensen ES, Petersen TE et al. *J Biol Chem* 270, 21264–21270 (1995).
20. Appelt DM and Balin BJ. *Brain Res* 745, 21–31 (1997).
21. Dudek SM and Johnson GV. *Brain Res* 651, 129–133 (1994).
22. Kahlem P, Terre C, Green H et al. *Proc Natl Acad Sci USA* 93, 14580–14585 (1996).
23. Conway KA, Harper JD and Lansbury PT. *Nature Med* 4, 1318–1320 (1998).
24. El-Agnaf OM, Jakes R, Curran MD et al. *FEBS Lett* 440, 67–70 (1998).
25. Narhi L, Wood SJ, Steavenson S et al. *J Biol Chem* 274, 9843–9846 (1999).


Figure 1

DOPAMINE TRANSPORTER

Striatum : Control

Acute MPTP lesion

Chronic MPTP lesion



Substantia Nigra (overview) Control

Acute MPTP lesion

Chronic MPTP lesion



Substantia Nigra (high power) Control

Acute MPTP lesion

Chronic MPTP lesion





Figure 2

Histology of the Substantia Nigra (Low Power)



Dopamine Transporter



Glial Fibrillary Acidic Protein



Figure 3

Histology of the Substantia Nigra (High Power)

DOPAMINE TRANSPORTER Control

Acute MPTP


Chronic MPTP



CALBINDIN




ALPHA SYNUCLEIN



UBIQUITIN



SYNAPTOPHYSIN



NEUROFILAMENT-M



8-HYDROXY-DEOXYGUANOSINE (ACUTE MPTP)



DAT Immunopositive Cells In The Substantia Nigra of MPTP Treated Mice

