

AD \_\_\_\_\_

Award Number: DAMD17-98-1-8343

TITLE: Interstitial Optical Diagnosis and Treatment of Breast  
Cancer

PRINCIPAL INVESTIGATOR: Stephen G. Bown, Ph.D.

CONTRACTING ORGANIZATION: University College London  
London WC1E 6BT United Kingdom

REPORT DATE: September 2000

TYPE OF REPORT: Annual

PREPARED FOR: U.S. Army Medical Research and Materiel Command  
Fort Detrick, Maryland 21702-5012

DISTRIBUTION STATEMENT: Approved for Public Release;  
Distribution Unlimited

The views, opinions and/or findings contained in this report are those of the author(s) and should not be construed as an official Department of the Army position, policy or decision unless so designated by other documentation.

20010302 053

REPORT DOCUMENTATION PAGE			Form Approved OMB No. 0704-0188																									
Public reporting burden for this collection of information is estimated to average 1 hour per response, including the time for reviewing instructions, searching existing data sources, gathering and maintaining the data needed, and completing and reviewing the collection of information. Send comments regarding this burden estimate or any other aspect of this collection of information, including suggestions for reducing this burden, to Washington Headquarters Services, Directorate for Information Operations and Reports, 1215 Jefferson Davis Highway, Suite 1204, Arlington, VA 22202-4302, and to the Office of Management and Budget, Paperwork Reduction Project (0704-0188), Washington, DC 20503.																												
1. AGENCY USE ONLY (Leave Blank)	2. REPORT DATE September 2000	3. REPORT TYPE AND DATES COVERED Annual (01 Sep 99 – 31 Aug 00)																										
4. TITLE AND SUBTITLE Interstitial Optical Diagnosis and Treatment of Breast Cancer			5. FUNDING NUMBERS DAMD 17-98-1-8343																									
6. AUTHORS Stephen Bown, Ph.D.																												
7. PERFORMING ORGANIZATION NAME(S) AND ADDRESS(ES) University College London London, United Kingdom WC1E 6BT  <b>e-mail: s.bown@ucl.ac.uk</b>			8. PERFORMING ORGANIZATION REPORT NUMBER																									
9. SPONSORING / MONITORING AGENCY NAME(S) AND ADDRESS(ES)  U.S. Army Medical Research and Materiel Command Fort Detrick Maryland 21702-5012			10. SPONSORING / MONITORING AGENCY REPORT NUMBER																									
11. SUPPLEMENTARY NOTES																												
12a. DISTRIBUTION / AVAILABILITY STATEMENT Approved for public release distribution unlimited			12b. DISTRIBUTION CODE																									
13. ABSTRACT (Maximum 200 words) <b>Aim: development of optical techniques for diagnosis and treatment of breast cancer</b>  Spectral analysis of white light reflected from tissue is a rapid, non-invasive, diagnostic technique. We collected paired optical and conventional histologic measurements from 290 sites in breast and axillary nodes and looked for spectral features to identify cancer. Spectral analysis used artificial neural networks (ANN), hierarchical cluster analysis (HCA) and model based analysis (MBA). The sensitivity and specificity for detecting cancer in breast tissue or lymph nodes were:  <table border="1"> <thead> <tr> <th>Breast</th> <th>ANN</th> <th>HCA</th> <th>MBA</th> <th>Nodes</th> <th>ANN</th> <th>HCA</th> <th>MBA</th> </tr> </thead> <tbody> <tr> <td>Sensitivity</td> <td>69%</td> <td>67%</td> <td>94%</td> <td>Sensitivity</td> <td>58%</td> <td>91%</td> <td>57%</td> </tr> <tr> <td>Specificity</td> <td>85%</td> <td>79%</td> <td>92%</td> <td>Specificity</td> <td>93%</td> <td>76%</td> <td>85%</td> </tr> </tbody> </table> Therapy aims for complete ablation of small cancers using MR guided Interstitial Laser Photocoagulation (ILP). We have shown that ILP can ablate small cancers and that contrast enhanced MR can detect untreated areas of cancer as small as 2mm. The number of suitable patients for study is small. The main problems are technical rather than biological. Real time imaging of ILP is possible in high field, closed MR scanners (1.5T), where fiber positioning is difficult, but not in low field interventional scanners (0.2T). ILP to fibroadenomas confirmed that laser necrosed tissue is resorbed and the treated area heals safely. The latter could become a valuable treatment in its own right.					Breast	ANN	HCA	MBA	Nodes	ANN	HCA	MBA	Sensitivity	69%	67%	94%	Sensitivity	58%	91%	57%	Specificity	85%	79%	92%	Specificity	93%	76%	85%
Breast	ANN	HCA	MBA	Nodes	ANN	HCA	MBA																					
Sensitivity	69%	67%	94%	Sensitivity	58%	91%	57%																					
Specificity	85%	79%	92%	Specificity	93%	76%	85%																					
14. SUBJECT TERMS Breast Cancer, Optical Biopsy, Interstitial Laser Photocoagulation.			15. NUMBER OF PAGES 51																									
			16. PRICE CODE																									
17. SECURITY CLASSIFICATION OF REPORT Unclassified	18. SECURITY CLASSIFICATION OF THIS PAGE Unclassified	19. SECURITY CLASSIFICATION OF ABSTRACT Unclassified	20. LIMITATION OF ABSTRACT Unlimited																									

NSN 7540-01-280-5500

Standard Form 298 (Rev. 2-89)  
Prescribed by ANSI Std. Z39-1  
298-102

## Table Of Contents

Front Page	1
Table of Contents	2
Standard Form (SF) 298	3
Foreword	4
Introduction	5
Body	6
Key Research Accomplishments	20
Reportable Outcomes	21
Conclusions	24
References	26

### Appendices

Appendix 1 – “Diagnosis of breast cancer using elastic-scattering spectroscopy: preliminary clinical results.” Irving J. Bigio et al. *J. Biomed. Opt.* 2000; 5(2): 221-228.

Appendix 2 – “Interstitial laser photocoagulation for fibroadenomas of the breast.” L.M. Lai et al. *The Breast* (1999) 8, 89-94.

Appendix 3 – Shedding light on breast cancer – Optical Biopsy (work in progress). C.M. Saunders et al.

Appendix 4 – “Interstitial laser photocoagulation of breast tumours.” G. Briggs, M. Hall-Craggs.

Appendix 5 – “Optical Diagnosis of Breast Cancer.” S.G. Bown.

Appendix 6 – “Local Destruction of Breast Cancer with Lasers.” S.G. Bown.

FOREWORD

Opinions, interpretations, conclusions and recommendations are those of the author and are not necessarily endorsed by the U.S. Army.

\_\_\_\_\_ Where copyrighted material is quoted, permission has been obtained to use such material.

\_\_\_\_\_ Where material from documents designated for limited distribution is quoted, permission has been obtained to use the material.

\_\_\_\_\_ Citations of commercial organizations and trade names in this report do not constitute an official Department of Army endorsement or approval of the products or services of these organizations.

\_\_\_\_\_ In conducting research using animals, the investigator(s) adhered to the "Guide for the Care and Use of Laboratory Animals," prepared by the Committee on Care and use of Laboratory Animals of the Institute of Laboratory Resources, national Research Council (NIH Publication No. 86-23, Revised 1985).

For the protection of human subjects, the investigator(s) adhered to policies of applicable Federal Law 45 CFR 46.

\_\_\_\_\_ In conducting research utilizing recombinant DNA technology, the investigator(s) adhered to current guidelines promulgated by the National Institutes of Health.

\_\_\_\_\_ In the conduct of research utilizing recombinant DNA, the investigator(s) adhered to the NIH Guidelines for Research Involving Recombinant DNA Molecules.

\_\_\_\_\_ In the conduct of research involving hazardous organisms, the investigator(s) adhered to the CDC-NIH Guide for Biosafety in Microbiological and Biomedical Laboratories.

Stephen A. Boman 27th Sept 2000  
PI - Signature Date

**Interstitial Diagnosis and Treatment of Breast Tumors**  
**Annual Report 1<sup>st</sup> September 1999 – 31<sup>st</sup> August 2000**

**Introduction:**

This research falls broadly into two main areas:

- 1) *Interstitial diagnosis of breast tumors by optical biopsy:* This involves placing a probe containing two optic fibres into a breast lump. One fibre is attached to a Xenon lamp which sends short pulses of white light into the area of tissue to be interrogated. A second optic fibre collects light, which is scattered back, and this is analyzed spectroscopically. A conventional histologic specimen is taken from precisely the same point, and the two sets of data are then compared. Algorithms can subsequently be developed once sufficient data sets have been collected. In this way it is anticipated that we can train the optical system to give an accurate diagnosis of any breast lump.
  
- 2) *Interstitial treatment of benign breast fibroadenomas and malignant breast cancers by Interstitial Laser Photocoagulation:* The tumors to be treated are first identified by either ultrasound scanning (USS) or Magnetic Resonance Imaging (MRI). Small-bore cannulae are inserted into the middle of the tumor through which optic fibres are passed. These in turn are attached to a semi-conductor diode laser. The laser is activated for between 10 and 20 minutes depending on the tumor size. For the fibroadenomas, follow up is with serial USS. Patients with cancer have laser treatment before routine surgery. They all have MR scans pre- and post laser treatment and just before surgery. These are subsequently compared to the histologic specimen. We aim to show that fibroadenomas and small breast cancers can be successfully treated with laser therapy. The most important challenge is to determine if MR imaging can detect any malignant tissue remaining after laser treatment.

## **Objective 1: Advance diagnostic techniques with Optical Biopsy.**

At the start of this program, little more than the basic principle of the use of elastic scattering spectroscopy for biological diagnosis was known. We have undertaken some basic experiments to understand what volume of tissue was being interrogated by the pulse of white light used and also to find new ways of interpreting the spectra obtained from tissue to make the analysis as simple and accurate as possible. We have looked particularly at ways of eliminating spectral features due to absorption of the light by chromophores, so maximizing the information available from the rest of the spectrum.

### **Experimental work:**

#### **Assessment of the volume of tissue studied**

Prior to gathering data on patients, preliminary experiments were undertaken on ex vivo tissue to ascertain the volume of tissue that was being interrogated by the optical probe. Breast tissue is very heterogeneous so if tissue from a large radius around the probe was contributing to the optical reading then we would have to look at larger areas of tissue histologically which may have many different tissue subtypes within it. This would make correlation between the optical biopsy and a specific tissue type more challenging. On the other hand, if the radius was very small then we would need to be extremely specific about which tissue we removed for histology. If the optical biopsy technique is to become a useful diagnostic tool, it is important to know how accurately the probe needs to be positioned in relation to a small, image detected lesion. For a conventional biopsy, part of the lesion itself must be removed for histologic examination whereas with an optical biopsy it may only be necessary for the tip of the optical fiber to be close to the lesion to get useful diagnostic information from the reflected light. However, in this case, it is essential to know how close to the lesion the fiber tip must be.

Two experiments were devised:

- a) A small hole was made in the center of a flat piece of aluminum and a device fitted to clamp the tip of the optical probe flush with the metal surface. The breast tissue was placed on the end of the probe and thin layers removed sequentially until the optical signature changed.
- b) On a piece of raw pork, optical measurements were made as the probe was moved in 1mm steps across the muscle towards the muscle-fat interface until the optical signal changed. As muscle and fat have grossly different optical properties, this would determine when the signal from the fat was contributing to the detected optical spectrum.

From theoretical considerations, the distance from the fiber tip from which light may contribute to the detected optical signal is about 1mm. Both our experiments

confirmed this result. Tissue up to a distance of 1mm from the tip of the probe could influence the spectrum, but tissue further away could not. We concluded that with the geometry of the probe as it is constructed at present, the volume of tissue interrogated is of the order of  $2\text{mm}^3$ . Thus conventional biopsy specimens needed to be taken within about 1mm of the site of the optical measurement for accurate correlation of the two.

### **Absorption by hemoglobin**

Usually the strongest chromophore in normal breast tissue in the visible part of the spectrum is hemoglobin (in both oxygenated and deoxygenated forms). In purely adipose tissue or if a blue dye has been used intra-operatively to locate the sentinel node then other chromophores may dominate. In our spectra, it was noticed that the hemoglobin absorption curves from different tissue types showed some obvious similarities. This raised the possibility of measuring the relative hemoglobin absorption within each spectrum. Not just might this give an approximation of the saturation and hematocrit levels within the tissue but this measurement could be used to attempt to remove the hemoglobin absorption contribution from each spectrum. If this could be done, it might reveal more diagnostic information from the remaining, underlying, parts of the spectrum.

The first problem was that the absorption spectra of oxy- and de-oxy hemoglobin, although similar in overall form, have slight differences in the position of their absorption maxima. The relative amounts of oxy- and de-oxy hemoglobin vary within tissue and also the overall amount of blood in the tissue, as well as any concentration of blood between the tip of the probe and the tissue, could vary over a large range. However, the separate oxy-Hb and deoxy-Hb peaks are sufficiently different to be recognisable so two experiments were devised to quantify the values for the absorption spectra to be used on the data we collected from patients.

- 1) Firstly a sample of venous blood (nominal Hb 12g/dL) was acquired and a series of concentrations were obtained with saline using a double dilution method. The concentrations ranged over 4 orders of magnitude i.e. 1:0 to 1:32768; blood:saline and ESS spectra were obtained from each concentration. A super linear relationship to absorption was found for concentrations below 1:256 but a linear relationship was observed over 2 orders of magnitude spanning 1:256 to 1:32768 which corresponds to the concentrations observed in-vivo. Using this data we can now obtain a relative concentration of blood for any given spectra, which could then be used as an additional factor in the analysis. The same change in super-linear to linear absorption was observed when the dilutant mixture contained a scatterer (Intralipid 10%).
- 2) In order to assess deoxy- and oxyhaemoglobin absorption we used a venous blood:saline concentration of 1:512 (inside the linear range) and gently bubbled pure oxygen through the solution for 5-10 minutes, until no further colour change was observed in the solution. A spectrum was obtained which therefore only

reflected absorption from oxy-haemoglobin, the pure oxy-Hb absorption spectrum could be obtained by examining the negative logarithm of the intensities after subtracting a reference reading. Next, we bubbled pure nitrogen through the same solution for a further 5-10 minutes and obtained a spectrum, which reflected absorption by pure deoxy-haemoglobin. Using these two as approximate end points, it was then possible to produce a composite absorption curve for any value of blood oxygenation, and this data could then be used to normalize tissue spectra after calculation of a relative value for oxygen concentration.

These two experiments have allowed us to account for, and hence normalize, different levels of saturation and amounts of blood on or within the tissue that is being sampled. This concept has also made us wonder if this technique could be used as a way of monitoring the level of oxygen saturation of blood, although this awaits further exploration.

Similar experiments to determine the absorption spectra, in the particular backscattering geometry of the instrument, have been conducted for the blue dye used in sentinel node location and are planned to determine the exact absorption pattern of  $\beta$ -carotene.

#### **Fiber probe development:**

All fiber probes used in these studies have been designed and fabricated by co-investigators at Los Alamos National Laboratory and supplied to both clinical sites. The optical geometry of all the probes has been standardized so as to provide maximum consistency of measurement conditions for all studies. For all probe designs the illumination fiber (carrying light from the pulsed arc lamp to the tissue) has a core of 400  $\mu\text{m}$  diameter and the signal (collection) fiber has a core diameter of 200  $\mu\text{m}$ . From modelling studies the predicted volume of tissue that is probed optically is approximately 500  $\mu\text{m}$  long, 300  $\mu\text{m}$  wide and 300  $\mu\text{m}$  deep, although from our experimental studies, there is some effect from tissue up to about 1mm from the probe tip.

Two different types of probes have been fabricated for the first series of clinical measurements: one type for interstitial measurements through a transdermal needle, and the other for direct superficial measurement during open surgery. For the interstitial application two variations of probe have been fabricated. One provides the smallest possible total probe diameter, for use through 18-gauge needles. This type has a polyamide outer protective sheath with an external diameter of approximately 900 microns. However, all transdermal optical measurements are correlated with a core biopsy from the same site, so a second transdermal probe was designed to fit the inner diameter of the guide needle part of the standard core-biopsy needle (MANAM<sup>TM</sup> automatic cutting needle). This probe has a surgical stainless steel sheath with a diameter of about 1.78mm, which permits easy insertion through the core-biopsy needle.



The other general type of probe was designed for easier manipulation by surgeons during breast surgery. It has a 5-mm diameter outer sheath of surgical stainless steel, and the fibers are fixed in the center, the remaining volume being filled with optically-opaque epoxy. This probe design is easier to handle for surgeons wearing gloves, and helps to reduce the intensity of ambient light that reaches the collection fiber.

We have conducted studies of robustness of our probes against various types of sterilization. Ethylene oxide can be used with any of them, but that method is expensive and must be scheduled one or two days in advance of the expected use. The probes can also be sterilized with standard immersion fluids (such as glutaraldehyde), but this requires keeping the SMA connector ends of the probes out of the fluid because of possible corrosion of the polished metal mating parts. Moreover, many hospitals are reducing the use of biostatic fluids both because of potential harm to workers and environment, and because of some questions about reliability of sterilization. Ideally, we wish to be able to sterilize the probes by autoclave, which is reliable, safe and inexpensive. To that end we have changed some of the medical-grade materials used, especially the bonding epoxies, and have successfully tested the various components of the probes in several autoclave cycles, although we are still short of developing a fully autoclavable probe.

We have begun experimental testing of fiber probes using illumination fibers with larger numerical aperture than that of standard quartz fibers, as large as 0.40. We expect that this will permit tighter fiber bends without light loss, when compared with the standard fiber numerical aperture of 0.22. This would provide advantages for use in tight working environments, where the fibres may undergo severe bending between the probe and the spectrometer unit. We are also looking at developing smaller and more portable spectrometer units, which require less floor space in theatre, are easier to take from one location to another and are faster to set up, therefore allowing more data to be collected.

#### **Patient enrolment, optical biopsy and histologic sampling:**

Clinical measurements are being taken with both types of fiber developed at Los Alamos. The principles are shown in Figs 1 and 2 in the attached paper (Appendix 1). The first studies were undertaken on excised human breast tissue within 1 hour of surgery as in this situation it is straightforward to be sure that optical measurements and tissue biopsies are taken from exactly the same site. These optical readings were obtained with the transmitting and detecting optical fibers held in the rigid 5 mm diameter probe. This was convenient for laboratory and open surgery studies but was too large for percutaneous measurements for which the smaller flexible probe was developed, small enough to pass through an 18-gauge biopsy needle. Following the initial studies on excised breast tissue, optical measurements have been obtained in three situations. All patients were enrolled into the study after the details had been explained to them and they had given full written consent.

To test the viability of taking ex-vivo measurements we conducted an experiment to determine how the optical properties of tissue change after removal from the body i.e.

changes due to cooling, dehydration, loss of circulating blood and possible deoxygenation. If we could show that the optical readings from breast tissue were essentially similar both *in-* and *ex-vivo* then it would be possible to obtain readings from mastectomy specimens immediately after excision in the operating room. This would greatly increase the number of data sets we could obtain for training the system. One method of testing this was to mark a small area of breast tissue in a tumor bed following wide local excision of a breast cancer and obtain an optical reading *in-vivo*. This area would then be excised with a small cuff of surrounding tissue and serial measurements would be taken over time on the same point. Alternatively in order to define the point of observation uniquely and maintain the position of the probe a canular from an appropriately gauged needle was sewn into position within the incompletely excised specimen and a spectrum was obtained. After the excision was complete the probe was re-inserted into the canular and a timed series of spectra were obtained over a period of up to two hours. Although variants of this procedure have been performed on five patients to date the numbers are too small to draw absolute conclusions although they strongly suggest that spectra obtained within a period of thirty minutes following excision contain very similar information to those taken *in-vivo*. Over time, a gradual shift in the oxygen absorption curves was seen, although the overall shape of the spectra did not change remarkably. Analysis is ongoing to determine if the small change is significant before embarking on obtaining further *ex-vivo* measurements. In the meantime we have concentrated on obtaining only *in-vivo* measurements by the methods outlined below.

**a) Percutaneous measurement:**

These were done on patients undergoing surgery for either benign or malignant conditions of the breast. Once the patient was anesthetized, a core-cut (14 French gauge) biopsy needle was inserted into the tumor through the skin (in the case of cancers or suspected cancers, the needle was inserted through skin that would be removed as part of the surgical procedure). When it was in the correct position, the inner needle was removed and the thin optical probe inserted for measurements to be taken. Once a satisfactory spectrum had been obtained, the core-cut needle was reassembled taking great care not to move the tip of the needle relative to the tumor. A standard tissue biopsy could then be obtained which contained the area of tissue that had been interrogated optically. After this, the scheduled surgery was performed.

**b) Examination of tumor bed:**

During wide local excision of a breast cancer, it is often difficult for the surgeon to identify the tumor margins just by direct inspection of the surgical wound. In this situation, biopsies are taken to see if there is still cancer present. When this was required, optical measurements were taken of the same site immediately prior to the conventional biopsy and the results correlated.

**c) Sentinel and other axillary lymph nodes:**

All breast cancers have the ability to metastasize to lymph nodes (glands) in the axilla. Knowledge of whether or not this has occurred is important in determining the stage of the cancer i.e. degree of spread. This gives an indication of a patient's prognosis and may determine if adjuvant treatment such as chemotherapy is warranted. The sentinel node is the first lymph node that drains the breast and is now recognized as a marker for axillary lymph node involvement with cancer. If the sentinel node is clear of cancer then the chance of any other node being involved with cancer is extremely small [1]. The sentinel node can be identified by various dye labeling techniques, but once found and removed, it must be assessed histologically either by frozen section while the patient remains anesthetized, or later, by paraffin embedded section. If the node is involved with cancer, then the other nodes in the axilla need to be removed. It would be simpler if the other nodes could be removed at the same operation, but this is only possible if one can get a rapid answer on whether or not the sentinel node is involved. The optical biopsy could provide this answer. We are now taking optical measurements on sentinel nodes as well as other resected nodes, immediately after surgical excision and correlating the results with subsequent conventional histology. Further details of the methods are given in the attached paper (Appendix 1).

#### **Data collection, recording and analysis:**

All optical data collected from patients was automatically recorded on a laptop computer, which runs the optical biopsy system. This is backed up onto disc after each new data set. The raw data is transferred into a spreadsheet file along with the corresponding histologic diagnosis. These files are used for analysis in both Los Alamos and London. Examples of the spectra obtained are shown in Figs 3 and 4 in the attached paper (Appendix 1).

#### **Development of spectral classification methods:**

Initially two different automated methods of spectral classification were used to assess the degree of correlation between pathology and spectral pattern differences: artificial neural networks and hierarchical cluster analysis. Artificial neural networks (ANNs) were selected for study because of the expectation by our group and other researchers [2, 3] that ANNs would prove to be a generally useful method of tissue spectral classification. ANNs are well suited for classification in systems where model-based classification is difficult. Such is the case with ESS spectra of breast tissue because of its remarkable heterogeneity of tissue types (comprising glandular, adipose, fibrous, tubular, connective and other tissue types) with consequent broad variability in optical scattering and absorption properties. Hierarchical cluster analysis (HCA) was selected for study as an alternative to the many approaches to classification that provide unbounded class regions (including linear discriminant analysis, regression analysis and ANNs). Further details of these approaches are given in the attached paper (Appendix 1).

In the second year of this program while the analysis detailed above has continued at Los Alamos, the analytical approach has been expanded in London to concentrate on a model based analysis (MBA) approach where certain consistent features within the

spectra are analyzed and accounted for. Such features might include the hemoglobin concentration (as mentioned above in the section on experimental work), the presence of blue dye or an absorption spectrum for  $\beta$ -carotene, which is only present in fat and not in tumors. In addition a number of invariant linear portions were noted by careful observation and linear approximations could be found for these sections. The remaining part of the procedure is to break the spectrum up into linear portions and using a process of line-fitting and repeated re-normalisation reduce the raw input to a series of gradients, intercepts and absorption co-efficients. When referenced to experimental measurements the absorption coefficients can be successfully converted to concentrations (or saturations in the case of Haemoglobin). The reduced set of descriptors (~30 as opposed to 1800 values for the whole raw spectrum) could then be fed as inputs into an appropriate neural net or hierarchical cluster model, for convenience, and to avoid repetition of effort between London and Los Alamos, the analysis of the model based results was done with a linear discriminant based method using the package SYSTAT. This pre-processing could result in a dramatic reduction in overall processing time and also the ability to get relative values between different spectra at certain fixed points.

#### **Data analysis results:**

Data sets are now available from a total of 86 patients recruited in London (71) and Little Rock (15). These patients yielded a total of 360 matched pairs of optical and conventional histopathological data. Although an average of 3 spectra were taken from each site there is an excellent correlation between successive spectra taken from the same site, shown statistically by  $r^2$  values for the cross correlation between separate spectra of >95% (>99% in the majority of cases). This shows consistency in the readings and allows multiple spectra from a single site to be averaged, further reducing the noise level. The sites studied included 67 percutaneous biopsies (TRU-CUT), 96 tumor margins examined during surgery, 45 specimens of breast tissue examined immediately after surgical removal and 134 from axillary nodes, also examined immediately after excision. Some measurements have been taken on exterior tissue to look at the possibility of identifying Paget's disease of the nipple in-situ. Currently this part of the investigation is at an early stage and although the diseases are related the spectra are not suitable for inclusion in the breast cancer analysis.

Unfortunately, a series of technical problems have hindered the data collection in Little Rock. The main problems were with the laptop computer that was used to drive the system and the spectrometer that was installed in the Arkansas version of the optical biopsy hardware. The laptop had problems running the spectrometer software, principally in controlling the analogue to digital converter card and the 16-bit version of the software. The Los Alamos team thinks that changing the operating system on the laptop may cure at least some of these problems and this is now being done. A more serious fault was found on the spectrometer as it was misaligned at the time of its original set-up and was registering the wrong range of wavelengths. This was only recognized when a batch of data from Little Rock was being compared with data taken in London and it was observed that the heme absorption peaks from the two spectrometers did not match up. Regrettably, it is doubtful if the data taken with the

misaligned instrument can be used. Nevertheless, we believe that these teething problems with what are really only prototype instruments are now largely resolved so future data collected in Little Rock should be more reliable.

Fortunately, even without the Little Rock data we have some 615 reliable spectra from a total of 300 sites in 54 patients (not including 17 patients in the pilot study, when we were learning how to use the instrument). These sites include 57 percutaneous needle biopsies, 57 inoperative tumor bed sites, 39 ex vivo measurements on breast tissue and 129 ex vivo measurements on axillary lymph nodes (typically 2 per node). The conventional histology showed that the breast tissues examined included evidence of 19 invasive cancers, 4 showing carcinoma in situ, 2 with atypical ductal or lobular hyperplasia and 34 with benign breast disease (including fibrosis, sclerosing adenosis and other non malignant lumps). The rest showed a mixture of normal fibrous, fatty or lobular breast tissue. In the lymph nodes, 30 showed metastatic cancer, 11 showed reactive changes and the rest were examples of normal lymphatic tissue.

For all analyses the spectra from breast tissues and sentinel nodes were examined separately since they are basically different tissues. For the modes of analysis used at Los Alamos the spectra were pre-processed by first normalizing each spectrum to the same total integral over the spectral range of 350 to 750 nm ensuring that only spectral shapes were compared and not total scattering efficiencies. For the London analysis the pre-processing routines were more complex and some aspects have been described above.

In presenting the statistical results, sensitivity and specificity are defined in the standard way:

$$\text{Sensitivity} = TP/(TP + FN) \quad \& \quad \text{Specificity} = TN/(TN + FP)$$

Where TP, FP, TN and FN represent the numbers of true positives, false positives, true negatives and false negatives, respectively, as determined by the corresponding histopathology. For the training and testing of the ANN's we randomly chose 80% of the data samples as a training set, reserving the remaining 20% as the test set. This was repeated three times with three different random choices of the 80/20 split. Results from the three different types of analysis for detecting cancer in both breast tissue and lymph nodes are shown below:

Table 1: Sensitivity and specificity for detection of cancer in breast tissue

	ANN	HCA	MBA
Sensitivity	69%	67%	94%
Specificity	85%	79%	92%

Table 2: Sensitivity and specificity for detection of cancer in axillary lymph nodes

	ANN	HCA	MBA
Sensitivity	58%	91%	57%
Specificity	93%	76%	85%

ANN: Artificial Neural Network, HCA: Hierarchical Cluster Analysis and MBA: Model Based Analysis

### **Complementary studies of scattering from cell suspensions:**

Under independent funding from a NCI/NIH grant, Dr. Judith R. Mourant, a colleague of Dr. Bigio at Los Alamos, has been studying the intrinsic scattering properties of parallel cell lines (cancerous and non cancerous). These studies demonstrate that the optical geometry of the fiber probes, as utilized for our breast cancer study, accentuates sensitivity of the collected scattering spectrum to variations in nuclear size and density, which are associated with malignancy [4, 5].

### **Complementary studies providing further optical biopsy data:**

Under separate hospital funding in London, Dr Laurence Lovat, a colleague of Prof Bown, has used the flexible optical probe to make optical measurements endoscopically on a range of lesions in the gastrointestinal tract that required a conventional biopsy, so the optical and conventional biopsies could be correlated. This study is showing particular promise in identifying areas of pre-malignant change in Barrett's esophagus, which can not be seen by conventional endoscopy alone. This is an increasingly important problem as the incidence of cancers in this site is increasing faster than for any other solid organ. A second study, in conjunction with the department of dermatology at UCL, has also been started where optical measurements are taken from suspicious pigmented skin lesions, which are undergoing surgical excision for histological analysis. The aim of this study is to develop an algorithm that will allow discrimination between benign and dysplastic naevi and malignant melanoma. This would have huge potential as a method of gaining immediate diagnostic information of any suspicious lesion so reducing the need for surgical biopsy. Early results have been encouraging and the increased numbers of matched pairs of optical and histologic data obtained by these means have helped to develop techniques for analyzing the optical data from the breast studies.

### **Comment:**

The results on breast tissue so far are remarkably encouraging and we hope that as the number of measurements increases, we will be able to consolidate and confirm the promising sensitivity and specificity found so far. A lot more work is required to find the best way to analyze the spectra we have. We need to identify the features that best distinguish between normal and malignant tissue and to find as simple a way as possible to interpret the results to minimize the computing time required. The model based analysis developed over the last year seems a lot simpler than the artificial neural networks and hierarchical cluster analysis used in the first year and is giving

comparable results, so this will be explored further in the next year. The hope is that an algorithm can be developed for rapid analysis of spectra so that in the clinical setting, the technique can be used to give almost immediate discrimination between benign and malignant tissue with a reliability that is comparable to conventional histology.

## **Objective 2: Improve treatment of breast cancer by using ILP.**

### **2A: Detection of residual cancer after ILP by contrast enhanced MRI:**

### **2B: Real-time, dynamic monitoring of ILP in an interventional MR scanner:**

These two parts of the program are being undertaken on the same group of patients. In London and Little Rock, both these studies had been started under separate funding prior to award of the present grant, although various practical and administrative problems have been encountered in the current running of these programs, which have seriously delayed patient recruitment.

#### **Patient selection:**

The patients invited to participate in this study are those with a proven small (up to 2cm) carcinoma in the breast who are scheduled for routine surgery (wide local excision or mastectomy). Further exclusion criteria are no previous radiotherapy or surgery to the lesion to be treated and no contraindication to MR imaging agents.

#### **Needle insertion and imaging during laser therapy:**

The systems used are different in the two centres. In London, the preliminary real time studies were done in a 1T scanner (Siemens). This gave good real time images of the developing area of laser induced necrosis, but the configuration of the scanner made it difficult to keep the needles and laser fibers in the correct position as they had to be inserted with the patient outside the scanner and tended to be dislodged sliding the patient into the magnetic field. To overcome this problem, a 0.2T interventional MR scanner was purchased. It was thought that this field would be strong enough to get real time images of the thermal effects produced by the laser, but at the time no data were available to see if this was true. Unfortunately, the 0.2T field has proved to be too weak to get reliable real time images of the laser effects. We have tried to find new pulse sequences to overcome this problem, but so far, have not succeeded. Thus, it has not been possible as yet to get new data on real time imaging of ILP in London. A new coil has however recently been purchased through separate funding with allows easier access to the breast and it is hoped this will allow real time imaging to recommence.

All patients had contrast enhanced MR scans to establish the full extent of the cancer being treated. This was done with Fast Low Angle Shot (FLASH) sequences. Needle insertion was performed either under ultrasound scanning (if the lesion was easily visible with this method) or MR guidance in the interventional 0.2T scanner.

In Little Rock, fiber placement was done using a high contrast, high resolution MR imaging method called RODEO (ROtating Delivery of Excitation Off-resonance) which was developed by the group there specifically for breast cancer imaging [6-8]. This has been used in over 1200 breast examinations (one of the world's largest series) and in 400 cases, its accuracy in demonstrating the true extent of cancers has been validated by rigorous pathological analysis of mastectomy specimens. The sensitivity (94%) and specificity (66%) were twice that of conventional breast imaging when the same cases were evaluated by readers who were blinded to the results of the other examination. Further, the MR demonstration of additional undetected disease foci in 38% of breasts closely approximates the prevalence of "sub-clinical" disease that is reported in rigorous pathological analysis.

For ILP treatment, the aim is to completely ablate the small cancers, assess the completeness of ablation on contrast enhanced MR scans prior to surgery and then carefully examine the surgical specimen to see if the MR scans detected any untreated areas of cancer. Thus accurate placement of the laser fibres is essential which requires reliable breast stabilization. In Little Rock, this is done using a commercial prototype stereotaxic localization and biopsy unit manufactured by MRI devices, Inc. This permits highly accurate placement of needles and localization wires at multiple locations. This is a c-arm approach which is unique for MR localization and allows flexibility in the selection of approaches so that the needle tract can be included in the operative field. In conjunction with this unit, thermal setting plastic will be used to achieve breast stabilization as an alternative to breast compression, which is uncomfortable for the patient.

After the patient has been positioned on the table and the breast stabilized with the thermal setting plastic, pre- and post-contrast 128 slice RODEO scans will be obtained for localization. Gadopentate dimeglumine will be used as contrast medium. Fiducial markers will be used to correct for gradient nonlinearity of the MR imaging coordinates, providing 3-D markers for localization and subsequent positioning of the needle. While remaining in position on the stereotaxic table, the patient will be moved to the front of the magnet where the stereotaxic c-arm is located. Local anesthetic will be injected and a needle placed in the centre of the lesion for laser fiber insertion. Once the fiber is in place, the patient will be returned to the magnet centre and laser ablation begun, as described previously using the Diomed (Cambridge UK) diode laser.

During laser ablation, MR scans will be obtained at 2 minute intervals using rapid 32 slice acquisitions. During heating, a zone of hypointensity appears on the MR images around the laser tip due to the phase change resulting from cellular death. When this hypointense zone adequately covers the post-contrast tumor image and an adequate apparently disease free margin, the heating will be discontinued. At the conclusion of



the ILP, the patient will again be moved from the magnet centre to the stereotaxic c-arm at the front of the magnet. Using the c-arm, the localization wires will be placed at the margins of the hypointense region and these will be used as boundary markers of the treatment zone for subsequent histopathology examination. A repeat MR will be done to confirm appropriate positioning of the wire. The patient will then undergo surgery (lumpectomy or mastectomy) for removal of the lesion. Detailed pathologic analysis of the surgical specimen will be undertaken to correlate the extent of laser damage seen under the microscope with the changes seen on the MR scans.

### **Results:**

This part of the program has been very slow for several reasons. In London, several other research programs on early breast cancer started at the same time as this one resulting in competition for recruitment of suitable patients. We are tackling this by making arrangements for appropriate patients to be identified in another hospitals and then referred to us. This has now been set up but recruitment has still been poor. During the second year, the program has been further handicapped by the emigration of the senior surgeon and many months of inability to undertake interventional procedures by the interventional radiologist following a skiing accident.

The problem of the low magnetic field in our interventional MR scanner is also proving extremely difficult to tackle. We have no solution at present and so task 2b, real time imaging of ILP in the MR scanner, may have to be limited to Little Rock, although we will continue to look for a way out of this problem.

In Little Rock there have been delays starting the program due to contractual problems (difficulties reconciling standard research contracts from each side of the Atlantic) but these have now been sorted out so the necessary contracts could be signed and it is hoped that there will be a better rate of recruitment from now onwards. There have also been some technical problems in Little Rock using a newer MRI stereotaxic device from Fischer Imaging but the arrival of some equipment modifications will hopefully allow this system to be used. This should give more accurate needle placement.

Only 4 patients have been treated so far on this protocol, and we do not yet have a full analysis to correlate the MR and pathologic findings although some patients have been treated at earlier date at both centers with funding from previous grants.

### **2C: Long term healing after ILP to benign fibroadenomas of the breast.**

This study was undertaken to understand how laser treated areas in the breast heal as it was felt inappropriate to leave laser treated cancers in the breast for an extended period of time at an early stage of this project. The technique of treatment was essentially the same as for interstitial laser photocoagulation of breast cancers, but most of the imaging was done using ultrasound rather than MRI. This was done for several reasons: fibroadenomas are much easier to define on ultrasound than MRI, so the simpler and cheaper imaging option was chosen and further, if part of the lesion was

missed or inadequately treated, it would not have the same serious consequences for the patient as if part of a cancer was missed.

The patients included in this study were those with palpable breast lumps confirmed to be benign fibroadenomas on clinical examination, ultrasound scan and fine needle aspiration. Some of the patients included in this study were first treated prior to the start of the present grant but their follow up was completed as part of the current program. Full details are given in the appended publication "Interstitial Laser Photocoagulation for Fibroadenomas of the Breast" (Appendix 2). The key findings were that the median reduction in lesion size after treatment, as measured on ultrasound, was 38% at 3 months, 60% at 6 months and 100% at 12 months. Of the 12 lesions scanned a year after treatment, none could be detected clinically and only one was detected on ultrasound. The treatment was a simple day case procedure. The only complication of note was a minor skin burn seen in 3 patients early in the series and since the technique was modified to protect the skin by cooling, this has not occurred again.

A further 20 patients have been treated since this program began, but the follow up period is not yet long enough for the results to be available. A control group of 14 patients with a total of 27 fibroadenomas has also been identified to monitor for the natural history of the condition. Full results on these individuals will be available at the end of this program in another year's time.

One of the anxieties at the outset of this program for treating breast cancer was that laser treatment, even if completely successful, would replace a palpable cancer in the breast with a palpable lump of scar tissue. We thought this would cause patients considerable anxiety, as they would worry that the cancer was still there. We have been very encouraged to find from this study on fibroadenomas that all the tissue necrosed by laser treatment appears to be resorbed without leaving any palpable scar tissue, even if this can take up to a year. This will make ILP a more attractive option to many patients.

## **2D: Delayed surgery after ILP in patients over 65 years treated with Tamoxifen.**

This study was undertaken as a first step to understanding how laser treated breast cancers heal if they are not removed by conventional surgery shortly after ILP. This group of patients was chosen, as treating them with tamoxifen to shrink the cancer for 3 months prior to surgery is an accepted treatment option in the United Kingdom. The technique for the laser treatment itself is exactly the same as used for patients treated with ILP just before surgery. Treatment was planned to cover the entire tumor, but the main aim of the study was to see if MRI could detect incompletely ablated cancers, so it was desirable that in some cases, ablation should be incomplete. This was acceptable as all patients were being treated with tamoxifen. All patients have pre-ILP, interim (6 weeks) and pre-surgery (3 months) MR scans (contrast enhanced) and the scans are correlated with the histological findings on the surgical specimen.

**Results:**

The number of patients suitable for this study is quite small and it is only being carried out in London. To date, 6 patients have been recruited for ILP and so far 4 have had surgery 3 months later. In the surgical specimens, 2 patients had residual tumor. In one patient this was detected as a 2mm area of increased enhancement on the pre-surgery scan. As the specimens are orientated in the transverse plane, we were able to confirm that the abnormality on the MR scan corresponded exactly with the abnormality seen on histology. In the second patient, there was minimal enhancement on pre-operative scans so attempts to identify the extent of residual tumor after treatment were unsatisfactory.

**Comment:**

The number of patients recruited so far on this protocol is small, but it is encouraging that a residual cancer as small as 2mm could be detected and that no areas of viable cancer were found on the surgical specimens that had not been seen on the MR scans. Recruitment for this study will continue over the next year.

## **7. KEY RESEARCH ACCOMPLISHMENTS**

### **Part 1: Optical diagnosis of breast cancer:**

Reliable optical probes have been developed which are suitable for examination of tissue exposed at open surgery, ex-vivo tissue (lymph nodes) and for percutaneous use through needles.

Optical spectra from tissue are straightforward to take and are reproducible, although there are still technical problems with some of the recording equipment.

Spectral data sets have been analyzed using Artificial Neural Networks (ANN), Hierarchical Cluster Analysis (HCA) and the much simpler model based analysis (MBA). The MBA undertaken recently has given results comparable to those from ANN's and HCA's but needs much less computer power, so may be a better way forward.

Depending on the method of analysis used, the sensitivity for detection of cancer ranged from 67-94% and 57-91% for breast tissue and lymph nodes respectively. The corresponding specificities were 79-92% and 76-93%.

Further work is required to improve the data analysis and to increase the size of the data sets, but these early results are most encouraging and suggest that the technique of optical biopsy might develop a useful role in clinical practice.

### **2. Optical treatment of breast cancer: Interstitial Laser Photocoagulation (ILP):**

Complete ablation of small, localized breast cancers with ILP is possible.

Residual tumor left after ILP as small as 2mm in diameter can be detected on contrast enhanced MR.

It is technically difficult to position the laser fibers at the correct sites, but systems are being developed to do this more easily and accurately.

Laser induced thermal destruction of cancers can be monitored by real time MR scanning, but it requires a high magnetic field (1T is adequate but 0.2T is not). We now have equipment in London, which we hope will enable us to perform this in the 1.5T scanner.

It may soon be possible to start studies treating small breast cancers with ILP without subsequent surgical excision.

MRI guided ILP may have lower costs and provide better cosmesis than surgical lumpectomy.

Long term follow up of fibroadenomas treated with ILP shows that the necrosed tissue is safely and completely resorbed without leaving a lump. It was not an original aim of the program, but this part of the study has shown that ILP is a simple and effective alternative to surgery for fibroadenomas. This could become a particularly attractive option in routine practice as the condition is common in young women who are naturally keen to avoid having a scar on their breast.

## 8. REPORTABLE OUTCOMES

### Journal articles / Book chapters:

1. Harms SE, Mumtaz H, Hyslop B, Klimberg S, Westbrook K, Korourian S: Magnetic Resonance Imaging Directed-Laser Lumpectomy. *Breast Diseases, A Year Book Quartely*, St. Louis; Mosby. 1998.
2. LM Lai, MA Hall-Craggs, H Mumtaz, PM Ripley, TI Davidson, MW Kissin, C Saunders, I Taylor, SG Bown. Interstitial laser photocoagulation for fibroadenomas of the breast. *The Breast* 1999; 8:89-94. **Included as appendix 2.**
3. Harms SE, Mumtaz H, Hyslop B, Klimberg S, Westbrook K, Korourian S: RODEO-MRI guided laser ablation of breast cancer. *SPIE* 1999; 3590:484-489.
4. C. D. O. Pickard, G. M. Briggs, L. Lovat, C. Saunders, P. M. Ripley, I. J. Bigio and S. G. Bown. Elastic Scattering Spectroscopy In-Vivo: Optical Biopsies of Cancers of the Breast and GI Tract. *SPIE Proceedings Vol.3917*
5. C. D. O. Pickard, G. M. Briggs, C. Saunders, P. M. Ripley, I. J. Bigio and S. G. Bown. Optical Biopsy: In-Vivo diagnosis of Breast Cancer using Elastic Scatter Spectroscopy. *SPIE Proceedings Vol.3907*, pp.592-599.
6. P. M. Ripley, D. Pickard, I. G. Rose, C. A. Kelley, I. J Bigio, G. Briggs, L. Lovat and S. G Bown. A Comparison of Artificial Intelligence Techniques for Spectral Classification in the Diagnosis of Human Pathologies based upon Optical Biopsy. *OSA Biomedical Topical Meetings Proceedings, 2000, MC5*
7. Bigio IJ, Bown SG, Briggs GM, Lakhani SR, Pickard CD, Ripley PM, Rose IG, Saunders CM: Diagnosis of breast cancer using elastic-scattering spectroscopy: preliminary clinical results. *Journal of Biomedical Optics* 2000; 5(2):221-228 **Included as appendix 1.**
8. Hall-Craggs MA, Smart S, Gillams A, Lees WR. MR monitored minimally invasive thermal therapies to the body. Editor I Young. John Wiley and Sons Ltd.
9. Hall-Craggs MA. Interstitial ablation therapy to breast tumors. *European Journal of Radiology* 2000;10(1): 59-62

### Presentations:

*The Wendy & Emery Reves International Breast Cancer Symposium October 1998, Dallas.*

“RODEO MRI Guided Laser Lumpectomy: The potential for treatment without disfigurement”. Harms S.

*Radiology Society of North America (RSNA). Nov 1998, Chicago.*

“Laser Lumpectomy with interactive MR imaging: Histopathological correlation”. Harms S.

*The International Society for Optical Engineering (SPIE). Jan 1999. San Diego.*

“RODEO MRI guided laser ablation of breast cancer”. Harms S.

*16<sup>th</sup> Annual Miami Breast Cancer Conference. Feb 1999. Miami.*

“Integration of MRI and treatment planning”. Harms S.

*British Breast Group. May 1999 Edinburgh.*

“Shedding Light on Breast Cancer”. Saunders CM.

**Abstract included as appendix 3**

*Biomedical Optical Spectroscopy and Diagnosis, (Munich, June 1999), OSA TOPS Vol. (1999, in press).*

Invited: "Optical Diagnosis and Treatment of Breast Cancer," Bigio IJ. and Bown SG.

*Interventional MRI, British Institute of Radiology. June 1999, London.*

“Thermal Ablation of Breast Tumors”. Briggs GM.

**Abstract included as appendix 4**

*Light for Life, (Cancun, Mexico, July 1999), Springer Verlag (1999, in press).*

Invited Plenary: "Minimally-invasive optical diagnosis and treatment of breast cancer," Bigio IJ. and Bown SG.

*Advances in Optics for Biotechnology, Medicine and Surgery, 1-6th August 1999, Kona, Hawaii, USA.*

“Diagnosis and Treatment of Breast Tumors through the combined use of Optical Biopsy and Interstitial Laser Photocoagulation”. Ripley PM.

*6<sup>th</sup> Nottingham International Breast Cancer Conference. Sept 1999, Nottingham.*

“Lasers – A minimally invasive way forward for breast tumors”. Briggs GM

*Magnetic Resonance Radiologists Association. Oct 1999. London.*

“Breast Biopsy and interstitial therapies”. Hall-Craggs MA.

*Breakthrough Breast Cancer meeting. Nov 1999, London.*

“New methods of breast biopsy and minimal invasive techniques”. Hall-Craggs M.

“Optical diagnosis of breast cancer”. Bown SG. **Abstract included as appendix 5.**

“Local destruction of breast cancer with laser”. Bown SG. **Abstract included as appendix 6.**

*High Care 2000, Feb 2000, Bochum, Germany*

“Optical Biopsy for Minimally-Invasive Diagnosis of Breast Cancer” Irving J. Bigio, Stephen G. Bown, Gavin Briggs, Christine Kelley, Sunil Lakhani, David Pickard, Paul M. Ripley, Ian G. Rose and Christobel Saunders

*Era of Hope. June 2000, Atlanta.*

“Interstitial laser photocoagulation for treatment of breast tumours”. Oral presentation by Bown, S.G. and poster presentation by Briggs, G.M.

“Optical biopsy for the diagnosis of breast tumours”. Pickard C.D.O.

British Society for Surgical Oncology, Nov. 2000, Nottingham

“Histological Assessment of Breast Tissue by Optical Biopsy” Briggs, G. M.

*Second International Congress on MR Mammography, Sept 2000, Jena Germany*

“Laser Treatment in Benign Breast Disease” Hall-Craggs, M. A.

“RODEO MRI Directed Laser Lumpectomy” Harms, S.

“Minimally Invasive Therapy in Breast Cancer” Hall Craggs, M. A.

“Optical Biopsy of Breast Tissues” Bigio, I. J., Bown, S. G., Briggs, G. and Hall-Craggs, M. A.

**Informatics:**

Set-up of a computer database, (Microsoft Access) for patient records. This includes patient details, treatment parameters, radiological and clinical follow-up, histology and any complications.

## 9. CONCLUSIONS

The work on optical diagnosis of breast cancer has proceeded extremely well. We now have a reliable system for taking optical readings at open surgery and through a biopsy needle. Analysis of the first 290 sets of paired optical and histologic data by artificial intelligence techniques has shown reasonably high specificity and sensitivity for the detection of cancer in breast tissue and sentinel nodes. The work in the second year using model based analysis has suggested that this simpler method may reduce the computing power required without jeopardizing the quality of the results, although more work is required to refine this approach. These good early results are encouraging, but much more data are required to know how reliable these measurements are. It is hoped that enough further data can be gathered over the next year to prepare a relatively simple algorithm for spectral analysis that can be run on a lap or palmtop to give an immediate indication of whether a particular spectrum is from normal or malignant tissue.

The studies on laser treatment have confirmed that it is feasible to completely ablate small cancers and that areas of viable cancer as small as 2mm in diameter remaining after ILP can be detected on contrast enhanced MR. We have also shown that laser induced thermal changes can be detected in real time during laser energy delivery and that these may be able to predict when enough heat has been delivered to destroy the entire cancer. However, it has also become clear that there are considerable technical problems involved in optimizing all aspects of the treatment. Real time monitoring only works in high magnetic field scanners (1.5T), but easy insertion of the fibers requires an interventional scanner, most of which currently only operate at low magnetic fields. In London, we have recently purchased a new 'open-access' breast coil, which we can use to place laser fibers into the breast and then move the patient into the high field strength, closed scanner. In this way we hope to use temperature sensitive, dynamic sequences which will allow 'real time' monitoring of the thermal necrosis. This program has the potential to provide a safe, relatively straightforward and effective treatment for selected small breast cancers that may have lower costs and better cosmesis than surgical lumpectomy.

The long term results from treating benign fibroadenomas have taught us a lot. The necrosed tissue is resorbed completely without leaving a residual lump of scar tissue in the breast and without any long term complications. This is very reassuring, as necrosed cancer tissue is likely to be resorbed in the same way. It is also good for patients psychologically as if any women could feel a residual lump in the breast after ILP for cancer, she would worry that there was still some malignant tissue left behind, even if repeat biopsies showed no evidence of cancer. This particular study was undertaken to understand how ILP treated cancers could be expected to heal. However, the results so far have been so impressive that if they are confirmed in the larger number of similar patients being treated in the present study, we are considering offering ILP as a routine treatment for benign fibroadenomas in patients who want active treatment but do not want open surgical excision. This could be of particular importance to women who have multiple fibroadenomas or who have a tendency to



keloid formation as the cosmetic result would be so much better than conventional surgery.

Overall, the progress on this program is good, although we have had considerable problems with patient recruitment for the cancer treatments. The optical biopsy results are encouraging and with further data and analysis this technique may be able to provide rapid pathological information that is comparable to that provided by conventional histology. Biologically, it looks realistic to aim for complete ablation of appropriately selected small breast cancers with ILP under MR guidance and to expect safe healing of the treated area. The real problems are technical. We need to improve techniques for positioning the laser fibers accurately in the target lesion and for monitoring therapy, both in real time and during subsequent follow up.

Studies on laser treatment of cancers will continue in the next year, but the existing problems of recruiting suitable patients are likely to continue and this will limit the amount of new information we can generate. Further data will be gathered on the long term follow up of ILP treated fibroadenomas. However, our most important advances have been made in the optical diagnosis part of this program and we should like to put the main emphasis on this in the next year.

## References:

1. Snider, H., *et al.*, *Sentinel node biopsy in the staging of breast cancer*. American Journal of Surgery, 1998. **176**(4): p. 305-10.
2. Ge, Z., K.T. Schomaker, and N.S. Nishioka, *Identification of colonic dysplasia and neoplasia by diffuse reflectance spectroscopy and pattern recognition techniques*. Appl. Spectroscopy, 1998. **52**: p. 833-839.
3. Osbourn, G., *et al.*, *Automated pattern recognition based on the visual empirical region of influence (VERI) method: A users guide*. .
4. Mourant, J., *Evidence of intrinsic differences in the light scattering properties of tumorigenic and non-tumorigenic cells*. Cancer Cytopathology, 1998. **84**(366-374).
5. Mourant, J., *Mechanisms of light scattering from biological cells relevant to non-invasive optical tissue diagnostics*. Appl. Optics, 1998. **37**: p. 3586-93.
6. Harms, S.E., *et al.*, *MR imaging of the breast with rotating delivery of excitation off resonance: clinical experience with pathologic correlation*. Radiology, 1993. **187**(2): p. 493-501.
7. Harms, S.E., *et al.*, *MR imaging of the breast: current status and future potential*. AJR. American Journal of Roentgenology, 1994. **163**(5): p. 1039-47.
8. Cross, M.J., *et al.*, *New horizons in the diagnosis and treatment of breast cancer using magnetic resonance imaging*. American Journal of Surgery, 1993. **166**(6): p. 749-53; discussion 753-5.

**Diagnosis of breast cancer using elastic-scattering spectroscopy:  
preliminary clinical results**

Irving J. Bigio<sup>1\*</sup>, Stephen G. Bown<sup>2</sup>, Gavin Briggs<sup>2</sup>, Sunil Lakhani<sup>3</sup>, David Pickard<sup>2</sup>, Paul M. Ripley<sup>1</sup>, Ian G. Rose<sup>1</sup> and Christobel Saunders<sup>4</sup>

<sup>1</sup> Los Alamos National Laboratory, MS-E535, Los Alamos, NM 87545, USA  
505-667-7748; fax: 505-665-4637; [ijb@LANL.gov](mailto:ijb@LANL.gov)

<sup>2</sup> National Medical Laser Centre, University College London, London W1P 7LD, UK

<sup>3</sup> Department of Histopathology, The Royal Free and University College Medical School, London W1P 7LD, UK

<sup>4</sup> Department of Surgery, The Royal Free and University College Medical School, London W1P 7LD, UK

**Abstract**

We report on the first stages of a clinical study designed to test the application of elastic-scattering spectroscopy, mediated by fiber-optic probes, for breast-tissue diagnosis. Three specific clinical applications are being investigated: 1) a transdermal needle measurement, intended to provide instant diagnosis with the minimal-invasiveness of fine-needle aspiration (FNA) but with sensitivity to a larger tissue volume than FNA; 2) a hand-held diagnostic probe for use in determining clearance, or otherwise, of resection margins during open surgery; and 3) use of the same probe for real-time assessment of the “sentinel” node during surgery to determine the presence or absence of tumor (metastatic). Preliminary results from *in vivo* measurements on 15 women are encouraging. For breast tissue 94 spectra were measured on 32 histology sites, and for sentinel nodes 75 spectra were measured on 29 histology sites. Two different artificial intelligence methods of spectral classification were utilized. Artificial neural networks yielded sensitivities of 100% and 83.3%, and specificities of 100% and 100%, for breast tissue and sentinel nodes, respectively. Hierarchical cluster analysis yielded sensitivities of 93.7% and 57.1%, and specificities of 92.3% and 85.2%, for breast tissue and sentinel nodes, respectively. The reliability of these numbers is limited by the small sizes of the data sets, and improved statistics are expected as the data sets continue to grow. The study is expected to enroll up to 400 patients over the next two years.

**Keywords:** elastic-scattering spectroscopy; diffuse reflectance; tissue spectroscopy; optical diagnosis; optical biopsy.

## Introduction and background

Various types of optical spectroscopy have been investigated as methods of "optical biopsy," with a majority of research efforts focusing on UV-induced fluorescence or Raman spectroscopies. [For a review of the topic, see, for example, Ref. 1 or references contained therein.] Recently, elastic-scattering spectroscopy (sometimes called "diffuse reflectance spectroscopy") has been studied as a method for minimally-invasive optical diagnosis ("optical biopsy") of tissue pathologies, with emphasis on distinguishing dysplasia and cancer from normal tissue or other benign conditions[2,3,4] or for distinguishing normal tissue types.[5] Elastic-scattering spectroscopy (ESS), when performed using an appropriate optical geometry[6,7], is sensitive to the size and structure of the sub-cellular components that change upon transformation to premalignant or malignant conditions (e.g., the nucleus, mitochondria, etc.).[8] In work reported to date, clinical application of the ESS technique has been fundamentally noninvasive, with access to the tissue mediated by endoscopes [2,3,4,7] or by means of direct topical access, as would be appropriate for diagnosis on the cervix.[9,10]

Within solid organs, such as the breast, the least invasive diagnosis requires access through a needle. Most early breast cancers are detected when an abnormality is seen on mammography, although some patients may detect a lump themselves. In either case, before any treatment is initiated, the diagnosis must be confirmed by fine-needle aspiration cytology (FNA) or biopsy (which is often done as an open procedure). Approximately 50,000 diagnostic lumpectomies are performed annually in the U.S. Of those, only about 12,000 turn out to be malignant when histology is performed on the excised tissue by a pathologist. If it had been known in advance that the remaining 38,000 lesions were benign, the potentially disfiguring surgery could have been avoided, along with the trauma and cost, as many benign lesions resolve spontaneously in time, without intervention. A core biopsy, through a large-gauge needle, is a frequent alternative to surgical resection or lumpectomy for biopsy. Although less invasive than core biopsy, FNA is only infrequently used in the U.S. because false-negative rates with FNA are often in the range 12-15% [11,12], and its reliability is under critical review. This is due to the heterogeneity of breast lesions and the relatively small number of cells accessed by FNA. Despite having the same level of invasiveness as FNA, the ESS method poses the potential advantage of immediate diagnosis, and there is the possibility of improved sensitivity when compared with FNA, due to the larger tissue volume that is sensed by the ESS method. If the optical biopsy technique based on ESS proves sufficiently reliable, it gives an immediate result which minimizes the time a patient must wait for a diagnosis and might make it realistic to treat a small cancer at the same clinic visit. This will reduce patient anxiety and reduce costs for the large number of patients who have suspicious areas seen on mammography. Image-guided optical biopsy either with magnetic resonance, ultrasound or conventional mammography could prove particularly valuable for patients with more than one suspicious area.

However, two other applications of ESS diagnosis to breast cancer may provide even greater patient benefits than the transdermal needle measurement. For open surgery procedures, the first of these is our effort to develop a probe for the surgeon to use during breast-conserving surgery (wide local excision or partial mastectomy) for determining the status of the resection margins in real time. In current surgical practice, especially when the tumor limits are not clearly visible, the surgeon (and anesthetized patient) are required to wait for pathology results on frozen section

to determine if tumor-free margins of excision have been established. Immediate frozen-section pathology is not always available, and, in real practice, with delayed pathology positive margins are found in as many as 20% to 55% of all breast-conserving surgeries [13], requiring a second surgical procedure.

The other possible important surgical application being investigated in this study, is to assess a "sentinel" lymph node in the axilla. For years, there has been controversy about how the axilla should be treated in breast cancer patients. Recent research has shown that if the main node in the axilla draining a tumor area, called the "sentinel" node, is removed and does *not* show cancer, then the chances of any other nodes in the axilla showing cancer are approaching 1%.[14] Thus, if the sentinel node does not show cancer, the rest of the axillary nodes can be left in place, but if it does show cancer, then a full surgical axillary-node clearance must be done. The sentinel node can be identified by injecting a radioactive marker and then scanning the axilla about 24 hours later (during surgical preparation) or by using a dye such as methylene blue, which can be easily detected in tissue during surgery. The ESS method may be able to provide immediate assessment of the sentinel node during surgery.

This diagnostic study is coupled, utilizing the same patient cohort, with a study of minimally-invasive optical treatment. In the case of focal lesions, treatment can be accomplished using interstitial laser photocoagulation with laser energy from a diode laser, again mediated by fiber-optics through a transdermal needle, to non-surgically treat both adenocarcinomas and fibroadenomas. Results for that part of the study will be reported in separate publication(s).

## **Materials and methods**

The clinical instrumentation based upon elastic-scattering spectroscopy is essentially similar to that described in publications on earlier clinical studies.[2,3] The system (see Figure 1) consists of a pulsed xenon-arc lamp (EG&G) for the light source, a PC-compatible spectrometer, (a modification of a spectrometer manufactured by Ocean Optics, Dunedin, Florida), which employs a linear CCD array for detection, an optical-fiber based probe, and a laptop computer for system control and data display. The wavelength range of the system is from 300 to 900nm, but the range used for these studies is 330-750 nm, which covers the near-UV-visible part of the electromagnetic spectrum. As depicted in Figure 2, the probe is designed to be used in (gentle) optical contact with the tissue and incorporates two optical fibers that are selected for their broadband light transmission over the spectral range used in the study. These fibers generally have core diameters of 200-400  $\mu\text{m}$ . The output of the arc lamp is coupled to one of the fibers, which transmits the light to the tissue target site. Similarly, a second adjacent, parallel fiber within the probe (usually of smaller diameter) is coupled to the spectrometer. The probe design fixes the collection fiber at a specified distance from the delivery fiber at the target site and is used to collect some of the elastically scattered light from the tissue. The collected light is then guided to the spectrometer where an optical spectrum is generated for further processing. For the probe geometry used in this study, the volume of tissue visited by the collected photons occupies a zone approximately 500  $\mu\text{m}$  long, 300  $\mu\text{m}$  wide and 300  $\mu\text{m}$  deep.

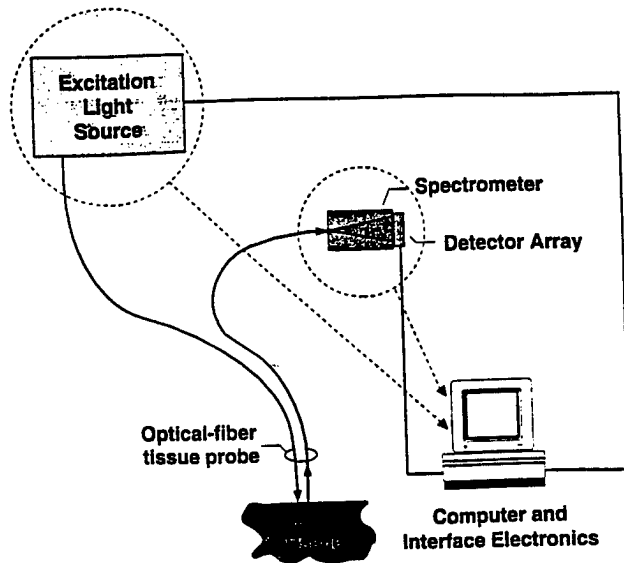


Fig. 1. Schematic diagram of the principal components of the ESS diagnostic system. All components (except for the fiber probe) are located inside a small, portable chassis.

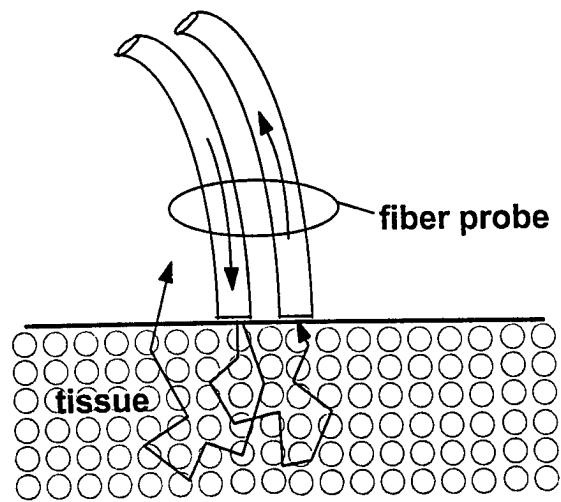


Fig. 2 Depiction of the optical geometry for the fiber-optic probe.

In clinical use the system automatically takes a background (“dark”) measurement without firing the lamp immediately (within 100 msec) prior to the tissue measurement. The entire measurement process, i.e., activating the spectrometer, triggering the arc lamp, reading the detector array with an A/D converter, etc., is computer controlled by a laptop PC, and can be triggered with a foot-pedal. This allows both accurate and reproducible measurements within the clinical setting. Furthermore, it also provides the clinician with the advantages of rapid data

acquisition and a graphical display for inspection. Typical data acquisition and display time is less than 1 second for a each site measurement. More specific details about the basic concepts of ESS and discussion about the optical system and the design philosophy of the optical fiber probe, can be found in previous publications. [6,15,16]

Prior to any clinical measurements the ESS system is calibrated with a reflectance standard. The reflectance standard (Spectralon™, Labsphere, Inc., North Sutton, New Hampshire) has a spectrally-flat, diffuse reflectance >98% over the entire wavelength range of the system. The purpose of referencing the system to a known standard is to allow the normalization of spectral data against the overall system response. This technique effectively minimizes any variations in the system response due to variations in the spectral transmission among different probes, thermal effects, coupling efficiency of the fiber probe, drifts in detector/spectrometer response, etc. The reference standard and probes are sterilized by autoclave, and the housing of the reference standard protects it from any airborne contaminants during surgery.

Two different optical-probe configurations have been fabricated for use in the clinical program. Both probes incorporate a "standardized" optical design, which specifies the diameters of the delivery and collection fibers, as well as the distance between the centers of the fibers. It should be noted that details of the probe's optical design, including the fiber sizes and separation, have a significant effect upon the characteristic spectra obtained for a particular tissue. Therefore, these parameters are standardized for each clinical study in order to optimize the sensitivity of the system to tissue variations and also to prevent spectral variations due to instrumental artifacts. The main difference between the two probes designed for this study entails the mechanical housing of the probe, allowing each to be optimized for the different specific clinical procedures. For interstitial, or transdermal, measurements a probes with a narrow ( 1 mm), stainless steel outer sheath were fabricated, which houses the optical fibers. The outer diameter of these probes was carefully chosen to be compatible with the inner-bore of current core-biopsy needles in use at the clinics, so that a probe could safely and easily be passed down the needle and presented to the tumor tissue under investigation. The second probe design incorporates a larger stainless steel sheath, ~5-mm diameter, to house the optical fibers. This creates an ergonomically convenient, pen-like design, which is utilized, hand-held, for optical measurements during open surgery, where both resected tumor margins and lymph nodes are addressed.

### ***In-vivo* measurement procedures**

All clinical measurements reported here have been performed at the Middlesex Hospital, University College London Hospitals, UK. Histological examination of all tissue samples has been performed by the same pathologist. Before any *in vivo* measurements were made, several *ex vivo* tissue samples obtained from resected breast specimens were measured with the ESS system. These initial findings were used to optimize the operational settings of the system, and also help to establish protocols for marking the "optical biopsy" sites for histological examination and correlation. Prior to surgery every patient within the study is informed about the research program, and they provide their informed consent for data to be taken. As mentioned in the previous section, three separate areas are currently under investigation and each warrants discussion due to the techniques employed in order to obtain the ESS spectra.

For interstitial measurements with the ESS system, a core-biopsy (Tru-cut™) needle is guided into the palpable lesion, sometimes with the aid of ultrasound or magnetic resonance imaging. The appropriate ESS optical probe is then inserted into the needle and gently placed in direct contact with the tissue at the needle's distal end. After the optical measurement has been made, a core biopsy is then taken from the same site, without moving the needle. The far tip of the tube-shaped core sample (which is opposite to the end of the tissue sample that was interrogated by the ESS probe) is marked with India-ink so that proper identification of the location examined with the ESS probe can be maintained and correlated with histology.

Following some of the core-biopsy procedures, patients immediately undergo surgery in order to have the tumor resected. In these and other surgical cases (not preceded by core biopsy), and depending upon the exact nature of the surgical procedure, measurements are taken from the tumor bed during and immediately after resection. Each optical measurement is followed by a small surgical biopsy of the same site, and the biopsy samples are coded to correlate with the ESS probe measurements.

With a subset of the surgical patients, assessment of the sentinel node is performed in order to determine the presence of metastatic disease. During the surgical procedure the sentinel node is located with the aid of radioactive tracer and/or blue dye (both injected previously into the tissue space near the tumor). The node is resected and cut in half, and ESS measurements are made on one or more sites on the cut surface of the node. Once again, the ESS measurement sites are clearly indicated so that the pathologist can provide the corresponding histological information about the exact locations measured.

### **Preliminary results and methods of classification**

Data were taken on 15 patients, with breast-tissue measurements being made on 12 of them and lymph-node measurements on 11 of them. The numbers of patients and measurements are summarized in Table 1. The last two columns list the histological designations for the sites measured optically, i.e., the numbers of true positives and true negatives. The numbers of spectra taken are larger than the numbers of corresponding biopsies because, frequently, biopsy specimens were significantly larger than the tissue volume measured optically, and more than one optical measurement was made. An effort was always made to mark precisely each site of optical measurement, so that corresponding histopathology could be properly correlated. In some cases, as in the case of measurements made through a core-biopsy needle, second measurements were made to provide information about repeatability.

**Table 1**

	Number of patients	Number of Biopsies	Number of ESS spectra	Number of cancer sites	Number of normal sites
Breast tissue	12	32	94	16	78
Sentinel nodes	11	29	75	21	54



Figures 3 and 4 show typical tissue spectra, malignant and non-malignant, for breast tissue and sentinel node tissue respectively.

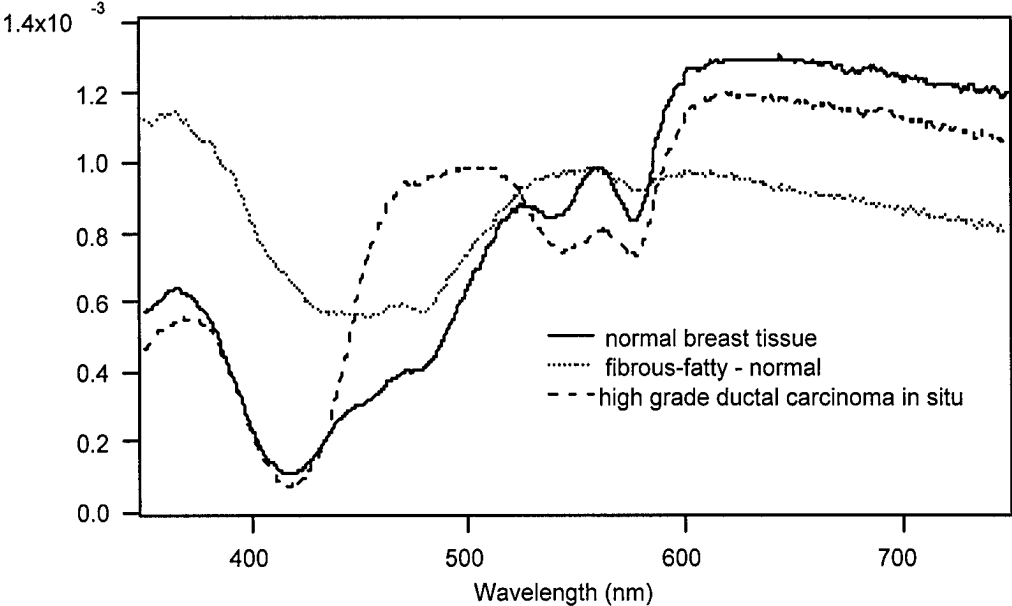


Fig. 3. Examples of ESS spectra for normal and malignant breast tissue conditions.

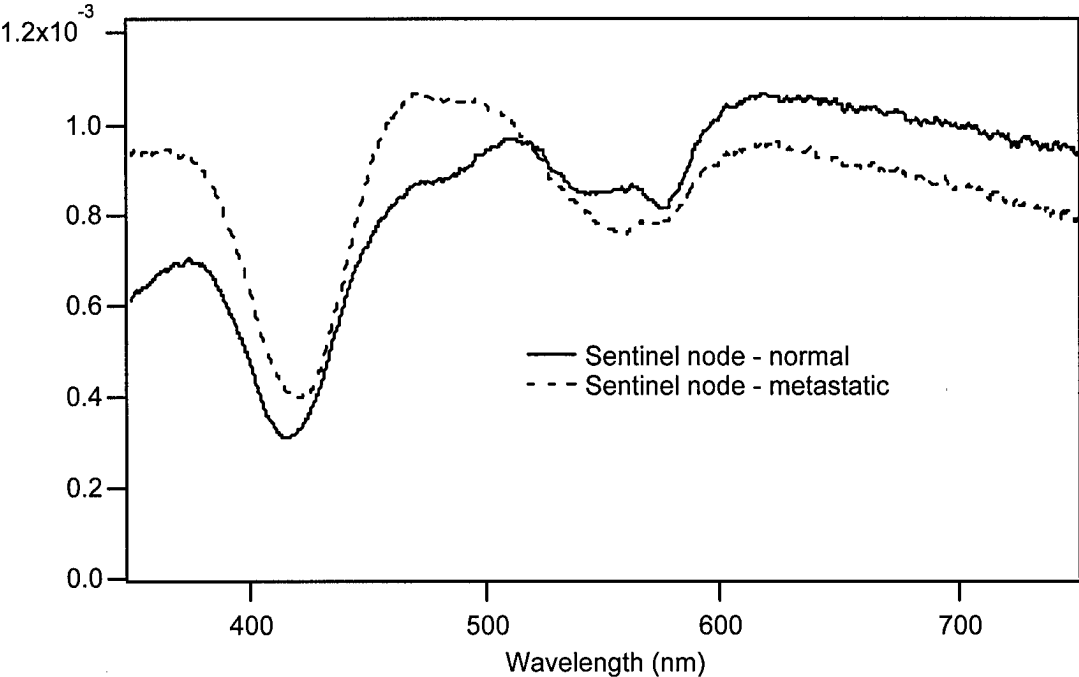


Fig.4 Examples of ESS spectra for a reactive node, without tumor and for node containing metastatic tumor.

Two different automated methods of spectral classification have been employed to assess the degree of correlation between pathology and spectral pattern differences: artificial neural networks and hierarchical cluster analysis. Artificial neural networks (ANNs) were selected for study because of the expectation by our group and other researchers [4] that ANNs would prove to be a generally useful method of tissue spectral classification. ANNs are well suited for classification in systems where model-based classification is difficult. Such is the case with ESS spectra of breast tissue because of its remarkable heterogeneity of tissue types (comprising glandular, adipose, fibrous, tubular, connective and other tissue types) with consequent broad variability in optical scattering and absorption properties. In light of this expectation, there was interest in our group to evaluate the relative merits of ANNs in ESS spectral analysis.

Hierarchical cluster analysis (HCA) was selected for study as an alternative to the many approaches to classification that provide unbounded class regions (including linear discriminant analysis, regression analysis and ANNs). The problem of unbounded class regions, and the benefits of using cluster analysis to avoid this problem, are discussed by Osbourn et al. [17] In general, the problem with unbounded class regions is that a new sample will be classified in one of the available classes of a previously-trained system, even if the input parameters of this new sample differ markedly from the other samples in the class to which it is assigned. This is not a problem when new samples are not expected to differ greatly from previous samples. In the field of optical biopsies, however, a number of variables can significantly alter the measured spectra, including experimental factors such as the presence of fluid (esp. blood) trapped under the probe tip, or simply as a consequence of the dramatic heterogeneity and variability of real tissue. It would thus be beneficial for a classification technique to be able to recognize samples that may have been affected by the above variables (i.e. samples that differ markedly from previous samples, or "outliers"). Having bounded class regions (such as those produced through HCA) provides this ability to reject outliers. A more detailed description and comparison of these artificial intelligence methods for classification for tissue spectra of several different organ areas is the subject of a future publication currently in preparation.

Although both ANN and HCA methods are intrinsically statistical-based classification methods, some preprocessing or weighting of input parameters can be implemented to help "bias" classification when something about the underlying tissue optical properties is known. One example is the fact that the presence of adipose (fatty) tissue in the measured volume is much more frequently associated with normal or benign breast conditions (for that site) than with adenocarcinoma, especially in postmenopausal women. Since adipose tissue has the characteristic absorption feature of beta carotene, the spectral bands containing that feature can be accounted for. Another possible weighting can be found in the fact that hypervascularization more frequently accompanies malignant tissue than normal or benign conditions. For the data analyses presented here, little "model-based" preprocessing was implemented, but this will be treated more extensively in a future publication, and will be used with larger data sets.

For all analyses reported here the spectra from breast tissues and sentinel nodes were treated separately since they are fundamentally different tissues. All spectra were preprocessed by first normalizing each spectrum to the same total integral over the spectral range of 350 to 750 nm. Thus, only spectral shapes were compared and not total scattering efficiencies. Such data treatment eliminates concerns about differences in optical coupling and/or transmission among

the number of fiber probes used (although any potentially useful information in the total scattering efficiency is, admittedly, also lost). In the case of sentinel nodes containing methylene blue dye (Patent Blue™), which had been used to assist in locating the node during surgery, the spectra were also treated to subtract the feature of that absorption band. Following normalization (and treatment for dye in some of the node spectra), all spectra were divided into 20 wavelength bands of 20-nm width, and the average signal for each band was calculated. The resulting 20 average-signal values constituted the input parameters for the ANN and HCA classification schemes. (Numerous other preprocessing schemes for defining the input parameters are possible, and several are being explored for future publication.)

In presenting the statistical results, sensitivity and specificity are defined in the standard way:

$$\text{Sensitivity} \equiv \text{TP}/(\text{TP} + \text{FN})$$

$$\text{Specificity} \equiv \text{TN}/(\text{TN} + \text{FP})$$

where TP, FP, TN and FN represent the numbers of true positives, false positives, true negatives and false negatives, respectively, as determined by the corresponding histopathology.

With ANN classification a variety of weighting factors and transfer functions (between neuron layers) are possible, and several have been tried to determine optical classification performance. For the training and testing of the ANN's we randomly chose 80% of the data samples as a training set, reserving the remaining 20% as the test set. This was repeated three times with three different random choices of the 80/20 split. Results of the three tests, for both breast-tissue sentinel-node spectra, are shown in Tables 2 and 3. The remarkably high values of sensitivity and specificity for the breast tissue data are almost certainly a fortuitous consequence of the small data sets and are not expected to persist as the sizes of the data sets grow. Nonetheless, these preliminary results are encouraging.

**Table 2. Neural network classifications for breast tissue spectra**

	Neural Net #1	Neural Net #2	Neural Net #3	Average
Number of specimens showing cancer histologically	3	3	3	
Number of cancers optically diagnosed as cancer (true positives)	3	3	3	
Number of cancers optically diagnosed as normal (false negatives)	0	0	0	
Sensitivity (%)	100	100	100	100
Number of specimens found normal histologically	16	16	16	
Number of normals optically diagnosed as cancer (false positives)	0	0	0	
Number of normals optically diagnosed as normal (true negatives)	16	16	16	
Specificity (%)	100	100	100	100

Table 3. Neural network classifications for sentinel node spectra

	Neural Net #1	Neural Net #2	Neural Net #3	Average
Number of specimens showing cancer histologically	4	4	4	
Number of cancers optically diagnosed as cancer (true positives)	4	3	3	
Number of cancers optically diagnosed as normal (false negatives)	0	1	1	
Sensitivity (%)	100	75	75	83.3
Number of specimens found normal histologically	11	11	11	
Number of normals optically diagnosed as cancer (false positives)	0	0	0	
Number of normals optically diagnosed as normal (true negatives)	11	11	11	
Specificity (%)	100	100	100	100

With the hierarchical cluster analysis (HCA) the need for adequately-large data sets is more pronounced than for ANN's. This is a consequence of the fact that with HCA the "training," or multidimensional cluster-template formation, is not performed in a backward manner using the known outcomes (as is the case for ANN's). Rather, the training consists of trying many different combinations of reduced sets of input parameters, using pattern recognition schemes to find clusters with no knowledge of actual classifications, and then comparing the resulting clusters with the known classifications of their members. The combination of input parameters that yields the cluster templates that most accurately correlate with each histology classification is the one that is chosen for testing with data points not involved in the training. (This is essentially like performing principal component analysis on the input parameters.) Different criteria are possible for determining the multidimensional Euclidian "distance" between a sample point and a given cluster; thus, we also compared various distance criteria in terms of predictive accuracy. However, with small data sets the clusters found are highly sensitive to the specific choice of training set. Thus, instead of dividing the data into an 80%/20% grouping of training/testing sets, we chose to test the HCA classification by the "leave-one-out" method, in which all but one of the data samples are used to form the clusters, and the remaining sample is tested to see into which (if any) cluster it falls. To generate the statistics shown in Table 4 (combining the results for both breast tissue and sentinel nodes), this procedure was repeated for every data point in the set. It can be seen that with the HCA method some samples appear as unclassifiable, rather than as false positives or false negatives. It is also clear that HCA performs less well than ANN's for these small data sets.

It is our expectation that with larger data sets an HCA with properly-chosen input parameters will yield similar sensitivity and specificity to ANN's, but with HCA having the advantage of identifying outliers as difficult to classify, rather than blindly forcing a classification. We believe this is a more realistic approach for clinical application of any new diagnostic method.

Table 4: Hierarchical cluster analysis - Leave-one-out results:

	Breast Tissue	Sentinel nodes
Number of specimens showing cancer histologically	16	21
Number of cancers optically diagnosed as cancer (true positives)	15	12
Number of cancers optically diagnosed as normal (false negatives)	0	7
Number of cancers with an indeterminate optical diagnosis	1	2
Sensitivity (%)	93.7	57.1
Number of specimens found normal histologically	78	54
Number of normals optically diagnosed as cancer (false positives)	1	7
Number of normals optically diagnosed as normal (true negatives)	72	46
Number of normals with an indeterminate optical diagnosis	5	1
Specificity (%)	92.3	85.2

### Discussion and problems encountered

It is not the purpose of this paper to present a detailed discussion of the structures and functions of different artificial-intelligence, pattern-recognition schemes for classification of tissue spectra, but rather to present the results of their implementation for these preliminary data of our breast cancer study. A careful discussion of the relative merits of AI methods for tissue spectra classification will require a full separate publication, which (as mentioned above) is in preparation. Although the data sets are small, we believe these preliminary results are compelling enough to merit presentation to the scientific community.

In actual clinical implementation of the ESS instrumentation, it became evident that some attention must be given to avoiding excessive amounts of blood on the tip of the fiber probe, as this can obscure information about the amount of tissue perfusion, or even block much of the scattering spectral information (due to the strong absorption by hemoglobin). Thus, it was sometimes necessary to sponge, or rinse with saline, the surgical resection surface to be measured, and/or to wipe the tip of the probe.

Another problem encountered on a few occasions was that the ambient lighting of the surgical site (with the high-intensity directed-beam lighting typically found in theatre) could scatter through tissue into the collection fiber of the probe, using up much of the detector's dynamic range, and making it difficult for the system to perform an accurate background subtraction. This was remedied by either having the surgeon momentarily shadow the strong light from the measurement site, or by a redesign of the probe fixture to incorporate a small shadow mask. (Of course, the strong lights could be temporarily aimed away from the surgery or reduced in intensity while the ESS measurements are being made, but we wished to minimize any inconvenience to the surgical team.)

In the development of a new diagnostic technique, the accuracy and robustness of the "gold" standard, histopathology, are always a concern. In our case all pathology reports were provided by a specialist breast pathologist (SL) of the University College London Hospitals. Careful attention has been paid to adequacy of tissue samples, correlation with optical measurement sites and consistency of pathology reporting terminology. As the program enlarges, and incorporates other medical centers, agreement among pathologists will be addressed, and slides will be read by multiple pathologists. Methods will be assessed to resolve conflicting reports.

For the purposes of these analyses, ductal carcinoma in situ (DCIS) was always classified as cancer, since the treatment consequences are the same regardless of whether the DCIS already shows signs of invasiveness or not.

### **Conclusions**

We have described a research program designed to test the value of elastic-scattering spectroscopy as a real-time diagnostic tool and as a diagnostic aid to surgical/therapeutic procedures for breast cancer. We have presented, as preliminary data, the results from the first 15 patients of a larger program. The small sizes of the data sets notwithstanding, the results of spectral classification by two different methods of "artificial intelligence" pattern recognition imply good agreement with pathology. This allows us to be hopeful that as the data sets grow, we will be able to successfully test the predictive capabilities of already-trained spectral classification schemes.

### **Acknowledgements**

This work has been supported in part by the U.S. Army Medical Research and Materiel Command, through the Breast Cancer Initiative program.

## References

---

1. I.J. Bigio and J.R. Mourant, "Ultraviolet and visible spectroscopies for tissue diagnosis ...," *Phys. Med. Biol.* **42**, 803-814 (1997).
2. J.R. Mourant, I.J. Bigio, J. Boyer, T. Johnson, J. Lacey, A.G. Bohorfoush & M. Mellow, "Elastic scattering spectroscopy as a diagnostic tool for differentiating pathologies in the GI tract..." *J. Biomed. Opt.* **1**, 192-199 (1996).
3. J.R. Mourant, I.J. Bigio, J. Boyer, R.L. Conn, T. Johnson & T. Shimada, "Spectroscopic diagnosis of bladder cancer with elastic light scattering," *Lasers in Surgery and Medicine* **17**, 350-357 (1995).
4. Z. Ge, K.T. Schomacker and N.S. Nishioka, "Identification of colonic dysplasia and neoplasia by diffuse reflectance spectroscopy and pattern recognition techniques," *Appl. Spectroscopy* **52**, 833-839 (1998).
5. M. Johns, C. Giller and H. Liu, "Computational and in vivo investigation of optical reflectance from human brain to assist neurosurgery," *J. Biomed. Optics* **3**, 437-445 (1998).
6. J.R. Mourant, J. Boyer, A. Hielscher and I.J. Bigio, "Influence of the scattering phase function on light transport measurements in turbid media performed with small source-detector separations", *Optics Letters* **21**, pp.546-548 (1996).
7. L.T. Perelman et al., "Observation of periodic fine structure in reflectance from biological tissue: a new technique for measuring nuclear size distribution," *Phys. Rev. Lett.* **80**, 627-630 (1998).
8. J.R. Mourant, A.H. Hielscher, A.A. Eick, T.M. Johnson and J.P. Freyer, "Evidence of intrinsic differences in the light scattering properties of tumorigenic and nontumorigenic cells," *Cancer Cytopath.* **84**, 366-374 (1998).
9. A. F. Zuluaga et al., "Fluorescence excitation emission matrices of human tissue: a system for in vivo measurement and method of data analysis," *Appl. Spectroscopy* **53**, 302-311 (1999).
10. I.J. Bigio et al., "Determination of the cervical transformation zone using elastic-scattering spectroscopy," *Proc. SPIE* **2679**, 85-91 (1996).
11. S.L. Willis and I. Ramzy, "Analysis of false results in a series of 835 fine-needle aspirates of breast lesions," *Acta Cytologica* **39**, pp. 858-864 (1995).
12. P. Purasiri et al., "A novel diagnostic index for use in the breast clinic," *J. Royal College of Surgeons of Edinburgh* **41**, pp.30-34 (1996).

---

13. J. Walls et al., "Can preoperative factors predict for residual malignancy after breast biopsy for invasive cancer?," *Ann. Royal Coll. Surg. Engl.* **77**, 248-251 (1995).

14. H. Snider et al., "Sentinel node biopsy in the staging of breast cancer," *Am. J. of Surg.* **176**, 305-310 (1998).

15. J. Boyer, J.R. Mourant and I.J. Bigio, "Theoretical and experimental demonstrations of elastic scattering spectroscopy as a diagnostic for tissue pathologies", in *Optical Imaging and Photon Migration*, R.A. Alfano, ed. (1994 APS Press).

16. J.R. Mourant, T. Fuselier, J. Boyer, T. Johnson and I.J. Bigio, "Predictions and measurements of scattering and absorption over broad wavelength ranges in tissue phantoms", *Applied Optics* **36**, pp. 949-957 (1997).

17. G. Osbourn, J. Bartholomew, A. Bouchard, and R. Martinez, "Automated pattern recognition based on the visual empirical region of influence (VERI) method: A user's guide," <http://www.sandia.gov/1100/1155Web/1155home.htm>



ORIGINAL ARTICLE

## Interstitial laser photocoagulation for fibroadenomas of the breast

L. M. Lai,\* M. A. Hall-Craggs,† H. Mumtaz,\* P. M. Ripley,\* T. I. Davidson,‡ M. W. Kissin,§ C. Saunders,‡ I. Taylor‡ and S. G. Bown\*

\*National Medical Laser Centre, Institute of Surgical Studies, Royal Free and University College School of Medicine, London, UK; †Department of Imaging, University College London Hospitals, UK; ‡Institute of Surgical Studies, Royal Free and University College School of Medicine, London, UK; §Royal Surrey County Hospital, Guildford, UK

**SUMMARY.** Fibroadenomas are benign lesions of the breast that are common in young women. Most can safely be treated conservatively, but if they are not excised, the majority persist for several years and some increase in size. Interstitial Laser Photocoagulation is a new approach to treating these lesions. Under local anaesthesia and sedation, using ultrasound guidance, fine needles are inserted into the fibroadenoma and a laser fibre passed through each needle to coagulate the lesion in situ. Twenty-nine lesions (diameter 14–35 mm) have been treated in 24 patients. Twenty eight (97%) shrank in size on follow up ultrasound assessment. Fourteen were followed for a year, at which time none was palpable and only one could still be detected on ultrasound. In early cases there were three minor complications (a small scar at a site of needle insertion), later prevented by improved technique. This is a simple and safe outpatient procedure for ablating fibroadenomas that does not require open surgery.

### INTRODUCTION

Fibroadenomas are benign lesions which develop from breast lobules at around the time of puberty, often becoming palpable a few years later. The peak incidence of these lumps is between the ages of 19 and 25 years. Fibroadenomas can be diagnosed with a high level of confidence using a combination of clinical examination, ultrasonography and fine needle aspiration cytology. Traditionally, surgical excision has been advocated for all palpable, discrete breast lumps because of the perceived risk of malignancy. However, as it is now appreciated that fibroadenomas are aberrations of normal breast development rather than true neoplasms,<sup>1-4</sup> conservative management is safe in women who are under 35 years of age and where there is confidence in the diagnosis.<sup>3,5-8</sup> As a consequence, the practice of routine excision of fibroadenomas is being increasingly questioned. Surgery for these lesions is usually straightforward, but still carries some risk of anaesthetic complications, wound infection, haemorrhage and scarring. In a largely young group of women, cosmesis is an important consideration and scarring may be unacceptable, parti-

cularly in the area of cleavage. This problem is exacerbated in patients who develop multiple fibroadenomas and those with a propensity to keloid formation. Furthermore, surgical excision of all benign breast lumps represents a significant workload, and a simple, non-surgical alternative would be an attractive, and potentially cost saving option.

Interstitial laser photocoagulation (ILP) is a technique first described in 1983 by Bown, whereby optical fibres inserted percutaneously through needles enable delivery of light directly into a lesion within a solid organ.<sup>9</sup> The mechanism of action is thermal, resulting in localized coagulation necrosis centred around the end of each fibre. As the treated area is in the centre of a solid organ, ILP requires concurrent imaging to localize the target lesion, guide the placement of optical fibres and assess the effect.<sup>10</sup> Initial studies of ILP in the human breast were performed using a single optical fibre inserted into cancers a few days prior to scheduled surgery and then examining the result in the excized tissue. This showed that areas of necrosis up to about 15 mm in diameter could be produced safely in the tumour and in the immediately surrounding normal tissue. The diameter of the zone of necrosis was made more predictable by a process of precharring the fibre tip prior to insertion.<sup>11</sup> More recently, in further studies of ILP on breast cancers prior to surgery, Mumtaz et al.<sup>12</sup> have shown that contrast enhanced magnetic resonance imaging (MRI) can define the extent of laser induced necrosis remarkably accurately.

Address correspondence to: Professor S. G. Bown, National Medical Laser Centre, Institute of Surgical Studies, Charles Bell House 67-73 Riding House Street, London W1P 7LD, UK. Tel.: (0) 171-504-9060; Fax: +44 (0) 171-813-2828; E-mail: s.bown@ucl.ac.uk

The aim of the present study was to evaluate the feasibility of ILP as a minimally invasive technique for treating fibroadenomas.

## PATIENTS AND METHODS

Patients for this study were recruited from outpatient clinics at the University College London Hospitals and the Royal Surrey County Hospital, Guildford. All patients had palpable breast lumps proven on clinical examination, ultrasound and aspiration cytology to be benign fibroadenomas and were informed of the conventional management options of either removing the lesion surgically or just keeping it under observation. The first group of 16 patients had elected to have surgical removal of their fibroadenomas but were then told of the possibility of the new laser treatment and consented to have ILP whilst waiting for surgery. The second group of eight patients, recruited after encouraging results were found in the first group, were told of the possibility of ILP at the time their diagnosis was confirmed, and chose ILP as an alternative to surgery or observation. This study was approved by the ethics committees at both hospitals and all patients gave written, informed consent prior to their participation.

The fibroadenoma was first localized and its maximum diameter measured by ultrasonography (Aloka 650, 7.5 MHz probe, Aloka, Tokyo, Japan, or Siemens, 7.5 MHz probe,

Siemens, Germany). ILP was performed using an aseptic technique under sedation with intravenous midazolam (2–5 mg) and pethidine (25–50 mg) and with monitoring for oxygen saturation and vital signs throughout the procedure. Initially, 10 to 15 ml of lignocaine 1% were infiltrated into the skin and the breast tissue around the fibroadenoma. Under ultrasound guidance, 1–4 19 G needles were then inserted percutaneously into the fibroadenoma (Figs 1 & 2). The tips of the needles were positioned 1 cm apart in the lump and a bare optical fibre loaded through each one. The tip of each fibre was precharred by heating its tip in a match prior to use as this had been shown previously to give more even tissue heating.<sup>11</sup> The needle and fibre were adjusted

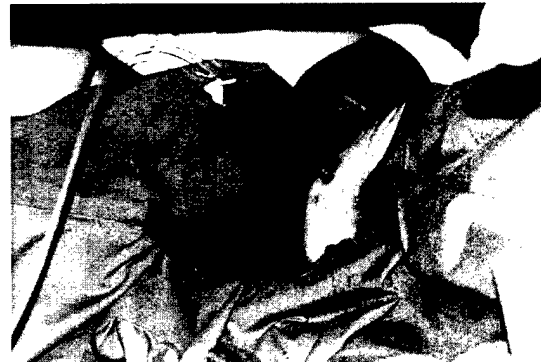

Fig. 1 Application of Interstitial Laser Photocoagulation to a fibroadenoma of the breast.

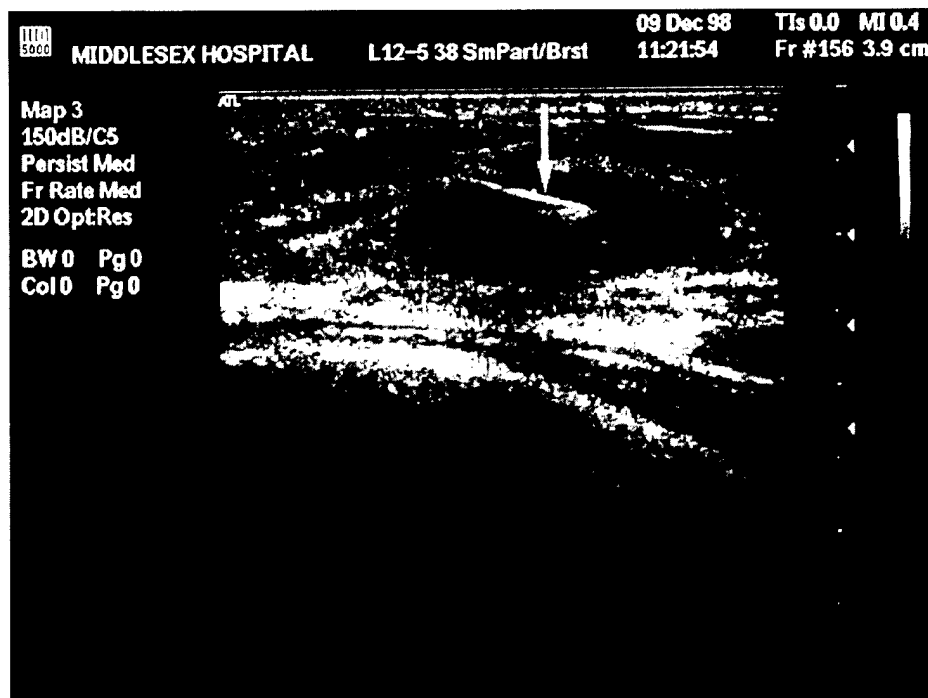


Fig. 2 Ultrasound scan of a laser fibre (arrow) positioned in a fibroadenoma immediately prior to ILP.

until the fibre protruded 4–5 mm from the needle, measured by marking the point on the fibre at which the proximal end of the needle had to be positioned. The number of fibres inserted was based on the size of the lesion to be treated (<15 mm: 1 fibre, 15–20 mm: 2 fibres, 20–25 mm: 3 fibres, >25 mm: 4 fibres). Once the fibres were in place, they were connected to a semiconductor diode laser (Diomed 25, Diomed Ltd, Cambridge, UK) via a beam-splitter (Diomed 4-way beamsplitter, Diomed, Cambridge, UK). This laser has a wavelength of 805 nm in the near infrared part of the spectrum, where tissue penetration is best for deep coagulation. The power used was 2.5 W per fibre for a planned duration of 500 s. When treatment was complete, the needles were removed and the patients allowed to go home as soon as they had recovered from the sedation.

Patients were seen for routine follow-up 2–4 weeks after treatment. The ultrasound scan was repeated at 3, 6 and 12 months after treatment. Any patient who was unhappy with the resolution of the lump in her breast at any time after ILP was offered surgical excision.

Seventeen of the patients treated in this series underwent contrast enhanced magnetic resonance imaging (MRI) on a 1.0T Magnetom 42SP scanner (Siemens, Erlangen Germany) before and after ILP to look for treatment induced changes. Transverse T1-weighted 3D Fast Low Angle Shot (FLASH) imaging was performed using the contrast agent gadopentate dimeglumine (Magnevist, Schering, Berlin, Germany) injected intravenously at a dose of 0.1 mmol/kg body weight. Post-ILP scans were performed 2–6 weeks after treatment.

**RESULTS**

A total of 24 patients with 29 proven fibroadenomas (2 patients with 2 lesions, 1 patient with 4) were treated. The median age of patients was 26 years (range 18–42 years) and the median size of lesions (measured by ultrasound) was 25 mm (range 14–35 mm). Twenty eight of the 29 (97%) lesions treated showed at least some reduction in size on serial ultrasound measurements. In one lesion there was no change. Only 6 of the original group of patients persisted

**Table 1** Results on patients who underwent surgery after ILP

Patient number	1	2	3	4	5	6
Age	22	23	25	28	29	25
Size of fibroadenoma before ILP (mm)*	22	28	24	35	34	25
Time from ILP to surgery (weeks)	2	24	2	4	2	12
Size immediately prior to surgery (mm)*	18	14	16	28	27	25
Size of lump on histology (mm)	18	16	18	25	30	30
Residual viable fibroadenoma (mm)	3	6	3	3	2	16

\*Fibroadenoma sizes were measured by ultrasound

with their original plan to have surgical excision following ILP, and 4 of these had surgery within a month of ILP, too short a time for there to be much reduction in lesion size due to the laser treatment. The other 2 (including the one with no change after ILP), requested surgery 12 and 24 weeks after ILP. None of those in the second group who chose ILP as an alternative to surgery have since requested surgery. Details of the lesions treated surgically are given in Table 1. All the excised lumps were confirmed to be fibroadenomas.

For the patients who declined surgery, the results are shown in Table 2. The median reduction in lesion size after ILP, as measured with ultrasound, was 38% at 3 months, 60% at 6 months and 100% at 12 months. In all 14 patients so far followed up for at least 1 year, the treated fibroadenomas were no longer palpable. Twelve of these had ultrasonography at 1 year, but only 1 patient still had a detectable lesion. This had measured 33 mm at presentation and had shrunk to 10 mm at 1 year. No fibroadenoma increased in size (other than some oedema in the first few days after ILP).

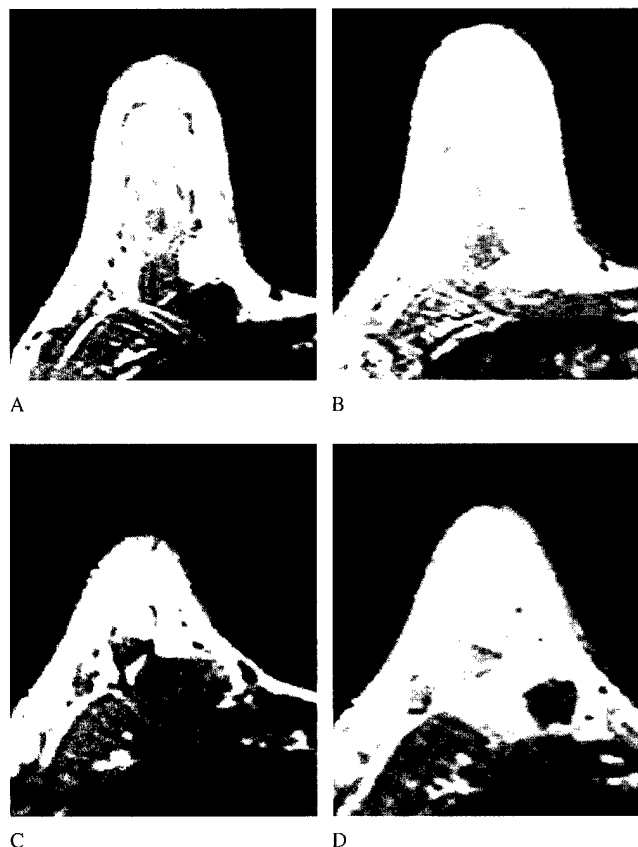
Of the 17 lesions that were assessed with contrast enhanced MRI before and after ILP, 11 were depicted as discrete, strongly enhancing masses on pre-treatment images. Following ILP, there was no change in the 6 lesions that had not enhanced prior to treatment, but zones of persistent non-enhancement were demonstrated in the previously enhancing areas in all the other 11 cases. In 2 of these patients who subsequently had surgery, these new zones of non-enhancement corresponded to areas of laser induced necrosis seen histologically (Figs 3 & 4).

Most patients (n=20) reported feeling some discomfort


**Table 2** Size of fibroadenomas measured by ultrasound prior to treatment and up to 12 months after ILP. The lesion seen on ultrasound at 12 months was not detectable clinically

Time	Lesion size (mm)		Percentage reduction in lesion size compared with size at presentation		Number of lesions examined	Number (%) of lesions no longer detectable on ultrasound
	Median	Range	Median	Range		
Prior to treatment	25	14–35	NA	NA	23	NA
3 months after ILP	14	0–23	38	5–100	23	1 (4%)
6 months after ILP	10	0–19	60	9–100	23	4 (17%)
12 months after ILP	0	0–10	100	71–100	12*	11 (92%)

\*Two further treated lesions were undetectable clinically at 12 months but did not have an ultrasound scan at that time.



**Fig. 3** MRI scans of fibroadenoma (patient 6 in the surgical group). (A) before ILP, without contrast; (B) before ILP, with contrast. (C) 3 months after ILP, without contrast; (D) 3 months after ILP, with contrast.



**Fig. 4** Histological section of the fibroadenoma imaged in Figure 3, removed a few days after the MRI scans were taken.

whilst the laser was activated, but were able to tolerate the procedure satisfactorily with the use of intravenous analgesia and sedation in addition to the local anaesthetic in the breast. Four patients experienced more severe pain whilst the laser was activated and treatment was stopped prematurely after 261–300 s. Pain was relieved immediately when

the laser was turned off. Even so, no treatment was stopped before at least half of the planned energy dose had been delivered and these patients still responded well. All patients were able to return to their normal activities the day after ILP. Local tenderness and swelling was reported by all patients following ILP. The swelling resolved by 1 week in most cases, although tenderness and sensitivity to touch in the treated breast persisted for anything from 1 day to 5 weeks (median 1 week). Bruising was seen in 4 patients but this resolved by 1 week in all cases.

There was no change in the size or shape of any of the breasts treated. Twenty-one patients had no visible scar following ILP to their fibroadenomas. The only complication was a small skin burn seen around a needle insertion point in three patients. In one of these there was also a persistent, clear, oily discharge for 3 weeks. Repeated cultures showed this to be sterile. These lesions all healed without further intervention. There were no wound infections and prophylactic antibiotics were not used. The resultant scars were all less than 1 cm in diameter, and all 3 patients felt these to be cosmetically acceptable.

## DISCUSSION

Fibroadenomas are the commonest cause of discrete breast lumps in young women.<sup>13</sup> Although benign in nature, they are often a source of discomfort and anxiety. Since fibroadenomas can be diagnosed with a high degree of confidence on 'triple assessment' (clinical examination, ultrasonography and fine needle aspiration cytology) and conservative management has been shown to be a safe alternative to surgical excision, at least in patients up to about 35 years of age,<sup>7</sup> clinicians are more inclined to adopt a conservative approach in their management. Nevertheless, even if the conservative approach is safe, many fibroadenomas do not resolve. Dixon et al.<sup>14</sup> reported 152 patients with 163 fibroadenomas who were followed for 2 years. Thirteen lesions (8%) increased in size and were excised, 19 (12%) reduced in size, 42 (26%) resolved completely (20 (12%) at 1 year and 22 (14%) in the second year) and 89 (54%) did not change in size. Thus, of the 150 lesions treated conservatively, 130 (87%) were still present after 1 year and 108 (72%) after 2 years. Carty et al.<sup>7</sup> reported very similar figures. Dent et al.<sup>4</sup> reported that 31% resolve and another 12% get smaller. Wilkinson et al.<sup>15</sup> concluded that the majority of fibroadenomas continue to grow.

In contrast, in the present study, 14 treated lesions were followed up for 1 year, and all were impalpable on clinical examination at the end of this period. In the 12 patients that had ultrasound scans at 1 year, only one residual fibroadenoma could be detected. No sustained increase in size of any fibroadenoma occurred after ILP. The transient swelling

seen shortly after treatment was attributable to inflammation and oedema around the treated area and settled within a week or so. These results compare very favourably with the less frequent spontaneous regression rates reported in the series treated conservatively. Seventy-five per cent of our patients who had initially opted for surgery decided not to proceed with surgery after ILP and were happy with the final result when interviewed at follow-up.

The major attraction of ILP is its potential for inducing resorption of fibroadenomas without leaving a surgical scar. Three patients sustained small skin burns which healed without complication. In one patient, this was due to placement of a fibre too superficially in a lesion just below the skin. The other two were 'needle tract burns' caused by retrograde charring of the fibre which caused heating of the needle shaft. These burns affected a small area (about 0.5 cm in diameter) around a needle track. In the patient who had a sterile discharge for 3 weeks, ultrasound scanning showed some liquefaction in the treated area, most likely from the necrosed tissue. In retrospect, the burns could probably have been prevented by more vigilant monitoring of skin temperature and checking that the fibre tip remained in the correct position, protruding far enough beyond the needle tip. Our current practice is to irrigate the area being treated with cold, sterile saline during laser activation, and no further burns have occurred since. The skin burns did not occur in any patient who complained of pain during the laser activation. This pain was most likely due to inadequate local anaesthesia. Even though these patients received little more than half the planned light dose, the biological effect was as good as in the other patients, which means that the treatment times used may have been longer than necessary.

Fibroadenomas have more clearly defined margins than most cancers. This makes them easy to delineate with ultrasound,<sup>16,17</sup> which has proved convenient for guiding fibre insertion and for monitoring the lesion size during follow-up. In the 6 lesions which were excised in this study, close correlation was observed between ultrasonographic measurements and histological measurements of lesion size (Table 1). A previous report<sup>11</sup> showed that ultrasound is poor at determining the extent of laser induced necrosis in real time or in the first few days after treatment, and we have not used it for this purpose in this study. However, unlike treating cancers, this is not critical for treating fibroadenomas, as the patient will not come to any harm if part of the lesion is left untreated. From our previous experience,<sup>12</sup> contrast enhanced MRI defines the extent of laser induced necrosis in cancers very well, and this was assessed in some of the lesions treated in this series. In the 11 lesions that enhanced on MRI prior to ILP, new zones of non-enhancement were seen after treatment and these were confirmed to be due to laser induced necrosis in two of the patients who opted for

surgical resection after ILP (Figs 3 & 4). However, for routine management of these patients, MRI is not necessary as all the required imaging information can be obtained using ultrasound.

Patient acceptability of conservative management of benign fibroadenomas varies widely. In his series of 202 patients, Dixon et al.<sup>14</sup> reported that 92% initially opted for conservative management and only those with lesions increasing in size during follow-up were subsequently excised. Another UK series<sup>15</sup> reported more than 80% of women opting for conservative management, but a series from South Africa<sup>8</sup> reported that amongst patients who had had fibroadenomas excised, only 21% would opt for conservative management if they developed another lesion and only 7% would have preferred to keep their original lesion. In these series, patients were only offered either surgical excision or conservative management. In general, few patients will choose to have a surgical procedure that is not absolutely necessary. A simple procedure with no cosmetic sequelae may be more acceptable if it is shown to be safe and effective.

ILP is relatively simple to perform and the equipment required (a small, portable laser and a standard ultrasound scanner) is straightforward to set up and maintain. It is a day case procedure that can be done in the ultrasound department with local anaesthetic and sedation and which does not require full operating theatre facilities. Surgical excision of fibroadenomas is a relatively minor procedure with few complications, although operating theatre facilities are required, a general anaesthetic is usually preferred and there will always be a small scar, even though this can be well hidden.

In conclusion, in this pilot study, ILP has induced resorption of almost all the fibroadenomas treated during a follow-up period of a year during which time less than 20% would have been expected to disappear spontaneously. Patient satisfaction was high with this simple outpatient procedure. Ultrasound guided ILP has the potential to become an effective and low cost technique for managing fibroadenomas in patients who are anxious to get rid of their lump, particularly those with multiple lesions and those who have a tendency to keloid formation.

## References

1. Hughes L E, Mansel R E, Webster D J T et al. A new perspective on benign breast disorders. *Br J Clin Pract* 1988; 42(Suppl. 56): 1-9.
2. Foster M E, Garrahan N, Williams S. Fibroadenoma of the breast: a clinical and pathological study. *J R Coll Surg Edin* 1988; 33: 16-19.
3. Sainsbury J R C, Nicholson S, Needham G K et al. Natural History of the benign breast lump. *Br J Surg* 1988; 75: 1080-1082.
4. Dent D M, Cant P J. Fibroadenoma. *World J Surg* 1989; 13: 706-710.
5. Dupont W D, Page D L. Risk factors for breast cancer in women with proliferative breast disease. *N Engl J Med* 1985, 312: 146-151.

6. Azzopardi J G. Problems in breast pathology. London. WB Saunders, 1979: 92–105.
7. Carty N J, Carter C, Rubin C et al. Management of fibroadenoma of the breast. *Ann R Coll Surg Engl* 1995; 77: 127–130.
8. Cant P J, Madden M W, Close P M et al. Case for conservative management of selected fibro-adenomas of the breast. *Br J Surg* 1987; 74: 857–859.
9. Bown S G. Phototherapy of tumours. *World J Surg* 1983; 7: 700–709.
10. Steger A C, Lees W R, Walmsley K, Bown S G. Interstitial Laser Hyperthermia: a new approach to local destruction of tumours. *Br Med J* 1989; 299: 362–365.
11. Harries S A, Amin Z, Smith M E et al. Interstitial laser photocoagulation as a treatment for breast cancer. *Br J Surg* 1994; 81: 1617–1619.
12. Mumtaz H, Hall-Craggs M A, Wotherspoon A et al. Laser therapy for breast cancer: MR imaging and histopathologic correlation. *Radiology* 1996; 200: 651–658.
13. Dixon J M. Cystic disease and fibroadenoma of the breast: natural history and relation to breast cancer risk. *Br Med Bull* 1991; 47: 258–271.
14. Dixon J M, Dobic V, Lamb J et al. Assessment of the acceptability of conservative management of fibroadenoma of the breast. *Br J Surg* 1996; 83: 264–265.
15. Wilkinson S, Anderson T J, Rifkind E et al. Fibroadenoma of the breast: A follow-up of conservative management. *Br J Surg* 1989; 76: 390–391.
16. Smallwood J A, Roberts A, Guyer D P, Taylor I. The natural history of fibroadenomas. *Br J Clin Pract* 1988; 42 (Suppl 56): 86–87.
17. Farouhi P, Walsh J S, Anderson T J, Chetty U. Ultrasonography as a method of measuring breast tumour size and monitoring response to primary systemic treatment. *Br J Surg* 1994; 81: 223–225.

## **Appendix 3**

### **Shedding light on breast cancer - Optical Biopsy (work in progress)**

C M Saunders<sup>2</sup>, G M Briggs<sup>1</sup>, P M Ripley<sup>1</sup>, C D O Pickard<sup>1</sup>, I J Bigio<sup>3</sup>, S R Lakhani<sup>4</sup>, S G Bown<sup>1</sup>.

1) National Medical Laser Centre; 2) Department of Surgery; 3) Department of Pathology; University College London Medical School, London.

4) Bioscience and Biotechnology Group, Los Alamos National Laboratory, Los Alamos, New Mexico 87545.

The objectives of this study are to evaluate the potential of an optical probe based on the principle of Elastic Scattering Spectroscopy (ESS)<sup>1,2</sup> for diagnostic applications in breast tissue and ultimately to develop an optical biopsy instrument capable of diagnosing breast lumps reliably in a clinical setting.

The system to be tested consists of a white light source, with fibre optic delivery and collection fibres, spectrometers for dispersion of the collected light and linear CCDs (charge coupled devices) for detection. The wavelength range of the system is 300-750nm, and the delivered power and energy are low enough to avoid any effect on tissue. The complete optical probe, including outer jacket, is less than 1mm in diameter. Only the fibre optic probe touches the patient and this will be sterilised prior to use.

Work to date has involved optical measurements on ex-vivo specimens shortly after they have been excised. These have shown identifiable differences in the optical properties of normal versus malignant tissue. We are however now taking measurements in-vivo as factors such as blood flow and higher temperature may make a difference to the readings and aim to show similar results.

Optical spectral measurements will be taken from a range of breast tissues in vivo and correlated with conventional histology of biopsies taken from the same sites. The proposal is to take such measurements in 3 situations. Firstly, on any occasion when a core-cut biopsy is being taken of a breast lesion, secondly during surgery on the breast and thirdly on excised sentinel nodes. It is planned to collect data from 300 patients of all ethnic backgrounds, who are between the ages of 18 and 85.

The ultimate aim is to produce a safe, simple and reliable diagnostic tool, which will give an immediate histological diagnosis either in the out-patient setting for initial diagnosis or in theatre to examine excision margins or sentinel nodes.

## **REFERENCES**

1. James Boyer, Judith R Mourant, Irving J Bigio, "Theoretical and experimental investigations of elastic scattering spectroscopy as a potential diagnostic for tissue pathologies", in *Proc. OSA: Advances in optical imaging and photon migration*, RR Alfano, ed., Vol.21, pp265-268, Optical Society of America, Washington DC (1994).
2. Judith R Mourant, Irving J Bigio, James Boyer, et al, "Elastic scattering spectroscopy as a diagnostic tool for differentiating tissue pathologies in the gastrointestinal tract: Preliminary testing" *Journal of Biomedical optics*, April 1996 Vol. 1(2) 192-199.

## **Appendix 4**

**Title:** Interstitial laser photocoagulation of breast tumours

**Authors:** G Briggs<sup>1</sup>, M Hall-Craggs<sup>2</sup>

**Institution:** 1) National Medical Laser Centre, University College London.  
2) Department of Radiology, Middlesex Hospital, London.

### **Introduction:**

Interstitial laser photocoagulation (ILP) is a technique whereby optical fibres, placed percutaneously into a lesion under local anaesthetic, deliver laser energy which causes local thermal necrosis of the surrounding tissue. Up to 4 optic fibres are placed radiologically into the centre of the lesion to be treated. In our institution we use the Diomed 25 (Diomed, Cambridge) semi-conductor laser as the laser source, operating at 805 nm. The laser is activated for between 10 and 20 minutes depending on the type of lesion to be treated. Light sedation (Midazolam) and analgesia (Pethidine) are given intravenously just prior to the treatment. The patients are allowed home after 1-2 hours.

Gadolinium contrast enhanced MR of breast is becoming an accepted modality for breast cancer imaging and staging. Employing contrast enhanced T1 weighted subtraction techniques, tumours stand out clearly as areas of increased enhancement. At high field, using temperature sensitive sequences, it is also possible to observe an immediate ILP effect although we have not been able to reproduce these findings at low field. We are continuing to evaluate its usefulness as a method for follow after ILP.

### **Experience to date:**

#### Fibroadenomas:

In our experience we have treated 29 tumours in 24 patients. Fourteen of these have been followed up for 1 year. All 14 had no residual palpable lesion following treatment. Twelve of these 14 had follow up ultrasonography, which confirmed complete resolution of the fibroadenoma in 11 patients and showed a small residual fibroadenoma in one.

#### Breast Cancer:

Data are accumulating from University College London Hospital, Little Rock, Arkansas and a group from Kharkov in the Ukraine. It has been shown that lesions of up to 3cm can be necrosed using multiple fibres. Current studies include:

- 1) ILP to primary breast cancers in the interim between diagnosis and surgery.
- 2) ILP for post-menopausal patients with oestrogen receptor positive tumours, followed by Tamoxifen for 3 months and then surgery.
- 3) ILP only for small screen detected tumours, 1cm or less, in post-menopausal women.

In all studies, pre and post treatment contrast enhanced MRI is being used to show treatment effect.

### **Conclusions:**

ILP is proving to be a useful alternative to surgery for fibroadenomas of the breast. There are early data that suggest ILP may prove to be an alternative therapy for breast cancer in some patients, especially those who are less suitable for surgery due to age or co-morbidity, either alone or in conjunction with



hormone treatment and/or radiotherapy. Further work needs to be carried out to assess the accuracy of MRI in detecting residual tumour.

**INTERVENTIONAL MRI**  
Wednesday 16<sup>th</sup> June 1999  
BIR, 36 Portland Place, London W1N 4AT

**SPEAKER DETAILS**

Surname	Briggs
Forename	Gavin
Title	Mr
Hospital/Organisation	National Medical Laser Centre
Address	Charles Bell House 67-73 Riding House Street London, W1 7PN
Telephone	0171 504 9095/9060
Fax	0171 813 2828
Email	<a href="mailto:g.briggs@ucl.ac.uk">g.briggs@ucl.ac.uk</a>
AV requirements	data projection / 35mm
Hotel accommodation	not required
Special Dietary requirements	none
Society Membership	N/A

## **Appendix 5**

### **“Breakthrough Breast Cancer”**

3 day meeting in London, UK, November 1999

### **Optical Diagnosis of Breast Cancer**

S.G.Bown. National Medical Laser Centre, Department of Surgery  
Royal Free and University College Medical School, London

When a lump is felt or mammography identifies a suspicious area in a breast, removal and processing of tissue and subsequent examination under a microscope are required to establish whether or not a cancer is present. Optical biopsy is a new technique just starting clinical trials that has the potential to provide an almost immediate diagnosis. It uses the principle of elastic scattering spectroscopy (ESS). A short pulse of white light is passed down a fibre positioned in or on the suspicious area and the light scattered within the tissue is collected by a second fibre immediately adjacent to the first. Spectral analysis of this signal gives patterns which are characteristic of the tissue within a mm or so of the fibre tip. Early results suggest that the regular size and shape of the cells and cell organelles in normal mammary glands can be distinguished from the wide variations seen in malignant areas and from fibrous tissue (as might be seen in a fibroadenoma) and fat. The optical probe is thin enough to be inserted down a biopsy needle so can be used at the time of percutaneous biopsy of a palpable lump or image detected lesion (using ultrasound or MRI guidance). Other potential applications are for examining the excision margins during surgery to detect residual cancer in the wound or for examining sentinel nodes. At present, data are being gathered to correlate the results of optical biopsies with conventional biopsies from the same sites, but if the optical data prove to be as reliable as conventional histology, it could represent an important advance, even if only to identify which sites should be targeted for conventional biopsy.

## **Appendix 6**

### **“Breakthrough Breast Cancer”**

3 day meeting in London, UK, November 1999

#### **Local Destruction of Breast Cancer with Lasers**

S.G.Bown. National Medical Laser Centre, Department of Surgery  
Royal Free and University College Medical School, London

Surgical management of small, localised breast cancers has become progressively more conservative. Interstitial laser photocoagulation (ILP) is a technique for destroying lesions in the centre of solid organs without the need for open surgery. With image guidance, one or more needles are inserted into the tissue percutaneously and thin fibres passed through the needles into the target lesion. Low power laser light (typically 2-3W per fibre from a near infra-red, semiconductor laser) is delivered to gently coagulate the tissue. In studies on breast cancers imaged and treated with ILP prior to conventional surgical excision, it has been shown that contrast enhanced magnetic resonance imaging (MRI) can define both the limits of the cancer and the limits of the ILP necrosis remarkably well. Studies treating benign fibroadenomas with ILP show that the dead tissue is resorbed by normal healing mechanisms over a period of months, so these lesions can be completely cleared by ILP without the need for further intervention. Treated cancers would be expected to respond similarly, but the challenge with cancers is to be sure that no viable cancer is left after ILP. Contrast enhanced MRI is the most promising way to detect inadequately treated cancers, and studies on this are currently under way.

Laser treatment of breast cancer is still an experimental procedure and could only ever be suitable as an alternative to lumpectomy in certain carefully selected patients, but in appropriate cases, it could be an attractive option as it leaves no scars and should not change the shape or size of the breast.