

AD _____

GRANT NUMBER DAMD17-94-J-4317

TITLE: Cytokines, Neovascularization and Breast Cancer

PRINCIPAL INVESTIGATOR: Scott H. Kurtzman, M.D., F.A.C.S.

CONTRACTING ORGANIZATION: University of Connecticut
Health Center
Farmington, Connecticut 06030-3955

REPORT DATE: October 1997

19980514 132

TYPE OF REPORT: Annual

PREPARED FOR: Commander
U.S. Army Medical Research and Materiel Command
Fort Detrick, Frederick, Maryland 21702-5012

DISTRIBUTION STATEMENT: Approved for public release;
distribution unlimited

The views, opinions and/or findings contained in this report are those of the author(s) and should not be construed as an official Department of the Army position, policy or decision unless so designated by other documentation.

DTIC QUALITY INSPECTED 4

REPORT DOCUMENTATION PAGE

Form Approved
OMB No. 0704-0188

Public reporting burden for this collection of information is estimated to average 1 hour per response, including the time for reviewing instructions, searching existing data sources, gathering and maintaining the data needed, and completing and reviewing the collection of information. Send comments regarding this burden estimate or any other aspect of this collection of information, including suggestions for reducing this burden, to Washington Headquarters Services, Directorate for Information Operations and Reports, 1215 Jefferson Davis Highway, Suite 1204, Arlington, VA 22202-4302, and to the Office of Management and Budget, Paperwork Reduction Project (0704-0188), Washington, DC 20503.

1. AGENCY USE ONLY (Leave blank)		2. REPORT DATE October 1997	3. REPORT TYPE AND DATES COVERED Annual (1 Oct 96 - 30 Sep 97)	
4. TITLE AND SUBTITLE Cytokines, Neovascularization and Breast Cancer			5. FUNDING NUMBERS DAMD17-94-J-4317	
6. AUTHOR(S) Scott H. Kurtzman, M.D., F.A.C.S.				
7. PERFORMING ORGANIZATION NAME(S) AND ADDRESS(ES) University of Connecticut Health Center Farmington, Connecticut 06030-3955			8. PERFORMING ORGANIZATION REPORT NUMBER	
9. SPONSORING/MONITORING AGENCY NAME(S) AND ADDRESS(ES) Commander U.S. Army Medical Research and Materiel Command Fort Detrick, Frederick, Maryland 21702-5012			10. SPONSORING/MONITORING AGENCY REPORT NUMBER	
11. SUPPLEMENTARY NOTES				
12a. DISTRIBUTION / AVAILABILITY STATEMENT Approved for public release; distribution unlimited			12b. DISTRIBUTION CODE	
13. ABSTRACT (Maximum 200) <p>Angiogenesis is critical for breast cancer growth and metastasis. Although several angiogenic factors (AF) such as Interleukin 8 (IL-8) have been described, little is known about the regulation of this process. In many ways, cancers behave like abnormally healing wounds. Both are characterized by infiltration with inflammatory cells, fibrosis and angiogenesis. We hypothesize that tumors stimulate their own growth and metastases by the local production of angiogenic factors. Further, this production of angio-genic factors is regulated by pleuripotent cytokines, much like in healing wounds. In order to prove this hypothesis, we examined human breast cancers for the presence of known angiogenic factors and their receptors. This work demonstrated that IL-8 and its receptors are found in human breast cancer. In a second study, we examined the ability of breast cancer cells <i>in vitro</i> to produce IL-8 in non stimulated, and stimulated conditions. Those experiments proved that breast cancer cells produce AF, and that this production was upregulated by IL-1. Currently, in order to confirm and extend our observations on human tissue and cells, we are developing an <i>in vivo</i> model of implanted human breast cancer cells in immunodeficient mice. In the future, these studies will form the foundation for anti-angiogenic treatment of human tumors.</p>				
14. SUBJECT TERMS Breast Cancer			15. NUMBER OF PAGES 57	
			16. PRICE CODE	
17. SECURITY CLASSIFICATION OF REPORT Unclassified	18. SECURITY CLASSIFICATION OF THIS PAGE Unclassified	19. SECURITY CLASSIFICATION OF ABSTRACT Unclassified	20. LIMITATION OF ABSTRACT Unlimited	

FOREWORD

Opinions, interpretations, conclusions and recommendations are those of the author and are not necessarily endorsed by the U.S. Army.

____ Where copyrighted material is quoted, permission has been obtained to use such material.

____ Where material from documents designated for limited distribution is quoted, permission has been obtained to use the material.

____ Citations of commercial organizations and trade names in this report do not constitute an official Department of Army endorsement or approval of the products or services of these organizations.

In conducting research using animals, the investigator(s) adhered to the "Guide for the Care and Use of Laboratory Animals," prepared by the Committee on Care and Use of Laboratory Animals of the Institute of Laboratory Resources, National Research Council (NIH Publication No. 86-23, Revised 1985).

For the protection of human subjects, the investigator(s) adhered to policies of applicable Federal Law 45 CFR 46.

____ In conducting research utilizing recombinant DNA technology, the investigator(s) adhered to current guidelines promulgated by the National Institutes of Health.

____ In the conduct of research utilizing recombinant DNA, the investigator(s) adhered to the NIH Guidelines for Research Involving Recombinant DNA Molecules.

____ In the conduct of research involving hazardous organisms, the investigator(s) adhered to the CDC-NIH Guide for Biosafety in Microbiological and Biomedical Laboratories.

 11/30/87
PI - Signature Date

Table of Contents

COVER PAGE	1
REPORT DOCUMENTATION PAGE	2
FOREWORD	3
TABLE OF CONTENTS	4
INTRODUCTION	6
BODY	8
Specific Aim I- To characterize IL-8 expression in human breast cancer	8
Study IA: To characterize IL-8 antigen distribution in human breast biopsy specimens	8
Study IB: To demonstrate IL-8 mRNA expression in human breast cancer tissues	9
Study IC: To Correlate IL-8 expression with neovascularization in human breast biopsy specimens	10
Specific Aim II- To characterize IL-8 expression by breast cancer cell lines in vitro	11
Study IIA: To characterize the expression of IL-8 antigen by cultured human breast cancer cell lines	11
Study IIB: To quantify IL-8 expression in cytokine stimulated breast cancer cells	12
Specific Aim III- To characterize IL-B antigen expression and neovascularization in human breast cancer cells grown as tumors in nude mice	12
Study IIIA: To demonstrate IL-B antigen expression in subcutaneously implanted human breast cancers	13
Study IIIB: To establish a dual tumor model using MCF-7 and BT-20 cells	14
Specific Aim IV-Additional Studies	15
Study IVA: VEGF in Human Breast Cancer	15
Study IVB: IL-1 in Human Breast Cancer	17
Study IVC: IL-1 Receptors in Human Breast Cancer Specimens: Immunohistochemical Analysis	17
Study IVD: The effect of Thalidomide on IL-8 Expression by Human Breast Cells in vitro	18
Study IVE: IL-8 Receptors in Human Breast Cancer	19
SUMMARY	20
LITERATURE CITED	21
ORIGINAL STATEMENT OF WORK	23
TABLE 1: IL-8 STAINING	24
TABLE 2: BREAST CANCER HOMOGENATE CORRELATIONS	24

TABLE 3: VEGF LEVELS IN BREAST CELL SUPERNATANTS **24**

APPENDIX **25**

Manuscript 1: Cytokines in Human Breast Cancer: IL-1 alpha and IL-1 beta expression

Manuscript 2: Expression of Interleukin-8 Receptors on Tumor Cells and Vascular Endothelial Cells in Human Breast Cancer Tissue. Accepted for publication Sept 11, 1997 Anti Cancer Research Vol 18(2) 1998

Introduction

Human breast cancers (HBC) are histologically characterized by tumor cell proliferation and extensive new vessel ingrowth (angiogenesis) [1, 2]. Tumor cell proliferation and new vessel formation within tumor tissue is generally believed to be controlled by a variety of locally elaborated factors including cytokines (*e.g.*, growth and angiogenic factors) [3-7]. Cytokines are low molecular weight glycoproteins secreted by tissue, inflammatory, immunologic and tumor cells that can regulate cell function in both an autocrine or paracrine fashion. Cytokines, such as interleukin 8 (IL-8), basic Fibroblast Growth Factor (bFGF) and Vascular Endothelial Growth Factor (VEGF) are recognized angiogenic factors. In work done in Years 01 and 02 of this project, we demonstrated that IL-8 was present in breast cancer homogenates. Further, we showed that the level of IL-8 correlated inversely with estrogen and progesterone receptor status, *i.e.* markers of poor prognosis. In our immunohistochemical work we examined distribution of IL-8 in benign and malignant breast tissue. As a result of the comments on our Annual Report, further descriptive work was done. In this further work, we describe the presence and distribution of IL-8 in other cells found in the tumor microenvironment (TME). These observations support our conclusion that IL-8 was present in the TME and was associated with tumor cells. The distribution in endothelial cells in the TME is also described.

Previous studies in inflammation and trauma have demonstrated that angiogenic factors such as IL-8 and VEGF can be induced by specific cytokines such as IL-1 and TNF [8]. During Year 02 of this project, we quantified the production of IL-8 by breast cells in an *in vitro* model. We found that baseline production of IL-8 was low, but highly inducible by IL-1 in estrogen independent breast cancer cells suggesting that IL-1 may be a pivotal cytokine controlling the angiogenesis seen in breast cancer. These observations raise the question of whether IL-1 or TNF may control the expression of IL-8 and other pro-tumorigenic cytokines within the TME of breast cancer. Interestingly, few studies have investigated the presence, distribution or levels of IL-1 in cancer. These observations have led us to the general hypothesis that: 1) IL-1 cytokine (IL-1 α and IL-1 β) are present in

the HBC TME, 2) that IL-1 α and IL-1 β are produced by tumor cells, and 3) that the local production of IL-1 within the tumor environment is pivotal in controlling the expression of protumorigenic factors such as IL-8 in the HBC TME. Since we hypothesize that IL-1 is an important regulator of the expression of pro-tumorigenic factors such as IL-8 in the TME, it is essential that we demonstrate of the presence, distribution and levels of IL-1 family and IL-8 in HBC tissue as the first step in understand IL-1's biologic function in HBC. Although these studies were not included in the initial Statement of Work, we felt that these were important questions to be addressed in support of our general hypotheses and goals for this project.

The general approach to this Annual Report is to describe progress on the Specific Aims from the original Statement of Work. Each section includes an Introduction and Rationale, followed by Results, Interpretation, Obstacles and Future Plans. Work completed in Years 01 and 02 is not reported.

The main goal of Year 03 was to begin the development of the *in vivo* tumor model. Due to unexpected obstacles described in detail below, progress on this Specific Aim did not meet expectations. In order to continue the project, several other investigations were carried exploring the regulation of IL-8 expression. These are presented as Specific Aim IV: Additional Studies. In order to facilitate reporting, when manuscripts are available that contain the results of studies, they are included in the Appendix.

Body

Specific Aim I- To characterize IL-8 expression in human breast cancer

The work of Specific Aim I was essentially completed in Years 01 and 02 of this project. As a result of the comments on the Annual Report for Year 02, several changes were made. These included a more rigorous analysis of the immunohistochemical analysis of the IL-8 staining patterns previously identified.

Study IA: To characterize IL-8 antigen distribution in human breast biopsy specimens

Introduction and Rationale

This portion of the Study was designed to characterize the distribution of IL-8 in human breast tissue, both benign and malignant. The study was expanded in two directions based on earlier results and comments of reviewers on our prior Annual Report. The distribution of IL-8 in human breast tissue was further examined. IL-8 localization was described in tumor cells, normal breast epithelial cells, endothelial cells associated with small and large vessels within the breast tissue, and fibroblasts. The presence of IL-8 in additional human breast tissue homogenates was measured and results correlated with ER and PR levels after correction for mg cytosol protein.

Results

The results of this study are presented in Table 1. Although IL-8 was found in normal breast tissue as well as in breast tumor cells, the intensity and pattern of the staining was markedly different. These results were presented in last year's Annual Report.

Interpretation

IL-8 is present in breast cancer specimens and is associated with breast tumor cells, and vascular endothelial cells. The intensity of the staining was greater in the invasive breast cancer specimens. This suggests that IL-8 plays an important role in human breast cancer.

Obstacles

The number of normal and DCIS specimens obtained for this Study was low. This was noted in the critique of last year's Annual Report. We have therefore accumulated additional specimens and are processing them now for IL-8 as well as several other cytokines.

Breast tissue homogenates were obtained on specimens from patients undergoing surgery for invasive breast cancer. Access to breast tissue from patients with *in situ* or benign breast diseases is limited due to the nature of the surgical procedures performed on such patients and the need to analyze the specimens for histologic diagnosis. We have obtained some samples from patients undergoing breast reduction surgery. However, this breast tissue is not "normal", and a large fraction of the tissue is supporting stroma rather than breast epithelium as would be found in specimens of breast cancer. This lack of normal control tissue prevents comparison of IL-8 levels in normal breast tissue with tumor specimens.

Future Plans

We are attempting to obtain clinical information on the patients included in this study. If this is possible, we will be able to correlate the results with clinical staging and outcome. This will allow us to correlate AF expression with clinical outcome. Such information would be useful in designing therapeutic trials.

Study IB: To demonstrate IL-8 mRNA expression in human breast cancer tissues

Introduction and Rationale

The purpose of this portion of the study was to confirm that the IL-8 found associated with the breast cancer cells in Study IA was produced by the breast cancer cells. It is our belief that the *in vivo* studies in Specific Aim

II adequately addresses this issue. It is noted that in the review of the Year 02 Annual Report, the reviewers were concerned that this issue was not clear. It was also felt that the homogenate data from Study IA also did not conclusively prove this point because the breast tissue homogenates consist of a myriad of cells other than breast tumor cells. However, it is still our feeling that the immunohistochemical data and the *in vitro* data strongly suggest that the breast tumors are the source of the IL-8.

Results

Not applicable

Obstacles

Not applicable

Future Plans

Based on our observations and results, this portion of the study has been dropped. Additionally, due to budgetary constraints, it was our decision that resources are best spent in completing Task 3, the *in vivo* portion of this study.

Study IC: To Correlate IL-8 expression with neovascularization in human breast biopsy specimens

Introduction and Rationale

The results of this study were presented in last year's report. Interestingly, when we began to systematically examine vessel counts in breast tissue, we did not replicate the results seen in the literature. In fact, when the specimens were examined using the techniques described by other authors, we found that there were no differences in vessel counts between invasive cancer, non invasive cancer, and benign tissue. This issue was raised in the critiques of the Year 02 report. However, based on our observations, it did not seem sensible to expend considerable time and effort towards this goal, as useful information was not likely to be obtained.

Results

See year 02 report.

Obstacles

Not applicable

Future Plans

The original hypothesis was that the number of vessels seen in the specimens would correlate with tumor aggressiveness, and would therefore correlate with IL-8 staining. Based on our careful analysis of vessel counts in tumor specimens, using techniques found in the published literature, we were unable to demonstrate a correlation between tumor stage and microvessel density. The number of vessels observed differed markedly based on where in the tumor tissue we counted. Even when the densest areas were counted, by us and an experienced pathologist, vessel counts varied widely. This observation does not mean that there is no relationship between AF expression and angiogenesis, but rather that vessel counts as measured by immunohistochemical staining is not a reliable way to measure angiogenesis in breast cancer specimens. More reliable techniques are needed.

Specific Aim II- To characterize IL-8 expression by breast cancer cell lines in vitro

Study IIA: To characterize the expression of IL-8 antigen by cultured human breast cancer cell lines

Having demonstrated in Specific Aim I that IL-8 was present in human breast cancer tissue, Specific Aim II was designed to determine whether or not the source of IL-8 was the breast cancer cells. The majority of this work was completed in Year 01 and 02. This data was presented in the manuscript submitted for publication. This work confirmed that breast cancer cells were capable of producing IL-8.

Future Plans

Revise manuscript if needed.

Study IIB: To quantify IL-8 expression in cytokine stimulated breast cancer cells***Introduction and Rationale***

Having proven that human breast cancer cells were capable of producing IL-8, we next studied the regulation of this process. We hypothesized that since cancers behave in many ways like abnormally healing wounds, that breast cancer cells *in vitro* would react to the same regulatory cytokines described in wound healing. Thus, we examined the response of breast cancer cells to IL-1 α , IL-1 β , TNF- α and TNF β . This work was completed in Year 02, and was presented in last year's report. The manuscript has been resubmitted with revisions.

Future Plans

Having demonstrated that IL-1 is a potent inducer of IL-8 expression, we asked whether in fact IL-1 receptors were present in human breast cancer specimens. This led to the added studies presented in Specific Aim IV: Additional Studies.

Specific Aim III- To characterize IL-B antigen expression and neovascularization in human breast cancer cells grown as tumors in nude mice

Specific Aim III was designed to translate the observations of Specific Aims I and II into an *in vivo* model. The development of this model would allow us to study the influence of the host versus the tumor factors in tumor associated angiogenesis. In addition, it would allow us to study the influence of inhibitors of angiogenesis in a tumor model.

During the time that we have been waiting for the *in vivo* model to work, we have been expanding the human tissue studies and the *in vitro* studies to better understand the regulation of IL-8 expression. These additional studies were not originally included in the Statement of Work, but seemed important and reasonable in light of our early observations.

Study IIIA: To demonstrate IL-8 antigen expression in subcutaneously implanted human breast cancers

Introduction and Rationale

The experiments of Specific Aims I & II have demonstrated that IL-8 is present in human breast cancer, and that breast cancer cells are capable of producing AF such as IL-8. This Study is designed to begin to explore the production of AF by implanted tumors in immunodeficient mice. The development of this model will allow us to measure AF production using immunohistochemical techniques, and to obtain tumor homogenates for AF quantitation. These studies are critical in order to understand the influence of the host on AF production and angiogenesis in general.

The completion of these preliminary studies will form the foundation for studies on angiogenesis inhibitors.

Results

Due to the obstacles outlined below, we have only limited experience with implanted tumors. Our early results show intense IL-8 staining of tumor cells in implanted tumors. A more detailed analysis is underway. We are examining other cells and blood vessels within the tumor microenvironment for AF expression. Other AF such as VEGF and bFGF are also being analyzed.

Obstacles

In preparing for the Studies in this Specific Aim, we originally used techniques well described in the literature for establishment of breast tumors in immunodeficient mice. We also relied on the literature and our extensive experience in implanting head and neck squamous cancers in these mice. This portion of the project consumes a considerable amount of resources. Accordingly, we limited the number of mice used until the model was well established.

We found that the consistent establishment of human breast cancer lines in nude mice was extremely variable. In our original group of mice, we obtained almost no tumors despite using several breast tumor lines, and the published techniques. In an effort to improve our yield, we further consulted the published literature. In addition, we contacted several other laboratories around the country to seek other investigators experience. As a result of these conversations and our reading we first tried implanting estrogen pellets into the mice one week before tumor implantation. We had hoped to avoid this step do to the considerably increased cost that this involves. In addition, we varied the number of cells injected, the number and sites of injection, the gauge of the needle used and the solvent for the cells (i.e. media versus Hank's solution). Since this is a time intensive effort, some of these manipulations were carried out simultaneously. In our latest effort, we have used Matrigel® to suspend the cells. We are hoping to have a yield of at least 50% on the tumors so that we can efficiently carry out the Studies outlined below.

Future Plans

We are very encouraged by the results we have obtained using modifications of tumor cell implantation described above. We are also increasing the number of cell lines being utilized. Based on results from the *in vitro* studies, we are selecting estrogen dependent and estrogen independent cell lines, as well as high and low IL-8 responding cell lines. We feel this approach will allow us to dissect the role of a variety of factors in AF production and tumor growth. This data will form the foundation of the angiogenesis inhibitor studies that are the ultimate goal of this project.

Study IIIB: To establish a dual tumor model using MCF-7 and BT-20 cells

Work on this Study has not yet begun. Depending on the results of Study IIIA, this approach may or may not prove to be useful.

Specific Aim IV-Additional Studies

Study IVA: VEGF in Human Breast Cancer

In our original proposal, we postulated that IL-8 was an important AF involved in neovascularization in human breast cancer. The Specific Aims described above address this question. As noted however, several other AF have been described. It is likely that these other AF are important in human tumors such as breast cancer. In fact, we feel that it is likely that more than one AF may be active in tumors in general, and the relative importance of each may vary from patient to patient. Thus in order to design treatment strategies aimed at interfering with angiogenesis will require agents that target multiple AF, or their common pathway. Therefore, it is appropriate to examine these other AF in our breast specimens. The analyses that are described below were carried out on samples obtained for the IL-8 studies described above. This allowed us to obtain useful data with relatively little increase in cost to the project.

Introduction and Rationale

VEGF is a known angiogenic factor [9-11]. The presence of VEGF in human breast cancer has been described [12]. In fact, the importance of VEGF on patient outcome in breast cancer has also been reported [13]. Therefore our approach to VEGF was similar to our approach to IL-8 expression. That is, we first determined that VEGF was present in the breast cancer homogenates described above. We then correlated the levels of VEGF with the other factors measured, including bFGF, another known angiogenic factor [10, 14].

Next, we examined our breast cancer specimens and benign breast specimens for the presence of VEGF using immunohistochemical methods. Finally, we examined the expression and regulation of VEGF in our *in vitro* model.

Results

Experiment 1: Tissue homogenates

Eighty seven breast tumor homogenates were examined for the presence of VEGF. All specimens

examined contained measurable amounts of VEGF. The results are presented in Table 2. Interestingly, the levels of VEGF in the homogenates correlated with IL-8 levels ($p < 0.003$). There was no correlation between VEGF and any of the other factors measured. Levels of bFGF were also measured in the samples. Levels of bFGF correlated directly with ER, and there was a trend towards an association with PR levels ($p 0.07$).

Experiment 2: Immunohistochemical Analysis

We examined 39 invasive breast cancer, 8 DCIS, and 12 non malignant breast specimens for the presence of VEGF using immunohistochemical analysis. VEGF was present in the majority of specimens tested. A more detailed analysis of this preliminary data is being completed.

Experiment 3: *In vitro* Expression of VEGF by Human Breast Cells

These studies were carried out in an identical manner to the *in vitro* studies described for IL-8. Since IL-1 and TNF were found to be potent inducers of IL-8 *in vitro*, we examined the effect of these pleuripotent cytokines on VEGF production by breast cells. The results of this experiment are presented in Table 3 as the stimulation index, i.e. the amount of VEGF in the stimulated conditions divided by the levels in the control, media conditions. Unlike IL-8 expression, VEGF levels in IL-1 stimulated breast cells were only moderately elevated compared to baseline conditions. TNF only stimulated one of the six lines tested.

Obstacles

None

Future Plans

A more detailed analysis of this data is underway. The results will be presented in a manuscript in the near future. Based on these promising results, we intend to include VEGF analysis on the specimens from the *in vivo* studies as well as the *in vitro* studies examining angiogenesis inhibitors.

Study IVB: IL-1 in Human Breast Cancer

Our general hypothesis is that cancers behave as abnormally healing wounds. Accordingly, the tumors are responding in an unregulated fashion to growth and healing signal normally found in healing wounds. Our *in vitro* data on the exaggerated response of some breast cancer cells to IL-1 stimulation supports this hypothesis. Thus these studies were added to demonstrate the presence of IL-1 in human breast cancer.

Introduction and Rationale

Our *in vitro* results clearly demonstrated that in human BCC, IL-1 is a potent inducer of IL-8. This data suggests that in human breast cancer, IL-1 could be serving as an inducer of AF, in a manner similar to IL-1's role in wound healing and inflammation [15-19]. In order to support our hypothesis that IL-1 plays a role in human breast cancer we first needed to establish that IL-1 is present in breast cancer specimens. Our approach was similar to those above. We examined the breast cancer homogenates for IL-1 α and IL-1 β . We then performed immunohistochemical analysis as described.

Results

The results of this investigation are presented in the Manuscript in preparation included in the Appendix.

Obstacles

None

Future Plans

We will complete the manuscript and submit it for publication. IL-1 analysis of tumor tissue obtained during the *in vivo* studies will be performed.

Study IVC: IL-1 Receptors in Human Breast Cancer Specimens: Immunohistochemical Analysis

The above studies demonstrate that IL-1 is present in human breast cancer tissue. However, in order for

IL-1 to have an effect on breast cancer angiogenesis or growth, it must stimulate the cells. IL-1 binds to two receptors, IL-1rI and IL-1rII [19-21]. These receptors have different functions in normal wound healing. This study was included to demonstrate the presence of IL-1 receptors in human breast cancer tissues.

Introduction and Rationale

The presence of IL-1 receptors in human breast cancer was investigated using standard immunohistochemical techniques.

Results

We examined 29 samples of invasive breast cancer for the presence of IL-1rI and 26 for IL-1rII. Eight DCIS samples and 7 non malignant samples were examined for both receptors. Our preliminary results indicate that a majority of samples demonstrate the presence of both receptors in all tissues examined. The intensity of the staining was higher in invasive cancer and DCIS cells when compared to benign breast ducts. We also noted staining of surrounding stroma in the breast tissue. Interestingly, IL-1rI stromal staining was intense, IL-1rII did not appear to be present in the stroma.

Obstacles

None.

Future Plans

We plan to increase the number of specimens examined in all categories. Statistical analysis will then be performed, and a manuscript prepared.

Study IVD: The effect of Thalidomide on IL-8 Expression by Human Breast Cells in vitro

Our overall plan for this investigation is to utilize angiogenesis inhibitors to limit the growth and spread of tumors in our *in vivo* model. Thalidomide is thought to be an angiogenesis inhibitor [22].

Introduction and Rationale

The mechanism of the anti-angiogenic effects of thalidomide are not known. One possibility is that thalidomide inhibits the expression of AF by tumor cells. In order to test this hypothesis, we have begun testing the ability of thalidomide to interfere with IL-8 expression in our *in vitro* model. Since thalidomide is insoluble in aqueous solutions, we are also testing the effects of DMSO on cell viability and growth rate as well.

Results

Our preliminary results indicate that neither DMSO or thalidomide in DMSO interfere with cell growth or the expression of IL-8 in IL-1 stimulated conditions.

Obstacles

None

Future Plans

We plan to expand these experiments to include pre and post stimulation treatment of the tumor cells.

Study IVE: IL-8 Receptors in Human Breast Cancer

Introduction and Rationale:

For the functional expression of IL-8 to occur, both IL-8 and the IL-8 receptors must be present. Because we have shown IL-8 to be present in both malignant and benign breast tissue, we wanted to characterize the presence and distribution of the IL-8 receptors, IL8RA and IL-8RB, in breast tissue. This was done using standard immunohistochemical techniques.

Results:

Breast cancer tissue (36 invasive, 7 DCIS) as well as 8 benign breast disease tissue specimens were examined for both receptors. We found that both IL-8RA and IL-8RB were expressed by the tumor cells from all of the malignant specimen while only 50% of the benign ductal epithelial cell samples expressed these receptors. It appears that the IL-8 receptors are upregulated in the malignant disease state. Additionally, the majority of the specimens showed small vessel endothelial cell expression of both receptors, while IL-8RB was the primary

receptor expressed by large vessel endothelial cells.

Obstacles:

None

Future Plans:

This manuscript was accepted and will be published in *Anticancer Research* Vol.18 (2), 1998.

Summary

The studies completed to date have supported our general hypothesis that tumor cells contribute to tumor growth by producing AF. In general the concept that tumors behave as abnormally healing wounds is consistent with our observations of the response of the cells to cytokines found in healing wounds. The presence of such cytokines and their receptors in the tumor microenvironment lends further support to this approach.

More detailed analysis was done as suggested in the critique of previous Annual Reports. The work proceeded on target until the *in vivo* experiments. Several changes in the original Statement of Work have been made based on observations. These were outlined above. We feel that the changes were appropriate, and will allow successful completion of the overall project. Establishing tumors in the immunodeficient mice proved more difficult than anticipated. This has resulted in a delay in completion of the Year 03 work. None the less, we have made progress not originally anticipated regarding the control of the angiogenic process. These studies will allow us to develop the critical experiments on angiogenic inhibitors.

Literature Cited

1. Folkman, J., Angiogenesis in cancer, vascular, rheumatoid and other disease. *Nature Medicine*, 1995. 1(1): p. 27-31.
2. Weidner, N., et al., Tumor angiogenesis: a new significant and independent prognostic indicator in early-stage breast carcinoma [see comments]. *Journal of the National Cancer Institute*, 1992. 84(24): p. 1875-87.
3. Lewis, C.E., et al., Cytokine regulation of angiogenesis in breast cancer: the role of tumor-associated macrophages. [Review]. *J Leukoc Biol*, 1995. 57(5): p. 747-51.
4. Strieter, R.M., et al., Role of C-X-C chemokines as regulators of angiogenesis in lung cancer. *J Leukoc Biol*, 1995. 57(5): p. 752-62.
5. Leek, R.D., A.L. Harris, and C.E. Lewis, Cytokine networks in solid human tumors: regulation of angiogenesis. *J Leukoc Biol*, 1994. 56(4): p. 423-35.
6. Hu, D.E., Y. Hori, and T.P. Fan, Interleukin-8 stimulates angiogenesis in rats. *Inflammation*, 1993. 17(2): p. 135-43.
7. Roesel, J.F. and L.B. Nanney, Assessment of Differential Cytokine Effects on Angiogenesis Using an in vivo Model of Cutaneous Wound Repair. *Journal of Surgical Research*, 1995. 58: p. 449-459.
8. Sica, A., et al., IL-1 transcription activates the NCF/IL8 gene in endothelial cells. *Immunology*, 1990. 69: p. 548-553.
9. Ben-Av, P., et al., Induction of vascular endothelial growth factor expression in synovial fibroblasts by prostaglandin E and interleukin-1: a potential mechanism for inflammatory angiogenesis. *Febs Letters*, 1995. 372(1): p. 83-7.
10. Bikfalvi, A., Significance of angiogenesis in tumour progression and metastasis. *Eur J Cancer*, 1995. 31A(7-8): p. 1101-4.
11. Claffey, K.P., et al., Expression of vascular permeability factor/vascular endothelial growth factor by melanoma cells increases tumor growth, angiogenesis, and experimental metastasis. *Cancer Res*, 1996. 56(1): p. 172-81.
12. Yoshiji, H., et al., Expression of vascular endothelial growth factor, its receptor, and other angiogenic factors in human breast cancer. *Cancer Res*, 1996. 56(9): p. 2013-6.

13. Toi, M., et al., Tumor angiogenesis in breast cancer: its importance as a prognostic indicator and the association with vascular endothelial growth factor expression. *Breast Cancer Res Treat*, 1995. 36(2): p. 193-204.
14. Folkman, J., *Seminars in Medicine of the Beth Israel Hospital, Boston. Clinical applications of research on angiogenesis.* *N Engl J Med*, 1995. 333(26): p. 1757-63.
15. Hu, D.E., et al., Inhibition of angiogenesis in rats by IL-1 receptor antagonist and selected cytokine antibodies. *Inflammation*, 1994. 18(1): p. 45-57.
16. Elner, V.M., et al., Human corneal interleukin-8. IL-1 and TNF-induced gene expression and secretion. *American Journal of Pathology*, 1991. 139(5): p. 977-88.
17. Kasahara, T., et al., IL-1 and TNF-alpha induction of IL-8 and monocyte chemoattractant and activating factor (MCAF) mRNA expression in a human astrocytoma cell line. *Immunology*, 1991. 74(1): p. 60-7.
18. Zoja, C., et al., Interleukin-1 beta and tumor necrosis factor-alpha induce gene expression and production of leukocyte chemoattractant factors, colony-stimulating factors, and interleukin-6 in human mesangial cells. *American Journal of Pathology*, 1991. 138(4): p. 991-1003.
19. Dinarello, C.A., Biologic basis for interleukin-1 in disease. [Review] [586 refs]. *Blood*, 1996. 87(6): p. 2095-147.
20. Hsieh, T.C. and J.W. Chiao, Growth modulation of human prostatic cancer cells by interleukin-1 and interleukin-1 receptor antagonist. *Cancer Letters*, 1995. 95(1-2): p. 119-23.
21. Strassmann, G., et al., Suramin blocks the binding of interleukin-1 to its receptor and neutralizes IL-1 biological activities. *International Journal of Immunopharmacology*, 1994. 16(11): p. 931-9.
22. D'Amato, R., et al., Thalidomide is an inhibitor of angiogenesis. *Proc Natl Acad Sci U S A*, 1994. 91(9): p. 4082-5.

Original Statement of Work

Task 1 Year 1 - To characterize IL-8 expression in human breast cancer

Study IA- To characterize IL-8 antigen distribution in human breast biopsy specimens

Study IB- To demonstrate IL-8 mRNA expression in human breast cancer tissues

Study IC- To Correlate IL-8 expression with neovascularization in human breast biopsy specimens

Task 2 Year 2- To characterize IL-8 expression by breast cancer cell lines in vitro

Study A- To characterize the expression of IL-8 antigen by cultured human breast cancer cell lines

Study B- To quantify IL-8 expression in cytokine stimulated breast cancer cells

Study C- To quantify IL-B expression in co cultures of MCF-7 and BT-20 cells

Task 3. Years 3-4- To characterize IL-B antigen expression and neovascularization in human breast cancer cells grown as tumors in nude mice

Study A- To demonstrate IL-B antigen expression in subcutaneously implanted human breast cancers

Study B- To establish a dual tumor model using MCF-7 and BT-20 cells

This Statement of Work has been modified to reflect 75% of the original budget. The final study has been omitted due to the lack of resources. Based on results from Year 03, the *in vivo* portion of this study will likely be modified

Table 1: IL-8 Staining

	IBC	DCIS	Benign
Tumor cells	97%	100%	n/a
Normal ductal cells	62%	100%	100%
VEC in small vessels	72%	71%	100%
VEC in large vessels	82%	0	0
Vessel assoc. smooth muscle	84%	83%	60%
Fibroblasts			

Table 1: Percent positive staining seen in breast tissue specimens. Any degree of staining is graded as positive in this table. 0=no staining; 1+ = faint staining; 2+ = inhomogeneous staining; 3+ = homogeneous staining; 4+ = intense staining.

Table 2: Breast Cancer Homogenate Correlations

	<i>VEGF</i>	<i>bFGF</i>	<i>ER</i>	<i>PR</i>
IL-8	0.003 (D)	0.64	0.002 (I)	0.02 (I)
VEGF		0.15	0.63	0.92
bFGF			0.02 (D)	0.07 (D)

Table 2: Correlations between AF and ER and PR, expressed as p values. D = directly correlated, I = inversely correlated.

Table 3: VEGF Levels in Breast Cell Supernatants

	<i>IL-1α</i>	<i>IL-1β</i>	<i>TNFα</i>	<i>TNFβ</i>
Normal Breast Cells				
HS578Bst	2	2	-	-
Estrogen Dependent BCC				
ZR-75-1	2.5	2.5	-	-
MCF-7	3.0	3.5	2	2.5
T 47-D	-	-	-	-
Estrogen Independent BCC				
MDA-MB-231	1.5	2.0	-	-
BT-20	1.5	2.5	-	-

Table 3: Stimulation Index of VEGF expression following stimulation with IL-1 or TNF. Stimulation index is the AF level in the stimulated/ control media condition.

Appendix

Manuscript 1: Cytokines in Human Breast Cancer: IL-1 alpha and IL-1 beta expression

Manuscript 2: Expression of Interleukin-8 Receptors on Tumor Cells and Vascular Endothelial Cells in Human Breast Cancer Tissue. Accepted for publication Sept 11, 1997 Anti Cancer Research Vol 18(2) 1998

**CYTOKINES IN HUMAN BREAST CANCER:
IL-1 ALPHA AND IL-1 BETA EXPRESSION**

**Scott H. Kurtzman, M.D.^{1,2}, Kathleen Anderson, B.S.^{1,2},
Yanping Wang, M.D.^{1,2}, Lauri Miller B.S., Maria Renna, B.S.,
Marra Stankus, B.S.^{1,2} Richard Lindquist, M.D.³,
George Barrows, M.D.⁴ and Donald L. Kreutzer, Ph.D.^{1,2,3}**

¹Department of Surgery, Division of General Surgery

²Department of Surgery, Surgical Research Center

³Department of Pathology

University of Connecticut Health Center, Farmington, Connecticut 06030; and

Department of Pathology, St. Francis Hospital, Hartford, CT 06105.

Corresponding Author: Scott Kurtzman, MD
Department of Surgery
University of Connecticut School of Medicine
Farmington, CT 06030-3105
Tel.: (860) 679-2290
FAX: (860) 679-1290

Running Title: IL-1 in breast cancer

Key Words: Cytokines, Breast Cancer, Interleukin-1, Immunoassays.

ABSTRACT

Introduction: Recently, we have demonstrated the ability of interleukin-1 α (IL-1 α) and interleukin-1 β (IL-1 β) to induce production of IL-8, a known angiogenic factor (AF), from human breast cancer cells *in vitro*. This data suggests that if IL-1 is present in the tumor microenvironment, it may play a role in tumor expression of AF *in vivo*. For the present study, we hypothesize that: 1) IL-1 α and IL-1 β are present in the tumor microenvironment, and 2) IL-1 α and IL-1 β are associated with human breast cancer cells, and 3) IL-1 levels correlate with IL-8 levels in tumor tissue.

Design: To test our hypothesis, immunologic analysis was performed on: 1) human breast cancer histologic sections for IL-1 α and IL-1 β distribution; and 2) in homogenates of human breast cancer (HBC) tumors for levels of IL-1 α , IL-1 β and IL-8 antigen expression.

Patients: Breast specimens were obtained from patients undergoing surgical resections for benign or malignant breast disease.

Results: Immunohistochemical analysis demonstrated the presence of IL-1 α in tumor cells in all patients with invasive cancer or DCIS. IL-1 α staining was also seen in some normal ductal epithelium, vascular endothelial cells, vascular smooth muscle and fibroblasts. IL-1 α staining of ducts and associated tissue cells was also seen in non-malignant breast tissue. Immunohistochemical analysis of the tumor tissues indicated that intense staining for IL-1 β was seen in tumor cells in invasive and DCIS specimens, but significantly less intense staining was seen in normal

ductal epithelial cells in benign tissue. Small vessel VEC, smooth muscle and fibroblasts in both malignant and benign tissue specimens stained positively for IL-1 β antigen. Quantitative analysis of tumor homogenates for IL-1 α and IL-1 β indicated that IL-1 α was present in 58/82 tumor homogenate specimens, with a mean of 17.6 ± 3.9 pg/mg TP. IL-1 β was present in detectable quantities in 96/101 tumor homogenate specimens, with a mean of 12.02 ± 1.42 pg/mg TP. Analysis of these same tumor homogenates for IL-8 levels indicated that the IL-8 levels, $\text{---} \pm \text{---}$ pg/mg TP. Correlation of IL-1 α , IL-1 β and IL-8 levels in the tumor homogenates indicated that although there was a positive and statistically significant correlation between IL-1 α and IL-8, as well as IL-1 β and IL-8, there was no correlation between IL-1 α and IL-1 β .

Conclusions: These studies demonstrated that IL-1 α and IL-1 β are present in the tumor microenvironment and is associated with tumor cells. This supports our hypothesis that tumor-derived IL-1, present in the breast cancer environment, likely plays a key role in tumor growth and metastases by promoting protumorigenic activities such as angiogenesis, tumor cell proliferation and tumor invasion.

INTRODUCTION

Human breast cancers (HBC) are histologically characterized by tumor cell proliferation and extensive new vessel ingrowth (angiogenesis) [Folkman, 1995 #315; Weidner, 1992 #28]. Tumor cell proliferation and new vessel formation within tumor tissue is generally believed to be controlled by a variety of locally elaborated factors including cytokines (*e.g.*, growth and angiogenic factors) [Lewis, 1995 #467; Strieter, 1995 #374; Leek, 1994 #313; Hu, 1993 #55; Roesel, 1995 #1]. Cytokines are low molecular weight glycoproteins secreted by tissue, inflammatory, immunologic and tumor cells that can regulate cell function in both an autocrine or paracrine fashion. Cytokines, such as interleukin 8 (IL-8), basic Fibroblast Growth Factor (bFGF) and Vascular Endothelial Growth Factor (VEGF) are recognized angiogenic factors. Previous studies in inflammation and trauma have demonstrated that angiogenic factors such as IL-8 and VEGF can be induced by specific cytokines such as IL-1 and TNF [Sica, 1990 #59]. These observations raise the question of whether IL-1 or TNF may control the expression of IL-8 and other pro-tumorigenic cytokines within the tumor microenvironment (TME) of breast cancer. Recently, our lab has demonstrated that IL-1 stimulates the production of IL-8 in primary cell cultures of HBC, suggesting that IL-1 may be a pivotal cytokine controlling the angiogenesis seen in breast cancer (Kurtzman, list first six authors, 199____, submitted for publication). Interestingly, few studies have investigated the presence, distribution or levels of IL-1 in cancer. These observations have led us to the general hypothesis that: 1) IL-1 cytokine (IL-1 α and IL-1 β) are present in

the HBC TME, 2) that IL-1 α and IL-1 β are produced by tumor cells, and 3) that the local production of IL-1 within the tumor environment is pivotal in controlling the expression of protumorigenic factors such as IL-8 in the HBC TME. Since we hypothesize that IL-1 is an important regulator of the expression of protumorigenic factors such as IL-8 in the TME, it is essential that we demonstrate of the presence, distribution and levels of IL-1 family and IL-8 in HBC tissue as the first step in understand IL-1's biologic function in HBC.

MATERIALS AND METHODS

Patient Population

Patients for this study represent individuals who underwent surgical procedures for benign and malignant breast disorders at the John Dempsey Hospital (Farmington, CT) and Saint Francis Medical Center (Hartford, CT).

Tumor Specimens

Patient specimens used for immunohistochemistry were identified by searching the Department of Pathology databases. The paraffin tissue blocks from these patients were obtained, and 4-6 μ sections were prepared and used for the immunohistochemical studies described below. Fresh tumor tissue obtained from patients undergoing surgery (either lumpectomy or mastectomy) for breast cancer were used in this study for tissue levels of the various cytokines. IL-1 α , IL-1 β , IL-8 and protein analysis was performed on the tumor tissue homogenates (see below).

Tissue Homogenates

Tumor tissue samples were stored in a -70°C freezer until processing. They were then thawed, weighed, placed in 1 ml of phosphate buffer saline (PBS) per 0.25 grams of tumor or control tissue, and homogenized in a tissue homogenizer. Triton (0.01 percent final concentration) was then added to the supernatants, which were then re-homogenized. The resulting homogenate was centrifuged twice at 10,000g (4°C). The supernatants were then aliquoted and frozen at -20°C.

Protein levels in the tissue homogenate specimens were determined using the Bradford Protein Assay (BioRad, Richmond, CA). The cytokine levels in the homogenates were determined, as described below.

General Histopathology

Tumor Differentiation: The cancer specimens were examined by a pathologist at our institution, who classified the lesions as invasive breast cancer (IBC), non-invasive breast cancer (DCIS) or benign (non-atypical/proliferative disease).

Immunohistochemical Analysis

Tissue was embedded in paraffin and processed into 4-6 µm sections. Paraffin-embedded sections were then deparaffinized in xylene and rehydrated in graded alcohol (100%, 95%, 75% and 50%). Samples were immersed in methanol containing 0.01% hydrogen peroxide (H₂O₂) for 20 minutes for inhibition of

endogenous peroxidases, allowed to air dry, and then blocked with 5% normal rabbit serum (Vector, Burlington, CA) in PBS at room temperature (RT) for 1 hour. The resulting sections were then washed three times with PBS (pH 7.4). Next, primary antibodies (IL-1 α 1:100 dilution, IL-1 β 1:100 dilution (Santa Cruz Laboratories, Santa Cruz, CA) in blocking serum were added to the slides. The sections were incubated overnight at 4°C. As a specificity control, the primary antibody was pre-incubated (2 hrs at RT) with a 10X (by weight) excess of the individual antigens prior to addition to the histologic sections. Following overnight incubation, biotinylated rabbit anti-goat IgG (Vector, Burlington, CA) was applied to the sections and allowed to incubate for one hour at RT. HRP-streptavidin (Zymed, San Francisco, CA) at a 1:100 dilution in PBS was applied to the sections and incubated at RT for 1 hour. The sections were incubated sequentially with 3-amino-9-ethyl carbazole (AEC) in 0.1 molar sodium acetate buffer (pH 5.0) and 0.03 percent H₂O₂ for 30 minutes at RT. Samples were then counter-stained with Mayer's hematoxylin (Sigma, St. Louis, MO) for 10 minutes, washed extensively in distilled H₂O, and dipped in dilute ammonium hydroxide. Sections were then mounted in crystal mounting solution (Biomedica, Foster City, CA) and analyzed by light microscopy.

The immunohistochemical analysis was performed by two of the authors. Staining was graded from 0-4+, 0 = no staining; 1+ = faint staining; 2+ = in-homogeneous staining; 3+ = homogeneous staining; and 4+= intense staining. Any staining (1+ or higher) was considered positive.

Cytokine Analysis

Tumor tissue homogenates were initially evaluated for total protein (TP) content using the Bradford assay technique (BioRad, Richmond, CA). Immunoassays of tumor homogenates were performed using IL-1 α and IL-1 β enzyme linked immunoabsorbant assay (ELISA) that was developed in this laboratory using matched antibody pairs and cytokine standards (Endogen, Cambridge, MA). Briefly, for each assay, monoclonal anti IL-1 α or IL-1 β antibody was coated onto microtiter plats, and incubated overnight at RT. Unbound antibody was washed away and a blocking solution (PBS with 4% BSA pH 7.2) was added to the plate and incubated for 1 hour at RT. The blocking solution was washed away and samples or standards were added to the multiwell plates. All assays were done in duplicate. For the IL-1 α assay, the samples were incubated at RT for 1 hour and then secondary polyclonal anti IL-1 α antibody was added, and the combination incubated for 1 hour. For the IL-1 β assay, the secondary polyclonal antibody was added simultaneously with the samples or standards, and incubated at RT for 2 hours. Following a wash step to remove any unbound sample, standard or antibody, HRP-streptavidin (Zymed, San Francisco, CA) at a 1:8000 dilution in PBS 4% BSA was added and incubated for 30 minutes at RT. Unbound HRP-streptavidin was washed away, and TMB substrate (Dako, Carpinteria, CA) was added to the wells and color developed in proportion to the amount of IL-1 α or IL-1 β in the sample. The color development was stopped with 4N H₂SO₄ and the plate

read at 450 nm. A standard curve was used to determine the quantity of cytokine in the sample. All results were expressed as picograms per milligram total protein.

IL-8 levels were quantified using RIA methods as previously described [Cohen, 1995 #137]. Standard curves were used to determine the quantity of cytokine in the sample based on the level of radioactivity of each sample. All samples were assayed in duplicate. Results were expressed as the number of picograms of IL-8 per milligram of TP.

Statistical Analysis

The immunohistochemical staining was analyzed by comparing the mean grade for each group (invasive breast cancer, DCIS, benign) using the one-way ANOVA analysis from the JMP 3.0 statistical package (SAS, Cary, NC). A linear regression analysis was also run to ascertain if a relationship existed between the staining for IL-1 α and IL-1 β for each patient.

To analyze the cytokine levels in the tumor homogenates, the data was transformed into natural log to achieve a normal distribution. The transformed values were then analyzed using a linear regression model (JMP Software). A p value of <0.05 was considered statistically significant.

RESULTS

INTERLEUKIN-1-ALPHA ANALYSIS

Histopathologic Correlations

In the present study, we examined 50 breast specimens for IL-1 α presence and distribution. Of these, 32 were from patients with invasive breast cancer, 11 were from patients with non-invasive (DCIS) ductal cancer, and 7 were from patients with non-atypical proliferative breast diseases. In addition, we examined 42 breast specimens for IL-1 β presence and distribution. Of these, 26 were from patients with invasive breast cancer, 9 were from patients with non-invasive (DCIS) ductal cancer, and 7 were from patients with non-atypical proliferative breast diseases. **kathy will check if the 41 betas are in the 51 alphas how many patients were included in both alpha and beta analysis, ie what is the ooverlap. what are the right #'s for specimens, discrepancy between table and paragraph above.**

Interleukin-1-alpha Immunohistochemistry

Initially, we determined the distribution of IL-1 α within the tumor microenvironment IBC, DCIS, and benign breast disease specimens. Our initial observations indicated that IL-1 α was consistently expressed in the tumor cells of 100% of specimens from patients with both IBC and DCIS (see Figure 1 and Table 1). When the histologically normal ducts were present within the specimens, we saw that in DCIS and benign specimens, normal ductal epithelial cells appeared

consistently IL-1 α positive (Table 1: 83% DCIS, 100% IDC and 100% benign).

Interestingly, normal ducts in IBC showed significantly fewer specimens with positive ductal epithelial cells. However, the intensity of the IL-1 α staining differed when comparing the benign and malignant tissues. The intensity of the staining of the tumor cells in the IBC and DCIS specimens was significantly higher than the staining of the ductal cells in the benign breast samples **INSERT MEAN SCORING VALUE** ($p < 0.01$ for both).

Analysis of IL-1 α expression in small vessels endothelium within the specimens indicated that IL-1 α was consistently expressed in the benign (71%) and DCIS (60%) specimens, as opposed to the invasive breast cancer where IL-1 α was seen in only 41% of the specimens. Interestingly, IL-1 α expression in the large vessel endothelium of the same specimens demonstrated that in benign disease there was a similar occurrence of IL-1 α staining (71%) compared to the small vessel endothelium (71%). However, the occurrence of IL-1 α staining of large vessel endothelium in the tumor specimens was dramatically lower when compared to IL-1 α staining of the small vessel endothelium in the same specimens (DCIS 20% vs. 60% or IBC 19% vs. 41%). Further analysis of the large blood vessels demonstrated that there was consistent expression of IL-1 α in the smooth muscle cells surrounding large vessels in benign and DCIS specimens, but markedly diminished expression in the smooth muscle cells associated with invasive breast cancer.

Finally, analysis of the fibroblasts within the stroma of the specimens indicated that there was IL-1 α staining of fibroblasts in all three types of breast specimens. ~~Interestingly, when IL-1 α staining was evaluated in non-activated fibroblasts, we saw significant staining in the fibroblasts present in invasive and benign breast disease, but virtually no staining in fibroblasts associated with DCIS.~~ Thus, these data clearly demonstrate that tumor cells likely represent a major and consistent source of IL-1 α in the tumor microenvironment, and that other cells such as vascular endothelial cells also can contribute to IL-1 α levels within the tumor.

Interleukin-1-alpha Quantitation

Analysis of breast tumor homogenates indicated that 58 of 82 cancer specimens had detectable levels of IL-1 α (i.e. _____ pg/ml) and that IL-1 α levels ranged from 2.02 pg/mg TP to 236.2 pg/mg TP, with a mean of 17.6 ± 3.90 pg./mg TP.

INTERLEUKIN-1-BETA ANALYSIS

Interleukin-1-beta Immunohistochemistry

need to put in 3's of samples
Immunohistochemical analysis of the human breast specimens for IL-1 β indicated that tumor cells showed a consistent staining of IL-1 β (Figure 1 and Table 2: IBC 83%, DCIS 80%). Analysis of normal ducts found in the specimens indicated that ductal epithelium in IBC, DCIS, and benign samples showed similar levels of positive staining for IL-1 β . The intensity of

staining of the tumor cells in IBC and DCIS was significantly higher than the staining of the ductal cells in the benign breast samples (i.e. IBC: _____ \pm _____ and DCIS: ____ \pm ____) ($p < 0.04$, $p < 0.03$ respectively). Interestingly, when the tissue was further evaluated for IL-1 β expression, the small vessel endothelium associated with invasive breast cancer demonstrated more frequent staining (63%) when compared to either DCIS or benign (i.e. 30 and 29%, respectively).

Analysis of IL-1 β staining in the large vessels of all three groups, demonstrated staining in fewer of the specimens (8-14%) when compared to the small vessel endothelium in the same specimens (29-63%). Analysis of the smooth muscle cells associated with vessels, also showed an interesting pattern in which smooth muscle cells associated with invasive cancer had a consistently higher rate of staining (75% staining) when compared to either DCIS (40%) or benign (29%).

Finally, analysis of specimen fibroblasts indicated that fibroblasts in invasive and DCIS showed 50% or greater staining for IL-1 β , but fibroblasts present in the benign breast disease did not show any staining for IL-1 β . Thus, these data suggest that the tumor cells may be a major source of IL-1 β , like IL-1 α , in addition to the tumor cells a number of cells in the tumor microenvironment also have IL-1 β associated with them.

Interleukin-1-Beta Quantitation

Analysis of tumor homogenates for IL-1 β antigen indicated that 96 of 101 cancer specimens had detectable levels of IL-1 β (i.e. > ____ pg/ml) **kathy or lauri**

please put in the lower limit of detection #, ranging from 1.43 pg/mg TP to 96.3 pg/mg TP. The mean IL-1 β value for the 101 samples was 12.02 ± 1.42 pg/mg TP.

IL-8 Quantitation

Analysis of tumor homogenates for IL-8 antigen indicated that xx of yyy cancer specimens had detectable levels of IL-8 (i.e. > ____ pg./ml) **kathy or lauri**
please put in the lower limit of detection #, ranging from xyz pg/mg TP to abc pg/mg TP. The mean IL-8 value for the yyy samples was $def \pm gh.i$ pg/mg TP.

Interleukin-1 α , Interleukin-1 β and Interleukin-8 Correlations

The levels of IL-1 α in the tissue homogenates was compared with levels of IL-8, and IL-1 β . Interestingly, we found that IL-1 α levels correlated directly with levels of IL-8 (Table 4), a know angiogenic factor, but IL-1 α levels did not correlate with IL-1 β levels in the homogenates. As with IL-1 α , the levels of IL-1 β directly correlated with levels of IL-8 (Table 4), but not with IL-1 α .

DISCUSSION

It has previously been suggested that wounds and tumors share so many common features (*e.g.* cell proliferating angiogenesis, fibrosis, fibrin deposition, etc.) that tumors can be viewed as wounds that will not heal [Dvorak, 1986 #94]. We have extended this concept to investigate the role of cytokines, specifically, the IL-1 family of cytokines that are involved in wound healing, in tumor growth and metastasis in HBC.

Cytokines have been implicated as important regulators of cell function in a variety of diseases. For example, cytokines have been considered to be key regulators of tissue cells and leukocytes in chronic inflammatory diseases such as rheumatoid arthritis [Brennan, 1990 #106; Folkman, 1995 #315; Endo, 1991 #110; Elford, 1991 #213; Koch, 1991 #228; Lindley, 1991 #121; Peichl, 1991 #256], inflammatory bowel disease [Hyams, 1995 #143; Radema, 1995 #177], and interstitial lung disease [Kline, 1993 #470] to name but a few. It has been further postulated that in the case of acute and chronic inflammation cytokines such as IL-1 and Tumor Necrosis Factor (TNF) are present in the tissue microenvironment in quantities sufficient to control both the inflammatory and reparative processes. Thus, the important role of cytokines in general, and IL-1 specifically, in inflammation and wound healing is clearly established. The scientific basis for the role of IL-1 in human breast cancer is presented below.

IL-1 Cytokine Family

The IL-1 family consists of two polypeptides, IL-1 α and IL-1 β . These cytokines possess a wide spectrum of properties that encompass inflammatory, metabolic, physiologic, hemopoetic, and immunologic functions [Dinarello, 1991 #471]. Although the term interleukin means "between leukocytes," IL-1 is synthesized by and regulates a variety of cells, including leukocytes, macrophages, astrocytes, endothelial cells, smooth muscle cells, fibroblasts, synovial lining cells, dermal dendritic cells, keratinocytes, intestinal, gingival, and cervical epithelium, natural killer cells, and maternal placental cells [Dinarello, 1991 #471]. Because IL-1: 1) regulates cell function in a large variety of cells; 2) is present in many different organs; 3) is associated with numerous disease processes; and 4) can induce the expression of a variety of other cytokines and receptors, it is often considered an "inducer" or "controller cytokine" in the hierarchy of pro-inflammatory cytokines. IL-1 α and IL-1 β bind to two IL-1 receptor molecules, an 80-Kd receptor (IL-1 RtI), and a 68-Kd receptor (IL-1 RtII) [Dinarello, 1991 #471]. In general, IL-1 α binds preferentially to the type I receptor, and IL-1 β binds optimally to the type II receptor [Dinarello, 1996 #514]. Knowledge of the mechanisms which regulate IL-1 is essential in order to not only determine its potential biologic role on tissue cells, but also its regulatory role in the tumor microenvironment.

IL-1 Family and Cancer

A considerable volume of literature exists demonstrating the *in vitro* ability of IL-1 to regulate a variety of cellular functions in tumor cells[Cohen, 1995 #137; Mann, 1992 #147;Basso, 1995 #528; Alexandroff, 1994 #525;Koch, 1995 #517;Hsieh, 1995 #519; Raitano, 1993 #520; Woodworth, 1995 #541]. Surprisingly little information exists on the *in vivo* expression and distribution of IL-1 in human cancers [Kayser, 1995 #511;Yoshimi, 1994 #542].

In vitro studies have shown that IL-1 can induce a variety of factors and functions in breast cancer cells. For example, malignant human breast tumors are known to contain high levels of prostaglandins. In a recent study [Schrey, 1995 #489], IL-1 β induced PGE2 production in breast fibroblasts. In that study, only two BCC lines, MDA-MB-231 and Hs578T demonstrated increases of PGE2 in response to IL-1 β . Several other BCC lines did not respond. IL-1 is also known to inhibit the growth of cultured BCC. For example, insulin and insulin like growth factor I (IGF-I) induced BCC proliferation was inhibited by the presence of IL-1 α and IL-1 β in MCF-7 cells. In that study, insulin receptor protein and mRNA were increased in the presence of IL-1 β . Additional data in that study suggests that IL-1 antagonizes insulin and IGF-I mitogenic effects in MCF-7 by blocking tyrosine kinase [Costantino, 1996 #491]. Danforth *et al*, examined the ability of IL-1 and IL-6 to inhibit BCC growth *in vitro*. These investigators found that both IL-1 and IL-6 inhibited growth of MCF-7 BCC. IL-1 alone had a greater effect than IL-6 alone. When the two were combined, the effect was synergistic. Further, IL-1 and IL-6

decreased the estradiol stimulated growth of the BCC. IL-1 but not IL-6 caused increased secretion of TGF- β by the BCC [Danforth, 1993 #500].

Interestingly, IL-1 was found to up-regulate HLA class I and HLA Class II (DR) antigen expression on the cell surface of ZR-75-1 cells. This up-regulation of antigens was associated with increased TNF expression [Speiser, 1993 #496]. Thus, IL-1 appears to play an important role in the regulation of breast cancer cell function and growth *in vitro*. Surprisingly, nothing is known about the presence and role of IL-1 in human breast cancer *in vivo*. Our present study is intended to fill this gap in our knowledge regarding the presence and localization of IL-1 in human breast cancer.

Our present studies demonstrate that IL-1 α and IL-1 β are present in HBC tumor homogenates (17.65 ± 3.9 pg./mg TP and 12.02 ± 1.42 pg./mg TP, respectively). Although these findings clearly demonstrate the presence of IL-1 in the tumor tissue microenvironment, they can provide no insight into the demonstration of IL-1 α or IL-1 β in the breast cancer microenvironment. In order to describe the distribution of IL-1, our immunohistochemical analysis of breast cancer and non malignant breast specimens was performed, and demonstrated the presence of IL-1 α and IL-1 β associated with a variety of cells in the tumor microenvironment (see Table 3). Specifically, IL-1 cytokines were found to be associated with breast tumor epithelial cells, and with blood vessels found in the tumors. Our studies showed that IL-1 α was not found in endothelial cells associated small blood vessel found in HBC specimens. IL-1 α was also not seen in

the endothelial cells of large blood vessels associated with IBC or DCIS, but was seen in VEC present in non malignant breast tissue.

A similar staining pattern was seen for IL-1 β staining in the malignant tissue. The most striking difference was the lack of IL-1 β staining in the specimens from non-malignant breast tissue, when compared to IL-1 α staining (see Table 3). Our studies therefore clearly demonstrate the presence and distribution of IL-1 in malignant and non malignant breast tissues. The differential staining of IL-1 α and IL-1 β in malignant and non-malignant tissues suggests that a complex regulatory network of cytokines exists, and likely influences the growth and metastasis of human BCC *in vivo*.

Based on these observations we have constructed a hypothetical model describing the role of IL-1 cytokines within the breast cancer microenvironment. In this model, we suggest that IL-1 is expressed by both tumor cells and surrounding stromal cells. The IL-1 thus produced then acts in both an autocrine and paracrine fashion to 1) regulate tumor and tissue cell proliferation and 2) control production of protumorigenic factors such as angiogenic factors, growth factors, metalloproteases, etc. Interestingly, and in support of our hypothesis, tissue levels of both IL-1 α and IL-1 β both correlated with tissue levels of IL-8, a known angiogenic factor. Therefore, future studies to evaluate our hypothetical model are needed to directly demonstrate the pivotal role that the IL-1 family of cytokines plays in regulating tumor growth and metastasis.

For example, in order to directly demonstrate the important role of IL-1 in

tumor growth and metastasis, and thus validate our model, future studies utilizing both IL-1 antagonists (e.g., antibodies and inhibitors), as well as genetically engineered tumor cells and mice (e.g., IL-1 and IL-1 receptor knockout cells and mice) will be essential. This current demonstration of the presence of IL-1 α and IL-1 β in human breast cancer provides the foundation for future diagnostic and therapeutic modalities that may be clinically useful for patients with breast cancer.

ACKNOWLEDGMENTS

This study is supported by a Department of Defense, U.S. Army Medical Research and Materiel Command Breast Cancer Research Program Grant DAMD17-94-J-4317.

REFERENCES

FIGURE LEGENDS

Figure 1: IL-1 α and IL-1 β immunohistochemical analysis of invasive DCIS and benign human breast disease tissue. {insert figure identifiers a,b,c, etc{

Table 1: Tissue distribution of IL-1 α in human breast disease tissue using immunohistochemical staining. The data is expressed as the number of positive samples over the total number tested, percent positive is in parantheses.

Table 2: Immunohistochemical distribution of IL-1 β in human breast disease tissue.

Table 3: Summary of the cell distribution of IL-1 α and IL-1 β in human breast disease tissue.

Table 1 IL-1 α Immunohistochemistry

Tissue	Tumors	Ducts	Small Vessels Endo	Large Vessels Endo	Vascular Smooth Muscles	Fibroblasts
Invasive (n=32)	32/32 (100%)	9/9 (100%)	22/31 (71%)	11/28 (39%)	14/28 (50%)	14/31 (45%)
in situ (n=11)	10/10 (100%)	9/10 (90%)	6/9 (67%)	3/10 (30%)	6/10 (60%)	5/10 (50%)
Non malignant (n=7)	N/A	7/7 (100%)	5/7 (71%)	4/7 (57%)	5/7 (71%)	4/7 (57%)

Table 2: IL-1 β Immunohistochemistry

Tissue	Tumors	Ducts	Small Vessels Endo	Large Vessels Endo	Vascular Smooth Muscles	Fibroblasts
Invasive (n=26)	23/26 (88%)	14/18 (77%)	21/26 (81%)	4/25 (16%)	18/25 (72%)	10/24 (42%)
in situ (n=9)	7/9 (78%)	5/9 (56%)	4/9 (44%)	1/9 (11%)	3/9 (33%)	4/9 (44%)
Non malignant (n=7)	N/A	6/7 (86%)	4/7 (57%)	2/7 (29%)	3/7 (43%)	0/7

Table 3

	IBC IL-1 α	IBC IL-1 β	DCIS IL-1 α	DCIS IL-1 β	Benign IL-1 α	Benign IL-1 β
Tumor cells	++++	++++	++++	++++	N/A	N/A
Normal ductal cells					++++	++
VEC in small vessels	++	+++	+++++	++	+++	++
VEC in large vessels	+	+	+	+	+++	+
Vessel assoc. smooth muscle	++	+++	+++	++	+++	++
Fibroblasts	++	+++	++	++	+++	0

IBC = Invasive breast cancer; DCIS = ductal carcinoma *in situ*

Table 4

	<u>IL-1β</u>	<u>IL-8</u>
<u>IL-1α</u>	<u>0.61</u>	<u>0.01</u>
<u>IL-1β</u>	<u>X</u>	<u>0.05</u>

Table 4: Comparison of cytokine levels in tissue homogenates using xyz test.
Values shown are p values.

ADD R VALUE

IL-8 RIA

Lauri need to check this paragraph

IBC homogenates were analyzed by an IL-8 specific radioimmunoassay (RIA) developed in our laboratory. Briefly, sample (100 μ l) was incubated at RT for 1 hour with chicken anti-human IL-8 antibody diluted 1:2,000 in RB buffer (1% BSA in PBS). Human ¹²⁵I-IL-8 (NEN Products, Boston, MA) diluted in RB buffer (70-80,000 CPM/ml) was added (100 μ l) and the reaction mix was incubated for 1 hour at room temperature. Next, 500 μ l of fetal bovine serum was added as carrier protein. The immune complex was precipitated out of solution using a 40% saturated ammonium sulfate solution, and pelleted (3000 RPM for 20 minutes), blotted and counted (gamma counter 1 min.). Samples were quantified by reference to a standard curve constructed using rIL-8 standards (0.039-10 ng/ml). Samples were assayed multiple times and results are expressed as the mean \pm S.D.

Standard curves were used to determine the quantity of cytokine in the sample based on the level of radioactivity of each sample using regression analysis. All samples were assayed in duplicate.

No. 5897.C
Please mark the
appropriate section
for this paper:
 Experimental
 Clinical
 Epidemiological

Name:
FAX:

Expression of Interleukin-8 Receptors on Tumor Cells and Vascular Endothelial Cells in Human Breast Cancer Tissue

LAURI J. MILLER^{1,3}, SCOTT H. KURTZMAN², YANPING WANG²,
KATHLEEN H. ANDERSON¹, RICHARD R. LINDQUIST¹ and DONALD L. KREUTZER^{1,2},

¹Department of Pathology and ²Department of Surgery
University of Connecticut, School of Medicine, Farmington, CT 06030;
³St. Joseph College, West Hartford, CT 06117, U.S.A.

Abstract. Background: Recently, we demonstrated the presence of Interleukin-8 (IL-8) in human breast cancer (HBC) tissue. We hypothesize that the IL-8 receptors are present and play a role in tumor cell and vascular endothelial cell (VEC) activation (e.g. proliferation and angiogenesis). **Materials and Methods:** Immunohistochemical analysis for IL-8 receptors (IL-8RA and IL-8RB) was performed on 43 malignant and 8 benign breast tissue samples. **Results:** Tumor cells expressed IL-8RA and IL-8RB in all of the malignant specimens. Only 50% of the benign ductal epithelial cell (DEC) samples expressed these receptors. The majority of small vessel endothelial cells (SVEC) expressed IL-8RA and IL-8RB, while large vessel endothelial cells (LVEC) showed primarily IL-8RB expression. **Conclusions:** Our results demonstrate that tumor and VEC express the IL-8 receptors and likely play a role in regulating tumor and VEC activation which controls proliferation, angiogenesis and metastasis in HBC.

Recently the cytokine Interleukin 8 (IL-8) has been shown to be both a potent angiogenic factor (AF) and a growth factor in both normal and disease states. For example, IL-8 has been proven to stimulate angiogenesis in the normally avascular environment of the cornea (1). Additionally, IL-8 has been shown to be present in many neoplastic diseases including in cultured melanoma cells (2) and in prostate (3) and head and neck cancers (4). Previously we have reported IL-8 expression on tumor cells and on the VEC in human breast cancer tissue (Kurtzman *et al*, Abstract presented at Society of Surgical Oncology, March 1994). For the functional

*Supported by: Department of Defense Grant DAMD 17-94-J-4317. Presented at the National Meeting of the Society of Surgical Oncology, Chicago, IL, March 1997.

Correspondence to: Dr. Donald L. Kreutzer, Department of Pathology, University of Connecticut School of Medicine, Farmington, CT 06030-3105, U.S.A. Phone: (860) 679-2818, Fax: (860) 679-2936 e-mail: kreutzer@NSO2.uchc.edu

Key Words: Interleukin -8 (IL-8), IL-8 receptors, human breast cancer, tumor proliferation, angiogenesis.

expression of IL-8 to occur, both IL-8 and the IL-8 receptors must be present within the tumor environment.

Currently, nothing is known regarding the expression of the IL-8 receptors (IL-8RA and IL-8RB) in breast cancer or in any other neoplastic disease. For the present study, we hypothesized that IL-8 receptors are expressed on the tumor cells as well as on the VEC within the tumor microenvironment, in human breast cancer and likely contribute to tumor growth and angiogenesis. To test this hypothesis, we determined the distribution of the two IL-8 receptors, IL-8RA and IL-8RB, on cells in tissue from malignant and benign human breast disease patients using immunohistochemical techniques. Our studies clearly demonstrate that IL-8RA and IL-8RB are present on both tumor cells and VEC, and support our hypothesis on the role of the IL-8 system in human breast cancer.

Materials and Methods

Breast tissue specimens. Breast cancer tissue [36 invasive, 7 ductal carcinoma in situ (DCIS)] as well as 8 benign breast disease tissue specimens were obtained from archival specimens in the Department of Pathology, University of Connecticut School of Medicine. These formalin fixed paraffin-embedded tissue were cut into 4mm sections and mounted on slides for evaluation.

Immunohistochemical techniques. Immunohistochemical analysis of the tissue specimens was performed by indirect immunoperoxidase staining as previously described (4). Anti human IL 8 receptor A and B (IL-8RA, IL-8RB) were obtained from Santa Cruz Biotechnologies, (Santa Cruz, CA). For all of the immunohistochemical analysis performed in this study, a set of controls was run to verify the specificity of the antibody reaction. All of the control slides were negative, and showed no evidence of staining. Figure 1 (C,F,I,L) shows an example of these control slides.

The stained slides were evaluated. For the malignant diagnoses, (invasive and DCIS) the presence of staining on the tumor cells, VEC, [both small vessels (SVEC) and large vessels (LVEC)], along with the smooth muscle surrounding the arterial large vessels was recorded. In samples where areas of adjacent normal or hyperplastic ductal morphology was present, the staining pattern of these ducts was noted. On the benign specimens, the staining pattern of the ductal epithelial cells (DEC) was noted, as well the staining of the SVEC, LVEC and the surrounding arterial smooth muscle.

When evaluating the VEC, a distinction was made between the SVEC and LVEC. Any vessel containing only endothelial cells (less than 6 cells

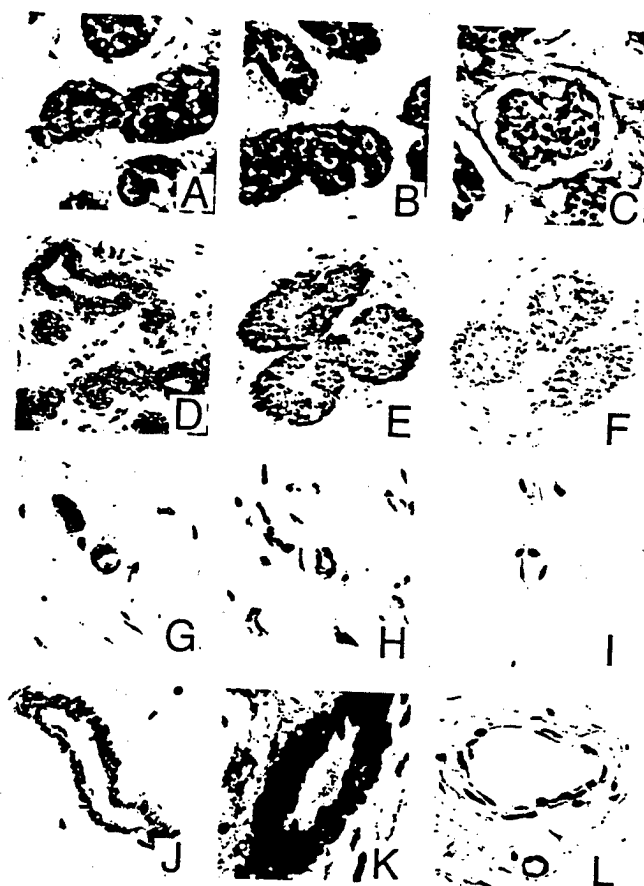


Figure 1. Expression of IL-8RA and IL-8RB by Tumor Cells, Benign Ductal Epithelial Cells (DEC) and Vascular Endothelial Cells (VEC) [Both Small Vessel Endothelial Cells (SVEC) and Large Vessel Endothelial Cells (LVEC)]. A) tumor cell expression of IL-8RA (40x), B) tumor cell expression of IL-8RB (40x), C) tumor cell control (40x), D) benign DEC expression of IL-8RA, [note apical staining pattern] (20x), E) benign DEC expression of IL-8RB (20x), F) benign DEC control (20x), G) SVEC expression of IL-8RA (40x), H) SVEC expression of IL-8RB (40x), I) SVEC control (40x), J) LVEC expression of IL-8RA, [note negative endothelial cells and positive smooth muscle] (40x), K) LVEC expression of IL-8RB, [note positive endothelial cell and smooth muscle] (40x), L) LVEC control (40x).

with no evidence of a smooth muscle layer) was labeled SVEC. Larger vessels, (> 6 VEC), or vessels that clearly contained a smooth muscle layer (i.e. arteries) were labeled LVEC.

Results

Malignant tumor cell IL-8RA expression. All of the invasive (36/36) and DCIS (7/7) HBC specimens stained positively for the IL-8RA receptor on tumor cells. (Figure 1A) Interestingly, IL-8RA expression showed a wide degree of variation of staining within a tumor, i.e. staining tended to be heterogeneous, associated with individual cells or within groups of tumor cells. In well differentiated tumors, with abortive duct formation, staining was in an apical, circular pattern. A number of malignant specimens examined contained areas of normal or hyperplastic ductal morphology adjacent to the tumor. The majority of these areas expressed the IL-8RA on the ductal epithelial cells. Again, as seen in the malignant samples, staining was in an apical pattern, with intense staining closest to the lumen of the duct. The

myoepithelial cells surrounding the ductal epithelial cells showed little evidence of IL-8RA expression.

Malignant tumor cell IL-8RB expression. All invasive (36/36) and DCIS (7/7), HBC specimens stained positively for the IL-8RB receptor on tumor cells. (Figure 1B) Unlike the heterogeneous, cell associated staining displayed for IL-8RA, the staining pattern for IL-8RB was homogeneous throughout the tumor with only slight variations within a specimen. On samples where areas of normal or hyperplastic ductal morphology was present adjacent to the tumor, less than half of the samples showed IL-8RB expression on the ductal epithelial cells. When staining in the non-neoplastic specimens was present, it was not in the apical pattern apparent for IL-8RA expression. Almost all of the myoepithelial cells expressed the IL-8RB. In summary, all of the HBC specimens examined showed that tumor cells express both the IL-8RA and IL-8RB. These results demonstrate that if IL-8 is indeed acting as a growth factor, it can be recognized by the tumor cells in HBC. Figure 1 (A-B)

Table I Expression of IL-8 receptors in malignant and benign breast tissue.

	IL-8RA		IL-8RB	
	POS ¹	%POS ²	POS ¹	%POS ²
Malignant				
Tumor cells				
Invasive	36/36	100	36/36	100
DCIS	7/7	100	7/7	100
Total	43/43	100	43/43	100
SVEC				
Invasive	24/36	67	34/36	94
DCIS	4/7	57	7/7	100
Total	28/43	65	41/43	95
LVEC				
Invasive	6/36	17	26/36	72
DCIS	0/7	0	4/7	57
Total	6/43	14	30/43	70
Benign breast disease				
Ductal cells				
Epithelial	4/8	50	3/8	37
Myoepithelial	7/8	88	8/8	100
SVEC	7/8	88	7/8	88
LVEC	1/8	13	6/8	75

1. POS: # positive / total
2. % POS: percent positive

displays the tumor cell expression of IL-8RA and IL-8R.

Malignant SVEC IL-8RA expression. In the invasive HBC, 67% (24/36) and in DCIS, 57% (4/7) of the samples showed some positive staining on the SVEC for IL-8RA. (Figure 1H) Overall, or 65% (28/43) of the malignant HBC patients showed IL-8RA expression. Even though positive SVEC's were located in 28 of the slides, only 11 (25%) had SVEC staining that was clearly evident while the remainder showed areas of positive and negative SVEC staining.

Malignant SVEC IL-8RB expression. A far different picture was present for IL-8RB expression on SVEC. (Figure 1I) In the invasive samples, 94% (34/36) and 100% (7/7) of DCIS, were positive for IL-8RB expression. A total of 95% (41/43) of the malignant specimens showed positive staining for this receptor. The SVEC's were very visible and easy to locate in the majority of slides.

Malignant LVEC IL-8RA expression. In the invasive samples

Table II. Comparison of IL-8, IL-8RA and, IL-8RB expression in malignant and benign breast tissue.

Tissue	IL-8	IL-8RA	IL-8RB
Malignant			
Tumor Cells	+++	+++	+++
SVEC	+++	++	+++
LVEC	+++		++
Benign breast disease			
Ductal epithelial cells	+++	+	+
SVEC	+++	++	+++
LVEC	---	---	++

Immunohistochemical Scoring:
+++ >90 % of positive specimens
++ 51-90 % positive specimens
+ 21-50 % positive specimens
--- < 20 % positive specimens

only 17% (6/36) while none of the DCIS specimens showed expression of IL-8RA on the LVEC. Overall, 14% (6/43) of the malignant samples showed positive staining for IL-8RA. Figure 1J shows the typical negative staining of the LVEC, while the smooth muscle surrounding the arterial vessels consistently expressed IL-8RA.

Malignant LVEC IL-8RB expression. The expression of IL-8RB on the LVEC was distinctly different from that of IL-8RA. 72% (26/36) of the invasive and 57% (4/7) of the DCIS, for a total of 70% (30/43) of the malignant samples showed positive staining for IL-8RB. The smooth muscle surrounding the arterial large vessels stained intensely for IL-8RB in the majority of the malignant specimens studied. From our investigation of the expression of IL-8RA and IL-8RB by the VEC, it is evident that while both IL-8RA and IL-8RB can be expressed, IL-8RB is the prominent receptor present on the SVEC and LVEC. An example of SVEC and LVEC expression of IL-8RA and IL-8RB can be seen in Figure 1 (G,H,I,J,K)

Benign DEC IL-8RA expression. Expression of IL-8RA on the ductal epithelial cells occurred in 50% (4/8) of the specimens. All of these displayed staining in an apical pattern, on the portion of the cell closest to the lumen of the duct. Eighty-eight percent (7/8) showed IL-8RA expression on the myoepithelial cells surrounding the ductal epithelium.

Benign DEC IL-8RB expression. Only 37% (3/8) of the samples tested stained for IL-8RB on the ductal epithelium. Two of the three showed the apical pattern of staining evident with IL-8RA expression. All (8/8) of the specimens showed expression of IL-8RB on the myoepithelial cells. In summary, only about 50% of the benign DEC samples expressed IL-

8RA or IL-8RB, whereas the majority of the myoepithelial cells surrounding the ducts expressed these receptors. Expression of IL-8RA and IL-8RB by the ductal epithelial cells is displayed in Figure 1 (D-E).

Benign breast disease specimens: VEC expression

Benign SVEC IL-8RA and IL-8RB expression. The majority of the benign breast disease samples (88%) showed positive staining for both IL-8RA and IL-8RB. As in the malignant samples, most of the samples showed positive and negative areas) of SVEC IL-8RA expression, while IL-8RB expression by SVEC's was clearly present throughout the specimens.

Benign LVEC IL-8RA and IL-8RB expression. Only 13% (1/8) of the samples tested were positive for IL-8RA on the LVEC in the benign breast samples whereas the majority, 75% (6/8), were positive for IL-8RB. The smooth muscle surrounding the LVEC stained positively in 63% (5/8) of the samples tested for both of the receptors. In summary, the majority of SVEC's expressed both IL-8RA and IL-8RB. As was seen in the malignant samples, IL-8RA was not as prominent as IL-8RB. There was no difference in LVEC expression of IL-8RB when comparing the benign and malignant samples. See Figure 1(G-L) for an example of SVEC and LVEC expression of IL-8RA and IL-8RB. The results cited above are summarized in Table I.

Discussion

Angiogenesis, or the process of formation of new blood vessels, has been shown to be critical for the growth and metastasis of human breast cancer (5). It is believed that angiogenesis is under the control of chemical signals known as angiogenic factors (AF). Additionally, tumor cells also have the ability to stimulate their own growth by producing and secreting their own growth factors and responding to these factors *via* receptor mediated pathways. This autocrine/paracrine pathway promotes uncontrolled tumor proliferation and plays a key role in the metastatic process. Regulating these growth factors and AF is the key to controlling angiogenesis and tumor proliferation. The cytokine IL-8 is both a proven tumor growth factor as well as a potent AF. We feel that this cytokine and its receptors play an important role in breast tumor growth and metastasis.

We recently have demonstrated the presence of IL-8 on tumor cells and in the surrounding VEC's in HBC tissues (manuscript in preparation). Furthermore, results from our analysis of breast tumor homogenates has indicated that there is an inverse relationship between IL-8 levels and estrogen receptor levels (manuscript in preparation). Because higher levels of estrogen receptors are indicative of better outcome, in breast cancer, increased IL-8 levels correlate with poorer prognosis. For IL-8 to elicit these physiological effects, it would be essential that IL-8 receptors be expressed on target

cell, *i.e.* tumor cells and VEC. We set out to verify that the IL-8 receptors do indeed exist on tumor cells and on the VEC's in the tumor microenvironment.

The IL-8 receptors (IL-8RA and IL-8RB) are present on a variety of cell types. Neutrophils, monocytes, keratinocytes, endothelial cells, fibroblasts, macrophages, smooth muscle and T cells have all been shown to express one or both of these receptors. To date, two distinct IL-8 receptors have been isolated, characterized and cloned. These receptors are 77% homologous and are seven transmembrane domain receptors. Both receptors act *via* G proteins through the phospholipase C pathway which induces the release of intracellular calcium and the activation of protein kinase C (6). Both IL-8RA and IL-8RB bind IL-8 with high affinity ($K_d = 0.1 - 4.0$ nM). Several other cytokines also bind to only IL-8RB with high affinity. Neutrophil activating protein (NAP-2) and melanoma growth stimulatory activity (MGSA) also known as Gro bind IL-8RB with affinity similar to IL-8, but show a much lower affinity for IL-8RA ($K_d = 100 - 130$ nM)(7). Hence, while IL-8RA is specific for IL-8 IL-8RB binds a variety of compounds. Chunthoapapai and Kim (7) further investigated the difference in affinities of IL-8RA and IL-8RB for IL-8 on human neutrophils. This group found that the affinity of IL-8RB for IL-8 ($K_d = 0.031 - 0.133$ nM) was two to five times greater than the affinity of IL-8RA for IL-8 ($K_d = 0.096 - 0.168$ nM).

IL-8, IL-8 receptors, and tumor cells. It is clear from our results that both IL-8RA and IL-8RB are expressed on HBC tumor cells. All of the samples studied revealed the expression of both of these receptors. In the tumor cell environment, this data supports our hypothesis that IL-8 may be working as a proliferative agent or growth factor. In view of the fact that other known growth factors (MSG, NAP-2) share an equal affinity and react with the IL-8RB, and that IL-8 definitely causes proliferation in a variety of cell types, IL-8 binding could trigger a pathway of proliferation in the breast cancer tumor environment. The exact role of IL-8RA, which binds only IL-8 with high affinity is not clear. One study discovered that IL-8RA once internalized (after IL-8 binding), is recovered at a much higher rate than IL-8RB (7). This group speculated that in areas of higher IL-8 concentration (*i.e.* site of inflammation, or in this case the tumor site) IL-8RA may play a major active role in transmitting the IL-8 signal due to the receptors rapid recovery rate. Whether IL-8RA is signaling proliferation as we propose IL-8RB is doing is not known at this time, but is clear that IL-8RA and IL-8RB are both expressed by breast cancer tumor cells.

IL-8, IL-8 receptors, and angiogenesis. The presence of IL-8RA and IL-8RB on SVEC and LVEC's is critical for the recognition of IL-8 as an angiogenic factor. In our study, there existed a difference of expression between the two receptors, on the SVEC as well as on the LVEC. While IL-8RB was expressed prominently on both SVEC and LVEC,

IL-8RA was clearly present on only 25 % of the SVEC and 14% of the LVEC's.

Chuntharapai and Kim (7) studied the different function of IL-8RA and IL-8RB. They concluded that IL-8 has a two to five fold higher affinity for IL-8RB than IL-8RA. They postulated that during the inflammatory response, IL-8 secretion at the site of inflammation diffuses through the tissue to reach blood vessels at a distant site. IL-8RB then receives the signal, (because of its higher affinity and the lower concentration of IL-8 at the distant site) and initiates the migration of neutrophils towards the site of inflammation. As the neutrophils approached the site of inflammation (*i.e.* higher concentration of IL-8), IL-8RA would become the dominant receptor in mediating the IL-8 signal. This hypothesis has been supported when looking at IL-8 levels in patients with chronic inflammatory airway disease (8).

A similar scenario can be found in the breast tumor model. In breast cancer, we believe the tumor is producing IL-8 which functions in an autocrine/paracrine manner. This cytokine is diffusing outward, until it reaches a blood vessel at which point it binds to IL-8RB (the prominent receptor on SVEC and LVEC). At that time, the endothelial cells are signaled to start the angiogenesis process. Degradation of the basement membrane of the parent vessel, migration of the endothelial cells towards the angiogenic stimulus (IL-8), proliferation and maturation of the endothelial cells, organization into capillary tubes and finally formation of a new basement membrane occurs as the angiogenic process unfolds (9,10). This process of angiogenesis is essential for tumor growth and metastasis. We propose that IL-8RB is the dominant receptor on the VEC and is responsible for recognizing the angiogenic factor IL-8.

IL-8, IL-8 receptors, malignant vs. benign tissue. One of our main objectives in testing benign breast disease specimens was to discover whether the expression of the IL-8 receptors was different in the benign samples when compared to the malignant ones. A comparison of the distribution of IL-8, IL-8RA and IL-8RB in malignant and benign breast disease is shown in Table II. The ductal epithelial cells in benign breast disease displayed positive expression of IL-8RA in 50% and IL-8RB in 37% of the specimens tested. Considering that all of the tumor specimens expressed both of the IL-8 receptors, it appears that these receptors are upregulated in the malignant disease state.

Furthermore, when we examined the adjacent areas with normal or hyperplastic ductal formation (in the malignant samples), we were excited to find that these ducts showed a still different staining pattern than the ducts in the benign specimens. For example, in the benign disease samples, while 50% of the ductal epithelial cells expressed IL-8RA, 88% of the normal adjacent ducts (in the malignant samples) expressed this receptor. We found this progression in the expression of IL-8RA from benign ductal epithelial (50%) to normal adjacent ductal epithelial (in malignant) (88%), to

malignant tumor cells (100%) to be present. For IL-8RB expression, we found very little difference between the ductal epithelial staining when comparing the benign DEC with the normal adjacent DEC from the malignant specimens.

Another difference was observed when comparing the benign to malignant samples. While the majority of benign ductal myoepithelial cells expressed both IL-8RA and IL-8RB, the expression of IL-8RA on the normal adjacent ductal myoepithelial cells (in malignant samples) was only apparent on 5% of the samples.

The pattern of staining on the VEC in the benign breast samples was comparable to that found in the malignant samples. IL-8RB was expressed on the VEC in the majority of all disease states tested. IL-8RA was expressed in almost all of the SVEC's in the benign samples (88%) while it was less prominent in the malignant samples (65%).

In conclusion, we found that IL-8RA and IL-8RB are expressed by human breast cancer tumors. Furthermore, there is increased expression of these receptors in malignant breast tissue. In addition, we observed IL-8RB to be the dominant receptor expressed by SVEC and LVEC. This data supports our hypothesis that IL-8 plays an important role as a tumor cell activator (proliferation) and a VEC activator (angiogenesis). Future studies targeting the regulation of IL-8 and its receptors, could prove promising in preventing tumor growth and metastasis in human breast cancer.

References

- 1 Strieter RM, Kunkel SL, Elnor VM, Martonyi CL, Koch AE, Poverini PJ, Elnor SG: Interleukin-8: A corneal factor that induces neovascularization. *Am J Pathol* 141: 1279-1284, 1992.
- 2 Singh R, Gutman M, Radinsky R, Bucana C, Fidler I: Expression of Interleukin-8 correlates with the metastatic potential of human melanoma cells in nude mice. *Cancer Res* 54: 3242-3247, 1994.
- 3 Weidner N, Carrol P, Flax J, Blumenfeld W, Folkman J: Tumor angiogenesis correlates with metastasis in invasive prostate carcinoma. *Am J Pathol* 143: 401-409, 1993.
- 4 Cohen RF, Contrino J, Spiro JD, Mann EA, Chen LLL, Kreutzer DL: Interleukin-8 expression by head and neck squamous cell carcinoma. *Arch Otolaryngol Head Neck Surg* 121: 202-209, 1995.
- 5 Gasparini G, Harris AL: Clinical importance of the determination of tumor angiogenesis in breast carcinoma: much more than a new prognostic tool. *J Clin Oncol* 13: 765-782, 1995.
- 6 Thelen M, Peveri P, Kern P, von Tscharnner V, Walz A, Baggiolini M: Mechanism of neutrophil activation by NAF, a novel monocyte-derived peptide agonist. *FASEB J* 2: 2702-2706, 1995.
- 7 Chuntharapai A, Kim K: Regulation of the expression of IL-8 receptor A/B by IL-8: Possible function of each receptor. *J Immunol* 155: 2587-2594, 1995.
- 8 Ricman-Eisenstat J, Jorens P, Herbert C, Ueki I, Nadel J: IL-8 and important chemoattractant in sputum of patients with chronic inflammatory airway diseases. *Am J Physiol* 264: L413, 1993.
- 9 Weinstat-Saslow D, Steep PS: Angiogenesis and colonization in the tumor metastatic process: basic applied advances. *FASEB J* 8: 401-407, 1994.
- 10 Kumar V, Contran R, Robbins S: Basic Pathology. Philadelphia, W.B. Saunders and Co., pp. 47-60, 1992.

Received September 11, 1997

Accepted