

OTS: 60-31,093

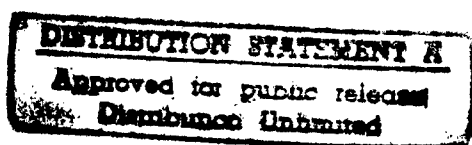
JPRS: 3072

17 March 1960

PROBLEMS CONCERNING TROPHIC CHANGES IN IRRADIATED TISSUE  
(USSR)

[Translation]

MAIN FILE



Distributed by:

OFFICE OF TECHNICAL SERVICES  
U. S. DEPARTMENT OF COMMERCE  
WASHINGTON 25, D. C.  
(Price: \$0.50)

U. S. JOINT PUBLICATIONS RESEARCH SERVICE  
205 EAST 42nd STREET, SUITE 300  
NEW YORK 17, N. Y.

19980109 181

## FOREWORD

This publication was prepared under contract by the UNITED STATES JOINT PUBLICATIONS RESEARCH SERVICE, a federal government organization established to service the translation and research needs of the various government departments.

PROBLEMS CONCERNING TROPHIC CHANGES IN IRRADIATED TISSUE  
(USSR)

[Translation]

Vestnik Rentgenologii i Radiologii  
/Roentgenology and Radiology News/,  
Vol. XXXIV, No. 6, 1959, Moscow  
Pages 58-62  
Russian, per

N. P. Mordinova

From the radiological department (chief - Professor A. V. Kozlova)  
of the State Scientific Research Roentgen-Radiological Institute  
(director - Assistant Professor I. G. Lagunova)

In the radiation therapy of malignant tumors, there are often observed skin injuries and a disturbance of the trophics of the tissues surrounding the tumor. Changes in the skin occur as a consequence of the injury of peripheral nerve ends, which leads to a disturbance of circulation and the development of dystrophic processes in the tissues (A. V. Kozlova, N. N. Garvey).

In the opinion of B. N. Mogil'nitskiy, V. P. Shekhonin, I. M. Zhdanov, P. N. Kiselev and others, a special role in trophic processes is played by the degree of permeability of the blood capillaries, which are under the regulating effect of the central nervous system.

B. N. Mogil'nitskiy thought, that the disturbance of vascular permeability upon irradiation is connected with functional and morphological changes in the main substance of connective tissue.

Studying the effect of roentgen rays on permeability of the skin of animals, P. N. Kiselev established, that with the appearance of erythema, the permeability of skin capillaries increases, and in the stage of pigmentation decreases, and 4 weeks after irradiation returns to the original state.

For the purpose of studying trophic changes in irradiated skin we conducted a series of clinical tests on two groups of patients: in the first group we included patients with malignant neoplasms, which had been subjected to telegammatherapy; in the second group were included patients with radiation injuries of the skin, which were formed as a result of previous radiation therapy.

For the study of the condition of the skin after its irradiation we used the cup test of V. A. Waldman, the test of A. Hecht and A. I. Nesterov, the test of MacClure and Oldridge as methods, which are most characteristic and at the same time practicable under any conditions.

The cup test of V. A. Waldman permits the determination of the percent of monocytic elements in the blood smears before and after the placing of the cup, and the explanation of their phagocytic function. With a positive cup test, the percent of monocytic cells in the smear increases by 2-4 times and more than 2-4 times.

A. P. Yegorov, M. S. Lapteva-Popova, Ye. A. Kolyaditskaya and O. A. Yuchenkova established, that this test characterizes the reaction condition of active connective tissue as a whole and should be positive in all cases, when any irritant effects it.

According to their data after irradiation of patients with roentgen and radium rays, there is observed an increase of the number of monocytes, more pronounced with small doses (20 r.) and less pronounced with irradiation with large doses.

We conducted this test on both groups of patients, which we were examining. In the first group the percent of monocytes in the blood was determined before treatment of the patients, during their treatment process on telegamma equipment (with a dose of from 2,000 to 2,500 r. to the skin) and after the completion of the course of radiation therapy. In the second group of patients with chronic radiation skin injuries, we carried out the V. A. Waldman test on all the patients before and after treatment of the radiation skin irritations.

For investigation of the stability of the skin capillaries A. Hecht suggested the method with a suction cup. A. I. Nesterov modified this test, and in addition established, that in the standard, this test coincides symmetrically on both hands with a degree 0-1, forming a pale background, on which appear 10-20 small superficial punctate hemorrhages, which completely disappear after 72 hours.

The test under consideration was used by N. V. Balanina and V. P. Shekhonin and is considered by them and by A. I. Nesterov as a test, connected with the change of permeability of blood capillaries. This test was conducted in both groups of patients during the periods as the V. A. Waldman test.

The MacClure and Oldridge test as an indicator of the tissue hydrophilic nature is based on the determination of the period of resorption of the pulp after the intracutaneous administration of 0.2 milliliters of a sterile physiological solution. For a healthy adult according to the authors, the resorption time of the papule is equal to 55 minutes. The physiologic fluctuations may be assumed within the limits of 10 minutes in either direction (V. P. Shekhonin). It is necessary to consider a more prolonged resorption of the papule as a deviation from the standard.

In the opinion of I. A. Oyvin it is possible to judge the functional condition of the skin capillaries according to the results of the test under discussion.

We conducted the test for the tissue hydrophilic nature simultaneously with the test of A. I. Nesterov and V. A. Waldman.

In the first group there were 20 persons, including 9 women and 11 men. The patients were from 18 to 70 years of age. Telegamma-therapy was given to patients with malignant neoplasms of the urinary bladder, lungs, esophagus and with melanomas of the skin.

On the patients of this group, treatment was carried out for the first time, and the integuments in the irradiation sites were not changed.

The indices of the cup test of V. A. Waldman, carried out several days before the beginning of treatment, among the majority of patients did not deviate from the norm.

The A. I. Nesterov tests under consideration corresponded to 1 degree among 17 patients, i.e. also did not indicate a disturbance of permeability and an increased vascular fragility.

The indices of the Oldridge test among all the patients fluctuated within the limits of 40-60 minutes, i.e. corresponded to the physiologic changes in one direction or the other.

In 10-12 days after irradiation with a dose in the skin area from 2500 to 3000 r. in 15 patients of this group, the data of the clinical tests indicated disturbances of vascular permeability and an increase of vascular fragility. The reaction of the reticuloendothelium became positive during the conducting of the V. A. Waldman test.

During the conducting of the A. I. Nesterov test on the site, where the cup had been applied, there appeared 30-40 punctate hemorrhages which corresponds to the II stage of the reaction.

The intracutaneous papule according to the Oldridge method was resolved during 40-45 minutes.

During these periods no changes on the irradiated skin appeared. The skin remained a normal color, elastic, its temperature did not rise. Only after 2 days among five patients, and after 3 days in 6 patients on the irradiated skin there appeared a bright erythema, which was accompanied by edema of the tissues. Irradiation of the patients was stopped.

During the following days the indices of functional tests among 15 patients indicated the ever increasing disturbance of vascular permeability. The number of hemorrhages during the A. I. Nesterov test on the 15 patients increased to 50-60, and in some of the patients there arose continuous ecchymoses, which did not disappear for 7-8 days.

The resorption time of the intracutaneous papule during the period of maximum manifestation of the skin reaction decreased to 30-25 minutes, which also indicated the further increase of the vascular permeability of the skin in irradiation sites.

In 10-12 days after the completion of the treatment, in 7 patients the reaction on the skin in irradiation sites ended; there remained only a slight pigmentation of the skin. The results of the V. A. Waldman, A. I. Nesterov and Oldridge tests during these periods did not indicate a disturbance of vascular permeability.

In 5 patients after the completion of the treatment there developed on the skin in the irradiation sites, a reaction in the form of moist epidermitis. In these cases the number of hemorrhages on the site, where the cup had been applied was increased and corresponded to the II and III stage according to A. I. Nesterov. The resorption of the hemorrhages was delayed up to 8-9 days. The V. A. Waldman reaction in these patients was also positive and the tissue hydrophilic nature was sharply disturbed. The intracutaneous papule was resolved in 25-18 minutes.

Conducting further observations, we noted, that in 3 weeks after the completion of treatment the indices of the V. A. Waldman, A. I. Nesterov and Oldridge tests in these patients had still not returned to the original magnitudes.

On subsequent observation, there appeared irreversible changes of the skin in these patients: the skin remained dry, became emaciated, pigmented; there appeared telangiectasia.

In the remaining 5 patients of this group the indices of the functional tests after treatment slightly deviated from the average figures. This indicates that changes of the vascular permeability in these cases were much less pronounced.

In the second group were included 20 women and 10 men from 22 to 67 6 years of age.

In these patients there were radiation injuries of the skin, which had occurred in the majority of cases after repeated courses of radiation therapy, which was used for the treatment of recurrences of malignant neoplasms. Repeated courses of radiation therapy significantly disturbed

the trophics of the tissues. In 5 patients the treatment was carried out in connection with melan with a total dose from 11,000 to 15,000 r..

In 3 patients changes in the skin were manifested in skin emaciation, the presence of telangiectasia, sections of depigmentation and moderately pronounced sclerosis of the tissues, which were involved.

In 2 patients on the emaciated, dry and atrophied skin there were ulcerations, which periodically became overcrusted with dry purulent crusts. In the overwhelming number of patients of this group radiation injuries of the skin covered an area with a diameter of from 5 to 12 centimeters, penetrated all the layers of the skin, had a rough bottom, covered with a considerable layer of necrotic masses and pus. The subcutaneous tissue in the surrounding tissues was sclerosed.

In 5 patients of this group the treatment, without result, of the radiation injuries of the skin continued for several months. The ulcerations remained on the skin in 5 patients from one to 2 years, and in 10 patients for more than 2 years.

In 9 patients of this same group during the conducting of the A. I. Nesterov test there did not occur any skin capillary reaction on the site, where the cup had been applied, which, in the opinion of V. P. Shekhonin, B. N. Mogil'nitskiy and M. S. Brumshteyn, is explained by changes in the basic intermediate substance, and namely by its concentration and transition from a gel state to a sol state.

In one patient the A. I. Nesterov reaction corresponded to the II stage. In the remaining patients the number of punctate hemorrhages on the site where the cup had been applied indicated the III stage of disturbance of the capillary permeability and fragility, whereas on the symmetrically located sections of the skin on the healthy part in the majority of the patients we obtained the I stage of the reaction and only in 5 patients -- the II stage. The hemorrhages in the skin on the site, where the cup had been applied, in the section of the skin injury, disappeared only on the 9-10th day after the conducting of the test.

The indices of the V. A. Waldman test in 20 patients were negative, which, in our opinion, is explained by the absence of reactivity of the irradiated tissues, and indicates the deep disturbance of the vascular wall permeability in these sections of the skin.

According to clinical data, in these patients were most strongly pronounced radiation changes of the tissues: the skin was atrophied, emaciated, dry, depigmented, scaled, and the involved tissues were sclerosed. The radiation ulcers penetrated deeply and involved the entire thickness of the skin; their bottom was covered with a layer of necrotic masses and pus. The ulcer areas were changed by scars.

The data of the Oldridge test also indicates the sharp disturbance of the vascular permeability with radiation injuries of the skin. On the borderline between normal and injured skin in 12 patients there was noted a sharp retardation of resorption of the intracutaneous papule. In the remaining patients resorption of the papule was significantly accelerated and was completed in 20-25 minutes.

Our observations indicated that the most sharply pronounced disturbances of vascular permeability occur in immediate proximity to the radiation injury of the skin; the degree of disturbance decreases when there is an increase of the distance from the site of radiation injury of the skin and at a distance of 20 centimeters the indices of functional tests in a number of patients almost do not deviate from the norm.

We obtained interesting data in 10 patients, in whom there was carried out treatment of radiation injuries of the skin for which there were applied various methods, which effected both the entire organism of the patient, as well as, locally, the injured skin. The patients were given weekly blood transfusions (100 milliliters), vitamins; and the weakened patients were given high-caloric diets and were given glucose intravenously. All the patients had a careful dressing of the ulcer every day bandage with anesthetic ointment, an emulsion of the same or aloe. To the bottom of the ulcer were applied fibrinous films.

For improvement of the trophics of the tissues, surrounding the ulcer, once during 5-6 days novocaine blocks according to the A. V. Vishnevskiy method were used.

On these patients the V. A. Waldman, A. I. Nesterov and Oldridge clinical tests were carried out periodically.

We were able to note that in 6 persons the indices of the tests indicated an improvement of vascular permeability, which had occurred several days before the clinical improvement of the course of radiation injuries of the skin.

In 4 patients the results of the clinical tests before and after treatment were not essentially different. We also did not observe clinical signs of improvement in them.

#### Conclusions

During radiation therapy in the skin, subjected to the effect of radiation energy, there occurs a disturbance of vascular permeability, which precedes the appearance of a visible reaction on the skin.



2. In the sites of radiation injury of the tissues there occur significant and stable disturbances of vascular permeability and depression of the function of the active connective tissue.

3. The results of the V. A. Waldman, A. I. Nesterov and Oldridge clinical tests make it possible to judge the stage of disturbance of the trophics of irradiated tissues, and also of the skin with radiation injuries, and may serve as indices of the effectiveness of their treatment.

#### Bibliography

1. Balanina, N. V., Shekhonin, V. P., "Questions of Permeability of Blood Capillaries in Pathology," Vol. 1, 1949, Moscow, Pages 102-107.
2. Waldman, V. A., Klinicheskaya Meditsina, (Clinical Medicine), No. 2, 1948, Pages 32-36.
3. Vishnevskiy, A. V., "Nerve Trophics in the Theory and Practice of Medicine," 1936, Moscow, Pages 15-22.
4. Garvey, N. N., "Theses of the Paper Presented at the Scientific Conference of Young Scientists of the Roetgen-Radiological Institute," 1958, Moscow, Page 1.
5. Yegorov, A. P., Lapteva-Popova, M. S., Kolyaditskaya, Ye. A. and others, "Roentgen Therapy for Gunshot Wounds," 1945, Moscow, Pages 18-24.
6. Zhadanov, I. M., "Questions of Permeability of Blood Capillaries in Pathology," Vol. 1, 1949, Moscow, Page 58.
7. Kiselev, P. N., Vestnik Rentgenologii i Radiologii, (Roentgenology and Radiology News), No. 5, 1953, Pages 3-8.
8. Kozlova, A. V., "Basés of Radiation Therapy," 1956, Moscow.
9. Mogil'nitskiy, B. N., Brumshteyn, M. S., "Questions of Permeability of Blood Capillaries in Pathology," Vol 1, 1949, Moscow, Pages 61-71.
10. Mogil'nitskiy, B. N., "Questions of Permeability of Blood Capillaries in Pathology," Vol. 1, 1949, Moscow, Pages 9-17.
11. Oyvin, I. A., "Works of the Stalinabad Medical Institute," Vol. 11, 1954, Pages 165-169.