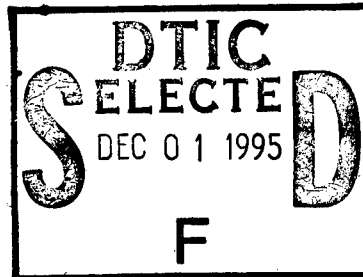


DEPARTMENT OF JUSTICE
Approved for public release
Distribution Unlimited

19951128 056

SGRD-RMS

Mrs. Patricia A. Madigan
SGRD-RMS/USAMRDC
Fort Detrick, Frederick, MD 21701



MEDICAL DEPARTMENT
UNITED STATES ARMY
IN WORLD WAR II

Accession For	
NTIS CRA&I	<input checked="" type="checkbox"/>
DTIC TAB	<input type="checkbox"/>
Unannounced	<input type="checkbox"/>
Justification	
By	
Distribution /	
Availability Codes	
Dist	Avail and/or Special
A-7	

DISTRIBUTION STATEMENT A
Approved for public release
Distribution Unlimited

DTIC QUALITY INSPECTED 8

MEDICAL DEPARTMENT, UNITED STATES ARMY

Surgery in World War II

ORTHOPEDIC SURGERY
in the
EUROPEAN THEATER OF
OPERATIONS

Editor in Chief

Colonel JOHN BOYD COATES, Jr., MC

Editor for Orthopedic Surgery

MATHER CLEVELAND, M. D.

Associate Editor

ELIZABETH M. McFETRIDGE, M. A.

OFFICE OF THE SURGEON GENERAL

DEPARTMENT OF THE ARMY

WASHINGTON, D. C., 1956

SURGERY IN WORLD WAR II

Prepared under the direction of
Major General S. B. HAYS
The Surgeon General, United States Army

Historical Unit, Army Medical Service

Colonel JOHN BOYD COATES, Jr., MC, *Director*
Major I. H. AHLFELD, MSC, *Executive Officer*
Captain J. K. ARIMA, MSC, *Special Projects Officer*
DONALD O. WAGNER, Ph. D., *Chief, Historians Branch*
WILLA B. DIAL, *Chief, Editorial Branch*
JOSEPHINE P. KYLE, *Chief, Archives and Research Branch*
HAZEL G. HINE, *Chief, Administrative Branch*

Advisory Editorial Board

MICHAEL E. DEBAKEY, M. D., *Chairman*
FRANK B. BERRY, M. D. JOHN B. FLICK, M. D.
BRIAN BLADES, M. D. FRANK GLENN, M. D.
J. BARRETT BROWN, M. D. M. ELLIOTT RANDOLPH, M. D.
STERLING BUNNELL, M. D. ISIDOR S. RAVDIN, M. D.
NORTON CANFIELD, M. D. ALFRED R. SHANDS, Jr., M. D.
B. NOLAND CARTER, M. D. HOWARD E. SNYDER, M. D.
EDWARD D. CHURCHILL, M. D. R. GLEN SPURLING, M. D.
MATHER CLEVELAND, M. D. BARNES WOODHALL, M. D.
DANIEL C. ELKIN, M. D. ROBERT M. ZOLLINGER, M. D.
Colonel JOSEPH R. SHAEFFER, MC (ex officio)
Colonel JOHN BOYD COATES, Jr., MC (ex officio)

ORTHOPEDIC SURGERY
in the
EUROPEAN THEATER OF OPERATIONS

Foreword

As a medical officer who served in Europe during World War II, I can speak with first-hand knowledge of the role of orthopedic surgery in a large and continuously active theater of operations. In terms of combat personnel and medical facilities, the European theater was the largest single theater of World War II. It was the scene of continuous and intensive combat; the fighting might vary in intensity from area to area, but there was never a general period of inactivity.

Casualties were very heavy, and, as in all theaters, battle injuries of the extremities, including bones and joints, comprised the largest single group, approximately two-thirds of the 381,350 wounded and injured in action in Europe.

The orthopedic care of this enormous number of wounded was a task of the first magnitude. It was accomplished brilliantly. It could not have been accomplished at all without thoughtful and detailed planning, which included:

1. The careful assignment of the relatively small number of qualified orthopedic surgeons in the theater to positions in which their professional qualifications could be employed with maximum benefit.

2. The training, overseas, in the fundamentals of military orthopedic surgery, of a large number of medical officers and enlisted technicians who were without previous training in this field.

3. The prompt publication and distribution of uniform combat-tested principles and practices of military orthopedic surgery, which in many respects were dissimilar to the principles and practices then current in civilian orthopedic surgery.

4. The continuous supervision of personnel caring for orthopedic casualties, and the consistent execution of the principles and practices mentioned above.

The result of this carefully planned program was a superior performance, from care rendered by medical aid men in the frontlines of the army area to definitive surgery in fixed hospitals far to the rear in the communications zone.

A large part of the credit for this accomplishment must be attributed to the tireless efforts of the senior consultants in orthopedic surgery, Col. Mather Cleveland, Medical Corps, and Col. Rex L. Diveley, Medical Corps, who preceded him in that assignment. There are few phases of the care of bone and joint casualties in the European Theater of Operations which do not reflect their administrative ability and clinical competence.

Colonel Cleveland has added to his wartime service by his continued interest in the recording of the orthopedic experience in this theater in World War II. This volume is the result of those endeavors.

It is essential that this experience be recorded. This volume is a record of errors as well as of successes. Both have been related with equal frankness and without reservation.

The lesson of history, as the saying goes, is that the lesson of history is never learned. If this volume is used as it should be, there is hope, in the unhappy event of another war, that these particular lessons will not have to be relearned, as they have had to be in previous wars, at a great price. They are plainly set forth, and, if they are properly applied, they should save both life and limb in any future war.

S. B. HAYS,
Major General, United States Army,
The Surgeon General.

Preface

In the spring of 1945, while serving as senior consultant in orthopedic surgery in the European Theater of Operations, I received a letter from Brig. Gen. Fred W. Rankin, chief consultant in surgery, Office of The Surgeon General, asking me to serve as editor of the volumes on orthopedic surgery in the history of the United States Army Medical Department in World War II. To carry out that objective, all junior consultants in orthopedic surgery in the European theater, as well as many chiefs of section, were requested to supply information concerning their experiences in the care of wounds and injuries involving the bones and joints. Some 25 of these officers furnished reports and clinical studies, and these data, together with my own observations and comments as senior consultant in orthopedic surgery, made up the report from which the story of orthopedic surgery in the European Theater of Operations has been written. This theater had the largest number of troops deployed of any of the theaters of operations and also had the largest number of hospitals and the greatest number of medical personnel.

Although these reports were written early in 1946, various delays in publication occurred. In November 1953, an advisory editorial board for the history of surgery, World War II, Medical Department, United States Army, was constituted. Dr. Alfred Shands (formerly colonel, MC, assigned to the Army Air Force) and I were asked to survey the orthopedic material available. We read, and wrote critiques upon, more than a hundred manuscripts, chiefly from the Zone of Interior. These manuscripts have been utilized to prepare the story of orthopedic surgery in the Zone of Interior and to supplement the history of this specialty in the European theater and the Pacific theaters.

Perhaps we should not be unduly discouraged by the length of time it has taken to prepare this history. The last of the 6 volumes which make up the Medical and Surgical History of the War of the Rebellion did not appear until 1888, 23 years after General Lee's surrender at Appomattox Courthouse. Similarly, some of the volumes of the Medical Department of the United States Army in the World War did not appear until 1928, 10 years after the so-called armistice of 1918.

A special debt of gratitude is owed to Miss Elizabeth M. McFetridge for her patient and untiring efforts throughout these years in correlating the material and providing the authors with invaluable assistance and encouragement. I would also like to express appreciation to Mr. Herman Van Cott, chief, Medical Illustration Service, Armed Forces Institute of Pathology, and to his staff for their valuable contribution in preparing for publication all illustrations in this volume.

We who were privileged to serve as medical and surgical consultants in the European theater owe a great deal to our Chief Surgeon, Maj. Gen. Paul R. Hawley, MC, United States Army.

We also owe a great deal to the late Dr. Elliott C. Cutler, onetime colonel, then brigadier general, Medical Corps, Army of the United States, chief surgical consultant in the European theater. In 1946, Dr. Cutler read the report from the European theater from which this history of orthopedic surgery in the theater has been prepared and wrote a foreword for it, as follows:

This volume contains material which will be of value and interest not only to the military surgeon but to those interested in bone and joint surgery in civil life. All surgeons know that wars have given great impetus to their art, and that many of the forward steps in our work have been the result of battlefield experiences. The recent war is no exception to preceding history. The matter of the proper handling of the combined major nerve injury and the compound fracture was varied and unsatisfactory until the experience of the recent war. Now, as can be learned by those who turn the pages of this volume, this difficult problem is settled and can be taught to the growing generation of doctors as a final, useful part of their education. Similarly, there are many other problems of equal importance which this war, with the benefits permitted by modern antibiotics, has given to our profession. That the orthopedic surgeon was sufficiently wide awake, well educated and alert to utilize all of the data available to him, and make such great strides forward, is a tribute to his education and the great experience afforded him by the war.

Having seen at first hand much that is written of in this volume, I can recommend it to all surgeons as a compendium of military experience now ready for use in the broad field of surgery and particularly in the surgery of bones and joints, as an excellent summary of where we stand today in this important field. The former senior consultant in orthopedic surgery for the European Theater of Operations writes with the voice of authority. Of the 16,000 civilian doctors serving as medical officers in the Army of the United States in the European Theater of War, those working in the field of orthopedic surgery shared mightily in the occasion, for injury to bone was a most frequent happening and the direct responsibility for the guiding of these orthopedic surgeons was that of the senior consultant. His directives, when sent out after careful evaluation, brought a standard form of surgery to those in his special field. This experience is now available to all.

These remarks, prepared by Dr. Cutler in 1946, are still valid almost 10 years later. They summarize excellently the orthopedic experience in World War II and the lessons to be learned from that experience, not only for a future war but for orthopedic surgery in a world at peace.

MATHER CLEVELAND, M. D.,
Colonel, MC, AUS,
Formerly Senior Consultant in Orthopedic Surgery,
European Theater of Operations.

Acknowledgments

Grateful acknowledgment is hereby made to the following medical officers and enlisted men who served in the European Theater of Operations in World War II and whose reports, data, and clinical observations have made this volume possible:

Col. Charles B. Odom, MC, Headquarters, Third United States Army
Lt. Col. George T. Aitken, MC, Headquarters, Fifteenth United States Army
Lt. Col. Roderick E. Begg, MC, 46th General Hospital
Lt. Col. Sante D. Caniparoli, MC, 46th General Hospital
Lt. Col. William H. Cassebaum, MC, 9th Evacuation Hospital
Lt. Col. Philip S. Foisie, MC, 129th General Hospital
Lt. Col. Louis A. Goldstein, MC, 19th General Hospital
Lt. Col. Nathaniel Gould, MC, 168th Station Hospital
Lt. Col. John A. Grove, MC, 15th Hospital Center
Lt. Col. George Hammond, MC, 298th General Hospital; 818th Hospital Center
Lt. Col. G. Baker Hubbard, MC, 216th General Hospital; 803d Hospital Center
Lt. Col. Julian E. Jacobs, MC, 65th General Hospital; 805th Hospital Center
Lt. Col. Darrell G. Leavitt, MC, 50th General Hospital; 819th Hospital Center
Lt. Col. John G. Manning, MC, Headquarters, Ninth United States Army
Lt. Col. Thomas B. Quigley, MC, 22d General Hospital
Lt. Col. Dudley W. Smith, MC, 4th Auxiliary Surgical Group
Lt. Col. Marcus J. Stewart, MC, 2d General Hospital; 307th Station Hospital; and
827th Convalescent Center
Lt. Col. William J. Stewart, MC, 102d Evacuation Hospital
Lt. Col. James E. Thompson, MC, 9th Evacuation Hospital
Lt. Col. John Pettit West, Jr., MC, 2d Evacuation Hospital
Lt. Col. Malvin White, MC, 129th General Hospital
Maj. William H. Blodgett, MC, 217th General Hospital; 815th Hospital Center
Maj. Arthur D. Ecker, MC, 117th General Hospital
Maj. Irvine M. Fliinn, Jr., MC, 67th General Hospital; 801st Hospital Center
Maj. Floyd H. Jergesen, MC, 2d Auxiliary Surgical Group
Maj. Harold B. Kernodle, MC, 65th General Hospital
Maj. Charles F. Kincheloe, MC, 68th General Hospital; 804th Hospital Center
Maj. William K. Massie, Jr., MC, 117th General Hospital
Maj. Marshall R. Urist, MC, 22d General Hospital; 802d Hospital Center
Capt. Edmund A. Maxwell, MC, 22d General Hospital
Capt. Lincoln Ries, MC, 22d General Hospital
Capt. Charles F. Stewart, MC, 9th Evacuation Hospital
M. Sgt. Robert Ferguson, Ordnance
Sgt. William Pitney, 129th General Hospital

Contents

Page

FOREWORD.....		VII
	<i>By Maj. Gen. S. B. Hays</i>	
PREFACE.....		IX
	<i>By Mather Cleveland, M. D.</i>	
ACKNOWLEDGMENTS.....		XI
INTRODUCTION.....		1
	<i>By Mather Cleveland, M. D.</i>	

Part I

ADMINISTRATIVE AND RELATED CONSIDERATIONS

By Mather Cleveland, M. D.

Chapter

I	THE CONSULTANT SYSTEM.....	7
	Functions of the Senior Consultant.....	7
	Junior-Consultant System.....	8
	Consultants in Army Areas.....	10
	Evaluation and Assignment of Personnel.....	11
II	TOURS OF HOSPITALS.....	19
	Tour of Hospitals in the United Kingdom Base, November 1944.....	20
	Tour of Hospitals on the Continent, 23 November-3 December 1944.....	29
III	TRAINING OF PERSONNEL.....	35
	General Considerations.....	35
	Methods of Training.....	36
	Professional Conferences.....	39
IV	HOSPITAL FACILITIES AND ORTHOPEDIC EQUIPMENT.....	41
	Hospital Facilities.....	41
	Equipment and Supplies.....	42
V	MASS MANAGEMENT OF CASUALTIES WITH BONE AND JOINT IN- JURIES.....	55
	Transit Hospitals.....	55
	General Hospitals.....	58
VI	MANAGEMENT OF BONE AND JOINT INJURIES IN PRISONERS OF WAR.....	63
VII	REPRESENTATIVE HOSPITAL EXPERIENCES.....	67
	298th General Hospital.....	67
	50th General Hospital.....	69
	217th General Hospital.....	69
	Fifteenth United States Army Hospitals.....	70

Part II

CLINICAL POLICIES AND PRACTICES

By Mather Cleveland, M. D.

<i>Chapter</i>		<i>Page</i>
VIII	GENERAL CLINICAL POLICIES.....	73
	Evolution of Clinical Policies.....	73
	Establishment and Dissemination of Policies.....	74
	General Medical Policies.....	77
	Evacuation Policies.....	78
IX	THE MANAGEMENT OF COMPOUND FRACTURES—INITIAL AND RE- PARATIVE WOUND SURGERY.....	81
	Development of Policies.....	81
	Debridement.....	83
	Delayed Wound Closure.....	87
	Management of Fractures.....	89
	Results of Delayed Primary Wound Closure in Compound Fractures.....	91
	Combined Nerve-Bone Injuries.....	104
	Combined Vascular-Bone Injuries.....	106
X	THE MANAGEMENT OF COMPOUND FRACTURES—TECHNIQUES OF FRACTURE MANAGEMENT.....	109
	Plaster of Paris.....	109
	Tobruk Splint.....	110
	Skeletal Traction.....	113
	External Fixation.....	116
	Internal Fixation.....	116
XI	REGIONAL INJURIES.....	119
	Forearm.....	119
	Clavicle.....	143
	Humerus.....	144
	Pelvis.....	146
	Spine.....	147
	Femur.....	147
	Tibia and Fibula.....	151
	Ankle.....	151
	Foot.....	153
XII	AMPUTATIONS.....	155
	Incidence and Case Fatality Rates.....	157
	Evolution of Techniques.....	158
	Special Considerations of Traction.....	165
	Amputations Caused by Special Types of Missiles.....	166
XIII	ADJUNCT THERAPY.....	167
	Resuscitative Measures.....	167
	Supplemental Therapy.....	167
	Chemotherapy and Antibiotic Therapy.....	168
	Psychotherapy.....	170
XIV	POSTOPERATIVE COMPLICATIONS.....	173
	Wound Infections.....	173
	Osteomyelitis.....	174
	Secondary Hemorrhage.....	174
	Decubitus Ulcers.....	175

<i>Chapter</i>	<i>Page</i>
XV REHABILITATION.....	177
Rehabilitation Hospitals.....	177
Physical Therapy Programs.....	178
Replacement Centers.....	179
XVI NONCOMBAT LESIONS.....	185
General Considerations.....	185
Elective Surgery.....	185
Disabilities of the Feet.....	186

Part III

SPECIAL TYPES OF BONE AND JOINT INJURIES

By Marshall R. Urist, M. D. and Mather Cleveland, M. D.

XVII COMPLETE DISLOCATIONS OF THE ACROMIOCLAVICULAR JOINT....	191
Anatomic Considerations.....	195
Mechanism of Injury and Nature of Lesion.....	197
Pathologic Process.....	199
Diagnosis.....	202
Management.....	202
Associated Fractures.....	215
Complications and Sequelae.....	216
XVIII BATTLE-INCURRED COMPOUND FRACTURES ABOUT THE HIP JOINT..	221
Emergency Measures.....	223
Initial Wound Surgery.....	224
Surgical Approach to the Hip Joint.....	232
Management of Retained Foreign Bodies.....	233
Wound Closure.....	234
Adjunct Fracture Management.....	234
Adjunct Therapy.....	237
Complications of Hip Injuries.....	238
Early Reconstructive Surgery.....	247
An Ideal Plan of Management.....	249
XIX JEEP INJURIES OF THE HIP JOINT.....	251
Basic Information.....	251
Anatomic Considerations.....	254
Dislocations.....	254
Fractures of the Acetabulum Without Dislocation.....	262
Fracture-Dislocations.....	269
Followup Studies.....	296
.....	305
XX INJURIES OF THE KNEE JOINT.....	305
Nature of the Injury.....	305
Diagnosis.....	306
Initial Wound Surgery.....	307
Treatment in the General Hospital.....	310
Suppurative Arthritis.....	310
Analysis of Cases.....	312
APPENDIXES.....	319
A Pertinent Directives.....	319
B Proposed Revision of Manual of Therapy (Orthopedic Section).....	335
INDEX.....	357

Introduction

*Mather Cleveland, M. D.**

In all of the major wars in which the United States has been engaged, battle casualties caused by injuries involving the bones and joints have presented a formidable problem to the Army Medical Department. This has been true from the standpoint of their frequency as well as their incapacitating effects. In the Civil War, in World War I, and in World War II, more than 70 percent of the wounded who survived to reach hospitals have had wounds or injuries involving the upper or lower extremities. In the Korean conflict, about two-thirds of the wounded or injured in action had injuries of these sites. Compound (or open) fractures make up an appreciable part of these wounds or injuries of the extremities; for the period of the Korean conflict, about one-fourth. The mere citation of these figures indicates the magnitude of the task which confronts the military orthopedic surgeon.

The full significance of the proportions just mentioned cannot be appreciated without knowledge of the numbers of troops under arms in the various theaters of operations. In May 1945, at the close of hostilities in the European and Mediterranean theaters, United States Army troops (including the United States Army Air Force) were deployed as follows:

1. In the European theater, the total strength was 3,065,505 men. These troops were served by a total of 290 hospitals, including 63 evacuation hospitals, 34 field hospitals, 146 general hospitals, and 47 station hospitals.

2. In the Mediterranean theater the total strength was 493,876 men. These troops were served by a total of 47 hospitals, including 8 evacuation hospitals, 7 field hospitals, 11 general hospitals, and 21 station hospitals. It should be remembered that the troop strength in the Mediterranean theater was correspondingly diminished when the United States Seventh Army invaded southern France, taking with it troops and hospitals from Italy to augment the strength of the European theater.

At the close of hostilities in the Pacific theaters, in August 1945, a total strength of 1,389,010 United States Army troops were deployed. This number was somewhat larger than the troop strength of 1,257,098 deployed in May 1945, when hostilities ceased in the European and Mediterranean theaters. These troops were served by a total of 146 hospitals, including 15 evacuation hospitals, 24 field hospitals, 46 general hospitals, and 61 station hospitals.

The enormous number of men under arms in the various theaters and the frequency of bone and joint injuries indicate the actual and potential responsi-

*Consulting orthopedic surgeon, St. Luke's Hospital, New York, N. Y.; member, special medical advisory group, Veterans' Administration; consultant in orthopedic surgery for The Surgeon General. Formerly colonel, MC, AUS.

bilities carried by orthopedic surgeons in theaters of operations in World War II.

In spite of the brief duration of the independent participation of United States Army Medical Department personnel in World War I, the total orthopedic experience, combined with the far longer British experience, resulted in the evolution of a method of management of injuries of the bones and joints. In summary, this experience was as follows:

1. In the British Army, the treatment of wounds by free excision (debridement) was generally adopted after 1918. The earlier the treatment was carried out and the more thorough was the removal of all damaged muscle and foreign bodies, the better were the results. Free incisions were necessary to provide access to the deeper parts, but unnecessary excision of the skin militated against satisfactory wound closure.

2. In the early days of the war, wounds were treated by suture, but healing was generally unsatisfactory and the practice was completely abandoned. In 1917, when wound closure was revived, it was found that if aseptic conditions could be obtained and if damaged tissues were thoroughly excised and all foreign bodies were removed, healing was generally satisfactory.

3. In 1918, Col. Joseph A. Blake, MC, United States Army, described the management of gunshot fractures of the extremities by wide incision of the overlying wounds; adequate debridement of all devitalized tissue; and closure by primary, delayed primary, or secondary suture. Bone fragments were left in situ in the absence of contraindications, the objective being to preserve the continuity of the shaft of long bones as far as this was possible.

4. The following year, Col. Eugene H. Pool, MC, United States Army, also stated that delayed primary suture could be carried out in most compound fractures of the long bones, with little risk and few failures. Like Blake, he emphasized that the temptation toward free removal of bony fragments should be resisted.

5. In this same publication, Pool advocated the management of wounds of the knee joint by ample debridement, immediate closure of the joint capsule, and delayed primary closure of the overlying tissues.

Blake's and Pool's observations were based on sizable series of casualties treated by adequate debridement of devitalized muscle and other damaged soft tissue, removal of foreign bodies, and competent management of compound fractures. Without the benefit of either chemotherapeutic or antibiotic agents, which did not then exist, satisfactory results were achieved by these techniques in more than 80 percent of the wounds in which they were employed.

These methods, however, were never in general use in the First World War. For one thing, as already noted, the independent American orthopedic experience was relatively brief. For another, the use of these methods was limited to a relatively small number of highly competent, top-ranking American officers. The information was not relayed to the outlying and forward hospitals in which the majority of orthopedic casualties were treated. The war was over, in fact, before the information appeared in the medical literature.

This priceless information was incorporated in both the British and American official histories of the medical experience in World War I. It would have proved extremely valuable had it been put to immediate use in World War II. It was not. Almost no use was made of these techniques in the interim between the wars. They were not utilized when World War II broke out, either in the training of medical officers after it had become evident that United States participation in the war was inevitable, or later, when this country entered the war.

Practically none of the experience of World War I was incorporated in the military manual entitled "Orthopedic Subjects," which was published in 1942 under the auspices of the Committee on Surgery of the Division of Medical Sciences of the National Research Council. The book was prepared and edited by the subcommittee on orthopedic surgery and contained forewords by the Surgeons General of the Army and the Navy.

This well-written text, designed to furnish "essential up-to-date and reliable information regarding military surgery," was prepared, for the most part, by medical officers who had served in World War I and who were outstanding orthopedic surgeons. It did not, however, meet the needs of the military situation. With few exceptions, the book is simply a compendium of reconstructive procedures on the bones and joints, all of them suitable for performance only in fixed hospitals in the Zone of Interior. The text is almost devoid of specific directions for the care of these injuries in active theaters of operations. Debridement is excellently described, and the importance of splinting compound fractures is emphasized. On the other hand, the observation, "Splints can be improvised at the scene of the accident if they are needed," is completely unrealistic. It fails to take cognizance of the fact that in military surgery there may be need, at any given point, for the simultaneous treatment of hundreds, and sometimes of thousands, of severely injured men. Wounds of the joints, which are a frequent and serious wartime injury, are dismissed in half a page; the discussion is totally inadequate. Acute and chronic hematogenous osteomyelitis, which was practically nonexistent in World War II, occupies almost a third of the 290 pages of the text. Skeletal traction in the management of compound fractures, delayed primary closure of wounds over compound fractures, and similar subjects are not mentioned.

The whole text, in short, although it purported to furnish the information necessary for orthopedic surgeons as they entered military service from civilian life, was chiefly written from the standpoint of civilian practice. The material that would have been of value to these new medical officers, and that would have avoided the trial-and-error method by which the management of bone and joint injuries was finally evolved in World War II, remained buried and forgotten in the British and American official histories of the war. As a result, American orthopedic surgeons and other physicians who found themselves obliged, by the exigency of the wartime situation, to handle casualties with bone and joint injuries, entered upon their World War II experience with

no clear-cut concepts of the optimum procedures for the management of these casualties.

If the medical histories of World War II incorporate the clinical experiences of that war and if what is printed will be read in the future—as it has not always been read in the past—military surgeons will not, in the future, repeat the mistakes of the past, as they did in World War II.

The account of the orthopedic surgical experience in the various overseas theaters and in the Zone of Interior is an endeavor to relate the errors as well as the successes associated with the management of bone and joint injuries in World War II. To deny that mistakes were made or to fail to describe them in detail would lessen the usefulness of this account for future military surgeons.

“They who forget the past are condemned to repeat it.”

PART I

ADMINISTRATIVE AND RELATED
CONSIDERATIONS

Mather Cleveland, M. D.

CHAPTER I

The Consultant System

The first formal step in the establishment of orthopedic surgery as a recognized specialty in the European Theater of Operations was the appointment of Col. Rex L. Diveley, MC, as senior consultant in orthopedic surgery in July 1942. The Professional Services Division, Office of the Theater Chief Surgeon, to which he was appointed, had been set up about a month earlier.

Colonel Diveley held this appointment until May 1944, when he was relieved to devote his full time to the Division of Rehabilitation. He was succeeded on D-day minus 20 by Col. Mather Cleveland, MC, who served until the end of the fighting in Europe.

Throughout the war, both senior consultants in orthopedic surgery had ready and satisfactory access to higher medical authority as well as to other consultants in the various branches of medicine and surgery. This access had much to do with the success of the planned program in orthopedic surgery and with the competent treatment of casualties with bone and joint injuries.

Functions of the Senior Consultant

The principal duties of the senior consultant in orthopedic surgery, European Theater of Operations, were as follows:

1. To investigate the training, qualifications, and competence of orthopedic surgeons and other medical officers doing orthopedic surgery and to recommend adjustments of personnel to provide for full orthopedic coverage in all hospitals;
2. To visit medical installations in the theater as often as possible, in order to aid in the processing and treatment of casualties with bone and joint injuries by advice, suggestion, correction of errors, and general direction;
3. To provide special supervision for hospitals in which there were no trained orthopedic surgeons or in which medical officers doing orthopedic work were inexperienced and likely to require special advice and direction;
4. To formulate policies of treatment of the wounded by writing circular letters and directives to be issued with the approval of the Chief Surgeon, European Theater of Operations;
5. To disseminate, and to interpret by word of mouth, Army and theater directives pertaining to the professional care of casualties with bone and joint injuries and to carry, from hospital to hospital, policies and practices devised in the various installations, when they had been found to be useful and efficient;
6. To organize such professional training programs as the exigencies of wartime service permitted;
7. To supervise and encourage such clinical investigation as wartime exigencies permitted;

8. To assemble, collect, and preserve data on the management of battle casualties and the results of various methods of treatment of bone and joint injuries; and

9. To function in a liaison capacity between the theater and army surgeons and personnel in lower echelons.

Hospital visits.—Visits of the consultant to the hospitals in the theater were of considerable practical value, especially when the units were isolated. Information as to specified techniques of management was disseminated more readily than through channels, and information as to methods devised in the various hospitals was thus transmitted to other hospitals. Techniques of management were surveyed, with the idea of keeping them as uniform as possible. Errors in management were also promptly detected, usually during the extensive ward rounds which were part of every visit. All incorrectly treated cases were fully discussed during these rounds, and, as far as was practical, personal conferences were held with the officers responsible for the errors.

Evacuation practices were also investigated and corrected as necessary. In some hospitals there was a tendency to hold patients too long, while in others evacuation was too rapid.

The consultant was often called upon for advice on both general problems and specific cases. One hospital, for instance, in the 802d Hospital Center, which had previously served as a transit hospital, was suddenly given the responsibility for definitive orthopedic surgery. No surgeon in the hospital had the necessary qualifications for its performance. The junior consultant in orthopedic surgery visited the hospital, reviewed the situation, and arranged for a team of qualified orthopedic surgeons to be placed on temporary duty in it. Before these surgeons left, they had been able to instruct the surgical personnel in the proper use of skeletal traction, in the technique of handling amputees, and in other orthopedic problems in which they previously had had practically no experience.

It was unfortunate that the senior consultant in orthopedic surgery could not visit the hospitals on the Continent more frequently. Some were visited only twice—once while they were still on the beachhead and once when the battlefield had moved farther inland. This was unavoidable, because of the increase in the number of hospitals and the increasingly great distances to be covered to reach them. Under these circumstances, the work of the junior consultants in orthopedic surgery was particularly useful.

Junior-Consultant System

The junior-consultant system was devised as the solution for two problems. The first, as just mentioned, was the inability of the senior consultant in orthopedic surgery to make frequent, regular visits to all hospitals. The second was the unavoidably uneven distribution of trained orthopedic personnel throughout the theater (p. 14). Junior consultants were appointed to serve in various

base sections and hospital centers in the United Kingdom and on the Continent. They assumed these duties in addition to their regular duties as chiefs of orthopedic sections in their own hospitals. All of them served with distinction.

In all, 7 orthopedic surgeons served as junior consultants in the United Kingdom, and 9 were later appointed to similar positions on the Continent. The situation on the Continent, however, never in the course of the active fighting presented the stability that was obtained in the United Kingdom, and frequent changes of consultant personnel were necessary as hospitals were moved from base to base and center to center. It was V-E Day, in fact, before anything approaching stability was accomplished on the Continent, and for this reason most of the junior consultants who served there were not appointed until near the end of, or after, the war. The interpretation of policies would have been greatly facilitated by their earlier appointment, whether they had served full time or part time.

The junior-consultant system filled a serious need and was regarded as extremely successful. The chief defect of the system was that the consultants did not have sufficient direct and personal contact with the senior consultant in orthopedic surgery. Provision for such contacts should be made in the event of a future emergency.

Some junior consultants rendered monthly reports to the senior consultant in orthopedic surgery. Others reported to him only after tours of duty. Some of the junior consultants also made complete reports at the conclusion of hostilities.

One such report, from the orthopedic section of the 802d Hospital Center, January-June 1945, is summarized statistically as typical of the work covered by a junior consultant in orthopedic surgery who, in addition to his consultant duties, supervised the work in this center, conducted a superior orthopedic service in his own hospital (the 22d General Hospital), and also found time to collect certain data of unusual interest, some of which will be commented on elsewhere. Other junior consultants had equally meritorious achievements to their credit.

	<i>Cases</i>	<i>Number</i>
Total admissions.....		42, 372
Orthopedic admissions.....		10, 647
Consultations (hospital and clinic).....		6, 790
Fractures of—		
Humerus.....		1, 182
Radius, ulna, both.....		2, 117
Femur.....		1, 202
Tibia, fibula, both.....		1, 307
Injuries of and about hip.....		161
Infected compound fractures.....		988
Plaster-of-paris splints.....		10, 448
Skeletal traction.....		2, 134
Open reductions.....		202
Amputations.....		215

Total admissions—Continued	Cases	Number
Delayed primary closure of compound fractures.....		1,880
Successful.....		1,514
Partly successful.....		283
Failures.....		83
No closures, or failures due to sepsis.....		312

The 802d Hospital Center consisted of 19 hospitals (13 general and 6 station hospitals) with 18,636 beds. The largest block of beds, 7,500, approximately 40 percent, was assigned to orthopedic surgery. The number of medical officers assigned to the orthopedic section averaged 64.

A summarized report from the orthopedic section of the 22d General Hospital, 10 June 1944 to 1 June 1945, is also included as typical of the work of a well-conducted orthopedic section in a general hospital.

	Cases	Number
Orthopedic admissions.....		2,460
Fractures of—		
Humerus.....		203
Radius, ulna, both.....		301
Femur.....		301
Tibia, fibula, both.....		567
Injuries of and about hip.....		154
Open reductions.....		90
Amputations.....		32

Consultants in Army Areas

It would have been highly desirable if each field army could have had its own consultant in orthopedic surgery in the army surgeon's office, though he would have been useful only if he had had ready access to all hospitals in the area and complete freedom, within the limits of security, to move about the area and to visit these units frequently. The logic of such an appointment is obvious, namely, the uniformly large proportions of wounds of the extremities in all battle-incurred injuries.

During World War II, only 2 of the 5 armies which functioned in combat in the European theater had their own consultants in orthopedic surgery. One of these armies, the Fifteenth, became operational so late that it handled few battle casualties. In the Ninth United States Army, however, the value of the policy was clearly evident. The consultant in orthopedic surgery for this army concentrated his attention and efforts on evacuation hospitals, where casualties with bone and joint injuries were constantly received in large numbers. This left the consultant in surgery free to devote himself to field hospitals, where surgery of the chest and abdomen and other urgent operations were performed. The two officers worked in close liaison with each other.

The direct supervision of work in the evacuation hospitals by the Ninth Army consultant in orthopedic surgery was soon reflected in the status of the patients received in the general and station hospitals to the rear. They arrived in better condition. There was a striking improvement in the selection and

application of plaster casts. There were also notably fewer errors in evacuation practices.

Evaluation and Assignment of Personnel

Evaluation.—A complete, up-to-date file of orthopedic personnel was maintained in the office of the senior consultant in orthopedic surgery, with all the information which could be secured about the officers assigned to this branch. The original material was secured on a special form (fig. 1). This permitted an immediate tentative evaluation of the officer, on the basis of data which he himself supplied, and served until additional and more authoritative information about him could be secured.

The Military Occupational Specialty (MOS) rating for orthopedic surgery was 3153:

An officer with the rating of A-3153 was professor of orthopedic surgery at a class A medical school, or a nationally or internationally recognized leader in the profession, or an officer who had made a definite contribution to advancement of the knowledge of this specialty.

An officer with the rating of B-3153 was a diplomate of the American Board of Orthopaedic Surgery or a fully trained medical officer who had not yet been able to take his examination for certification. This group also included an occasional American Board of Surgery diplomate with qualifications in traumatic surgery.

An officer with the rating of C-3153 had almost completed his civilian training in orthopedic or traumatic surgery and had augmented his experience in these fields during Army service.

An officer with the rating of D-3153 had had little or no basic surgical training in civilian practice and a varying amount of experience during his Army service.

In 1944, when the invasion of the Continent occurred and mass management of battle casualties was necessary for the first time, there were 820 living diplomates of the American Board of Orthopaedic Surgery. Sixty-three of these were then serving among the approximately sixteen thousand medical officers assigned to the European theater.

Three of the sixty-three diplomates were serving as consultants in orthopedic surgery, and three were assigned to the rehabilitation service. The other diplomates in the European theater were assigned to general, station, and evacuation hospitals or headed orthopedic surgical teams in auxiliary surgical groups.

The 63 certified orthopedic surgeons in the European theater were supplemented by 95 other medical officers who had some training in orthopedic surgery. At a minimum, each of them had had 3 years of surgical training, including a year or more of training as a resident in orthopedic surgery. There were also 85 other surgeons who had completed residencies in general surgery or who had served as surgical residents for varying periods of time. These 3 categories

ORTHOPEDIC SURGERY IN EUROPEAN THEATER

Last Name	First	MI	Rank	Branch	Component	ASN	Date	Interview
DATE BIRTH _____			ENTERED ACTIVE DUTY _____					
UNIT _____				T/O VACANCY _____				
MEDICAL SCHOOL _____						DEGREES _____		
INTERNSHIPS _____								
RESIDENCIES _____								
FELLOWSHIPS _____				BOARD CERTIFICATIONS _____				
OTHER TRAINING OR POSITIONS _____								
PRIVATE PRACTICE _____								
ARMY ASSIGNMENTS. & SPECIAL COURSES _____								

CIVILIAN GRADING _____			MILITARY GRADING: PAST _____			PRESENT _____		
(Include dates in filling out questionnaire)								
REMARKS:								

FIGURE 1.—Special form used for securing information about officers assigned to the orthopedic surgery branch.

TABLE 1.—Assignment of medical officers with MOS 3153, Orthopedic Surgeon, 6 June 1944

Rating ¹	Hospital						Auxiliary surgical group		Other		Total
	General		Station		Evacuation						
	Number	Percent	Number	Percent	Number	Percent	Number	Percent	Number	Percent	
A.....	3	0.72	0		1	0.24	0		3	0.72	7
B.....	36	8.63	4	0.96	9	2.16	4	0.96	5	1.20	58
C.....	87	20.86	19	4.56	27	6.47	14	3.36	6	1.44	153
D.....	91	21.83	22	5.27	34	8.15	5	1.20	47	11.27	199
Total.	217	52.04	45	10.79	71	17.02	23	5.52	61	14.63	417

¹ See p. 11 for requirements for each rating.

provided a more or less solidly trained nucleus of 243 medical officers, who carried most of the orthopedic responsibility in the theater. (See table 1.)

In the early spring of 1945, there were in the European theater 146 general hospitals, 47 station hospitals, and 63 evacuation hospitals whose tables of organization called for one or more specialists in orthopedic surgery. If these requirements had been fulfilled, the theater would have utilized the services of 446 specialists in this field, 2 for each general hospital, each 750-bed station hospital, each 500-bed station hospital, and each 750-bed evacuation hospital, and 1 for each 400-bed evacuation hospital and each 250-bed station hospital.

To fill existing vacancies in these various hospitals, it was necessary to utilize the services of 174 medical officers who had had no basic civilian training that qualified them as surgeons. Some were very recent graduates. Some were older practitioners. Some had specialized in other fields of medicine. For the most part, these officers received their training for orthopedic work on the orthopedic sections of Army general hospitals in the theater, under more experienced orthopedic surgeons. Their instructors were well qualified, and most of the untrained officers were willing pupils. It was therefore perfectly possible to teach them quickly the relatively simple surgical techniques of military traumatic surgery of the extremities.

It should be noted, however, that there were two reasons why this system succeeded so admirably: (1) Definite regimens of management were set up and followed precisely; and (2) there was careful supervision in all echelons. To fulfill the technical minimum requirements in orthopedic surgery in the European theater, it would have been necessary to use several times the number of qualified surgeons who were available for service. By adherence to the criteria just stated, it was possible to maintain high standards of professional care in the absence of a full complement of professionally trained orthopedic surgeons.

The 243 fully or partially trained orthopedic surgeons and the other officers trained in the theater to do orthopedic work provided service in this specialty for a maximum troop strength in May 1945 of 3,065,505 men.¹ Between 1

¹ Strength reports of the Army, prepared by office of Chief of Staff.

February 1942 and 8 May 1945, 381,193² casualties with battle-incurred injuries and 278,500³ admissions with nonbattle injuries were treated in the medical installations in the European theater. Between 35 and 40 percent of battle casualties and some 36 percent of nonbattle injury admissions had involvement of the bones and joints.⁴ This small number of orthopedic surgeons (243) was called upon to treat between 220,000 and 250,000 hospitalized patients, aside from wounded prisoners of war and the patients managed in outpatient clinics.⁵

Assignment.—The personnel problem in the European theater was a matter of assignment as well as of number of trained orthopedic surgeons. A shortage of adequately trained orthopedic personnel will undoubtedly occur in any war, because so much of the patient load consists of injuries to the bones and joints. The solution of the shortage in World War II was twofold: The effective distribution of such qualified personnel as were available and the performance of forward surgery by surgeons without specialized orthopedic training.

Orthopedic responsibilities began with the arrival of the first United States troops in the United Kingdom early in 1942. The orthopedic sections of the 6 general and 7 station hospitals which had reached the European theater by the end of that year were all occupied with the treatment of civilian-type accidents and the various injuries which always occur in mass training for combat. The 2d Evacuation Hospital, at Diddington, Hunts, was kept busy with Air Force casualties.

At first, there was no shortage of orthopedic personnel in the theater, and assignment presented no difficulties. Even as late as the fall of 1943, some hospitals were arriving in the theater with two or more qualified orthopedic surgeons among their personnel. These were usually affiliated hospitals. As time passed, the situation became very different. From 1943 until the end of the war, some hospitals arrived in the United Kingdom with only partly trained orthopedic surgeons on their staffs, while other hospitals had none at all. It was always nonaffiliated general hospitals which came into the theater without orthopedic personnel. Furthermore, the medical officers in many hospitals of this kind had been engaged in administrative problems and had been without professional contacts for so long that they were inadequately prepared for the clinical problems presented by hundreds and thousands of soldiers with battle-incurred injuries of the bones and joints.

The problem of supplying qualified personnel to staff the orthopedic sections of the hospitals in the European theater therefore became acute long before the invasion of the Continent. As D-day approached and the military

² Army Battle Casualties and Nonbattle Deaths in World War II, Final Report. Note: Personnel killed in action and battle-wound or injury cases carded for record only (CRO admissions) are excluded from the figure cited.

³ This figure included CRO admissions. Data for 1942-44 were obtained from tabulations of individual medical records; data for 1 January-8 May 1945 are estimated. The estimate was based on sample tabulations of individual medical records and data compiled from summaries of the Statistical Health Report (WD AGO Form 8-122). Provisional tabulations such as these will be supplemented in time by final tabulations.

⁴ These battle-casualty estimates represent the general opinion of the medical staff, based upon personal experience. The nonbattle estimate is provisional, awaiting publication of final tabulations.

⁵ Semiannual Report, Professional Service Division, Orthopedic Surgery, Office of the Chief Surgeon, European Theater of Operations, 1 January-30 June 1945.

exigencies became keener, it was necessary that hospitals with an oversupply of qualified personnel be plundered to supply the needs of hospitals which had arrived without orthopedic surgeons on their staffs. The objective was to supply all general hospitals, as well as all station hospitals in the United Kingdom, with orthopedic surgeons. Later, as the need increased with the increase in combat casualties, station hospitals, except for those in East Anglia which served the Air Forces, themselves had to be plundered of their orthopedic personnel to supply the general hospitals which came into the theater without qualified chiefs of orthopedic sections.

Needs of hospitals.—Normally, an orthopedic surgeon is unnecessary in a field hospital, and qualified orthopedic surgeons were not used in this manner in the European theater.

The great bulk of work in an evacuation hospital consists of casualties who must undergo debridement. At various times in the European theater, 4 teams of surgeons, each team working 12-hour shifts around the clock, could scarcely keep up with the admissions. This did not mean, however, that orthopedic surgeons would have been properly utilized in these forward hospitals. Theoretically, the argument is sound that, if injuries of the bones and joints are treated correctly initially, the results will be better and correspondingly less secondary surgery will be necessary in rear areas. On the other hand, even if there had been enough trained orthopedic surgeons to assign 2 to each evacuation hospital, these 2 surgeons could not possibly have taken care of the casualties. The solution, therefore, was to use trained general surgeons as well as other less well trained surgeons who, after some instruction, proved able to perform perfectly satisfactory debridement. This was what was done. In times of stress, even otolaryngologists worked in evacuation hospitals, outside of their specialty, it is true, but they performed entirely acceptable debridement.

If an orthopedic surgeon was assigned to an evacuation hospital, he was most useful in the supervision of other surgeons and in the making of frequent spot checks of the quality of the work. He could occasionally undertake particularly difficult cases himself, but it was unwise for him to tie himself up in run-of-the-mill cases if he was working in a hospital with surgeons inexperienced in the management of bone and joint injuries. It is under such circumstances as these that a consultant in orthopedic surgery assigned to a field army has his widest field of usefulness.

Originally, teams of orthopedic surgeons from auxiliary surgical groups were attached to evacuation hospitals. This did not prove to be a particularly economical use of trained personnel. A corpsman was a satisfactory assistant, and sometimes a better assistant than a trained surgeon, in almost all of the operations permissible in an evacuation hospital. The feeling was frequently expressed that it would have been better to give the assistant surgeon on the orthopedic team a table and an operating crew of his own and to let the orthopedic surgeon on the team operate with the assistance of corpsmen.

The opinion was also often expressed that the orthopedic surgeons in evacuation hospitals in reserve could profitably have served on auxiliary

surgical teams during their periods of waiting. This plan would have provided a more flexible group of qualified orthopedic surgeons, without any increase in personnel, and would undoubtedly have given satisfaction to the surgeons themselves, who were always restless and unhappy during the long periods of inactivity required by the Army policy of holding some evacuation hospitals in reserve. Theoretically, this was a sound suggestion. Practically, logistic difficulties would probably have made it extremely difficult to carry out as a routine procedure.

According to the tables of organization, a general hospital was supposed to have a chief and an assistant chief of the orthopedic section, both of them well trained. In many instances it would have been desirable if this requirement could have been fulfilled, but it would have necessitated 3 to 4 times as many adequately trained (MOS 3153) orthopedic surgeons as were ever available in the entire European theater.

As a practical matter, most of the trained orthopedic and traumatic surgeons in the theater, especially those with the highest ratings, were assigned to the general and the large station hospitals. It was frequently necessary to plunder evacuation hospitals and auxiliary surgical teams to fulfill the orthopedic needs of these hospitals. When the fighting on the Continent began, all auxiliary surgical groups had orthopedic surgeons in their complement. By the end of hostilities, most of these surgeons had been released and reassigned to general hospitals which had entered the theater without orthopedic specialists on their staffs.

Level of training.—Even when orthopedic surgeons were in numerical sufficiency on hospital staffs, the level of training was not always adequate. In the 19 hospitals which comprised the 802d Hospital Center, for instance, 7,500 of the 18,636 beds were assigned to orthopedic surgery. Of the 18 surgeons in charge of these beds only 3 had B-3153 ratings. The training of the average chiefs of orthopedic sections in the C and D categories in this center, as well as in other centers and hospitals, was often frankly inadequate, though, with careful supervision, they were able to handle the compound fractures which made up the bulk of the work.

Before D-day, when the situation was not urgent, it had frequently been possible, when officers in charge of orthopedic sections of newly arrived hospitals were regarded as inadequately trained, to send them on detached service to one or another of the older hospitals in the United Kingdom to serve on the orthopedic sections under chiefs of known competence. After several weeks, the officers under whom these inexperienced officers were serving prepared an evaluation of their current abilities and future potentialities. Certain chiefs of section rendered extremely valuable service in this way; their judgment proved almost unerring, and they were responsible for the training and assignment of many originally poorly trained officers who later rendered valuable service in their own hospitals. After D-day this plan of training naturally had to be discontinued.

Utilization of qualified personnel.—From May through October 1944, most of the older affiliated units in the United Kingdom were engaged in staging, so that they could be set up on the Continent in the wake of the invasion. They were replaced, in the hospitals which they had formerly manned in the United Kingdom, by more recently arrived units. The arrangement was perhaps unavoidable under the circumstances, but the first result of it was that the most experienced orthopedic staffs in the theater did not participate, as units, in the first 2 months of the invasion, though teams from some of them did participate in the early care of battle casualties.

The second result was that the early care of these orthopedic casualties was left to the newer and more inexperienced units, whose orthopedic sections, in many instances, were staffed by officers who were not qualified orthopedic surgeons. The professional personnel of these hospitals was frequently a source of great anxiety. On the whole, the work that was done was excellent, but it would have been better if the surgeons of experience could have been fully utilized in the first weeks of the invasion, to establish standards of orthopedic care and to lighten the burden of the less experienced surgeons who were called upon to assume heavier responsibility than their professional training qualified them for.

The situation on the Continent was equally uneven. The hospitals which went over first, as well as the hospitals which came up from Italy, were the oldest and most experienced of the affiliated units. There was, in all, a nucleus of perhaps 30 such hospitals. It may be, again, that under the tactical circumstances which prevailed, the uneven distribution of experienced and inexperienced hospitals could not have been prevented. It left, however, large areas in which it was difficult to maintain a high level of professional care. In retrospect, from the orthopedic standpoint, it would have been a better plan to scatter the older hospitals, especially the affiliated units, in such a way that they could have served as a nucleus or parent installation for the hospital centers set up on the Continent.

This was not done, and the orthopedic setup on the Continent was often far from ideal. One hospital center, for instance, consisted of four affiliated units. Another, in a total of 6 hospitals, had 4 affiliated units. A third, in a total of 11 hospitals, had 3 such units. In contrast, two hospital centers located adjacent to each other consisted of a total of 18 component hospitals, all of them newly arrived, none of them with previous experience as functioning organizations, and none of them with a single adequately prepared and trained orthopedic surgeon in their personnel. As a result, it was necessary to transfer a trained orthopedic surgeon, with an active orthopedic service, from another center to these centers to serve as orthopedic consultant for both.

Exchange of personnel.—A few orthopedic surgeons in the European theater served at various times in both the army zone and the zone of communications. This was a highly desirable practice (p. 86). It gave these officers a more complete experience and also provided them with a fuller and a greatly

needed understanding of the problems in both areas. Had this policy been carried out consistently, it would probably have ended most of the (unadmitted) dissatisfaction of the orthopedic surgeons who worked entirely in forward areas and who would have preferred to work in base areas where they could have done definitive or reparative surgery which, of course, could not be performed in forward areas.

It was the plan to develop more extensively the exchange rotation of personnel from forward to rear areas and vice versa, but the war ended before it could be put into practice to any considerable extent. There were two practical objections to this policy. One was the unwillingness of commanding officers to lose competent personnel. The other was the unconscionable length of time it usually took a medical officer to travel as a casual from the rear to the front and vice versa, though the actual distance was seldom more than 600 to 800 miles. Officers were known to spend as long as 10 to 14 days in various depots awaiting transportation. This waste of time naturally tended to cool the ardor of commanding officers of hospitals, whose orthopedic sections might be left uncovered for long periods of time while exchange officers were en route from one assignment to another.

Rank.—The matter of rank naturally had nothing to do with the treatment of patients, but it played its part in the morale of orthopedic surgeons in the European Theater of Operations just as it did in the morale of all other specialists, particularly toward the end of the war. At this time a few 1,000-bed hospitals were raised to 1,500-bed status, which theoretically provided for an increase in rank for some specialists. With a single exception, the hospitals in this group were not the original affiliated units which had been in the theater from the very beginning but were new hospitals, whose officers, in terms of service, were not always entitled to increases in rank. A number of last-minute shifts in personnel were effected, in an attempt to secure promotion for outstandingly qualified officers with long and meritorious service, but few of these promotions went to orthopedic surgeons.

Some hospitals entered the European theater from the Mediterranean theater with 1,500 beds and with some of their specialists already lieutenant colonels, though their service had been no longer than that of the orthopedic surgeons in the European theater who had been denied promotion. The comparison in rank naturally was unfortunate.

It was the feeling of the senior consultant in orthopedic surgery that some 10 of the approximately 400 surgeons doing orthopedic work in the European theater should have been advanced to the rank of lieutenant colonel by the end of hostilities. All of this group had served approximately 3 years in grade, and all had made significant contributions to the Army effort. Because of redeployment and freezing of promotions, 9 of the 10 recommended increases in grade were never accomplished.

CHAPTER II

Tours of Hospitals

When a new senior consultant in orthopedic surgery (Col. Mather Cleveland) was appointed in the European theater shortly before D-day, one of his first duties was to visit as many hospitals as possible in the United Kingdom. A total of 40 were visited before the invasion occurred. The wards had been stripped of patients, as far as was practical, in all of them, in the expectation of the heavy casualties to follow D-day, and the planned demonstrations of diagnosis and management, including plaster techniques, were necessarily limited.

Otherwise, most of the visits fell into the same general pattern. The qualifications of personnel were reviewed, and notes were made of suggested changes of assignment. General problems of orthopedic management were discussed with the chiefs of the surgical services and of the orthopedic sections, and matters of policy were discussed with commanding officers. It was suggested to the latter that they utilize the services of orthopedic surgeons to instruct all personnel in the management of bone and joint injuries and in the application of plaster.

After D-day, the practice of visiting hospitals was continued as far as time and other duties permitted. The situation in the United Kingdom was not too difficult, because distances were short. On the Continent, however, as the fighting moved farther and farther away from the beaches, distance introduced a considerable problem, and some hospitals were visited only twice in the 11 months that elapsed between D-day and V-E Day.

Two hospital tours made by the senior consultant in orthopedic surgery late in 1944 are reported because they illustrate a number of points, including (1) the various functions of a consultant; (2) the unevenness of the qualifications, both in training and experience, of chiefs of surgical services, under which orthopedic sections functioned; (3) the resulting differences in the concepts of orthopedic surgery in the various hospitals; (4) the difficulties of providing orthopedic sections with trained and competent personnel; (5) the techniques of instruction employed in the management of battle-incurred injuries; and (6) the effectiveness of consultant supervision in detecting errors of management and in providing for their correction.

For comparative purposes and as a matter of convenience, the reports of these two tours are summarized under general headings, instead of being presented chronologically.

The first report deals with a tour of 17 hospitals and 1 hospital center in the United Kingdom in early November 1944, when casualties with bone and joint injuries were being treated in considerable numbers (table 2). The second report deals with a tour of 8 hospitals and 2 headquarters on the Continent in late November and early December of the same year.

Tour of Hospitals in the United Kingdom Base, November 1944

Personnel

The general plan, at each of the hospitals visited, was to hold conferences with the commanding officer and the chiefs of the surgical and orthopedic sections. Special reports were received from the chiefs of orthopedic sections who were also serving as junior consultants in orthopedic surgery under the system described elsewhere (p. 8). Newly assigned personnel were evaluated, and arrangements were made for the evaluation, by competent officers, of orthopedic personnel to be assigned to the orthopedic section in the immediate future.

TABLE 2.—*Sample distributions of hospital populations in the United Kingdom, November 1944*

General hospital	Patients			
	Total	Surgical (total)	Orthopedic	Holding
97th.....	1, 029	539	165	-----
102d.....	910	750	350	-----
103d.....	1, 100	-----	350	-----
104th.....	861	550	160	-----
106th.....	795	684	226	-----
22d.....	791	-----	83	260
216th.....	877	441	291	-----
121st.....	734	700	300	-----
159th.....	769	380	160	-----
67th.....	1, 112	801	260	246
74th.....	976	¹ 600	¹ 400	-----
117th.....	1, 199	950	375	75
192d.....	1, 072	966	374	-----

¹ Approximate.

Sample reports of these evaluations and corollary recommendations follow. Precise identification is omitted for obvious reasons.

1. At the . . . General Hospital, the chief of the surgical service had had a year's internship and a 36-month residency in surgery at the . . . University Hospital. He is a diplomate of the American Board of Surgery. His 3 years in the Army have been spent in executive and surgical positions.

The chief of the orthopedic section at this hospital was graduated from the University of . . . Medical School in 1922. He practiced general surgery from 1926 through 1931, and thereafter, until he entered the Army in 1942, limited his practice to general surgery and orthopedic surgery. He had had 13 years' hospital training and 2 years' postgraduate training at the University of . . . He is a diplomate of the American Board of Surgery. He had served on the orthopedic section at . . . General Hospital in the Zone of Interior. He was away on detached service at the time of this visit, but on paper his qualifications seem adequate for the chief of an orthopedic section.

Another officer in this hospital may be of some value as a second man on this section, although his qualifications do not make him adequate to be chief of section.

He was graduated from the . . . Medical School in 1939 and has had a total of 32 months of hospital training and service as an orthopedic consultant in the Veterans Administration.

2. At the . . . General Hospital, the chief of the surgical service had a 2-year internship at . . . Hospital in . . . and had practiced general and industrial surgery for 3 years before he entered the Army. He is not a diplomate of the American Board of Surgery. He served as chief of the surgical service at Camp . . . in the Zone of Interior before being sent overseas. In private practice, he performed approximately 60 operations a year, chiefly appendectomies, hemorrhoidectomies, and hernioplasties, but his experience in fracture work is extremely limited.

The officer in charge of the orthopedic service is a graduate of the . . . Medical School, class of 1935. He served a 2-year internship in surgery; his experience in the Army has been entirely surgical.

There is thus no officer in this hospital who is trained in, or familiar with, orthopedic surgery. A competent orthopedic surgeon should be in charge of the orthopedic section. Since the . . . General Hospital has two officers with considerable experience in fracture work, it will be suggested that one of them be assigned to the . . . General Hospital as chief of the orthopedic section and that his replacement be an officer with adequate training in general surgery.

3. At the . . . General Hospital, an excess of trained personnel was found, including a young, very well trained orthopedic surgeon and an older officer (major) with considerable training in traumatic and fracture surgery. This hospital does not need the services of both these trained men, especially at a time when other hospitals in the United Kingdom are short of trained orthopedic personnel. It will be suggested that the orthopedic surgeon be assigned elsewhere, where he can be more fully utilized.

4. At the . . . General Hospital, it was interesting to observe how the level of treatment of bone and joint injuries had risen since the senior consultant's last visit and after the change of personnel which had occurred in the orthopedic section. Similar improvement was observed in other hospitals where similar changes had occurred.

5. At the . . . Station Hospital, the senior consultant in orthopedic surgery had a conference with Captain . . . and received reports from him of the orthopedic work at the . . . , . . . , and . . . Station Hospitals, to which he had been assigned as consultant. All were prisoner of war installations, but in spite of this handicap, Captain . . . reported that the orthopedic work was satisfactory in all respects. Captain . . . has done an excellent job as a junior consultant and it has been recommended that he be named consultant in orthopedic surgery for the . . . Hospital Group (Center), where he will work under the surgical coordinator. The commanding officer of the hospital group (center) has approved this arrangement.

Administrative Details

At the 102d General Hospital, several wounded Free French soldiers were encountered, and the consultant was questioned as to their disposition. Apparently, British hospitals no longer received them. A note was made to investigate this situation.

At all hospitals visited, it was emphasized that patients who were neurosurgical problems should be transferred without delay to a neurosurgical center. Similarly, patients with complicated hand injuries were to be transferred to special hand centers.

At the 117th General Hospital, no operative work was being done on the neurosurgical service, because the neurosurgical officer was suffering from a dermatitis which precluded his scrubbing. It was recommended that this

officer be replaced or be given a competent assistant. This hospital is capable of doing excellent bone and joint work and should be fully utilized.

At the time of this visit, the 22d General Hospital was serving as a holding hospital and had not received battle casualties for a considerable period of time. Because of its superior equipment and staff, the senior consultant considered it wasteful to use this hospital merely as a holding unit and recommended that it be given a high priority for the treatment of battle casualties.

Evacuation Time

The time of arrival after wounding of patients transported from the Continent to the United Kingdom hospitals showed a wide range. Up to 3 or 4 weeks before this visit, which was in early November, many of the hospitals visited had received patients within 4 or 5 days. When air evacuation was available, some patients were still being received within a week after wounding. In many installations, however, the average time had lengthened to 2 weeks. The 192d General Hospital received patients from Holland and from Belgium by air within 6 days, and sometimes as early as 2 days, after wounding. These patients, who were mainly paratroopers, were flown in by the British.

At the 104th General Hospital, several patients with compound fractures had recently been received too late for skeletal traction, and 1 patient had not been received for 36 days. The position of the femoral fragments was not too unsatisfactory in another, similarly delayed case, but shortening amounted to almost an inch. Since these patients had already been evacuated to the Zone of Interior, their names and serial numbers were not available. It was stressed to the hospital staff that careful record should be kept of all patients delayed in transit long enough to interfere with their care, so that such errors could be investigated and corrected.

Experience varied from hospital to hospital. At the 106th General Hospital, 4 hospital trains had been received since 25 July, but at the time of the visit patients were chiefly being received by ambulance from the 79th General Hospital and the 110th Station Hospital. Ambulance convoys brought from 60 to 90 patients per trip. At the 121st General Hospital, convoys were received by air, train, and ambulance. In the first 3 convoys, the wounded were received from 24 hours to 5 days after wounding. The timelag for the fourth convoy was 8 to 10 days, and for the fifth it was as long, for some cases, as 21 days. At the 74th General Hospital, a total of 13 trainloads of patients had been received, the most recent from 10 days to 2 weeks after wounding. No patient had ever been received too late to be put in skeletal traction. At the 216th General Hospital, the last trainload of casualties, 50 percent of whom were neuropsychiatric, had previously passed through from 3 to 9 hospitals.

During the last 12 weeks, the condition of the patients on arrival was not as good as it had formerly been. The average timelag after wounding during this period was 12 to 14 days, but some patients had been delayed for 21 days or longer.

Wound Closure

At the 187th General Hospital, 90 percent of compounding wounds were closed by delayed primary suture, and healing was usually complete when the patients were evacuated to the Zone of Interior. At the 216th General Hospital, closure of wounds over compound fractures was similarly successful.

At the 102d General Hospital, wounds were closed by suture over compound fractures in about 80 percent of all cases and by skin grafts in the remaining cases. The 15th Hospital Center had treated approximately 3,500 compound fractures since D-day. Preliminary analysis of the material showed that healing had been satisfactory in 80 percent of the first 1,500 wounds closed by suture or skin graft.

At the 67th General Hospital, 62 compound fractures of the femur had been treated since D-day; in 21 of these cases the wounds were infected when the patients were admitted. Spontaneous closure occurred in 18 of the 62 wounds, and closure was undertaken in 23 others. Healing occurred in all 11 cases in which delayed primary closure was carried out from 5 to 16 days after wounding. In the 12 closures done later, in slightly infected wounds, primary healing was not accomplished, but all wounds were healed before the patients were evacuated.

At the 192d General Hospital, 71 compounding wounds closed by delayed primary suture healed satisfactorily, and healing was partially successful in 18 others. Both surgical and orthopedic section chiefs agreed that patients who were evacuated from the front in circular plaster-of-paris splints seldom presented wound infections and were best suited for early closure of compounding wounds. Secondary debridement was seldom necessary in these cases. Recently a number of patients whose wounds had not been debrided had been received through British hospitals, but this was an exceptional experience.

The chief of the orthopedic section at the 121st General Hospital reported that debridement of compounding wounds had been almost universally necessary before wound closure could be undertaken. As a result, relatively few wound closures were being performed. This experience was entirely contrary to that of most other hospitals in the United Kingdom, where wound closure was seldom delayed more than 5 to 10 days after the patients' arrival. The senior consultant in orthopedic surgery wondered whether so many debridements were really necessary and suggested, instead, that wounds which did not look healthy be treated by wet dressings for 2 or 3 days.

Very few compound fractures had been closed at the 103d General Hospital in the past 6 weeks, because of the attitude of the surgeon in charge of the orthopedic section toward delayed primary wound closure. This policy was to be remedied.

At the 192d General Hospital, it was observed that when a patient was received with a large, metallic foreign body in the wound, healing almost never occurred until the foreign body had been removed. The delay was

attributed not to the metallic object itself but to the bits of clothing that had usually entered the wound with it.

Plaster Techniques

Plaster of paris was, on the whole, well applied. At the 67th General Hospital, the circular plasters were rather bulky, but this was because it had been necessary to use cotton batting as a substitute for sheet wadding, which had been unobtainable.

At the 192d General Hospital, it was found that every patient who had been evacuated in a Tobruk splint had suffered a great deal of pain during transit. The chief of the orthopedic section said that in his experience it was as hard to apply a Tobruk splint correctly as to apply a plaster spica, which he thought was much more comfortable for the patient. It was also reported that there was some loss of the skin of the dorsum of the foot whenever the Thomas splint was used with the Army boot strap in place during evacuation.

The surgical coordinator of the 15th Hospital Center, who had recently traveled with a hospital train, said that in his opinion all patients in thoracobra-chial spicas should be regarded as class 2. In a few instances, the spicas were too widely abducted. When plaster spicas were used for fractured femurs, he thought that a wicket should always be employed to protect the toes. No foul-smelling plasters were encountered on the train.

When the holding unit was investigated at the 22d General Hospital, 24 patients were found whose status was not considered entirely satisfactory for transportation. Their general condition was good, but the plaster casts in which they were encased were not well applied. Since these patients had all come from the 104th and 106th General Hospitals, it was suggested that the commanding officers and the chiefs of the surgical and orthopedic sections of these hospitals be asked to visit the 22d General Hospital and examine these patients with the chief of the orthopedic section.

At the 67th General Hospital, a similar criticism was made, and it was similarly suggested that commanding officers and chiefs of the surgical and orthopedic sections of the hospitals sending patients to be held should meet at the 22d General Hospital for briefing on the proper preparation of patients to be returned to the Zone of Interior.

It was noted that fractures of the humerus received from the 112th General Hospital had been put up in thoracobra-chial spicas in wide abduction. It was agreed to correct this technical error in the future.

Skeletal Traction

At most of the hospitals visited, fractures of the femur, tibia, and fibula were being correctly treated in skeletal traction. The use of traction in fractures of the femur was fairly general. At some institutions, it was not employed consistently in fractures of the tibia and fibula. It was also not employed uniformly in fractures of the humerus.

At some hospitals, the technique of skeletal traction had been greatly improved since the consultant's earlier visit. Some criticisms, however, were still necessary. At the 97th General Hospital, it was pointed out that more adequate provision should be made for motion in the knees and the ankle joints. At the 102d General Hospital, skeletal traction was adequate, but more than was necessary (up to 25 pounds) was being employed in injuries of the tibia and fibula. One patient was observed in traction with distraction of the fragments and some distraction at the ankle joint. Two men with compound fractures of the femur required dependent drainage which had not been instituted. At the 159th General Hospital, Army splints were found not in balanced suspension. One compound fracture of the femur was associated with an abscess of the thigh which needed drainage. At the 216th General Hospital, there was a slight tendency to overpulling in fractured femurs.

It was pointed out at every hospital that the great majority of fractures of the long bones should be treated by skeletal traction. When the technique was not used generally or properly, the attention of the chief of the orthopedic section was called to the directives on the subject, and he was urged to make a wider use of the method and to employ it for fractures other than those of the femur. At the 216th General Hospital, where the use of skeletal traction was limited almost entirely to fractures of the humerus, it was suggested that the chief of the orthopedic section and the chief of the surgical service visit the 22d General Hospital, which had an excellent and adequate program for the management, by skeletal traction, of all fractures of the long bones.

At the 106th General Hospital, the last convoy had brought only ambulatory casualties with no fractures of the long bones. Skeletal traction was employed in this hospital, but only a few patients were in it at the time of this visit. Two patients were observed in the Roger Anderson apparatus. The chief of the orthopedic section was reminded that the use of apparatus for external fixation should be limited to the special cases in which a pedicle graft was necessary. After the graft had been applied, balanced suspension skeletal traction should be instituted. Pedicle grafts were to be performed only in plastic centers, in which category this hospital was not included, and indications for the use of the Roger Anderson apparatus therefore should not have arisen in it.

Amputations

At the 103d General Hospital, amputation stumps were found in good condition, with adequate skin traction. The condition of the stumps had been greatly improved at the 104th General Hospital since the consultant's previous visit. At the 97th and 74th General Hospitals, the skin traction observed on some of the amputation stumps was not altogether adequate. This matter was called to the attention of the chiefs of the surgical and orthopedic sections to be remedied.

At an occasional hospital, amputation stumps had been closed by suture, in direct violation of the theater policy which required maintenance of skin

traction in all circular amputations until healing had occurred. This matter was called to the attention of the surgical and orthopedic staffs and of the commanding officers, and it was directed that skin traction be employed thereafter on all amputation stumps.

At the 121st General Hospital, patients with amputation stumps were received in good condition. Only one amputation for gangrene of circulatory origin had been necessary at this hospital.

At the 216th General Hospital, the question arose whether to amputate a viable foot which was functionally useless or to return the patient to the Zone of Interior for definitive surgery. The senior consultant in orthopedic surgery expressed the opinion that whenever a patient could be transported without risk, amputation should be deferred until he reached a hospital in the Zone of Interior.

Infections

Three patients with suppurative arthritis of the knee joint were observed at the 192d General Hospital. Symptoms had subsided under treatment with aspiration and instillation of penicillin, and a considerable amount of motion in the knees had already been gained.

Very little gas-bacillus infection was observed at most hospitals, but this was not invariably true. At the 67th General Hospital, 9 of 21 patients received with infected wounds had *Clostridium welchii* infections, and 1 died of gas gangrene. The other 8 were treated by debridement, and most of the wounds were well healed before the patients were evacuated to the Zone of Interior.

At the 216th General Hospital, 2 patients in 1 convoy were received moribund from clostridial myositis, and both died promptly. Inquiries produced no information concerning the hospitals through which they had previously passed.

The incidence of frank osteomyelitis had increased materially at the 216th General Hospital in the last several weeks. Healing of the wounds in these cases was seldom complete before the patients were evacuated to the Zone of Interior, though drainage had usually decreased. At this installation, every patient with a compound fracture of the pelvis had developed osteomyelitis, and many had required sequestrectomy.

Hand Injuries

At every hospital visited, an attempt was made to make the staff thoroughly conscious of the importance of early mobilization of wounded hands and fingers. In some instances, prolonged immobilization was still being practiced. Whenever possible, as at the 103d General Hospital, a clinic was held on hand injuries, and the importance of early, active motion was stressed. Emphasis was put upon the definitive management of wounds of the soft tissues, with secondary emphasis upon the skeletal injuries.

At some hospitals, as at the 117th General Hospital, plastic surgery on the hands was of a very high caliber.

At the 22d General Hospital, Capt. (later Maj.) Marshall R. Urist, MC, reported an interesting and useful study. After amputating a finger, he fixed the digit at various levels with Kirschner wire. He found that the entire proximal phalanx is influenced by the tendons, and that, with a single exception, it is not possible to insert Kirschner wire without transfixing them. The single exception, and the only area in the finger entirely free of tendinous structures, is a small triangle on the dorsal surface of the middle phalanx, just distal to the proximal interphalangeal joint. At this point, a small dental drill could be inserted into the marrow cavity, and adequate skeletal traction could be assured by passing a hook into the hole made by the drill. The consultant regarded this as the best means of skeletal traction of the fingers which he had encountered in his experience.

New Devices

At the 22d General Hospital, a number of appliances had been devised for the management of compound fractures, including:

1. A suspended long leg cast, utilizing the Pierson attachment, which is incorporated in the plaster of paris above and at the knee (p. 45).
2. A rotating Bradford frame to facilitate the care of extensive wounds of the extremities and trunk associated with compound fractures (p. 50).
3. A Böhler-Braun type of traction cradle (p. 50).

Special Cases

At the 121st General Hospital, an autogenous bone graft had been performed on a compound fracture of the humerus before the compounding wound was closed, with the tibia as the donor site. The graft was put in place with four vitallium screws. In the course of the operation, the surgeon disposed of a number of bone fragments at the site of the fracture which, from the description, might very well have served as autogenous grafts if they had been left in place. Purulent exudate was present at the site of the fracture at the time of the operation, which, in itself, should have contraindicated the use of a large tibial graft.

In another case at this same hospital, open reduction and internal fixation were performed on a compound fracture of the femur with a vitallium plate and screws. This wound had previously been closed.

These cases are cited as instances of questionable surgical judgment, and the commanding officer, the chief of the surgical service, and the chief of the orthopedic section were directed to refrain from such surgery in the future. Whether or not the outcome in these cases would be favorable did not alter the fact that neither operation should have been performed.

At the 67th General Hospital, a patient was seen with an unrecognized dislocation of the elbow joint. He had been injured 25 October 1944, near

Aachen, Germany. At the second evacuation hospital to which he was admitted, roentgenograms were taken of the elbow joint while he was in an upper-extremity traction splint. The views were oblique, and, because of the presence of the traction apparatus, the nature of the lesion was not appreciated and the roentgenologist failed to discover the dislocation. The surgeon listed the lesion as a sprain. The patient was evacuated to the 203d General Hospital 4 days after operation and remained there for another 4 days. At this time, a note was made that he had a very marked regional swelling, probably resulting from a dislocation which had spontaneously reduced. When the patient finally arrived at the 67th General Hospital, 10 days after wounding, he was found to have a complete dislocation of the elbow, which was reduced with considerable difficulty. The case was cited simply to ensure a more critical and inquiring attitude on the part of medical officers through whose hands casualties pass.

At the 22d General Hospital, three interesting fractures of the hip were observed, all beautifully handled. One, a dislocation with separation of the symphysis, had been treated by vertical traction. The second, a trochanteric fracture, had been fixed with a Smith-Petersen nail. The third, another dislocation, had also been treated by vertical skeletal traction.

At this same hospital, a medical officer was examined with onychogryphosis of both great toenails. The condition had originally been diagnosed as ingrowing toenails. It was recommended that he be treated by excision of the nail and bed, with amputation of part of the distal phalanx and folding of the plantar skin over the dorsal surface of the remaining portion of the toe. This type of surgery was not indicated in an overseas hospital, and a disposition board had recommended transfer to the Zone of Interior.

At the 140th General Hospital, the roentgenologist was examined because of pain in the right wrist and arm. It had been present for several years but had recently become much more severe. Roentgenograms taken during the past 8 weeks showed punched-out areas in the right capitate and unciform bones, as well as in the head of the right humerus and in the right tibia near the articular surface of the knee joint. The wrist was swollen and tender. Although the officer felt well and had recently gained weight, he was frequently incapacitated by pain. The staff was of the opinion that the condition was Boeck's sarcoid but believed that an atypical gouty lesion should also be considered. The consultant suggested biopsy on the right capitate bone to establish the diagnosis, and also recommended the tentative use of colchicine for a long-enough period to see if it would relieve the symptoms.

At the 67th General Hospital, a patient was observed with a rarefying lesion of the tibia, probably an osteitis fibrosa cystica. A Brodie's abscess of the lower end of the radius with a perilunate posterior dislocation of the carpus was also observed. Open reduction was to be employed because the dislocation was a month old. There was no fracture of the carpal scaphoid.

Eight or nine patients observed at the 216th General Hospital were suffering from symptoms of mild immersion foot. Objective findings were minimal.

Treatment consisted of keeping the foot in a tent at room temperature, with injection of the posterior tibial nerve with Novocain (procaine hydrochloride), or Pontocaine (tetracaine hydrochloride). Weight bearing was permitted after the injection and was possible for a considerable period of time without pain.

Tour of Hospitals on the Continent 23 November-3 December 1944

The following report concerns the visits of the senior consultant in orthopedic surgery to 9 hospitals (2 general hospitals, 5 evacuation hospitals, and 2 field hospitals) and 2 headquarters on the Continent between 23 November and 3 December 1944. The general plan of this tour followed the plan described for visits to hospitals in the United Kingdom Base.

Most of the hospitals visited on this tour were either in or supporting the First and Ninth United States Army areas. The Ninth Army had both a surgical consultant and a consultant in orthopedic surgery. The First Army had only a surgical consultant.

Hospital Population

The 62d General Hospital had a population of 1,307. At this time, 302 patients had bone and joint injuries. During October, there had been 3,337 admissions, 1,039 of them to the orthopedic service. Of the 2,484 surgical admissions, 1,884 had been battle casualties. On the whole, 50 percent of the battle casualties received in this hospital were handled on the orthopedic section.

The 77th Evacuation Hospital had 800 patients, 602 on the surgical service. Most of them had already had as much surgery as was permissible in this area.

The 2d Evacuation Hospital had had 15,117 admissions since 2 October, the first 2,000 of them during the period the hospital was acting as a transit hospital. Since it had arrived on the Continent in June 1944, it had been in 2 previous locations and had received approximately 27,000 patients; 3,583 operations had been performed, with 137 deaths.

The 44th Evacuation Hospital had been in six previous locations since its arrival on the Continent. During the busiest period, from 8 July to 4 August, inclusive, it had received between 600 and 700 patients daily for several days. It had done a considerable amount of station hospital work. The total population between 21 June and 31 October had been 11,094. Between 35 and 40 percent of all battle casualties had compound fractures.

At the time of this tour, the sector immediately in front of the Ninth United States Army was relatively quiet. At one clearing station visited, only five patients had been received during the day; all had minor complaints and none were battle casualties. At the 53d Field Hospital, only 25 patients had been admitted.

Administrative Considerations

At the 41st Evacuation Hospital, the chief of the surgical service reported that he had sent out between 750 and 800 cards on nontransportable patients whose subsequent condition he was anxious to check. He had received only 21 replies. Possibly many of these cards were overlooked because the field medical record of evacuation was not completely studied. It was suggested that the matter be taken up with the surgical consultant at the United Kingdom Base.

At the 2d Evacuation Hospital, the consultant attended a meeting at the office of the commander of the 68th Medical Group. This was a daily meeting at which a tactical report was made on the entire Army situation. It was an extremely interesting meeting and seemed a worthwhile plan.

At ADSEC (Advance Section) Headquarters, it was reported that evacuation was progressing much more smoothly than at the time of the last report. On one day, there had been an airlift to the United Kingdom of 1,200 patients and on another day an airlift of 800.

Plaster Techniques

Much of the discussion at the various hospitals had to do with the advantages and disadvantages of the Tobruk splint.

At the 62d General Hospital, only one patient had arrived in a Tobruk splint. The case was well selected, and the patient was comfortable. The splint was changed to a plaster-of-paris spica before he was evacuated to the United Kingdom. At this hospital, it was reported that plaster-of-paris splints in which the patients arrived from evacuation hospitals had to be changed in about 10 percent of all cases before their transshipment to the United Kingdom.

At the 41st Evacuation Hospital, a number of patients were observed in Tobruk splints. All appeared comfortable. In each instance, the knee had been put up in about 15 to 20 degrees of flexion, and elastic cords had been used to secure traction. It was pointed out that the use of this splint achieves an enormous saving in plaster. The plaster splint requires four 6-inch rolls of plaster for the posterior component and another four 6-inch rolls for the outside casing which grips the wide bars of the Thomas splint.

At the 44th Evacuation Hospital, the chief of the orthopedic section had had a good deal of experience with the Tobruk splint and much preferred the plaster spica. If the patient's general physical condition at the end of debridement in a compound fracture of the femur did not warrant the application of a spica, it was his opinion that a Thomas splint with adhesive-plaster traction should be employed until there was sufficient improvement to permit the application of the plaster spica.

At ADSEC Headquarters, it was reported that a detailed investigation was being conducted by the consultant in orthopedic surgery for the Ninth United States Army on the advantages and disadvantages of the Tobruk splint in compound fractures of the femur. It was hoped that this report would be

available at the next meeting of the Anglo-American consultants. The study was to be correlated with the senior consultant in orthopedic surgery. It was felt that this investigation (p. 110) would be of great value.

The Tobruk splints observed in the various hospitals were usually well applied, and the patients put up in them were comfortable. Their chief advantage in a busy evacuation hospital was that they could be applied in 12 to 15 minutes. An orthopedic surgeon who was thoroughly familiar with plaster techniques could, however, apply an adequate plaster-of-paris spica almost as rapidly and was therefore much more likely to use it. It was the consultant's opinion that the chief field of usefulness of the Tobruk splint was in certain selected fractures involving the supracondyloid region of the femur.

Trenchfoot

On this tour, a considerable amount of trenchfoot was observed and discussed, though cold injury was not a true orthopedic problem. The following experiences were typical:

At the 41st Evacuation Hospital, trenchfoot was of a mild type, and very few severe cases had been seen. Patients were treated on the medical service. The observation was made that anybody with a sore foot was now supposed to have trenchfoot. About 50 percent of the patients with this diagnosis had minimal physical signs, or none at all, but it was believed that not more than 10 percent of them were in any sense malingerers.

At the 77th Evacuation Hospital, about 100 patients with trenchfoot had been received daily over a period of several days some 3 weeks ago. At the present time, relatively few were being received. The unit from which these men came had not been properly instructed in the care of the feet. It was reported that some soldiers who had fought in Holland had worn overshoes over felt slippers and two pairs of socks and had escaped cold injury entirely; this arrangement kept their feet warm and provided room for adequate movement of the toes. The chief of the surgical service at this hospital felt that exercise must be taken and constriction must be avoided if this crippling disability was to be prevented.

At the 102d Evacuation Hospital, 85 of 119 surgical patients recently received had come in with the diagnosis of trenchfoot. They were chiefly from the 28th Division where, they said, little or no instruction was given about the care of the feet necessary to prevent this condition.

The professional services of the Ninth United States Army were extremely foot conscious. The chief of the Preventive Medicine Division had had an effective poster made, embodying the salient etiologic features. Immobilization and constriction of the extremities were thought to be the chief causes. The term "trenchfoot" was thought to be a misnomer. In large, roomy trenches the men could move about freely, and the condition seldom occurred. In foxholes they could not, and "foxhole foot" was suggested as a much better term.

A total of 511 patients with this condition had been received from the 84th Division, within 12 days. The great majority of these soldiers came from a single infantry regiment which had bogged down in a swamp, where it was pinned down by gunfire and unable to move. Each patient admitted with trenchfoot had to fill out a questionnaire on the details of the injury.

At Headquarters, First United States Army, the subject of trenchfoot was discussed in detail. The 91st Medical Gas Treatment Battalion had been taking care of these cases, the number of which was now decreasing. One company, set aside as a study center, had 70 patients. Another had 200 under treatment. Patients considered convalescent were sent to the 4th Convalescent Hospital for a 10-day period. The total holding time for this Army area was only 10 days, but for purposes of study some patients had been held as long as 21 days.

All patients who presented discoloration, marked edema, or associated injuries of the feet were evacuated as promptly as possible. The possibility of a psychic factor had been recognized promptly, and it was now the policy to hold these men in corps and division areas in the absence of positive physical findings. Buerger's exercises were instituted at the walking stage, with unilateral sympathetic block, but this regimen seemed of no help in the earlier stages. The first patients treated were now returning to duty and would be observed carefully for possible recurrences.

It was clearly recognized that control of trenchfoot is a command function, and medical officers were investigating how control was being carried out.

Amputations

Amputation stumps were generally in well-applied transportation plaster of paris with skin traction obtained by stockinet and elastic attached to a wire ladder loop incorporated in the plaster.

At the 44th Evacuation Hospital, many casualties had been received after injuries from land mines and had to be treated by amputation. It was observed, however, that if a good covering of snow was on the ground, traumatic amputation did not occur, as it usually did when the ground was bare and there was a direct hit on either the foot or the leg, which was totally or partially torn off.

Tour of Field Hospital

The 8th Field Hospital was visited 3 December. At this time it was located near an airfield in the Seine Base Section and was serving as a holding unit. It had 750 patients, all to be transported to the United Kingdom. Patients arrived from 5 to 7 days after wounding, and the average holding time was 24 to 36 hours, with a maximum of 5 days. The order of priority for evacuation was head wounds and maxillofacial injuries, chest wounds with hemopneumothorax, multiple fractures of the long bones, and amputations.

Up to 1,400 litter cases had recently been evacuated from this hospital in a single day, November having been a better month for air evacuation than

October. The weather was the one great stumbling block. Approximately 1 in every 500 litter patients was returned to the receiving hospital as non-evacuatable. This was an excellent record.

Approximately 150 patients were observed in the 2 wards visited. They were all in good condition, and the plaster work seen was on the whole excellent.

Fractures of the femur were for the most part received in plaster-of-paris spicas. Only a few were in Tobruk splints. The officers stated that plaster techniques had greatly improved and that very few casts now had to be changed.

Practically no orthopedic surgery had been necessary at this hospital. No gangrene had developed and no amputations had been required.

Four patients were encountered who were improperly prepared for transportation:

1. A staff sergeant with a compound comminuted fracture of the first left metacarpal, caused by a gunshot wound, had had pulp traction applied at a field hospital 22 November. On 24 November, he was evacuated to the 203d General Hospital, where he remained until 26 November. His wound was inspected, and pulp traction was continued. It was also continued when he reached the 8th Field Hospital.

2. Another staff sergeant, who was wounded in action by a land mine, also sustained a fracture of the second metacarpal. He was evacuated through the 111th Evacuation Hospital to the 76th General Hospital, where pulp traction was applied through the soft tissue of the distal phalanx of the second finger. He was then transferred to the 40th General Hospital, where he remained until 2 December. He was still in traction when he was seen at the 8th Field Hospital 3 December.

The senior consultant suggested that pulp traction be discontinued at once in both of these cases. Neither patient up to this time had showed any untoward effects from it, but the danger of ulceration and of loss of fingertips had been established by experience, and pulp traction had been forbidden in the most recent Circular Letter (No. 131, 8 November 1944),¹ Office of the Chief Surgeon, European Theater of Operations. It was suggested that this matter be called to the attention of the officers responsible for instituting this kind of traction, and that its further use be avoided.

3. A private wounded 28 November received a compound comminuted fracture of the right tibia, a perforating wound of the right leg, and cold injuries of both feet. Circular plaster of paris was applied at the 45th Evacuation Hospital, but the cast was not split through to the skin and was not spread. Thereafter, the patient was passed through the 46th Field Hospital and through a general hospital in Paris, the number of which was not available. When the patient was seen in the 8th Field Hospital by the senior consultant in orthopedic surgery, he complained of considerable discomfort. Examination revealed that the circulation in the foot was apparently adequate, but that the plaster was too snug.

¹ See appendix A, p. 325.

4. Another private, wounded 17 November, sustained a penetrating wound of the urinary bladder, penetrating wounds of both legs with compound comminuted fractures of both patellas and the lateral condyle of the right femur, a penetrating wound of the right buttock, and a penetrating wound of the right arm, with a compound comminuted fracture of the right radius and ulna. Circular plaster was applied to the left leg at the 51st Field Hospital, a Tobruk splint was applied to the right leg, and a circular cast was applied to the right arm. The splints on both legs were incompletely split and were not spread at all. The man arrived at the 48th General Hospital on 30 November and at the 8th Field Hospital on 3 December. When he was seen by the consultant shortly afterward, he was complaining of pain around both ankles.

These two patients were both examples of failure to carry out the specific instructions from the Office of the Chief Surgeon that circular plaster casts should be split to the skin or to the dressing overlying the wound and should then be spread.² It was suggested that the plaster in both these cases be split at once and that the officers responsible for its application be notified of their error and requested in the future to follow instructions about splitting and spreading primary circular plaster-of-paris casts.

² See footnote 1, p. 33.

CHAPTER III

Training of Personnel

General Considerations

Almost 2 years were spent in the United Kingdom in preparation for the care of casualties with bone and joint injuries expected in the campaigns to be conducted on the Continent. When the time came, these campaigns lasted only 11 months. Orthopedic care began, of course, with the arrival of the first troops in the United Kingdom in 1942, and the period between 6 June 1944 and 7 May 1945 was the summation of all the previous efforts.

This preparation had to be accomplished in the face of certain difficulties not apparent in the bare statement of the facts:

1. The period of training was not the same for all surgeons. Only a few hospitals were in Great Britain for the full 2-year period mentioned. Some arrived shortly before D-day and had only a few weeks of training; many others arrived long after D-day.

2. The training of physicians in special skills is difficult to accomplish in a limited period of time, particularly when they have had no previous surgical experience at all, though in times of great need there is no choice but to rise to the emergency. The results of the training of orthopedic surgeons before D-day were extremely good. Many medical officers who had had little or no surgical experience and who acted as ward officers in the first hospitals which arrived in the theater served with usefulness and even distinction as chiefs of orthopedic sections in hospitals which arrived later. This was a result of the training they received during the period of preparation.

3. A major problem was that even the most experienced surgeons in the theater had had, for the most part, no experience at all in the mass management of battle casualties with injuries of the bones and joints. The senior consultant in orthopedic surgery is a case in point. He had had a wide civilian experience. From previous experience in the Zone of Interior, he had had extensive experience in accidents which occur in training for combat. He had served overseas in World War I, though, as a matter of fact, this experience was less useful than his civilian and Zone of Interior experience. He had had, however, no experience at all in the mass management of casualties with bone and joint injuries as they were to be encountered in World War II. Furthermore, he assumed his duties in the United Kingdom Base only a few weeks before D-day, and he was therefore additionally handicapped by lack of knowledge of the location and personnel of the various hospitals which had been set up in preparation for the invasion.

Methods of Training

Medical Officers

The Medical Field Service School organized at Shrivenham, Berkshire, England, in 1943 was staffed by instructors who were handicapped, as already noted, by their own lack of battle experience. Instruction in the care of battle casualties and in plaster techniques was therefore, as a matter of necessity, chiefly theoretic. Medical officers who attended the courses came from evacuation and field hospitals and from divisional medical units.

No formal Army program of orthopedic training was instituted, but each unit was provided with a full file of theater circular letters and administrative memoranda, Army medical circulars, and the material in the Manual of Therapy¹ prepared shortly before D-day. It was recommended that all of this material be used for instructional purposes.

As far as was practical, the large battle experience which the British had had and the techniques of care which they had developed were disseminated to American medical officers. Opportunities were provided to attend the meetings of the Orthopaedic Section of the Royal Society of Medicine, the semiannual meetings of the British Orthopaedic Association, and the monthly Inter-Allied medical meetings. Every 3 months, Sir R. Watson-Jones, Royal Air Force consultant in orthopaedics, and Air Vice-Commodore Osmond-Clarke conducted 5-day courses of instruction in fractures in the hospitals in and about London. These were enthusiastically attended by as many of the younger orthopedic surgeons in the American forces as could be enrolled.

Some American surgeons had the opportunity of working in British hospitals. British arrangements for the care of their wounded differed materially from those in the United States Army. The care of casualties was a function of the Emergency Medical Service, a civilian organization manned by civilian physicians. In England and Scotland, only a few Army, Navy, and Air Force hospitals were operated as service hospitals. The wounded British soldier, sailor, or airman was cared for by the medical corps of his special branch of service as long as he was overseas. As soon as he reached the British Isles, his care reverted to civilian physicians. This particular arrangement was made at the outbreak of hostilities because it was expected that there would be an enormous number of civilian casualties incidental to bombings. It also necessitated the withdrawal of far fewer physicians from civil life, in proportion to the population and the total available supply of physicians, than in the United States. Although the number of civilian casualties was smaller than had been expected, British civilian hospitals were generally understaffed and their personnel was generally overworked. Early in the war, therefore, a number of United States orthopedic surgeons in the European theater had the opportunity of participat-

¹ A proposed revision of the orthopedic section of the Manual of Therapy, in the light of the European experience, was drafted in June 1945 but was not officially published because the war in the Pacific ended within the next few weeks. It appears as an appendix in this volume (appendix B).

ing in the care of the British civilian population after bombing. This provided greatly needed help for the British, established invaluable contacts between American and British orthopedic surgeons, and gave American orthopedic surgeons excellent experience in the management of what were, in effect, battle casualties.

The response of untrained and inexperienced surgeons to such rapid training in orthopedic surgery was, as might have been expected, extremely uneven. Many instructors remarked that poor surgeons who worked with orthopedic surgeons of superior ability often failed to improve their techniques in either orthopedic surgery or the application of plaster, while poor surgeons continued to do poor debridements no matter what their specialty or training might be. Men in this group were inclined to excuse their inefficient performance on the ground that they were not trained orthopedic surgeons.

A fundamentally good surgeon, however, while he might do unsatisfactory work for a brief time, when once he realized the principles of debridement and the application of plaster, immediately improved his technique. There were many illustrations of the fact that a well-trained general surgeon can readily adapt himself to the needs of a specialty in which he has had no previous experience. One general surgeon, for instance, although he had never before seen the Smith-Petersen approach to the hip joint, once it had been described to him, extracted a foreign body from the joint and performed an extensive debridement as competently as if he had done the operation a dozen times.

One of the greatest difficulties with new surgeons who were without military experience or previous training was making them understand the fundamental principles of debridement. There were two chief errors, (1) a tendency to excise skin and superficial layers of tissue, and (2) a failure to make bold incisions through the fascial planes, so that the deeper layers of tissue could be adequately debrided. A wound treated in this superficial manner was seldom ready for closure within 5 to 7 days after wounding. Wound closure at that time was the objective of reparative surgery. With proper supervision, these errors could be corrected, but they would have been corrected more rapidly if the consultant system had been somewhat more flexible.

It was an excellent plan, when possible, to attach officer and enlisted personnel from new hospitals to older hospitals for instruction before they were permitted to receive patients. Another excellent plan was to attach a small number of officer, nurse, and enlisted personnel to an older hospital for a few weeks in exchange for a like number of personnel from a new hospital. In this manner, it was possible for the group from the older hospital to supervise and train the staff at the new hospital, while at the same time key personnel from the new hospital received intensive training at the old hospital.

Still another plan was to attach one or two teams from an auxiliary surgical group to each new hospital for the first few weeks after it opened. Finally, arrangements could sometimes be made with nearby established hospitals for personnel from new units to visit them frequently, observe the wounded as they arrived, and study the techniques of surgical management. The plans just

described were very frequently used in evacuation hospitals as they arrived on the Continent.

Nursing Care

Nursing care of bone and joint casualties was of high quality, though the policy of certain hospital chief nurses of rotating nurses through all services in the hospitals was regrettable. Orthopedic surgeons, like all other specialists, frequently complained that few nurses remained on their sections long enough to become really proficient in the care of these casualties. Repeated requests were made for key nurses and key enlisted men to be given permanent assignments, without rotation, and in some hospitals this practice was carried out as well as circumstances permitted. In others, the recommendations were ignored.

Enlisted men who served as ward attendants had been carefully trained in their duties before D-day. A few had had additional training at the Derwin Training School for cripples in England. The more instruction these men received, the better, naturally, was their work. Some of them became extremely proficient in setting up traction and in caring for patients immobilized in plaster.

Plaster Technicians

Plaster of paris was used so extensively in bone and joint injuries, both in evacuation and in general hospitals, that surgeons and ward officers could not possibly take care of it themselves. It was always desirable for the surgeon to apply the plaster of paris after operation, but frequently this was impossible, and it had to be applied by enlisted technicians under his supervision. After several months' experience in this work, these enlisted men became extremely proficient and were able to change casts, as well as apply them, under the supervision of medical officers, thus saving a great deal of professional time and effort for other purposes.

The ideal arrangement was the assignment of technicians specifically for these duties, but such arrangements were often accomplished after considerable delay and much argument. In one general hospital, for instance, which served as a transit hospital at D-day, the orthopedic staff consisted of a chief of section, an assistant chief whose only orthopedic experience was a year in the Army, and three ward officers with no orthopedic training at all. The enlisted assistants were supposed to be any of the several men assigned to the operating room who happened to be available when the need for plaster arose. It was with the greatest reluctance that an enlisted man was finally assigned for full-time duty in the plaster room and was given an assistant who could be called upon when necessary. This reluctance soon disappeared before the weight of facts, and eventually five men were assigned full time to plaster duty in this particular hospital.

The most efficient arrangement was to assign 5 enlisted men to the plaster room—3 to be on duty from 7 a. m. to 7 p. m. and 2 to be on duty from 2 p. m.

until the day's work was completed. It was sometimes necessary for them to remain on duty until 7 a. m. This arrangement permitted an overlap of personnel during the afternoon, when the work was likely to be heaviest, and provided technicians around the clock. It also established a good working relationship between the day and night hospital staff.

When men assigned to plaster work were not applying casts or changing them, they prepared supplies and kept abreast of the daily heavy needs. The best plan was to put a single man in charge of the preparation of plaster bandages, though when casualties were heavy this arrangement was not always practical. Enlisted men assigned to plaster work frequently also took care of the braceshop and the preparation of external appliances for shoes. This was not as desirable an arrangement as having trained craftsmen in charge of this work, but it served the purpose when they were not available.

Professional Conferences

It was strongly recommended that each hospital set up some type of professional meeting or conference at which all orthopedic problems could be discussed and policies of management could be clarified and modified. Theoretically, and under the conditions which existed, there was no better way to improve the work of general surgeons and of others not trained in orthopedic surgery. The presentation and discussion of special cases were particularly valuable. This method, however, was not as practical as it might seem on the surface. Before D-day, when there was ample time to hold such meetings, the orthopedic material was not available. After D-day, when casualties were heavy and surgeons often had to work on long day or night shifts and sometimes around the clock, there was no time for such meetings. Finally, when the hospital was not receiving patients, it was difficult to arouse interest in any sort of professional meeting among medical officers who were tired and needed rest.

Between D-day and V-E Day, three formal conferences were held with the British and Canadian consultant staffs, and similar conferences were held with the French and Belgian medical services. The personnel in attendance included both civilian and military authorities of high rank. There was always, in addition to formal exchanges, free interchange of ideas and professional techniques between the American and other Allied forces, with great advantage to both.

A meeting of the junior consultants in orthopedic surgery in the United Kingdom was held in London in December 1944, and a second meeting was held in June 1945. A meeting of the junior consultants serving on the Continent was held in Paris in June 1945.

These meetings, like all the others, were in effect training sessions. Clinical, administrative, and associated problems were discussed and clarified, and the exchange of experiences proved extremely profitable.

CHAPTER IV

Hospital Facilities and Orthopedic Equipment

Hospital Facilities

Bed capacity.—Orthopedic sections of general and station hospitals occupied, on the average, about a third of the total bed space. This was in line with realities. Bone and joint injuries constituted from 35 to 40 percent of all battle-incurred injuries and also constituted the major number of nonbattle injuries.

Allotments varied from hospital to hospital, as well as from time to time within the same hospital. The 217th General Hospital, for instance, when it served as a 1,000-bed transit hospital, set aside 4 ward buildings, each containing 40 beds, for casualties with bone and joint injuries. When it moved to the Continent, it occupied the Hôpital de la Pitié in Paris, a large city hospital with a capacity of about 1,500 beds. A surgical pavilion contained 6 large operating rooms and other facilities. The orthopedic section was assigned the second floors of each of 2 buildings, each floor consisting of 8 wards. The total bed assignment was 403, and this number could be expanded to 550 during periods of stress, by placing the cots in corridors and elsewhere.

At Commercy, France, the 50th General Hospital occupied an old 3-story barracks, in which it could house as many as 460 orthopedic patients at one time.

Tented hospitals sometimes had to serve as fixed hospitals on the Continent, and during the spring, summer, and early fall, these arrangements were generally satisfactory. During the incredible mud of late fall and early winter, buildings with solid floors and modern heating were distinctly better for men with bone and joint injuries, even though it required a longer haul to get them there.

Tented hospitals, while satisfactory for this purpose, did not lend themselves as well as conventional buildings to the definitive treatment of fractures of the long bones, which require Balkan frames for satisfactory skeletal traction. As far as possible, their use was limited to prisoners of war.

The bed capacity of a tent was about half that of an ordinary ward, and there were several other disadvantages. One was the difficulty of moving the portable X-ray machine. Another was the darkness of the tent, which required artificial light around the clock. This made for a monotonous existence and had a depressing effect on the soldiers' morale. Nonetheless, when it was necessary, a Balkan frame could be shortened at the head of the bed to meet the sloping tent roof, and concrete floors could be provided to give stability for both the fracture setup and the making of roentgenograms.

Location of space.—The location of the space assigned to orthopedic surgery was not always convenient, especially in hospitals in which it was the practice to locate septic wards immediately adjacent to the operating rooms. The orthopedic wards were often at a considerable distance from the operating facilities and from the X-ray facilities.

Sometimes these inconveniences were unavoidable. At other times they could be attributed to failure to grasp the realities of military surgery. Some commanding officers and some chiefs of surgical sections were slow to appreciate the magnitude of the trauma sustained by the extremities and spine by men in training, to say nothing of the greatly increased volume of bone and joint injuries which could be expected when combat began. As time passed and lessons were learned by experience, most of these difficulties were smoothed out, though until the end of the war some chiefs of surgical services did not realize the importance of segregating fractures from general surgical cases and placing them in the charge of special personnel.

It was always a great convenience to have the plaster room located near the operating room, though this advantage was canceled out when its supervision was put into the hands of operating-room personnel rather than those of trained orthopedic personnel.

When orthopedic facilities were set up in buildings which had not been constructed primarily for hospital purposes or in which space had not been adapted and fitted for orthopedic use, plaster facilities were frequently inadequate. The experience of the 217th General Hospital is an illustration. When it served as a transit hospital after D-day, the plaster room, which measured 10 by 20 feet, was off the main operating room and had been set up for minor surgical procedures. It therefore had no plaster sink, and the water supply and drainage were both entirely inadequate. Storage space was also insufficient, and it was impossible to provide a backlog of plaster bandages and other supplies.

Equipment and Supplies

United Kingdom hospitals.—Most hospitals and hospital centers in the United Kingdom were furnished with a combination of British and American orthopedic supplies. The 68th General Hospital, for instance, was located close to a British orthopedic hospital and secured from it many items not obtainable in United States Army issue. At the 217th General Hospital, when it served as a 1,000-bed transit hospital, all orthopedic wards were equipped with British fracture beds with segmented mattresses and with single bar overhead frames. On the other hand, some centers, such as the 802d Center in the Blandford area, England, had full United States Army table-of-equipment supplies, including orthopedic beds, Balkan frames, fracture tables, full supplies of surgical instruments, and many nonstandardized items. Work in such a center was naturally facilitated, but it was still possible to do excellent orthopedic work with less complete equipment.

Numerous desirable orthopedic items were missing from the standard equipment of general hospitals, such as curved osteotomes, stainless-steel brads, bone nails, bone punches, stainless-steel rules, and suture wire for tendon repair. The drill points supplied did not contain a sufficient variety of small points. Metal hammers of suitable weight were not available, and the wooden hammers provided did not stand up under repeated sterilization. Smith-Petersen nails were available but only in sizes smaller than those generally used. Nails measuring 4, 4¼, 4½, 4¾, and 5 inches should also have been provided.

These deficiencies, as in the case of larger items of equipment, did not prevent the performance of high-quality orthopedic work. The items listed were needed only in general hospitals in the United Kingdom Base, where definitive orthopedic surgery was done. Medical supply did an extremely good job throughout the war in furnishing promptly all reasonable and necessary supplies. It would be unreasonable to expect many of the special items listed to be carried as standard supply items in an overseas theater.

There were occasional instances of insufficient supplies and procrastination before D-day. In one hospital in the United Kingdom, for instance, it took constant prodding of the medical-supply officer to obtain anything like the proper amount of orthopedic supplies. Eventually, 1,500 rolls of sheet wadding and 1,000 rolls of plaster bandage were obtained, but ambulatory patients had to be used to help the personnel of the plaster room get the supplies ready in time. Enough orthopedic instruments were finally obtained after a hunt through medical supplies, but the Scanlon Morris fracture table was not obtained until the day after D-day. This was, however, an isolated instance. For the most part, supplies were ample for the work which had to be done. Col. (later Maj. Gen.) S. B. Hays, MC, after his assignment as Chief, Supply Division, Office of the Theater Chief Surgeon, did a splendid job of procuring and distributing needed orthopedic supplies throughout the war in Europe.

Supply difficulties sometimes arose when hospitals were shifted from their assigned function, as was sometimes necessary just after D-day. The 68th General Hospital, for instance, did the work of an evacuation hospital for a number of weeks. A general hospital is equipped to handle only a certain number of surgical patients and is not equipped for unlimited emergency surgery. When the population in this hospital suddenly became 90-percent surgical and most of the operations were urgent, there were not sufficient sterile supplies and not enough laundry facilities to take care of the large turnover in the operating room. As a result, some debridements had to be delayed longer than was desirable, though the results indicated that very little real harm had been done by the prolonged timelag.

Hospitals on the Continent.—The equipment of fixed hospitals on the Continent, while usually adequate, was seldom equal to that of hospitals in the United Kingdom. Hospitals in the British Isles almost invariably had modern American fracture tables. Those which crossed the channel had only the Army type of portable fracture table, which left much to be desired.

Every hospital on the Continent required a multiple supply of fracture tables, and all of them were frequently in use at the same time for the application of plaster. It was uncommon, in an evacuation hospital, for at least one fracture table not to be in continuous use around the clock.

Plaster

The most universally useful roll of plaster was 6 inches wide and 4½ yards long. Plaster reinforcements were made of 5 individual layers of plaster-impregnated crinoline, 6 inches wide and 2 feet long. These were folded in squares and stored in paper wrappings. The most satisfactory mesh was American No. 11 gage crinoline, which corresponded to the British No. 14 gage muslin.

As far as possible, all plaster supplies were kept in dry storage, with the rolls wrapped in paper. Lukewarm water was used for soaking the plaster before it was applied.

Braces and Arch Supports

As a rule, the 1,000-bed general hospitals sent to the European theater had few or no facilities for making braces, arch supports, and minor adjustments to shoes. With few exceptions, patients who required braces had to be returned to the Zone of Interior.

At first, the provisions for arch supports and for making minor adjustments to shoes were extremely haphazard. Before D-day, there was no provision at all in Army general hospitals for arch supports, Army issue, which a few non-combatant soldiers required.

These supports were chiefly for the use of the troops in the London area. Combat troops seldom required them; a soldier who needed one, in fact, did not belong in a combat unit. A considerable number of these supports, which were satisfactory and well made, were obtained by purchase from British civilian sources. Each transaction was an individual one and was usually conducted through one of the United States dispensaries in London. This did not wholly solve the problem, for shortages of leather and labor made it impossible to rely entirely upon the British for these and other orthopedic supplies. An occasional hospital solved the problem as did the 68th General Hospital, which took part of the wards originally assigned to venereal disease and converted the space into four excellent plaster rooms, with an adjoining shoe and brace shop. This hospital could thus care for orthopedic shoe prescriptions and for arch corrections on the post without delay.

The disciplinary center at Shepton Mallett, England, had among its officers a young man who in civil life had run a successful chain of shoe-repair shops in Florida. It was possible to work out with this officer a plan for utilizing labor of imprisoned United States soldiers to repair shoes and make prescribed adjustments. As far as shoe repairs were concerned, this arrangement was fairly satisfactory. On the other hand, the arch supports provided on pre-

scription left much to be desired. An incidental result of this plan was the good effect on the morale of the prisoners, through their feeling that, in spite of their incarceration, they were still contributing to the war effort.

While hospitals were static in the United Kingdom and the number of patients was relatively small, these improvised arrangements worked out satisfactorily. Later, as the number of troops increased and soldiers were moved to the Continent and widely dispersed, other and more elaborate plans had to be worked out. Prefabricated leather and sponge-rubber arch supports began to arrive in the theater and became available through Army medical supply channels early in January 1945. At first, only the 10th General Dispensary in London and the 9th General Dispensary in Paris were authorized to stock these items. As supplies increased, distribution was widened, and eventually certain authorized hospitals and general dispensaries stocked specified levels which could be replaced on requisition. When it was practical, patients were sent to these hospitals for fitting. When it was not, supports were requisitioned. Final arrangements for orthopedic corrective devices were not made until the spring of 1945, and it is not known how effective they were, in view of the constant deployment and shifting of units after V-E Day. If there had been any degree of stability, the new arrangements should have been satisfactory.

Whenever possible, quartermaster shoe-repair units and local shoemakers were used to make minor shoe adjustments. A special graphic, bilingual order form for French shoemakers was devised by the Chief Quartermaster, European Theater of Operations, and the senior consultant in orthopedic surgery and proved very satisfactory.

Improvised Equipment

At a number of the hospitals in the European Theater of Operations, a good deal of ingenuity was shown in the construction of special devices, frequently out of salvaged material, for the care of casualties with bone and joint injuries. Several devices of this kind were made and employed at the 22d General Hospital in the 802d Hospital Center by Lt. Col. Thomas B. Quigley, MC, Maj. Marshall R. Urist, MC, and Capt. Lincoln Ries, MC.

Plaster traction splint.—The plaster traction splint for compound comminuted fractures of the tibia and fibula was devised at the 22d General Hospital in Blandford, England, and tested there and at the 97th General Hospital in England and on the Continent, between May 1944 and December 1945. It was constructed and employed as follows (figs. 2 through 6):

A plaster cylinder, padded with felt in the upper thigh and the popliteal and malleolar regions, was applied from the groin to the ankle while the knee and hip were flexed 45 degrees. U-shaped wire hoops, fashioned from No. 12 iron wire or any other available metal, were incorporated in the plaster at the mid-thigh and the malleolus in such a manner that the closed portion encircled the lateral and posterior aspects of the leg (figs. 2 and 3). Two similar wire hoops, or a single heavier metal hoop, were incorporated in the same manner in the

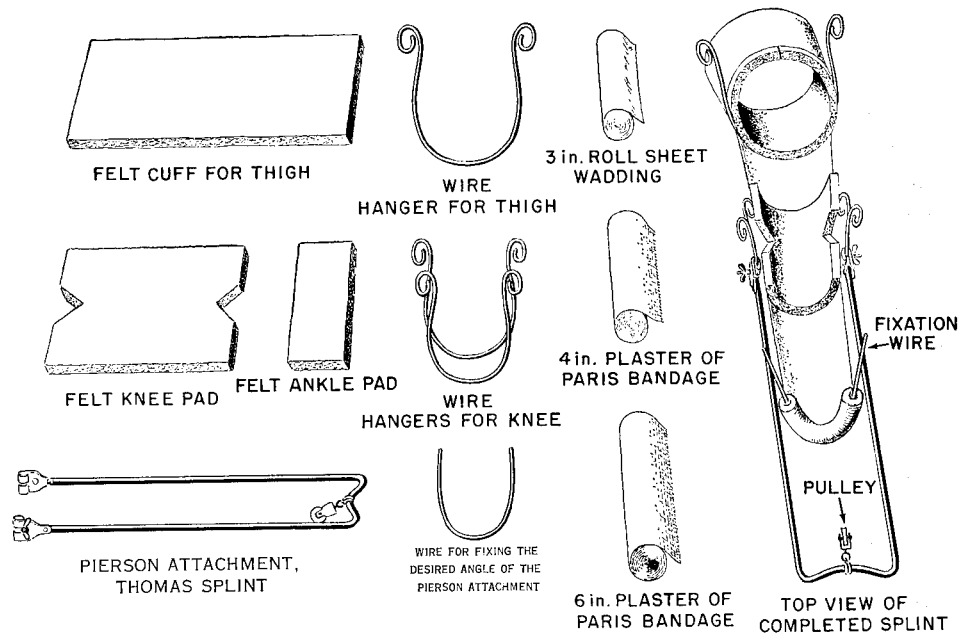


FIGURE 2.—Materials required for construction of plaster traction splint for compound fractures of tibia and fibula with interior view, from above, of assembled splint. They include:

Four pieces of heavy wire, $\frac{1}{8}$ -inch gage, each 20 inches long, bent into the shape of a U, to fit about the posterior aspect of the cast at, respectively, the middle third of the thigh, the tibial tubercle, and the leg, 1 inch above the ankle joint. One or two wires were used at the knee, to provide a strong fitting for the Pierson attachment. The ends of the wires were turned into loops, so that they could serve as hangers for suspending the completed splint in a Balkan frame.

Three felt pads, suitably cut to encircle the upper third of the thigh under the plaster cuff, to fit the popliteal space and cover the tibial tuberosities, and to fit the posterior aspect of the lower third of the leg.

A standard Army Pierson attachment.

Six rolls of 4-inch plaster-of-paris bandage.

Four rolls of 6-inch plaster-of-paris bandage.

Three rolls of 3-inch sheet wadding.

A Cramer wire ladder splint (fig. 4) used as a frame for the foot support.

plaster at the knee. A Pierson attachment, with a pulley fastened to the cross-bar, was placed over the leg in the sagittal plane and clamped in place to the hoops at the knee (figs. 2 and 3). The ends of the wire at the malleolar level were wound about the Pierson attachment. The anterior portion of the cast was cut away between the open ends of the hoops from the superior pole of the patella to the ankle. If access to soft-tissue wounds was necessary, windows were also cut on the posterior and lateral aspects of the cast.

A suitable weight was attached and traction was applied, with the leg suspended in a Balkan frame (figs. 4 and 5). The foot was supported by a stockinet or moleskin sling fastened to a Cramer wire which was attached to the

long bars of the Pierson attachment. When minor corrections in alignment were necessary, the distal fragment could be moved up to 10 degrees in the sagittal or coronal planes by shifting the pulley from side to side and elevating or lowering the end of the Pierson attachment.

Overhead suspension was continued during the first 2 weeks of healing or as long as nursing care, including the bath and the use of the bedpan, were painful. It was then discontinued, and the patient was allowed more freedom in bed. At the end of 3 to 5 weeks, when movement had ceased to be painful, he could be up in a wheelchair (fig. 6). At the end of 6 weeks, when callus formation was usually adequate and the fracture site had become sufficiently stable, traction was discontinued, and a long leg cast was substituted for the original cast. Ambulation on crutches was then instituted as rapidly as possible.

The efficiency of this plaster traction splint was tested, as already noted, under military circumstances in the 22d United States General Hospital in England and the 97th General Hospital in England and on the Continent between May 1944 and December 1945, on 65 battle-incurred fractures of the tibia and fibula in 63 patients, and in 11 simple and compound comminuted fractures of the same bones which were sustained accidentally.¹ During the early months of this period an approximately equal number of similar fractures, which served, in effect, as a control series, were treated in the Böhler-Braun splint or in the Thomas splint with Pierson attachment. The com-

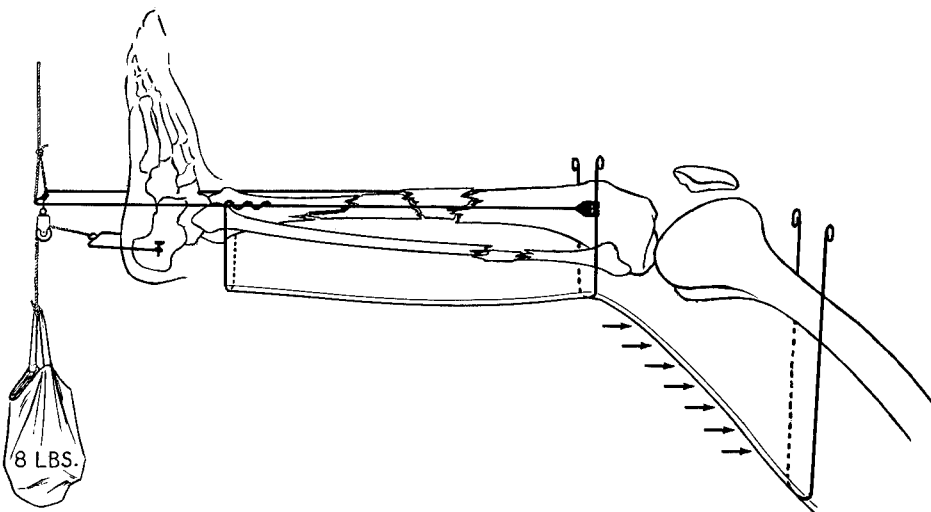
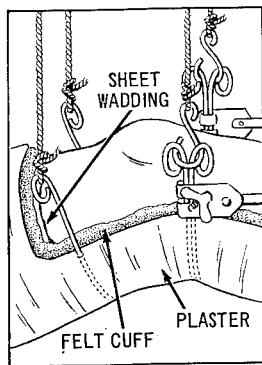
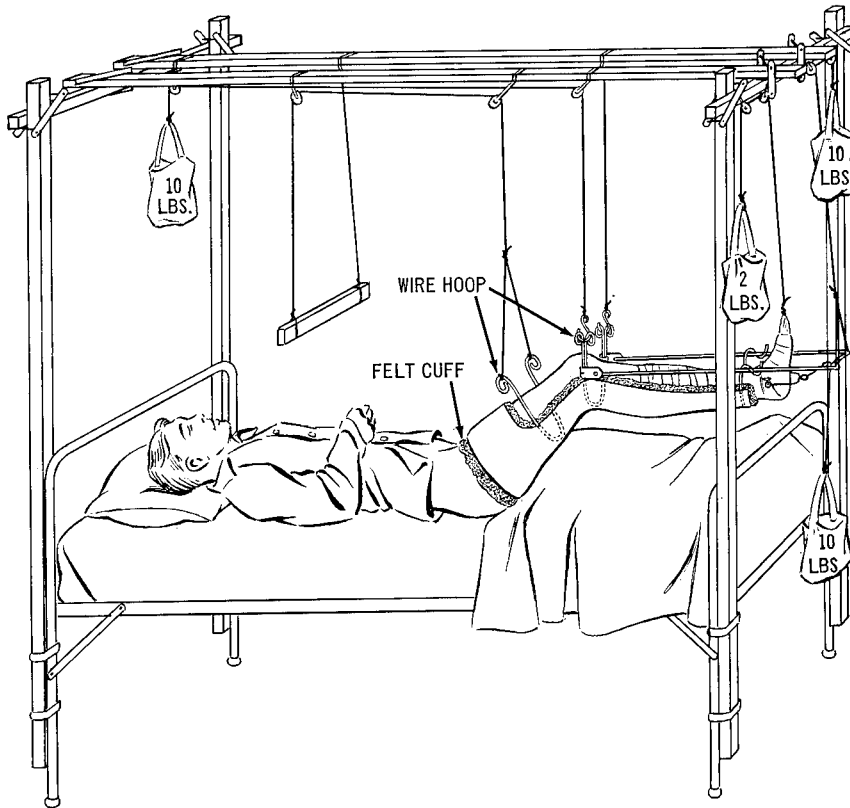
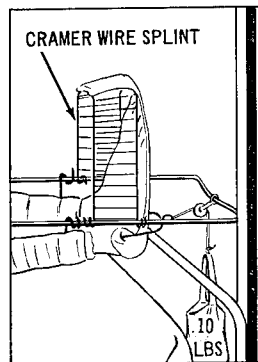


FIGURE 3.—Mechanism of action with splint in traction obtained through Pierson attachment incorporated in long leg plaster cast. The countertraction is mainly from a hoop to which the Pierson attachment is clamped at right angles, and also, but slightly, from the ventral aspect of the cast around the thigh.

¹ Urist, M. R.; Ries, L.; and Quigley, T. B.: A Plaster Traction Splint for Compound Comminuted Fractures of the Tibia and Fibula. *Surgery* 23: 801-805, 1948.



DETAILS OF CONSTRUCTION OF THE KNEE JOINT SECTION



REARRANGEMENT OF THE FOOT SUPPORT RENDERS IMMOBILIZED LEG PORTABLE

FIGURE 4.—Diagrammatic showing of method of suspension of splint and use of trapeze by which patient can lift himself off bed and aid in his own nursing care. Details of construction of the knee-joint section are shown in lower left insert. Method of mobilizing splint and adding foot support is shown in lower right insert.

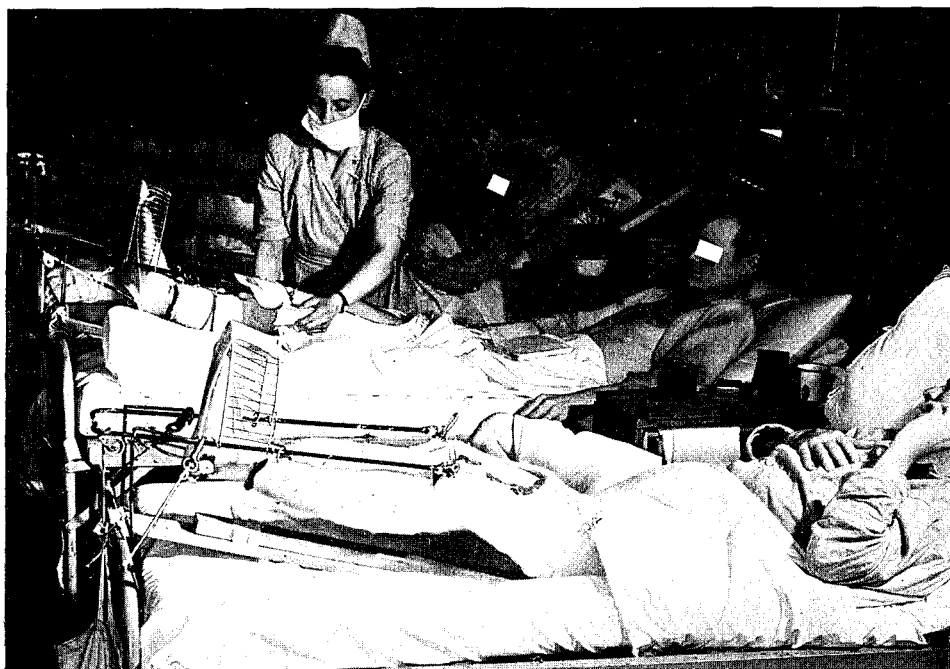


FIGURE 5.—Ward at 22d General Hospital showing battle casualties recently evacuated from Germany put up in plaster traction splints to maintain reduction of compound comminuted fractures of both bones of leg.

ination splint was at first used only tentatively, but as its advantages became apparent it was used more frequently.

The combination splint was found to compare very favorably with the classical traction splint from the standpoint of providing skeletal traction and securing immobilization of the fractures in plaster. It was also found to possess several additional advantages:

1. It furnished better protection for the reduced fractures.
2. It made movement less painful during the early days of healing.
3. It eliminated the uncomfortable counterpressure of the ischial ring of the Thomas splint.
4. It also eliminated the painful play at the fracture site permitted by the Böhler-Braun frame.
5. It did not require the time-consuming, continuous, expert attention necessary when the Thomas splint with Pierson attachment was used. This was a particular advantage when heavy casualties had been received and experienced personnel were in short supply.
6. The combination splint proved of great usefulness in patients received more than 8 to 12 hours after injury, when internal fixation was contraindicated by the risk of infection or when extensively comminuted fractures of the shaft of the tibia would have required undesirable dissection of the whole leg for the safe application of plates and screws.



FIGURE 6.—Patients in traction splints after overhead suspension has been discontinued.

Traction cradle.—At the 22d General Hospital in England, the use of an improved Böhler-Braun type of traction cradle, for the management of battle-incurred undisplaced or incomplete fractures, was found to have several advantages. This cradle permitted easy access to the compounding wound. Alinement of the bone fragments was maintained. The patient could be transported from the ward to the operating room with ease and safety. Most important, the atrophy which was often extreme in limbs treated in plaster was minimized by this type of open immobilization, which permitted exercise of muscles of the uninjured segments of the extremity.

The cradle was fashioned (figs. 7 and 8) of a packing box, into the top of which a trough had been built. The felt padding which covered the top of the box was covered with surgical oiled silk. An adjustable thigh support was attached to the top of the box at one end by means of hinges and a wire stanchion. The angle between the end of the box and the thigh support was adjusted to the plane which provided maximum comfort for the knee; the angle varied with the stature of the patient. The box was supported in bed by a transverse base extension made of basswood splint. A slot in the side of the box allowed for the insertion of an X-ray cassette for portable roentgenograms to be taken.

This cradle proved simple to construct and provided maximum comfort for the patient. It was suitable for use with skeletal or skin traction and also was useful simply as a support for the bony and soft parts of the leg. When it was used with traction, adjustments of the position of the pulley and weight, and the use of a crossbar of the Balkan frame, permitted alinement of minor anteroposterior and mediolateral angulation.

Revolving orthopedic frames.—Compound fractures of the hip joint and pelvis were always, in themselves, serious orthopedic problems. They

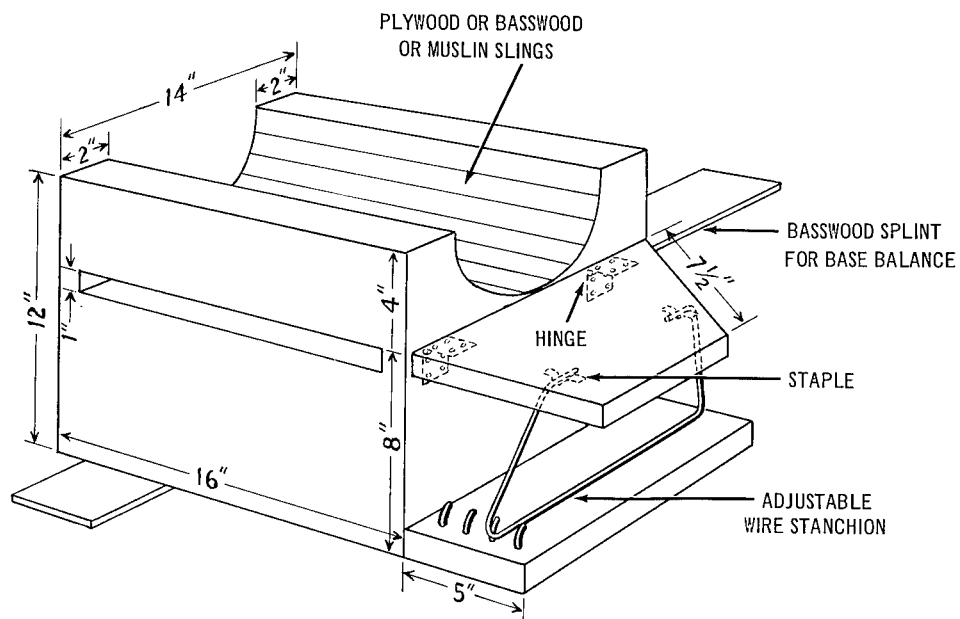


FIGURE 7.—Details of construction of Böhler-Braun type of traction cradle made from ordinary packing box.

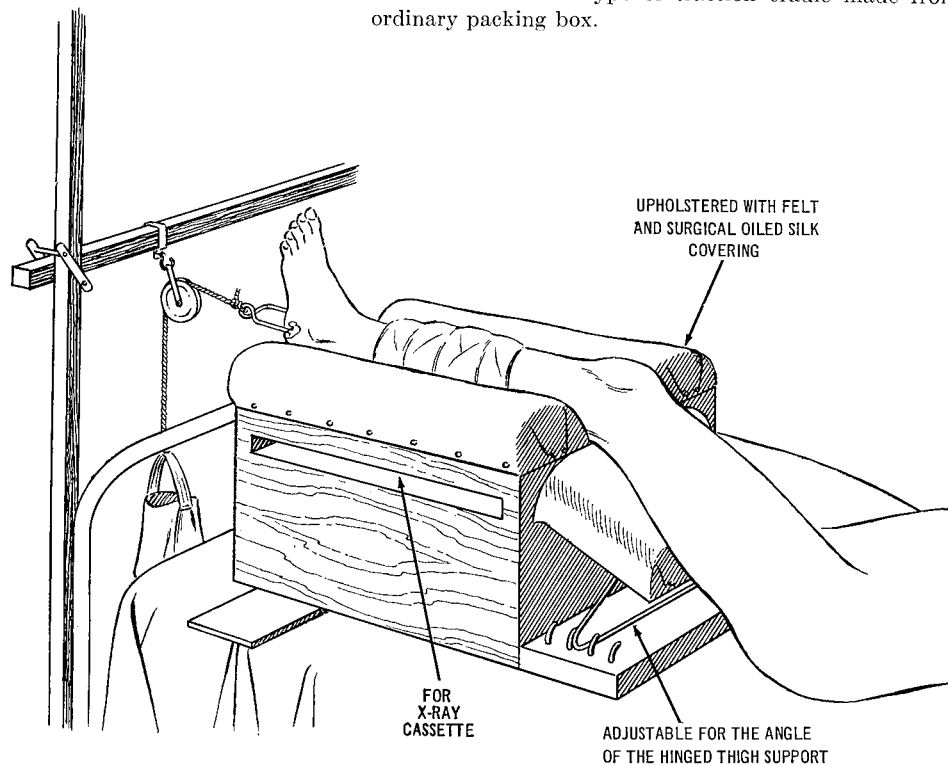


FIGURE 8.—Management of compound fractures of both bones of leg in improvised traction cradle.

were considerably more serious when, as often happened, they were associated with injuries of the genitourinary and gastrointestinal tracts. These injuries required suprapubic cystostomy or colostomy or, occasionally, both, and nursing care was extremely complicated, since the orthopedic injuries required complete immobilization for several months in a plaster-of-paris spica. The most careful precautions often did not prevent the development of decubitus ulcers over the sacrum. The situation was also a difficult one for the physiotherapist.

One solution of these problems at the 22d General Hospital was the construction of a wooden frame (fig. 9), which reenforced the plaster spica or plaster bed and compensated for the weakening caused by the large windows that had to be cut into it, to allow care of the bladder and intestinal wounds. This frame supported the patient on an inclined plane, with his hips above the level of his thorax, a position which eliminated pressure on wounds of the buttocks and sacrum. When he was turned from the recumbent to the lateral or prone position, as was usually done in such cases at hourly intervals, 2 attendants could easily lift and rotate both frame and patient 90 or 180 degrees as was desired (fig. 10).

Other frames devised at the 22d General Hospital not only reenforced fenestrated plaster-of-paris casts but also turned the patient. They could be constructed from the salvage material available at any Army Ordnance depot.² The principles of both the Bradford and the Stryker frame were employed in their construction.

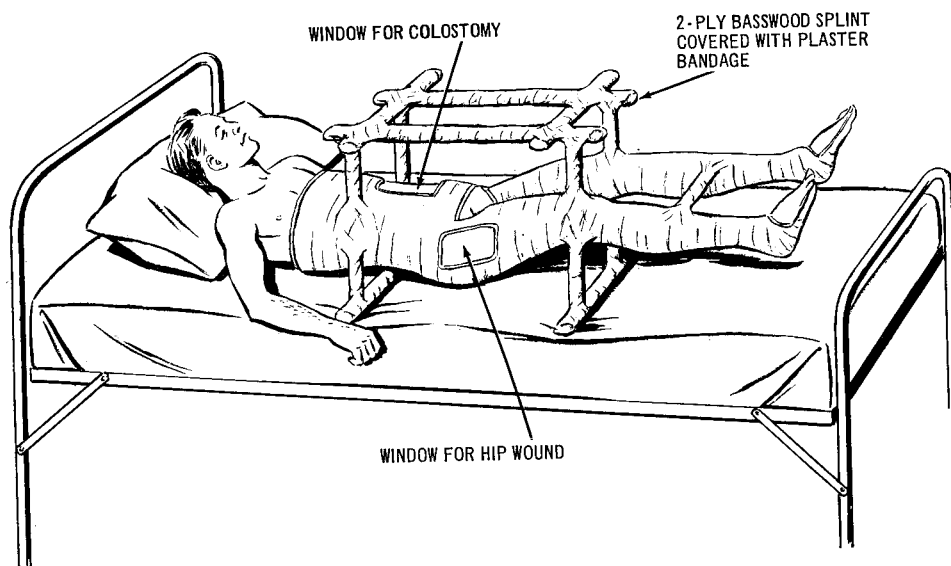


FIGURE 9.—Improvised frame used to suspend and reenforce plaster cast with multiple windows.

² M. Sgt. Robert Ferguson, Army Ordnance Department, assisted in the construction of these frames.

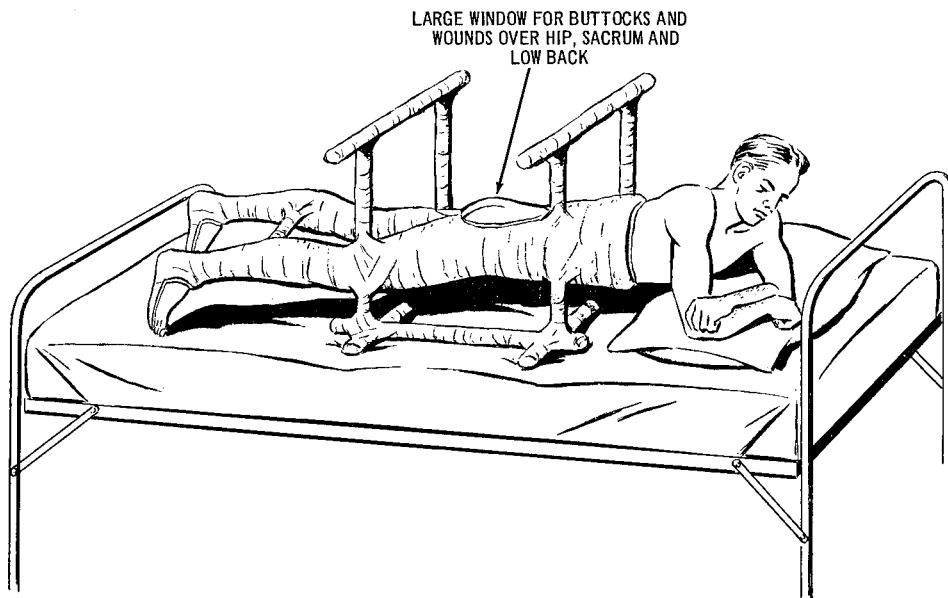


FIGURE 10.—Cast in frame. Patient has been turned to relieve pressure on hip wound and on colostomy.

In one type of revolving Bradford frame, the boiler-plate rims rolled in tracks on ball bearings (fig. 11). One nurse or other attendant could turn the patient 90 or 180 degrees simply by removing the wing nut and turning the hinge-locking device, so that the rims could revolve. When a revolving twin Bradford frame was indicated, an apparatus could be constructed (fig. 12) in which, by means of a worm gear, a turn of 360 degrees could be accomplished. In the frame shown, the self-locking worm gear was made from the elevating mechanism of a salvaged 75-mm. gun which has a 40:1 gear ratio, making a 360-degree turn possible. The rod for the base consisted of $\frac{1}{2}$ -inch by $1\frac{1}{2}$ -inch cold mild steel with a $\frac{3}{4}$ -inch rod for the base. The basswood splint was provided for additional fixation.

Devices such as these greatly facilitated the care of the patient and saved time and effort for nurses and corpsmen, who were almost always overworked. The usefulness of these frames was not limited to compound fractures of the hip joint and pelvis. They were also useful in injuries of the spine, in paraplegia, and in any other condition in which it was necessary to change the position on a regular schedule. The patient was simply sandwiched between two full-length sheets of canvas which were laced to the frames. It was also possible, when plaster of paris was not required, to attach a self-retained extension apparatus to the head rim and equip it with a pulley. When traction was required, this was a convenient method of caring for a patient with a fracture of the cervical spine who was being treated by Crutchfield tongs. One patient was evacuated to the Zone of Interior in a revolving Bradford frame which was bolted to a litter.

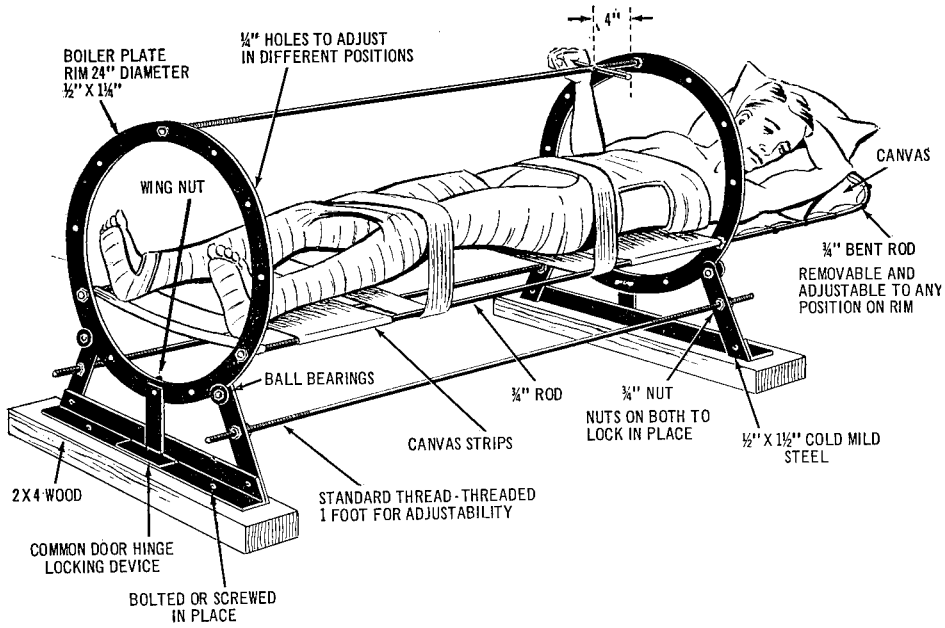


FIGURE 11.—Improved revolving Bradford frame.

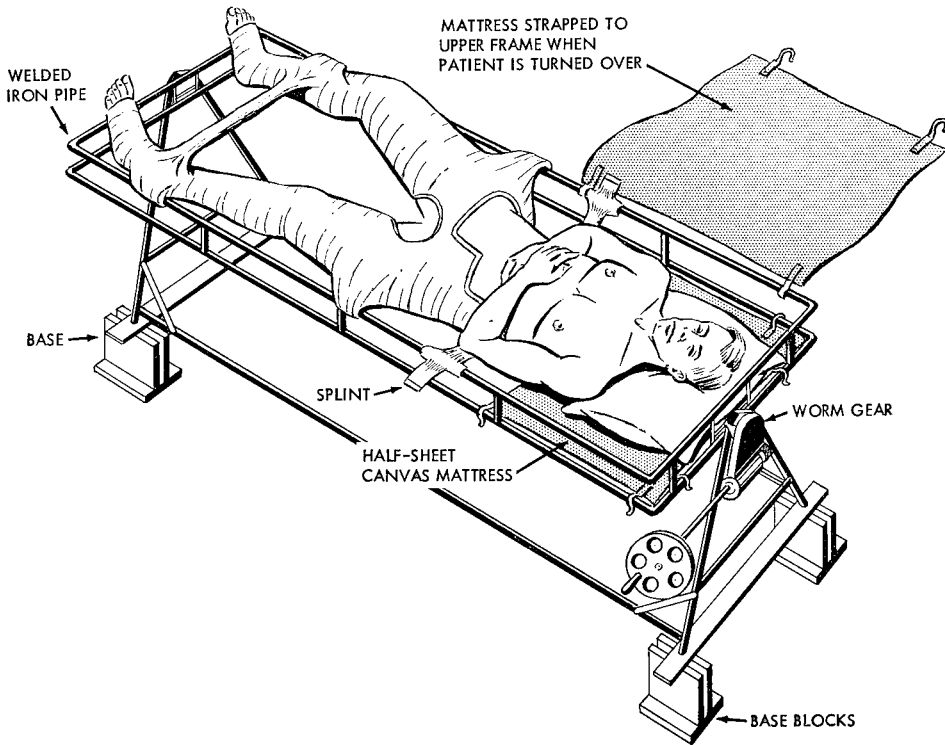


FIGURE 12.—Improved revolving Bradford twin frame with patient in fenestrated bilateral hip spica.

CHAPTER V

Mass Management of Casualties With Bone and Joint Injuries

Methods of mass management of casualties depended upon the type and mission of the particular hospital, the kind of injuries to be handled, and the size of the casualty load, as well as upon the cumulative experience of the staff. In evacuation hospitals, no segregation was attempted, other than the assignment of priorities according to the necessities of the special cases. Patients with severe abdominal, chest, and vascular injuries seldom reached evacuation hospitals. As a rule, they were diverted to field hospitals, to which patients with only bone and joint injuries were seldom sent unless they were in a state of shock or had associated injuries which required immediate attention. The principal function of evacuation hospitals was the performance of initial wound surgery (debridement), which was essentially the same for all patients received in them.

When peak loads were being handled, regardless of the type of hospital, as many operating teams as were available worked at the same time. Surgical efficiency was greatest when shifts could be limited to 12 hours, but in times of stress both temporal and physical limitations frequently had to be exceeded.

Transit Hospitals

Adjacent to ports of embarkation for the invasion of the Continent were about a dozen hospitals designated as transit hospitals. They consisted, for the most part, of station hospitals, though a few general hospitals were included. The mission of these hospitals was triage of returning wounded and the performance of such emergency surgery as had not been done on the far shore or on returning landing ships, tank (LST's), and other ships. For all practical purposes, these transit hospitals functioned as evacuation hospitals. Only those patients were held who could not be safely evacuated. Patients who could be evacuated were sent, as rapidly as possible, to general and station hospitals farther north. As evacuation hospitals were set up on the Continent, these transit hospitals reverted to their regular status. Many of them later moved to the Continent themselves and were replaced by units more recently arrived from the Zone of Interior.

The report of the 217th General Hospital is cited as typical of the organization and work of a general hospital which served as a transit hospital during this period. The original plan was that this hospital receive casualties soon after injury. They were to be transported from the far shore by air and brought to the hospital from an airfield 8 miles away. At this airfield, a field hospital had been set up for the direct reception and care of any emergencies

that might have arisen in transit. With these exceptions, the patients were to receive initial treatment at the transit hospital. Then, if they were transportable, they were to be taken within 48 hours to a general hospital, where they would be retained. This general hospital, while it served as a transit hospital, was thus to act essentially as an evacuation hospital.

The first patients with bone and joint injuries to arrive at the 217th General Hospital after the initial assault on the Normandy beaches were received in the afternoon of D-day. Five transport pilots were admitted with compound fractures caused by small-arms fire as they had gone in low to drop supplies to paratroopers. A paratrooper was also admitted who had fractured his ankle when struck by the door load during evasive action of the plane over the drop zone.

The next casualties with bone and joint injuries arrived on the afternoon of D-day plus 4. They were a mixed group of 20 wounded, consisting of American officers and men, a French civilian, some German prisoners of war, and several Mongolian-Russian slave laborers. Thereafter, patients arrived daily in increasing numbers until, in July, the maximum received in a single day from the airfield was 740. Air evacuation from the far shore had begun to function within a week of the landing on 6 June.

The transportability of the patients received at the 217th General Hospital varied according to the severity of their injuries and the treatment they had previously received. Some had received thorough surgical care on the far shore and were immediately transportable. Others arrived wearing their original field dressings. The untreated patients had usually been injured from 24 to 36 hours before their arrival, but it was entirely possible, and by no means infrequent, to receive patients who had been wounded in France on the same day on which they were injured. These variations were caused by differences in the number of hospitals available near the front, the casualty load in these hospitals, and the proximity of air evacuation strips to the frontline.

Most transit hospitals, like the 217th General Hospital, received only a few patients in the first day or two after D-day, and for the next few days received only a limited number of seriously wounded patients. At the 38th Station Hospital, for instance, only 4 of the 107 patients received 8 June were severely wounded. Most of the chest and abdominal injuries were apparently being cared for on the beachhead by field-hospital platoons whose normal staffs were augmented by surgical teams from auxiliary surgical groups.

The pace in the transit hospitals then began to step up. The 110th Station Hospital received 1,000 patients in a 20-hour period 8 June. By 12 June most of the transit hospitals were fully occupied. As a rule, between 250 and 500 patients were received in each convoy, with the percentage of urgent surgical cases varying according to the proportions of walking wounded and litter patients.

The average stay at the transit hospitals was 36 hours or even less, which was well within the 48-hour maximum planned. Wounded were evacuated by

hospital trains to the general and station hospitals farther inland, most of which were fully engaged by 2 weeks after D-day.

Routine of Management

The management of casualties with bone and joint injuries received in moderately large to large numbers at a transit hospital was often as follows:

Triage was conducted in the admitting section for all patients. Those whose wounds had already been debrided and immobilized, and who were in obviously good condition, were sent to a medical ward, not to an active orthopedic ward. The other patients were sent to a single orthopedic ward which had previously been designated by the chief of section, and, when it was filled, to another ward intended to take care of any overflow. All the beds in these wards were empty, except for occasional nonevacuable patients who had been moved to one end of the ward.

The dressing cart was in the center of the ward, with the plasma units already open. The traction cart was available. A table was conveniently set up with request forms for X-ray examinations and laboratory tests. Additional nursing and other personnel had been assembled for the care of the patients, including two litter teams for taking patients to the X-ray department and the operating rooms. Finally, the kitchens had been warned of the need for extra food, some of which had been brought to the ward. As soon as patients began to arrive, additional workers were sent to the designated wards, including a physical therapist, a Red Cross worker, and an enlisted man ordinarily assigned to the orthopedic clinic.

The advantage of admitting all casualties with bone and joint injuries to a single ward or to two adjunct wards at the same time was twofold:

1. The other wards were kept free of the movement of patients.
2. The fact that the recently arrived patients were all in one place, with all necessary facilities at hand, facilitated their examination by the chief of section and the ward officers.

As soon as each patient was put to bed, his pulse, temperature, and blood pressure were taken and recorded. He was also given sulfadiazine (2 gm.). X-ray and laboratory blanks were filled in with his name, serial number, and other necessary information, and the hospital number was filled in on the 55C record form. By the time this was done, the patients had been allotted in groups of 3 or 4 to the medical officers on the orthopedic service.

A brief history of each case was taken. A complete examination was made, exclusive of the wound, and the findings were recorded. As soon as these details had been completed, the patient was presented to the chief of service and the ward officer, who made whatever additional examinations were necessary and decided what laboratory work and X-ray examinations were required. Finally, a tentative plan of treatment was formulated.

Patients who needed emergency care or who were to be operated on were designated by pieces of red flannel, pinned conspicuously to the bed covering

on their beds. Patients who did not need surgery were given hot drinks and sandwiches at once.

The first patients who were examined and who required surgery were sent to the operating room and cared for there by designated officers from the orthopedic section. When all patients had been examined and evaluated, the chief of service and the ward officer themselves went to the operating room to continue the necessary surgery.

Wounds were not uncovered on the wards. They were first uncovered under sterile conditions in the preparation room, where an enlisted technician, in cap and mask, made a sterile preparation of the wound, after anesthesia had been induced. Preparation before induction of anesthesia would have been too painful. The entire procedure was repeated in the operating room by the surgeon after he had prepared his hands. The skin was then prepared chemically by an instrumental technique. The wound was draped and the operation started after the surgeon and assistant had rescrubbed their hands and put on gowns and gloves.

Most of the extremity wounds which required operation at transit hospitals were managed by wound excision or debridement, with the application of plaster of paris.

The patients who were operated on, depending upon their number, were put on one or two wards, where they could be easily kept under observation by experienced medical officers and nurses. The ward officer on the designated wards might well operate the entire night, but for the next day or two he would be assured of no admissions.

Finally, 48 hours after the reception of the first patients, the ward was emptied in a mass movement, beds were made up, and facilities were again prepared to receive fresh patients.

General Hospitals

The United Kingdom, owing to the stability of its hospital sites, was designated as a base center after the invasion of the Continent. In addition to the general hospitals which operated in it, seven hospital centers had been set up, each one under its own commanding officer. This arrangement was a notable step in increasing the efficiency and improving the results of professional care, and it also resulted in a significant saving in orthopedic personnel.

The routine of management of mass casualties in general hospitals and hospital centers varied from installation to installation. The important consideration was that some general plan of management be set up. At the 803d Hospital Center, the following routine was found efficient:

Casualties arrived at this hospital center by ambulance or hospital train, after having been brought from the Continent by air or boat and having spent 24 hours or more in a transit hospital, before being distributed to various installations in the United Kingdom.

As soon as they arrived, they were subjected to triage by the chief of the surgical service, assisted by the chief of the orthopedic section. It was thus determined immediately what types of injuries had to be dealt with and which wounds required priority of treatment. These were matters of great practical importance when 200 to 300 patients were received at the same time.

The patients were first divided into three groups: (1) Those who needed immediate attention; (2) those who could wait a brief period for treatment; and (3) those whose wounds were not urgent at all.

Patients were next segregated according to type of injury. Those with fractures of the long bones were sent to wards equipped with facilities for traction. Those who had undergone amputation and those with hand injuries were sent to special wards designated for the management of those injuries. Those with multiple injuries, whose condition was more or less critical, were sent to the shock ward, which was equipped for the combined management of abdominal, chest, bone, and other injuries, in addition to the treatment of shock.

At the 802d Hospital Center, a plan similar in principle but somewhat different in detail was followed:

All casualties with bone and joint injuries were sent directly to the orthopedic section, unless other wounds required some departure from this practice. Then, when the casts had been removed and the nature of the injury clearly defined, the following channels of distribution or courses of treatment were adopted:

1. Seriously injured men with compound fractures were sent to the orthopedic wards, which were equipped with Balkan frames, elaborate dressing carts, and supplies which permitted wound management by a scrupulous aseptic technique. These wards were staffed by young medical officers who were on 24-hour call. As far as possible, the nurses most skilled in the care of orthopedic injuries were also assigned to them.

2. When skeletal traction was not required, the patients were transferred in plaster casts to various other sections of the hospital, depending upon the necessities of the case, such as the need for plastic surgery, neurosurgery, or genitourinary surgery. The orthopedic surgeons followed the patients on these wards and continued treatment at the convenience of the officer who was in charge of the major problem.

Nerve injuries were always given priority of treatment whenever some graver injury did not prevent it. Patients with injuries of the sciatic or other major nerves were transferred, in the original plaster casts, to a neurosurgical center or to a hospital equipped for neurosurgery, unless there was some contraindication or some necessity for further evaluation. Peripheral nerve surgery could be provided at two of the hospitals which made up the 802d Hospital Center.

Certain plastic procedures had to be performed immediately. Exposed tendons, for instance, had to be covered, and orthopedic management had to be modified to suit the requirements of pedicle flaps.

Patients with compound injuries of the hand were eventually transferred to the hand-surgery section, but only after they had been studied on the orthopedic section.

3. Patients with injuries of the rectum and other injuries which required colostomy were retained on the orthopedic wards, where their wounds were treated by general surgeons. Whenever possible, patients with injuries of the rectum were managed in a special septic section, with special precautions against infection.

4. Patients who did not require traction, plastic surgery, or other special treatment and who were not acutely ill were immediately transferred to the convalescent ward, where a rehabilitation program could be pursued with the elaborate facilities provided. From this section, they were transferred to convalescent centers, rehabilitation hospitals, or, in some instances, directly to duty.

Each ward officer could usually care for a total of 72 patients and was likely to average 15 to 25 new patients with each mass admission. It was his responsibility to see them all as soon as they entered the ward to determine their priority for surgery; to evaluate their general condition; to observe them for possible complications, such as wound infection; and to continue the administration of penicillin or a sulfonamide if it had already been begun. Otherwise, an order was written for the administration of one agent or the other.

After all patients had been distributed and examined, the chief of the orthopedic section visited each ward in turn, examined each patient to check the ward officer's evaluation, and then made the operating-room schedule, listing the patients in the order of priority for surgery.

Each newly admitted patient who required surgery was taken to the operating room as soon as possible. In all general hospitals, there were complete facilities at hand for any indicated procedure. Three operating tables were usually employed for orthopedic surgery. Each was set up with a complete set of orthopedic instruments, as well as with sets of instruments for skin grafting. Fracture tables, plaster of paris, full traction equipment, and portable X-ray equipment were also provided in the operating room. As a rule, not more than 6 orthopedic operations could be done at each table in the course of the day, 3 in the morning and 3 in the afternoon. Ward officers worked in the operating room either in the morning or in the afternoon, spending the rest of the day in the care and supervision of the orthopedic patients on their wards.

Personnel assigned to each orthopedic operating table consisted of 4 trained orthopedic technicians, 2 surgical technicians, a sterile nurse, and a circulating nurse. As many shortcuts were employed as possible. Trained enlisted personnel performed the preliminary procedures, removing splints, preparing the surgical field, and frequently applying the plaster casts after operation. When these men were well trained, as they usually were, and were adequately supervised, this system was perfectly satisfactory and saved a great deal of time for professional personnel.

By the time a patient had left the operating room, a good deal had been accomplished for him. Bones had been set in the best possible alignment and were maintained in reduction by whatever method was indicated. If sepsis was not present, the wound had been closed either by delayed primary closure or skin graft, or by a combination of these methods. Not infrequently, the patient required no more active management of any kind until he was ready to be evacuated to the Zone of Interior.

Under this or some similar scheme of management, if from 200 to 300 casualties were received at a time, all of them could be operated on or otherwise disposed of in about 4 days.

Principles of Management

Whatever plan of mass management was followed in a general hospital, the principle of segregation of like cases was always followed whenever appropriate specialists were available. If they were not, there was no point in separating the orthopedic service, even in name, from the general surgical service. The best plan, in these circumstances, was to direct the patients who required specialized care to centers in which trained orthopedic surgeons were available. This policy was quite generally followed, except in the occasional instance in which a commanding officer failed to recognize that orthopedic surgery is quite as much a specialty as neurosurgery or radiology.

Segregation had two great advantages, as follows:

1. It was of great aid to a newly wounded man's morale to be assigned to a ward in which patients with injuries similar to his own were being cared for. A newly admitted man with a midhigh amputation, for instance, was much less perturbed when cared for with 30 to 40 similar amputees and could see how well they had already become adapted to their disability.
2. Ward officers assigned to special wards soon became skilled in handling special types of injuries, even if they had had no particular training directed toward this end in civilian life.

When mass admissions required the united effort of all hospital personnel, it was particularly important that their potential capabilities be used to the fullest possible extent. This principle was violated when trained orthopedic surgeons were assigned to ward work instead of operating-room work; when the chief of surgery made out the operating-room schedule without consultation with the chief of the orthopedic section, who might not know what was being done in his section, or by whom, until just before operation; and when ward officers were assigned to work in teams, which often prevented them from assisting at operation on their own patients. In enlightened hospitals, these practices were not followed. Ward officers were assigned in the operating room to their own patients and were encouraged to follow them into the recovery wards, even though other officers were detailed to these wards. Even in wartime, some semblance of physician-patient relationship could thus be maintained.

CHAPTER VI

Management of Bone and Joint Injuries in Prisoners of War

Prisoners of war who fell into Allied hands were always treated humanely and according to the best Allied medical practices. They seldom, however, received first aid and initial wound surgery as promptly as Allied wounded. This was to be expected, not only because preference was naturally given to Allied wounded but also because of the tactical situation. In all wars, prisoners abandoned during a retreat are always the most seriously wounded. The high incidence of infection among prisoners was easily explained by the usually unavoidable delays before initial wound surgery, combined, in many instances, with the extremely serious character of their wounds.

Circular Letter No. 39, Office of the Chief Surgeon, European Theater of Operations, 5 May 1945 (see appendix A), directed that the Manual of Therapy, European Theater of Operations, and Circular Letters Nos. 71, 15 May 1944; 101, 30 July 1944; 131, 8 November 1944; and 23, 17 March 1945 should be made available to captured German medical officers as guides for treatment, with the understanding that when these officers were caring for protected prisoner personnel they would be permitted to practice such methods of their own as were in accord with reasonable medical care.

Circular Letter No. 39 directed that commanding officers of hospitals utilizing the services of protected prisoner medical personnel should instruct German medical officers that skeletal traction must be used in the treatment of fractures of long bones and that wounds must be closed by suture, by skin graft, or both. The reason for the regulation was that, in the hands of United States Army medical officers, these methods had materially reduced the periods of hospitalization and of subsequent disability.

Equipment for the treatment of fractures of the long bones by skeletal traction was, according to these directives, to be furnished to German medical officers who were capable of using it. Simple illustrations demonstrating correct techniques of fracture management in various locations (figs. 13 through 16) were prepared by Maj. Floyd H. Jergesen, MC, and distributed to these officers. They were permitted to employ Steinmann pins or Kirschner wire, but splints for external fixation, such as the Roger Anderson and the Haines apparatus, were not distributed to them.

When skeletal traction was not employed in the management of compound fractures of long bones, German medical officers were expected to employ circular plaster-of-paris splints. If wounds could not be closed by delayed primary suture, the closed plaster technique was to be employed.

ABTEILUNG FUER ORTHOPAEDISCHE CHIRURGIE
STRECKVERBAND OBERARMBRUCH

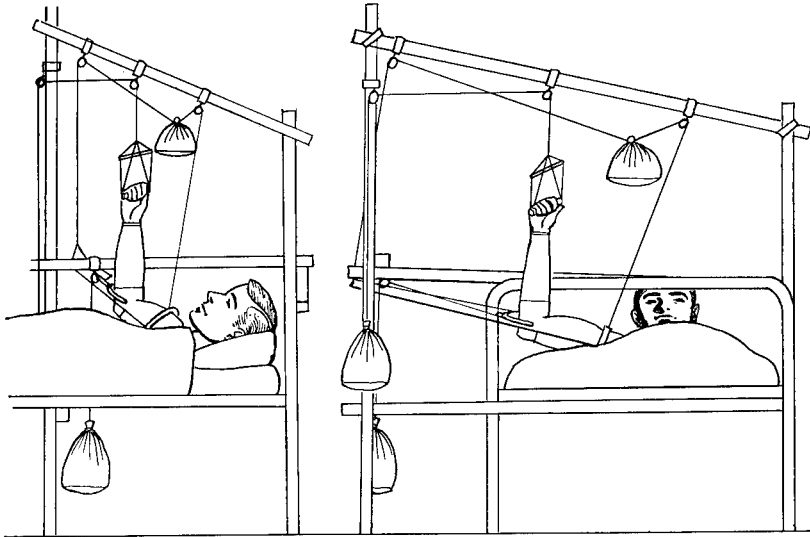


FIGURE 13.—Instructional charts prepared for use of German surgeons caring for protected prisoner personnel. Technique of traction in fractures of humerus.

ABTEILUNG FUER ORTHOPAEDISCHE CHIRURGIE
STRECKVERBAND BRUCH DES DISTALEN TEILES DES OBERARMS

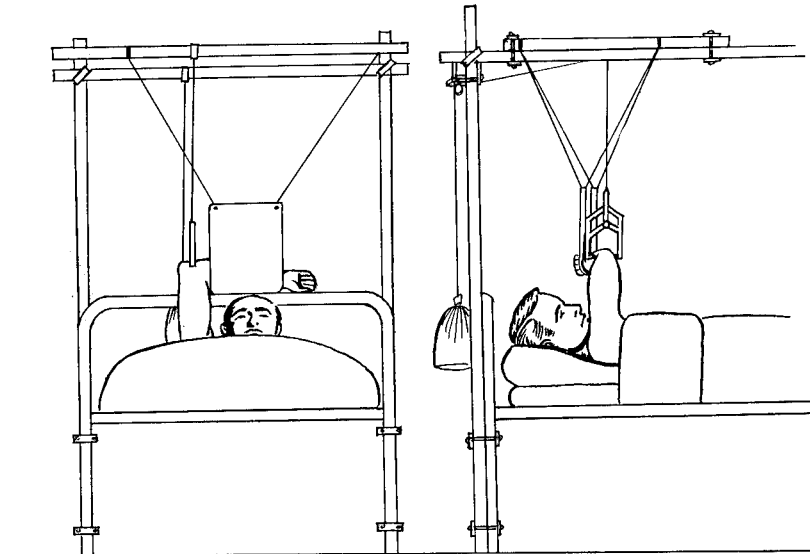


FIGURE 14.—Instructional charts prepared for use of German surgeons caring for protected prisoner personnel. Technique of traction in fractures of lower humerus.

ABTEILUNG FUER ORTHOPAEDISCHE CHIRURGIE BRUCH DES OBERSCHENKEL'S
MIT WUNDEN NAHE DES KNIE'S UND ANWENDUNGSMETHODE DES STRECKVERBAND'S

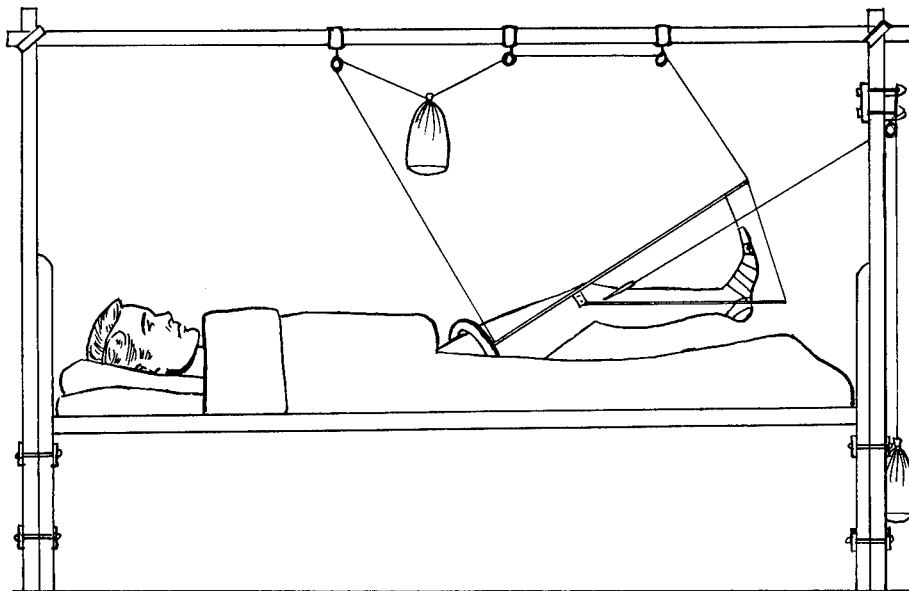


FIGURE 15.—Instructional chart prepared for use of German surgeons caring for protected prisoner personnel. Technique of traction in fractures of lower femur near knee joint.

ABTEILUNG FUER ORTHOPAEDISCHE CHIRURGIE
ANWENDUNGSMETHODE DES DRAHT STRECKVERBAND'S BEI UNTERSCHENKEL BRUCH

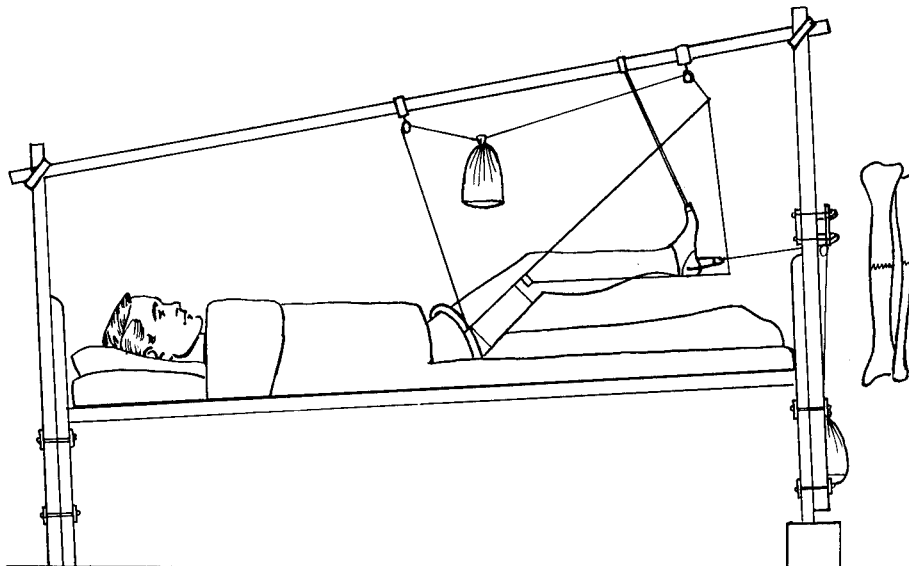


FIGURE 16.—Instructional chart prepared for use of German surgeons caring for protected prisoner personnel. Technique of traction in fractures of bones of leg.

As a practical matter, captured German medical officers served, as far as possible, only as ward officers. This limitation was necessary because so many of them were poorly trained. Internal fixation of compound fractures, bone grafts, or pedicle grafts were performed by United States Army medical officers. At one of the large prisoner-of-war hospitals in Normandy, Major Jergesen had some 2,000 compound fractures under treatment, and he himself did the great bulk of the definitive surgery there. The prisoners of war could not be evacuated, as could United States Army wounded, and Major Jergesen did the work that would normally be done for American wounded in Zone of Interior hospitals.

It was generally observed that German military surgeons, when placed in charge of their own wounded, under Allied supervision, were inclined to advise amputation with great frequency, in preference to making prolonged attempts to clear up infection and close wounds, while employing skeletal traction to stabilize fractures. If there was a chance that a badly infected limb could be saved, they preferred to salvage it by the closed plaster method, even though it meant prolonged suppuration.

The experience at the Hôpital de la Pitié in Paris illustrates why careful supervision of German military personnel was necessary. When the 217th General Hospital took over this hospital in 2 detachments, 29 August and 2 September 1944, it was filled almost to capacity with German wounded, who had been left behind with 2 medical officers, 2 nurses, a surgical technician, and a chaplain. Among the wounded were a few American and British prisoners. The incoming staff was impressed with the lack of cleanliness, which was, however, partly explained by the shortages of personnel during the preceding week or two; the paper bandages; the wire ladder splints and metal trough splints, which were widely used instead of more efficient traction; the overgenerous use of morphine; the high incidence of osteomyelitis; and the large number of amputees. In spite of the condition in which the German wounded were found, it was possible, by vigorous treatment, to get most of them ready within a few weeks for safe evacuation to hospitals designated for enemy wounded.

Penicillin.—Since penicillin was in constantly short supply throughout the fighting in Europe, it was given to prisoners of war only when it was indicated to save life and limb, and not routinely, as it was given to Allied wounded after it became available in the spring of 1944. Circular Letter No. 39 directed that it was not to be issued to protected enemy medical personnel. It was, instead, to be kept under the control of United States medical officers, and the commanding officer of each hospital had to approve both the indication and the dosage in every instance in which it was prescribed for a prisoner of war.

CHAPTER VII

Representative Hospital Experiences

298th General Hospital

Pre-D-day experiences.—The 298th General Hospital, which began to function 11 November 1942, at Frenchay Park near Bristol, was the third general hospital to be established in England. Because it was located close to a major port on the west coast of England, it gained valuable experience with battle casualties before D-day, which proved of great benefit in its later work in France and Belgium. The patients first received were evacuated from North Africa, Sicily, and Italy. During 1943, this hospital received 573 true battle casualties, over 50 percent of whom were patients with bone and joint injuries, chiefly fractures of the extremities requiring long-term treatment. About 80 percent of these patients were British, it being the policy of the British to send to the 298th General Hospital the most seriously ill patients from each hospital ship, because the proximity of the hospital to the port eliminated the necessity of a long trip by train or ambulance.

These patients required considerable attention and the exercise of keen surgical judgment. They had been wounded on an average of 6 to 8 weeks before their reception. Many had not had wound debridement within the optimum time, and, as might be expected, the incidence of wound infection and osteomyelitis was significantly higher than in battle casualties later treated on the Continent. Penicillin was not then available, but all the patients had received sulfonamide therapy. The plan of treatment, because of the timelag, was chiefly to carry on with the closed plaster technique until the wound and the fracture had healed. Every endeavor was made to improve the general health of the patient during this time. Drainage operations were performed as indicated, and the position of the bone fragments was improved whenever that was possible. It was the opinion of the hospital staff at this time that the closed plaster technique was of great value in the management of war wounds and fractures and that plaster-of-paris casts served adequately for transportation.

The nonmilitary experience of the 298th General Hospital can be taken as typical of that of the general hospitals which served in the United Kingdom before D-day. Before the invasion of the Continent, like most other hospitals in Great Britain, it was performing station-hospital duty, that is, it was serving the need of troops in training. During the year ending in May 1944, the orthopedic section of this hospital treated approximately 2,300 patients with civilian-type orthopedic conditions, chiefly fractures, dislocations and sprains, arthritis, bursitis, cicatrices, osteochondritis, osteomyelitis, poliomyelitis, synovitis, an occasional amputation, and some cases of frank psychoneurosis.

This type of work was sufficient to keep the orthopedic services of all the hospitals busy. Aside from accidental injuries, chiefly from automobiles and other mechanical equipment, most of the orthopedic material consisted of patients with disability of the feet, back, and knees. The majority of these complaints were among soldiers who were over age and who had other conditions which made them unfit for actual combat duty. The difficulties of these troops were for the most part problems in reassignment rather than actual medical or surgical problems. Line officers hesitated, and often refused outright, to reclassify them, with the result that the outpatient departments of most hospitals had large clinics filled with soldiers who were seeking downgrading. These men really needed little treatment, though they occupied a great deal of professional time. They were referred to the clinic simply because all combat units were endeavoring to streamline their personnel and to obtain as physically perfect combat teams as possible.

All combat units were finally directed to follow Circular No. 96, 15 July 1943, Headquarters, European Theater of Operations, paragraph 2,¹ which emphasized the necessity of trying to find places of limited duty with individual units before men with so-called civilian-type disabilities were admitted to hospitals for reassignment. All the hospitals in England were cluttered with such cases, and many unwise elective operations (p. 185) were done in an endeavor to place essentially unfit men on full-duty status. This proved an impossible task.

Post-D-day experiences.—When the 298th General Hospital was moved to Cherbourg, France, where it operated from 27 July to 28 October 1944, it supplied station and general hospital medical service to large numbers of troops stationed in this port area. It also cared for many battle casualties and acted as a holding hospital for patients to be evacuated by hospital ship to England. A maximum of 30 days was allowed for the treatment of any case. Orthopedic injuries included:

1. Acute non-combat-incurred injuries of the bone, joints, and soft tissues. These were numerous, because many thousands of troops were working at the port.
2. Minor battle-incurred wounds. Many lightly wounded battle casualties were treated, with the objective of returning them directly to duty.
3. Serious battle-incurred injuries. Patients with this type of injury were treated in large numbers before their evacuation to England.
4. Other war-connected injuries. Many patients were received who had been wounded by mines left by the Germans or in the course of handling and dismantling captured German ammunition.

From 20 November 1944 through May 1945, the 298th General Hospital was stationed at Liège, in Belgium. Here the majority of patients admitted had battle-connected wounds and injuries. Most of them were received within 1 to 3 days of primary debridement done in evacuation or field hospitals. Particularly in December 1944 and January 1945, a number of lightly and

¹ See appendix A, p. 319.

moderately wounded patients were admitted because forward hospitals had been too heavily loaded with more serious cases to receive them. The patients required debridement as well as later, more definitive, surgery. Over the same period, a number of casualties were also received who had been wounded in the immediate vicinity from aerial and buzz bombs (V-1 type).

50th General Hospital

The 50th General Hospital, which had spent its time near Glasgow before D-day, was moved to Utah Beach 15 July 1944 and bivouacked near Carentan, France. At this time the front was not very far away, the beaches were close, and the bridge into the town was being shelled by Germans. The hospital did not become operational immediately. An orthopedic team, consisting of the chief of the section, an assistant surgeon, 2 surgical corpsmen, a surgical nurse, and a nurse anesthetist, worked in the 41st Evacuation Hospital for 3 weeks, during the attack on Saint-Lô, France.

When the 50th General Hospital became operational 15 August, the orthopedic work was heavy and diversified. There were many injuries caused by boobytraps and injuries on the beaches, as well as numerous serious automobile accidents, involving military as well as civilian personnel. German prisoners of war with combat wounds of the extremities and long bones were also treated. During this 3-month period, the hospital, which was a 1,000-bed installation, treated 1,206 casualties with bone and joint injuries, answered 820 orthopedic consultations, and treated 175 outpatients with bone and joint conditions.

On 17 November 1944, the hospital moved to Commercy, France, and a second orthopedic team was placed on detached service at Morhange with the 30th Field Hospital. This installation was supporting armored units, and the bone and joint injuries, while less numerous than previously, were extremely severe and mutilating. When the main hospital again became operational 18 December 1944, the first patients received were about 300 Russian prisoners of war who had been recaptured from the Germans by the Third United States Army. They were in poor condition, and some were starving. There were many fatalities in injuries of the knees, hips, and spine, alone or in combination, in contrast to the usually low case fatality rate in bone and joint injuries uncomplicated by other wounds.

217th General Hospital

When the 217th General Hospital, which was part of the 814th Hospital Center, was in Paris, there were 590 admissions to the orthopedic service during September 1944. At this time, the advance past Paris was moving rapidly, and most of the injuries were the result of small-arms fire. The percentage of untreated cases was high.

As the front moved away from Paris, patients began to be received by hospital train and by air. There were 1,570 admissions to the orthopedic ward in November and 2,042 in December. These numbers are exclusive of the patients with bone and joint injuries admitted to other wards. From September through April, there were 8,211 admissions to the orthopedic section, of which 5,172 were battle casualties. Included in this number were 408 patients with fractures of the femur; 694 with fractures of the tibia, fibula, or both; 301 with fractures of the humerus; and 284 with fractures of the radius, the ulna, or both. Two of the patients died, one of the uremic syndrome after a blast injury and the other of a compound dislocation of the hip, with deep pelvic infection and hemorrhage. Over the same period, 1,238 orthopedic consultations were answered. Some of the patients thus seen were later transferred to the orthopedic section for care.

Fifteenth United States Army Hospitals

The evacuation and field hospitals of the Fifteenth United States Army functioned primarily in the role of station hospitals, serving all the troops in the areas to which the army was assigned. This was the last Allied army to enter the conflict with Germany. Combat work in all hospitals of the Fifteenth Army was at a minimum, because of its tactical mission. Becoming operational on 6 January 1945, this army, other than in April when it conducted operations within the Ruhr and the Lorient-Saint Nazaire pockets, was initially mainly concerned with receiving, training, and equipping organizations newly arrived on the Continent, as well as rehabilitating, reequipping, and reenforcing various units that had suffered heavy losses during the Ardennes campaign. Later, its mission was primarily to occupy, organize, and administer military government in the Rheinprovinz, Saarland, Pfalz, and a portion of Hessen. In the final stage of the war, as well as in the postwar period, the medical picture was altered by the necessity of caring for large numbers of displaced persons, RAMP's (Recovered Allied Military Personnel), and German civilians who required treatment for emergency conditions.

Because of the impossibility of evacuating eastern European displaced persons, RAMP's, and German civilians, orthopedic problems differed considerably from those usually encountered in hospitals at the army level. The four main sources of orthopedic cases encountered by this army's hospitals were motor accidents, accidental gunshot wounds, mine accidents, and injuries and diseases in RAMP's and in displaced persons from German military and civilian hospitals. The circumstances under which the injuries from general accidents and mines were received made them different from injuries received in combat. The timelag was considerably shorter than was usual in combat injuries, and exposure was not the rule. Secondary shock was less, as was the preoperative morbidity. On the other hand, inability to evacuate displaced persons rapidly or within the regulation 10-day period required that they receive a definitive type of treatment which was not ordinarily permitted in an evacuation hospital.

PART II

CLINICAL POLICIES AND PRACTICES

Mather Cleveland, M. D.

CHAPTER VIII

General Clinical Policies

Evolution of Clinical Policies

The North African (Mediterranean) Theater of Operations began to be the scene of active combat in November 1942, more than a year and a half before similar action began in the European theater. The experience of the former theater with injuries of the bones and joints is related in detail elsewhere in this series of volumes. The closed plaster technique, which was originally employed on the basis of the successful experience with it in presumably comparable civilian injuries, proved thoroughly unsatisfactory in combat-incurred injuries. Its use was attended with a high incidence of infection, a resultant prolongation of the wound-healing time, and a high incidence of deformity and dysfunction. It was eventually learned by hard experience that the solution of the problem of war wounds was (1) adequate debridement and (2) delayed primary suture. By the spring of 1944, it had also been learned that by far the best results were obtained in combat-incurred compound fractures in all locations if they, too, were managed by these principles. After May 1944, this plan of management was official policy in the Mediterranean theater.

Official liaison between the Mediterranean and European theaters was poor, and it is regrettable that the vast experience of the Mediterranean theater was not made available to the European theater through official channels. After the invasion of Italy, in the fall of 1943, certain of the surgeons stationed in the British Isles were able to visit the (then) North African theater. They returned with practical, firsthand information regarding the best methods of care of wounded soldiers, and these methods became the official policy of the European theater.

It was inevitable, however, since the care of the wounded was of necessity in the hands of physicians fresh from civilian practice and often with little or no surgical experience, that the original concepts and practices in the European theater should often be essentially those of civilian practice. As a result, there was some delay, and some false steps were taken, in setting up policies and plans for the proper and expeditious care of battle casualties with bone and joint injuries. These errors were of brief duration. Within 6 to 8 weeks after the invasion of the Continent, the correct principles of management of battle-incurred injuries were generally in effect throughout the European theater. The existence of the senior and junior consultant systems, with repeated tours of inspection of evacuation, station, and general hospitals, was largely responsible for this prompt transition.

Studies on the management of battle-incurred compound fractures had been conducted before D-day at various hospitals in East Anglia, England, which were serving elements of the Army Air Forces, particularly the 2d Evacuation Hospital and the 49th Station Hospital.¹ Three parallel series were studied. In each series, surgical management was the same—debridement of the wound and immediate primary closure. In the first series, no supplemental chemotherapy was used. In the second, the patients received local and systemic sulfonamide therapy. In the third series, they received local and systemic penicillin therapy. The results in each series were essentially the same. The incidence of wound infection was less than 10 percent, and healing was usually prompt and satisfactory.

Not a great deal of attention was paid to this study by Army medical officers. These wounds were all in Army Air Force personnel and had been sustained at high altitudes, under clean conditions, by officers and enlisted men who lived in relatively sanitary surroundings and who had frequent opportunities to bathe. The circumstances somewhat resembled those which had been encountered earlier in the war in desert areas of North Africa. These wounds, it was thought, bore no resemblance to those which would be sustained after the invasion of the Continent, in the highly manured soil of France. It was therefore not considered wise, on the basis of this study in Army Air Force personnel, to make any change in the policy that war wounds should be thoroughly debrided and should be left open for several days after wounding.

It is unfortunate that more attention was not paid to this investigation, for it served to emphasize a universal truth. The results were equally satisfactory in all three series, in each of which the common factor was careful, adequate debridement of the wound. The good results were due, therefore, to adequate surgery. They were no better in the series in which chemotherapy and antibiotic therapy were used than they were in the series in which no supplementary therapy was employed. Emphasis upon this fact would have been of great practical value before the invasion, especially to medical officers who had the mistaken notion that the new drugs had made established surgical principles of somewhat less importance.

Establishment and Dissemination of Policies

In addition to preparation of the various circular letters which were issued for the guidance of medical officers in the management of orthopedic and other injuries, part of the time before D-day was spent in the preparation of a Manual of Therapy,² which was issued in May 1944. It served as a guide to the management of all varieties of wounds, including injuries of the bones and joints.

It soon became evident, however, that this manual, while it laid down broad, sound surgical principles, did not meet all the needs of younger, inexperienced surgeons who necessarily cared for great numbers of casualties and

¹ (1) Annual Report, 2d Evacuation Hospital, 1943. (2) Annual Report, 49th Station Hospital, 1943.

² Manual of Therapy, European Theater of Operations, 5 May 1944.

who had had little or no experience with traumatic surgery, at least of the kind and in the mass encountered in war wounds. Furthermore, some of the principles laid down in the original Manual of Therapy required revision in the light of increasing experience and more extensive observation.

As a result of these necessities, circular letters revising the original methods of management of injuries of the bones and joints and other injuries were published from the Office of the Chief Surgeon, European Theater of Operations, at various times after D-day. The most important of these letters were Nos. 101, 30 July 1944; 131, 8 November 1944; and 23, 17 March 1945.³ Among other things, all these letters stressed that there must be close adherence to the policies and methods of management described in them. One reason was the usual military reason that casualties were treated in a line of evacuation by a number of different surgeons, each of whom had to be able to take for granted that the surgeons who had preceded him in the management of the particular patient had followed the course of action specified for this particular type of wound. The second reason was that, as the theater expanded and the number of untrained and inexperienced surgeons increased, whatever freedom of action might have been permissible for experienced orthopedic surgeons could not be permitted for less experienced surgeons, and restrictions, however hampering they might seem, had to be set up and strictly enforced.

Each of the circular letters published in the theater incorporated, and was built upon, the accumulated previous surgical experience. After the suspension of hostilities, a revised draft of the Manual of Therapy was completed on the basis of the wartime experience. Comments on and criticisms of various methods of treatment had been collected throughout the period of combat, and a series of meetings had been held with the junior consultants in orthopedic surgery in the United Kingdom and on the Continent (p. 39). Discussions at these meetings were free and uninhibited, and detailed notes were kept. The proposed revision of the Manual of Therapy⁴ (appendix B) therefore represents the final judgment of all the orthopedic surgeons who cared for the bone and joint injuries sustained in the European Theater of Operations in World War II. The final revision was the work of Lt. Col. John G. Manning, MC, who was assisted by Lt. Col. William J. Stewart, MC, and the senior consultant in orthopedic surgery, European Theater of Operations, Col. Mather Cleveland, MC. It was not published officially because the war in the Pacific ended soon after it was completed.

As an illustration of how policies of treatment formulated by the Theater Chief Surgeon were disseminated to Army units, the following directive is cited which was issued by Headquarters, Third United States Army, 28 January 1945, on the subject of medical policies for tactical operations.⁵ In substance, the material contained in this directive read as follows:

³ See appendix A—orthopedic details, circular letters.

⁴ Cleveland, M.; Manning, J. G.; and Stewart, W. J.: Care of Battle Casualties and Injuries Involving Bones and Joints. *J. Bone & Joint Surg.* 33-A: 517-527, April 1951. (See appendix B.)

⁵ Letter, Hq. Third U. S. Army, 28 January 1945, subject: Medical Policies for Tactical Operations, inclosure 1—Surgery.

General.—The Manual of Therapy, European Theater of Operations, will be utilized as a general guide and reference manual by all Medical Department officers and will be available in all medical installations at all times.

Fractures.—All compound fractures will be debrided, and the compounding wounds will be left open. No casualty with a fracture will be transported without proper immobilization in a splint or plaster cast. Neither field nor evacuation hospitals are held responsible for the anatomic reduction of compound fractures. The responsibility of these hospitals is to see that patients with these fractures are prepared for early evacuation in comfort and safety. No internal fixation or plating will be practiced in a field or evacuation hospital or any other Third United States Army medical unit.

Plaster casts.—All casts applied to the extremities must be padded. All circular casts, after manipulation or operative procedure, must be split through all layers down to the skin—in the lower extremity from the tips of the toes to well above the knees and in the upper extremity from the tips of the fingers to well above the elbow. When a cast is applied to immobilize the leg, the foot must be in neutral position, at right angles to the leg.

Fractures of the femur will be immobilized for transportation in a double circular plaster spica extending from the toes of the affected foot and from the knee of the sound leg. The spica will be reenforced by a strut placed posteriorly. The leg should not be spread more than litter width, with the knees slightly flexed. A properly applied Tobruk splint may be substituted for the spica in selected cases, if the fracture is below the upper third of the shaft.

Fractures of the tibia and fibula will be immobilized in circular plaster of paris extending from the toes to the groin. Fractures of the feet and ankles will be immobilized by a circular plaster boot, extending from the toes to just below the knee.

Fractures of the humerus are to be transported in a plaster spica bandage, with the arm held forward and rotated medially, so that the forearm rests in front of the body. The elbow should be flexed to at least 90 degrees. A plaster Velpau bandage may be used to transport the patient to the general hospital but is not as satisfactory. The hanging cast is not an acceptable means of fixation for transportation and must not be used.

Fractures of the forearm and wrist will be immobilized in circular plaster, extending to the midbrachial region, with the elbow flexed from 90 to 110 degrees to the long axis of the humerus. This cast must be cut back in the palm of the hand to the proximal sulcus so as to permit free motion of the fingers.

Thomas splints.—The Thomas full- or half-ring splint is to be used only as an emergency measure. If the Army traction strap or clove hitch is left on the foot for more than 6 to 8 hours, skin necrosis almost invariably results. Patients will therefore not be transferred or evacuated from evacuation hospitals with the Thomas splint left on the limb, except as part of a Tobruk plaster. A Thomas splint on the upper extremity is extremely uncomfortable and should be discarded at the first hospital in which a plaster-of-paris circular splint can be substituted for it.

External fixation.—The use of Steinmann pins incorporated in plaster of paris or the use of metallic external fixation splints leads to gross infection or ulceration in a high percentage of cases. This method of treatment is not to be employed in the Third Army.

Joint injuries.—Wounds of the joints should be closed at the earliest possible moment, by delayed primary suture or skin graft. Whenever possible, the synovial membrane should be closed at the time of debridement. Large foreign bodies overlooked in joints lead to infection and should always be removed.

If the joint surfaces are not badly damaged, early active motion should be insisted upon. If they are so badly damaged that bony ankylosis is inevitable, the joint should be immobilized as follows: Hip joint, 25 degrees of flexion, 0 to 5 degrees of abduction; knee joint, 10 to 15 degrees of flexion; ankle joint, 10 degrees of equinus.

Joints of the upper extremity should be immobilized for evacuation in the manner described for fractures of the same parts. The wrist should be dorsiflexed about 40 degrees. The spontaneously ankylosed elbow joint is the most serious problem in the upper extremity, and many of these injuries may later require amputation.

Amputations.—The technique of circular amputation and the post-operative management of the stump should follow the directions in Circular Letter No. 101, Office of the Chief Surgeon, European Theater of Operations, 30 July 1944. These amputations are often traumatic, and the skin edges are irregular, but in most instances traction, if it is adequately applied, will effect closure of the stump. These techniques must be used in all amputations in the Third United States Army.

The surgeon in the hospital in which the amputation is performed will, in every case, explain to the patient before he is evacuated exactly why the amputation was necessary.

General Medical Policies

It was always emphasized, during the prewar training of American hospital units, that preferential care should be given to wounded soldiers who could return to duty, on the ground that the maintenance of fighting strength was the first responsibility of the Medical Corps. As might have been expected, American medical officers, when it came to the actual test, maintained the civilian concept of medical care and utilized their available facilities to save life first and return men to combat second. The urge to save life produced the concept by which triage was conducted, and most seriously wounded men received preferential care for the reason that they would have died without it. Knowledge that they would receive prompt care fortified the courage of the fighting men and improved their morale in danger.

This policy and practice meant, however, that only relatively few men with bone and joint injuries were first-priority cases. Orthopedic casualties,

as a rule, had first priority only when they also had suffered vascular injuries or abdominal or chest wounds. Even then, the care of the bone or joint injury usually had to be deferred until the major wound had been cared for. Orthopedic surgeons were not assigned to field hospitals, where first-priority surgery was done, and surgical personnel was seldom in sufficient supply in these hospitals to permit orthopedic surgery to be conducted simultaneously with other surgery.

The timelag between wounding and the patient's arrival in a mobile or fixed hospital depended upon the type and location of the hospital, the tactical situation, and the conditions of transport. Sometimes a man who was wounded in combat passed through the echelons of the division and arrived in an evacuation hospital within 2 or 3 hours of wounding. More often the timelag was close to 8 hours, and sometimes it was considerably longer, depending, in particular, upon combat conditions. In Normandy, some evacuation hospitals received the wounded within an hour or two after they had been hurt. Later, the timelag was lengthened to 2 or 3 hours. Still later, long ambulance hauls were necessary, and sometimes patients were received as long as 72 hours after wounding. Casualties with bone and joint injuries, unless they had suffered associated visceral or vascular injuries, were, as just noted, seldom treated in the field hospital located in the vicinity of the clearing station but were taken directly to evacuation hospitals.

The timelag between wounding and arrival at a general hospital for reparative treatment also varied. During the summer months following D-day, wounded soldiers frequently arrived in the United Kingdom within 3 to 5 days after they had been removed from the frontlines. As the battlefront moved farther and farther beyond the Normandy beachhead, the interval increased from 10 to 14 days and was sometimes longer. During the winter months, when the flow of casualties was extremely heavy and air transport was hampered by weather conditions, intervals of 3 weeks or more were not unusual. During the last 3 months of hostilities, when air transport was again possible and had reached a high state of efficiency, casualties sometimes reached the United Kingdom within 2 to 3 days after they had been wounded.

Evacuation Policies

The holding period on the Continent varied. At the maximum, it was seldom over 60 days between admission and return to duty or further evacuation. This meant that fractures of the long bones to be treated by skeletal traction almost without exception had to be managed in the United Kingdom Base, where the holding period was 120 days.

The peak load of casualties on the Continent occurred between December 1944 and March 1945. At this time, as well as during all periods of general offensives in France, Belgium, and Germany, evacuation in all hospitals had to be rapid and efficient. Otherwise, there would not have been enough beds available for the constant stream of wounded. At certain periods, the only patients held were those who needed further care before evacuation and those

who could be returned to duty within 10 days. Patients with bone and joint injuries practically never fell into the latter group.

After March 1945, the holding period on the Continent was gradually increased to 30, 60, 90, and finally 120 days, if it was thought that the man could be returned to duty within this time.

The tactical situation and medical necessities always had to be reconciled. The optimum time for delayed wound closure, for instance, was 3 to 10 days after debridement. Often there were mass admissions from evacuation hospitals to general hospitals of casualties who required definitive surgery. Surgical policy required that such patients be held for 10 to 14 days afterward. The military situation, on the contrary, required that nontransportable patients in general hospitals be held to a minimum. Most of the candidates for closure actually were in the militarily evacuable class and therefore subject to evacuation at any time after admission. The general policy was to close the wounds within 12 to 48 hours after the patient had been received, unless local or general factors prevented operation without further preparation or unless it was thought that the tactical situation would require prompt evacuation.

These statements, of course, must not be interpreted to mean that there was mandatory evacuation of patients who were in no condition to travel. The commanding officer of any hospital could at any time declare a particular patient nonevacuable. For this reason, a certain number of fractures of the long bones were treated by delayed primary suture and skeletal traction in general hospitals on the Continent. This policy was usually followed, if it seemed unlikely that the patient could be evacuated safely to a general hospital in the United Kingdom Base within an optimum period for the institution of skeletal traction, which was 7 to 21 days after wounding.

In some hospitals, far too much emphasis was laid upon the importance of rapid evacuation. There was an occasional tendency to commend hospitals for the number of patients who were passed through them, and, conversely, to criticize hospitals in which evacuation seemed less efficient. As a result, essentials of treatment were sometimes disregarded. Patients with unreduced fractures, improperly or inadequately immobilized fractures, or severe infections and, very occasionally, incipient gangrene, were sometimes evacuated when they should have been held for treatment. The need for beds was never so urgent as to warrant these practices, and it is only fair to say that errors of this kind were observed, for the most part, during the Battle of the Bulge, when tactical necessities demanded the evacuation of every patient possible.

In the occasional case, the patient was evacuated because that was the easiest way to handle him. To hold men who required treatment meant that each individual had to be carefully appraised, and an occasional medical officer was unwilling to take so much trouble. On the other hand, strict adherence to evacuation policies sometimes militated against the basic objective of medical management, that is, the return of soldiers to duty as soon as possible. Patients with minor injuries or ailments got into the line of evacuation and continued in it until some alert medical officer took time to appraise their

condition and halt their journey to the rear. By this time, the soldier was often well back in the communications zone, and it required weeks to get him back into the line, although his wound would have not required him to be off duty for more than a few days.

None of these errors was inherent in the system itself. They were all to be attributed to personnel failure. Evacuation policies were well set up and efficient, and they were carried out with an elasticity and coordination unknown in previous military operations. Furthermore, casualties from the Continent were, as a rule, received in good condition in the United Kingdom Base. They were received in much better condition as the war progressed, for the reason that, as time passed, it was learned which casualties could safely be evacuated promptly and which must be held for further observation and treatment.

While it was not always desirable, and was frequently highly undesirable, to evacuate some patients with bone and joint injuries, it could be done, under the stress of necessity, with one notable exception: When vascular injuries were associated with compound fractures, the casualty had to be observed for several days before evacuation was permitted, to be certain of his circulatory status and to be sure that gas gangrene was not developing.

CHAPTER IX

The Management of Compound Fractures— Initial and Reparative Wound Surgery

Wounds of the extremities often made up as much as 70 percent of the caseload of an evacuation hospital. Half or more of these wounds were associated with compound fractures, which means that from 35 to 40 percent of all casualties presented this type of injury.

Col. Charles B. Odom, MC, consultant in surgery, Office of the Surgeon, Headquarters, Third United States Army, analyzed 64,389 battle casualties treated in Third Army hospitals from 1 August 1944 to 1 February 1945.¹ Of these injuries, 43,345 were found to involve the extremities or the buttocks. This was 67.3 percent of the total number; it had been estimated that the proportion would be 71 percent. The case fatality rate for wounds of the extremities was 0.82 percent, compared with a rate of 2.9 percent for all battle casualties in this series.

Compound fractures thus constituted a major part of the surgical load in all Army hospitals. They also presented major problems, for four reasons over and above their frequency:

1. They were often of a devastating character not observed in civilian practice.
2. The compounding wound was often so large and extensive that it constituted another problem in itself.
3. There was frequently an accompanying nerve lesion, and less often there was an accompanying vascular lesion.
4. The same soldier frequently presented a multitude of injuries, any one of which constituted a major problem in itself. Thus it was not uncommon to admit a casualty with a perforating wound of the thorax with hemothorax, a perforating wound of the abdomen for which a colostomy had been necessary, and compound fractures of two major bones, frequently associated with division of a major peripheral nerve. The first objective in every such case was naturally to save life, and it was extremely dangerous to overtreat the patient, who might readily go into shock or go back into shock as the result of too vigorous treatment. As a result of the circumstances, the bone injury was usually the last to be treated, and the delay was sometimes considerable.

Development of Policies

The evolution of the method of delayed primary wound closure in the North African (Mediterranean) theater is recounted in detail elsewhere in this

¹ Semiannual Report, Office of the Surgeon, Third U. S. Army, 1 January-30 June 1945.

history. The technique was developed and generally accepted by an evolutionary process. It was not put into practice as the result of directives from the Theater Chief Surgeon's Office. On the contrary, the directives finally issued concerning it took cognizance of what had then become an established practice.

Many months were to pass, and many poor results were to be obtained by other techniques, before delayed primary wound closure was routinely adopted in the Mediterranean theater in the management of injuries of the soft parts. It was not until the late spring of 1944, only a few weeks before D-day in the European theater, that delayed primary wound closure was also adopted in the Mediterranean theater as a technique of management of compound fractures, and lack of time, as well as lack of liaison, prevented the general dissemination of the information in the European theater.

In the European theater a similar, though considerably briefer, period of evolution occurred. The Manual of Therapy² prepared before D-day emphasized, in the directions for initial wound surgery, the importance of "early secondary closure" (delayed primary closure) or early skin grafting. Later directives were specific that wounds were to be closed by delayed primary closure, preferably within 4 to 5 days after debridement if there was no clinical evidence of infection. Closure within 10 days or less from the date of injury was still to be undertaken under the same circumstances.

In the rush of casualties that followed D-day there was a certain inevitable confusion, and the method was unevenly and improperly applied in some cases. Some wounds were closed with strict regard to the regulation about the time of closure but with too little attention to the requirement that they be clinically free from infection. This happened chiefly because many newly arrived hospitals became swamped with casualties, and their medical officers, who were inexperienced and who had not been in the theater long enough to have any thorough training, closed some wounds regardless of their appearance. When cases began to be properly selected and the method was properly applied results were excellent.

It was only in occasional cases that the principles of delayed primary closure of clean wounds 4 or 5 days after debridement was not accepted for soft-tissue wounds. There was reluctance, however, to accept the same principles of management for compound fractures. When this method is successful, as it is in a large proportion of the cases in which it is properly employed, it converts a compound fracture into a simple fracture, but it took some time to convince many medical officers of the possibilities of the technique. Indeed, it was with reluctance and trepidation that many orthopedic surgeons in the European theater finally proceeded with delayed primary closure of compound fractures. They clung to the routine of removing the plaster, redressing the wound, and putting on a fresh cast, with, in selected cases, closure of the wound at a later date. In most cases in which this method was used, healing was permitted to occur by granulation. It was not a satisfactory technique. Infection was frequent overseas, and while it was not possible to determine the

² Manual of Therapy, European Theater of Operations, 5 May 44.

end results, because the patients were evacuated to the Zone of Interior, the impression was general that function was often not as good as it might have been.

When it was demonstrated in the cases in which the technique was employed that delayed primary closure of compound fractures was a safe and satisfactory method, the situation changed. After persuasion and perhaps some browbeating by the consultants, orthopedic surgeons began to use this technique. In late June of 1944, it began to be employed in a trickle of cases, out of many later shown to be entirely appropriate for its use. By mid-July, the number had become a torrent. By September 1944, the situation in respect to wound closure was well stabilized, and delayed primary closure was being used routinely in all compound fractures in which it was justified. By the end of the war, almost the only wounds left to heal without delayed primary closure were very small wounds which had already begun to close by granulation when the casualties were received in the general and station hospitals to the rear. At this time it was exceptional to find surgeons who were not carrying out the prescribed techniques and who had not greatly improved their original technique.

The full story of the success or failure of delayed primary suture of compound fractures could not, of course, be ascertained in the European theater. Most patients with these injuries were returned to the Zone of Interior in plaster, and final results were evaluated there. There was no question, however, in the minds of orthopedic surgeons in the theater as to the value of this method. The practice of delayed primary wound closure had the same advantages in the European Theater of Operations as had already been demonstrated in the Mediterranean Theater of Operations. Prolonged drainage incidental to healing of the wound by scar tissue from the depths to the surface was obviated. The percentage of infection was minimal as compared to the high percentage of infection which had accompanied the closed plaster method. Underlying exposed bone was conserved and bone healing was expedited along with soft-tissue healing. Convalescence was shorter and far more satisfactory.

Finally, repair of divided peripheral nerves, open reduction of such fractures as required this procedure, the application of bone grafts, and similar surgery could all be performed much earlier, with relative ease and with generally good results, whenever delayed primary wound closure had been practiced.

Debridement

The principles of debridement as it was practiced ideally in the European theater did not differ from the principles by which it was practiced in other theaters. The cardinal consideration in all initial wound surgery was thoroughness. If the debridement was adequate, the patient was almost always received at the general hospital in the communications zone with the wound healthy and ready for primary closure or for skin grafting as necessary. If debridement was not adequate, frank infection or a dirty wound prevented closure at the optimum time. Frequently, in these cases, secondary debride-

ment or even a drainage operation was necessary. Paradoxically, therefore, the surgeon who was most radical in the debridement of war wounds was really practicing conservatism.

A correct debridement was carried out according to the following principles:

1. The incision was preferably longitudinal and was always generous enough to permit complete exposure of the wound to its depths. It was made through the original wound when possible. If for any reason this was not practical, a new incision was employed.

2. Damaged and devitalized tissue was excised until cleanly bleeding surfaces were reached. Fascial planes were widely opened to relieve tension. The tissue removed consisted, for the most part, of muscle whose fibers had been destroyed by the enormous expansile force of modern high-velocity projectiles.

3. All accessible foreign bodies, particularly bits of clothing, were removed.

4. As much skin as possible was conserved. Intact skin is essential for proper healing of underlying tissues.

5. It was also the rule to conserve bone fragments, especially if they were large. Even bone chips could serve, in effect, as bone grafts and thus provide additional support for the injured extremity.

6. Severed nerves were loosely approximated by a single wire suture. If this could not be accomplished, an identifying suture, which was demonstrable by X-ray, was put in each end. Primary nerve suture was never attempted.

7. Hemostasis was complete and precise.

8. The wound was always left open for drainage at the initial operation. Drainage or counterdrainage was sometimes instituted through another incision also. Provision for drainage was particularly important in wounds in the thigh and buttocks, and failure to institute it accounted for a number of fatalities in patients with bone and joint injuries, as well as for a number of serious infections.

9. The wound was well irrigated at the conclusion of the operation. It was then held open with fine-mesh gauze which was placed loosely in the wound, no more being used than was necessary to accomplish this purpose. Tightly packed gauze prevented drainage, and the damming back of secretions by this means could give rise to serious infections. Vaseline-impregnated gauze was frequently used early in the European theater experience, but as time passed it was found to be open to many of the same objections as tightly packed gauze, and fine-mesh dry gauze was used routinely thereafter.

10. Finally, pressure dressings were applied and the wounded extremity was encased in a plaster-of-paris splint which was well padded and which had been selected with a view to the necessities of the particular case. This splint was merely for transportation purposes. Forward hospitals were not concerned with the anatomic reduction of fractures. The splint was split or bivalved through both plaster and padding before the patient was taken off the operating table. The assumption was that it would be removed within 3 to 7 days for delayed wound closure.

11. If penicillin had not already been administered, it was begun at the conclusion of the initial operation. In any event, it was continued until 3 days or more after delayed wound closure.

The policy of early, complete debridement, with the establishment of adequate drainage, preferably through the open wound, was the policy set up in the European Theater of Operations for every wound of the extremities, regardless of its type and size. On the whole, as already noted, it was carried out fairly consistently, even in the early days of the theater.

Common errors in initial wound surgery.—The availability of the sulfonamides and, more particularly, of penicillin induced an occasional inexperienced surgeon to eliminate debridement, especially in small, perforating wounds. This was not a safe or a wise policy, chiefly because it was impossible to determine by external inspection of an injury what the state of the deeper tissues might be. The burden of responsibility was always placed squarely upon the surgeons who failed to adhere to theater policy in this regard. The senior consultant in orthopedic surgery and the junior consultants lost no opportunity, on their visits to the various hospitals, to stress the point that adequate debridement was the only acceptable policy in a battle wound, and that every surgeon must adhere to this policy, regardless of the size of the wound. In addition to inadequate debridement, the chief errors made in the initial surgery of combat-incurred compound fractures may be stated as follows:

1. Circumcision rather than excision of wounds. Debridement through a linear incision provided the only satisfactory exposure of the deeper tissues. Operation by a circular, coning-out technique was completely ineffective, one reason being that satisfactory closure of the wound was impossible when a circular incision had been made at initial surgery. This type of incision was particularly undesirable in compound fractures, regardless of their location.

2. Failure to expose and examine adequately wounds which also involved vessels and nerves. Nerve injuries were sometimes overlooked in both the upper and lower extremities, though this error, for obvious reasons, was seldom made in vascular injuries.

3. Too free removal of bone chips in comminuted compound fractures.

4. Failure to split all transportation casts and underlying wadding down to the skin.

5. Holding patients too long in forward hospitals and thus delaying primary closure unduly.

6. Using penicillin too frequently and in too large amounts, merely because it happened to be available.

Strict adherence to directives would have prevented all of these errors. The fact that they continued to be made throughout the war is an indication of the extreme difficulty which civilian surgeons experienced in changing over from civilian to military practice. It is also an indication of inability to recognize the difference in the function and responsibility of surgeons in a forward and in a fixed hospital. If all orthopedic surgeons could have had

some instruction and orientation before they were sent to evacuation hospitals, many of these errors would probably not have occurred.

A report to the surgical consultant of the Third United States Army from Maj. Dudley W. Smith, MC, of the 4th Auxiliary Surgical Group, on detached service at the 94th General Hospital, is an interesting, instructive, and practical commentary on the errors which had to be combated at forward hospitals. His observations were based on 500 cases collected from the First, Third, and Ninth United States Armies. The mission of this hospital was chiefly the delayed primary closure of compounding wounds after debridement and the establishment of skeletal traction. The most important of Major Smith's observations were as follows:

1. Valuable time could be saved and the patient could be spared considerable discomfort if it were prominently marked on both the plaster splint and the field record that the patient had a nerve lesion, and if the extent of the skin loss were also noted. Some patients did bear these notations on their splints and their records, but they were in the minority. A patient with a diagnosed or suspected nerve lesion which was thus identified could be transferred to a neurosurgical center without the necessity for removal of the cast and examination of the wound.

2. Far too many wounds could not be closed for two reasons: (1) Many contained dead muscle and damaged fascia which were actually sloughing when the cast was removed and the wound was inspected. This was because a sufficiently long longitudinal incision had not been made at debridement, which was inadequate because exposure was inadequate; (2) many wounds were actually blocked by heavy vaseline-gauze wicks or Penrose drains which had been inserted deep into them. When these were removed, a well-circumscribed tract was left, which was sloughing and contained more or less exudate. The wounds in perfect condition for closure were those in which a sufficiently long incision had been made for complete excision of damaged tissue and which contained only two flat strips of vaseline gauze on each side, with the flat edges extending into the depths of the wound. These wounds were clean and healthy looking and almost invariably healed well after delayed primary suture.

3. Enough attention was not paid to extremities in which vascular injuries were associated with bone and joint injuries. In 1 such case the popliteal vein had been ligated 4 days before. The leg was enormously enlarged, the foot was cold, and the limb was not supported in any way. The patient was in great pain, and the process was obviously not going to subside. This result might have been prevented if the leg had been put up in a long leg split cast with large lettering on it to warn all concerned to keep the extremity elevated. Surgeons at forward hospitals should have been warned that patients with vascular injuries, whether or not the bone was involved, would not be comfortable without some kind of adequate support to the leg. These surgeons should also have been warned that limbs might be lost by failure to observe this precaution.

4. In a number of instances, casts had been incompletely split, while in some instances the sheet wadding had not been split at all.

5. In the occasional case, foreign bodies in joints had not been completely removed. As a general rule, however, the results of removal of shell fragments from the joint, followed by the instillation of penicillin and closure of the synovial membrane, had been excellent.

6. Some patients who had been subjected to amputation were grossly anemic and needed massive transfusions, though they had stood the trip well. The care of amputations and stumps was generally excellent.

All these observations attested the paramount importance of adequate initial surgery in the combat zone. If surgery there was inadequate, the mission of the general hospital in the communications zone was complicated and the end results of treatment were jeopardized. It was always valuable when, as in this case, a surgeon from the army area was able to make observations in the communications zone and report to his colleagues the results of failure to carry out precisely the policies of management laid down by the Theater Chief Surgeon.

Anesthesia.—Almost without exception, debridement was carried out under general anesthesia. Only a brief experience was necessary to prove that it could not be satisfactorily performed under local analgesia. For one thing, this technique would have introduced further contamination into an already contaminated and possibly infected field. Furthermore, battle wounds were seldom in the category of inconsequential injuries. Even the smallest wounds, as just pointed out, were likely to be associated with severe damage to the underlying tissues, as well as gross contamination by foreign material. In this kind of injury, an adequate debridement could not possibly be performed except under general anesthesia.

Wounds debrided under local anesthesia in forward hospitals were often frankly infected when patients were received at the general hospitals. Primary closure was not possible in these cases until secondary debridement had been performed. This necessity delayed closure of the wound beyond the optimum period, and healing was never quite as satisfactory as in the cases in which closure could be accomplished more promptly. Even when frank infection did not occur, wound healing was likely to be delayed, and the delay could often be attributed to the original error of not using a general anesthetic for debridement.

Delayed Wound Closure

The management of compound fractures in general hospitals began with an examination of the wound as soon as possible after the patient was admitted. If the cast was merely split and was not bivalved, it was bivalved at this time and the upper portion was lifted off. It was thus possible to inspect the area without contaminating the wound. The operating list was made up after all the casualties had been inspected, priority being given to patients whose

wounds were of longest duration and to those who had fractures which would require traction.

Plaster and dressings were removed completely in the preparation room or the operating room, and the surgical field was prepared with soap, water, and ether or tincture of Metaphen (nitromersol).

The wound was carefully inspected to be certain it was clinically clean throughout, but the depths were disturbed only if secondary debridement seemed necessary. If the wound was clean, closure was proceeded with at once. If secondary debridement was necessary, the surgeon had to use his judgment to determine whether he might safely proceed with closure at this time or whether it would be better to defer the procedure until a later date.

If closure was undertaken within a maximum of 10 days after wounding, the skin edges were mobile and it was necessary to free them only slightly. The wound was then approximated with vertical mattress sutures of silk or cotton, preferably rather widely spaced. Buried sutures were avoided. If closure without tension was not possible, undermining incisions were employed or split-thickness skin grafts were used on part of the wound or, if necessary, on the whole wound. The directives issued before D-day required the sprinkling of sulfonamide crystals into the wound before closure, but this practice was forbidden by directive several months later.

Rubber-tissue drains were used for 48 to 72 hours in all deep wounds. Small stab wounds were occasionally used for counterdrainage if dead spaces had not been entirely obliterated.

When, for any reason, 10 days or more had elapsed from the time of wounding to wound closure, mobilization of the skin edges, which by this time had become fixed and rigid, was practically always necessary at the reparative operation. Secondary debridement was sometimes necessary also. The criterion of wound closure at this time was the same as the criterion for earlier closure, that is, a clinically clean wound. The preferable technique was the use of interrupted sutures, widely spaced and loosely tied. A drain was placed in the wound for 48 hours, and pressure dressings were kept in place for 10 to 14 days. At the end of this time, the sutures were removed.

Split-thickness skin grafts.—When there had been an extensive loss of tissue, particularly of the skin, it was frequently impossible to close wounds completely by suture, and sometimes they could not be closed at all. In such cases, split-thickness skin grafts were employed to complete the partial closure or to accomplish total closure. By this means the objective of converting a compound fracture into a simple fracture was attained, tension on the wound edges was avoided, and scar-tissue formation was prevented. Any surgeon, even with no great amount of training, readily learned the technique of split-thickness skin grafting and the results were practically always satisfactory. If it was found, later, that additional plastic surgery was necessary, the split-thickness graft could be excised and a full-thickness graft applied with little risk of infection.

The cases in which complete wound closure would be impossible without skin grafting could usually be determined before operation, and the donor site, which was on the thigh whenever possible, was prepared on the ward. Many hospitals eventually adopted the practice of preparing a donor site before operation in any case in which there was a severe compound fracture of the lower extremity. The operating room was always set up with equipment for skin grafting, and, even if the procedure had not been planned previously, there was no delay if it was decided upon during the course of the operation.

Massive pressure dressings were always used after skin grafting.

The results of split-thickness grafts applied to fresh, clean wounds were usually good (figs. 17 and 18). Many surgeons obtained takes of 100 percent. Results were less good in old, previously infected, granulating wounds, but if the granulations were shaved down to the base, takes of 40 to 50 percent were readily obtained. The least successful results were obtained in prisoners of war with neglected wounds, in which successes usually did not exceed 35 percent.

If split-thickness grafts were not successful, the use of a pedicle graft often gave excellent results (fig. 19). In certain selected cases, in which closure by other means was impossible, pedicle grafts were used at reparative surgery, without any trial of other techniques (figs. 20 and 21) or were applied later (fig. 22).

Infected wounds.—In the first days of fighting on the Continent, when debridement was frequently inadequate, a distressing number of patients were received in the United Kingdom with infected wounds. Later, it was found that treatment by wet compresses for a few days, sometimes supplemented by secondary debridement, made wound closure possible in many of these cases. In others, closure was not attempted; instead, the wounds were dressed with vaseline gauze, which was then being used by directive. Many wounds treated in this manner were frankly infected when the patients were evacuated to the Zone of Interior.

Management of Fractures

Skeletal traction or, better, balanced suspension with skeletal traction (p. 113) was the method of choice in the management of most fractures of the long bones. It was the policy to reduce the fracture with the use of skeletal traction on the operating table, then check the position and alinement by X-ray. It was thus possible to determine the amount of weight to be used for traction and to determine the cases in which a sling or other supplementary equipment was needed to prevent angulation. The original time spent in careful reduction saved many hours in manipulation and many roentgenologic examinations later, and also avoided distraction.

Open reduction (p. 116) was performed with a high degree of success provided that care was taken to select cases in which there had never been any gross evidence of infection and in which the wounds had been healed for 17 to 21

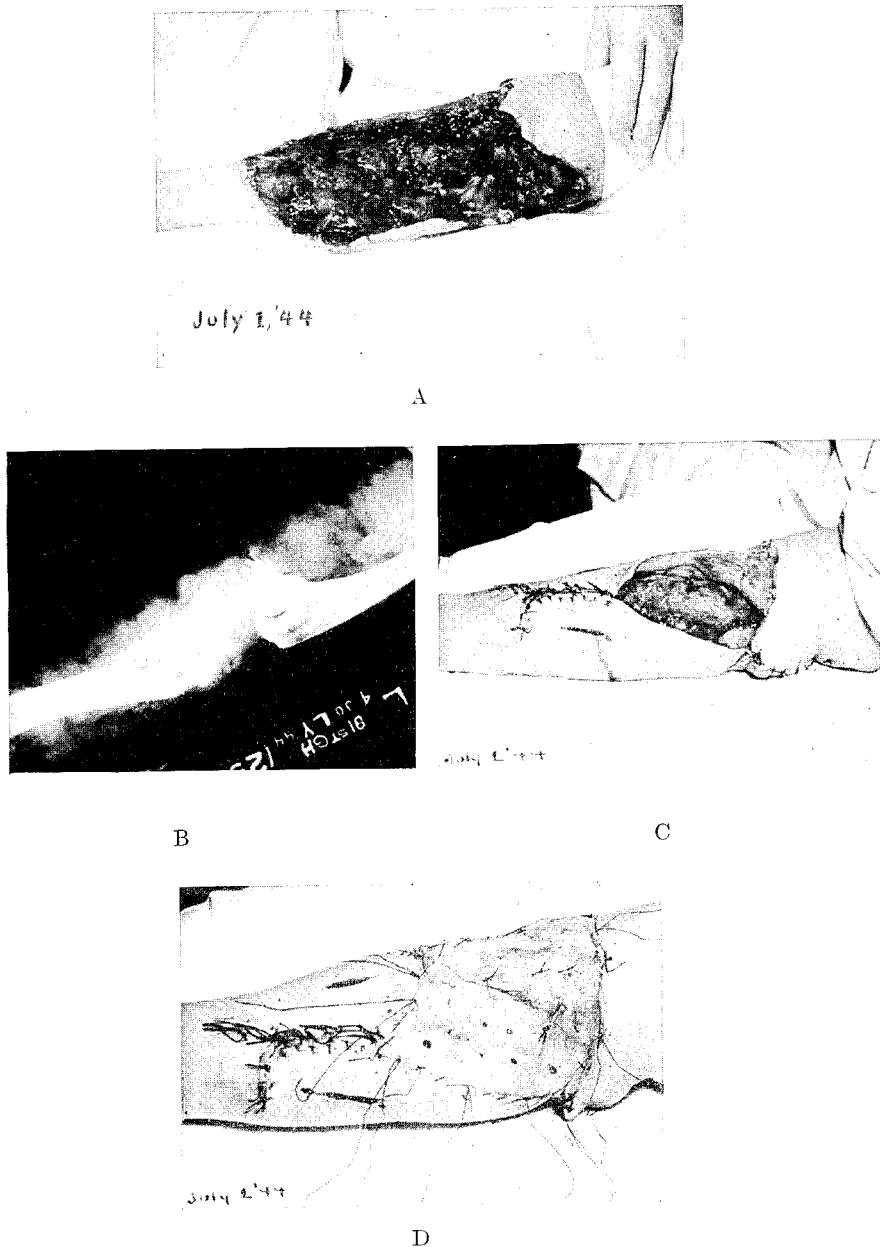
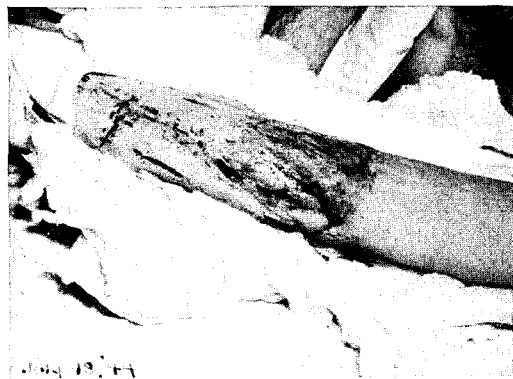

FIGURE 17.—Compound fractures of humerus and radius, lacerated wound of arm and forearm, sustained 25 June 1944. Initial surgery was done at a Royal Air Force Hospital, and the patient was received at the 91st General Hospital 29 June. He was returned to the Zone of Interior 7 August. A. Appearance of wound when reparative surgery was undertaken. B. Roentgenogram showing compound fractures of radius and humerus. C, D. Wound closure by suture and split-thickness skin graft after secondary, more extensive debridement.



E

FIGURE 17.—Continued. E. Stage of wound healing 18 July, 2½ weeks after reparative surgery.

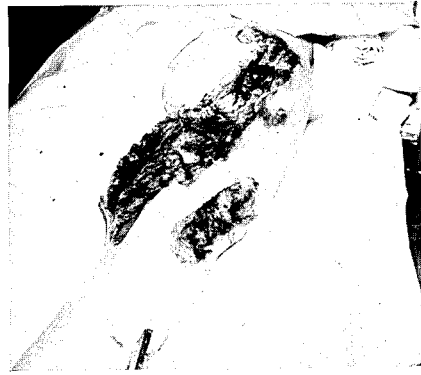
days. Penicillin was used intramuscularly for a minimum of 5 days after operation.

Results of Delayed Primary Wound Closure in Compound Fractures


Overseas Theaters

Results of the policy of delayed wound closure were generally good in the European Theater of Operations. A report by Maj. (later Lt. Col.) John A. Grove, MC, on the work at the 15th Hospital Center is typical of both the material handled and the results of the policy. At this center, the policy of closing all soft-tissue wounds over compound fractures was immediately established and was continued throughout the war. At first, patients were received promptly, and delayed primary wound closure was possible within 2 to 6 days after wounding. In the later stages of the fighting in Europe, when patients had to be evacuated after deep penetration of their units into Germany, wounds were closed on an average of 14 days after wounding. It was the impression of the hospital staff that the results then were somewhat less good than they had been when closure was accomplished on the third or fourth day after wounding, as had frequently been possible in the first weeks of the early European fighting.

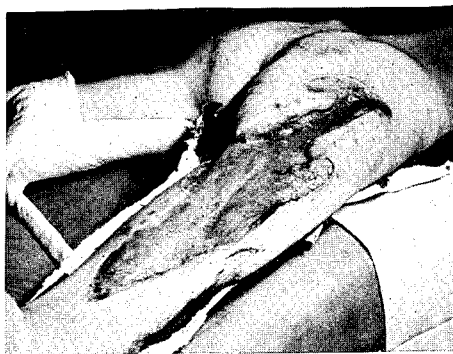
During the whole period from D-day to V-E Day, 60.3 percent of all compound fractures managed in this hospital center were treated by delayed wound closure. In another 25 percent, suture was omitted because the wounds were small and of the puncture type; in practically all of these cases, the wounds were well healed or were well on the way to healing when the patients were ready for evacuation. In the remaining cases, the wounds were severely infected and two policies of management were followed, (1) partial closure, and (2) evacuation of the patients to the Zone of Interior with open wounds.



A

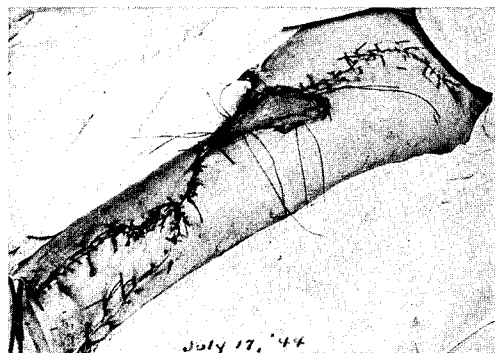


B

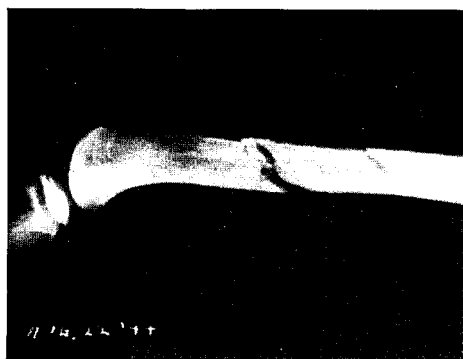


C

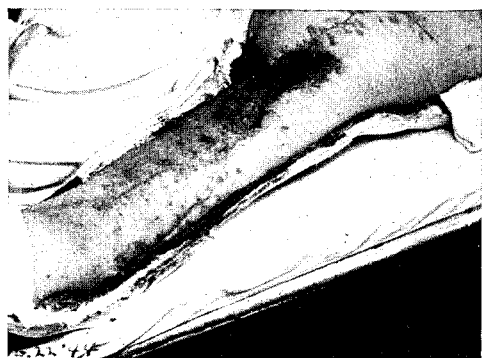FIGURE 18.—Compound fracture of right femur, lacerated wounds of posterior thigh and buttock, sustained 16 June 1944. Debridement was done 14 hours after injury, and the patient was admitted to the 91st General Hospital 20 June. Here a secondary debridement was done and skeletal traction was applied. The wound was closed 16 July and by 22 August was well healed. The fracture was also satisfactorily aligned. A. Appearance of wounds when patient was first seen in the 91st General Hospital. B. Roentgenogram showing compound fracture of femur. C. Appearance of wound when reparative surgery was undertaken approximately 3 weeks after wounding.



D

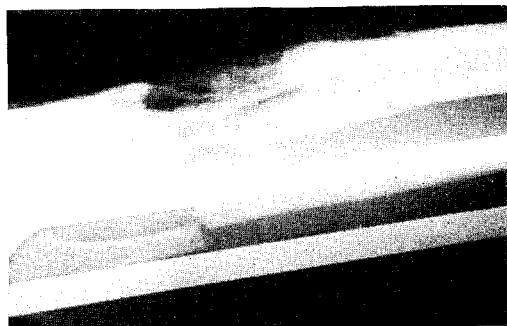


E

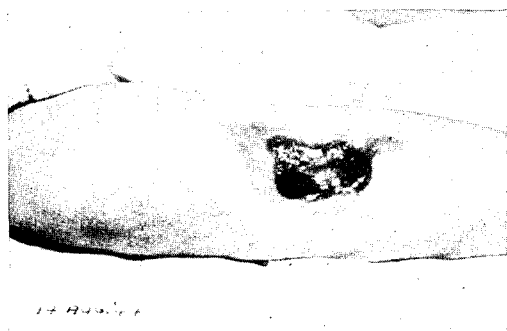


F

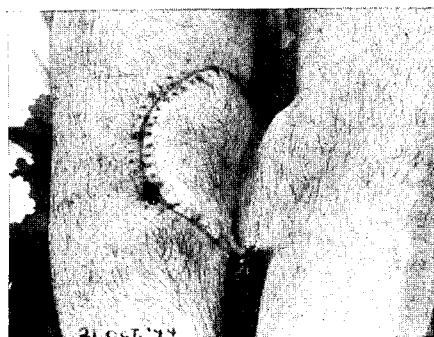FIGURE 18.—Continued. D. Wound closure by suture and split-thickness skin graft. E. Roentgenogram showing femoral fracture in satisfactory alignment 2 months after wounding. F. Appearance of healed wound 5 weeks after reparative surgery.



A

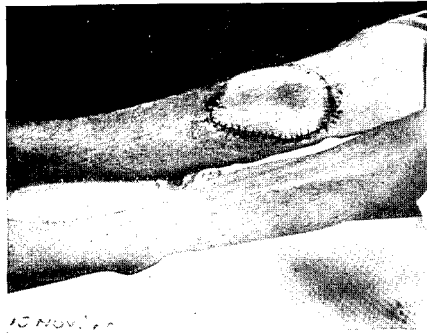


B



C

FIGURE 19.—Compound fractures of tibia and fibula sustained 5 August 1944. Debridement was done at the 104th Evacuation Hospital the same day. Closure of the soft-tissue wound was attempted at the 82d General Hospital 14 August but was not successful. On 6 October, a split-thickness skin graft was applied but did not take. On 21 October a direct cross-leg pedicle graft was applied at the 129th General Hospital. It was divided 15 November and the patient was returned to the Zone of Interior shortly afterward. A. Roentgenogram showing compound fractures of tibia and fibula. B. Appearance of wound 21 October just before delayed primary wound closure by pedicle graft. C. Appearance of cross-leg pedicle graft 15 November just before division.



D

FIGURE 19.—Continued. D. Appearance of wound after separation of pedicle graft.

Two somewhat more detailed statistical surveys of wound closure at the 15th Hospital Center were also made by Major Grove. The first included the period from D-day to 6 November 1944. The second covered the period from 1 December 1944 to 1 March 1945.

First series.—During the 5-month period ending 6 November 1944, the 15th Hospital Center received and treated 5,042 compound fractures, excluding fractures of the bones of the face and the skull, and fractures of the spine with associated spinal-cord injuries. With few exceptions, all of these fractures were battle incurred. Bones of the lower extremities were involved in 2,614 instances and those of the upper extremities in 1,895 instances. The remaining 533 fractures consisted, in the order stated, of fractures of the pelvis, scapula, patella, clavicle, and vertebrae. The bones most frequently fractured were the tibia (757), humerus (702), and femur (684).

Preparation for the reparative operation consisted of the standard routine, including transfusions of whole blood whenever the patient showed any evidence at all of anemia. Massive whole-blood replacement was frequently necessary. Whenever operation was delayed for any reason, the extremity was suspended in balanced suspension with skeletal traction, which reduced edema and facilitated later closure.

Delayed primary wound closure was attempted in 2,393 of the 5,042 cases, the average timelag between wounding and closure being 14 days. Closure was accomplished by suture in 2,087 cases, by skin graft in 236, and by a combination of suture and skin graft in 70 cases. In many large, frankly infected wounds, partial closure of the wound was performed with free drainage at the site of maximum infection; counterincisions were sometimes used for dependent drainage. This technique prevented the large losses of serum, with resulting protein deficits, which occurred from large draining surfaces. It was practically always accompanied by marked improvement in the patient's general condition.

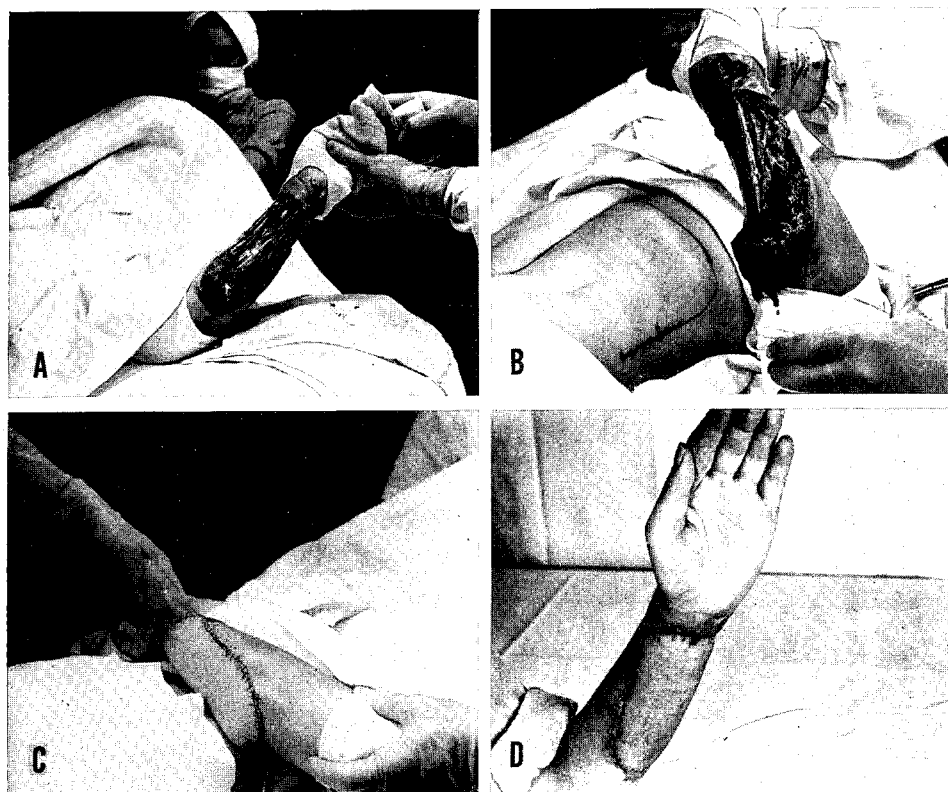

FIGURE 20.—Huge defect with massive loss of skin and other soft tissues on palmar surface of left forearm. Management by pedicle graft. A. Appearance of defect 8 days after initial wound surgery. Note exposed tendons. B. Outline of large pedicle graft from abdomen designed to fit defect on forearm. C. Application of pedicle graft to wound of forearm. Care was taken to avoid excessive tension. D. Healed defect 4½ weeks after reparative surgery. It is reasonable to assume that the function of this patient's hand was salvaged chiefly because of the prompt application of a pedicle graft. Early healing could not have been obtained by any other method, and the several tendons exposed in the wound would certainly have sloughed if they had not been promptly protected by skin coverage.

This patient was treated by Lt. Col. Eugene M. Bricker, MC, senior consultant in plastic surgery, European Theater of Operations.

Healing by primary intention occurred in 1,592 of the 2,393 cases (66.5 percent) in which delayed primary wound closure was attempted. In an additional 640 cases (26.74 percent of the total number), closure was partly successful. Wounds in this category were characterized by small sinuses, stitch abscesses, or partial loss of skin grafts. With few exceptions, these wounds healed after secondary suture or secondary skin grafting or, in some instances, spontaneously. This meant, then, that a total of 93 percent of the 2,393

wounds in which delayed primary closure had been undertaken were completely healed when the patients left the hospital.

In the remaining 161 cases, 6.73 percent of the total, the attempt at wound closure was a complete failure. The entire wound broke down, or an osteomyelitis developed and required wide surgical opening of the wound. These failures chiefly occurred in wounds involving the upper third of the femur or the pelvis, with complicating wounds of the bladder or bowel. Wounds involving the lower third of the leg and foot were also represented in the group of failures. Cultures from the wounds which failed to heal revealed mixed types of infection, with staphylococci and bacilli of the colon group predominating.

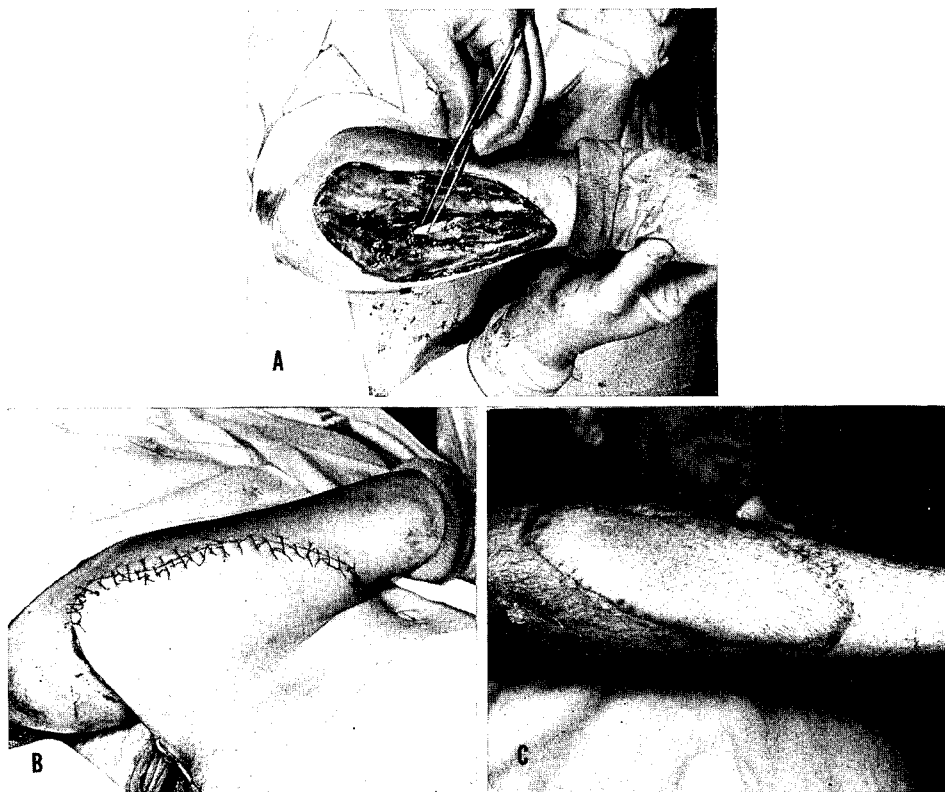
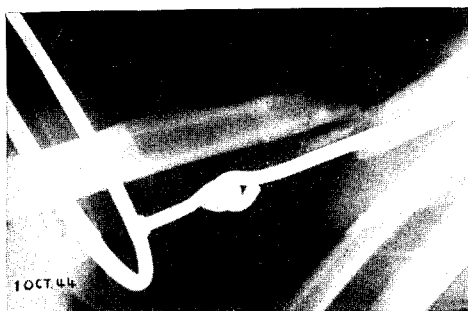
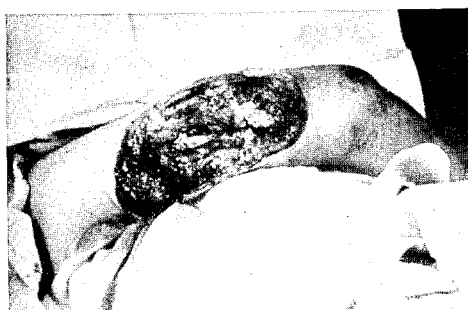

FIGURE 21.—Fracture of ulna, with large compound wound in upper half of right forearm. Management by pedicle graft. A. Wound at reparative surgery 9 days after wounding. Note comminuted fragment of ulna held by tissue forceps. B. Pedicle graft from abdomen immediately after application to wound of forearm. C. Completely healed wound 5 weeks after reparative surgery.

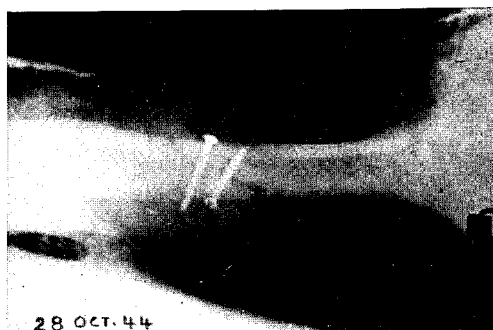
This patient was treated by Lt. Col. Eugene M. Bricker, MC, senior consultant in plastic surgery, European Theater of Operations.



A

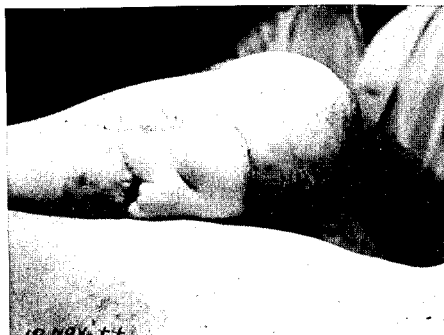

B

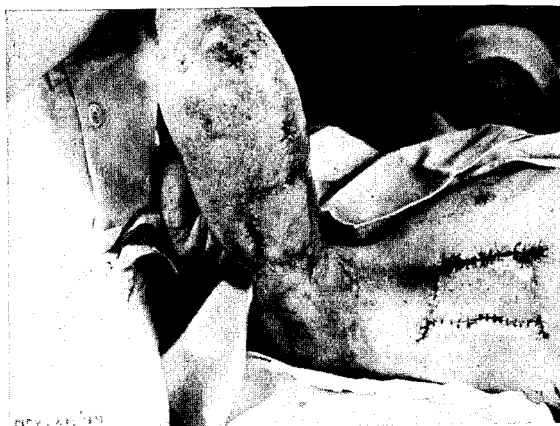

C

FIGURE 22.—Compound fracture of right humerus, with paralysis of median, radial, and ulnar nerves, laceration of right brachial artery, and gangrene of tips of fingers of right hand. Wounds were sustained 22 September 1944. Skeletal traction was applied 1 October and a pedicle graft from the chest was applied 28 October; at the same operation, the humeral fracture was fixed with two screws. The pedicle was divided 21 November, and the patient was returned in a plaster spica to the Zone of Interior the following month. A. Roentgenogram showing compound fracture of right humerus with application of skeletal traction. B. Wound of posterior humeral region just before application of pedicle skin graft. C. Roentgenogram showing fixation of fracture of humerus by two screws. This procedure was carried out when the pedicle skin graft was applied.



D



E

FIGURE 22.—Continued. D. Coverage of wound by pedicle from infra-axillary region. E. Healed wound and coverage of donor site by split-thickness skin graft.

It is a matter of interest that 2,152 of the wounds which were not closed surgically, approximately 42.6 percent of the total number, showed spontaneous healing during the period the patients were hospitalized overseas. The maximum holding period in this theater was 10 to 12 weeks at this time, depending upon the site of the fracture. The majority of the wounds which healed spontaneously were small penetrating or perforating wounds. This means that failure of healing occurred in only 658 wounds, 161 in which the attempt at closure did not succeed and 497 in which no attempt at surgical closure was made. In other words, within the holding period permitted, 87 percent of the compound fractures were converted to simple fractures by healing of the compounding wounds. Frank osteomyelitis occurred in 272 cases, 5.4 percent.

Second series.—Between 1 December 1944 and 1 March 1945, 3,053 compound fractures were received and treated at the 15th Hospital Center, the

same center from which the preceding study was made. Delayed primary wound closure was undertaken in 2,241, approximately 75 percent of the total. Eighty-seven percent of these wounds healed satisfactorily. The percentage of absolute failure was only 7.6 percent, since healing occurred spontaneously or later secondary closure was successful in another 5.4 percent of the cases, after failure of the first attempt at suture. The incidence of osteomyelitis was 7.6 percent.

It should be noted that during the period covered by the second of these two series, delayed primary wound closure was attempted in almost three-quarters (73.4 percent) of the cases, against less than half (45.4 percent) of the first series. The incidence of complete success on the first attempt at suture rose from 67.6 percent to 87 percent. The incidence of osteomyelitis rose from 5.4 percent to 7.6 percent, and the small increase may fairly be taken as an indication of how greatly the surgeons on the staff, in spite of the much bolder attack on the problem of wound closure, had increased in surgical wisdom and judgment. If they had not, the proportion of bone infection would undoubtedly have been much higher. In all probability, the success or failure of closure was always determined by the adequacy and boldness of the original wound excision and debridement. The results were better in the second series than in the first, because this lesson had been almost universally learned.

The good results in these cases can also be attributed to two other factors, the youth and generally good condition of the casualties and the generous use of whole-blood transfusions whenever they were indicated. A much higher percentage of good results was secured in the cases in which transfusions were used to correct anemia of any degree. There was no proof, however, that the incidence of serious wound infections in this series was materially reduced by the use of either the sulfonamides or penicillin.

Zone of Interior Hospitals

The results of delayed wound closure in compound fractures of the long bones could not, as already noted, be determined overseas. In December 1944, therefore, an attempt was made by the Office of The Surgeon General to investigate the results of this technique at 23 named general hospitals in the Zone of Interior. The outcome of the investigation was not particularly happy. It was probably undertaken too soon. When the bulk of the questionnaires which were answered were returned, less than 6 months had elapsed since D-day, and there had been insufficient time for the union of many major fractures. The wording of the questionnaires, or so the replies suggested, does not seem to have been as clear as it should have been. A number of different observers prepared the replies, and they naturally determined the results in accordance with their individual standards, so that the personal equation made it almost impossible to tabulate results, let alone correlate them. Finally, the reports on union of fractures (delayed union versus nonunion) were particularly colored by individual interpretations.

Nineteen of the twenty-three general hospitals queried returned questionnaires covering 3,469 compound fractures. Of these, 1,180 were fractures of the femur, 1,540 were fractures of the tibia and fibula, and 741 were fractures of the humerus. Delayed primary wound closure had been attempted in 1,951 cases and had succeeded in 1,403. Of the 3,190 cases in which the information was supplied, bony union had been accomplished in 2,189 cases, but 417 patients presented malunion and 584 still had no union. The tabulated results confirmed the general impression that closure can be more readily accomplished over femoral and humeral fractures than over fractures of the tibia and fibula. Osteomyelitis was reported in 864 cases, but the figure is misleading since the incidence was figured on both closed and unclosed wounds.

Data from studies of compound fractures in which delayed primary closure had been attempted are more illuminating than the data just cited.

At *Batley General Hospital, Rome, Ga.*, for instance, almost 90 percent of the compounding wounds were successfully closed in fractures of the femur and humerus, the incidence of union was high, and the incidence of osteomyelitis was low. In compound fractures of the tibia and fibula, on the other hand, the incidence of bony union remained high, and the incidence of osteomyelitis low but closure was successful in only about 60 percent of the cases.

In the other hospitals reporting, the number of cases in which closure had been attempted was frequently surprisingly small. Some of the results were also frankly surprising. Thus it is difficult to reconcile the 9 out of 10 failures in fractures of the humerus at *Kennedy General Hospital, Memphis, Tenn.*, with the percentage of successes reported from certain other hospitals, particularly *Batley General Hospital*, where there were only 4 unsuccessful results in 38 attempted closures.

Unfavorable Cases

Nineteenth General Hospital.—An analysis of a sample of material from the 19th General Hospital is typical of the results obtained in delayed primary wound closure when the circumstances were frankly unfavorable. At this hospital, between 16 February and 31 May 1945, 881 wounds were closed by this technique in 379 patients.³ About 90 percent of these wounds were battle incurred. Almost all of them were severely comminuted compound fractures, chiefly of the long bones of the extremities. In many instances, extensive soft-tissue wounds were associated with the bone injuries.

Seventy-seven of the 379 patients were United States Army personnel; 298 were prisoners of war whose injuries were, almost without exception, the most severe and extensive in the reported series.⁴

When the patients in this series were first admitted to the 19th General Hospital, their wounds were inspected merely by lifting off the upper layer of the bivalved cast and the top layer of dressings. If the gauze was adherent to the wound, as it frequently was, it was not removed. If a through-and-

³ Semiannual Report, 19th General Hospital, European Theater of Operations, 1 January-30 June 1945.

⁴ There were four additional patients of other nations (see footnote 3.).

through drain had been used, as it had been in a few instances, it was removed at once. If the wound was too tightly packed, the plug of gauze was also removed. The policy at this time was a minimum of wound inspection and manipulation.

If the preliminary inspection just described could be carried out on the ward it saved time. If, however, it was clear from the history that the wound was extensive or if the gauze could not be readily removed, then the first complete inspection was carried out under anesthesia in the operating room.

On the whole, the wounds were in reasonably good condition, and debridement had been adequate. Most of the wounds had been kept open by dry, fine-meshed gauze, lightly packed; only occasionally had the packing been inserted so tightly that it was actually plugging the wound. In some cases there had been too liberal a removal of comminuted bone fragments, and the large bony defects which were left could obviously be corrected only by bone grafting.

All patients with wounds of any severity had immediate blood studies and were given transfusions of whole blood before operation if the hemoglobin level was below 12 gm. percent and the hematocrit level below 35.

The technique of delayed primary wound closure was that ordinarily employed (p. 87).

The results in these 881 wounds in 379 patients were analyzed from several different standpoints. Complete data were not always available in each category.

In the 305 cases in which data are available on this point, wound closure was carried out on the 2d day in 2 cases and on the 75th day in 1 case. The (cumulative) figures show that 200 patients underwent reparative surgery between the 2d and 7th days after wounding; of these, 184 were operated on between the 4th and 7th days. Two hundred and twenty-five patients were operated on between the 2d and 8th days and 251 between the 2d and 10th days. The other 54 were operated on between the 11th and 75th days.

While these patients were under observation in the 19th General Hospital, 59 frank wound infections occurred among them. Seven were in United States Army personnel, and 52 in prisoners of war. Fifty-six of these 59 infections occurred in men wounded in battle, 50 of whom were prisoners of war.

Primary healing occurred after delayed primary wound closure in 195 patients, 68 of whom were United States Army personnel.

It was observed that the highest percentage of good results in these 379 patients was obtained (1) when the hemoglobin at operation was 80 to 90 percent and the red blood cells 4,000,000 to 5,000,000 per cu. mm.; (2) when the wounds were in the shoulder, arm, forearm, and hand rather than in the leg, ankle, and foot (almost 100 percent versus 67 percent); and (3) when the discharge from the wound was serous but not seropurulent.

Composite studies.—In his annual report for 1944 to the Theater Chief Surgeon, the senior consultant in orthopedic surgery commented on two other reports dealing with delayed primary suture in prisoners of war.

The first of these reports concerned 97 prisoners of war who had been caught between lines of fire.⁵ As a result, the timelag between wounding and initial wound surgery was unusually prolonged in most of these cases. Only 16 of the 97 had received penicillin or sulfonamide therapy before debridement. It is significant that only 33 of the 97 wounds (approximately a third) were considered clean enough to close at once by delayed primary suture.

The second of these reports concerned 51 prisoners of war, in most of whom the timelag was also unusually prolonged. Delayed primary wound closure was carried out in all cases but was entirely successful in only 32 instances. Partial healing occurred in 15 cases. In the other 4 instances, the attempt at closure was a complete failure.⁶

Three of the 32 patients whose wounds healed satisfactorily after delayed primary suture had finally been performed had undergone debridement on the day of wounding. The average timelag in the other 29 cases in this group was 32 hours. Of the 19 patients in whom delayed primary suture was only partly successful or was completely unsuccessful, 6 underwent debridement on the day of wounding, but in the other 13 cases the average timelag was 72 hours.

Only 7 of the 51 patients in this series had received penicillin before debridement was done; they had had an average of 50,000 units each. Thirty-one others received approximately 120,000 units each after debridement. Two of the four patients whose wounds had failed to heal had received penicillin and two did not.

The figures in this series are far too few to permit conclusions, but they corroborate the generally accepted fact that the longer the delay between wounding and initial wound surgery, the higher is the incidence of infection and the less satisfactory is the healing process. These cases also demonstrate again that basic surgical principles cannot be violated with impunity and that adequate debridement is the keynote of success.

That the use or nonuse of supplemental antibiotic therapy was not the most important consideration in the determination of the end results of wound closure in this series is clearly shown in another series, which consisted of 107 compounding wounds in 73 soldiers. Sixty-three of the 73 patients had received penicillin, sulfadiazine, or both after admission to a general hospital. The largest number of complete or partial failures of wound closure occurred in these 63 patients, although in every instance in the series the wounds had been closed within 13 days, or less, after wounding, which is a fairly early timelag.

The figures, of course, must be interpreted with discretion. These wounds were unfavorable for a variety of reasons. When the cases are carefully analyzed, other factors, such as inadequate blood replacement, the location of the wound, and the size of the wound obviously require consideration. Nonethe-

⁵ Annual Report, Professional Service Division, Orthopedic Surgery, Office of the Chief Surgeon, European Theater of Operations, 1944.

⁶ *Ibid.*

less, in every failure or partial failure, the underlying reason was inadequate debridement; the use of chemotherapeutic or antibiotic agents was no guaranty of success when surgical principles were violated.

Combined Nerve-Bone Injuries

The exact frequency of peripheral nerve injuries in battle casualties is not yet known. If the experience of the 45th Evacuation Hospital between 24 June 1944 and 26 April 1945 is taken as typical, it is just over 1 percent.⁷ During this period, this hospital treated 14,891 surgical patients, all but 409 of the number with combat injuries. These patients presented a total of 20,740 separate wounds, 248 of which included damage to a major peripheral nerve.

About 75 percent of the compound fractures complicated by nerve lesions occurred in the upper extremity, with compound fractures of the humerus and injuries to the radial nerve comprising the great majority of these. Compound fractures of the femur, with division or other injury of the sciatic nerve, did not form more than 10 percent of the combined nerve-bone injuries. The distribution was fortunate. The humerus is not only easier to approach surgically than the femur but it also lends itself better to the shortening sometimes necessary in serious associated nerve injuries. A completely divided sciatic nerve which cannot be repaired leaves an almost useless lower extremity, even if the fracture of the femur heals in good position. In such cases, amputation occasionally proved the solution of the problem.

Routine of management.—Several months after D-day, after a joint visit to several specialized treatment hospitals for neurosurgery by the senior consultant in orthopedic surgery and the senior consultant in neurosurgery, the following plan of procedure in combined bone-nerve injuries was proposed to the Theater Chief Surgeon and after his approval became official policy:

1. All casualties with fractures associated with division of a major peripheral nerve were transferred immediately to one of the seven specialized hospitals for neurosurgery in the United Kingdom Base. The same policy was followed when it was suspected that the nerve was contused but not divided. There was, in fact, no sure method of ascertaining, within the first weeks after wounding, precisely how much nerve damage had been sustained.

2. Wounds of the soft tissues were closed as soon as possible, by suture, by skin graft, or by both methods.

3. Fractures of the long bones were treated with skeletal traction and balanced suspension. No effort was made at this time to obtain anatomic length of the bone, because the attempt was likely to defeat the objective of bringing the nerve ends together.

4. Physical therapy was employed as extensively as possible to encourage active motion of the unparalyzed muscles and to maintain mobilization of the joints of the extremities. It included both diagnostic and therapeutic electric stimulation of the injured part.

⁷ Semiannual Report, 45th Evacuation Hospital, European Theater of Operations, 1 January–30 June 1945.

5. Definitive neurosurgical and orthopedic surgical procedures were performed approximately 3 weeks after complete healing of the wound, which was usually 5 to 6 weeks after wounding.

6. After operation, if a circular plaster-of-paris splint was applied, windows were cut out over the muscle bellies, to allow postoperative electric stimulation of the paralyzed muscles. Some cases, as indicated later, were managed by skeletal traction with balanced suspension, without plaster.

7. A booster dose of tetanus toxoid was administered before each operation.

8. Penicillin was administered for 48 hours before each operation and for 10 days afterward.

9. Evacuation to the Zone of Interior was effected as promptly as possible, with a plaster splint in place.

Technical considerations.—The first step in the management of combined nerve-bone injuries was to secure closure of the wound. If simple suture was not sufficient, a skin graft was used. If the plan for the second operation was to approach the nerve injury through the original wound, full thickness of skin was required, and a full-thickness graft was used. Otherwise, a split graft was used.

After the wound had been completely healed for about 21 days, a second operation was done to explore the nerve injury and repair it as necessary. About 50 percent of the nerve injuries explored in the European Theater of Operations proved to be instances of contusion and not of division. The nerves were found intact and only neurolysis was required, though, as already emphasized, exploration was frequently required to establish this fact.

Whenever possible, the bone injury was cared for at the time that the nerve injury was repaired. This was frequently practical, especially when the neurosurgical center was part of a hospital center and competent orthopedic surgeons were immediately available. When the nerve and bone injuries could be repaired at the same time, it was estimated that the soldier was saved at least 6 months of hospitalization. If the combined operation was not possible, the nerve injury always took precedence over the bone injury.

The neurosurgeon first exposed the nerve and performed the necessary nerve surgery. If possible, nerve suture was performed. If it was impossible to bring the nerve ends together, no hesitancy was felt in shortening the bone, it being regarded as more desirable to have a shorter functional extremity than to have a paralyzed limb of normal length. Motion of the elbow joint was not impeded if the humerus was shortened on an average of 5 cm.

After the nerve repair had been accomplished, exposure of the bone offered no difficulty. Various methods of management of the fracture were employed. Fragments of the humerus were often held in position by one or two screws. Screws could also be used on the femur, or it could be plated. Bone fragments were often used as autogenous grafts, but care had to be taken to place them in such position that they would not impinge upon the nerve.

Balanced suspension with skeletal traction was preferably used after operation. This method had two advantages: Elevation of the limb prevented

edema, which was particularly undesirable after nerve surgery; and electric stimulation was easily carried out because the motor parts were exposed.

The percentage of shortening operations varied from hospital to hospital but was, on the whole, larger than might have been expected in view of the numerous injuries in which only neurolysis was necessary. Thus, in one 3-month period at the 117th General Hospital in the United Kingdom, 19 percent of the patients with combined injuries of the humerus and radial nerve required shortening operations.

The results in 10 cases treated by this technique at this hospital are fairly typical of the results achieved in shortening operations. The amount of shortening varied from 2.5 to 7 cm. and averaged 5 cm. Within an average of less than 11 months of hospitalization, 4 of the 10 patients received certificates of disability for discharge and had returned to civilian life, while 4 others were on furlough, in expectation of discharge under the same circumstances. No details are known of the ninth case except that the patient was discharged. The 10th patient had such a severe nerve injury that a tendon transplant was regarded as a better procedure than the 9 cm. of shortening which would have been required to approximate the nerve ends. Eight of these 10 patients had well-healed fractures when they were last seen. The only one whose fracture failed to heal satisfactorily was later treated by bone graft. In 8 cases, radial nerve function had ranged from 50 to 80 percent of normal when the patients were discharged from service.

Full details of the management of nerve injuries are set forth in the volume of this series dealing with neurosurgery.

Combined Vascular-Bone Injuries

Most often the vascular injuries associated with bone and joint injuries were caused by the direct effect of missiles, though occasional damage to the popliteal artery resulted from penetration of the vessel by bone fragments in supracondylar fractures of the femur. Vascular injuries associated with bone or joint injuries naturally took precedence over them and required immediate surgery. Full details are given in the volume of this series devoted to vascular surgery.

Almost without exception, loss of the leg above the knee resulted in all cases in which immediate ligation of the popliteal vessels was necessary. If ligation could be deferred for as long as 3 to 5 days, it was sometimes possible to perform the amputation below the knee, resecting the anterior lateral group of muscles, which was most frequently involved, and leaving the patient with a more useful stump. Ligation of the femoral artery below the level of the profundus was attended with little risk to the limb.

After ligation, the limb was protected from trauma and was kept cool. In the absence of edema, the dependent position was preferred. If edema was present, the limb was kept level with the body. Sympathetic blocks with Novocain were repeated as often as necessary, and in some hospitals the patients

were given small amounts of whisky by mouth to encourage dilatation of peripheral vessels.

Sympathetic block was of great value in the management of vascular spasm, which was often associated with compound fractures of the long bones of the extremities. It was also of value in persistent edema and in causalgia, which were other complications of bone and joint injuries. Sympathectomy was performed in some cases after the value of repeated sympathetic blocks had been established.

CHAPTER X

The Management of Compound Fractures— Techniques of Fracture Management

Plaster of Paris

Technique.—The following general instructions were issued for the application of plaster casts for transportation in evacuation hospitals:

1. The extremity must be put up in the proper position.
2. Joints proximal and distal to the fracture must be immobilized.
3. Heavy padding must be used freely, with felt or other material applied over bony prominences and major subcutaneous nerves.
4. Anterior and posterior plaster reinforcements must be applied smoothly; then they must be encircled with plaster bandages, which must be applied evenly and snugly and without tension. The turns of the plaster bandages must be rubbed until they form a homogeneous mass.
5. All circular plaster-of-paris casts must be split throughout their length and through all layers, or must be bivalved, as soon as the plaster has set.
6. After the cast has been applied, an outline of the wound and of the fracture must be drawn on it. Data must include the nature of the fracture (simple or compound), the date of injury, the date and hour of debridement, and the unit which treated the patient.
7. The circulatory status and the motion and sensation of the fingers or toes must be checked at frequent intervals after the cast has been applied. If there is any doubt of these facts, the upper half of the cast should be removed, or, if necessary, the entire cast, to be certain that the circulatory status of the limb is not impaired.
8. Symptoms and signs of pressure sores must be looked for. If they appear, a window must be cut in the cast and firm padding applied over the area.

Casts applied after delayed primary suture were usually changed about 10 days later. At this time, the sutures were removed, and new circular plaster splints were applied. No more padding was used than was absolutely necessary. Casts applied at this time, unlike the casts applied after delayed primary suture, did not need to be split, the chief reason being that the patients were in a general hospital and under constant observation. Furthermore, swelling was not apt to occur after reparative surgery.

Commanding officers of hospitals which evacuated patients to the Zone of Interior were instructed to pay particular attention to the condition of plaster casts in which they were to travel. Circular casts over open wounds were always changed just prior to departure. If the wounds had been successfully closed by primary suture, the same procedure was frequently followed but was

not necessary in all cases, since the splints did not become foul-smelling and stained with blood and discharge as they did in the open method of treatment.

The consultants in orthopedic surgery at first had some difficulty seeing that the rule for splitting plaster casts for transportation was universally applied. There was much less difficulty about insuring that enough padding be used. Both of these were fundamental considerations, about which vigilance could not be relaxed.

Other errors were also fairly frequent. Casts were sometimes unduly heavy. Spicas were too widely abducted. The feet were put in the equinovarus position. The knees were sometimes straight and sometimes hyperextended.

Before D-day, the plan was followed of having the medical officers who had made errors correct them immediately. Theoretically this was an excellent plan but practically it took up a great deal of time, which after the invasion could not be spared from more important duties. Furthermore, the same officers frequently continued to make the same mistakes in spite of the demonstration to them of their errors. Eventually, most orthopedic consultants and chiefs of sections arrived at the conclusion that as long as the basic principles of padding the extremity and splitting or bivalving the cast were adhered to, no permanent harm would come from minor errors which would be corrected in a few days anyway in a general hospital, when definitive surgery was done.

Plaster proved useful and effective for orthopedic purposes in World War II, though it had many obvious disadvantages. The hope is that in the future some plastic dressing may be devised which will permit direct inspection of the wound. If this type of material were available, it might not be necessary to use the enormous quantities of protective sheet wadding which must be used with plaster of paris, and direct inspection of the injury would be possible without removal of the cast. This would permit prompt detection and immediate treatment of incipient gas gangrene and other infections.

Tobruk Splint

Although the splint used by the British in North Africa as a transportation splint for casualties with fractures of the femur was called the Tobruk splint, the name was somewhat misleading. This splint was essentially the Thomas splint, which had been devised in 1870, reenforced with plaster of paris to keep it snugly on the limb while the patient was on his journey.¹ The standard method of application was as follows:

1. A wide posterior plaster splint was applied from the level of the upper thigh to a point 2 inches above the malleoli. Two 3- or 4-inch adhesive-plaster strips were applied to the skin of the leg on the medial and lateral aspects from just below the knee to the malleoli. The splint was applied with the knee in 15-degree flexion and was well molded by the use of a muslin bias bandage.

¹ Surgical meeting, 108th General Hospital, Paris, 26 May 1945.

2. The popliteal space was protected by a 6- by 6-inch piece of felt which was applied before the splint was applied.

3. The splint was anchored to the full-ring Army splint by circular plaster bandages which were applied loosely, so that they could be well crimped to both sidebars of the Army splint.

4. The circular bandages and sheet wadding were split down to the skin.

5. The foot was supported by the device attached to the splint for this purpose.

6. Approximately 5 pounds of active traction was applied by the use of elastic traction cord or plasma tubing attached to the adhesive-plaster strips and tied over a spreader to the end of the Army full-ring splint.

The Tobruk splint, according to its British advocates, was superior to the plaster spica in two respects: It could be applied more quickly, and it required less plaster and less water. In North Africa, where the splint was first used, these were undeniable advantages. British hospitals in forward areas were understaffed, at least by American standards, and supplies of plaster of paris were sometimes inadequate, while water was often difficult to obtain.

In the light of the British experience and recommendations, the Tobruk splint was accepted with enthusiasm by some American surgeons and a training film was produced to teach its correct application. All the orthopedic surgeons who entered the European theater in 1942 and early 1943 were instructed in the technique. Enthusiasm lessened, however, when the splint was observed under battle conditions. Members of the 3d Auxiliary Surgical Group who went to North Africa in January 1943 returned almost unanimously condemning it as inferior to a plaster-of-paris spica.

This did not end the discussion. The relative merits of the Tobruk splint and the plaster-of-paris spica continued to be argued. British consultants, at the meeting held with them by American Army consultants in Paris in October 1944, expressed the opinion that the United States Army Medical Corps was unwise in failing to use the Tobruk splint more extensively. To settle the question on the basis of facts rather than impressions, Lt. Col. John G. Manning, MC, consultant in orthopedic surgery, Ninth United States Army, was requested to conduct a controlled investigation and to report on it as soon as possible.²

Colonel Manning's investigation, which covered the months of November and December 1944, was carried out in five evacuation hospitals.³ During this period, 202 fractures of the femur were treated. One hundred forty-three of these were immobilized for transportation in the Tobruk splint. This technique was not used in the remaining cases for three reasons: (1) The ring of the splint would have caused pressure on a wound of the upper thigh or buttocks; (2) skin traction could not be applied because of wounds of the leg

² Annual Report, Professional Service Division, Orthopedic Surgery, Office of the Chief Surgeon, European Theater of Operations, 1944.

³ Semiannual Report, Professional Service Division, Orthopedic Surgery, Office of the Chief Surgeon, European Theater of Operations, 1 January-30 June 1945.

or fractures of the tibia or fibula; and (3) full-ring leg splints were sometimes not available. The British technique was followed as precisely as possible whenever the Tobruk splint was used.

A questionnaire was placed in the medical records jacket which accompanied each of the 143 patients, and Colonel Manning's report was based on the 63 which had been returned by 15 April 1945. While not all questionnaires were complete on all points, the following summarized data were obtained from them:

The 63 fractures of the femur included in the analysis consisted of 37 fractures of the shaft, 16 fractures of the upper third, and 10 supracondylar fractures.

The time required for application of the splint ranged from 10 to 45 minutes.

Between 6 and 12 rolls of 6-inch plaster bandage were used for each application, the average being 9 rolls.

The splint was kept in place from 1 to 25 days. The average range for the individual hospitals was from 4.4 days (in hospitals in Liège, Belgium) to 18 days (in hospitals in Normandy, France), and the average for the whole group of hospitals was 8.1 days.

The location of the fracture apparently influenced the surgeons' opinion of the value of the splint, though the number of cases is too small to be conclusive in any category. It was stated to be superior to the plaster spica in 1 of 15 fractures of the upper third and to be inferior in 14. In 36 fractures of the shaft, the splint was stated to be superior to the plaster spica in 8 and inferior in 28. In 10 supracondylar fractures, it was stated to be superior in 3 and inferior in 7. For the 61 cases in which this information was available, the splint was thought to be superior to the plaster spica in 12 and inferior in 49. Inconclusive as are these figures, there was no doubt of the preference of American surgeons for the plaster-of-paris spica.

Information as to the patients' opinion of the splint was also secured in 62 cases (table 3). At the meeting of the consultants in May 1945,⁴ at which the report of this investigation was made, the Theater Chief Surgeon agreed with the criticism voiced by one of the British surgeons present, that it was rather risky to draw statistical conclusions from a patient's evaluation of his

TABLE 3.—*Patients' opinions of Tobruk splint in 62 fractures of the femur*

Opinion	Location of fracture			Total
	Upper third	Shaft	Supracondylar	
Comfortable.....	2	13	5	20
Uncomfortable.....	10	15	3	38
Painful.....	3	9	2	14
Total.....	15	37	10	62

⁴ See footnote 1, p. 110.

own comfort, and further agreed that a casualty with a fractured femur and compounding wound was unlikely to be very comfortable at the best.

The majority of surgeons who reported on these cases stated that the Tobruk splint could be applied more rapidly and with less effort than the plaster spica. They agreed that patients were comfortable in it as long as they remained in an evacuation hospital. They felt, however, that this splint was not suitable for all fractures of the femur and that it did not supply adequate or comfortable transportation. They therefore regarded it as inferior to the plaster spica for transportation purposes.

A number of complications were recorded in these 63 cases. In 11 instances the ring of the splint had become displaced medially, causing pressure, pain, and discomfort in the perineal area. In 2 instances, superficial pressure sores resulted from pressure on the buttocks.

Two of the 63 patients required amputation, but in neither instance was the splint responsible. In 1 case, the circulation in the leg and foot was unimpaired, but massive loss of soft tissue, bone, and sciatic-nerve tissue made it impossible to save the limb; this patient died after a transfusion reaction. In the other case, the popliteal artery and vein had been ligated when debridement was done. Amputation was required in a general hospital in the United Kingdom 5 days later, presumably for gangrene of circulatory origin.

This report, which was read at a final meeting of British, Canadian, and United States Army consultants in Paris in May 1945,⁵ produced vigorous discussion but changed few minds. The British and Canadian surgeons remained convinced of the value of the splint. American medical officers continued to favor the plaster spica for transportation splinting in fractures of the femur. The interesting point was made, in the concluding remarks on the subject, that the Tobruk splint was almost the only important matter on which all Allied medical officers were not in substantial agreement concerning the principles and techniques of orthopedic practice.

Skeletal Traction

Skeletal traction proved in World War II to be the safest and simplest method of mass treatment of compound fractures of the long bones. Immediate results achieved overseas and followup reports from observers in hospitals in the Zone of Interior all supported this point of view. One of the great advantages of this technique, furthermore, was that it was readily mastered by the general practitioners, obstetricians, pediatricians, and other medical officers who had had no previous experience with fractures in civilian practice but who often had to be assigned to surgical services in overseas hospitals because of shortages of trained personnel.

During active combat, the holding period on the Continent was never sufficiently long to permit the routine treatment of fractures of long bones by skeletal traction. This technique was, however, widely used in United Kingdom

⁵ See footnote 1, p. 110.

hospitals. Originally, it was chiefly employed for compound fractures of the femur. After the visit of The Surgeon General to the European theater in July 1944, its use was extended to fractures of the tibia and the humerus, and, in some instances, it was also used for fractures of the forearm.

In the United Kingdom Base, the holding period for compound fractures varied from 5 to 10 weeks, depending upon the type and site of the fracture. If a patient was received within 7 to 14 days of wounding, he could be treated in continuous traction after the wound had been closed by delayed primary suture. The patients were comfortable, and the results from every standpoint were usually good. Reduction was maintained satisfactorily, and wound healing was ordinarily prompt. Every effort was made to encourage exercises which would prevent atrophy of the regional muscles, as well as to secure free motion in the joints above and below the site of the fracture. If these exercises were carried out as directed, functional results were usually good. Practically always the explanation of poor results in cases in which the severity of the original injury did not explain them was either failure to give proper attention and constant supervision to the apparatus in which the patient was put up in continuous traction or failure to carry out exercises as directed.

Patients were held in overseas hospitals until their fractures had frozen sufficiently to assure maintenance of position in a plaster cast during the period of transfer to the Zone of Interior.

As noted elsewhere, it was interesting to observe how conveniently, when the necessity arose, patients in traction could be cared for in tented wards, though the necessary equipment reduced the number of beds from the usual 30 to 15. In the busiest times, some hospitals had as many as 35 or 40 patients in traction in tents, and many had 200 or more in traction at the same time in wards.

While skeletal traction was, generally speaking, the most universally satisfactory technique for the mass management of compound battle-incurred fractures, each injury required individual analysis with careful consideration of such factors as the location and type of the fracture, the position and size of the wound or wounds, the extent of destroyed or paralyzed muscle, the need for ready accessibility to the wound for secondary operations and dressings, and the necessity for skin grafts and nerve suture.

Only occasionally could traction alone be depended upon to effect satisfactory reduction. Before traction was instituted it was almost always necessary to reduce the fractures by carefully planned, gentle manipulation, which was usually carried out under intravenous Pentothal Sodium (thiopental sodium) anesthesia, supplemented by oxygen and nitrous oxide. Exploration, wound closure, and suspension of the fractures constituted a major surgical procedure, which often occupied several hours. Both before and after operation, blood replacement, maintenance of the fluid balance, and the administration of antibiotics and of dietary supplements were matters of great importance.

The Kirschner wire was almost always used for skeletal traction, with the Steinmann pin reserved for special cases. In many instances, the greater

surface area of the heavier Steinmann pin might have provided a theoretic advantage, but the Kirschner wire was better tolerated. Experience soon showed that, for optimum results, the wire must be inserted with the limb in its final position in traction. If, for instance, the knee was flexed after a wire had been inserted transversely in the supracondylar area of the femur with the leg in extension, the skin and subcutaneous soft tissues would be folded against or stretched around the wire, and, within a few days, there would be an infected conical cavity extending down to the bone.

It was perfectly practical, however, to use the wire and tautener as a handle for manipulation. When this was intended, the limb was placed in its final position, the wire was inserted, and the necessary manipulations were then carried out.

Whenever possible, the wire was inserted at right angles to the long axis of the bone. The skin was punctured directly by the wire at the point of entrance. On the opposite side, the wire was allowed to create its own aperture for exit. Because of the normal process of bone resorption, even correctly inserted wires became loose 7 to 8 weeks after insertion. Sterile felt, cork, or sponge rubber was inserted between the skin and the tautening bow to prevent the wire from sliding; individual surgeons used for this purpose whatever they happened to have available.

Wires were never inserted into bare bones or through wounds. It was almost always possible to use adjacent areas with normal uninjured bone and skin and to adjust the skeletal traction to compensate. When the proper precautions were taken, infection, loosening, and drifting of pins or wires, and even ring sequestra appeared far less often than might have been expected. Chronic osteomyelitis practically never occurred.

The amount of weight required to maintain reduction was, on the whole, less than was required in similar fractures in civilian life. The explanation was the large volume of destroyed or paralyzed muscle in battle-incurred fractures. When this factor was borne in mind, distraction was readily avoided.

As a rule, patients were put up in permanent traction immediately after delayed primary wound closure, preferably while they were still under anesthesia. In an occasional hospital, this practice was not followed. Instead, the patient was put up in temporary traction and taken to the recovery ward for 24 to 48 hours. This was a bad practice as well as an unnecessary precaution; a properly managed patient almost never went into shock after delayed primary wound closure. On the other hand, when he was placed in traction twice, he sometimes went into shock after the movement and manipulations required by the secondary procedure. From the standpoint of the injury itself, this practice was also undesirable, particularly in fractures of the femur. The continued manipulation of fragments frequently meant loss of position, as well as considerable discomfort to the patient.

In some hospitals, skeletal traction was used so extensively that, as in the 22d General Hospital, a medical corpsman was designated as the traction technician. His only duties were to make continuous rounds to refresh traction

slings and adjust apparatus. Once daily, he applied 70-percent alcohol to the skin dressings around the pins. The value of the antiseptic application was open to question, but this was a simple and certain way to assure that the technician carried out his major duties on every patient. The morale factor was also important. The maintenance of skeletal traction was a matter of teamwork, and the application of the alcohol, it was found, helped to make the technician feel that he was an important member of the team.

External Fixation

Some of the compound fractures which occurred at Pearl Harbor the opening day of the war were treated by external skeletal fixation. Unfortunately, the reports which described the experience not only concerned too small a series of cases for objective evaluation of this method but were also published prematurely, before the followup was sufficiently long for a fair estimate of results. The enthusiasm of the first reports, however, was contagious, and before it could be shown to be unjustified the Army had invested heavily in various forms of apparatus for external fixation, and inexperienced young Army surgeons had used the method in a fairly large number of cases.

External fixation soon proved itself to be a method totally unsuited to the general management of military casualties. It had an extremely restricted field of usefulness, and, unless the patients were selected with the greatest care, its use in both simple and compound fractures was inevitably associated with a high percentage of both infection and delayed union. In the relatively small number of cases in which the method was used in the European theater, with pins incorporated in circular plaster casts, distraction of the fractures and pinhole osteomyelitis occurred very frequently. The use of the method was therefore forbidden, and the apparatus was removed from the hospitals.⁶

Internal Fixation

In certain simple fractures, open reduction and internal fixation sometimes seemed to be the only way to secure union with proper alinement. In compound fractures, anatomic replacement of the fractured bones with maintenance of their position by internal fixation was also sometimes indicated. Fractures of the long bones adjacent to joint surfaces often could not be managed in any other way.

In simple fractures, in which internal fixation is seldom indicated, this technique was probably used more often than it should have been. In compound fractures, it proved a useful method in certain carefully selected cases but one that was completely unsuited for general use. Often it was an extremely formidable procedure.

Internal fixation had to be performed with a number of precautions, one of the most important being strict attention to the preoperative blood level.

⁶ Circular Letter No. 131, Office of the Chief Surgeon, Headquarters, European Theater of Operations, 8 November 1944, Care of Battle Casualties, Treatment of Wounds of Bones and Joints. (See appendix A, p. 325.)

The hematocrit had to be raised to at least 40. Surgeons rapidly learned that in this operation, as in many others, there was no substitute for whole blood in the preoperative preparation of patients.

After penicillin became available, in the spring of 1944, it was administered routinely before all internal-fixation operations. It was given, as a rule, in 25,000-unit doses at 3-hour intervals before surgery and as long thereafter as it was indicated. As time passed, it was found that the postoperative period of administration could be shortened considerably over what had previously been thought necessary.

Minimal traction was used until the wound was healed. No comparative figures are available, but the clinical impression was that this practice, in addition to adding to the patient's comfort after operation, shortened the hospital stay and improved the anatomic and functional results.

One other consideration was extremely important in the use of internal fixation: This method could be used with safety and with relative frequency before D-day, when the general and station hospitals were staffed with qualified surgeons experienced in this technique. As newer hospitals began to arrive staffed with officers who were less adequately trained in bone and joint surgery, its use had to be considerably curtailed, even for noncombat injuries. With the great majority of surgeons who were treating military casualties both under-trained and inexperienced, disaster would have been inevitable if permission had been given for the general employment of this method. For this reason, and for the reasons already stated, internal fixation was forbidden as a primary procedure.

Reports from special hospitals in which internal fixation was correctly used, with discretion and in properly selected cases, show both the possibilities of the method and its extremely limited field. It was used, for instance, in only 71 cases at the 46th General Hospital. These included 30 fractures of the femur, 14 of the tibia, 13 of the humerus, 6 of the ulna, 5 of the radius, 2 of the patella, and 1 of the clavicle. The distribution of cases indicates the relative usefulness of the method in various regional fractures. Examinations of the records showed that without exception these patients did well in the hospital. There was not a single serious postoperative infection. Dependent drainage was often necessary in femoral fractures, and a posterolateral incision was used. Healing usually occurred promptly.

The 23d General Hospital had a similar experience. Internal fixation was used only 55 times in 1,628 bone and joint injuries observed over a 2-month period while the hospital was operational in Italy, and the proportion of operations in the European theater was roughly the same.

On the other hand, it is doubtful that the end results of internal fixation were as good as the immediate results seemed.⁷ In communications between The Surgeon General's Office and the Theater Chief Surgeon during the winter of 1944-45, it was pointed out that a review of patients treated in the Mediter-

⁷ Circular Letter No. 23, Office of the Chief Surgeon, Headquarters, European Theater of Operations, 17 March 1945, Care of Battle Casualties, Orthopedic Surgery. (See appendix A, p. 330.)

ranean theater by internal fixation had revealed several disturbing facts. One was that it was necessary to remove the metal in from 25 to 40 percent of all cases in order to end drainage and permit healing. It also seemed that this method had been used in numerous cases in which the indications were doubtful. The Surgeon General therefore proposed that this method be reserved strictly for cases in which there was no doubt of the indications. He also proposed that two series of compound fractures, one treated by the usual method and the other by internal fixation, be studied from the standpoint of wound healing and fracture healing, with particular reference to the position of fragments and the incidence of osteomyelitis. An incidence of infection of 25 to 40 percent was so far in excess of the incidence in patients treated by delayed primary suture and skeletal traction that it seemed essential to know whether the increased accuracy secured in reduction of fractures by internal fixation compensated for the higher rate of infection. The fighting in Europe ended before this study could be made.

CHAPTER XI

Regional Injuries

The amount of mechanized equipment used by the United States Army in World War II accounted for the extreme frequency of noncombat injuries both before and after D-day. Traffic injuries were also distressingly frequent. At the 801st Hospital Center, for instance, it was startling to learn that of 150 consecutive compound fractures treated immediately after D-day, 30 were caused by accidents which had nothing at all to do with fighting. Simple fractures were much more frequent in noncombat than in combat injuries, in which compound fractures, often with serious comminution, were the general rule.

It will be observed that in this chapter a distinction is made between the management of noncombat and combat injuries of the bones and joints, as well as between the management of injuries before and after D-day. Before D-day there was time—though perhaps not always justification—for techniques of management which would have been completely unwarranted when hospitals had become crowded with battle casualties whose need for treatment was urgent.

Forearm

Many of the fractures of the forearm treated before D-day were of the type usually encountered in civilian practice and were managed in much the same way as similar fractures would be managed in civilian life. Special types of fractures, especially fractures of the radial head and of the carpal scaphoid, were frequent and will be discussed in detail later in this chapter. A large number of Monteggia's fractures were handled at the 803d Hospital Center, whose staff believed that the best results were accomplished by early surgery on the ulna, through an incision which gave complete exposure of both the fracture and the elbow joint. The procedure consisted of internal fixation of the ulnar fracture, reduction of the head of the radius, and suture of the orbicular ligaments.

Wounds of the forearm of combat origin usually healed well after delayed primary suture. Special methods of reduction were, however, often necessary to establish bony continuity, in order to speed healing and improve functional results. The difficulty in fractures of the radius and ulna was to effect and maintain reduction. They were preferably put up in plaster of paris in moderate pronation. A decided tendency was noted on the part of some surgeons who had had no special orthopedic training to put them up in full supination. Cross union was inevitable in most cases in which this position was maintained for any length of time. If the patient was caught in the chain of evacuation for 3 or 4 weeks, as could readily happen, the initial bad position was likely to become permanent.

Skeletal traction.—When simple reduction of fractures of the bones of the forearm was not sufficient and open reduction was contraindicated because of the seriousness of compounding wounds, infection, extensive bleb formation or other complications, unstable fractures of the shaft of the radius and ulna were sometimes managed by the use of heavy Kirschner wires to maintain reduction. At the 298th General Hospital, the practice was to insert one wire through the bases of the second, third, fourth, and fifth metacarpals and a second wire through the olecranon process, after which spreaders were applied and the fragments were manipulated into good alignment. The wires were then incorporated in a long arm plaster-of-paris cast, the spreaders being removed after the plaster had set firmly. The wires were withdrawn at the end of 6 weeks, but immobilization was continued until firm union had occurred. Careful selection of cases was essential. No serious complications were encountered in the fractures in which this method was used, and it served as a satisfactory alternative to open reduction in some of the cases in which the latter method was contraindicated.

At the 802d Hospital Center skeletal traction was used in 30 fractures of the bones of the forearm, as follows:

Wires through the olecranon process and distal radius were used in 20 fractures of the proximal radius and ulna. The ulna could usually be controlled very well, but satisfactory realignment of the proximal third of the radius was much more difficult to achieve.

Traction through the metacarpals was used in 10 fractures of the distal radius and ulna. A nice adjustment of ulnar or radial deviation was necessary, and particular care was required to insert the wire and preserve the palmar curve of the hand. The wire did not always transect all four metacarpals, and the method was extremely difficult to apply, even when an experienced technician was in charge of the case. This particular technique also had other disadvantages, such as the following:

Patients were reluctant to exercise the fingers because movement was painful and because even the slightest fixation of the carpometacarpal joints interfered with the rotation, gliding, and interaction of the complicated, highly flexible joints of the hand. When the fracture was in the distal or middle third of the radius, traction through the metacarpal of the thumb or the styloid process of the radius, with the hand put up in ulnar deviation, proved a satisfactory method of management. At this hospital center, traction was practically never used in fractures involving only the ulna.

When fractures of the radius were associated with extreme shattering of the fragments, the collapse of the bone was often enough to cause radial shortening. Radial deviation was then the end result, even when the cast had been carefully applied in ulnar deviation. One alternative, the application of traction through the carpus or the first metacarpal, was not viewed with particular favor, since traction had to be maintained at least 8 weeks to obtain solid union. Many surgeons thought that more satisfactory function of the hand and wrist could be obtained by a technique which permitted earlier removal of

the cast, even though a later resection of the ulna might be necessary to correct radial deviation. The relative end results of the two techniques are not known, since wartime exigencies made followup of most patients entirely impractical.

Internal fixation.—Internal fixation was the preferred method of management of compound fractures of the radius and ulna which could not be handled by more conventional methods. In many cases, however, in which comminution of the radius was considerable, it appeared, regardless of the technique employed overseas, that osteotomy and bone grafting would eventually be necessary in Zone of Interior hospitals.

Fractures of the Radial Head

In the early orthopedic literature, fractures of the head of the radius, although they were always recognized as important because of the disability they caused, were regarded as rather uncommon. The increasing use of roentgenograms helped to overturn that impression, though many incomplete vertical fractures, and even some complete fractures, continued to be diagnosed as sprains of the elbow.

This civilian type of injury assumed considerable importance in World War II not only in training areas but also overseas, where it accounted for a considerable loss of days from duty. For that reason, two typical series of cases are presented in some detail.

The 168th Station Hospital, according to a report by Maj. Nathaniel Gould, MC, treated 49 of these injuries in England in 1943 and 1944. The 65th General Hospital, according to a report by Maj. Julian E. Jacobs, MC, and Capt. Harold B. Kernodle, MC, treated 42, also in England, in the course of 10 months. The latter hospital, over the same period, treated 10 simple fractures of the radial neck, 2 Colles' fractures, 2 Smith's fractures of the distal radius, and 100 simple fractures of the scaphoid bone.

Nature of the injury.—The history of the injury in fractures of the radial head is sometimes that of a direct, forceful blow upon the elbow, or a fall upon the elbow. Much more often, and much more typically, the story is of a minor accident, a fall from a bicycle or a ladder, or merely a fall, with the attempt, whether the fall is forward or backward, to break its effect against the outstretched hand, with the forearm partly pronated and the elbow slightly flexed. In the fractures under consideration in the two overseas hospitals these stories, which are typical of injuries in civilian life, were frequently heard, but the histories also included falls from the wings of planes, or simple falls during the blackout.

The regional anatomy (fig. 23) serves to explain the result of such accidents. Grossly, the head of the radius is of the same bony composition as the patella, with the columnar type of dense cancellous bone running lengthwise. That is why the plane of the fracture is so often longitudinal. The head, which is rounded on its lateral aspect and somewhat hollowed on its proximal end, to permit articulation with the capitellum of the humerus, is entirely covered by articular cartilage. Unless the articulation is almost anatomically perfect, full

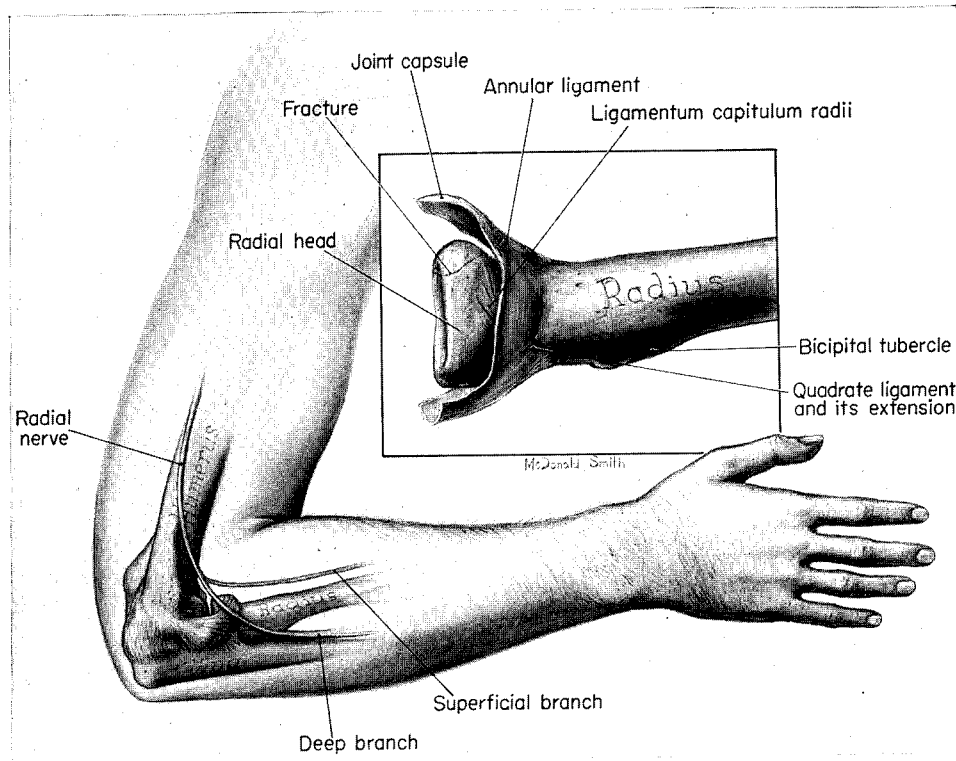


FIGURE 23.—Lateral view of partly dissected joint of right elbow, showing relationship of radial nerve to annular ligament. Insert shows ligamentum capitulum radii as continuation of quadratus ligament. Note relationship of biceps tubercle to fracture with forearm pronated (from dissected specimen, Cambridge University Medical School).

supination and pronation of the forearm will not be possible. As a result of the fall or other accident which causes the fracture, and the effort to break its force, an abduction force is transmitted through the head of the radius to the capitellum. The degree of leverage and the resulting angle at which the pronated radial head is driven into the capitellum determine both the degree of comminution and the degree of displacement which result. Unless the coronary ligament, by which the radial head is strongly bound to the ulna, should rupture, the general contour of the radial head will be maintained, even if mushrooming occurs.

The radial head is entirely covered by articular cartilage. The posterolateral continuation of the attachment of the quadratus ligament (ligamentum capitulum radii) is covered by a distinct fold of synovial membrane (fig. 23), which is a fact of importance in cases treated surgically.

The abduction force which damages the radial head also traumatizes the medial capsule. This explains why, even late in the followup, some patients may complain of discomfort about the medial aspect of the elbow joint. In the 42 patients treated at the 65th General Hospital, 3 of 28 with mild fractures

in the form of simple cracks of the bone and 2 with comminuted or displaced fractures complained of this type of pain. The fact that patients with much more severe injuries did not complain of it was explained in those cases by dissipation of the abduction force by collapse of the radial head.

Classification.—All 49 fractures of the radial head observed at the 168th Station Hospital were classified as simple. The 42 fractures treated at the 65th General Hospital were divided into three groups:

1. Twenty-eight fractures, two-thirds, were simple cracks, in the form of a single longitudinal cleft across the head, without depression (fig. 24) or with a slight depression (fig. 25). In this type of fracture, there was no actual increase in the circumference of the head. The abduction force had been applied briefly to the anterolateral segment of the head against the capitellum (fig. 26). All fractures in this group could be treated conservatively.

2. Five fractures in which the circumference of the head had been increased moderately by comminution or had been disturbed by marginal displacement of the anterolateral segment (fig. 27). All 5 cases were treated conservatively, though the question of surgical excision was raised in one or two.

3. Nine fractures in which there was marked displacement of one or more bony fragments (figs. 28 and 29). All these cases were treated surgically.

The circumstances of the accident determined the side affected. In these 42 cases, the distribution was almost equal, 22 of the fractures being on the left side and 20 on the right.

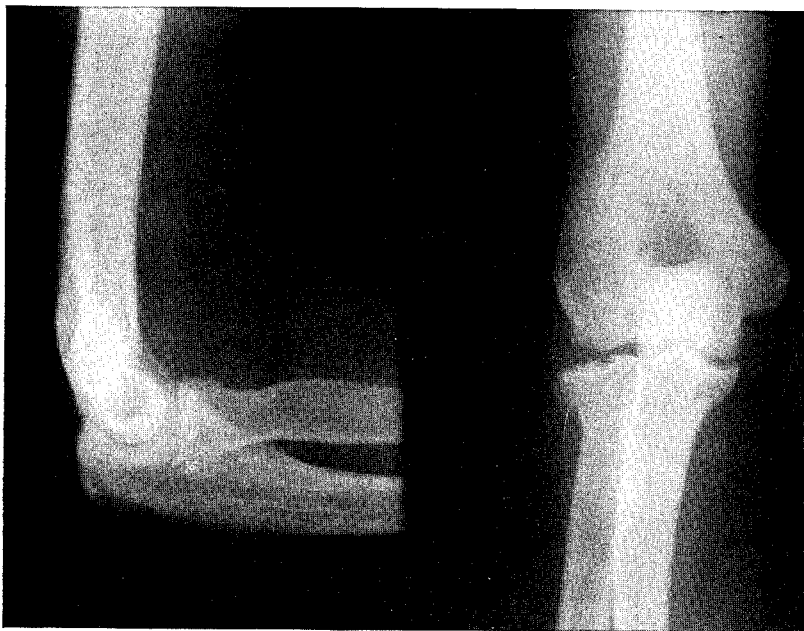


FIGURE 24.—Cleft fracture of radial head, group 1, 10 months after patient had sustained a "sprain." Note persistence of fracture. (See also figures 31 and 33.)

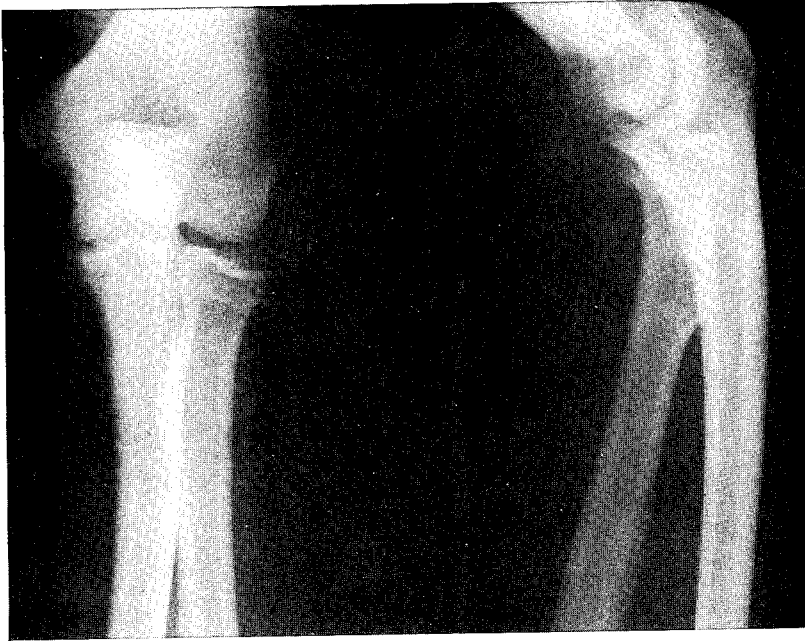

FIGURE 25.—Cleft fracture of radial head, group 1. Note slight depression of anterolateral segment.

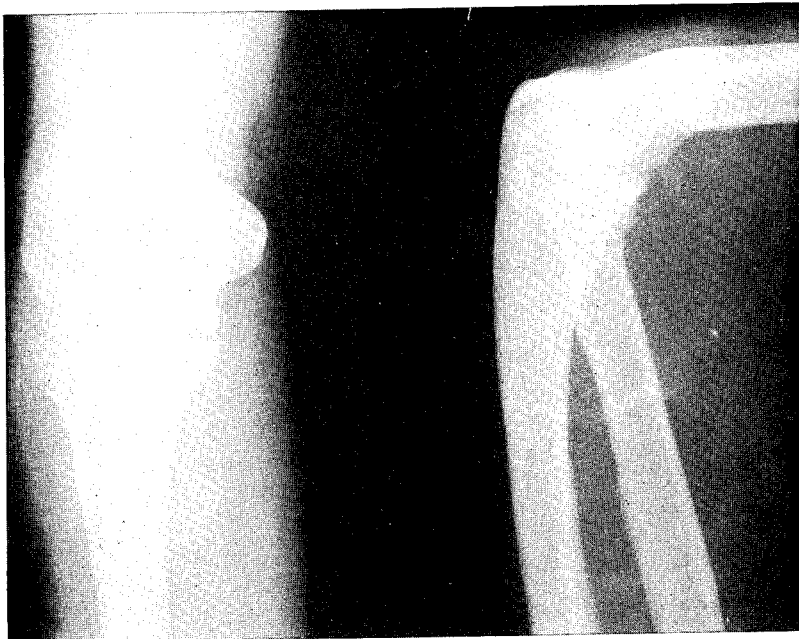


FIGURE 26.—Fracture of radial head, group 1, with forearm in pronation (position at time of injury), showing relationship of fractured segment to capitellum.

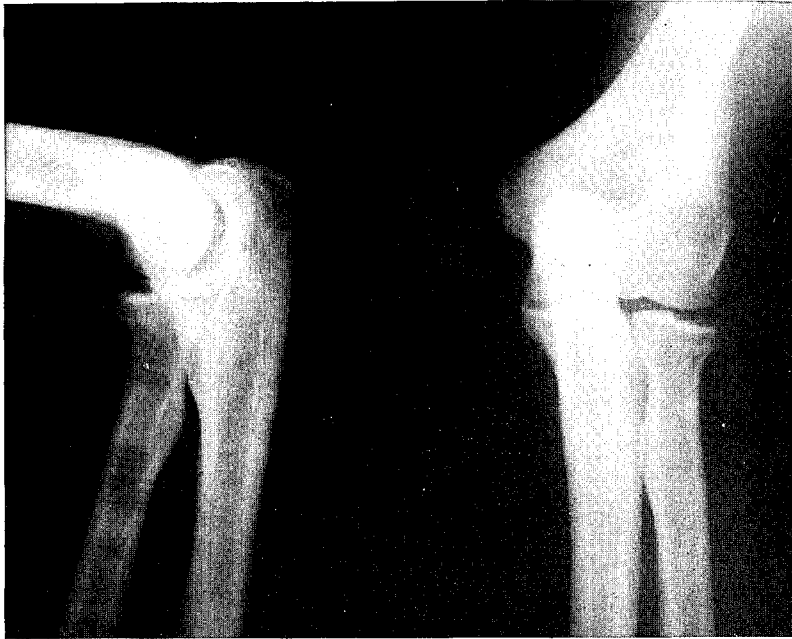

FIGURE 27.—Fracture of radial head, group 2, with comminution and some displacement.

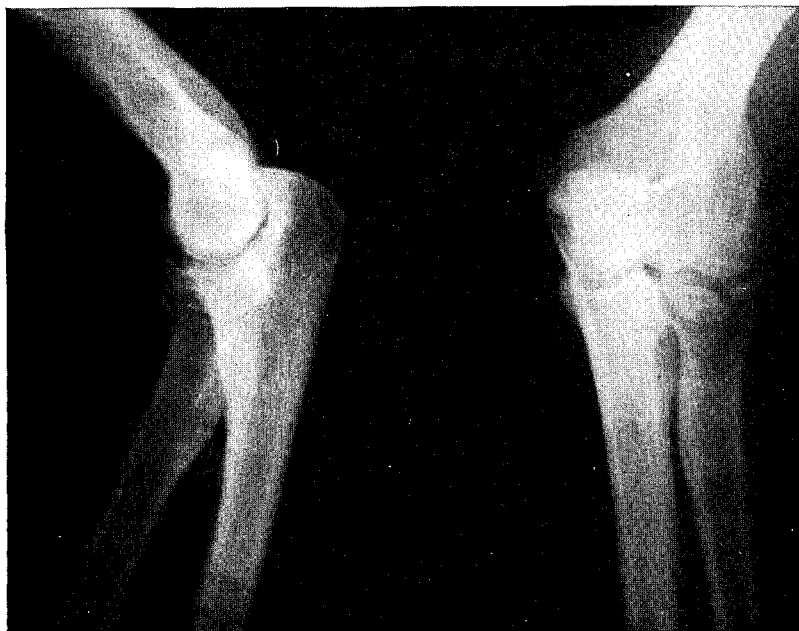

FIGURE 28.—Fracture of radial head, group 3, with severe comminution involving entire head.

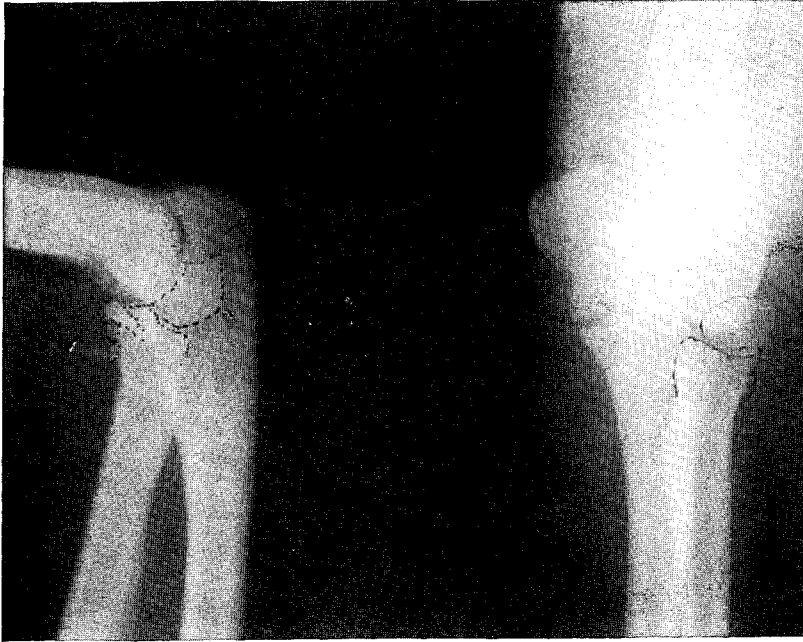


FIGURE 29.—Fracture of radial head, group 3, showing severe comminution with displacement.

Diagnosis.—The diagnosis of this injury presented no difficulty in either of these series, partly because the story was always typical and partly because the relative frequency of the fracture made it impossible not to bear it in mind as a possibility. Usually, as already noted, there was a history of a fall upon the extended hand, with the forearm also extended. Less often there was a story of a direct fall or blow on the elbow. As a rule, immediate discomfort was slight, and a full range of motion was possible for some hours. Then the elbow began to feel stiff, there was pain of increasing severity even when the arm was at rest, and there was severe pain on motion. The pain was always most severe on attempted supination. A full range of motion was impossible. The arm could not be extended completely, and full flexion was also impossible. The limitation of motion was chiefly due to hemorrhage into the elbow joint, which is almost invariable in this type of fracture.

An occasional patient with a fracture of the radial head complains of discomfort or pain referred to the wrist. This type of pain was not observed in any of the cases in this series. On the contrary, the absence of clinical or radiologic evidence of trauma to the distal radio-ulnar joint was repeatedly noted. When pain in the wrist is present with a fracture of the radial head, it is best explained as referred pain. The explanation is that the wrist joint is innervated by the terminal branches of the deep branch of the radial nerve, which has conceivably been irritated by trauma to the radial head.

When the patients in this series were first seen, the position of the injured extremity was usually typical. The forearm was supported, in neutral position, with the elbow flexed 100 to 135 degrees. Attempted supination of the forearm by either the patient or the examiner caused great pain, especially in the region of the radial head. Palpation over the head of the radius elicited a complaint of tenderness. An effusion, which invariably proved hemorrhagic, could be demonstrated in the joint.

Anteroposterior and lateral roentgenograms confirmed the clinical diagnosis.

Management.—It was the practice at some hospitals in the European theater, when fractures of the radial head were encountered, to decide immediately whether the damaged head should be excised or be left in situ, on the ground that delay in excision might end in the development of a degenerative arthritis between the radial head and the capitellum. If surgery was decided upon, it was carried out as promptly as possible, on the ground that to delay excision for a period of months and then perform it for the relief of a painful elbow was simply tempting fate, since arthritis is almost never relieved by delayed surgery. It was the practice at other hospitals to treat fractures of the radial head conservatively unless the articular surface was badly damaged. This policy was followed even if there was a slight angulation at the neck. The two series of cases upon which the foregoing discussion has been based were chiefly treated conservatively.

At the 168th Station Hospital, 43 of the 49 fractures of the radial head were treated conservatively but as immediate emergencies.¹ As soon as the clinical diagnosis had been made and had been confirmed by roentgenograms, the patient was taken to the operating room, where the joint was aspirated under strict sterile conditions. The surgeon wore gloves and was masked, and his assistants were also masked. The elbow, after it had been prepared with iodine and alcohol, was draped with sterile towels.

After the affected area had been injected with sterile Novocain solution (2 percent), a No. 20 intravenous needle was introduced into the joint and aspiration was continued until all the blood had been evacuated. The amount removed ranged from 6 to 36 cc. and averaged between 18 and 20 cc.

A well-padded plaster cast was then applied from the midarm to the base of the fingers, with the forearm in neutral position and the elbow at 90 degrees. In the early experience, the cast was kept on the arm for 7 days. As experience increased, it was removed on the fourth day.

As soon as it was removed, the patient was sent to physical therapy. He kept his arm in a sling for the remainder of that day but discarded the support the following day. Exercises in the physical-therapy department consisted of active flexion and extension exercises, at first with a 2-pound weight, pulley, and rope. On the following day, the weight was gradually increased until a maximum of 15 pounds was reached. Massage and whirlpool treatments to

¹ The 6 other patients, because of associated fractures of other bones, had to be transferred to a general hospital for treatment, since theater policy limited the holding period in station hospitals to 30 days.

the arm, forearm, and elbow were also used. In the later part of the experience, formal exercises were supplemented by hot water soaks and by exercises on the ward. Since pain was relieved dramatically almost as soon as the joint was aspirated, only the occasional patient had to be persuaded to carry out these instructions. Incidentally, no patient in this series required any sedation.

At the 65th General Hospital, 33 patients (groups 1 and 2) were treated conservatively and the other 9 (group 3) by surgical measures.

The 28 (group 1) patients with simple noncomminuted or nondisplaced fractures used slings for a week or 10 days, but aspiration was employed only if the joint was tense. It was repeated as necessary. It was preferred, when aspiration was indicated, to delay it for 24 hours after injury, by which time active bleeding had usually ceased.

In the 5 cases in group 2, the same type of treatment was used, unless comminution was considerable. Then a plaster splint was applied for 10 to 14 days, with the forearm in neutral position and the elbow at a right angle. When the splint was removed a sling was employed. Aspiration was carried out in 2 of the 5 cases in this group but was not thought to have influenced the end results. Heat and light massage were employed when the splint was removed.

The 9 patients in group 3 were subjected to surgical excision of the entire radial head. It was not always possible to determine, before direct inspection, whether excision could be limited to the small fragment demonstrated roentgenologically or whether so much comminution would be found that resection of the entire head would be necessary. Total resection was necessary in all 9 cases in this group. Trauma to the articular cartilage, which was not revealed by roentgenograms, was also considerably greater in every case than had been suspected.

The technique of operation was as follows:

A sphygmomanometer cuff, inflated to 200 mm. Hg, served as a tourniquet. An incision was made extending from the lateral epicondyle through the conjoined tendon of the extensor digitorum and the extensor carpi ulnaris (fig. 30). It was usually about 2 inches long. It extended down to, but not beyond, the annular ligament. Care had to be taken not to cut or otherwise traumatize the deep branch of the radial nerve by traction on the supinator muscle mass. Adequate exposure of the joint could always be obtained by carrying the incision to, or proximal to, the epicondyle.

When the forearm was fully pronated, the triangular ligament came into view through the incision. The relationship of this ligament to the bicipital tubercle and the fracture (fig. 23 insert) which had been demonstrated at the anatomy table was invariably confirmed.

The ligamentum capitulum radii was stripped with the osteotome down to the point at which it blends with the synovial reflection, to provide a flap that could be sutured across the raw stump. The use of a sharp osteotome, held rigidly at the base of the radial head, proximal to the annular ligament, produced a smooth stump. Frequent light tapping, together with rotation of

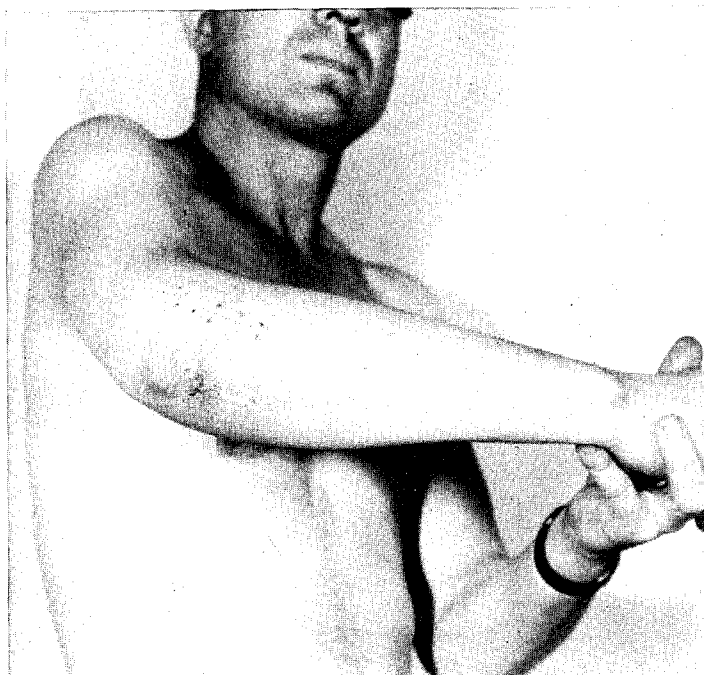


FIGURE 30.—Lateral incision at elbow used in resection of radial head.

the forearm through 150 degrees, left a smooth cut and offset the minute bony fragments that resulted from the use of the Gigli saw. Any shredding of the cartilage over the capitellum was then pared down. Further inspection of the lateral joint compartment and visualization of the humeroulnar joint allowed removal of any interposing fragments.

The ligamentum capitulum radii, which had previously been reflected, was now sutured across the smooth radial neck, completely covering it. The incision was closed in layers, (1) the synovial membrane and capsule, (2) the split conjoined tendon, and (3) the skin.

After the wound had been dressed and the arm covered with sterile sheet wadding, a plaster cast was applied, with the elbow flexed to 90 degrees and the forearm in neutral position.

At the end of 14 days the cast was removed, the skin sutures were removed, and active motion and physical therapy were begun. A sling was worn for the next 14 days.

End results.—At the 168th Station Hospital, where treatment was entirely conservative, the hospital-stay days ranged from 12 to 26. In the first cases, when the cast was worn for 7 days, the stay days averaged 22. In the later cases, when the cast was maintained for only 4 days, the average stay days were 15. An additional reason for the reduction in the period of hospitalization was the more intensive physical therapy in the later cases and the

self-treatment on the ward with hot water soaks and continued flexion and extension exercises. In the cases treated later, a more intensive effort was also made to gain the confidence of the patient and to assure him that the continuous rigorous workout would help his arm and not injure it. One patient, who was on duty in the hospital, was treated as an outpatient, with satisfactory results. There were no readmissions after discharge.

There were three criteria for discharge, (1) freedom from pain, (2) complete pronation and supination, and (3) flexion or extension disability of no more than 8 degrees.

Forty of the forty-three patients treated at the 168th Station Hospital could be followed up for 2 months or more after their discharge. Results were good in all 40 cases. Most patients had no disability at all at the end of the period of observation and all of them were on full duty and had no difficulty in performing their duties. These results were attributed to the brief period of bleeding, as the result of prompt aspiration, with the resulting prevention of adhesions or of a mechanical block due to the presence of an unresolved clot. Prompt resumption of motion also played a part in the good results.

At the 65th General Hospital, where an adequate followup was also possible, only 17 of the 42 patients had entirely satisfactory results, the distribution being 9 of 28 in group 1, 1 of 5 in group 2, and 7 of 9 in group 3, which was the surgical group.

Of the 33 patients treated conservatively in groups 1 and 2, 18 had a 5- to 10-degree limitation of extension and supination, which was painless in 15 cases and painful in 3 (fig. 31). The discomfort was not severe enough to

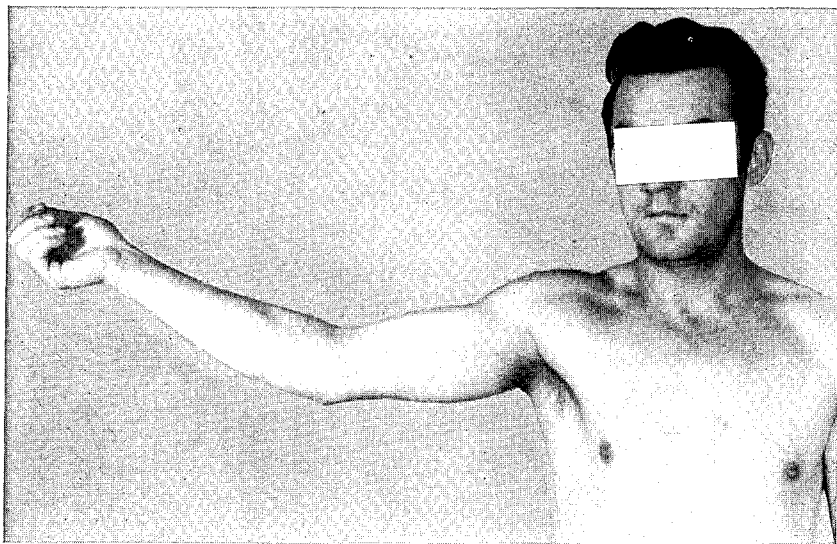


FIGURE 31.—Fracture of radial head, group 1, 6 months after injury, with limitation of extension. The patient, who had been treated conservatively, complained of discomfort on both extension and supination. (See also figures 24 and 33.)

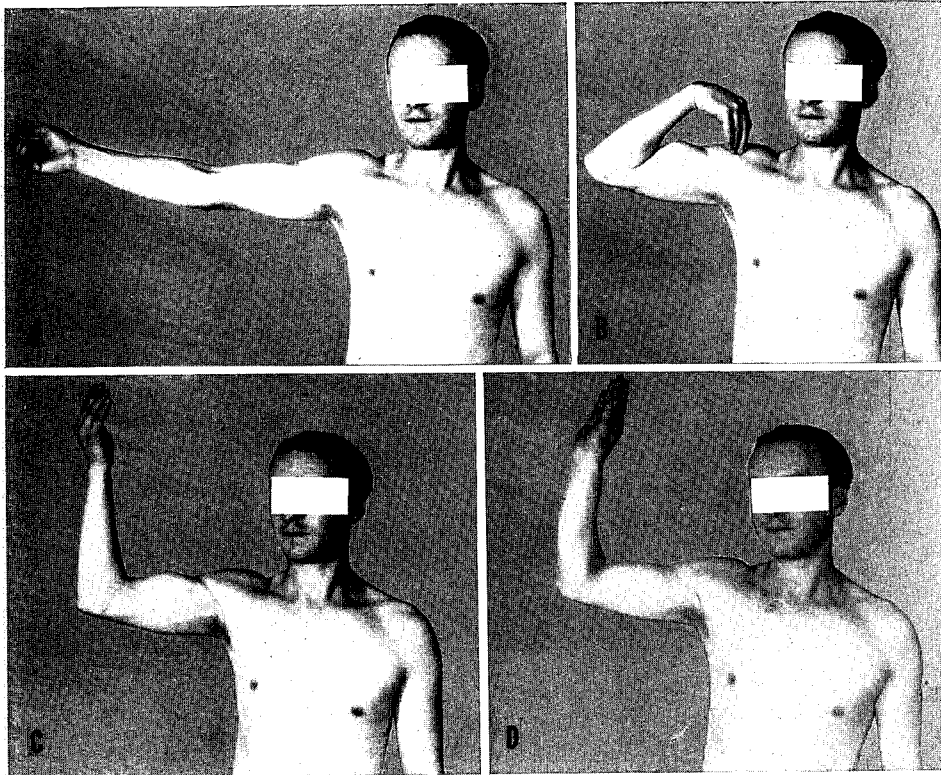


FIGURE 32.—Fracture of radial head, group 3, 6 months after resection of head. At this time patient had full range of painless motion. A. Extension. B. Flexion. C. Supination. D. Pronation.

bring any of the patients back for treatment; the complaint in each case was elicited on the routine followup visit. Both the discomfort and the limitation of motion were attributed to the presence of the injured radial head. Surgical excision, however, was not considered, partly because the pain and disability were slight and partly because this operation, whether it is performed early or late, does not always correct limitation of motion.

None of the nine patients who were operated on (group 3) had any complaints on their 6-month followup visit, and their range of motion (fig. 32) was often better than in some of the nonsurgical cases. The only postoperative complication was a temporary palsy of the radial nerve, which disappeared in 7 weeks. It was attributed to unnecessarily tight application of the sphygmomanometer cuff.

In the 2 cases in group 2 in which, as already noted, aspiration of the joint was carried out in addition to the use of a sling or the application of a cast, the results were not considered any better than were accomplished in the cases in which aspiration was omitted.

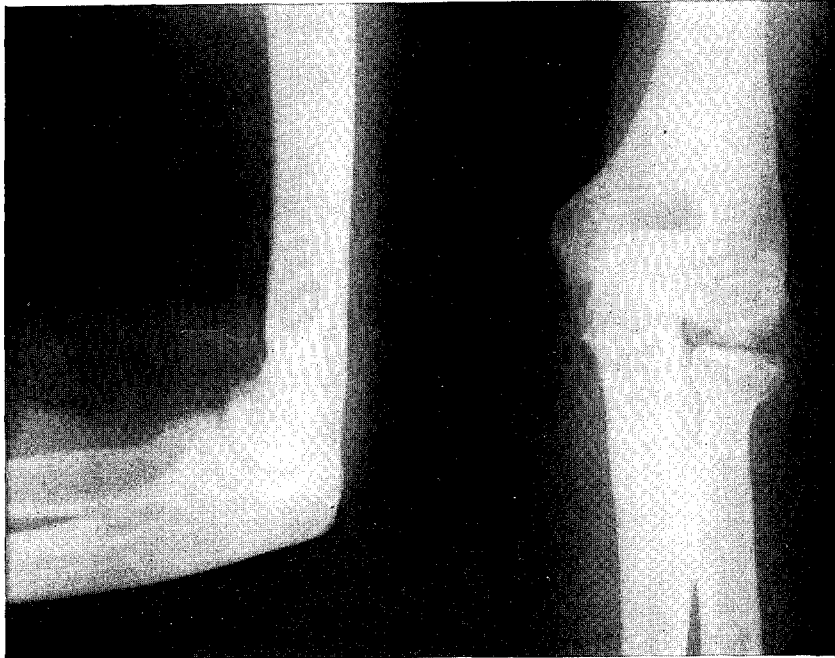


FIGURE 33.—Fracture of radial head, group 1, 12 months after injury, showing roughening of capitellum and persistent bony cleft. (See also figures 24 and 31.)

In 1 case in group 1, the fracture was still present in the roentgenograms made at the end of 10 and of 12 months (figs. 24 and 33) and the patient had some limitation of motion (fig. 31) and discomfort on movement. The findings were explained by the presence of an intra-articular fracture. Trauma to the capitellum was evident in this case.

The absence of bony spurs or myositis ossificans (fig. 34) in all the surgical cases was considered due to the surgical technique, which included covering of the stump left after excision of the radial head. Osteochondritis dissecans was not observed in any case in the series.

Specimen Case Histories

The 2 case histories which follow (the first and last in the series of 49 from the 168th Station Hospital) are presented as typical of this kind of injury in respect to the nature of the accident; the clinical picture, including the usual delay of several hours before symptoms became severe enough to require medical consultation; the ease of diagnosis; the roentgenologic confirmation of the clinical diagnosis; the prompt relief of pain and discomfort by aspiration; and the excellent end results, which permitted prompt return to full duty. It is interesting to note that the patient described in case 2 was treated on an ambulatory basis and was returned to full duty in 13 days, while the patient described in case 1 was hospitalized for 18 days.

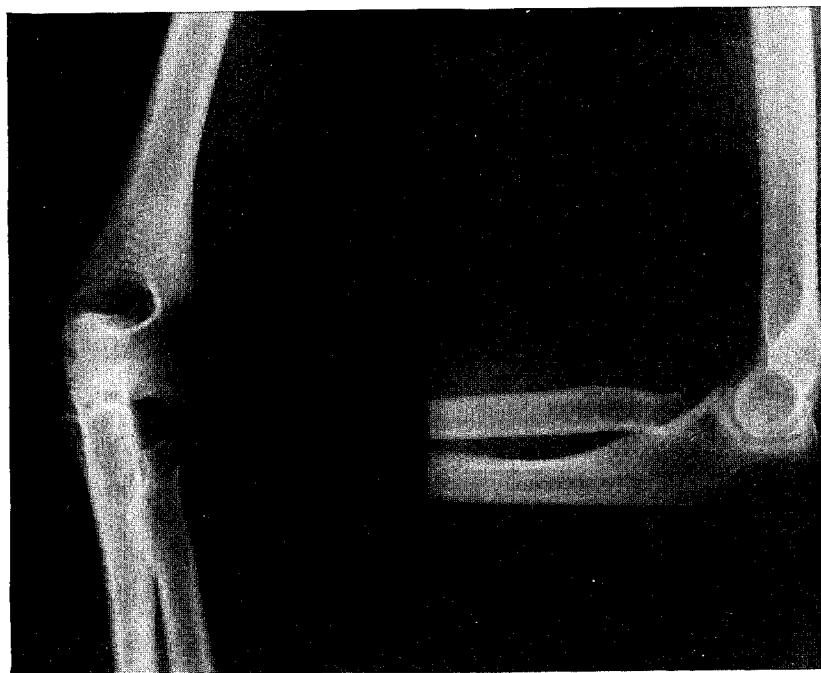


FIGURE 34.—Fracture of radial head, group 3, 6 months after resection of head. Note absence of any bony reaction.

Case 1.—A 21-year-old soldier fell from his bicycle on his right elbow 4 October 1943, 4 hours before admission to the hospital. Clinical examination suggested a fracture of the radial head, with hemarthrosis of the joint. X-ray examination revealed a vertical, incomplete fracture of the radial head, without displacement. Aspiration of the joint yielded 16 cc. of blood. Upon his discharge 18 days later, the patient had full function and no pain. One month later, he was entirely symptom free and was performing all his required duties as an airplane mechanic.

Case 2.—A technician, from the hospital's medical detachment, fell from his bicycle on his extended left hand and forearm 30 August 1944, and was seen in the outpatient department 3 hours later. The clinical diagnosis of fracture of the radial head with hemarthrosis was confirmed by roentgenograms, which revealed a transverse impacted fracture of the radial head. Aspiration of the joint yielded 22 cc. of blood. The cast was removed 48 hours later and physical therapy was begun. This patient, who was treated on an ambulatory status, was returned to full duty as a cook 13 days after injury, with no limitation of motion and no pain. He had no difficulty in performing any of his duties during the several months he was under observation.

Fractures of the Carpal Scaphoid

Fractures of the carpal scaphoid, a civilian type of injury, were even more frequent in the Army than in civilian life. Diagnostic errors are more common in fractures of this bone than in fractures of any other bone in the body; this was as true in the Army as it is in civilian life. The situation is strange, since, without exception, all these fractures are produced in the same manner—by

force transmitted through the proximal palmar surface of the hand—and the history is the key to the diagnosis. When the same type of trauma occurs in the middle-aged person, whose muscles are flabby and whose reaction time is longer, the result is the Colles fracture, which was seldom encountered in soldiers.

The data which follow were collected by Lt. Col. Marcus J. Stewart, MC, at the orthopedic service at the 826th and 827th Convalescent Centers. The 436 injuries which were observed at these centers between September 1942 and September 1945 consisted of 433 fractures of the carpal scaphoid bone and 3 sprains of bipartite scaphoids. The 433 fractures fell into 3 groups:

Eleven incomplete fractures of the distal third of the carpal scaphoid, all of which healed promptly and without definitive treatment.

Three hundred and twenty-three fresh or acute injuries, which were diagnosed within a month of the accident.

Ninety-nine old fractures which had occurred, on the average, 38 weeks before the diagnosis was made.

Fresh fractures.—Of the 323 patients with fresh fractures, 320 were treated by immobilization in plaster, and 3, all of whom had good results, by early excision of the proximal fragment.

Immobilization was accomplished in a position of maximum relaxation of the carpus, the so-called grasping pose (fig. 35). The wrist was placed in extension of approximately 30 degrees, with midulnar and radial deviation.

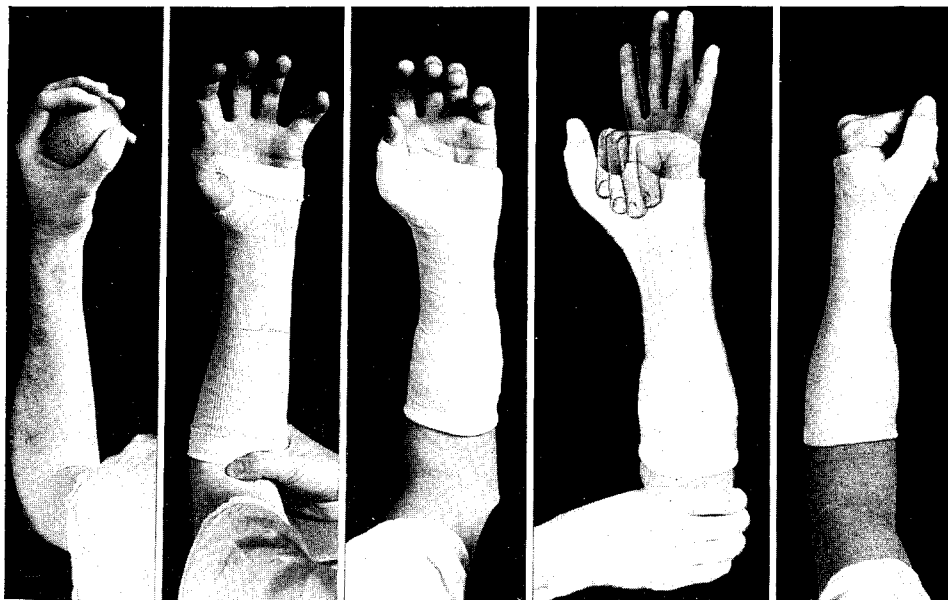


FIGURE 35.—Type of plaster cast used for immobilization in fractures of carpal scaphoid bone. Note so-called grasping pose. Note also possible range of motion of metacarpophalangeal joints.

The first metacarpal was abducted and the metacarpophalangeal and interphalangeal joints of the thumb were flexed toward the palm. A circular plaster cast, which was skintight except for a single layer of stockinet, was applied from 1 inch below the elbow to the metacarpophalangeal joints and the base of the thumbnail on the dorsal aspect, and to the distal end of the proximal flexion crease on the palmar side. This position usually permitted the hand to pass through the sleeve of the shirt or the coat. The practice of having the patient clench his fist during the period the plaster was setting was avoided, on the ground that in this movement the flexor muscles recede proximally and the circumference of the wrist is correspondingly reduced. If the plaster hardens in this position, the patient has considerable difficulty in extending the fingers and opening the hand.

Movement of the interphalangeal joint of the thumb was permitted during immobilization, provided that the plaster did not weaken and allow movement of the metacarpophalangeal joint. The latter motion, since the middle fibers of the abductor of the thumb are attached to the tubercle of the scaphoid, would permit movement of the fracture. In the position in which the fracture was put up, the thumb was relaxed and the metacarpophalangeal joints of the fingers were completely free. This meant that the patients, who were seen at a rehabilitation center, could carry on an active program of work or play. They were encouraged to participate in such activities as rope climbing, tumbling, chinning exercises, and even baseball.

The cast was changed and the fracture studied by roentgenograms at the end of 4 to 6 weeks. When the cast was removed, the patient was instructed not to move the thumb or wrist until he was told expressly that he might. When necessary, immobilization was reinstated immediately after the roentgenographic examination. Routine roentgenograms included a true anteroposterior view, a lateral view, and 2 oblique views, 1 in pronation of 45 degrees and the other in supination of 45 degrees (fig. 36, A through D).

Of the 320 patients treated by immobilization according to this technique, 258 obtained solid bony union, with restoration of full function in the wrist and hand, an excellent range of painless motion, a normal grip, and normal strength in the wrist. The other 62 patients were transferred to other hospitals or to the Zone of Interior, and the end results are not known. At the time of transfer, 45 were progressing satisfactorily, and union was expected. Three had definite signs of persistent nonunion, and 14 had been treated too recently to permit any conclusions. It may be considered, however, that 303 of the 320 patients, about 95 percent, had good to excellent results.

When these results were analyzed, a number of factors were found to have influenced healing.

1. *Location of the fracture.* This was a most important consideration, as it always is in this type of fracture. As a matter of fact, fractures in various portions of the carpal scaphoid should be considered as if they were different bones in different parts of the body.

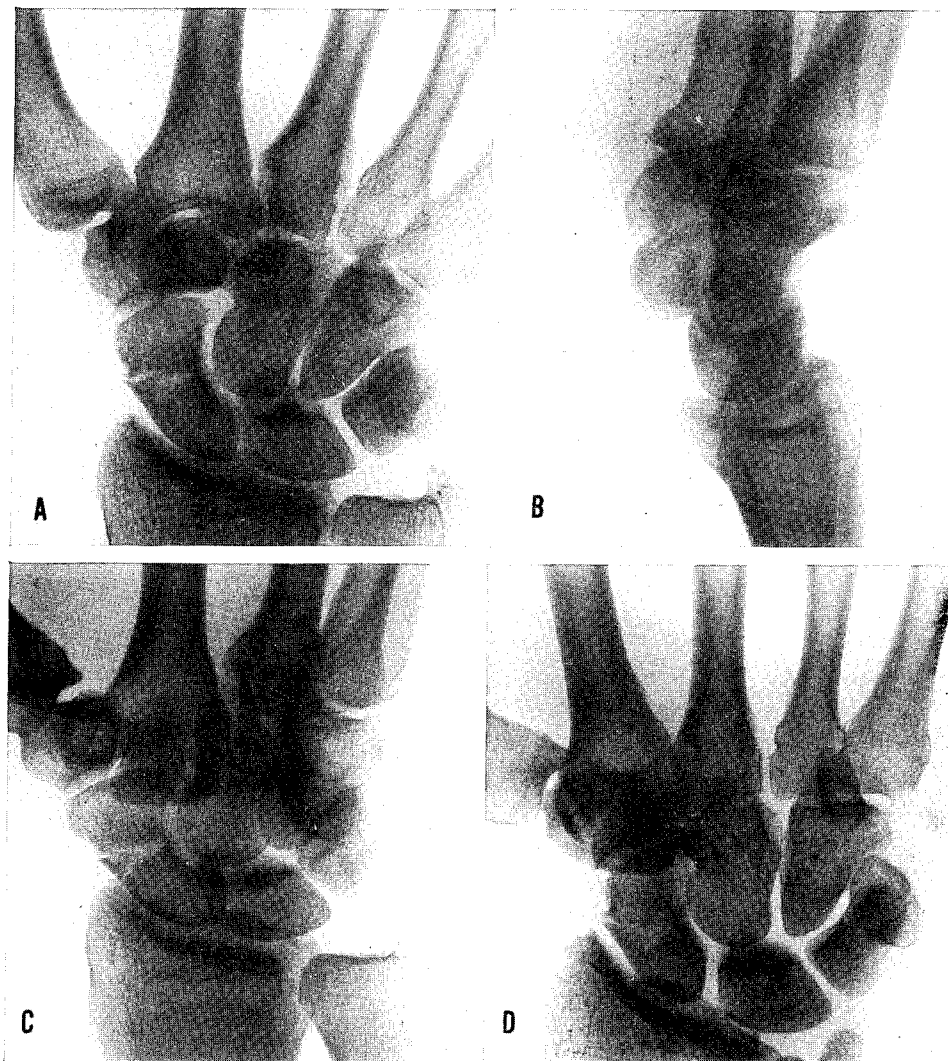


FIGURE 36.—Routine roentgenographic studies in fractures of carpal scaphoid bone. A. Anteroposterior view. B. Lateral view. C. Oblique view in pronation of 45 degrees. D. Oblique view in supination of 45 degrees.

Of the 258 patients who obtained bony union under conservative treatment, 44 (17 percent) had fractures of the distal third of the scaphoid, which required immobilization in plaster for 5 to 20 weeks and for an average of 8 weeks; 207 (80 percent) had fractures of the waist or middle third, which were immobilized in plaster for 3 to 35 weeks and for an average of 12 weeks; and 7 (3 percent) had fractures of the proximal third of the bone, which were immobilized from 12 to 32 weeks and for an average of 23 weeks.

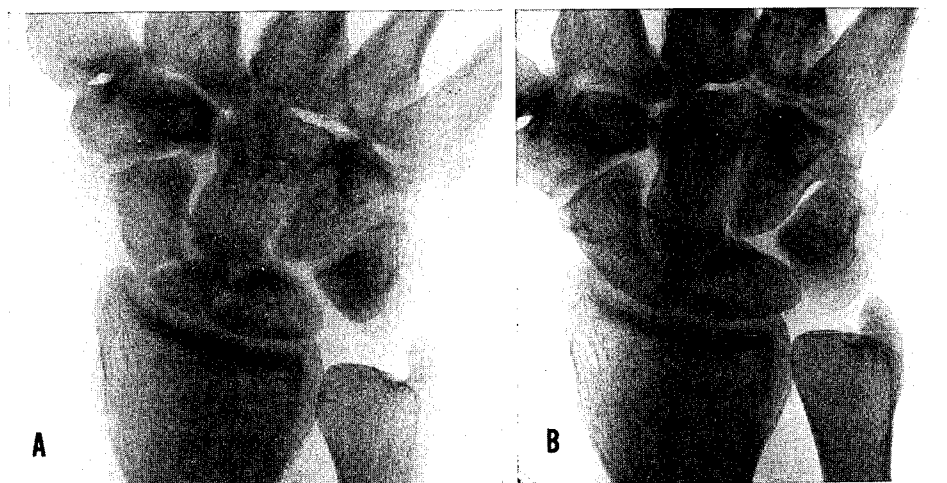


FIGURE 37.—Serial roentgenogram showing fracture of carpal scaphoid bone through waist. A. Development of sclerosis in proximal fragment in spite of early and adequate immobilization. B. Excellent end result, after 30 weeks of immobilization in plaster before union and revascularization occurred.

The average period of immobilization for the entire group of 258 patients was 12 weeks. The reconditioning period necessary after removal of the plaster was encouragingly short, the average time required for complete recovery of function being only 3.5 weeks. Activity of the fingers while the plaster was in situ apparently maintained good tissue turgor, stimulated the blood supply, and kept the tendons freely movable.

2. *Reduction.* The accuracy of reduction proved of paramount importance in the healing process. This is shown by the necessary duration of immobilization. In 9 of the 258 patients, reduction was fair, and an average of 16 weeks in plaster was required. In 129, good reduction was obtained, and an average of 14 weeks in plaster was required. In 120, anatomic reduction was obtained, and an average of 10 weeks in plaster was required.

3. *Vascular changes.* It is well known that fractures through the proximal third of the carpal scaphoid and those through the waist may result in deprivation of the blood supply to the proximal fragment in a certain proportion of cases, with resulting necrosis. This development was observed in this series:

In 41 patients, mild to marked vacuolation or cystic changes were observed at the site of the fracture. Immobilization in plaster was maintained for an average of 16 weeks. In spite of early diagnosis and adequate immobilization, avascular necrosis developed in 22 (8.5 percent) of the 258 patients who obtained bony union and excellent results.

In 10 cases, increased density or sclerosis was observed at the site of the fracture. Plaster immobilization was maintained from 11 to 35 weeks, the average being 21 weeks.

In 12 cases, avascularity of the proximal fragment occurred. These patients (fig. 37) spent an average of 21 weeks in plaster. Before they left

the hospital, all of them were able to negotiate an obstacle race and participate in vigorous sports, and all returned to full duty with normal function of the hand and wrist. In such cases, however, there is always the possibility that degenerative arthritis may develop later.

Old fractures.—Of the 99 patients in this series with old fractures, 90 were treated only by immobilization. Fifty-one of the 90 were returned to full duty. All had obtained solid bony union, as shown by roentgenograms, and all had an excellent range of motion in the wrist and hand, without tenderness, and with normal grip and strength.

Thirty-nine patients were returned to the United States or discharged to other hospitals before the conclusion of treatment. In 15 cases, healing was progressing satisfactorily at the time of transfer, but in 3 cases nonunion was evident. In the other 21 cases, treatment was too recent to permit any evaluation of results. There was, however, solid bony union or reasonable expectation of union in 66 of the 90 patients (73.3 percent). These results are to be compared with the approximately 95 percent of good results secured in the 320 cases in which treatment was instituted while the fractures were still fresh.

The same factors influenced healing in the old fractures as in the fresh fractures:

1. *Location.* The 2 fractures which involved the distal third of the carpal scaphoid remained undiagnosed for 16 weeks and 34 weeks, respectively. Immobilization in plaster was maintained for 22 weeks and 8 weeks, respectively, an average of 15 weeks.

The 43 fractures through the waist of the bone remained undiagnosed for from 4 to 82 weeks, an average of 22 weeks. Immobilization in plaster was maintained for 6 to 59 weeks, an average of 19½ weeks. Prolonged immobilization in these cases did no harm, since daily exercise and activity of the fingers was systematically practiced.

The 6 fractures of the proximal third remained undiagnosed for from 10 to 56 weeks, an average of 23 weeks. Immobilization in plaster was maintained for 12 to 60 weeks, an average of 24 weeks.

The period of immobilization required in these 51 old fractures in which return to full duty was possible averaged 20 weeks, as compared with an average period of 12 weeks for fresh fractures. Aside from any other consideration, the delay in diagnosis caused an average of 8 additional weeks in plaster.

2. *Reduction.* As in fresh fractures, the character of the reduction obtained influenced the duration of immobilization. In 9 cases in which reduction was excellent, immobilization was necessary for an average of 10.9 weeks. In 38 cases in which it was good, immobilization was necessary for an average of 22.9 weeks. In 4 cases in which it was fair to poor, immobilization was necessary for an average of 23.1 weeks.

3. *Vascular changes.* Mild to marked cystic changes were observed in 42 cases, in which immobilization was necessary for an average of 19.3 weeks. Sclerosis at the fracture site was observed in 9 cases, in which immobilization was necessary for an average of 21.4 weeks. Six of the nine patients showed

arthritic changes, but none of them complained of pain or weakness, and all had full range of motion.

The presence or development of cystic changes or sclerosis, as these cases show, does not preclude the use of prolonged immobilization in fractures of the carpal scaphoid. The sclerotic area present in many fractures when the cast was applied looked worse after 4 to 6 weeks in plaster, but improvement became evident (figs. 38 and 39) as immobilization was continued. The freedom and activity of the fingers, as already noted, contributed materially to the success of the treatment.

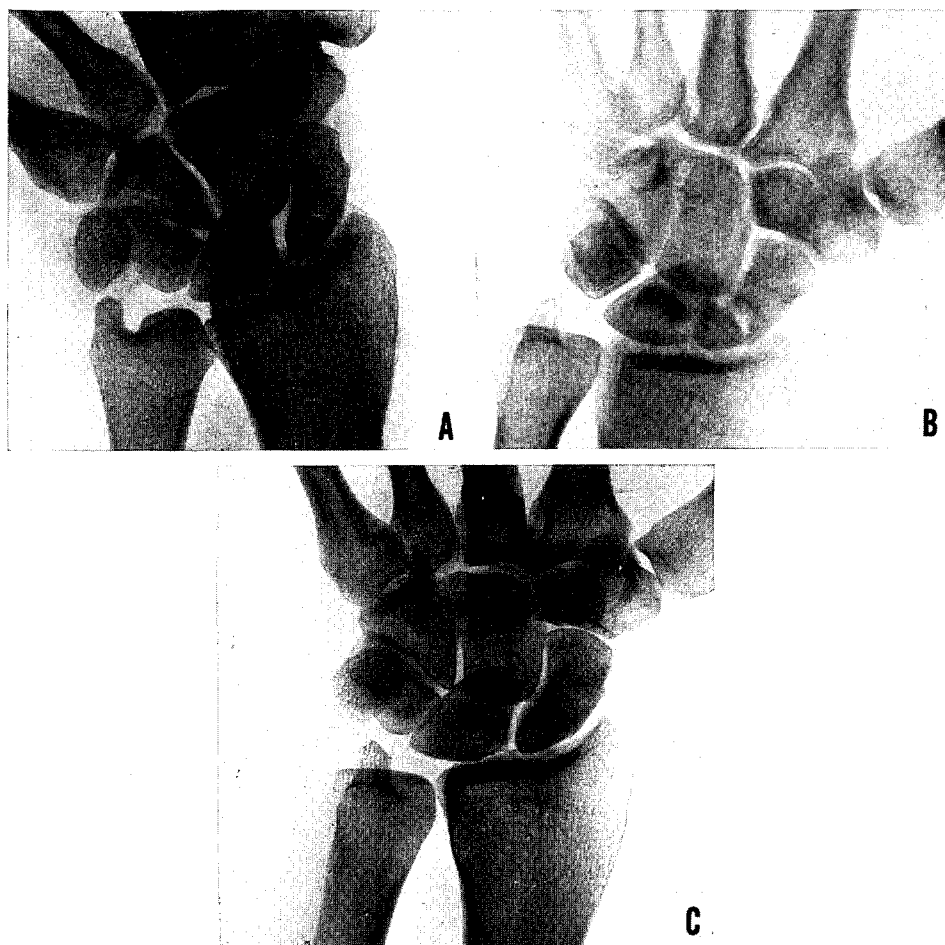


FIGURE 38.—Serial roentgenograms showing fracture of carpal scaphoid bone which was not diagnosed for 10 weeks. A. Cystic changes at fracture site. B. Appearance after immobilization in plaster for 5 weeks. C. Appearance after immobilization for 22 weeks. This was an excellent result, with solid union.

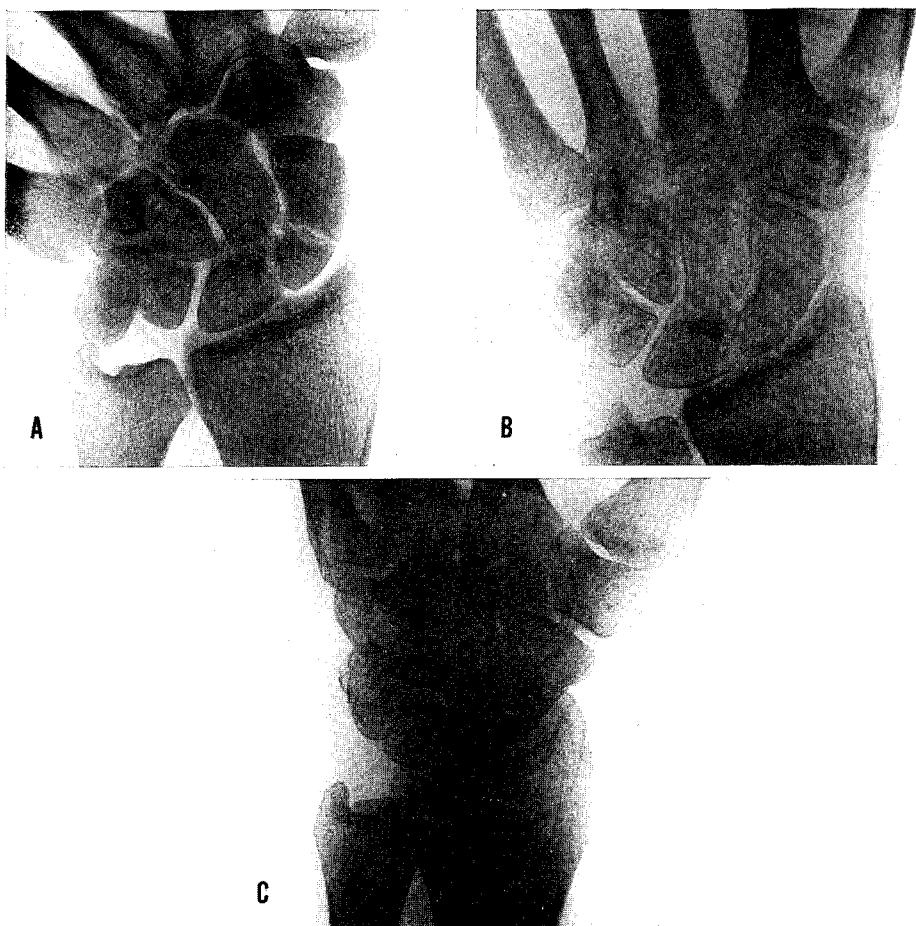


FIGURE 39.—Serial roentgenograms showing fracture of carpal scaphoid bone which was not diagnosed for 56 weeks. A. Roentgenogram taken when patient was first seen. B. Appearance of bone after immobilization in plaster for 4 weeks. C. Appearance of bone after immobilization for 12 weeks. Fracture union was solid, but mild osteoporosis developed.

Nine patients with old fractures were treated by surgery, as follows:

Five patients were treated by autogenous bone grafts. In 1 of these cases, the graft was resorbed and the fracture failed to unite; the patient was then transferred to the Zone of Interior for further treatment. Another patient had marked stiffness of the wrist, with 50-percent disability after operation; he was returned to limited duty. The 3 other patients were returned to full duty. In the light of present knowledge, and on review of the roentgenograms, there is every reason to believe that at least 3 of these fractures would have healed just as satisfactorily and rapidly if they had been treated by immobilization alone.

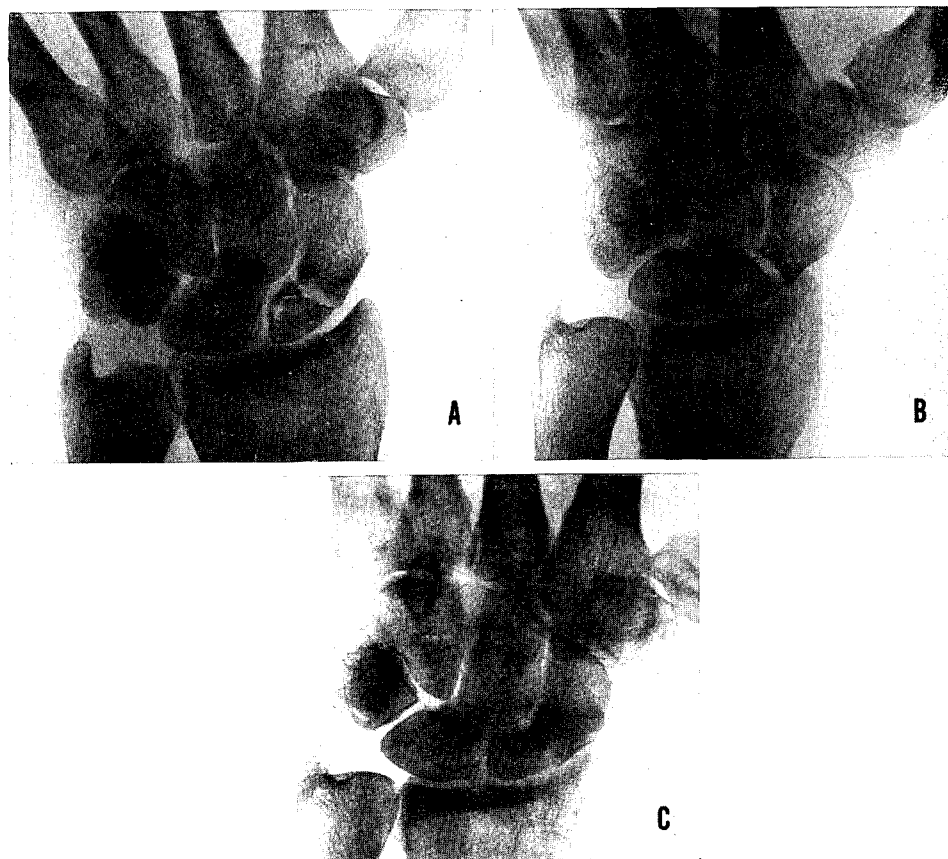


FIGURE 40.—Serial roentgenograms showing fracture of carpal scaphoid bone which was not diagnosed for 6 weeks. A. Roentgenogram taken when patient was first seen. B. Roentgenogram taken after immobilization in plaster for 25 weeks. At this time there was still no evidence of progress toward union. An inlay type of cancellous-bone grafting was done. Postoperative immobilization was maintained for 8 weeks, and 4 weeks' reconditioning was required. C. Roentgenogram taken 3 months after patient had returned to full duty as truck driver.

One of the patients treated by bone graft (fig. 40) had a fracture which was not diagnosed for 6 weeks. No improvement was evident after immobilization for 6 months. Solid union was secured 8 weeks after excision of the fibrocartilage at the fracture site, and an inlay bone graft was performed. The patient was returned to full duty as a truck driver. This case presented the ideal indication for grafting; namely, failure of viable fragments to show progress toward union after 6 months of immobilization.

Two patients were treated by excision of the proximal fragment. One fracture, through the middle third of the scaphoid, was not diagnosed for 24 weeks; mild sclerosis was then present at the fracture site and moderate sclerosis

in the proximal fragment. The patient returned to limited duty after 10 weeks of postoperative treatment, with pain and weakness in the wrist and an estimated 40-percent disability. The other patient in this group had a fracture of the proximal third of the scaphoid which had remained undiagnosed for 40 weeks (fig. 41). The proximal fragment was greatly displaced. The fragment was excised and the patient, who was a paratrooper, was returned to full duty after 8 weeks of postoperative reconditioning.

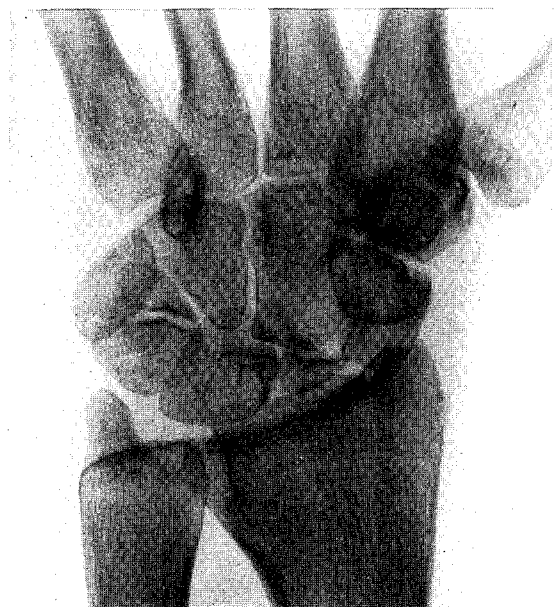


FIGURE 41.—Roentgenogram showing fracture of carpal scaphoid bone with marked displacement of small proximal fragment. The fracture was not diagnosed for 40 weeks. After excision of fragment and 8 weeks of postoperative reconditioning, the patient could be returned to full duty.

Two patients were treated by multiple drilling. One obtained union within 6 weeks but required 7 weeks' reconditioning before he could be returned to full field duty. The other had no sign of union 18 weeks after drilling and was returned to the United States.

Comment.—As this analysis shows, excellent results can be obtained, with a minimum period of immobilization, in fractures of the carpal scaphoid bone which are promptly diagnosed and accurately reduced. The proportion of good results obtained in fractures which are not promptly diagnosed is considerably less, and delayed union or nonunion must be expected in a certain proportion of cases. The presence of vacuolation or cystic change in delayed cases does not, however, necessarily presage a poor result; when the fracture has been properly immobilized, healing in the cystic area will include the fracture line. If the proximal fragment is viable, sclerosis at the fracture site is not a contraindication to prolonged immobilization. In most cases of avascular sclerosis, a continuation of nonsurgical therapy is warranted; protection of the wrist is essential until revascularization is complete. Generally speaking, sur-

gery does not offer any better prospects of union than does nonsurgical therapy. Normal function of the wrist is seldom obtained following an excision operation, though in the occasional fracture with excessive displacement of the proximal third, early excision of the proximal fragment is the best course unless accurate reduction can be obtained by manipulation. Plaster should be applied with two objectives, (1) adequate immobilization and (2) free use of the hand. Immobilization may be prolonged for a year or more if daily exercise and activity of the fingers are systematically practiced. Perhaps the most significant point of this analysis is the very large proportion of soldiers who could be returned to full duty after an injury that, if not properly diagnosed and treated, could have resulted in a serious loss of manpower.

It should be noted that this interesting study of fractures of the carpal scaphoid bone was begun in September 1942, 21 months before the invasion of the Normandy beachhead. During this period, the number of hospital beds in the European theater considerably exceeded the need for bed space. After the invasion, with the beginning of what was to prove a steady flow of battle casualties, the maximum holding time in the European theater was reduced to 120 days, or 17 weeks. Holding times of 20 weeks, the average for fractures of the carpal scaphoid bone seen late, were no longer permissible. In many instances in this series the holding time was considerably in excess of this average. When battle casualties must be treated, there is no reason to consider holding in an overseas theater patients whose treatment may require as long as 60 weeks, as happened in 1 case in this series. Many of these patients who were seen after the D-day invasion should have been, and doubtless were, promptly evacuated to the Zone of Interior.

Attention is also directed to the proper treatment of recent fractures of the carpal scaphoid, as exemplified in this series. When diagnosis is prompt and treatment is correct, soldiers with this type of injury can usually be returned to duty within the prescribed limits of time in an overseas theater.

Clavicle

Fractures of the clavicle encountered before D-day were satisfactorily treated by Blake suspension traction for 12 to 21 days, followed by ambulation in a figure-of-8 plaster bandage for 7 to 14 days. Whether the patient was in bed or ambulatory, hospitalization was necessary. Traction was preferred by some orthopedic surgeons because it caused the least deformity, which is always of importance in fractures in this area.

In battle-incurred fractures of the clavicle, the emphasis was on immobilization and early evacuation. The plaster figure-of-8 dressing and the clavicular cross were used with equal effectiveness. A common error in fractures of the clavicle treated in plaster was failure to instruct the patient in active shoulder exercises. This omission often resulted in significant, and unnecessary, stiffness of the shoulder joint.

Humerus

Before the invasion of the Continent, simple (closed) fractures of the humerus were chiefly treated by hanging casts, as in ordinary civilian practice. Compound fractures were also treated by the methods employed in civilian practice.

Battle-incurred fractures required a different approach. Standard treatment at some hospitals was the insertion of a Kirschner wire through the olecranon process, combined with traction and vertical or horizontal suspension. Excellent results were also obtained after reduction and fixation by continuous Blake traction, whether skeletal or skin traction was employed.

Severely comminuted fractures with loss of bony continuity and large compounding wounds responded excellently to open reduction, usually by the use of a wire or screws or by a combination of these methods. When there was considerable loss of bony substance, no hesitancy was felt in shortening the bone as much as 2 inches to obtain good bony union and to forestall the necessity for later bone grafting.

The most common complication of a fracture of the humerus was radial nerve injury with resulting paralysis. In such cases, management of the nerve injury took precedence of management of the bone injury. Vascular injuries were sometimes associated with the bone injury, and in at least 1 instance, at the 68th General Hospital, the vascular damage was severe enough to require amputation.

Patients with fractures of the humerus were transported in plaster-of-paris spicas. A hanging cast was not suitable, as was proved in the few cases in which it was employed shortly after fighting began on the Continent.

A shoulder spica or plaster Velpeau was readily applied by the following technique: An issue type of Army arm splint was stretched between two tables, with the ring end higher than the other end. The patient was then placed on the splint, the ring of which formed an excellent head cushion. In this position the plaster was easily applied about the body. When it had dried, the splint was withdrawn. A metal bar 2 or 3 inches wide served the same purpose.

At the 802d Hospital Center, the 1,065 compound fractures of the humerus treated in traction fell into 3 groups:

1. *Fractures of the upper third.* Traction through the olecranon process was used in all but a few of the fractures in this group. The Kirschner wire was introduced from the medial to the lateral side, particular care being taken to identify the ulnar nerve by palpation and to avoid it. In a few instances, a temporary neuritis developed from irritation caused by the adjacent wire, but in no instance was there permanent nerve damage. The humerus was usually held at right angles to the thorax and in midrotation (fig. 42). Often a posterior wound had to be kept from contact with the bed or underlying apparatus. In some instances, the axis of the immobilization

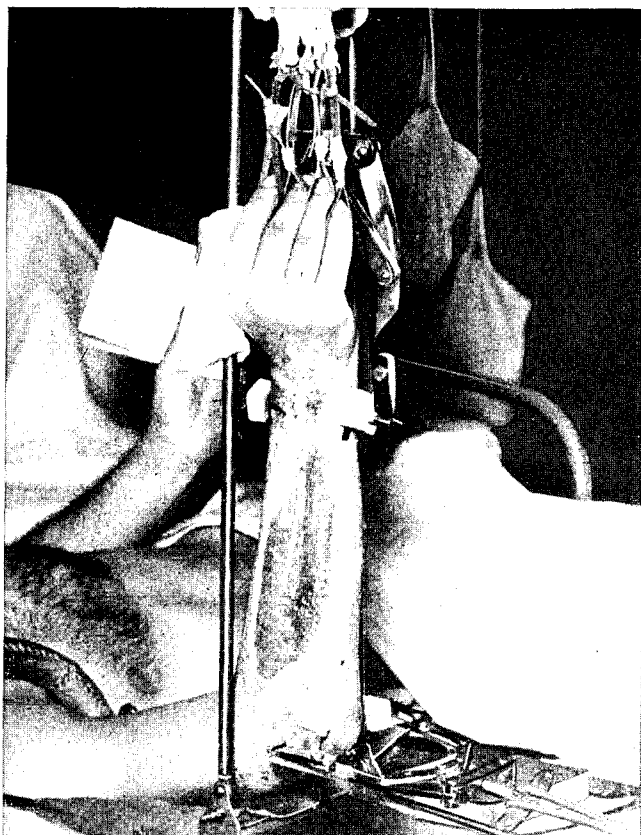

FIGURE 42.—Skeletal traction applied for treatment of injury by 88-mm. shell fragment, which caused compound comminuted fractures of the radius and ulna and a simple fracture of the humerus.

apparatus was applied with the humerus at anterior flexion of 90 degrees and with traction directed overhead.

The hanging cast was not suitable for early treatment of extensive compound fractures. After, however, a good callus had developed, at 6 to 8 weeks, a thoracbrachial or hanging-type plaster cast could be substituted for traction.

2. *Fractures of the middle third.* Traction through the olecranon process was also found most satisfactory for this group of cases. Fractures in this area were seldom manipulated and were often reduced by traction alone; 10 pounds of weight for 12 to 24 hours almost invariably produced satisfactory alinement, after which the weight could usually be reduced to 4 to 6 pounds. The Thomas arm splint was used only when a Pierson attachment was needed for traction on the forearm (fig. 42).

Approximately 20 percent of the patients with fractures of the upper third of the humerus exhibited radial nerve weakness or paralysis in which recovery followed, sometimes as early as 72 hours after reduction of the fracture and institution of traction. Complete interruption of the nerve and loss of bone substance were frequent complications. They were managed by deliberate shortening of the bone when necessary, though not until after the wounds were clean and covered with healthy skin. In these cases, the presence of infection and the loss of muscle, vascular, and nerve tissue directly over the fracture site were a direct threat to the function of the hand, and correction of these defects was obviously more important than strict immobilization and purely mechanical treatment of fractures of the arm or forearm.

3. *Fractures of the lower third and at the elbow.* In this group of cases, early motion of the elbow joint and hand was the primary consideration, and anatomic reposition of fragments was not sought at the price of immobilization. Traction was instituted either through the olecranon process or at some point in the dorsal cortex of the proximal third of the ulna. Active motion of the hand in the traction apparatus was begun at the earliest possible moment. In no instance did this practice appear to inhibit the formation of callus. The functional end results obtained by these policies in fractures of the elbow were, in fact, curiously better than might have been expected from the deformity and displacement often evident in the roentgenograms. Results were, however, notoriously poor after prolonged immobilization and after open operations intended solely to obtain anatomic position.

Pelvis

Fractures of the pelvis were at least as often caused by the highly accelerated vehicles and heavy machines of modern war as by missiles, though the latter produced shattering compound wounds which were not present in the vehicular type of injury. In battle-incurred fractures, injuries of every organ within the pelvic basin were seen, and treatment of the bone injury often had to be deferred until urinary and bowel function had been reestablished by urethrostomy, cystostomy, and colostomy as indicated. In many instances, the position of the fractures could not be changed, although manipulations of every description were attempted.

Once reduction had been effected, the elements of traction had to be carefully analyzed and applied with due regard both for immobilization of the fracture and for the nursing care required by the patient. Lateral suspension of the pelvis by traction through the femoral condyles, with the hips flexed at 90 degrees, was both useful and comfortable in properly selected cases. Certain extensive comminuted fractures with a tendency to collapse were maintained by lateral traction through both iliac crests and distal traction through the upper tibia or lower femur. The Rouvillois or lumbo-femoral suspension frame (p. 236) obtained from liberated medical depots in France was often a more comfortable and more effective apparatus from the nursing standpoint than the conventional hammock.

Patients with the conventional fractures of the pelvis usually caused by vehicular accidents, without complications to the intrapelvic soft parts, did very well in bilateral plaster-of-paris hip spicas carried to the knee.

Spine

Fractures of the spine and injuries of the spinal cord are discussed in detail elsewhere in this series of volumes, and only one or two points concerning these injuries need be mentioned here.

Transportation of the patient was the major problem in fractures of the cervical spine. No movement was attempted until conditions were favorable. All manipulations were avoided, and the head was not raised under any circumstances. Good results were usually obtained by moving the patient on an ordinary litter, supported with massive gauze rolls or folded blankets to minimize lateral movement. When possible, a jacket of the Minerva type was used.

In injuries of the thoracic spine, a plaster body jacket was also used to good advantage. The patient was usually transported prone on the litter if laminectomy was likely to be necessary.

It was standard practice to evacuate immediately all patients with neurologic involvement, so that a neurosurgeon might decide whether or not laminectomy was necessary.

Femur

General considerations of management.—The fractures of the femur received in the United Kingdom from forward hospitals immediately after D-day were not always well managed. The wounds were often firmly packed with gauze and were sometimes in such condition that delayed primary closure could not be performed within the optimum period. Later, as experience increased, the state of the wounds was improved, and gauze was placed in them lightly, as was desirable.

Delayed primary wound closure sometimes had to be deferred while the patients were prepared for it. Fractures of the femur were often associated with heavy blood loss, and massive transfusions were necessary before operation could be safely performed. An interesting incidental observation was made in this connection at the 802d Hospital Center. In a number of cases in which extensive wounds of the thigh required incision and debridement before suspension in skeletal traction could be carried out, two teams worked in friendly competition with each other to minimize blood loss by accomplishing complete hemostasis by the use of fine ligatures and endothermy. The amount of blood lost at operation was estimated by studies of the supernatant fluid after all dressings, drapes, and gowns had been soaked in a dilute solution of saponin. The smallest amount lost at any operation was 600 cc. The amount of blood lost on the field and during transportation was assumed to be at least equal to this quantity, and probably greater.

Patients with fractures of the femur were transported to the Zone of

Interior in plaster-of-paris spicas. The fact that some fractures, especially those in the upper portion of the femur, became displaced in the plaster during transportation, after they had been regarded as frozen, made it clear that in some injuries, at least, the designated holding period of 6 to 9 weeks was too short.

Fracture management.—Two definite lessons were learned from the more than 1,000 fractures of the femur treated at the 802d Hospital Center: (1) In no other site in the body is the action of muscles more important in producing deformity; and (2) in no other group of fractures is correct application of traction more important for the achievement of satisfactory alinement of the fracture.

The general plan of management was to use the femoral condyles or the tibial tubercle for the site of the Kirschner wire, depending upon the nature of the fracture and the position of the associated wounds (fig. 43). When the wire was inserted through the lower end of the femur it had to be above the attachments of the collateral ligaments and posterior to the medial and lateral aspects of the suprapatellar pouch. If the wire was inserted with the leg fully extended and the knee was later flexed in the splint, the skin and deep soft

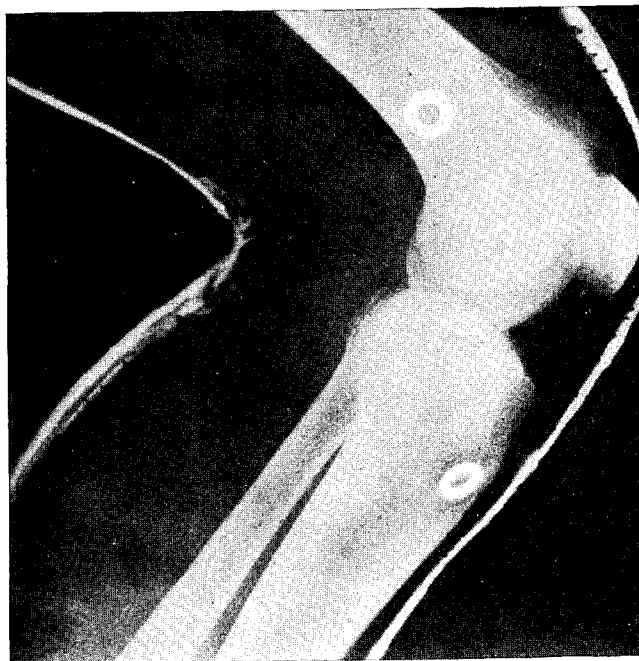


FIGURE 43.—Roentgenogram showing method of locating approved sites of election for insertion of Kirschner wires in lower femur and tibial tubercle. The topographic anatomy is shown by means of barium sulfate paste applied to the skin. Iron washers show areas for insertion of wires. This graphic method was useful, as an adjunct to the method of palpation, in teaching skeletal landmarks and orthopedic techniques to physicians without previous orthopedic experience.

parts would become folded up or stretched around it, and ischemia and infection were apt to follow. When the wire was correctly applied, damage to the knee joint did not occur as a result of traction through the tibia, even though a weight of 30 pounds was sometimes used for brief periods.

Fractures of the femur were managed according to the location of the fracture:

1. The neck and intertrochanteric region. In this group of fractures, a coxa vara deformity was invariably present by the time the patient had been brought in from the battlefield. Reduction was effected by manual traction and maintained by continuous skeletal traction through the lower femur, with suspension in either an inverted Keller-Blake half-ring splint or the French lumbofemoral splint. If the half-ring splint was used in the standard manner, the patients were uncomfortable, dressings of the wound were difficult, and displacement was relatively unimproved.

2. Upper third of the shaft. This group of fractures was one of the few in which displacement followed a standard pattern. The proximal fragment was almost always flexed, abducted, and externally rotated. Reduction by manipulation was usually successful and could be satisfactorily maintained merely by lining up the distal fragment and the leg with the position of the upper fragment.

3. Shaft. Sixty percent of the fractures in this group showed satisfactory position after suspension in skeletal traction and did not require manipulation. In the remaining 40 percent, manipulation was necessary. The minimum acceptable position required 50-percent contact of the fracture ends in 2 planes, without overriding or angulation. Less than 50-percent contact of the fracture faces was generally untenable, and every effort was made to achieve at least 75-percent contact. Displacement occurred insidiously, and roentgenograms made 4 to 6 weeks after the institution of definitive traction sometimes showed unexpected loss of position and the presence of deformity which could lead to malunion or nonunion. Disability was greatly prolonged when massive callus had developed to overcome inadequate apposition or muscle interposition.

The majority of fracture patterns, fortunately, were dentate, spiral, comminuted, or of the so-called blown-straw variety and therefore could be interdigitated well by manipulation. The possibility of muscle interposition was always investigated at the time of delayed closure of the wound, as well as when open reduction was necessary. Only occasionally were the mass and bulk of interposed muscle sufficient to form an obstacle to normal healing. In almost all instances, the muscle was found attached to periosteum or callus at the fracture site and was present in soft, hemorrhagic flaps, which could easily be pushed aside by simple manipulation.

4. Supracondylar fractures. Shattering injuries of the lower third of the femur were the commonest of all battle-incurred fractures of this bone, though the condylar variety of fracture caused by indirect violence is seldom seen in civilian practice. The distal fragment varied from a single condyle to the entire lower third of the femur. The main deformity factor was the pull of the gastroc-

nemius muscle. Lateral or forward displacement of the distal fragment was infrequent and was easily corrected.

The insertion of Kirschner wires in both the supracondylar region of the femur and the upper third of the tibia, followed by manipulation by manual traction on the tautening bow at right angles, was usually successful. The use of a posterior sling in place of skeletal traction from the distal fragment was found undesirable. It retarded wound healing and interfered with the circulation when it was applied to a swollen, edematous thigh. In a few cases treated at the 802d Hospital Center, simple suspension through the distal fragments, with the hip and knee each flexed at 90 degrees, produced satisfactory results. This position was also often used, of necessity, for the care of extensive soft-tissue wounds of the posterior aspect of the thigh.

The management of the so-called T-fracture of the lower femur which extended into the knee joint was a problem created by the differential pull of the two heads of the gastrocnemius muscle. After aspiration to relieve the severe pain in the knee joint, which was usually greatly distended with blood and bone-marrow fat, it was possible, without much difficulty, to palpate the condyles and manipulate them into a satisfactory position. Compression could be exerted manually, and a padded carpenter's clamp or other mechanical device was seldom necessary.

Fractures of the lower end of the femur, with large open wounds of the knee joint, were always a serious problem. They were managed by a bold policy of arthrotomy and open manipulation, followed by closure of the wound. Infection was surprisingly infrequent. Large doses of penicillin were administered systemically and implanted locally, though, in the light of postwar knowledge, local implantation of the antibiotic seems of doubtful efficacy.

If the compounding wound was so extensive that no site was feasible for the insertion of pins or wires, open reduction was sometimes preferable to a trial of traction. Fractures of the neck, if there were no contraindications, were sometimes treated by the Smith-Petersen nail.

Results in prisoners of war.—An analysis of 63 compound fractures of the femur observed at the 19th General Hospital illustrates possible results of delayed primary closure in cases which were none too favorable, since all the patients, including 5 United States soldiers who had been held by the Germans, were prisoners of war.² Fractures of the femoral condyles associated with wounds of the knee joint are not included. Seventeen of the wounds were infected when the patients were received, the cause of the infection, in every instance, being inadequate or late debridement. In all of these cases, extensive secondary debridement or wound excision was necessary.

Primary healing occurred in 21 of the 39 wounds in which delayed primary suture could be carried out shortly after these soldiers were received in a general hospital. Eight patients were evacuated too soon to permit evaluation of results. Healing was delayed in 10 cases, but wound necrosis and suppuration occurred in only 1 instance.

² Semiannual Report, 19th General Hospital, European Theater of Operations, 1 January-30 June 1945.

Tibia and Fibula

Fractures of the fibula furnished few problems. Simple fractures of the tibia and fibula were satisfactorily treated by traction. Reduction was obtained by the insertion of a wire through the os calcis or in the supramalleolar region of the tibia. A long leg cast was applied snugly about the fracture site and loosely about the knee and thigh. The wire was included in the cast.

Oblique fractures of the shaft of the tibia and fibula were more difficult to handle. They tended to be unstable and required continuous traction or open reduction with screw fixation to maintain the correct position.

In battle-incurred compound fractures of the tibia and fibula, delayed primary wound closure was less satisfactory than it was in other fractures. Important causes were the lack of soft tissue in this area and the greater tension in the tissues. These difficulties were increased if the wound had caused tissue and skin defects. Closure frequently had to be accomplished by means of relaxing incisions and split skin grafts. The relaxing incisions themselves sometimes required skin grafting.

In cases which could be managed by traction, wires were inserted in the os calcis for shattering wounds of the lower leg and in the lower tibia for wounds in the upper leg. Suspension of the limb in a Thomas splint with Pierson attachment had many disadvantages. One was that the considerable structure of pulleys and ropes necessary in this technique required daily readjustment, and at the best the patient was likely to be uncomfortable.

The Böhler-Braun method was used in many cases but had one important defect which outweighed all its advantages: When the lower leg was in traction on the cradle, although the distal fragment was relatively immobile, the proximal fragment moved with the patient.

The plaster traction splint (fig. 44) employed at the 22d General Hospital, 802d Hospital Center (p. 45) seemed to combine the best aspects of both of these methods of traction. As already pointed out, this technique was used in 65 compound fractures of both bones of the leg, including fractures at the ankle, treated at the 22d General Hospital. It proved highly efficient. Skin grafting was facilitated in the cases in which it was necessary, and it was even possible for some patients to get about in wheelchairs while they were still in continuous traction (p. 50).

Some badly comminuted fractures of the tibia and fibula were reduced by internal fixation. Maintenance of length was more satisfactory than with other techniques, though this method was not suitable when the compounding wound was extremely severe. In properly selected cases, it secured anatomic reduction, excellent fixation, and a high incidence of satisfactory union, with a minimal number of complications.

Ankle

Sprains and complete tears of the external lateral ligament of the ankle required plaster immobilization for 8 weeks. Any other method of management left a weak ankle, with recurrent luxation of the astragalus on slight

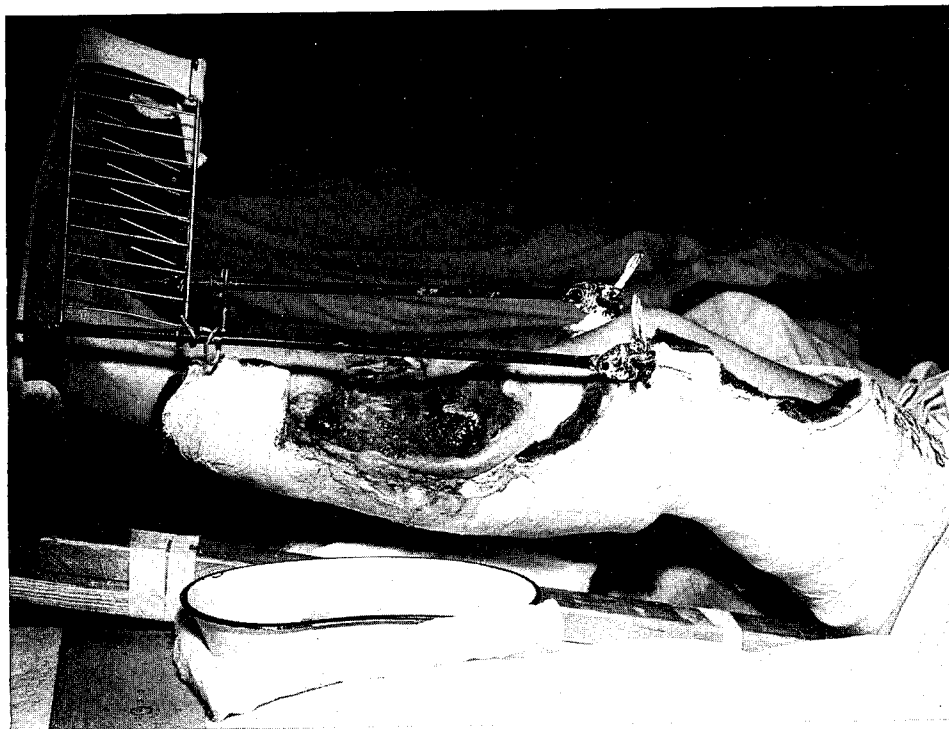


FIGURE 44.—Compound comminuted fractures of the leg with large avulsed wounds of the leg by 88-mm. shell fragments in France, after immobilization in the plaster traction splint.

inversion strain. The diagnosis of a complete tear was made by anteroposterior films, with the heel held in strong inversion while the patient was under Pentothal anesthesia. Comparison with the normal side was necessary. Significant displacement of the astragalus out of the mortise was considered diagnostic of a complete tear of the external lateral ligament.

Management of fractures of the posterior malleolus of the tibia before D-day depended upon the extent of the injury. If less than a fourth of the articular surface was involved, the residual upward displacement caused little concern. If sufficient smooth joint surface remained intact, the small fragment was displaced out of the way, and there was no tendency for the astragalus to displace posteriorly. If, however, the fragment comprised as much as a third of the articular surface, anatomic reduction was necessary. If closed methods failed, open reduction was relatively easy. A posterior approach was employed, with screw, brad, or nail fixation.

In fractures of the external malleolus, if the fracture line took the usual direction (oblique from behind, downward and forward), immobilization was not always necessary. Treatment consisted of elevation until the swelling had subsided, after which the ankle was strapped in neutral position and the patient was permitted to be ambulatory in a shoe.

In fractures of the neck of the astragalus with displacement, reduction by manipulation was usually successful. If, however, optimum position was not obtained, open reduction could be done, to assure optimum realignment. The fracture line was often intra-articular, at least in part, and this technique offered the best chance for revascularization of the body. If open reduction was necessary, there was frequently a strong indication for subastragalar arthrodesis at the same time, to increase the chances of early revascularization of the body.

Although fracture dislocations were not always regarded as emergencies, they should have been. Unless immediate reduction of the dislocated body is carried out in this type of injury, necrosis of the overlying skin may result, with conversion of the injury to a compound fracture and with consequent chances of serious infection. The displaced body may produce such severe pressure on the posterior tibial vessels that gangrene may result, while the vascular deficiency caused by direct pressure and swelling may also cause Volkmann's ischemia. Furthermore, the longer the dislocation continues, the more difficult reduction becomes. Although these facts should be of common knowledge, they were not always understood, nor was the emergency nature of this kind of injury appreciated. As a result, patients were sometimes not seen until 4 or 5 days after such an injury, with the fracture dislocation still unreduced.

In a properly treated case of this kind, manipulative reduction was performed immediately, sometimes aided by the application of traction to the os calcis by a Kirschner wire. If closed reduction was unsuccessful, open reduction was resorted to promptly. Astragalectomy was a last resort, as it did not produce satisfactory function. The best method of management, therefore, was to reduce the fracture dislocation and hope that avascular necrosis of the body would be minimal. If the results were poor, later arthrodesis could be done.

Diastasis of the inferior tibiofibular joint, which was often overlooked, always left a painful ankle if it was not treated. This possibility should have been investigated in all injuries about the ankle. If it was diagnosed, it was usually easily reduced by manipulation, after which a plaster cast was applied for 10 weeks. It was important that the cast be snug; displacement recurred promptly if it was not.

After the invasion of the Continent, many of these techniques ceased to be practical in an active theater of operations, and patients with serious injuries about the ankle, after initial treatment, were promptly evacuated to the Zone of Interior, since they could not be returned to duty within the holding period permitted within the theater. Even before the invasion, it would probably have been wiser to return many such patients to the United States rather than hold them in the theater.

Foot

Fractures of the os calcis with no significant displacement were treated by elevation and immobilization until the acute reaction had subsided. Then

physical therapy was begun, and the foot and ankle were actively exercised once an hour. Weight bearing was not permitted for 8 to 12 weeks except in an occasional case in which, for the last 4 to 6 weeks, the patient was treated in a walking cast.

Fractures with significant displacement but without comminution which caused reduction in the salient angle were also treated by elevation and immobilization until the acute reaction had subsided. Then manipulative reduction was carried out under portable roentgenologic control. A Steinmann pin was inserted through the lower third of the tibia and the posterosuperior portion of the os calcis, with a compression clamp to reduce the medial and lateral displacement of the calcaneal fragment. Both pins were incorporated in a short leg plaster cast.

Fractures with significant displacement and severe comminution, in which a subastragalar joint did not seem a possibility, were treated by elevation and immobilization until the acute reaction had subsided. Then manipulative reduction of the gross displacement was carried out, with early triple arthrodesis.

The results of fractures of the tarsal bones were usually disappointing. In addition, the patient with a compression fracture of the os calcis always had a great deal of pain. Some surgeons believed that the Pridie operation, in which the entire os calcis is removed, might be a more generally useful procedure in such cases than subastragaloid arthrodesis.

These practices were all employed before D-day, but even then prompt evacuation to the Zone of Interior would probably often have been wiser than the performance overseas of such definitive surgery as has been described.

Skeletal traction was advisable for a small number of battle-incurred compound fractures of the midtarsal and metatarsal regions. This technique was used only 15 times at the 802d Hospital Center. Traction was applied by means of a vertical wire inserted through the middle of the distal phalanx of the toes. The ends of the wires were turned back to form hooks for elastic bands, which were attached to a metal hoop incorporated in the plaster cast. The combination of plaster cast and traction to hold the fractures in position was effective, but only after the fractures had been reduced by correct manipulation and a molded splint had been applied.

Several errors were common in management of injuries of the foot. Casts were originally left on for too long a time. It was eventually found that fractures of the tarsal bones without displacement required no immobilization in plaster, except for a short time in some cases for relief of pain. It was an error to immobilize the foot and ankle in a position of equinovarus.

In battle-incurred compound fractures of the foot, some observers came to believe that better results would have been secured if amputations had been done more promptly in selected cases. This was particularly true when the entire os calcis was destroyed. A great deal of time was spent in debridement and other care, and in the end the patient was no better off functionally than he would have been if amputation had been performed at once.

CHAPTER XII

Amputations

In all wars, amputation of a limb has been an operation of necessity, not a procedure of choice or election. The total destruction of tissue, including bony tissue, was the chief indication for the majority of amputations performed in the European Theater of Operations in World War II. When the limb was irretrievably shattered and mangled or was almost completely avulsed, the attending surgeon had no choice but to amputate it. In effect, a nearly complete traumatic amputation had already been performed, and it was his clear duty to complete it.

Vascular damage, the second most frequent reason for amputation, was in many instances inherent in the destruction of tissue. This was, however, not always true. It also very often occurred in association with compound comminuted fractures, in cases in which tissue damage was not in itself irretrievable and in which, in the absence of vascular damage, the bone injury could have been managed successfully by one technique or another.

In such cases, the decision to amputate was frequently difficult and painful. Demonstrable, complete loss of blood supply to a portion of the limb, because of destruction of the main artery or arteries, was practically always an indication for amputation. Recoveries were occasionally recorded after anastomosis of a major artery, and from the theoretical standpoint, therefore, there was no justification for amputation of a limb in which vascular damage had occurred without an attempt, at least, at anastomosis and a period of postoperative observation. On the other hand, with vascular surgery at the stage at which it was in World War II¹ there was only a remote chance of saving such a limb. The operation was time consuming. For this reason, it could lead to the neglect, or at least the delayed treatment, of other seriously wounded men. Finally, the procedure was not justified on the basis of the results obtained. The reports from orthopedic surgeons in the European theater, from whose observations these data are derived, again and again state that the writers had never seen a recovery after anastomosis of the popliteal artery.

The senior consultant in orthopedic surgery knew definitely of only 3 instances in which survival of the leg below the knee occurred after ligation of the popliteal artery. In each of these instances, the indication for ligation was secondary hemorrhage 2 or 3 weeks after wounding, by which time an

¹ It should be emphasized that these observations concern only World War II. Although there will probably never be more than a limited number of combat-incurred injuries with damage to the blood supply of the limbs in which vascular surgery would be justified, in selected cases this procedure now (1955) would be both practical and warranted. A fairly large number of successes followed conservative management of vascular injuries in the Korean War, and further advances have been made in this field in the interval since those hostilities ceased. (Author's note.)

anastomosis of sufficient size to carry the blood to the leg beyond the knee must have been established. At the 68th General Hospital, the chief of the orthopedic section stated that amputation was done in only 1 of 3 cases in which the popliteal artery had been severed but that the other 2 patients would have been better off if they also had been submitted to primary amputation. The surgeons who performed the two conservative operations were misled by the condition of the superficial tissues. Eventually, the muscles of the leg, with the exception of the gastrocnemius muscle, went on to necrosis and had to be dissected out.

In the light of these results, which were typical of results in general, experienced medical officers almost universally took the position that immediate supracondylar or transcondylar amputation of the limb was indicated whenever the popliteal artery had been divided. The chances of recovery, even when surgery was supplemented by sympathetic block and such other adjunct measures as were practical in a frontline hospital, were seldom good enough to warrant the risk to life inherent in a policy of conservatism. If the anastomosis failed, as it usually did, gangrene invariably and inevitably ensued, and a secondary amputation under these circumstances was fraught with far more risk to life than primary amputation would have introduced.

The third important indication for amputation was clostridial myositis. Fortunately, it was not very frequent. The important point was to make the distinction between diffuse, spreading *Clostridium welchii* infection, in which amputation was mandatory and in which any significant delay put the patient's life in jeopardy, and localized gas bacillus infection, in which conservative therapy was warranted. The experience reported from the 804th Hospital Center is typical. Clinical *Clostridium welchii* infection was observed in 10 cases. In 5 of the 10, true clostridial myositis was present and amputation was necessary; 1 patient died. In the other 5 cases, the infection was localized and responded to wide incision and drainage, supplemented by penicillin and sulfadiazine. In the localized type of gas bacillus infection there was, of course, no indication whatsoever for amputation.

Similarly, the question of amputation never arose in the type of case in which *Cl. welchii* organisms were cultured from the wound but in which they gave rise to no clinical manifestations and were obviously nonpathogenic. Any battle wound, if examined with refined bacteriologic techniques, will probably reveal clostridial organisms, which will, however, grow and multiply only if dead muscle tissue is left as a culture medium.

Conservatism was the rule in all cases in which amputation was a possible procedure. As a rule, it was entirely justified, though, as pointed out elsewhere (p. 154), many observers thought that prompt amputation of badly shattered feet would have been wiser than the policy of conservatism employed throughout the war.

A greater degree of conservatism was both indicated and practical in the upper extremity than in the lower. The reason for this policy was the greater functional importance of the upper extremity. Military surgeons, properly,

went to almost any length to save even a small portion of a functioning hand. The reason why this policy was practical was that *Cl. welchii* infection in both military and civilian surgery is much less frequent in the upper than in the lower extremity.

Incidence and Case Fatality Rates

The incidence of amputation in the European Theater of Operations was not high in relation to either the total number of casualties or the devastating character of many wounds of the extremities. The great advances in surgery between World War I and World War II permitted the salvage of many limbs in the Second World War which would necessarily have been sacrificed in the First. Indeed, it is an ironic fact that during the period of World War II, the number of amputations which were performed for medical reasons or which were of traumatic origin in civilian life exceeded by several times the number of amputations performed for combat-incurred injuries. There was an estimated total of 17,000 major amputees as the aftermath of World War II. The number of civilians who lost one or more of their limbs during the same period has been estimated at about 80,000.

The case fatality rate for amputation was also not excessive. The 2d Evacuation Hospital, for instance, which was a 750-bed hospital, served from Normandy to Naumburg, Germany, between 23 June 1944 and 18 April 1945. During this time, it received 37,377 patients, 10,398 of whom had surgical conditions. Orthopedic admissions included 2,243 fractures of the long bones with 30 deaths (1.3 percent) and 388 amputations with 25 deaths (6.4 percent). Forty-five amputations, sixteen of which were fatal, were performed for clostridial myositis, and 327, of which 9 were fatal, were performed for trauma. There were no deaths in the 16 amputations performed on the indication of circulatory damage.

Col. Charles B. Odom, MC, analyzed the amputations performed in the 64,389 battle casualties treated in Third United States Army hospitals from 1 August 1944 to 1 February 1945² (tables 4, 5, and 6). In this total, there were 39,600 injuries of the extremities, and 3,245 wounds of the buttocks, totaling 42,845. This total represented a proportion of 66.5 percent battle casualties, reasonably near the 71 percent which it had been estimated would occur in these areas. The case fatality rate of all battle casualties was 2.9 percent and for wounds of the extremities (including the buttocks) 0.81 percent.

During the 6-month period covered by this survey, 1,365 amputations were performed on 1,290 patients in 12 evacuation and 5 field hospitals. More than 75 percent of these amputations were of the lower extremities, the disproportionate distribution being tacit testimony to the destructive efficiency of the land mines employed in World War II. Traumatic destruction of tissue was the indication for about two-thirds of the amputations, vascular damage for about a fifth, and clostridial myositis for the remainder. The case fatality rate was 9.0 percent.

² Semiannual Report, Office of the Surgeon, Third U. S. Army, 1 January-30 June 1945.

TABLE 4.—Indications for 1,365 amputations in 1,290 casualties, Third United States Army, 1 August 1944-1 February 1945¹

Hospital	Indications				Total	Deaths
	Traumatic	Gas gangrene	Vascular injury	Unknown		
Evacuation:						
12th.....	45	16	14	-----	75	4
32d.....	45	4	6	-----	55	3
34th.....	53	12	44	-----	109	9
35th.....	97	5	38	-----	140	13
39th.....	91	20	20	-----	131	11
101st.....	54	16	21	-----	91	6
104th.....	77	25	14	-----	116	8
106th.....	33	21	19	8	81	6
107th.....	72	15	32	10	129	16
109th.....	41	17	7	-----	65	8
110th.....	38	6	18	-----	62	4
Field:						
16th.....	20	6	9	-----	35	9
30th.....	27	-----	2	2	31	8
59th.....	14	-----	1	-----	15	4
60th.....	45	2	-----	-----	47	4
65th.....	11	5	8	-----	24	-----
Total.....	763	170	253	20	1,206	113

¹ The 159 amputations performed at the 103d Evacuation Hospital are omitted from the tabulated data because the breakdown is incomplete. It is known that 21 amputations were performed for vascular injury, but data are incomplete on how many of the remaining 138 operations were performed for the original trauma and how many for subsequent gas gangrene. There were 3 deaths in the 159 cases.

The 1,290 casualties upon whom these 1,365 amputations were performed included 1,012 United States Army personnel, 28 Allied soldiers, 206 German prisoners of war, and 44 civilians.

Evolution of Techniques

From the historical standpoint, the best way to describe the change in the point of view about techniques for amputation is to summarize the instructions given in the Manual of Therapy³ issued just before D-day and the instructions in the revision of the orthopedic section of this manual which were prepared in June 1945 but were not published because of the ending, shortly afterward, of the fighting in the Pacific. A comparison of the two sets of instructions furnishes an illuminating reflection of how combat experience alters the point of view.

Manual of Therapy, 1944.—Amputations, it was pointed out in the manual issued before D-day, should not be done unless the limb was almost

³ Manual of Therapy, European Theater of Operations, 5 May 1944.

TABLE 5.—Site of injury in 274 amputations for vascular damage, Third United States Army, 1 August 1944–1 February 1945

Hospital	Blood vessel								Total
	Axillary	Brachial	Iliac	Femoral	Popliteal	Anterior tibial	Posterior tibial	Both tibials	
Evacuation:									
12th.....				7	2	5			14
32d.....				2	4				6
34th.....	1	8	1	15	13			6	44
35th.....	3	3		16	12			4	38
39th.....	1	9		1	7	1	1		20
101st.....	1	6		2	12				21
103d.....		2		3	10	2	2	2	21
104th.....	1	2		6	5				14
106th.....		5		8	5			1	19
107th.....		2		14	9	4	3		32
109th.....		2	1	4					7
110th.....	1			10	7				18
Field:									
16th.....		2		6	1				9
30th.....		1			1				2
59th.....					1				1
60th.....									
65th.....		1		2	3	1	1		8
Total.....	8	43	2	96	92	13	7	13	274

completely detached. Instructions for the immediate management of the battlefield casualty who was a possible candidate for amputation were to treat a complete or incomplete traumatic amputation as any other open wound; to control active arterial bleeding; and to be certain that a tourniquet, ready for instant application, accompany the patient during his evacuation.

Further instructions in the 1944 manual were as follows:

1. Indications for amputation were (1) complete destruction of the blood supply, which meant loss of the main blood supply and most of the collateral blood supply; and (2) fulminating gas bacillus infection.

2. Indications for amputation of the upper extremity should be more rigid than indications for amputation of the lower extremity because gangrene of circulatory origin is more infrequent in the upper extremity, and because conservation of a small remnant of the hand is of far greater functional importance than conservation of a small remnant of the foot.

3. Regardless of any consideration of prostheses in the future, the limb should be amputated as low as the nature and location of the wound would permit.

4. Two types of amputation were permissible in the 1944 manual, (1) the guillotine amputation, in which the skin, soft tissue, and bone are all divided

TABLE 6.—Site of 1,365 amputations in 1,290 casualties, Third United States Army, 1 August 1944-1 February 1945

Hospital	Site						Total	Deaths
	Upper arm	Fore-arm	Hand	Thigh	Leg	Foot		
Evacuation:								
12th.....	6	1		36	31	1	75	4
32d.....	2	10	2	4	23	14	55	3
34th.....	9	14	1	28	57		109	9
35th.....	8	4	4	42	76	6	140	13
39th.....	27	21	3	34	33	13	131	11
101st.....	13	9	2	10	50	7	91	6
103d.....	24	20	7	24	52	32	159	3
104th.....	26	10		35	44	1	116	8
106th.....	9	2	2	25	35	8	81	6
107th.....	6	21	4	32	48	18	129	16
109th.....	11	13	4	16	17	4	65	8
110th.....	1	4		18	39		62	4
Field:								
16th.....	6	2	2	12	12	1	35	9
30th.....		3		8	18	2	31	8
59th.....					15		15	4
60th.....	5	5	4	6	24	3	47	4
65th.....	2	2		8	7	5	24	
Total.....	155	141	35	338	581	115	1,365	116

at exactly the same level, and (2) the circular or irregular short flap amputation, in which the skin and soft tissues are left slightly longer than the bone.

5. The guillotine amputation was to be used in cases in which the amputation level was well within the site of election. This technique was always employed with the idea that reamputation would later be necessary. The circular or irregular flap type of amputation was to be used when the point of bone division was at, or close to, the point of election. As much skin as possible was thereby saved to pull over the end of the stump, and later reamputation would not be necessary. The stump was never to be sutured.

6. If the bone had to be divided at the site of election, and if skin beyond this point could not be saved, a guillotine amputation was then indicated. The main artery and nerve were divided at the same level as the bone. The artery should be secured with a ligature, with a transfixion stitch ligature distal to it. The nerve stump was not to be treated by ligation, crushing, alcohol injection, or any other means. It was simply left unsutured.

7. Careful hemostasis of small vessels in the stump was essential, lest later elevation of the blood pressure of a patient previously in shock should cause bleeding in vessels which had not been identified at operation.

8. After both types of amputation, the stump should be frosted with sulfanilamide. A small dressing of vaseline gauze should be applied over the open stump, and additional dressings were to be applied after the stump had been placed in the splint.

9. Skin traction should be accomplished with adhesive tape and a Thomas splint, or a plaster spica could be applied for splinting and the incorporation of distal traction.

10. Skin traction should be maintained indefinitely or until healing took place. The 1944 manual permitted certain exceptions to this rule, though the exceptions were limited to irregular flap amputations with clean, granulating wounds, without discharge or edema, or without a systemic febrile reaction. In such cases, later secondary closure was permitted, with a few loose retention sutures.

11. The 1944 manual recommended that, whenever possible, a written statement should be incorporated in the patient's record, prepared by a second medical officer and signifying agreement with the necessity for amputation of the limb.

The instructions for amputation in the 1944 Manual of Therapy were confusing and were definitely written without the benefit of the extensive experience in combat-incurred wounds which was soon to occur. The chief points of difference between these instructions and those in the 1945 revision of the orthopedic section of the manual will be discussed in detail shortly.

Revision of orthopedic section of proposed Manual of Therapy, 1945.—

The summarized instructions contained in the proposed revision of the Manual of Therapy in June 1945⁴ were as follows:

1. Amputation was justified for only two reasons, (1) complete destruction of the blood supply, which meant the loss of the main artery and most of the collateral arteries, and (2) diffuse clostridial myositis.

2. Amputation should always be performed at the lowest possible level which the nature and location of the wound would permit.

3. Experience showed that the open circular amputation is the procedure of choice in the management of war wounds. The guillotine amputation had proved unsatisfactory and was not to be used. In the guillotine technique the skin, muscle, bone, and all tissues are divided at exactly the same level. In a circular amputation, each tissue layer beneath the skin is allowed to retract before it is severed, so that, after the operation has been completed and traction has been applied to the skin, the stump has the appearance of a shallow, inverted cone or saucer. The precise technique was described step by step (p. 162).

4. Decision to amputate was not to be made without consultation with the chief of the surgical service or, in his absence, with whatever senior surgeon might be available. The details of the consultation were to be noted in the patient's medical record.

⁴ Appendix B.

5. Psychotherapy, it was pointed out, was of the utmost importance in the rehabilitation of the amputee, and the surgeon, by a few words of his own, could help in the program. It was important that the operating surgeon, himself, should inform every amputee of certain facts before he was evacuated:

- a. That the amputation had been necessary as a life-saving procedure.
- b. That it had been decided upon only after consultation.
- c. That further surgery for revision of the stump would probably be necessary.
- d. That the patient would be sent to an amputation center where he would be fitted with an artificial limb and where other facilities would be available for his rehabilitation.

6. A disarticulation was to be performed only when there was no other possible choice of a more conservative procedure. This is not a desirable operation. The stumps are difficult to handle, and they discharge profusely. Traction is extremely difficult to maintain. The stumps always need extensive revisions, most of which must be performed in two stages. In view of these considerations, disarticulation of the knee was permitted as an emergency measure but was not to be performed routinely.

Technique of circular amputation, 1945.—The successive steps of a circular amputation were set forth as follows in the 1945 revision of the orthopedic section of the 1944 manual:

1. The skin of the extremity is prepared as for a surgical procedure.
2. A tourniquet is applied.
3. The incision is made in a circular fashion, down to the deep fascia, at the lowest possible level. An oblique incision is permitted in cases in which it would result in conservation of the skin and of the length of the extremity.
4. The skin is allowed to retract. The deep fascia is then divided at the level to which the skin has retracted.
5. The muscle is divided in circular sweeps, about three-fourths of an inch being included in each sweep, so that, as the muscle retracts, the next muscle division is made at a slightly higher level.
6. The periosteum is cut in a circular manner at the level to which the last muscle layer has retracted.
7. The bone is sawed through cleanly at this level. The periosteum is not elevated or stripped, and no attempt is made to remove it at a higher level than the saw cut.
8. Nerves are severed cleanly at the level of the surrounding muscle division. They are not crushed or ligated, and the ends are not injected with alcohol.
9. Precise hemostasis of the stump is essential. All large veins and arteries are doubly ligated, separately and not en masse. Extreme care is taken not to include large amounts of muscle in the ligation of small vessels. After all the larger vessels have been ligated, the tourniquet is removed, the field is inspected, and any remaining bleeders are ligated.
10. The end of the stump is covered with dry, fine-mesh gauze. Sulfonamides are not used to dust it or frost it.

11. Skin traction is applied immediately and is maintained continuously while the patient is being evacuated and until healing occurs. There is but one exception to this rule: When the amputation has been performed for clostridial myositis, skin traction is not applied for the first 24 to 48 hours. At the end of this time it is possible to determine whether the wound is clean or infected. No patient, however, should be evacuated from any Army installation until skin traction has been applied.

Skin traction for transportation has been found to be most satisfactory when it is applied in the following manner:

a. After the stump has been covered with sterile, fine-mesh gauze, a circular roll of stockinet is applied to the stump and is rolled as far as possible proximally.

b. The skin is painted with tincture of benzoin.

c. After the skin has dried, an adherent is applied to it down to the cut edge of the stump. The stockinet is then unrolled down on the stump and is allowed to adhere to the skin. Traction is applied to the stockinet and additional dressings are placed inside it, against the end of the stump.

d. Traction is continued by an assistant while several layers of sheet wadding are applied loosely over the stockinet. A circular plaster pylon is then applied to the stump, with an outrigger made of a wire ladder splint. The end of the stockinet is fastened to the outrigger by means of a short piece of elastic traction cord or, if the cord is not available, by means of plasma tubing.

The following types of plaster pylons are indicated for special injuries:

Below the knee, a below-the-knee-to-the-groin pylon, with the knee in full extension.

Thigh, a single hip spica pylon, with the hip in neutral position.

Forearm, a full-arm pylon, with the elbow flexed at 90 degrees.

Arm or humerus, a shoulder spica pylon, with as little abduction as possible and the axilla well padded to avoid pressure.

Comparison of the 1944 and revised instructions for amputation.—The revised draft of the orthopedic section of the Manual of Therapy for the most part simply took cognizance of changes in technique that had been in effect since shortly after D-day. Most of them were incorporated in Circular Letter No. 101, issued 30 July 1944 from the Office of the Chief Surgeon, ETO.⁵ Other instructions were contained in Circular Letter No. 131, issued 8 November 1944.⁶ In that letter, secondary closure of the stump was forbidden in the European theater, on the ground that it often led to infection and necrosis of the skin. When the skin sleeve was inadequate for closure by traction or when the bone ends were obviously too long and protruded, the stump was to be revised at the lowest possible level. The skin edges were to be mobilized by undercutting and the bone and soft tissues were reamputated just enough to allow closure by traction, which was promptly reapplied and maintained continuously. Split-thickness skin grafts were prohibited in the absence of

⁵ Circular Letter No. 101, Office of the Chief Surgeon, European Theater of Operations, 30 July 1944 (appendix A, p. 322).

⁶ Circular Letter No. 131, Office of the Chief Surgeon, European Theater of Operations, 8 November 1944 (appendix A, p. 325).

unusual and sound indications, for the reason that they do not tolerate prostheses.

The differences between the 1944 and later instructions for amputation concerned both substance and emphasis. As has already been pointed out, the original instructions were written without practical experience in combat-incurred wounds and the later instructions after an extensive experience.

The differences in point of view and specific details may be summarized as follows:

1. In the 1944 Manual of Therapy, both the guillotine and the circular techniques of amputation were permitted. In the 1945 draft of the proposed revision, circular amputation was mandatory, a fact which reflects the early, brief, and unsatisfactory experience with the guillotine technique. This ill-named operation is almost impossible to perform without the help of an actual guillotine. When the skin is divided in a circular amputation, it always retracts, and so does each layer of muscle. The surgeon who attempts a so-called guillotine operation usually ends by performing a true circular amputation, which is an inverted cone, with skin left long enough to pull down over the stump to close it. It was not very long before circular amputations were routine in the European theater, and both the name and the technique of the guillotine amputation were abandoned.

The circular amputation, which was performed at the farthest possible distal point of the wounded extremity, was a preliminary step. Usually a re-amputation at an elective site was expected to be performed in an amputation center in the Zone of Interior. The amputee was always informed of this plan.

While the circular technique, with nonsuture of the stump, was the safest procedure for combat-incurred wounds, there was some basis for the claim that immediate flap amputation at an elective site would be equally successful *if all damaged muscle and retained foreign bodies were removed*. The healing power of young soldiers in superb physical condition, as these men were, was remarkable. On the other hand, the majority of the surgeons who were performing these amputations were inexperienced and, at the time, closure of amputation stumps seemed an invitation to surgical disaster. The advantages of immediate elective amputation, which would have prevented duplication of surgery, therefore had to be foregone. There is no doubt that the technique which was made mandatory was by far the safest under the circumstances.

2. In the draft of the proposed 1945 revision of the orthopedic section of the manual, specific techniques were described in detail. In the 1944 manual, instructions were very general. The greater specificity of the revision is, again, a reflection of the necessity for leaving nothing to the imagination of inexperienced military surgeons.

3. In the 1945 revision, provision was specifically made for the use of a tourniquet at operation. A tourniquet was not mentioned for this purpose in the 1944 manual.

4. The use of sulfonamides on the stump was provided for in 1944 and specifically prohibited in 1945. As has already been pointed out, their local

application perhaps did no harm, but it was discovered, after several months' experience, that it also did no good, and the practice was discontinued.

5. The use of vaseline gauze was provided for in the 1944 manual, but in the 1945 revision it was specifically directed that dry, fine-mesh gauze be used. The use of vaseline gauze proved actually harmful because it prevented free drainage of secretions (p. 84).

6. In the 1944 manual, the provision of traction by adhesive plaster strips and the Thomas splint was described. In the revision, this technique was omitted, and a technique of skin traction combined with plaster was described, again very specifically. In the revision, the only exception to the immediate institution of traction was a 24- to 48-hour delay after amputations for clostridial myositis.

7. Consultation before amputation was permissive in 1944 and mandatory in 1945. It was specifically directed that the situation, including the need for a second amputation at an elective site, be made clear to the amputee. It was also to be made clear to him that the second operation, for revision of the stump, was part of the ordinary routine.

8. Psychotherapy was also provided for in 1945. Very early in the experience of the European theater, it became evident that, when the necessities of his special case were clearly and sympathetically explained to an amputee, it was the exceptional patient who did not bear with remarkable fortitude the psychologic blow inherent in the loss of a limb.

Special Considerations of Traction

Orthopedic surgeons stationed in the United Kingdom Base usually found amputation stumps of patients received from the Continent in good condition, from the standpoint of the wound. Frequently, however, the surgeons complained that traction was inadequate. For this error there were several explanations: Sometimes the circular plaster type of countertraction had been used; this was not a satisfactory technique. Sometimes the elastic cords and rubber tubes used for purposes of traction had not been tightened en route. Sometimes the transportation casts were not satisfactory. A hip spica, with traction incorporated in it, proved the only way to guarantee really effective traction during transportation after amputation of a lower limb.

Until the end of the war, occasional medical officers continued to prefer the Thomas splint, as had originally been advised in the 1944 Manual of Therapy (p. 161), with fixed countertraction against the ischium. The reason for their preference was that when this splint is used there is no tendency for the skin to pull in the opposite direction.

Long leg casts were not always satisfactory. When patients were transported in them, traction had frequently ceased to be functional by the time a general hospital was reached. This was true whether the amputation had been above or below the knee. The cuff always had a tendency to slip down, because there was nothing to which it could be anchored. Traction hooked up to wire ladder splints was also not entirely satisfactory in amputations of

the upper extremity, whether the amputation had been above or below the elbow.

In fixed general hospitals, traction was easily maintained by the use of a pulley and weight over the foot of the bed. The essential consideration was that it be continuous. The maintenance of continuous traction required repeated inspections, with correction of the position of the equipment if it had slipped at all.

Amputations Caused by Special Types of Missiles

Blast injuries.—Among the large number of wounds of the extremities encountered in the hospitals in the United Kingdom Base soon after D-day were numerous blast injuries caused by mines at sea. These injuries were frequently presented in the form of destruction of the os calcis, fractures of the upper tibia, and fractures at the knee joint, often with dislocation. Profound damage to the popliteal vessels was usually part of the picture, and amputation was often the only possible procedure.

It soon became apparent that in this type of injury it was not safe to undertake operation without a particularly careful evaluation of the patient's status and without unusually careful preoperative preparation. When the casualties were first seen, they were, for the most part, obviously poor risks. Sometimes, however, they would seem to recover from the initial shock of wounding and to be in good condition. They looked well, the pulse was of good quality, and the blood pressure was well above the dangerous level, or, occasionally, abnormally high. Appearances were deceptive. If the timing of operation was not correct, these patients were likely to go into profound secondary shock, which was difficult, and sometimes impossible, to overcome. It was ultimately found that the best plan in all of these cases was to delay operation several hours longer than on the surface seemed absolutely necessary, to be certain that the appearance of well-being was genuine and not specious and misleading.

Land mines.—Patients with wounds of the lower extremities received in land-mine explosions often presented, in addition to multiple comminuted compound fractures, damage to the popliteal circulation, which was frequently total. Multiple foreign bodies had often penetrated the regional vessels. Because of the vascular damage, amputation was practically always necessary in such injuries, though, as in the blast injuries just described, it was best performed as a delayed procedure, to be certain that the patients were completely out of shock.

Guided missiles.—Much the same observations as those just described for blast injuries and injuries from explosions of land mines were made on patients who had suffered injuries of the extremities from guided missiles. Their appearance was often misleading, and, unless this fact was recognized and surgery was delayed, fatalities from unrecognized shock were not infrequent.

CHAPTER XIII

Adjunct Therapy

Resuscitative Measures

The techniques of resuscitation are described in detail in other volumes of this history. Here it need only be said that from the standpoint of a casualty with a bone or a joint injury resuscitation was a continuous procedure. It began on the battlefield with the control of hemorrhage, temporary emergency splinting, the application of dressings, and the administration of morphine in limited doses for the control of pain. It was continued through the various forward echelons of medical care up to the evacuation hospital, where initial surgery was done. In the evacuation hospital it had to be carried through without delay and with full appreciation of all measures, including the position of the patient, protection from unnecessary exposure, the use of oxygen and of blood and plasma as indicated, emptying of the stomach before operation, and the maintenance of a free, dry airway during anesthesia.

Emphasis was consistently placed on adequate blood replacement and proper timing of surgery. Even casualties whose injuries were limited to the bones and joints were frequently in severe degrees of shock and required the liberal administration of blood before they were fit for operation. If the patient did not respond with reasonable promptness (preferably within 3 hours) to adequate measures of resuscitation, it could be assumed that some factor was present which accounted for the situation, such as continuing hemorrhage, massive infection, or blast concussion. Under the circumstances, it was frequently wiser to proceed with surgery without further delay and to continue the administration of blood on the operating table. Patients with fractures of the long bones, particularly compound comminuted fractures of the femur, required especially large amounts of blood for resuscitation.

Supplemental Therapy

Blood replacement.—Blood replacement was an extremely important phase of management in all stages of bone and joint injuries. Transfusions, as just pointed out, were lifesaving immediately after injury and were essential in the preparation for surgery when a patient reached a general hospital. Plasma was no substitute for whole blood. When a casualty had suffered a large blood loss, as was particularly frequent in compound fractures of the femur, blood transfusions were necessary to restore the blood volume, maintain the plasma proteins, combat sepsis, prevent shock when long surgical procedures were required, and improve the appetite and general well-being after operation. The preferred plan was not to operate on these patients until the hematocrit

was at least 35 and preferably higher. The copper sulfate technique was a rapid and efficient method for the determination of the hematocrit in large numbers of patients.

Transfusion reactions were remarkably few, considering the enormous quantities of blood used. Thus, at the 216th General Hospital, 1,389 transfusions were given on the surgical service between D-day and V-E Day with no deaths and with only two transfusion reactions of any severity; both were instances of hemoglobinuria.

Protein replacement.—Casualties with severe wounds rapidly became depleted of protein, though the deficit was not always precisely reflected in the plasma protein values, since this protein was held up at the expense of the body tissues. Instead, the deficit was chiefly manifested in the development of wound edema, failure of wound healing, decubitus ulcers, and general wasting.

The need for protein replacement was generally realized, as was clearly shown by a study carried out on the orthopedic section of the 803d Hospital Center. This section, for a period of 2 months, was divided into 2 parts. Half the patients were fed the regular hospital diet, with supplemental vitamins but no additional proteins. The other half were given a daily diet which contained 135 gm. of protein. The contrast was impressive. Edema was practically absent in the patients provided with additional amounts of protein. Infected wounds cleared up twice as fast as in the control group. Wound breakdowns were 33 percent less. There were no decubitus ulcers in the treated group against two in the control series. The general physical condition and the mental condition of the treated patients were also far superior to the condition of the patients in the control group.

As a result of this study, it was made standard operating procedure at the 803d Hospital Center that all patients with compound fractures and other wounds be managed by a so-called orthopedic diet until their wounds were completely healed and they were in excellent condition. This daily diet included a total intake of 3,500 calories, 135 gm. of protein, a unit of plasma intravenously, and multiple vitamins. Additional calcium was given in the form of calcium gluconate and in milk and eggs, chiefly served in the form of chocolate milk with powdered egg added.

Position.—The edema invariably present in war wounds after wounding and debridement was particularly noted in the legs, feet, forearms, and hands. It sometimes made delayed primary closure extremely difficult. Some general hospitals therefore adopted the practice of suspending the injured extremity from an overhead frame as soon as the patient was admitted. Elevation, in the absence of contraindications, was maintained for 7 to 14 days after operation.

Chemotherapy and Antibiotic Therapy

Until almost the end of the war, American soldiers were provided with sulfanilamide pills and sulfa crystals in their first-aid kits. They were instructed to take the pills as soon as they were wounded and to sprinkle the

crystals into their wounds if they were able to do so. If not, this was accomplished by the first-aid men. It was also a rather general policy for a few months after D-day to sprinkle sulfa crystals into the wounds at surgical closure. These practices did no good either on the battlefield or in the operating room, and both were eventually abandoned.

Penicillin became available in the European theater before D-day, and the Mediterranean-theater policy was instituted of administering it to all but the most lightly wounded immediately upon their arrival in the evacuation hospital. Later, when it became more plentiful, a European Theater of Operations directive¹ gave instructions for the first dose to be administered in the division clearing station. Allied personnel received 20,000 to 30,000 units every 3 hours, frequently in combination with 1 gm. of sulfadiazine every 4 hours. This was the practice in all major compound fractures and major joint injuries. In minor injuries, sulfadiazine frequently continued to be used alone. Because of limited supplies of penicillin, prisoners of war received only sulfa drugs, unless their wounds were considered dangerous or their condition was serious.

The administration of penicillin was either by continuous intramuscular injection or intermittently. It was thought that the former technique gave more consistent drug concentrations. It was the best practice, though it was not usually possible, to determine the sensitivity of the particular organisms present in a wound before the penicillin was given. When no sensitivity was demonstrated, a sulfonamide drug was substituted.

The local use of penicillin was discouraged except for its instillation into wounds of the joints. It was used for this purpose in 10,000- to 25,000-unit doses before primary or secondary closure of the joint.

Opinions differed as to the value of combined therapy. Some observers believed that it was better to use penicillin and the sulfonamides independently. Others considered that combined therapy was useful. Still other experiences suggested that the substitute of one drug for another after a certain period of time was a more useful practice than administering them together.

The sulfonamides and penicillin had their widest field of usefulness in broadening the scope of surgery. Their function, from the surgical standpoint, was protective rather than prophylactic or curative. This use aided in the debridement of wounds even after an extensive timelag. It also gave surgeons a feeling of confidence in the delayed primary closure of wounds, even when they were associated with compound fractures. Finally, operative procedures could be conducted through healed wounds without reactivation of latent infection.

On the other hand, the remarkable freedom from infection which was enjoyed in World War II, particularly in the later months of the war in the European theater, must not be attributed chiefly to the use of these new agents. It is primarily attributable to adequate debridement plus the liberal

¹ Circular Letter No. 71, 15 May 1944, Office of the Chief Surgeon, European Theater of Operations. Principles of Surgical Management in the Care of Battle Casualties.

use of whole blood to replace blood which had been lost. If these principles were disregarded, infection was just as likely to occur with the use of penicillin as without it.

Psychotherapy

One of the highly favorable factors in the management of patients with injuries of the bones and joints was that, in spite of the severity of many of these injuries, they occurred in men who were young, in excellent health, well fed, and, for the most part, well clothed. The concurrent illnesses and disabilities which had existed in many previous wars and had militated against optimum results in orthopedic surgery did not exist in the European Theater of Operations, with the single exception of trenchfoot, which was a major problem during certain periods of the winter of 1944-45. This subject is discussed in detail in a separate volume in this series.

The emotional status of the casualties was, however, another matter. An evaluation of it was one of the first considerations of treatment, no matter what type of wound the soldier had sustained. Most of the patients brought into aid stations, clearing stations, and evacuation hospitals were suffering from battle exhaustion as well as from severe physical injury, and the one state required attention quite as much as the other. In the first weeks after D-day, orthopedic surgeons frequently called upon the psychiatrist if the emotional disturbances were severe. As time passed, psychiatric services became less and less necessary because the surgeons, after handling large numbers of patients, had themselves learned the principles of management of these disturbances.

Sympathy had no place in their management. For the first 3 or 4 nights spent in an evacuation hospital the patient usually received large doses of barbiturates, to prevent him from reliving his battle experiences after the ward quieted down. As soon as possible, the surgeon in charge of the case talked to him. He explained to him as simply as possible the nature of his injury and the treatment already instituted and proposed, and told him, in a general way, how long the course of treatment would be. It was made clear that in many respects the length of convalescence would depend upon the cooperation of the patient quite as much as upon the skill of the medical officers treating him. If he had the kind of injury which would require his return to the United States, he was given that information at once, though never if there was the slightest doubt that this would happen.

One of the most effective ways of raising the injured man's morale was placing him on a ward with other men who had received the same sort of injury and who were on the way to recovery. This was particularly true if amputation had been performed or if it was thought it might be necessary. This plan often had remarkably good results. Ward discipline was relaxed as much as possible. A spotless environment was regarded as of much less importance than having a man with both legs off, for instance, throw an orange peel at a similarly afflicted patient across the ward.

Workers in the rehabilitation section, workers in the various special services, and Red Cross workers all helped to keep the patients occupied and leave them with no time to brood. Red Cross workers were untiring in their efforts to solve individual problems, which sometimes were major and sometimes only seemed major because of the circumstances. Finally, Army chaplains were always of the greatest assistance in the management of casualties, not only those who were fatally injured but also those who had survived with disabilities and deformities.

Attention to such considerations as these might seem, on first glance, to be completely unnecessary in orthopedic surgery. Inexperienced surgeons who were at first inclined to take this point of view soon learned just how important they were and how greatly attention to them contributed to prompt recovery and rehabilitation.

CHAPTER XIV

Postoperative Complications

Wound Infections

Three types of wound infections were observed in bone and joint injuries treated in United Kingdom Base hospitals after debridement in hospitals on the Continent:

1. In some wounds the infection was superficial; there was no local reaction other than a moderate discharge of debris, and there was no systemic reaction. Closure was usually possible after 3 to 5 days of treatment by compresses of physiologic salt solution and pressure dressings. At operation in these cases, particular care was taken to place the sutures loosely, and drainage was always provided for 48 hours. Penicillin by the intramuscular route was given for at least 72 hours after operation.

2. The type of wound infection just described was sometimes complicated by a low-grade osteitis. These patients were also treated with compresses of physiologic salt solution and pressure dressings for 3 to 5 days, after which secondary debridement was done, with the removal of all obviously infected bone. Compresses were continued for another 3 days, after which the wound could usually be closed loosely. Penicillin by the intramuscular route was given during this entire period and for 5 days following wound closure.

3. Wounds which were grossly infected usually yielded streptococcus and many other bacteria. Retained foreign bodies were frequent. Complete re-debridement was done in these cases, under penicillin protection, and sometimes had to be repeated one or more additional times. Foreign bodies were removed, and the wound was counterdrained. Intramuscular penicillin was continued after operation and local penicillin drips were sometimes used also.

Draining sinuses.—Draining sinuses were a frequent complication of inadequate debridement. They were also the most frequent complication of unwise closure of infected wounds. The best method of treatment was to cut down on the sinus, remove the underlying dead bone, and reclose the wound. Clostridial infection seldom occurred when this technique was employed.

Clostridial infections.—There were two chief causes of clostridial myositis, (1) inadequate debridement and (2) destruction of the regional blood supply. Even if debridement had been adequate, packing the wound tightly with vaseline or other gauze or enclosing it in a tight plaster cast could so completely seal it that anaerobes could flourish in the tissues. Under these circumstances, no amount of sulfonamides or penicillin could control the local growth of the organisms, because there was no local blood supply to carry these agents to them. Similarly, anti-gas-gangrene serum was ineffective.

The only 2 deaths from clostridial myositis in the 7,500 surgical admissions at the 803d Hospital Center are typical. Both followed compound comminuted fractures of the femur. In both, debridement had been inadequate. In both, the infection was established in the psoas muscle when the patients were received. Death occurred promptly in each case, from toxemia; 1 patient died 2 hours after admission and the other within 16 hours.

Clostridial myositis was more frequent during the Normandy campaign than at any other time during the war; it was especially frequent during the fighting around Saint Lô, France. At this time, debridement was inclined to be somewhat conservative. It was necessary, however, to guard against the other extreme of radicalism, which solved the problem by amputating the extremity with too much haste. Acceptable standards of therapy were eventually worked out as a result of bitter experience.

Local abscesses from which gas bacillus could be cultured were frequent. They were treated by wide debridement, and penicillin therapy was given intramuscularly and was sometimes supplemented by sulfadiazine. The results, due to the debridement, were usually good.

Osteomyelitis

Low-grade osteomyelitis was treated by curettage of the infected bone until normal, bleeding bone was reached. The patient was given penicillin, and a pressure dressing was kept in place for 7 days. In some cases, compresses of physiologic salt solution were substituted for the pressure dressing. If at the end of a week the wound appeared clean, a muscle transplant was placed in the bone defect and the wound was closed with a split-thickness skin graft. Healing usually followed promptly. The patient was then evacuated to the Zone of Interior where, later, the muscle transplant and skin graft were excised and the wound defect was filled with cancellous bone chips. Wound closure was effected at this operation with a full-thickness graft.

Secondary Hemorrhage

The ever-present possibility of secondary hemorrhage furnished an important argument for complete exploration and debridement of every battle-incurred wound. Any wound, no matter what its size, could conceal severe vascular damage, and this damage, in the absence of adequate examination, could remain undiscovered until serious hemorrhage ensued.

Other causes of secondary hemorrhage included the retention of foreign bodies; the pressure of drains and packs placed too near major vessels; and infection which could cause erosion or damage to a vessel wall, or lysis of a thrombosis which had effectively closed the lumen of a lacerated vessel. Oozing through the wall of a gradually enlarging aneurysm was still another cause of secondary hemorrhage. Whenever splinting was careless, two risks were introduced: (1) Movement of the fractured bone during transportation, and

(2) the impingement of mobile bone fragments on vessel walls, with resulting trauma to the tissue. Hemorrhage could follow in either of these circumstances.

A patient in whom bleeding was considered a possibility was never evacuated until the risk was definitely ended. Whenever the history of previous bleeding or the location of the wound made secondary hemorrhage a possibility, the ward personnel was warned to be on guard and was given instructions in what to do until help could arrive. It was sometimes thought best to warn the patient also of the possibility, so that he would call for help promptly if symptoms appeared. Splints were always so adjusted as to allow for emergency control of hemorrhage until definitive control could be effected. This was accomplished by providing windows in the cast over pressure points proximal to the wound, or by placing a tourniquet beneath the plaster so that it could be tightened, if necessary, for emergency control of bleeding.

It was the general experience that most major secondary hemorrhages were preceded by oozing or by minor hemorrhage. These signs should always have served as warnings, but they often did not because they could be controlled by packs and pressure dressings, sometimes with deceptive ease. It was also the general experience that resort to these temporizing measures simply postponed the severe and perhaps fatal hemorrhage likely to follow the first minor bleeding. Failure to appreciate the gravity of the warning oozing, no matter how slight it might seem, was an outstanding error of management in many hospitals. The correct policy was to explore the wound at once, under general anesthesia and under aseptic conditions, in order to find and ligate the bleeding point. This plan sometimes resulted in unnecessary explorations, but it also prevented many severe hemorrhages which could easily have been fatal, particularly if the patient had been evacuated without first identifying or excluding the source of the first bleeding.

The source and management of secondary hemorrhage are discussed in detail in the volume on vascular surgery in this series. The subject is simply mentioned here because hemorrhage is one of the possible complications of combat-incurred injuries of the bones and joints.

Decubitus Ulcers

Decubitus ulcers were best managed by taking precautions to prevent their occurrence. If they developed, as they not infrequently did in spite of these efforts, local applications of Azochloramid (chloroazodin) with debridement as necessary, was standard treatment. The practice of placing Kirschner wires through the iliac crests and suspending the patient from a Balkan frame, so that the buttocks did not come into contact with the bed, hastened healing and greatly simplified nursing care. A high-protein diet was an essential part of the treatment.

CHAPTER XV

Rehabilitation

Rehabilitation Hospitals

Rehabilitation and reconditioning were matters of considerable importance even before D-day, because an overwhelming proportion of hospital admissions in the United Kingdom Base consisted of bone and joint injuries. Col. Rex L. Diveley, MC, who was the first senior consultant in orthopedic surgery, developed a special interest in this field. Shortly before D-day he was relieved of his consultant duties to become chief of the Rehabilitation Division in the Office of the Theater Chief Surgeon. Meantime, a number of enlisted personnel from the United States Army were trained in rehabilitation work in the Royal Army Medical Corps institutions for rehabilitation at Kingston-on-Thames, Aldershot, Taunton, and Edinburgh.

The first American rehabilitation center was set up at Bromsgrove, England, and was originally planned as a superorthopedic center, where the more difficult orthopedic procedures would be handled in addition to rehabilitation. The idea was sound as long as the expeditionary force remained small. It ceased to be practical by the time that 3,065,505 troops were in the theater and were being served by about 200 general and station hospitals.¹

After D-day, as the flood of casualties increased, the load became too heavy even for the special rehabilitation hospitals which had been set up, and the program many times had to be assumed by rehabilitation sections in individual station and general hospitals, sometimes with distinctly inferior results. Even in the best hospitals, the program was somewhat slow in getting under way after D-day. Then it began to improve, particularly as cooperation between orthopedic and rehabilitation sections became closer. Nonetheless, rehabilitation of orthopedic casualties was best handled in hospitals set up for this special purpose. Without them, there would have been a great deal of delay in getting many men back to duty because the large hospital centers were too crowded and too busy to undertake the work properly, and on the wards rehabilitation often had to give way to more urgent problems. A maximum number of orthopedic casualties were returned to duty, in optimum condition, from the rehabilitation hospitals. Furthermore, as time passed, evacuation policies were improved, and one error which had taken up much time and bed space unnecessarily, was corrected; namely, men with relatively minor injuries were no longer sent to these units.

¹ Strength reports of the Army, prepared by the Office of the Chief of Staff.

Physical Therapy Programs

The load of rehabilitation in bone and joint injuries was chiefly carried by the department of physical therapy. There was, however, a constant shortage of properly trained physical therapists and technicians to handle the volume of injuries which became their responsibility. As a result, the therapists were not on the ward as often as was desirable, and much of the instruction and the persuasion necessary to implement the program were necessarily left to the ward attendants, who were constantly with the bed patients and who could insist that the prescribed exercises be carried out.

Most orthopedic surgeons were fully conscious of the need for rehabilitation and reconditioning and regarded definite programs of exercise for both bed and ambulatory patients with bone and joint injuries as part of their therapeutic responsibility. One or two hospitals displayed a good deal of imagination in setting up these programs.

An elaborate program of rehabilitation was set up at the 802d Hospital Center, where it was started as soon as the patient was admitted. It was carefully explained to him, as soon as his condition permitted, that his recovery depended more upon his general condition than upon any other single factor and that his general condition depended, in turn, upon his eating, keeping all his muscles in optimum tone, and keeping himself interested, cooperative, and eager to live and recover. He was told that the hospital would make his surroundings as attractive as possible, that the first few days would be difficult but that, nonetheless, he must make himself participate in all the activities which were prescribed and that he would soon find participation easier. It was explained to him that a healed bone was useless without a functioning muscle, and that a prosthesis would be of small value without muscular function. He was also plainly informed that, once muscles were allowed to become wasted, it was very hard to rebuild them. The physical therapist and a technician were present when the patient was given this information by the medical officer, and they, in turn, explained and demonstrated to the patient the remedial exercises required of him to achieve the results expected.

Early each morning all roentgenograms taken the previous day were reviewed by the chief of the orthopedic section and his entire staff, including the physical therapist. Progress was discussed, and a general review of the whole program was undertaken. Informal rounds were made during the week, to keep those in charge of the program fully abreast of it. On Sunday, formal rounds were made by the chief of the orthopedic section and were attended by everyone who had any connection with the program. At this time, the exercises for each patient were outlined for the following week.

On the ward, regularly performed remedial exercises were the basis of rehabilitation. The wardmaster was responsible for the supervision of the patients. Each hour was announced by him and, for the next 5 minutes, all other activities that could be stopped were discontinued while the prescribed exercises were carried out. Whenever possible, new or difficult exercises

were checked by the physical therapist or by the physiotherapy technician to be certain that they were being carried out correctly. Three times daily, at 10, 2, and 4 o'clock, exercises for the entire hospital were directed over the loudspeaker system. Ward personnel were encouraged to take the exercises with the patients.

As might have been expected the results of reconditioning and rehabilitation at this hospital center were unusually good. Time and effort were spent on the program, which was directed with energy and imagination, and the patients responded to the program with equal enthusiasm and interest.

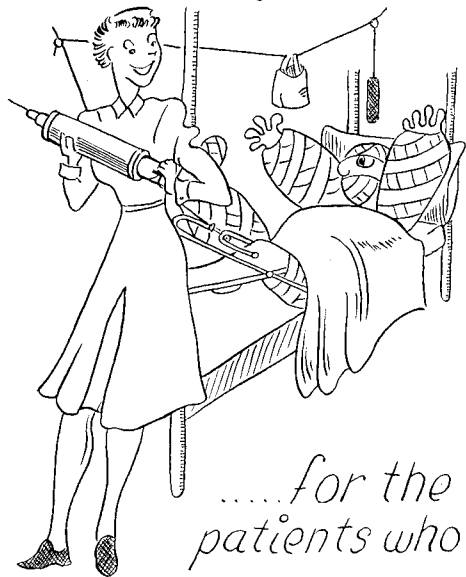
Another excellent program was directed and carried out at the 129th General Hospital. One of its features was the presentation to each patient of a booklet entitled "Fracture Facts" which had been written by Lt. Col. Philip S. Foisie, MC, and illustrated by Sgt. William Pitney (see extracts from booklet, pages 180 to 183). The necessity of using the arms and legs to prevent muscular atrophy from disuse was clearly set forth, and the booklet proved of great value in the rehabilitation of patients with bone and joint injuries.

Replacement Centers

From the standpoint of orthopedic surgery, replacement centers did not function as well as could have been wished. Soldiers sent to them with precise recommendations for limited duty were frequently returned to their original units or were sent to other units in which the duties were equally arduous. As a result, they were soon on their way back to the dispensary or the hospital.

This was extremely unfortunate. There were in the theater many positions which were occupied by men who were good combat material and which could quite well have been filled by men qualified only for limited duty. Too frequently, until the last weeks of the war, little or no attempt was made to substitute these men for men fitted for frontline duty. Even then, the exchange was often not entirely satisfactory. On the other hand, some of the men designated for limited duty were in need of rehabilitation themselves, and sometimes in need of actual hospital care. This waste of manpower in World War II should be borne in mind in any future war. It could have been partially avoided by having mature and experienced medical officers, preferably with combat experience, serve on disposition boards and in replacement centers.

FRACTURE FACTS



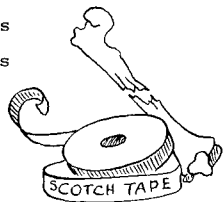
.....for the patients who

GET ALL THE BREAKS

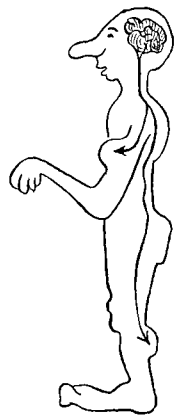


You have now arrived at a GENERAL HOSPITAL where your broken bones and your wounds are to receive the best possible treatment we can give. The personnel of this hospital is eager to do its level best to restore full function to your injured parts. . .

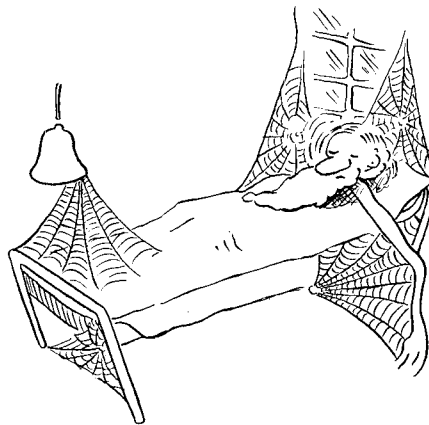
We will set your bones and sew up your wounds and give you medicine and take care of your needs.




The human body is designed for continued use. It doesn't build up strength by resting . . . that is, not by COMPLETE rest or TOTAL inactivity



But your muscles are controlled by your brain alone, and WE can't move them for you any more than we could breathe for you. YOU alone have control over those muscles. . .

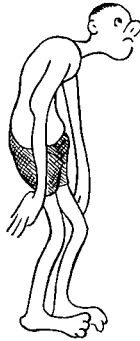


You can't pull the main switch for a month or two and then start up again. The human body must function at least in low gear to stay in good condition.

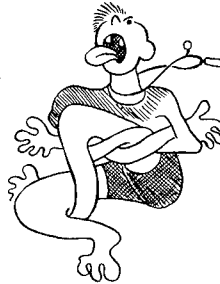

Muscles, particularly, depend on use to REMAIN HEALTHY. Use develops them. . .

...and with disuse they soften and shrivel up. Joints also, even uninjured ones, become stiff if they aren't moved.



Wounds in healing contract or shorten so that fingers, knees, elbows, and all other joints become bent. . . .



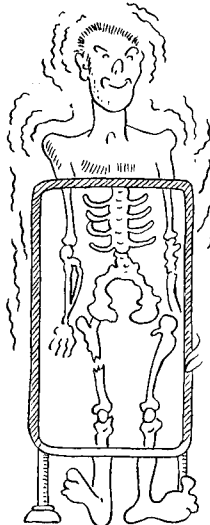
Now, broken bones have to be SPLINTED in order to knit together.

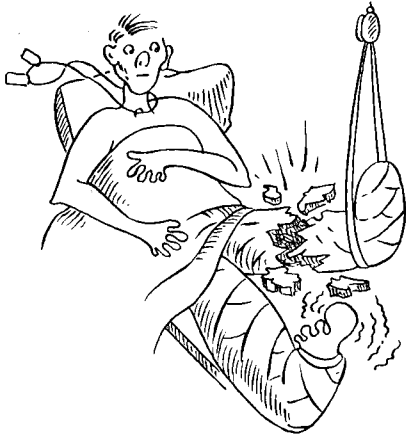


This means that for a while the adjacent joints will not move. We don't like this, but we can't avoid it. However, we'll tie up those joints for the shortest possible time consistent with healing. We'll watch the fracture with X-rays (and otherwise) and remove the splints as soon as we can.



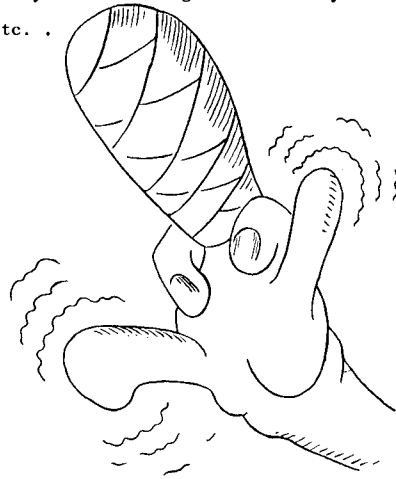
Therefore. . if you just lie in bed and vegetate until your injuries are healed, you will have stiffened and bent-up joints which your disused muscles won't be able to straighten out again. The only way to keep your joints and muscles supple is to never let them get stiff.




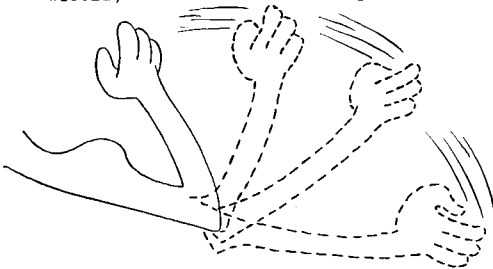


During this period you can still keep the muscles strong by "SETTING" them even though they don't actually move the joints. The ward personnel will show you how to do this.

All joints that are not tied up must be kept moving. Move everything that isn't tied down. This means that if your wrist is in a splint, keep on moving your fingers and elbow and shoulder. If your middle finger is tied up, move your thumb and your other fingers. . . and your wrist, etc. .



. and move them not just a LITTLE WIGGLE, but over the full range of motion.




Five minutes out of every hour throughout the day must be spent in setting muscles and in exercising joints.




Then when a joint is removed from fixation you are going to have to limber it up. Don't be discouraged when you find out that it won't move at first, and don't try to do it all the first day.

Apologies to Sir Dick Wingard

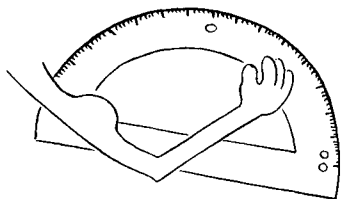


It takes days, weeks, and sometimes months, to get full motion . . . but this is done by constantly, hour by

hour, gaining a fraction of a degree at a time which adds up to a full range of motion.



Everyone on the surgical service from the technician on the ward to the Chief of Surgery on rounds will be constantly urging you to move those joints. . . .



Don't say. . . .
"I can't...IT HURTS ME..." They know that. If you do it

gradually, but constantly, it won't hurt very much and even if it does, it has to be done. The more you postpone it the harder it will be to do.

The test of a good result is whether you are in BETTER shape when you are discharged from the hospital than you were before you got hurt.

We want good results as much as you do and we'll help you all we can, but there are some things that only YOU can do, so

Keep 'em moving and we'll all be happy.

Text by
Lt. Col. Philip S. Foisie

Illustrations by
Sgt. William Pitney

CHAPTER XVI

Noncombat Lesions

General Considerations

If, at the outbreak of World War II, the official history of World War I had been made required reading for every newly inducted Army surgeon, in the senior as well as in the junior grades, and if the advice of World War I surgeons had been heeded, a great many elective operations, particularly on the feet and the knee joint, would not have been performed in World War II. Many of them were unnecessary; they were often meddling; and they usually failed to achieve their objective, which was to increase the number of combat soldiers.

Elective operations done in the United Kingdom prior to D-day included operations for hammertoes; bone grafts; operations on the spine, particularly for herniated intervertebral disks and spondylolisthesis; operations on the shoulder; and, most frequently, arthrotomy of the knee joint. Eventually, after a great deal of time and effort had been wasted, it was realized that most of these operations were, for all practical purposes, complete failures. It was the exception rather than the rule for a soldier to be able to do full combat duty after any elective procedure. Usually he could do no more than before he was operated on, and sometimes he could not do as much.

Some of this misplaced surgical zeal could be attributed to the paucity of surgical work in the early days of the European theater, but more of it could be explained by a lack of mature judgment. With the approach of D-day the problem practically solved itself. There was a general realization that the performance of elective orthopedic surgery is not the function of the medical corps of an expeditionary force and that in most instances the difficulties of the individual soldier are better resolved by reassignment than by attempted rehabilitation by means of surgery. Thereafter, with the exception of a few carefully selected officers, whose services were of special value in the theater, officers and enlisted men who absolutely required elective surgery were returned to the Zone of Interior. Few of them ever came back to the theater.

Elective Surgery

Shoulder

Chronic dislocations of the acromioclavicular joint were relatively frequent and always troublesome. At the 298th General Hospital, excision of the outer inch of the clavicle was found to be an excellent reconstructive procedure, particularly when it was compared with other operations designed for the same purpose. It was simple, the period of hospitalization was short, and the immediate results were good. On the other hand, the end results were

not known, and there was a good deal of hesitancy over performing a procedure that was irreparable until the results could be accurately assessed.

Spine

Herniation of the intervertebral disk is discussed in detail in the neurosurgical section of this history. In the early days of the European theater, there was a great deal of indiscriminate surgery for this condition. Later, the responsibility was shared jointly by the senior consultant in orthopedic surgery and the senior consultant in neurosurgery, one or the other of whom had to give his consent before operation could be performed. With a few notable exceptions, even this restricted policy failed to increase the number of combat soldiers. Eventually, the great majority of the officers and enlisted men who really required surgery appeared before disposition boards and were returned to the United States. Few of them ever came back to the theater.

Knee Joint

Arthrotomy for internal derangements of the knee joint was performed more often than any other elective procedure and probably accomplished more than any other, but at that the results fell far short of what might be expected from the same operation in civilian practice. One reason was the successive reduction in the theater holding period. When a long holding period was possible, some soldiers were salvaged for combat duty, though details as to the number are not available. Information is therefore lacking on what amounts to the acid test of the value of this procedure. When the holding period was reduced to 120 days, and later to 90 days, it became obviously impossible to rehabilitate a man after this operation, and, as had become the policy with other elective procedures, those who clearly needed it were returned to the Zone of Interior for surgery.

The more mature surgeons who undertook elective arthrotomy for internal derangements of the knee joint had the best immediate results, because of their careful selection of cases. They did not perform the operation often. Patients were selected for it only after careful evaluation of their status on the basis of a detailed history, a painstaking physical examination, and multiple excellent roentgenograms. One thing that the experienced surgeon always realized was that it was as necessary to evaluate the soldier's personality as to examine his knee. Good, stable soldiers seldom manifested prolonged postoperative disability and sometimes could return to full combat duty within 60 days after exploration of the knee, removal of the menisci, and similar procedures. These results, however, were exceptional, even in the hands of competent surgeons.

Disabilities of the Feet

Elective surgery in disabilities of the feet needs no extended discussion. Numerous operations were performed on these indications, and practically all of them were failures.

While the tendency was sometimes observed to diagnose static foot disturbances without sufficient objective evidence, there was no doubt of the seriousness of these disabilities and of the manpower losses which resulted from them. The experience of the 29th Infantry Division is illustrative.¹

The training marches undertaken by this division in the fall of 1942 resulted in complaints of pain and fatigue in the lower extremities so far exceeding expectancy that at the suggestion of the senior consultant in orthopedic surgery, Col. Rex L. Diveley, MC, a detailed investigation was undertaken. It was carried out by Capt. (later Lt. Col.) Marcus J. Stewart, MC, with the cooperation of the commanding officer, Maj. Gen. Leonard T. Gerow, MC, and the division surgeon, Lt. Col. (later Col.) William H. Triplett, MC.

The mean strength of the 29th Division when the survey was undertaken was 9,753 men and the marching strength 6,820 men. During a 2-week individual survey of all foot troops, 820 men (12 percent) presented themselves with complaints of pain and disability referable to the feet. The survey was not extended to the artillery battalions, which spent much of their time on the firing range and were not subjected to the same marching program as the remainder of the division. This program consisted of weekly or biweekly hikes, usually for 25 miles, with field pack and equipment, over hard-surfaced roads.

The troops in the 29th Division had been in the Army of the United States for approximately 2 years. A large number of them had previously been in the National Guard. They had been on active, large-scale maneuvers twice. Their training had included frequent long hikes on dirt roads and only a small percentage of man-days had been lost because of foot injuries until long hikes on hard-surfaced roads had been started.

Of the 820 men examined after they had complained of foot disabilities, 20 were found to have normal feet. In seven cases, the trouble could be traced to poorly fitted shoes. In the remaining cases, there was objective evidence for the complaints, chiefly as follows:

Congenital malformations of bony structures, 325 cases, including low anterior arches (123 cases), low longitudinal arches (67 cases), short first metatarsals (50 cases), and cavus foot (33 cases).

Developmental malformations of bony structures, 40 cases, including 11 instances of bunions.

Soft-tissue lesions, 199 cases, including 125 instances of tenosynovitis, in 87 of which the Achilles tendon was affected.

Acute injuries to soft tissues, 221 cases, including 17 sprains, 29 blisters, and 172 instances of foot strain from overtraining.

As the report pointed out, in a certain number of cases the deformities were so severe and of such long standing that the soldiers should never have been sent overseas. The error was open to two explanations: (1) Improper

¹ Report, Capt. Marcus J. Stewart to Lt. Col. Rex L. Diveley, 28 January 1943, subject: Report on a Study of the Foot Injuries in the 29th Division.

medical examinations, and (2) the desire to retain men who were of special value in operational clerical work or who had some other special ability. In all, 198 soldiers were reclassified because of foot disabilities. It was thought that the others, under a less exhausting training program and with proper foot care, might be expected to return to full duty and remain 100 percent efficient.

A change in the shoes worn was recommended in 16 cases, and corrections in the shoes were recommended in 187 cases, in 54 of which the corrections would be permanent. If these corrections were not made and if they were not supplemented by a program of foot training, it was expected that these 54 men would also have to be reclassified.

When the situation was again reviewed in March 1943,² it was found that in the Infantry, Engineers, and division special troops, 739 men had fallen out of line on test marches because of trouble with their feet, against 131 who had fallen out for all other causes. One hundred and fifty-one of the men who complained of their feet were recommended for reclassification, against 39 of the 131 who fell out of line for other causes. Captain Stewart noted in his March 1943 report that no change or alteration had been made in the foot training or marching program in line with the recommendations made in his January report, and that only 23 of the 187 shoe corrections recommended had been made.

Difficulties with improperly fitted shoes continued throughout the war. Shortly before D-day, a survey in replacement pools conducted by Maj. Irvine M. Flinn, Jr., MC, of the 801st Hospital Center revealed a large number of foot complaints. The men in these pools had been sent from the Zone of Interior to serve as combat replacements after the first wave had gone ashore on the invasion beaches. Most of them had been in the Army for only a short time. Many were in their late thirties or had done desk work all their lives. Little could be done for their difficulties except to suggest arch supports and better fitting shoes. The impression was that the majority of the troubles of which these men complained could be attributed to badly fitted shoes which sometimes, the report stated, seemed to have been "given away at random."

The situation revealed by this survey and the detailed statistics secured in the investigation conducted in the 29th Infantry Division in 1942 and 1943 indicate clearly why surgery for foot disabilities had so little success in the European theater and why operations to relieve these conditions promptly fell into disfavor.

² Report, Capt. Marcus J. Stewart to Lt. Col. R. L. Diveley, 22 March 1943, subject: Test Marches in 29th Division.

PART III

**SPECIAL TYPES OF BONE AND JOINT
INJURIES**

Marshall R. Urist, M. D., and Mather Cleveland, M. D.

CHAPTER XVII

Complete Dislocations of the Acromioclavicular Joint

*Marshall R. Urist, M. D.**

Up to the end of World War II, no single recorded series of complete dislocations of the acromioclavicular joint consisted of even a dozen cases. Orthopedic surgeons of wide experience in civilian practice seldom encountered more than 3 or 4 cases, if as many, in the course of their professional lives. The mass trauma of combat altered that situation. During the war, several times as many of these injuries were treated by single observers as would have been ordinarily observed in a lifetime of civilian practice. This chapter is based upon the author's personal observation of 41 instances of complete dislocation of the acromioclavicular joint while the 802d Hospital Center was stationed at Blanford, England, during 1944-45 and while the 97th General Hospital was stationed at Frankfurt, Germany, in 1945.

These 41 injuries (tables 7 through 10) were all war connected, though not all were battle incurred. A few were sustained on the football field and a few more in traffic accidents. The remainder were incurred in combat, chiefly during parachute jumps and in the course of hazardous engineering operations. All were of great violence, however they were incurred, as might be expected, because all the casualties were strong, active, young soldiers in the same age group.

Twenty-three of the forty-one injuries were acute and were recognized so promptly that most of the victims received first aid immediately or shortly after the injury. All of this group were evacuated from the combat zone as promptly as possible. Those who were transported by air arrived in fixed hospitals within a few hours after injury. Those transported by water or by rail arrived within 10 days.

In the other 18 cases, the injury was unrecognized or unreported, and therefore untreated, for periods of time ranging from a few weeks to 18 months after it had been sustained.

Eleven of the 41 soldiers, in addition to complete dislocations of the acromioclavicular joint, had associated fractures of various portions of the clavicle, the acromion process, and the coracoid process. One of these patients had 2 fractures. Some of them, as would be expected, were suffering from combat fatigue or other war-related psychosomatic conditions.

*Associate clinical professor of surgery, Division of Orthopedics, University of California, Los Angeles, Calif. Formerly major, MC, AUS.

TABLE 7.—Significant data in 18 complete dislocations of the acromioclavicular joint treated in author's splint¹

Case No.	Type of joint	Associated fractures	Position at 4 weeks	Ballottement at 4 weeks	Calcification in coraco-clavicular ligaments	Cosmetic results	Residual symptoms	Figure references
1	Overriding		Excellent	Positive	Present	Excellent		50
2	do		do	do	do	Good	Pain	
3	do		Good		Present	Excellent		
4	Overriding, nearly vertical	Acromion, chip	do		do	Fair		55
15	Nearly vertical	Clavicle, subchondral	Wide joint space	Positive	Present	Subluxation	Pain	52
16	Incongruent, vertical		do	do	do	Slight subluxation	do	
7	Overriding	Coracoid, avulsion	Excellent		Present	Perfect		54
8	do	Clavicle, avulsion	do		do	do		49
9	do	Clavicle, acromial end	do		Present	Excellent		46
10	Incongruent, vertical		do		do	do		
11	Overriding		do		Present	do		
12	do		Slightly wide joint space		Present	do		
13	do		do		do	do		
14	do		Excellent		do	do		
15	do		do		do	do		
2 16	Vertical	Clavicle, avulsion	Good		Present	Slight subluxation	Pain	51
2 17	do		do		do	do	Slight pain	45
2 18	Nearly vertical		do	Positive	do	Subluxation	do	

¹ See table 10 for details of later surgical management.

² Splint applied after 10 days of management in adhesive strappings.

TABLE 8.—Significant data in 11 complete, late, untreated dislocations of the acromioclavicular joint

Case No.	Type of joint	Primary treatment	Days of healing	Calcification in coracoclavicular ligaments	Osteoarthritis	Cosmetic results	Figure references
19	Overriding	Hunkin cast	56	Present	Present	Subluxation	56
20	Vertical	Watson-Jones adhesive splint	58	Present	do	do	
21	Congruent, vertical	do	35	Present	Present	do	
22	Overriding	Jones humeral splint	34	Present	do	Subluxation and Erb-Duchenne palsy	
23	Underriding	Stimson adhesive splint	395	do	do	Subluxation	57
24	Vertical	Velpeau adhesive splint	270	do	do	Dislocation	
25	Overriding	None	35	do	do	do	58
26	Vertical	Velpeau bandage	70	do	do	do	
27	Overriding	None	42	do	do	do	47
28	Incongruent, overriding	do	300	do	do	Subluxation	
29	do	do	330	do	Present	do	

372572°—56—14

TABLE 9.—Significant data in 5 complete, variously treated, recent dislocations of the acromioclavicular joint

Case No.	Type of joint	Primary treatment	Cosmetic result	Residual symptoms
30	Overriding, nearly vertical	Skeletal traction	Excellent	Pain.
31	Overriding	do	do	Slight pain.
32	do	Phemister transarticular wire	Slight subluxation	
33	do	Coracoclavicular screw	Slight deformity	
34	do	Thoracobrachial spica, 90-degree abduction.	Excellent	

¹ This patient also had a fissure fracture of the acromion process and an avulsion fracture of the coracoid process.

TABLE 10.—Significant data in 9 complete dislocations of the acromioclavicular joint eventually treated by excision of the distal end of the clavicle

Case No.	Type of joint	Associated fractures	Primary treatment	Interval before surgery	Operative findings		Cosmetic results	Figure references
					Coracoclavicular ligaments	Joint		
35	Overriding	Clavicle, subchondral	Stimson strapping	4 weeks	Stretched but intact	Fibrous adhesions	Poor	
36	do	do	Watson-Jones strapping	4 weeks	Trapezoid stretched and frayed	Interposed capsule and fibrous adhesions	do	
37	do		None	3 weeks	Intact	do	do	
38	Incongruent, overriding		do	12 months	do	Chronic synovitis or fibrous ankylosis	Dislocation	48
39	do		Adhesive brachioclavicular sling	11 months	Ossified	Extra-articular new bone	Subluxation	53
40	do	Clavicle, transverse of shaft	Arm sling	10 months	do	do	do	
41	do	Clavicle, subchondral	Velpeau bandage	5 months	Intact	Interposed fibrous connective tissue	do	
15	Vertical		Author's splint	10 weeks	do	Interposed capsule and fibrous adhesions	do	52
16	Incongruent, vertical		do	10 weeks	do	do	do	

1 See table 7 for details of primary treatment.

The material in this chapter is presented from three points of view:

1. The anatomicopathologic, which up to the end of World War II was incompletely understood, probably because no single observer had previously encountered a large enough series of cases to permit conclusions.

2. The therapeutic, which had not previously been clarified for the same reason. Up to the end of World War II, in spite of the small number of recorded cases, more than 35 conservative methods of treatment, and at least 28 surgical methods, had been proposed for the management of these injuries. During the course of treatment of these 41 injuries, what seemed to be an improved method of conservative treatment was developed.

3. The prognostic. Up to the end of World War II, very few end results of therapy by any methods had been recorded in the literature.

Anatomic Considerations

Before discussing the pathologic process in complete dislocations of the acromioclavicular joint, certain anatomic facts must be summarized. This joint is made up of two structures, the clavicle and the acromion process, which are maintained in relationship to each other by the acromioclavicular and coracoclavicular ligaments. The coracoclavicular ligaments form a syndesmosis, the term implying a synostosis of a special type in which the skeletal elements are bound together by a continuous band of elastic connective tissue. Whether the coracoclavicular syndesmosis represents a trend toward the development of a diarthrodial joint between the coracoid process and the inferior surface of the clavicle or is simply a metamorphosed joint is still not clear. In about 1 percent of random roentgenograms of the shoulder, the coracoclavicular joint is a well-developed diarthrosis. The acromioclavicular joint itself is a true diarthrosis; the articular surfaces of the acromion process and the outer end of the clavicle, which are separated by a joint cavity, are surrounded by a capsule which is reinforced by ligaments. The motion of the acromioclavicular joint is synchronous with the motion of the shoulder joint. There is, however, no motion of the coracoacromial syndesmosis (represented by the coracoacromial ligament), and it can be sacrificed without effect on the function of the shoulder. Its functional significance is, therefore, not apparent.

As part of this study, 100 unselected roentgenograms of the shoulder area were examined, to determine possible variations in the form of the acromioclavicular joint and to confirm or disprove the impression that they are frequent. These films were all taken by the standard Army technique, and the patients on whom they were made had no symptoms referable to the shoulder. The only selective consideration was that such variations as existed be present bilaterally. The clinical impression that there are numerous variations in this joint was promptly confirmed. Only infrequently, in fact, was the roentgenogram entirely in accord with the classical anatomic description. The explanation probably is that the articulation is made up of parts which are formed at

different stages of the morphogenesis of the typical diarthrosis and that its normal evolutionary development is frequently interrupted.

In these particular roentgenograms, the following variations from the classic norm were observed: The articular surfaces were occasionally separated by a meniscus attached to the superior acromioclavicular ligament. Sometimes the meniscus took the form of a blade of fibrocartilage which extended halfway into the joint. Sometimes it formed a complete disk which divided the joint into two parts. In one case, no diarthrosis was present; the joint was represented merely by a pad of fibrous tissue attached to the outer end of the clavicle, with no evidence of an articular cavity. This is not an uncommon observation. The joint surfaces were often incongruent. The outline of the articular surface of the acromion process sometimes corresponded to the outline of the clavicle, but often it did not. Sometimes no part of the clavicle opposed the end of the acromion; then the patient, for all practical purposes, had a congenital subluxation or relaxation of the acromioclavicular joint. The clinical prominence of the acromioclavicular joint was usually determined by the degree of overriding of the acromial end of the clavicle. Sometimes the joint surfaces lay in a vertical plane (fig. 45, case 17). Sometimes the acromion partly overlay the clavicle (fig. 46, case 9). In the majority of roentgenograms, some overriding of the clavicle on the acromion was observed (fig. 47, case 27).

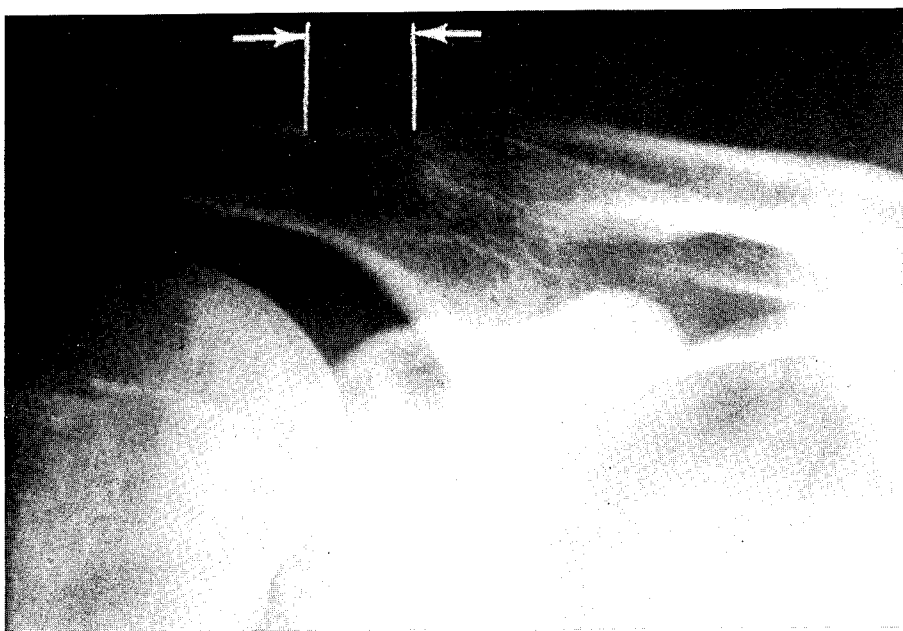


FIGURE 45 (case 17).—Roentgenogram of severe dislocation of right acromioclavicular joint sustained in motorcycle accident. Joint is of vertical type. Interposition of capsular ligament was suspected in this case, because joint space was greatly increased on affected side after reduction of dislocation.

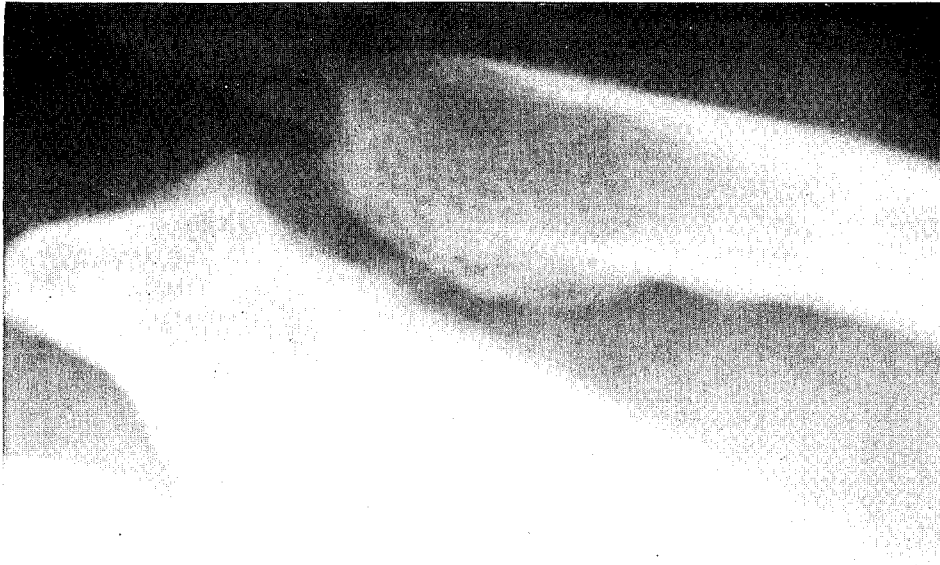


FIGURE 46 (case 9).—Roentgenogram showing dislocation of right acromioclavicular process, with minute fracture of distal end of inferior margin of clavicle, 7 weeks after injury was sustained in tank striking tree in combat. Note calcification of inferior capsular ligament. At this time, the patient complained of pain and had limitation of abduction of arm beyond 90 degrees. The intact joint is partly overriding at the inferior margin because the articular surface of the clavicle is concave and the acromial surface is convex.

The shape of the distal end of the clavicle also varied, being bulbous, square, fusiform, flattened, or cylindrical.

When the material was analyzed statistically, it was found that the articular surface of the clavicle overrode the articular surface of the acromion process in 29 of the 100 roentgenograms. The articular surfaces of the acromion and clavicle were nearly vertical and lay in the same plane in 27 cases. The inferior margin of the articular surface of the clavicle overrode the superior margin of the acromion in 3 cases. In 21 cases, the articular surfaces were incongruent. In 9 the clavicle overlay the acromion. In 6 the inferior margin of the clavicle underrode the superior margin of the acromion. In 6 cases, finally, the articular surfaces were not in contact at any point.

Mechanism of Injury and Nature of Lesion

It would be a far simpler matter to explain the mechanism of injury in these 41 dislocations of the acromioclavicular joint if the soldiers had been able to supply more information. They knew the general circumstances of




FIGURE 47 (case 27).—Roentgenogram showing dislocation of left acromioclavicular joint 4 months after injury had been sustained in fall from moving tank. Note calcification of capsular ligament (indicated by arrow) which was associated with mild symptoms of traumatic arthritis. This patient presented an extreme example of the overriding type of joint with nearly horizontal articular surfaces.

injury but most of them could provide no precise details. In two cases, ecchymoses and abrasions indicated the point of contact of external force. One patient (case 40) had a discoloration over a fracture of the clavicle, and the other (case 34) had been struck over the acromion process by a falling steel beam. In most cases, reconstruction of the injury in correlation with the clinical and roentgenologic findings suggested that the men had been struck (or had fallen) on the dorsum or the anterior aspect of the shoulder and that the scapula had thus been forced downward or backward.

There were no illustrations in this series of two mechanisms of injury which have been reported in the literature. In one, the scapula is drawn forcibly inferiorly and anteriorly by a sudden change in the position of a heavy burden that is being carried; in the other, the coracoid process comes into contact with the clavicle, and the joint is literally pried apart by force transmitted through the arm.

Illustrations in current textbooks were of little help in dealing with complete dislocations of the acromioclavicular joint, since they were (and continue to be) based on the concept that this injury cannot occur without tearing of the conoid and trapezoid ligaments. Neither past experience, as derived from the literature, nor the evidence of these 41 cases supports that point of view. When the distance between the clavicle and the coracoid process is greatly increased, as it may be in this type of injury, in comparison with the

distance between these structures in the uninjured shoulder, the coracoclavicular ligaments are correspondingly stretched and may be sprained, but it does not follow that they must be torn. In some cases in this series, in fact, in which force was transmitted through the arm, it was entirely conceivable that the joint capsule took the full force of the blow or fall and that the ligaments suffered no damage at all.

In unreduced dislocations of the acromioclavicular joint, the deformity was maintained by three factors, (1) gravity, (2) the pull of the trapezius on the distal end of the clavicle, and (3) the absence of counterpull by the aponeurosis of the anterior portion of the deltoid. When the arm on the affected side was weighted, the scapula, and with it the acromion process, was drawn downward and forward, so that the gap in the joint was increased both anteroposteriorly and superoinferiorly. In several doubtful cases in this series, this maneuver was used to accentuate the suspected lesions in the roentgenograms.

Pathologic Process

No fresh material was available for examination, since United States Army Medical Department policy was to treat acromioclavicular dislocations conservatively and not to resort to surgery until the lapse of a sufficient time after injury to permit healing or to establish the existence of a residual disability. It was possible, however, to study the process of healing after complete dislocation in 9 cases in which resection of the distal end of the clavicle was necessary at intervals varying from 3 weeks to 1 year after injury.

In each of these nine specimens the coracoclavicular ligaments, while stretched and elongated, had healed in complete continuity. The texture of the ligaments ranged from cicatricial induration to bony hardness. Elongation and scarification were proportional to the distance between the outer end of the clavicle and the coracoid process, but bony tissue was not always identified. The joint capsule, as the result of the healing process, showed an increase of thickness in every specimen, sometimes up to 4 mm.

Late changes were less uniform. In five cases, the articular surfaces were obliterated and replaced by fibrous connective tissue. In two of these cases, interposed flakes of cartilage, fibrocartilage, and necrotic hyalinized material were regarded as remnants of capsular ligament and meniscus, presumably separated at injury. In five cases, osteoarthritic changes, such as bony eburnation and marginal spurs, were observed. In two cases, there was evidence, which had not been present in the roentgenograms, of subchondral compression fractures of the clavicles and acromion processes. In one case (fig. 48, case 39), loose osteocartilaginous bodies were present.

The changes observed in these late specimens were in accord with those observed by Gurd¹ in fresh cases. In 1 of his cases, complete dislocation of the

¹ Gurd, F. B.: The Treatment of Complete Dislocation of the Outer End of the Clavicle. A Hitherto Undescribed Operation. *Ann. Surg.* 113: 1094-1098, June 1941.

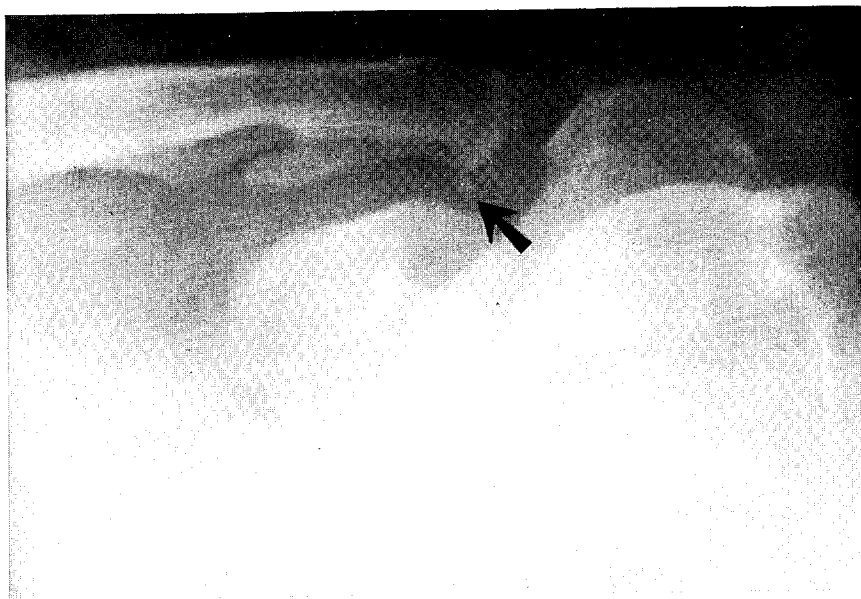


FIGURE 48 (case 39).—Roentgenogram showing healed dislocation of acromioclavicular joint 10 months after patient was kicked squarely on point of shoulder in football game. Note loose osteocartilaginous bodies in joint (indicated by arrow) and ossification of insertions of trapezoid ligament. The patient was subjected to surgery because of annoying crepitations, with pain, while doing heavy work, and because he had 30 degrees of limitation of abduction.

clavicle occurred without complete rupture of the coracoclavicular ligaments. In other cases, stretched or ruptured ligaments were found at open operation for repair of conoid and trapezoid ligaments with fascia lata.

Experimental observations.—For further elucidation of the mechanism of injury in complete dislocations of the acromioclavicular joint, a number of observations were made on cadavers:

1. The coracoclavicular ligaments were transected through a stab incision, after which the acromial end of the clavicle was grasped with bone forceps and tested for motion. The motion produced did not differ perceptibly from the motion possible on the opposite, intact side, nor did subluxation occur on the transected side when strong traction was applied to the arm.

2. The superior acromioclavicular ligament and the entire joint capsule were transected through an incision overlying the joint. It was then possible to produce an incomplete dislocation of approximately 50 percent. The incision was next carried around the outer end of the clavicle in U-shaped fashion, and the attachments of the deltoid and trapezius muscles to the clavicle were divided. The end of the clavicle was then drawn upward and posteriorly. This made it possible to accomplish complete disarticulation. When, however, the end of the clavicle was pulled straight upward, only incomplete disarticulation could be produced. When the coracoclavicular ligaments on the same

side were cut, as previously described, the entire outer end of the clavicle could be disarticulated farther upward than when only the attachments of the deltoid and trapezius muscles were divided.

3. The trapezoid ligament, the deltoid and trapezius attachments to the clavicle, and the superior acromioclavicular ligaments were all dissected and divided. It was then possible to move the clavicle posteriorly or superiorly and produce complete dislocation.

4. The experiment just described was repeated, except that the conoid ligament was sectioned instead of the trapezoid. The same results were accomplished as in the previous experiment, except that the acromial end of the clavicle could be dislocated farther upward.

5. The third and fourth experiments were repeated, except that the coracoacromial ligament was sectioned, first alone and then in combination with each of the other ligaments. There was no perceptible alteration in the stability of the acromioclavicular joint.

Similar observations had been reported in the literature before these were undertaken, and the same conclusions had been drawn from them, with one exception: The observations made in World War II were thought to emphasize the predominant role played in complete dislocation of the acromioclavicular joint by the joint capsule and the attachments of the deltoid and trapezius muscles. When these structures were severed, to simulate the tearing or stretching which they undergo in dislocation of the joint, the outer end of the clavicle could be completely dislocated without injury to the conoid or trapezoid ligaments. Greater displacement of the clavicle was possible when the conoid and trapezoid ligaments were sectioned, but the alteration was quantitative not qualitative. Section of the conoid or the trapezoid ligament alone had no perceptible effect, as might have been expected, since there is no separate excursion of the bones united by these structures. In the interpretation of these results, however, it was necessary to bear in mind Cadenat's² warning that in the living subject the relationships of parts in the functioning joint are probably altered by the tone and action of surrounding muscles and that the elasticity of individual ligaments may vary, depending upon the necessity for synchronizing the motions of the clavicle with those of surrounding parts.

Both the pathologic and the experimental observations in this series of dislocations suggested that the clavicle can become completely dislocated without rupture of the coracoclavicular ligaments. It was also apparent that the trapezoid ligament is occasionally stretched in acromioclavicular dislocations and that still more infrequently it is grossly ruptured. Microscopically, it had to be assumed that individual fibers of both the conoid and the trapezoid ligaments are torn during injury, but the observations made in this study indicated that the capacity of these ligaments for both healing and repair is excellent and can be relied upon for reconstitution of the joint relationships.

² Cadenat, F. M.: The Treatment of Dislocations and Fractures of the Outer End of the Clavicle. *Internat. Clin.*, Series 27, 1: 145-169, 1917.

Diagnosis

Diagnosis in this series of cases was made on the history of the injury, the clinical evaluation of the symptoms, the physical findings supplemented by certain objective tests, and the roentgenologic findings.

In the acute case, there was considerable pain. In the untreated or recurrent case, after joint effusion and periarticular swelling and tenderness had disappeared, which was usually by the end of the third week, there was little pain in a complete dislocation with overriding if there was no contact between the clavicle and the acromion process. Unless they were called upon to do hard work, most soldiers with nonacute injuries tended to make light of their symptoms.

In some cases, residual subluxation following the conservative treatment of complete acromioclavicular dislocations gave rise to pain, annoying crepitation, and sometimes limitation of joint motion. In such cases, there was an unsightly protrusion of bone on the shoulder. Some soldiers, like men in civil life, were willing to disregard the deformity if the symptoms were not severe. In other cases, the complaints were disproportionately greater than the clinical and roentgenologic evidence indicated that they should be.

In these circumstances, a number of simple tests proved useful. When they were positive, it was assumed that there was a physical basis for the complaints.

1. When the man leaned against the wall, so that the inferior angle of the scapula was firmly and sharply pressed into the posterior aspect of the thorax, pain was felt in the acromioclavicular joint.

2. When the man elevated his arm and pain was experienced on the affected side, it was assumed that synovitis, fibrous ankylosis, or arthritis of the injured joint was present. Full elevation of the arm was sometimes impossible.

3. When the man shrugged his shoulder, rotated the arm internally, or carried a weight, palpable crepitations or subjective grating sensations were accentuated. A 35-pound bucket of sand in each hand was used routinely to amplify the deformity for roentgenologic purposes.

4. Crossing the elbows on the chest in the position of adduction might be impossible because of pain in the joint or ankylosis.

Management

As in all injuries of this kind, the purpose of treatment in dislocations of the acromioclavicular joint was twofold, to secure anatomic reposition and to relieve symptoms. Unfortunately, although the objectives are obviously interrelated, the accomplishment of one objective did not necessarily result in the accomplishment of the other. After perfect anatomic restoration of the joint, symptoms sometimes persisted in these cases, as in many other reported cases, because there was residual damage to the articular surface and joint capsule. In other instances, there were no residual symptoms, but the anatomic result was poor.

Recurrence of the dislocation furnished the same problems that it does in civilian practice. In a number of instances, although clinically and roentgenologically the bones were in perfect position after immobilization for the accepted length of time, the dislocation recurred as soon as the splint was removed, showing that healing had not yet been sufficient to reestablish the continuity of the periarticular ligaments. Subluxation recurred in 5 of the 18 cases treated conservatively in this series (table 7). According to the literature, residual subluxation or some degree of disability occurs in 10 to 20 percent of all cases managed by this method.

Conservative Management

The necessity for standardization of treatment underlay all Army policies, including the policy that complete dislocations of the acromioclavicular joint should be treated conservatively for a certain period of time before it was concluded that this method would not be effective. Some of the data in this series suggest that there may be ways of determining in advance which cases will, and which will not, be responsive to conservative measures. It was found, for instance, that men who had overriding clavicles frequently were symptomless after conservative treatment (table 7), while those with vertical or partially overriding joints presented complications (table 9). Two patients with this type of joint (case 5, table 7 and case 41, table 10) had subchondral compression fractures.

Although conservative treatment was necessarily used in fresh cases because of Army policies, better results might have been obtained if more flexibility had been permitted. It would probably have been wiser to resort to surgery at once in untreated cases and neglected cases.³ It would also have been wiser to resort to it without further delay, if improvement was not evident at the end of 3 or 4 weeks of properly applied conservative measures. Finally, complete dislocation of the outer end of the clavicle did not respond well to conservative methods, and some degree of deformity was inevitable if surgery was not done. A correct evaluation of the patient was, of course, an essential part of the decision to undertake operative measures.

Conservative management included various techniques of manipulation and reduction, followed by various methods of immobilization.

Manipulation and reduction.—The following methods of manipulation were employed in this series to correct the deformity and reduce the dislocation before the application of splints:

1. Pressure was exerted with the thumb over an appropriately placed small felt pad, in order to depress the prominent distal end of the clavicle.
2. The scapula and acromion process were elevated by elevation of the flexed elbow.

³ This argument is necessarily theoretical. As long as combat conditions prevailed in the European Theater of Operations, no elective surgical procedure was permitted unless the soldier could be returned to full field duty after it within 120 days. (Editor's note.)

3. These two methods were used in combination in most cases to obtain the desired position for immobilization in a brachioclavicular splint. The patient's role in both was passive.

4. The patient, lying supine, threw his shoulders back and abducted his arm 90 degrees or more, or hyperextended his head, to relax the pull of the trapezius on the outer end of the clavicle.

5. The patient, standing erect, either threw his shoulders upward and backward or abducted the injured shoulder 90 degrees or more. This maneuver, as well as the maneuver described under heading 4, could be carried out by the surgeon rather than performed actively by the patient, if that was more convenient.

Reduction of the dislocated joint was, as a rule, easier than maintenance of the optimum position for the necessary 6 weeks. In the occasional case, however, there were several obstacles to successful reduction. Sometimes the clavicle slid into position and rotated on its long axis (case 5, table 7). Sometimes it lay posterior to the acromion process, even when held down at the correct level by manual pressure (case 4, table 7). As has already been intimated, it was found, when some of these patients came to surgery for excision of the distal end of the clavicle, that the source of these difficulties was interposition of meniscus, frayed ends of capsular ligament, and flakes of articular cartilage between the joint surfaces.

6. If the acromioclavicular joint was ruptured as well as dislocated, the deformity could be overcorrected by pushing the clavicle down below the level of the acromion process. In the two cases in this series (fig. 49, case 8; cases 8 and 18, table 7) in which immobilization was carried out in this position, both cosmetic and functional results were excellent.

Immobilization.—Various types of splints and other techniques of immobilization were used to maintain the extremity in position until healing oc-




FIGURE 49 (case 8).—Roentgenogram [retouched] of left acromioclavicular dislocation sustained in motorcycle accident, after reduction and overcorrection in author's splint. Arrows indicate points of main pressure of shoulder strap on clavicle. The clavicle has been depressed below the level of the acromion process.

curred, which was theoretically at the end of 6 weeks, or until it was evident that conservative management would not be successful.

One of the eleven patients seen late and not treated (case 26, table 8) had been put up in a Velpeau bandage, which had had no effect on the dislocation. Otherwise, slings and bandages were not used in this series except immediately after injury, for first aid. Some of the older surgeons devised complicated bandages to be applied by complicated techniques, but modern orthopedic surgeons had had little experience with these methods. They give very uneven results and have the additional disadvantage that if the bandages and slings are to be effective for any length of time, they must be painfully tight.

Four of the eleven patients seen late and not treated had been put up in various types of adhesive splints by the surgeons who first treated them, but in no instance had the result been satisfactory (cases 20, 21, 23, and 24, table 8). Otherwise, adhesive dressings and strappings were not used in this series for definitive treatment. Even the use of protective felt boards, coaptation splints, elastoplast, and other modern elastic materials does not eliminate the fundamental objection to this method, namely, that perspiration and skin irritation make the patient extremely uncomfortable and that removal and reapplication of the dressing, which is necessary at intervals if position is to be maintained, are unpleasant procedures for physician as well as for patient.

Suspension of the extremity in 90 degrees or more of abduction, by means of the Balkan frame or some similar device, is a useful method in the management of incomplete dislocations in bedridden patients but of rather doubtful value in complete dislocations. It was not indicated in any case in this series. Harnesses and braces were also avoided. The patient must be under constant supervision when they are used; they require a considerable degree of cooperation from him, which is not always forthcoming, and better results can be secured by less complicated methods.

Plaster immobilization.—Nineteen of the patients in this series who were seen early or relatively early (within 10 days) were treated conservatively, with immobilization in plaster splints for approximately 6 weeks. Another patient (case 19, table 8) who was seen late, had also been treated by plaster immobilization, in a sort of hanging (Hunkin) cast, which had left him with a subluxation. This cast is a loose, plaster torso cast, suspended from a webbed shoulder strap. It has the serious disadvantage that the effort to maintain reduction is relaxed when the patient is recumbent. The Gibben splint has the same objection. The Gibben, a hanging arm cast suspended from an elastic band over the shoulder, functions on the same principle as the Hunkin splint—that the weight of the plaster will depress the outer edge of the clavicle.

The thoracobrachial spica, with 90-degree abduction, recommended by Key and Conwell,⁴ was used in one fresh case (case 34, table 9) with excellent results.

⁴ Key, John A., and Conwell, H. Earle: *The Management of Fractures, Dislocations, and Sprains*, 3d ed. St. Louis: The C. V. Mosby Co., 1942.

Case 34.—An engineer, working with a crane, was struck on the left shoulder by a falling steel beam. Roentgenologic examination an hour later showed a linear fracture of the acromion process without displacement, avulsion of the coracoid process, and acromioclavicular separation. The plaster abduction splint of Key and Conwell was considered more practical in this case, because of the swelling and ecchymosis over the dorsum of the shoulder, than a splint which required the pressure of a shoulder strap to be effective. The dorsal section of the cast was removed at the end of 2 weeks, and massage and biceps-setting exercises were ordered. The remainder of the cast was removed 4 weeks later, and limited exercises were undertaken. At 8 weeks, use of the shoulder wheel was begun. Roentgenologic examination at this time showed union of the coracoid process and the scapula, with complete healing of the fracture of the acromion process. When the man returned to duty 12 weeks after the accident, he had a slight subluxation but was free of symptoms. When the cast was first removed his shoulder had been painful and stiff.

The Key-Conwell cast only partially reduces the acromioclavicular separation, because the distal end of the clavicle is displaced slightly posteriorly, and the distance between the clavicle and the acromion process is undesirably increased. It should therefore be employed only on special indications, such as existed in this case. This case is an excellent illustration of the justification for the general policy in military practice that a sufficient period of conservative therapy be tried before surgery is resorted to. The dislocation was associated with fractures of the coracoid and acromion processes, and, as in all such cases, management was a compromise, in an endeavor to secure comfortable immobilization.

A number of available casts were considered and deliberately rejected for these fresh cases. Legg, among others, devised a brachioclavicular cast which is a Velpeau bandage with an elastic shoulder strap added to depress the clavicle. The objection to the use of such casts in combination with shoulder straps is that the pressure of the strap in brachioclavicular slings, when the scapula is not elevated, is usually too much for skin tolerance over a 6-week period. This is particularly true if techniques which utilize suspension and gravity are employed.

The torso cast recommended by Dillehunt⁵ elevates the acromion process until it is alined with the distal end of the clavicle, by fixation and elevation of the arm at the side of the chest (fig. 50B). Reduction and immobilization are accomplished with the expenditure of very little force, because the pull of the trapezius is counteracted, while at the same time the weight of the arm is canceled out.

The author's splint (fig. 50) was devised to incorporate the most desirable features of the splints devised by Dillehunt and Howard. As in Dillehunt's splint, elevation of the scapula is maintained by anchoring the body plaster to the iliac crests, to provide the necessary counterbalance. Neither of these splints, however, provides for overcorrection of the deformity by depression of the clavicle below the level of the acromion process, which is necessary for optimum cosmetic and functional results. In the author's modification, a broad elastic shoulder strap, made of a strip of salvaged inner tube, provides

⁵ Dillehunt, R. B.: Luxation of the Acromioclavicular Joint. *S. Clin. North America* 7: 1307-1313, October 1927.

the necessary clavicular depression, while at the same time excessive cutaneous pressure is avoided. The main objection to this splint seems to be that it restricts movement of the arm and chest.

This splint was used in 18 cases in this series (table 7), in 15 of which it was applied promptly after injury.

Results.—The 15 patients just referred to were evacuated promptly from forward areas in first-aid bandages or temporary adhesive splints. They wore the author's splint for 6 weeks and had had 2 weeks of physical therapy before the first record of results was made, though in each instance, after the splint had been worn for 3 to 4 weeks, the shoulder strap was turned medially on itself, and the mobility of the acromial end of the clavicle was determined.

In no instance did the splint cause any disability in the elbow. Twelve patients were returned to duty completely cured after a period of physical therapy and rehabilitation (table 7). Another (case 4) was left with a subluxation but without significant pain or limitation of motion. He was also returned to unrestricted military duty, and followup showed that activity had not increased the deformity.

The two remaining patients (cases 5 and 6) presented subluxations associated with pain, swelling, tenderness, and deformity after several days of physical therapy. When they were operated on later, the capsular ligaments were found interposed between the joint structures, and interference with satisfactory reduction of the dislocations was evident, although it had not been observed in the anteroposterior roentgenograms. This finding, as will be pointed out later, could have been predicted.

Twelve successes in fifteen early cases handled by the author's splint are about in accord with the results of other observers with newer methods of conservative treatment. It should be emphasized, however, that this report concerns only complete dislocations. Many successes reported with strapping and similar obviously inadequate methods of treatment concern only sprains, subluxations, or incomplete dislocations of minor degree, such as the football type of injury sustained in blocking.

The three other patients treated by the author's splint (cases 16, 17, and 18, table 7) were seen 10 days after injury, when they were transferred to it from the adhesive strappings originally applied for first aid. At the end of 6 weeks of immobilization, all presented subluxation of some degree, but associated symptoms were neither severe nor disabling. One of these patients (case 16) who also had an avulsion fracture of the clavicle, had more pain than the other two patients, whose dislocations were uncomplicated, but all three were perfectly satisfied to return to full duty without further treatment.

Two tests used in the course of conservative therapy seemed useful in determining the results being accomplished:

In some patients (fig. 51, case 16; fig. 45, case 17) roentgenograms taken 1 week after reduction showed measurable widening or separation of the joint space. These were cases in which the outer end of the clavicle was characteristically above and posterior to the acromion process and in which it had ap-

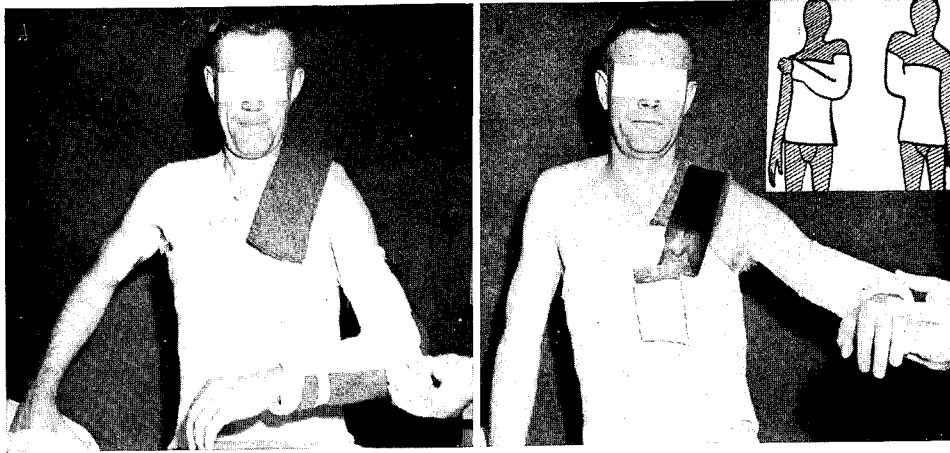

FIGURE 50 (case 1).—Application of author's splint. A. Separate application of padded arm and body plasters. B. Elastic shoulder strap, made of strip of salvaged inner tube, is stretched tightly over clavicle. The tube ends are doubled back on themselves between layers of plaster bandage, to maintain constant pressure.

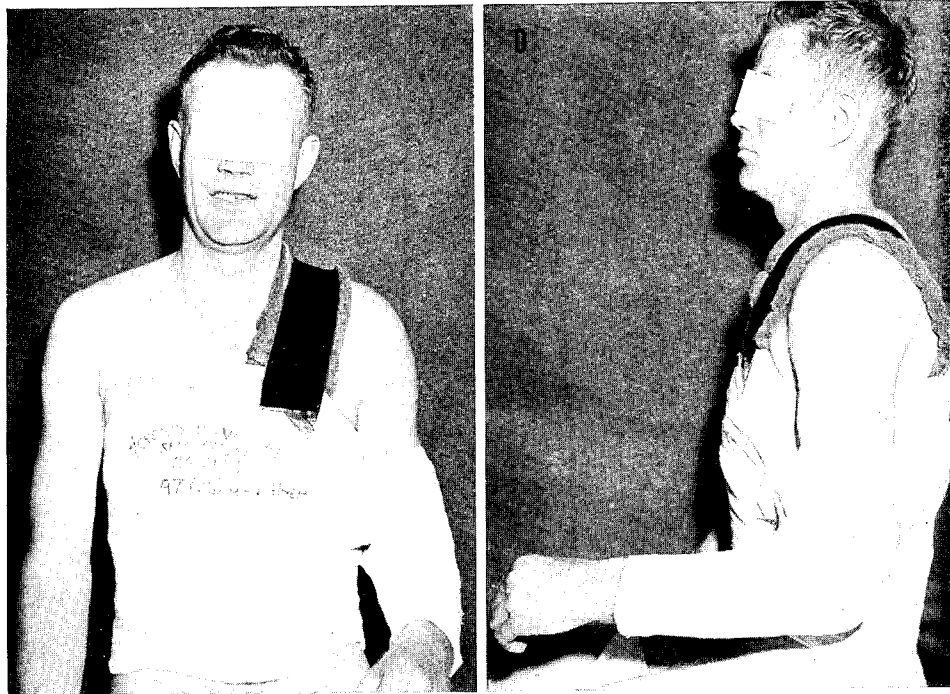

FIGURE 50.—Continued. C. Elastic shoulder strap in place. Scapula elevated, as in method of Dillehunt. Arm section of plaster fixed to body section and elevated so that shoulder on affected side is 1 to 2 inches higher than shoulder on intact side. D. Continuous pressure maintained by wide area of shoulder strap. Support of body plaster on iliac crests furnishes countertraction and aids in maintaining elevation of arm on body.

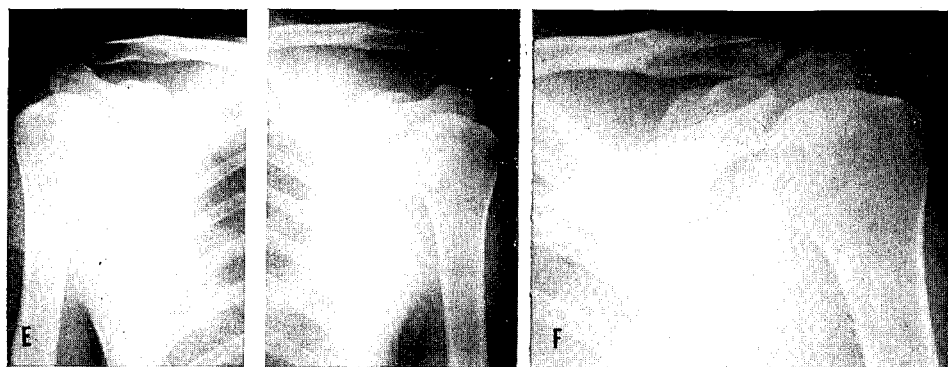


FIGURE 50.—Continued. E. Roentgenogram of patient shown in figure 50A through 50D, showing dislocated left clavicle before treatment. Note overriding type of joint. F. Roentgenogram showing reduction of dislocation in Urist splint. Note slight over-correction of dislocation, as shown by comparison of distances between coracoid process and clavicle in reduced joint in this roentgenogram and intact right joint shown in figure 50E.

parently been possible to reduce the dislocation and obliterate the deformity. In these cases, when both clavicles were outlined with the fingertips, it could easily be demonstrated that, while the upward displacement of the dislocated clavicle had been corrected, there was still slight posterior displacement. These were both delayed cases, in which further manipulations would not have been effective. In earlier cases it should be possible to correct the position.

In five cases in this series, ballottement or free floating of the distal end of the clavicle was observed after 3 weeks or more of conservative treatment. It was particularly striking in two cases (cases 4 and 5), both of which were instances of posterior displacement. In each case, ballottement was evident when, at the end of 3 weeks, the shoulder strap of the splint was turned back and the distal end of the clavicle was pushed inferiorly and anteriorly, in an attempt at adjustment. When the splints were removed at the end of 6 weeks, the dislocation in each case was only partially corrected, and subluxation was evident during the 3 weeks of rehabilitation. In both cases, pain and a sense of instability later required excision of the distal end of the clavicle. In both cases, as already noted, the interposition between the joint surfaces of fibrous connective tissue, capsular ligament, and torn meniscus, clearly prevented accurate reposition and presumably accounted for the ballottement observed earlier. In three other cases, there were similar but less conspicuous findings at operation.

At the end of 3 weeks, uncomplicated or well-reduced dislocations of the acromioclavicular joint ordinarily become stable, because the capsular ligament has healed and the attachments of the deltoid muscle are repaired. This is not a large enough number of cases to warrant conclusions, but it may well be that the finding of a free-floating clavicular end at this time indicates the unlikelihood of success with conservative measures and the necessity for an early resort to surgery.

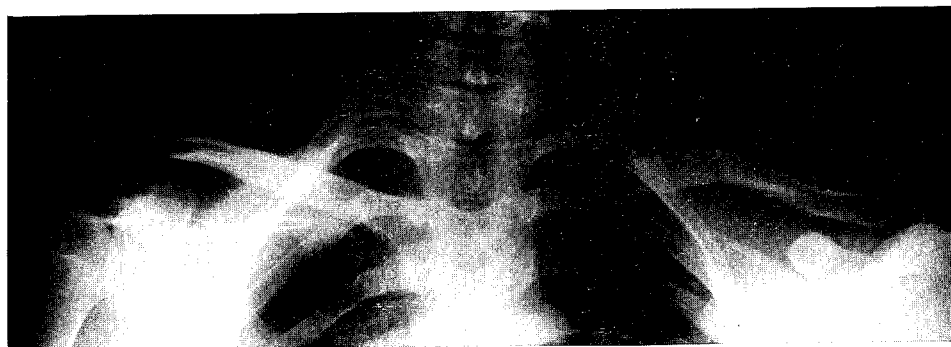


FIGURE 51 (case 16).—Roentgenogram showing severe dislocation of right acromioclavicular joint after reduction in author's splint. The injury was sustained in a fall over a fence, on a dark battlefield. A false impression of overcorrection of deformity may be obtained when, as in this case, the clavicle is displaced posterior to the acromion but is actually farther from the coracoid process than on the opposite side.

The following case history is another illustration of the good results which can follow properly applied conservative treatment:

Case 1.—A soldier who was sitting in the front seat of a jeep was thrown out after a head-on collision with another vehicle, striking his left shoulder on the pavement and sustaining a complete dislocation of the clavicle (fig. 50E). A Velpeau bandage applied in a local dispensary did not maintain satisfactory reduction. Twenty-four hours later, the dislocation was reduced and the shoulder put up in the author's splint (fig. 50A, B, C, and D), in which it was maintained for 6 weeks. Physical therapy was carried out for 10 days, and 4 days later the man was discharged to full duty, with no restrictions on calisthenics or sports. Roentgenographic examination at this time (fig. 50F) showed the structures in correct anatomic position. There was slight induration on palpation of the joint, with slight crepitus, but the patient had no symptoms and had full range of motion.

Surgical Measures

The end results in arthrotomy, internal fixation, and other surgical measures used in acromioclavicular dislocations depend, just as the end results of nonsurgical measures, upon healing of the ligaments and periarticular structures. In neglected and old lacerations, good results are unlikely. The theoretic advantages of management by arthrotomy and suture under direct vision, but the literature does not suggest that the results are any better cosmetically, symptomatically, or functionally than are achieved by improved conservative measures.

Arthrodesis was a fairly popular method of management in the days when suture operations on the joint frequently resulted in ankylosis. It was the practice in these cases to resect the articular cartilages later, to insure bony fusion, correct deformity, and relieve pain. Limitation of motion of the shoulder, particularly abduction, was explained by experimental observations on the cadaver, which showed that the articulations of the clavicle, scapula, and humerus must function independently for elevation of the arm. Arthrodesis

continues to be mentioned by occasional observers as a solution of the problem of complete dislocation, but it is not an acceptable procedure in modern orthopedic surgery, and it was not performed, or even contemplated, in any case in this series.

Syndesmoplasty and ligamentopexy were also not employed in this series. No conclusive data on the results of syndesmoplasty had been reported up to World War II, and there are theoretic objections to the operation, the chief being that repair of the conoid and trapezoid ligaments is probably impossible because they are still inaccessible after the widest possible exposure. Suture has been accomplished by indirect methods, such as binding the clavicle to the coracoid process with heavy silk or wire, or repairing the periarticular ligaments by transfer of fascia or tendons at the site of the lesion.

There has never been agreement about the value of ligamentopexy. Reconstruction of the conoid and trapezoid ligaments with an isograft of fascia lata is theoretically valuable in old dislocations with extreme deformity, but if the grafts stretch, the deformity will recur and will be increased by postoperative stiffness of the shoulder. Furthermore, the fascia or old ligaments frequently calcify, and the resulting synostosis limits abduction.

One patient in this series (case 32, table 9) was treated by open reduction and internal fixation with Phemister's transarticular wire. He was left with slight luxation but no residual symptoms.

Two patients were treated by skeletal traction (cases 30 and 31, table 9). They had excellent cosmetic results but some residual pain. This is an excellent method for patients who have sustained other injuries which require confinement to bed, since it assures maintenance of the anatomic position continuously for the desired length of time. It is not, however, suitable for either industrial or military practice; it requires great skill and judgment, and it carries the risk of infection and of injury to nerves and blood vessels. Finally, it can be used only in fresh injuries, and even in them it is associated with all the disadvantages inherent in the use of external skeletal fixation.

When skeletal traction is correctly employed, traction is obtained by the use of small threaded pins; two are inserted into the outer third of the clavicle and another is inserted into the coracoid process, all three being tied into a triangle with rubber bands. These bands serve, in effect, as a second, external set of ligaments, and reduction is obtained by continuous skeletal traction. The patient, to relieve the tension, involuntarily elevates the shoulder on the affected side and thus actively aids in maintaining the reduction.

One case (case 33, table 9) was managed primarily by a coracoclavicular screw. The patient was left with a slight deformity but no residual symptoms. Because of bone resorption, however, the screw became loose 4 weeks after it was inserted. It had to be removed and another splint applied. This method was introduced by Boardman M. Bosworth⁶ in 1941 and, therefore, had not

⁶ Bosworth, B. M.: Acromioclavicular Separation. New Method of Repair. *Surg., Gynec. & Obst.* 73: 866-871, December 1941.

had a wide trial when the United States entered World War II. Watson-Jones,⁷ who recommends the removal of the screw in most cases after 4 to 6 weeks, considers the results better than those accomplished by conservative methods. Since he advanced this opinion in 1943, he was presumably referring to the use of adhesive strappings, not to the newer conservative techniques.

The coracoclavicular screw is applicable only to fresh injuries. It seems highly doubtful that patients who do not respond to conservative therapy, because of the interposition of soft parts between the joint structures, will be benefited by it. Theoretically, it is open to all the objections applicable to operative methods which do not include arthrotomy. Since the clavicle rotates on its long axis with abduction, it is hard to see how it could move normally when this method of fixation has been employed. The effect on the shoulder as a whole, in fact, seems the same as the effect of fusion of the acromioclavicular joint. Fixation of the clavicle to the scapula limits abduction of the arm and causes pain if motion is attempted beyond 90 degrees.

Surgical excision of the outer end of the clavicle was used in nine cases in this series (table 10) after conservative methods had failed. The cosmetic results (fig. 52, case 5) were excellent in all cases, the contour of the dorsum of the shoulder being maintained by the acromion process. Neither the function nor the appearance of the shoulder, however, could be described as normal in any case.

Prior to World War II, this operation had frequently been used in such conditions as osteomyelitis, arthritis, and tumors, and it had been used, though less frequently, in both fresh and old dislocations of the acromioclavicular joint. These experiences, as well as observations on persons with partial or complete congenital absence of the clavicle, had led to the conclusion that the patient with this type of defect was far better off than the patient with acromioclavicular ankylosis, and that the only disability after operation is a possible slight impairment of the muscular coordination needed for forceful forward thrusts of the arm or for acrobatics.

The results in these nine cases, while satisfactory, do not fully bear out these observations. Careful study of these men showed that the intact clavicle acts as a kind of yardarm, which prevents the shoulder from falling anteriorly and inferiorly onto the chest wall (fig. 52A). This is probably its most important function in man. These were all young men, and the musculature of the shoulder girdle compensated for the stability lost with excision of the clavicle. All of them, however, admitted to rapid fatigue or slight weakness of the affected shoulder as compared with the intact shoulder when they engaged in prolonged vigorous exercise, though within a few weeks of surgery all had been relieved of pain and disability.

In all nine cases, the operation consisted of resection of from 6 to 8 cm. of clavicle, which excluded the clavicular stump from interference with the motions of the scapulothoracic joint. Suture of the cut end of the clavicle to

⁷ Watson-Jones, Reginald: *Fractures and Joint Injuries*, 3d ed. Baltimore: Williams & Wilkins Co., 1943, vol. 2, pp. 433-435.

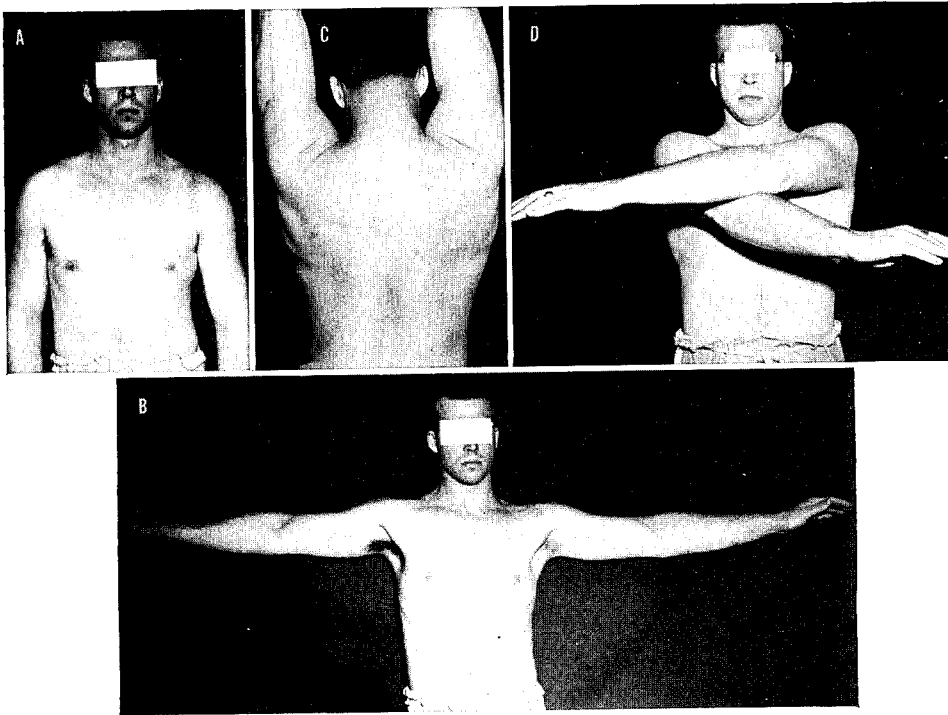


FIGURE 52 (case 5).—Results of excision of outer end of clavicle in complete dislocation of the left acromioclavicular joint, sustained in football game, after failure of management in author's splint. A. Photograph 10 days after operation and just after removal of sutures from incision, through which coracoclavicular ligaments were also explored. Note that affected shoulder is slightly lower than intact shoulder as scapula falls forward and lower on thorax. B. Photograph 15 days after operation. Range of active abduction is 90 degrees. C. Photograph 21 days after operation. Full elevation of arm is now possible. D. Photograph 28 days after operation. Painless crossing of elbows on the chest, which is now possible in this case, is seldom possible with any appreciable acromioclavicular separation.

the coracoid process with nylon sutures, as advised by Rowe,⁸ was not regarded as an essential part of the procedure and was omitted in all cases.

The following case reports illustrate both the indications and the results of this method of surgery:

Case 5.—This soldier was injured when, in the course of a football game, he was struck sharply over the dorsum of the shoulder by an opponent who blocked him out of a line play. A Velpeau bandage was applied as a first-aid measure and was replaced 2 days later by the author's splint. Roentgenograms showed excellent reduction, but there was slight widening of the acromioclavicular joint as compared with the joint on the opposite, intact side. Examination 4 weeks after injury showed the distal end of the clavicle to be abnormally mobile and apparently floating free. The splint was removed at 6 weeks, and daily exercises were begun at the shoulder wheel. At 8 weeks, there was 30 degrees of limitation of motion

⁸ Rowe, M. J.: Nylon Bone Suture. *Surgery* 18: 764-768, December 1945.

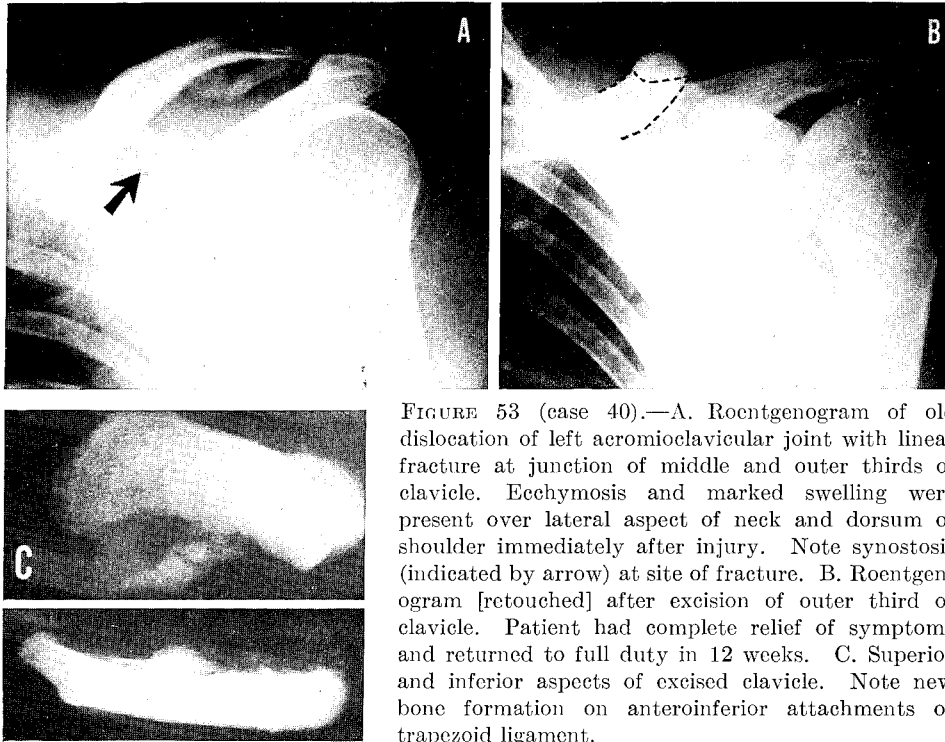


FIGURE 53 (case 40).—A. Roentgenogram of old dislocation of left acromioclavicular joint with linear fracture at junction of middle and outer thirds of clavicle. Ecchymosis and marked swelling were present over lateral aspect of neck and dorsum of shoulder immediately after injury. Note synostosis (indicated by arrow) at site of fracture. B. Roentgenogram [retouched] after excision of outer third of clavicle. Patient had complete relief of symptoms and returned to full duty in 12 weeks. C. Superior and inferior aspects of excised clavicle. Note new bone formation on anteroinferior attachments of trapezoid ligament.

when the arm was elevated, and pain and crepitus were experienced during exercises at the shoulder wheel. When the arms were folded across the chest, the distal end of the clavicle rose out of the joint. Ten weeks after injury, when it was evident that the man had full justification for his continued complaints, the distal end of the clavicle was resected. Shoulder exercises were begun even before the sutures were removed. Three weeks after operation there was no evidence of deformity or disability, and all symptoms had disappeared. The soldier cheerfully returned to full duty. This case is an instance of failure to heal under conservative therapy, even when conditions are ideal.

Case 40.—This soldier sustained a fracture of the left clavicle, with separation of the acromioclavicular joint, produced by a direct blow over the shoulder in a jeep accident 10 months earlier in France. The fracture healed uneventfully and in good position, and the man was returned to combat. Nine and a half months after the accident, he began to experience pain in the left shoulder. It increased in severity and was aggravated by exercise in games and calisthenics. The acromioclavicular joint was painful to palpation but was not abnormally mobile. The clavicle on the injured side was more prominent than on the intact side. The limitation of abduction of the arm was 30 degrees. Roentgenograms (fig. 53) showed a well-healed fracture at the junction of the middle and outer thirds of the clavicle, with synostosis between the fracture site and the coracoid process and ossification of the conoid and trapezoid ligaments.

The operative findings clarified the pain and disability from which the patient had suffered. A mass of bone and scar tissue was found throughout the insertion of the subclavius muscle and in the area of the coracoclavicular ligaments. A bridge of bone was palpable between the coracoid process and the site of the old fracture. The distal third of the clavicle and the ossified coracoclavicular ligaments and regional scar tissue were

removed en masse (fig. 53C), with a minimum of dissection. Physical therapy was begun as soon as the sutures had been removed. At the end of 3 months, when the patient had complete range of motion and was able to lift heavy weights, he was discharged to unrestricted duty.

Associated Fractures

Fractures were associated with the acromioclavicular dislocations in 11 cases in this series, there being 2 fractures in 1 instance (case 34, table 9). They were distributed as follows:

Four subchondral compression fractures of the clavicle (case 5, table 7; cases 35, 36, and 41, table 10).

Two avulsion fractures of the trapezoid ridge (cases 8 and 16, table 7).

A transverse fracture at the junction of the middle and outer thirds of the shaft of the clavicle (case 40, table 10).

A chip fracture of the acromial end of the inferior margin of the clavicle, in a partially overriding joint (case 9, table 7).

A chip fracture of the acromion process (case 4, table 7).

A fissure fracture of the acromion process (case 34, table 9). This patient also had a subchondral compression fracture of the clavicle.

Two avulsion fractures of the coracoid process (fig. 54, case 7; see also case 7, table 7; case 34, table 9), one of them in a patient who also had a subchondral compression fracture of the clavicle.

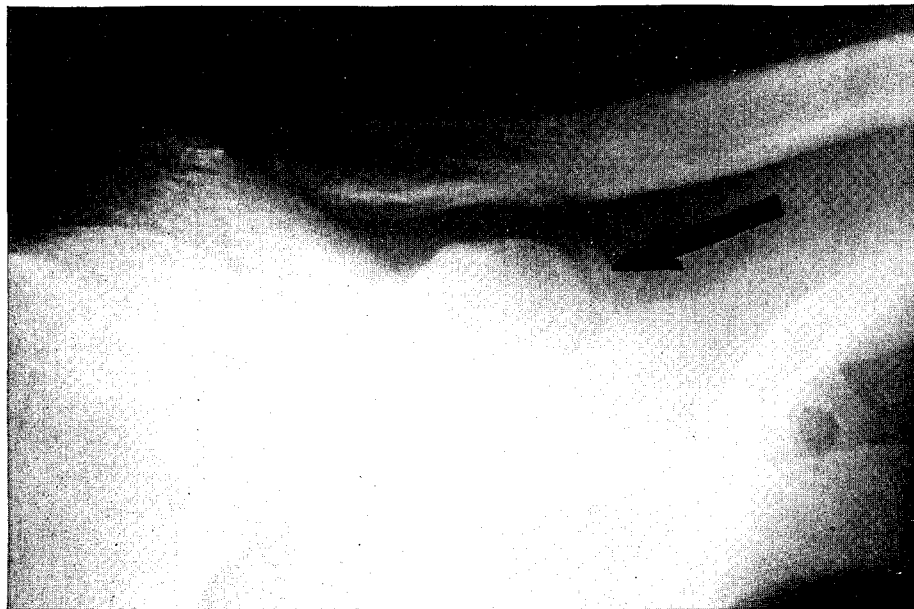

FIGURE 54 (case 7).—Roentgenogram showing avulsion fracture of medial aspect of right coracoid process sustained in jeep accident. This patient had a perfect cosmetic and functional result after immobilization for 6 weeks in author's splint.

As in similar traumatic dislocations in other areas of the body, the ligaments presumably suffered less damage when their bony insertions were avulsed. In both avulsion fractures of the coracoid process (cases 7 and 34), healing was not influenced adversely, and conservative treatment produced good results, though ossification of the coracoclavicular ligaments occurred. The same course of events was observed in the single avulsion fracture of the inferior aspect of the clavicle. Abduction was painful in 3 of the 5 cases in which articular surfaces were involved in the injury, and all 5 patients had painful joints for varying periods of time, though in only 1 instance (case 5, table 7) did the pain persist and eventually require excision of the outer third of the clavicle.

Complications and Sequelae

As this series shows, pain and limitation of motion may follow any type of complete acromioclavicular dislocation, whether the patient is seen early or late and whether the treatment is good, bad, or lacking altogether. Symptoms and disability in this series were, as is usually the case, chiefly the result of the development of arthritis, calcification, and ossification of the soft parts, and synovitis and adhesions in the joint.

Arthritis.—Osteoarthritic changes (see fig. 47, case 27), calcifications of the capsular ligament (fig. 55, case 4), and loose osteocartilaginous bodies (see fig. 48, case 39) were found on the roentgenograms in 12 cases in this series.

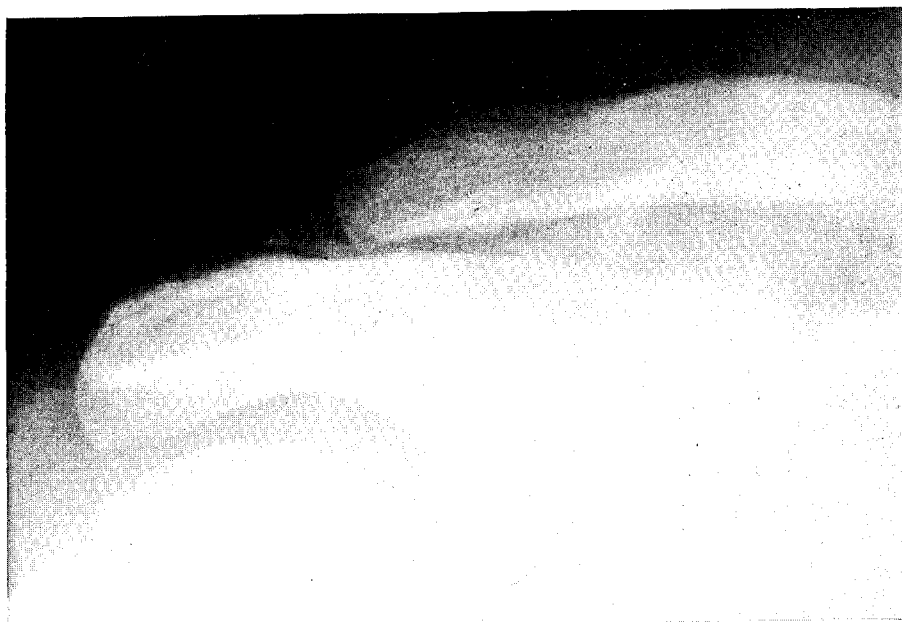

FIGURE 55 (case 4).—Roentgenogram showing dislocation of right acromioclavicular joint 8 weeks after injury in motorcycle accident. Ossification of coracoclavicular ligaments and calcification of meniscus, with chip fracture of acromion, have been demonstrated by soft-tissue technique. Note nearly vertical joint line.

Five of the twelve were treated by excision of the distal end of the clavicle. All had complete relief of symptoms within 3 weeks.

Atrophy or rarefaction of the acromial end of the clavicle was apparent in the roentgenograms in almost all the severe recent dislocations as well as in the cases seen late. If the dislocation remained reduced and normal function was resumed, the density of the bone gradually returned to normal.

So-called avascular necrosis or osteochondritis was observed in two cases (cases 35 and 36, table 10). In both, subchondral compression fractures were found at operation. Gross examination and roentgenologic examination of the excised specimens showed sclerosis of old bone, irregular areas of resorption, and new periosteal bone formation, typical of the process of healing in crushed spongiosa. Avascular necrosis is a complication which must be expected in a certain proportion of complete acromioclavicular dislocations, especially in severe cases, whether or not reduction is accomplished.

Only 7 of the 12 patients who presented these various changes had genuine pain, and only 5 of these, as already mentioned, had pain severe enough to require operation. There seems logic, therefore, in the position of some observers that the phenomena are not necessarily evidence of traumatic arthritis.

Calcification and ossification of soft parts.—Calcification of the conoid and trapezoid ligaments was demonstrated by roentgenograms in 18 cases (figs. 56, 57, and 58). (See figs. 47, 48, 53, and 55 for further examples.)

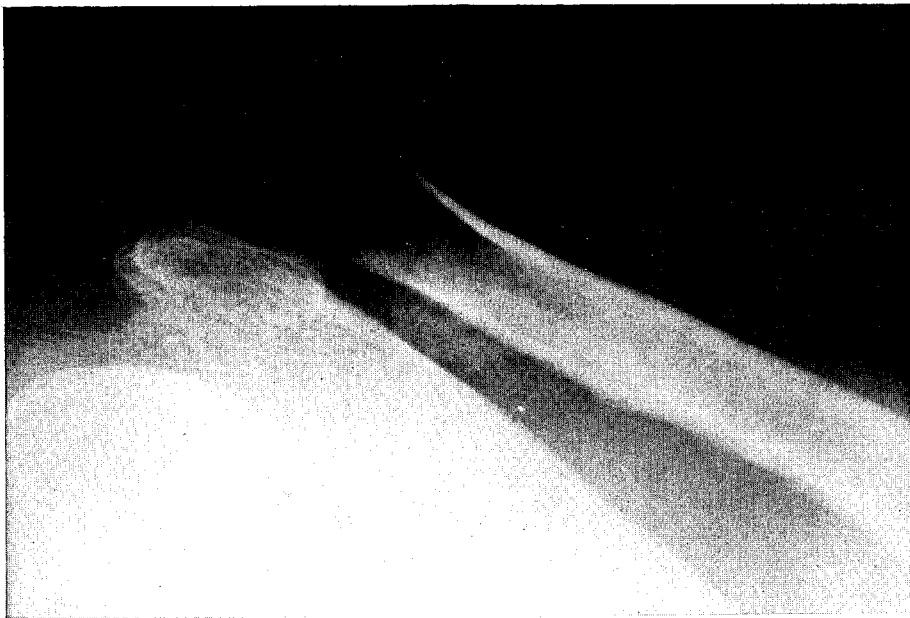

FIGURE 56 (case 19).—Roentgenogram showing dislocation of left acromioclavicular joint, 7 weeks after fall from motorcycle. Note calcification under clavicle, which had been evident since 3½ weeks after injury, but at that time did not show up clearly enough for reproduction.

These deposits first appeared within 3 or 4 weeks after injury and increased in density and extent during the several months that healing was in progress. They varied widely in their final size. In some instances, the deposit was a mere fleck, which could be observed only in oblique roentgenograms made by a special soft-tissue technique. In other instances, it took the form of massive ossification of the coracoclavicular ligaments and synostosis of the clavicle and scapula. Gross and roentgenologic examination of excised specimens containing new bone showed that in some instances the calcification appeared as an outgrowth from the periosteum of the clavicle or the coracoid process, while in other specimens it was a completely detached body.

Until actual fusion of the clavicle and scapula occurred, these deposits, judging by the patients' complaints and the physical findings, were not of clinical significance. When the synostosis was nearly complete (see case 24 in table 8 and fig. 57), range of motion of the coracoclavicular syndesmosis was diminished, and the effect on function was that of ankylosis of the acromioclavicular joint. In the case just mentioned, abduction beyond 90 degrees was painful and limited, although subluxation was only moderate. Both symptoms and deformity were relieved by excision of the outer end of the clavicle.

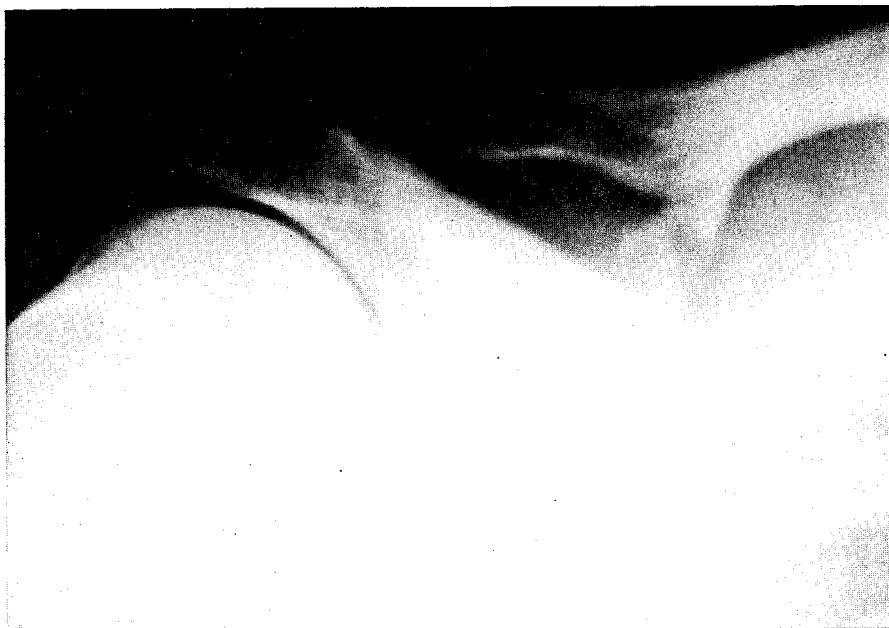

FIGURE 57 (case 24).—Roentgenogram showing dislocation of left acromioclavicular joint 9 months after injury sustained when jeep rolled down embankment under enemy fire. Note coracoclavicular synostosis, which was associated with moderate pain and inability to abduct arm beyond 80 degrees.

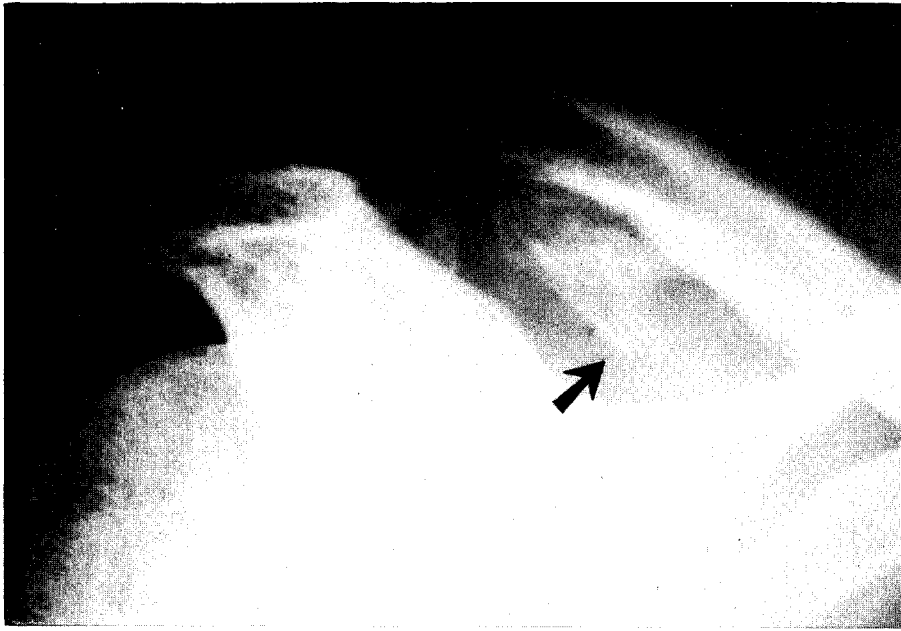

FIGURE 58 (case 26).—Roentgenogram showing dislocation of right acromioclavicular joint 10 weeks after automobile accident caused by artillery blast. Note coracoclavicular synostosis (indicated by arrow) which was associated with slight pain and limitation of abduction.

Synovitis and joint adhesions.—When vague pains and uncomfortable crepitations are present in complete dislocations of the acromioclavicular joint in the absence of demonstrable roentgenologic changes in the bone or the joint, it may be assumed that synovitis and articular adhesions are present. Swelling over the acromioclavicular articulation is sometimes observed in such cases. The patients may complain of instability with extreme motions of the shoulder, though this complaint usually disappears as time passes. These complications, as has already been noted, may occur whether or not the dislocation has been successfully reduced.

In the only case (case 6, tables 7 and 10) in this series in which these particular complications were evident, conservative treatment with the author's splint had apparently been successful for a year after treatment. Then the man, who was a stevedore, began to be incapacitated for his duties. When the outer end of the clavicle was eventually resected, the joint cavity was found obliterated by intra-articular fibrous connective tissue, calcified capsular ligament, and torn meniscus.

CHAPTER XVIII

Battle-Incurred Compound Fractures About the Hip Joint

Marshall R. Urist, M. D.

Battle-incurred compound fractures about the hip joint have been a major problem and have been attended with almost equally unsatisfactory results in all the recorded wars of history. This is true of the Napoleonic Wars; the Crimean War; the War of the Rebellion; the Wild West era of American development, which had all the effect of warfare; the Anglo-Boer War; the Spanish-American War; the Russo-Japanese War; World War I; and the Spanish Civil War. The records show that in all of these conflicts, compound fractures produced by war wounds in the region of the hip joint were more often septic, were more frequently associated with systemic infection, and healed more slowly and more unsatisfactorily than other joint injuries. They also had the poorest functional results and had the highest case fatality rate of all joint injuries.

The background of this chapter is a detailed analysis of 29 intensively treated, personally observed battle-incurred fractures in the region of the hip joint (fig. 59). These 29 fractures were selected from 154 similar injuries which occurred in a total of approximately 25,000 (chiefly battle incurred) orthopedic injuries treated in the 18 general hospitals which made up the 802d Hospital Center in the United Kingdom Base between May 1944 and July 1945. The reason for the selection of these 29 cases was threefold: (1) The patients were all treated intensively; (2) they were all personally observed and, because they were all classified as nontransportable, the period of observation was unusually long, ranging from 12 to 20 weeks; and (3) they were all followed up for periods varying from 6 months to 2 years. From this selected sample, it is possible to determine the special problems inherent in the reaction of the hip joint to injury and to evaluate the methods of treatment employed against methods previously employed and those recently proposed. The analysis of these cases is shown in the following tabulation:

Classification:	
Intracapsular.....	1 24
Extracapsular.....	4
Intrapelvic.....	1
Operations:	
Superficial debridement.....	20
Debridement and arthrotomy.....	9

¹ The intracapsular classification includes involvement of the head of the femur in 20 cases; of the neck of the femur in 5 cases; and destruction of articular surfaces in 18 cases.

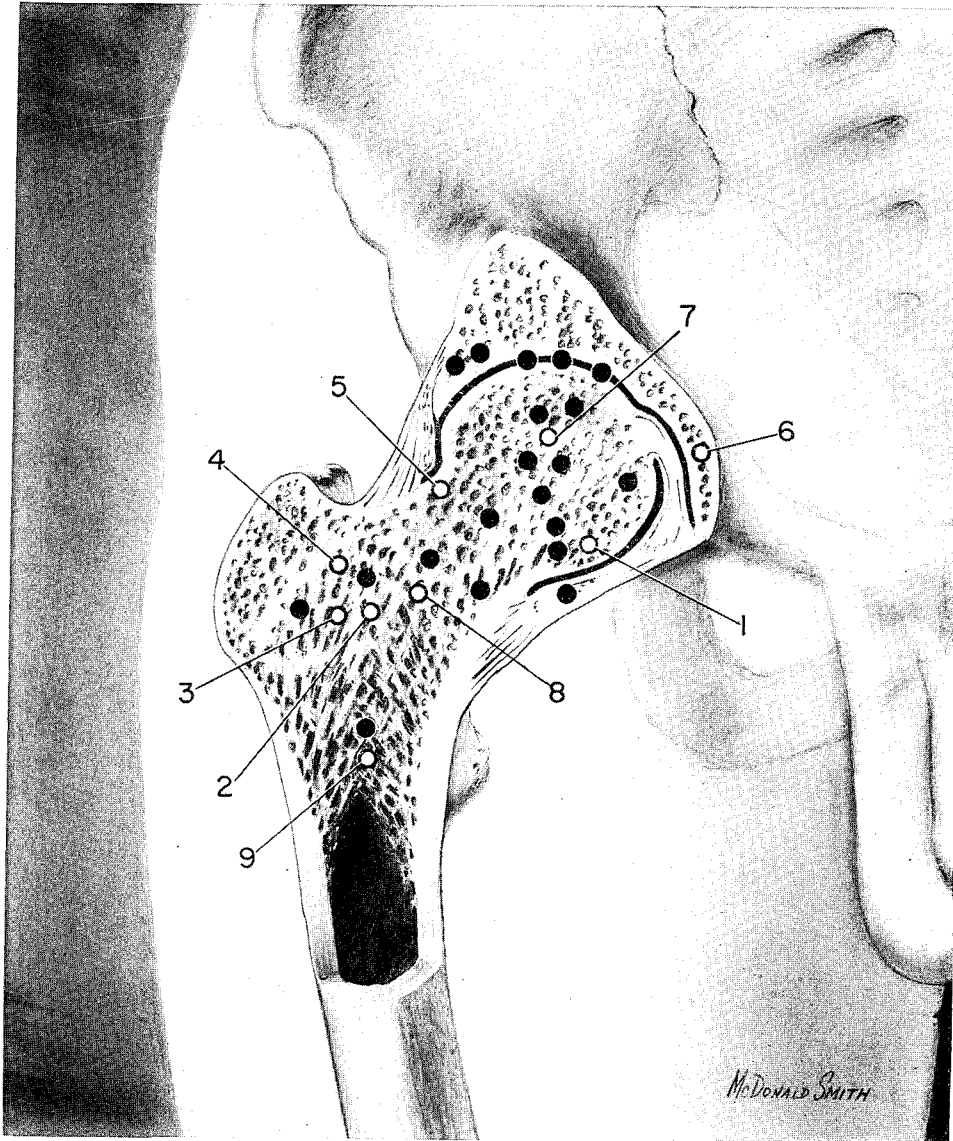


FIGURE 59.—Semidiagrammatic showing of distribution of 29 battle-incurred compound fractures of hip joint. Circles represent locations of main fractures. Numbered circles represent fractures described in detail in case histories in text. Since each fracture was the result of a missile injury, and since missile fractures are practically always comminuted, each circle may be considered the point from which a stellate lesion radiated to involve inferior and superior segments of the bone. Circles also, however, indicate the points of maximum displacement of the fractures.

Complications:	
Suppurative arthritis.....	9
Incision and drainage.....	6
Excision head of femur.....	3
Bronchopneumonia.....	3
Thrombophlebitis.....	1
Pulmonary embolism.....	1
Deaths (both from homologous serum hepatitis).....	2
Known end results.....	² 27
Less than 25-percent disability.....	9
Disability moderate or not yet determined.....	12
Disability more than 50 percent.....	5
Death from sepsis and undetermined other causes after 2 years.....	1
Other bone and joint injuries.....	19
Septic fractures.....	6
Sciatic nerve injuries.....	2
Laceration femoral vein.....	1
Chest injuries.....	2
Intra-abdominal injuries.....	8
Gastrointestinal tract.....	7
Liver.....	1
Genitourinary tract injuries.....	5
Nonorthopedic operations.....	20
Laparotomy.....	³ 9
Thoracotomy.....	2
Genitourinary.....	5
Incision-drainage septic wounds.....	4

² Known end results include 15 cases in which avascular necrosis of the femoral head occurred.

³ Including 6 major operations on the gastrointestinal tract.

Although the immediate results of wounds of the hip joint were no more encouraging in the early days of World War II than they had been in any other recent war, the situation had changed in one important respect: These wounds are not lethal in themselves, but they are frequently associated with other serious wounds, and in former wars the men who sustained them succumbed in large numbers on the battlefield or in forward areas. In World War II, many of them survived serious abdominal, thoracic, and other wounds which, of course, took precedence of bone injuries, and the fractures about the hip could therefore be treated. This was because of the speed of first aid; the competent abdominal, thoracic, and other urgent surgery performed in forward hospitals soon after wounding; the liberal use of whole blood and blood substitutes; the wise use of chemotherapeutic and antibiotic agents not available in earlier wars; and the excellent supervisory care along the whole chain of evacuation. Orthopedic surgeons in World War II were thus confronted with a challenge of almost unique magnitude, as compared with the responsibilities which had confronted specialists in this field in earlier wars.

Emergency Measures

Transportation of the wounded soldier from the battlefield to the hospital was more rapid, more efficient, and more humane in World War II than in

any other recorded conflict. The splints provided for transportation of casualties with injuries about the hip joint were modified from those employed in World War I. The most popular was the Keller-Blake half-ring modification of the Thomas splint, in which the leg is maintained in full extension. The traction obtained by this method was helpful in the control of pain, but adequate immobilization of the hip joint was not secured unless the torso was also bandaged to the litter. Immobilization of the torso is inherent in the use of the Liston and Hayes splints, which do not seem to have been employed on the battlefield in World War II, but the application of bandages, as just mentioned, was equally effective when the Keller-Blake modification of the Thomas splint was used, as it was in 19 of these 29 patients. The other 10 were transported in improvised splints, including splints made from rifles. One rifle was applied from the axilla to the lower extremity and the other from the groin to the foot. Both were held in place by bandages.

Patients strapped to litters for transportation in ambulances or airplanes automatically obtained good immobilization and efficient splinting for short periods of time between medical installations. Medical-aid men had been thoroughly schooled in the dictum that a soldier with a fresh fracture should be moved about or otherwise disturbed only when it was absolutely necessary. This practice alone probably saved as many lives as splints saved in World War II. Its importance was apparently not realized in World War I, when the Thomas splint was considered to be lifesaving.

Morphine, plasma, whole blood, and careful avoidance of any measures that would produce disturbance and pain at the fracture site reduced the incidence of shock originating on the battlefield in injuries about the hip joint and reduced the incidence of death from that cause before casualties reached a forward (field) hospital to a level not much higher than obtains in ordinary civilian automobile accidents. Unless a very large artery had been lacerated, pressure bandages were sufficient to control hemorrhage for several hours. During the time these particular men were treated, penicillin was available and was used routinely, usually with a sulfonamide.

With these exceptions, methods of treatment of injuries of the hip joint were much the same as those described in American, English, and German records of World War I. These records, unfortunately, were not made generally available in World War II, nor was their value emphasized, with the result that many of the errors made in the First World War were repeated in the Second. The experience in these 29 cases is typical in that respect, and their record may prevent similar errors of omission and commission in some future conflict.

Initial Wound Surgery

A directive from The Surgeon General's Office,¹ based on the accumulated experiences of World War I and experiences in World War II prior to D-day

¹ War Department Technical Bulletin (TB MED) 147, March 1945.

in the European Theater of Operations, provided for the management of wounds of the hip joint by debridement and early arthrotomy whenever circumstances permitted. Because of the more destructive character of the weapons used in World War II, extensive debridement was even more necessary than it had been in World War I. Wounds caused by land mines, hand grenades, shell casings, and particles of disrupted bullets might seem insignificant on the body surface, but underneath there would almost invariably be found extensive lacerations of the muscles and other deep tissues, and numerous blood clots.

In the presence of these injuries, it had to be assumed that bacterial contamination had occurred. The fact that bullets and some shell fragments had penetrated the body at white heat did not warrant the assumption that they were sterile. The phenomenon of the ricochet and the low velocity at which fragments of mine casings frequently entered the body made it inevitable that they would carry with them soil and fragments of clothing. This was not always evident when the foreign bodies were first lifted out of the tissues. When, however, blood clot, old fibrin, friable granulating tissue, or ensheathing scar tissue was soaked off, it was usually possible to identify wisps of woolen clothing, water-repellent raincoat material, and other fabrics which had not been apparent on the first inspection. Many observers thought the explanation of the apparently greater incidence of wound infection in winter was the greater amount of clothing worn in cold weather and the greater difficulties of personal hygiene under combat conditions. There seems little doubt that the original damage to soft parts, as well as the later ravages of infection, was almost directly proportional to the volume of cold steel, stone, wood, and other foreign material, including excreta inevitably present on clothing worn in combat, and to their retention in the tissues.

Fractures of the bony structures were the result not only of the force of the direct impact of the missile but also of its blast effect as it passed through the limb. The disorganization and disruption of the skeletal structure which followed, and the cutting effects of sharp fragments of bone, caused quite as much damage to muscles, nerves, blood vessels, and viscera as did the missile itself. Finally, foreign bodies which might have passed out of soft tissues were frequently retained in the hip joint because this pelvifemoral structure was powerful enough to arrest them.

All of these considerations explain why, in wounds of the hip joint as in other combat wounds, the first principle of management, regardless of location, was a bold incision. The excision of macerated tissue and retained foreign bodies was equally important; both served as excellent culture media for infection.

Primary arthrotomy, which is simply an extension of debridement to the joint, was regarded as a radical measure by many observers in World War I and by some surgeons in World War II. Pool,² however, in reporting to The

² Pool, Eugene H.: Wounds of Joints. *In* The Medical Department of the United States Army in The World War. Washington: U. S. Government Printing Office, 1927, vol. XI, pt. 1, pp. 317-341.

Surgeon General on its use in World War I, termed it a "conservative" operation. A comparison of his report with reports by British,³ French,⁴ and German⁵ surgeons makes it apparent that all of them followed much the same policies and practices and that apparent differences can usually be explained by differences in nomenclature. The French, for instance, advocated what they termed extensive primary resection of the joint as soon as possible after wounding. What it amounted to was a particularly extensive debridement.

The basic principles of arthrotomy and joint debridement may therefore be said to represent the evolution of a large experience, accumulated over the same period of time by many different surgeons working under much the same circumstances in several different theaters of war. Furthermore, the criticisms of arthrotomy voiced by such experienced military surgeons as Jolly,⁶ Trueta,⁷ Wheeler,⁸ and Levit⁹ were all expressed prior to the introduction of penicillin and the subsequent decrease in the surgical risk.

Analysis of Cases

It is not evident from any report in the literature that arthrotomy, per se, has ever been responsible for the introduction of infection into the joint. That generalization holds for the 9 cases in this series in which it was employed. On the other hand, sepsis is frequent when primary arthrotomy is omitted. It was present in 9 of the 20 cases in this series in which the joint was not opened at operation, and Ellis¹⁰ reported that it occurred in more than half of the cases in his series under the same circumstances. The figures suggest that whatever may be the merits of a watching and waiting policy in some injuries, it is not sound in wounds of the hip joint.

The only possible exception to the routine application of early debridement and arthrotomy was the type of case described by Pool¹¹ in the medical history of World War I, in which a high-velocity bullet perforates the hip joint cleanly, leaving punctate wounds of entrance and exit. In 2 such cases in this series, arthrotomy was omitted and only debridement was done. There were no septic complications, it is true, but it should also be pointed out that bone damage was much less severe than in the other cases.

In all, 20 of the 29 injuries of the hip joint in this series were treated initially by so-called conservative measures, consisting of cleansing the wound with soap,

³ Frankau, C. H. S.: Gunshot Wounds of the Joints. *In* Great Britain War Office, Medical Services. General History, Surgery of The War, History of The Great War Based on Official Documents. London: His Majesty's Stationery Office, 1922, vol. 2, pp. 297-325.

⁴ Fruchaud, H.: Wounds of the Joints. *Lancet* 2: 235-238, 19 August 1944.

⁵ Franz, Carl: Lehrbuch der Kriegschirurgie. Verletzungen des Hüftgelenks. Berlin: Springer-Verlag, 3d ed., 1942, pp. 303-307.

⁶ Jolly, Douglas W.: Field Surgery in Total War. New York: Paul B. Hoeber, Inc., 1941, pp. 123-128.

⁷ Trueta, José: The Principles and Practice of War Surgery With Reference to the Biological Method of the Treatment of War Wounds and Fractures. St. Louis: The C. V. Mosby Co., 1943, pp. 170-173; 214-226; 352-355.

⁸ Wheeler, W. I. de Courcy: Wounds Involving the Hip Joint. *In* Bailey, Hamilton: Surgery of Modern Warfare. Edinburgh: E. and S. Livingstone, 1st ed., 1941, pp. 474-480. 3d ed., 1944, pp. 541-549.

⁹ Levit, V. C.: Concerning Gunshot Wounds of Joints and Their Treatment. *Khirurgiya* 14: 3-8, 1944. Abstracted *in* Bull. War Med. 5: 303-304, January 1945.

¹⁰ Ellis, J. S.: Wounds in Region of Hip Joint. *Lancet* 2: 490-492, 20 October 1945.

¹¹ See footnote 2, p. 225.

water, and antiseptics; more or less complete debridement of the damaged soft parts, and final irrigation of the wound, without exposure of the joint or arthrotomy. The other 9 cases, as already noted, were treated within 12 hours of wounding by debridement of the soft parts, incision of the joint capsule, and removal of readily available foreign bodies and unattached fragments of bone and cartilage. The joint capsule was left open in 8 of the 9 cases, and the soft-tissue wounds were left open in all 29 cases.

Complete debridement was recognized, theoretically, as the ideal primary treatment for wounds of the hip joint, but there were many reasons why it could not always be applied:

1. Patients brought off the battlefield were frequently in shock and could not have withstood such extensive surgery as debridement and arthrotomy implied in wounds of the hip joint.

2. The injuries were often so extensive that complete debridement was not possible. The aim of early surgical treatment was to obtain gross mechanical cleanliness. To achieve it, wide excision of tissues was frequently necessary because small fragments of wood or metal, gritty substances, or bits of stone were so adherent that they could not be removed manually or by irrigation; sometimes their complete excision was impossible.

3. If injuries to bowel, bladder, or other structures were present and offered an immediate threat to life, their treatment had to take priority over treatment of a wound which threatened merely the vitality of a limb.

4. The tactical situation was often such that time-consuming operations on a major joint were not practical within an optimum, or even a reasonable time after wounding.

5. Surgery of the hip joint is a complex, difficult, and highly specialized procedure. Surgeons experienced in it and competent to undertake it were always in short supply and were seldom available in forward areas. Debridement of the soft tissues could be performed by inexperienced surgeons, but they could not undertake arthrotomy and debridement of the joint.

Nonetheless, the conservative measures employed in many cases in this series were deliberately undertaken, preliminary to a policy of so-called expectant observation or masterly inactivity. This was in direct conflict with instructions from the Office of The Surgeon General.¹² With all due regard for the difficulties of complete debridement and arthrotomy, token treatment of surface wounds in fractures of the hip joint in which thorough debridement was impossible still could not be condoned. The least that should have been done was to remove accessible foreign bodies, together with fragments of tissue crushed and deprived of circulation. When ideal therapy proved impossible, the least that should have been done in any case in which sepsis was clearly inevitable or seemed likely was to employ a bold incision and saucerize the wound. When infection was not present or was not thought a possibility, the local forces of nature usually proved remarkably adequate to prevent it in the young, healthy men who made up the casualties of war. When the circulation

¹² See footnote 1, p. 224.

in the hip joint and the capacity for repair seemed insufficient, debridement should have included removal of parts whose death or loss might reasonably have been anticipated. These simple principles were violated in a number of cases in this series.

Case Histories

Poor results did not always follow inadequate debridement, as the first and second of the following case histories show. The poor results which may follow an inadequate procedure are, however, well illustrated in the third case.

Case 1.—An infantryman was shot in the right hip by a rifle bullet which entered the anteromedial aspect of the joint, ripped away a segment of the inferior margin of the epiphyseal line of the femoral head, and lodged in the tissues adjacent to the greater trochanter (fig. 59). After superficial debridement of the wound in a field hospital, the patient was transported in a plaster-of-paris hip spica to an evacuation hospital, which he reached 4 days after injury. At this time, there was considerable local tenderness, but no local or constitutional signs of infection were evident.

When the patient reached a general hospital in the United Kingdom Base, skeletal traction was instituted by means of a Kirschner wire at the level of the adductor tubercle of the femur in a Thomas splint with Pierson attachment, with 30-degree abduction, 150-degree extension, and 5-degree internal rotation in a Balkan frame. On the 16th day after wounding, exploration was carried out through a lateral incision; the gluteus maximus was split at right angles to the line of the skin incision. The bullet was located by palpation of the muscle bellies and was removed. It lay in a pool of purulent fluid, and the adjacent tissues were discolored. The wound was deepened to the level of the greater trochanter and was debrided of all contused, necrotic tissue. It was left open, and closure was not undertaken until the 15th postoperative day. At this time, the wound was clinically clean and healing was uneventful. A smear from the fluid surrounding the bullet had showed typical purulent exudate, but routine cultures were sterile.

At the end of 4 weeks, the patient was removed from skeletal traction and put up in Buck's extension. Active exercises were carried out in it for the next 4 weeks. Eight weeks after wounding, roentgenograms showed no evidence of avascular necrosis. Eight weeks later, there was moderate limitation of rotation in both directions, 15-degree abduction, 15-degree adduction, and from 18- to 60-degree flexion. The patient was in excellent condition when he was evacuated to the Zone of Interior 2 weeks later. He was eager to begin to walk, but weight bearing was not permitted until 6 months after injury. At the end of the year, there was no appreciable disability.

Case 2.—An airborne infantryman was injured by a machinegun bullet which caused a compound fracture in the intertrochanteric region, with fissure fractures of the neck and head of the femur (figs. 59 and 60). The wounds were thoroughly debrided in a field hospital a few hours later, and the bullet was removed from the substance of the muscular attachments on the greater trochanter. Although the capsule was torn and frayed anteriorly at the base of the neck of the femur, the joint was not opened. Supportive therapy, including transfusions, was required for 4 days after operation.

On the 11th postoperative day the patient was transported in a plaster-of-paris hip spica to a general hospital in the United Kingdom. His temperature had been normal for the preceding 6 days. Roentgenologic examination at this time showed an extreme coxa vara deformity. The fracture was manipulated on the fracture table, and the wound, which was clinically clean, was closed by delayed primary suture. The hip was suspended in skeletal traction in a Thomas splint, with the ischial half ring inverted and with a Pierson attachment. Excellent reduction was obtained.

Eight weeks after wounding, the fracture was united, and the wound was well healed. Four weeks later the patient was evacuated to the Zone of Interior in a double hip spica with

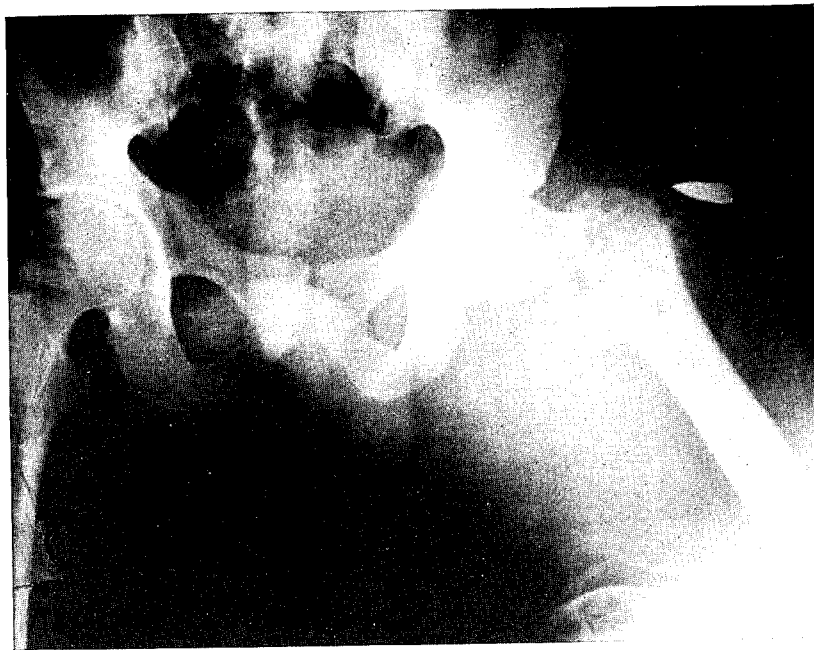


FIGURE 60 (case 2).—Roentgenogram showing compound intertrochanteric fracture. High-velocity machinegun bullet is seen in posterior soft parts. (Unless otherwise noted, all roentgenograms were taken within a few hours of wounding. This film and those reproduced in figures 66 and 67 were made with field equipment, under difficult conditions, which accounts for their poor quality.)

abduction, internal rotation, and flexion at the hip. At 9 months, he was reported to be walking in an ischial non-weight-bearing caliper brace, with 50 percent of the normal range of motion of the hip.

Case 3.—An infantryman was wounded in the abdomen by an artillery-shell fragment which perforated the pelvis and the right upper hip joint and emerged on the lateral aspect of the thigh. The upper end of the femur was shattered (figs. 59 and 61). Exploration of the abdomen at a field hospital a few hours later, after resuscitative measures which included a transfusion of 500 cc. of whole blood, revealed multiple lacerations of the large and small intestine. Enteroenterostomy and jejunostomy were performed. A 2-inch wound on the lateral aspect of the right thigh, through which the shell fragment had emerged, was enlarged to 7 inches, and debridement was done through it, but the joint was not opened. The saucerized wound was dressed with vaseline gauze, and a hip spica was applied.

Up to the 10th day, convalescence was uneventful, but in the hospital train, en route to the coast of France, a foul odor began to issue from the dressings, and the temperature rose to 101° F.

The hip spica was removed at a general hospital in England, and bilateral vertical skeletal traction was applied (fig. 62). The wound sloughed, and purulent material drained copiously from it. Cultures taken from the depths of the wound revealed a mixture of organisms, including both anaerobic and aerobic forms of streptococci and bacilli. In spite of systemic and local penicillin therapy (250 units per cubic centimeter of physiologic salt solution) drainage continued for 49 days. Closure of the wound was attempted at this time but was only partly successful, and a draining sinus persisted for several months longer. Over this whole period, there were daily temperature elevations to 99° and 100° F.

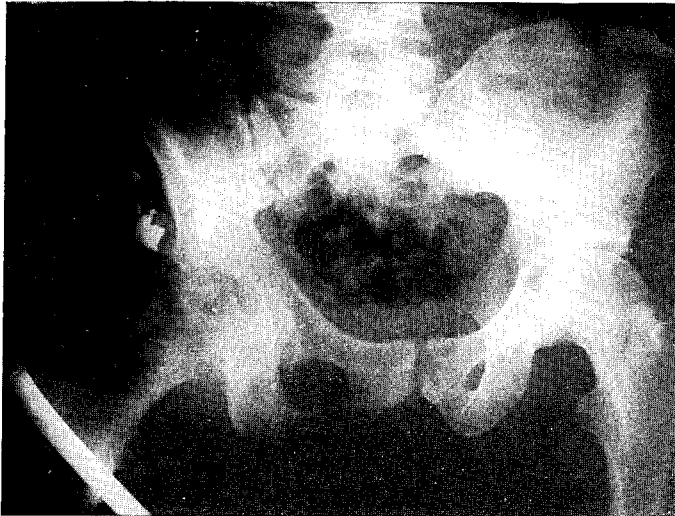


FIGURE 61 (case 3).—Roentgenogram showing extensive compound fracture of hip joint involving acetabulum and head of femur. Roentgenogram also shows shell fragments which produced the damage. This picture was made after fractures had been reduced and immobilized for 10 weeks in vertical skeletal traction.

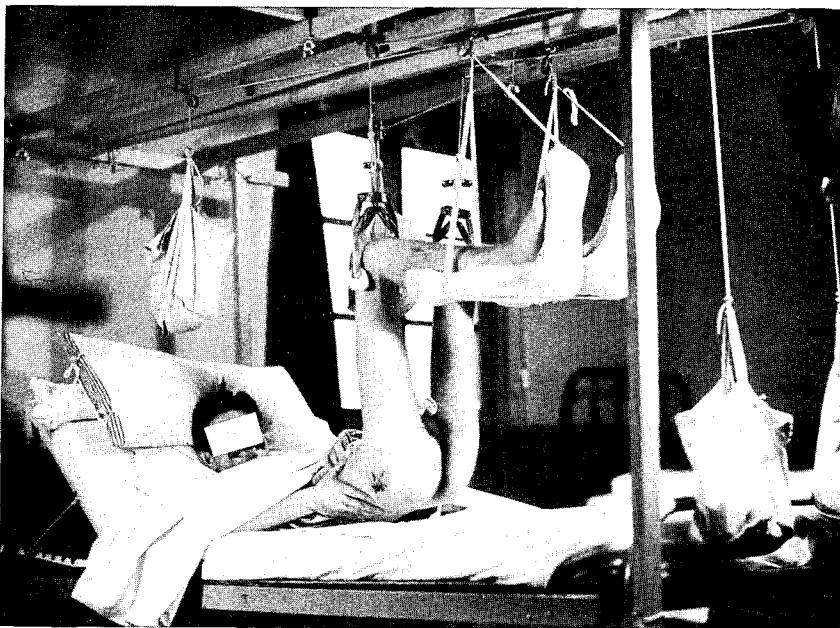


FIGURE 62.—Vertical skeletal traction with overhead balanced suspension in compound fracture of hip joint. Note that patient can lift himself on bedpan and that active and passive exercise of knee joints is possible. This form of traction and suspension could therefore be maintained for 4 to 5 weeks without much danger of development of contractures.

Although the jejunostomy functioned well, the patient lost weight steadily. Laboratory studies showed a secondary anemia and slight hypoproteinemia. Supplementary feedings of a high-protein, high-caloric, high-vitamin diet were followed by a slow gain in weight.

At the end of 10 weeks, vertical skeletal traction was discontinued, and the patient was put up in suspension in a Rouvillois splint (fig. 63), with 45-degree flexion and 20-degree

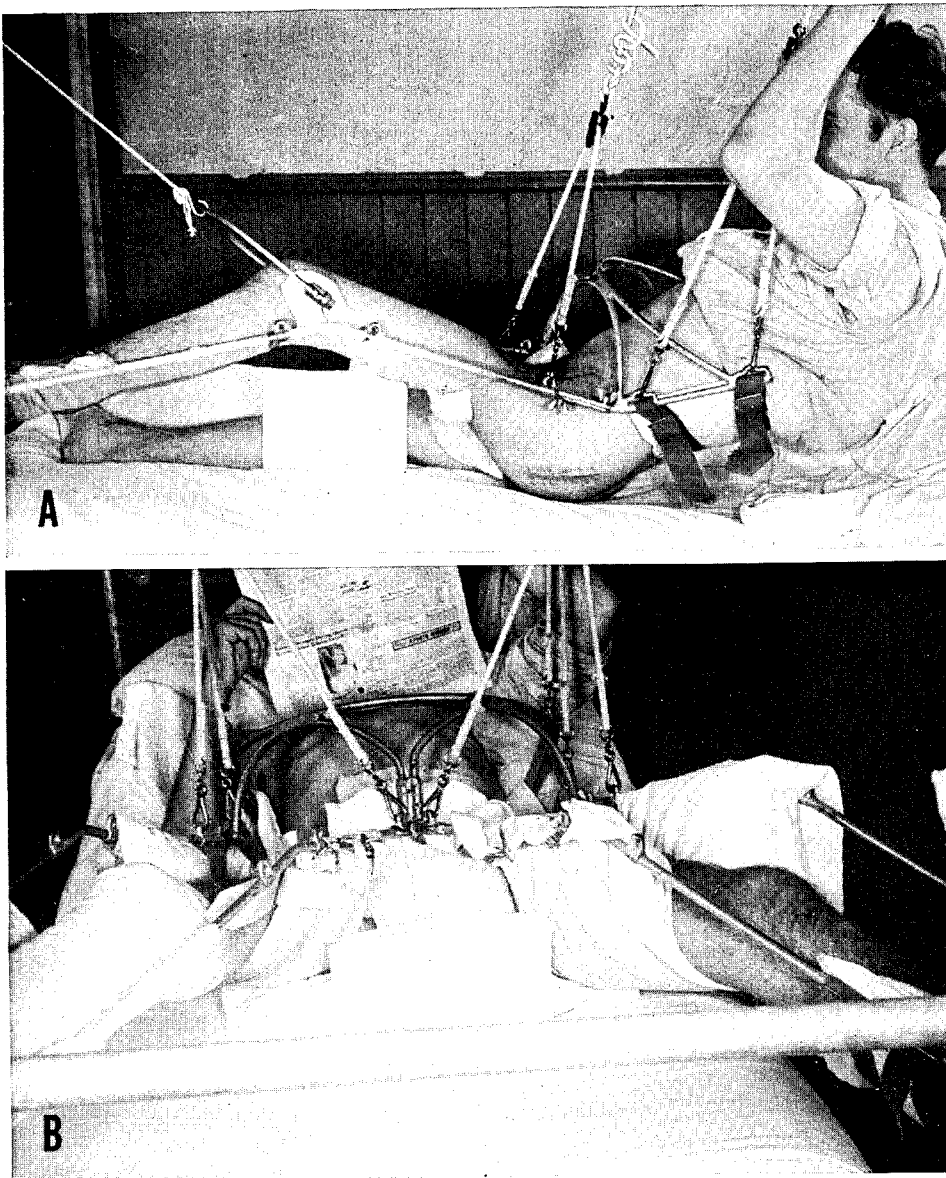


FIGURE 63.—A. Use of Rouvillois lumbofemoral splint with skeletal traction and unilateral suspension in compound fracture of neck of femur. Note that patient can lift himself from bed and exercise while in this apparatus. B. Use of Rouvillois splint with bilateral suspension in bilateral fractures of pelvis and hips.

abduction. At this time, the fracture was in excellent position, and some motion could be obtained in the joint under anesthesia. At the end of 6 months, the roentgenograms showed a typical picture of avascular necrosis, with ossification of the superior capsule. Clinically, the joint was ankylosed and painful, and disability was almost complete.

Surgical Approach to the Hip Joint

In 2 of the 9 cases in this series in which arthrotomy was done, the approach was by a posterior (Kocher) incision, which was merely an enlargement of the original wound. In another instance, the approach was by a lateral (Watson-Jones) incision. In the other 6 cases it was by an anterior or Smith-Petersen incision. This approach, which was widely popular in the United States even before World War II, consists of anterior iliofemoral arthrotomy, with exarticulation of the head of the femur. In an occasional case, when the traumatic wound is very large, it is good judgment, as in this series, to use any other standard incision, such as the Kocher or the Watson-Jones incision, which best exploits the exposure already present. With these exceptions, the anterior iliofemoral route is the most expeditious of all approaches.

The Smith-Petersen incision has a number of advantages. It is easily modified. In 2 of the cases in which it was used in this series, the original technique was followed, except for omission of tenotomy of the rectus femoris. The incision was particularly useful in both cases because it permitted debridement and irrigation of the acetabulum under direct vision, which would not have been possible with any other approach. In both of these cases, elongation of the wound and development of the iliac portion of the approach, as in arthroplasty, provided sufficient exposure to permit exarticulation and resection of the head of the femur, including part of the acetabulum. In another case, L-shaped incision of the capsule and removal of numerous fragments of the head of the femur resulted in sufficient relaxation to permit exarticulation and irrigation of the joint and to make excision of the anterior ligaments unnecessary. It was possible, as the next step, to close the joint and instill penicillin. Another advantage of the Smith-Petersen approach is that the exposure can be made to correspond with the degree of damage to the joint. In 3 cases in this series in which there was a fracture of the neck or only minor damage to the circumference of the head of the femur, exposure of the joint in the sulcus between the sartorius and rectus femoris permitted thorough debridement without exarticulation.

The following case history illustrates the advantages of the Smith-Petersen approach:

Case 4.—When an infantryman was examined at an evacuation hospital a few hours after he had sustained a perforating wound of the left hip from a machinegun bullet, a small puncture wound was found on the anterior aspect of the upper portion of the injured thigh. The wound of exit, 2 inches long, was in the left buttock. Roentgenograms made under field conditions showed a stellate fracture of the neck of the femur which extended into the head and split the upper portion of the greater trochanter (fig. 59). After resuscitative

measures, including a transfusion of 500 cc. of whole blood, the joint was exposed by the anterior iliofemoral approach and was thoroughly cleansed of all loose bone and blood clots by debridement and irrigation. The posterior wound was enlarged to 3 inches and was carried down to the bone by splitting the muscle along the track of the missile. Closure of the joint capsule could not be effected. Penicillin solution (10,000 units) was injected into and around the articular cavity. The fractures were reduced by manipulation, and the hip was temporarily immobilized by skin traction in a Thomas splint.

Seven days later, the patient was evacuated to a general hospital in the United Kingdom in a plaster hip spica, in Whitman's position. Three days later, the wounds were closed by delayed primary suture, and the patient was suspended in skeletal traction in a lumbo-femoral Rouvillois splint, in which he remained for the next 8 weeks. At the end of this time, there was partial union. The patient was evacuated to the Zone of Interior 3 weeks later (11 weeks after wounding) in Whitman's position. There the hip was again suspended, this time in a Thomas splint with Pierson attachment. An ischial caliper non-weight-bearing brace was fitted at 20 weeks. At 10 months, although the fracture was still incompletely united, there was no limitation of adduction or abduction, and 90-degree flexion was possible. A McMurray osteotomy was performed at the end of a year because of insufficient bone structure in the neck of the femur.

Management of Retained Foreign Bodies

The foreign bodies encountered in these 29 injuries about the hip joint consisted of fragments of steel from hand grenades, high-velocity bullets, casings from high-explosive artillery shells and land mines, and similar objects. In 9 cases the hip joint was perforated, and in 2 instances infection followed. In 1 of these cases the bullet passed through the bladder, did great damage to the head of the femur, and left a track of metallic dust behind it.

In the other 20 cases, 1 or more fragments penetrated the hip joint and lodged in it or about it. In 6 of these cases, no attempt at removal was made. In 9 cases, complete removal of the foreign bodies was possible; infection followed in 1 instance. Infection also followed 5 operations in which only partial removal of the foreign bodies was accomplished.

Operations for removal of foreign bodies from the hip joint were undertaken only through standard surgical approaches. These permitted sufficient visualization of vital nerves and blood vessels in the region to prevent further trauma. Blind extraction of a sharp missile from its bed was extremely dangerous and was not attempted. In actual practice, the most efficient method of detecting foreign bodies was found to be by digital exploration, oriented by true antero-posterior and lateral roentgenograms. Two gloves were always worn, because of the risk of tearing the glove on the sharp fragment.

In 4 cases, the foreign bodies were found at operation in lakes of green, purulent fluid. In 2 such instances, the fluid was sterile on culture. In the other 2 cases, various organisms were identified, including *Bacillus proteus* and *Bacterium coli*. One of these 4 patients developed fulminating pyoarthrosis. The other 3 recovered uneventfully, and wound healing was satisfactory in each instance.

Wound Closure

Closure of the wound of the joint was always the desideratum after arthrotomy, but in most fractures of the neck or head of the femur the ligaments were so badly damaged that complete closure of the capsule was usually impossible.

When the incision was anterior, closure of the wound of the soft tissues offered no difficulty; the muscles fell together with remarkable ease. When there had been considerable loss of substance in the soft parts, it was the practice to remove various amounts of iliac crest with a sharp osteotome, to obtain close approximation of bone and soft parts, and to eliminate dead spaces or close the incision without tension, according to the circumstances of the individual case. Black silk, which was used for deep stay sutures, was tied loosely, so as not to interfere with drainage of the wound along the natural anatomic planes. Closure of the skin was delayed for 5 to 7 days, until the critical period of possible infection had passed.

Delayed primary closure of the soft-tissue wound was carried out successfully in 9 clean cases in this series and was partly successful in 2 others. The operations were usually done within 4 to 10 days after wounding. Drainage was not employed in any of these cases. Nine other clean cases which were closed by the same plan healed by secondary intention or were treated by skin grafting. In the remaining 9 cases, wound closure was never seriously considered, because infection was present or was obviously impending when the patients first came under observation. In several of these cases, multiple foreign bodies were retained; delayed primary closure was, quite correctly, never employed in such cases.

Adjunct Fracture Management

Postoperative transportation splinting.—Twenty-seven of the twenty-nine casualties, after surgical treatment in the field or evacuation hospitals, were transported to rear installations in plaster-of-paris double hip spicas, with the plaster carried only to the knee on the uninjured side. The other 2 patients were moved in Tobruk splints.

The orthopedic surgeons in general hospitals who treated the 154 patients with compound fractures of the hip joint from which these 29 cases were selected for detailed analysis had no doubt of the relative advantages of these 2 splints. Almost without exception, they agreed that the men were more comfortable and their injuries were more adequately immobilized in the properly padded full plaster spica than in the Tobruk splint or any of its modifications. It is true that the initial application of a hip spica was slightly more troublesome and somewhat more time consuming than the application of the Tobruk splint, but the hip spica was the least difficult of all splints to maintain, and in the end time was saved by its use. Extension in the Tobruk splint was advantageous when there were no other wounds or when the wounds were so located that the padded bar of the splint could be placed against the ischial

tuberosity, but this advantage was more than counterbalanced by the ineffectiveness of the traction thus obtained, as well as by the rapidity with which whatever traction had been achieved was dissipated during transportation.

Ellis' ¹³ suggestion that a Thomas splint be incorporated in the hip spica was made independently by several United States Army surgeons in evacuation hospitals about the time that he advanced it. This technique was employed in 2 cases (not included in the 29 analyzed in this chapter) but it proved no more effective than the original Tobruk splint.

Skeletal traction.—Two patients in this series were retained in plaster spicas without traction. Two others were treated in extension, one by Russell's and the other by Buck's apparatus. The other 25 were treated by skeletal traction. This was a larger number of cases treated by this technique than had been recorded in any other single series of combat-incurred fractures of the hip joint up to the end of World War II.

Reduction of fractures of the hip can be obtained more easily, at least by comparison, in combat-incurred injuries than in similar civilian-type fractures, because of the soft consistency and flexibility of fractures resulting from combat. Maintenance of fragments in position, however, requires some form of continuous traction. The proper combination of manipulation and traction is essential for good results. Neither one of these methods is sufficient in itself. In this series, the advantages of combined manipulation and traction were clearly evident. The combination provided comfortable immobilization, while at the same time it permitted maximum exposure of the wounds for dressing and other treatment. It kept the joint surfaces separated while they were healing. It held the reduced fractures in proper position in cases which had originally showed extreme coxa vara. Finally, and by no means least important, it facilitated nursing care.

The advantages of traction for compound fractures of the hip joint were recognized in World War I, just as in World War II, though not all of the methods proposed were efficient. Wheeler ¹⁴ in 1944 and Ellis ¹⁵ in 1945 suggested that the Jones abduction frame, which Frankau ¹⁶ had recommended in World War I, be used when patients could not tolerate countertraction on the ischial tuberosities or about the gluteal or perineal regions. This apparatus (an upholstered table with leg splints attached for traction) was, however, cumbersome and not entirely efficient. It did not provide for flexion of the hip, which is essential in bilateral injuries, or for exposure of wounds of the buttocks or sacrum, which are frequently associated with hip injuries. Efficient nursing care was also difficult in this apparatus. Some of these difficulties had been solved in World War I ¹⁷ by the use of the pelvic elevator, as suggested by the United States Navy Medical Corps, but the weights and pulleys required were also cumbersome and difficult to handle.

¹³ See footnote 10, p. 226.

¹⁴ See footnote 8, p. 226.

¹⁵ See footnote 10, p. 226.

¹⁶ See footnote 3, p. 226.

¹⁷ See footnote 2, p. 225.

The newer techniques of suspension used in overseas hospitals in World War II proved far more efficient than any of the methods employed in World War I. Among them were the following:

1. Vertical traction (fig. 62). Although this is not a universally applicable method, it proved more efficient than the Thomas splint in every case in which it could be used.

2. The hip spica. This was the most efficient method for the immediate postoperative management of suppurating hip joints with missing bone substance. It was equally efficient as a transportation splint for patients to be returned to the Zone of Interior.

3. Pelvic suspension. This technique, which was devised by German surgeons,¹⁸ was carried out by means of wires placed through the anterior superior spines of the pubis. It could be used alone or in combination with vertical skeletal traction. American orthopedic surgeons did not use it widely.

4. The Rouvillois splint.¹⁹ This splint (fig. 63), which had been introduced in 1925, was standard equipment in the French Army. Considerable quantities were captured by the Germans at the fall of France in 1940, but they apparently did not use it, as large numbers were found by American forces going through France in 1944. A supply was issued to the 22d General Hospital, by the senior consultant in orthopedic surgery, for preliminary trial, and the splint soon became very popular among the surgeons who had access to it, though it remained unknown to other surgeons until the end of the war. This was unfortunate, for it provided more comfort for the patient than any other method of traction currently in use, and it also simplified nursing care. Not a single instance of sacral decubitus ulcer was observed in any case in which this method was used.

The Rouvillois splint (fig. 63) is essentially a modification of the Blake splint. It consists of a metal frame in which the leg and thigh are suspended on slings and attached to which is another large curved metal frame which extends anteriorly over the lower torso. This second frame holds the attachments of the supporting hammock placed under the lumbar spine. The weight of the frame, aided by the hammock, provides the necessary countertraction. Universal joints at the knee and hip permit any angle of flexion, abduction, and rotation. The whole apparatus can be suspended in balanced traction, and the region of the hip and sacrum can swing freely, without pressure on the bed at any point. The patient can also exercise in this splint.

5. The revolving orthopedic frame. This frame, which was devised at the 22d General Hospital in World War II,²⁰ is basically a Bradford frame revolved by mechanical means. One of its advantages was that it could easily be constructed from salvage material available in any Army ordnance depot. This frame solved many of the problems which were encountered

¹⁸ Westhues, H.: Die knöcherne Halbschwebelagerung des Beckens. *Chirurg.* 14: 489-493, 1942.

¹⁹ Rouvillois, M. H.: Appareils universels à suspension pour le traitement des fractures du membre inférieur. *Bull. et mém. Soc. nat. de chir.* 51: 846-849, 1925.

²⁰ Urist, M. R.; Maxwell, E. A.; and Ferguson, R.: Revolving Orthopedic Frames Made From Salvaged Material. *Bull. U. S. Army M. Dept.* 6: 628-630, November 1946.

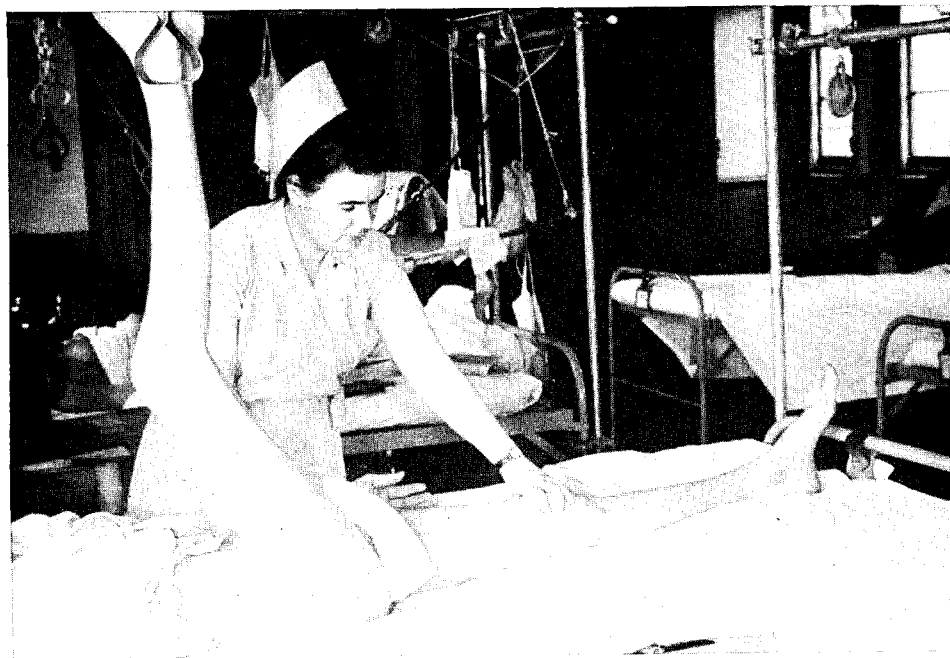


FIGURE 64.—Active exercises in bed 8 weeks after open reduction and internal fixation of pertrochanteric fracture of femur. Old scars of bullet wounds of entrance and exit can be seen, as well as healed incision of lateral approach to upper femur between these wounds.

when fractures of the hip joint were associated with wounds of the intestine which required colostomy and wounds of the bladder which required cystostomy. It greatly simplified nursing care in such cases and was particularly useful when patients with severe, complicated injuries of the hip joint had to be transported in plaster casts for long periods of time.

Early motion.—Moderate passive exercises could be carried out while the patient was in suspension and were usually begun during the first 8 weeks after injury (fig. 64). Quadriceps-knee exercises were always supervised by physical therapists.

Active exercises were seldom possible or practical during the first 12 weeks of healing in compound fractures of the head or neck of the femur. They were, however, instituted guardedly and gradually in 2 cases in this series within this period, with very good results. One of these cases (case 1) has been described in detail elsewhere in this chapter.

Adjunct Therapy

Supportive therapy.—The constitutional and nutritional status of many patients in this series, especially those with pyoarthrosis, was extremely poor and furnished extremely serious problems of management. Eight of the 9 septic patients became greatly emaciated within 4 to 8 weeks after wounding,

their weight loss being progressive. Many of the septic patients, as well as a number of others, presented serious secondary anemia, and most of the 29 patients had low plasma protein levels.

Men with extensive wounds were routinely given supplementary feedings of high-caloric, high-protein substances in addition to their regular meals. They also received supplementary vitamins and iron salts. The correction of anemia in the septic patients was more of a problem. Some of them had already had so many transfusions that matching them with donors was difficult when more blood was needed to fortify them for additional surgery on the joint. In a number of instances in which multiple small transfusions would have been highly desirable, this plan, for the reason just stated, could not be employed.

Chemotherapy and antibiotic therapy.—Every patient in this series was treated with penicillin and sulfadiazine for at least 10 days from the day of injury. In many instances, chemotherapy was continued for weeks, the duration of treatment depending upon the temperature response. The early use of chemotherapeutic agents constituted one of the essential differences between the management of casualties with injuries of the hip joint in World War I and their management in World War II. Chemotherapy proved an effective measure, though the reliance apparently placed upon penicillin in the early days of its availability, when it was sometimes regarded as a possible substitute for surgery, was never justified. It should have been evident from the beginning that damaged bony tissues lack circulation to distribute a drug given systemically and lack interstices for its diffusion when it is given locally.

When therapy was systemic, as it usually was, penicillin was given in doses of 20,000 units at 4-hour intervals and sulfadiazine in doses of 1 gm. by the same schedule. Chemotherapy was used locally as a routine measure in the early phases of American participation in World War II and was occasionally employed by this route almost until the end of hostilities. Penicillin was used locally much less frequently.

Fourteen of the twenty-nine patients in this series, chiefly those injured in France within the first weeks after D-day, received local sulfonamide therapy, crystalline sulfanilamide being implanted in the wound in doses of 2 to 5 gm. In 5 instances, the sulfanilamide (10 gm.) was combined with 20,000 to 50,000 units of penicillin. In 2 other cases, penicillin solution (20,000 units) was injected into the joint after arthrotomy.

Seven of the nine septic cases were treated by one or another of these methods. There is no reason to believe that the infection was modified by their use in any instance. There is also no reason to believe that local chemotherapy had anything to do with the absence of sepsis in the 20 nonseptic cases in the series.

Complications of Hip Injuries

Suppurative Arthritis

Suppurative arthritis was a major problem in wounds of the hip joint in World War II, just as it had been in previous wars, but the incidence was much

lower than it had been in the War of the Rebellion²¹ and in World War I.²² The fearful infections so commonly observed in military hospitals during those wars were seldom observed in World War II, probably as the result of the almost routine use of the sulfonamides and penicillin from the time the patient was injured until his wound was completely healed. In the 154 wounds of the hip joint observed between D-day and V-E Day at the 802d Hospital Center, there was not a single instance of the type of rapidly spreading hemolytic streptococcal or staphylococcal infection described by Frankau²³ in World War I and characterized by hyperpyrexia, tachycardia, and septicemia. Infections of this sort were usually promptly fatal.

The incidence of infection in this series, 9 of 29 injuries, is slightly less than that reported in similar series by Ellis²⁴ and by Franz.²⁵ There was 1 instance of infection in the 5 fractures involving the neck of the femur and 8 instances in the 20 cases in which the femoral head was fractured or completely exploded. Most writers, unfortunately, have failed to specify the region of the fracture in reports of the development of infection, though this is an important consideration. The femoral head has low vitality and high susceptibility to infection, and injury to it alone may largely determine the end result.

The infection was mixed in all 9 cases in this series. *Bacterium coli* and *Bacillus proteus* predominated in 5 cases and could be cultured from the deep spongiosa of the femoral head in a sixth case.

Experience proved that it was extremely important to keep close watch on the charts of patients receiving chemotherapy, to pick up low-grade fevers, anorexia, and other evidences of infection which might be masked by the drugs being administered. In 1 case in this group, aspiration, and later incision, revealed pyoarthrosis and a gluteal abscess, and, in another, pyoarthrosis was associated with a pelvic abscess. In both cases, the clinical localizing signs—rubor, calor, and dolor, as well as the usual systemic responses to infection—were strangely obscure. The explanation probably is that the more virulent organisms originally present had been controlled by penicillin and sulfadiazine, while the organisms undoubtedly introduced by fecal contamination on the buttocks and the clothing, although they did not produce the usual acute manifestations of suppurative arthritis, were not suppressed by chemotherapy and flourished in the deep necrotic tissues.

Suppurative arthritis developed in all 7 cases in which intestinal wounds were also present, just as in 6 similar cases observed by Collom and Hampton²⁶ in the Mediterranean theater. In 2 cases, the anterior wounds of the hip

²¹ Otis, George A., and Huntington, D. L.: Wounds and Injuries of the Hip Joint. In *The Medical and Surgical History of the War of the Rebellion*. Washington: U. S. Government Printing Office, 1883, vol. 2, pt. III, pp. 61-168.

²² See footnote 2, p. 225.

²³ See footnote 3, p. 226.

²⁴ See footnote 10, p. 226.

²⁵ Franz, C.: Zur Frage der Gelenkresektionen. *Deut. Militärarzt*. 7: 266-272, April 1942. Abstracted in *Bull. War Med.* 3: 322-324, February 1943.

²⁶ Collom and Hampton. Unpublished data.

joint were only a few inches from the colostomy stoma, and in spite of the utmost care in dressing the intestinal wounds, as well as repeated attempts to isolate them with collodion gauze and adhesive tape, contamination of the wounds of the hip joint was repeated and constant. The juxtaposition of the intestinal wound to the hip joint was so obvious a source of infection that it was an error, as the following case shows, not to place the colostomy well up on the abdominal wall, even if it had been necessary to create it in a more proximal portion of the bowel.

Case 5.—A paratrooper suffered lacerated wounds of the right lower abdomen and a penetrating wound of the right hip joint from high-explosive shell fragment. Debridement, removal of a large intra-articular foreign body, and cecostomy were carried out shortly afterward at a field hospital. The hip was put in a spica. During the first week after wounding, the patient received 2,000 cc. of whole blood and 7 units of plasma. Although every effort was made to prevent contamination from the colostomy, the hip spica became soiled. On the seventh day, the temperature rose to 102° F., and the hip wound began to discharge large quantities of pus with an unmistakably fecal odor.

When the patient was received by air in the United Kingdom Base on the 11th day after wounding, the original cast was replaced by a fresh, reinforced, well-padded hip spica which was constructed with fenestrations lined with waterproofed material to permit dressing of the hip wound and the cecostomy. The temperature continued to rise daily to 102° F., and, by the 18th day after wounding, there had been a considerable and progressive loss of weight and bedsores had appeared over the sacrum. By the 32d day, sloughing of the wound had resulted in the loss of so much substance on the anterior aspect of the hip joint that the fracture site was clearly exposed.

At this time, the patient was removed from the spica and put up in suspension in skeletal traction, by means of a Kirschner wire inserted through the tibial tubercle. On the 50th day, in an attempt to simplify the management of the hip wound, an abdominal surgeon closed the colostomy and partly repaired the wound of the abdominal wall. Evacuation of the bowels through the rectum after this operation eliminated many of the previous problems of nursing care. Supplementary high-protein, high-caloric feedings were instituted. On the 60th day, the hip wound was widely opened, and the entire anterior aspect of the joint was saucerized. Drainage continued to be copious. On the 63d day, the patient became severely jaundiced, and weight loss was even more rapid than it had been previously. Death occurred 12 days later, on the 75th day after wounding. Homologous serum hepatitis was regarded as the immediate cause. The necropsy also revealed, as frequently happened in battle-incurred injuries, that the bone was damaged much more extensively than the roentgenograms had indicated. The inferior portion of the fracture line was healing, but the femoral head was necrotic.

The only other death in the series, also in a serious infection of the hip joint, was also attributable to homologous serum hepatitis. This patient had been given a transfusion of dried plasma immediately after wounding, 3 months earlier.

A followup of the 29 cases in this series for a minimum of 6 months and usually for longer periods of time showed that, if joint infection were to occur, it would become evident within 12 to 16 weeks after wounding. Suppuration did not occur primarily in any case in this series during the period of hospitalization overseas, which usually was 3 months, if delayed closure had been accomplished successfully, though abscess formation was reported in all kinds of wounds as late as 4 or 5 months after the patient was evacuated to the United

States. Suppuration was probably also a hazard in closed wounds of the hip joint, but it must have been extremely infrequent, if it occurred at all. At any rate, the possibility was not regarded as a reason for disregarding the important surgical principle of delayed primary suture of war wounds.

The immediate results in these 29 cases, and the similar results in the (unpublished) series studied by Collom and Hampton,²⁷ show clearly what can be expected when thorough debridement is omitted or delayed. Even when debridement was omitted for the valid reason that men who had been submitted to major intra-abdominal surgery appeared incapable of tolerating surgery of the hip joint immediately afterward, the omission was followed by sepsis in a large proportion of cases.

It was not possible to determine in advance whether a wound of the hip joint would be contaminated in the course of intestinal surgery. On the surface, there seemed no reason why contamination should occur at this time unless there was a direct communication, either external or intrapelvic, between the two wounds. The difficulties of preventing contamination afterward when colostomy had been done have already been described.

Methods of management of suppurative arthritis in World War II included incision and drainage, resection of the femoral head, and amputation or disarticulation.

Incision and drainage.—Incision and drainage were carried out in 6 of the 9 septic cases, through a liberal anterior or anterolateral incision, or through both approaches. The wound was kept open by Penrose tubing, rubber drains, or vaseline-impregnated gauze applied to various aspects of the drainage tract. Posterior incision, which was attempted in 1 additional case, proved just as inadequate in World War II, in which it was supplemented by chemotherapy, as it had proved in World War I. In this case, the tract closed within a week, as the result of contraction of the gluteal muscles, but the joint went on to destruction, just as in the World War I experience, and a second operation was necessary to excise the head of the femur.

The following case history illustrates the stormy course which a patient with suppurative arthritis following inadequate debridement was likely to pursue.

Case 6.—An infantryman sustained penetrating wounds of the pelvis and left hip (fig. 59) from a high-explosive shell. Shortly afterward, a portion of the ileum was resected, with end-to-end anastomosis; a large laceration of the rectum was repaired; and a Mikulicz sigmoidostomy was performed. The man was in such poor condition at the end of these procedures that the wound in the left hip was merely cleansed with soap, water, and antiseptic. Other injuries included a large lacerated wound of the left calf, fractures of the right elbow, forearm, wrist, and hand, and minor lacerated wounds of the right upper extremity.

Roentgenograms (fig. 65) taken at the field hospital showed a fragment of shell, approximately 1 cm. in each dimension, lodged squarely in the middle of the body of the ischium at the point at which it forms the acetabulum. The assumption was that the fragment had penetrated the joint from the pelvis outward after lacerating the upper rectum.

²⁷ Ibid.

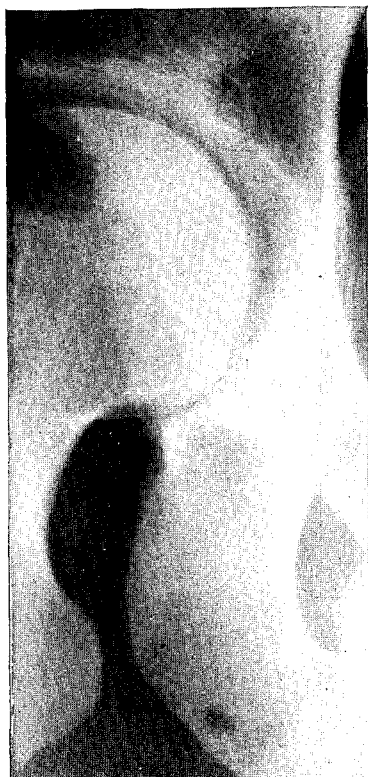

FIGURE 65 (case 6).—Roentgenogram showing fragment of 88-mm. artillery shell lodged in left anteroinferior acetabulum after traversing lower abdomen, penetrating rectum, and penetrating body of ischium. Septic arthritis, necrosis of head of femur, and luxation of hip joint followed within 3 months.

It was not possible at this time to determine which of four wounds of the hip and sacrum led down to the hip joint.

At the end of 3 weeks, the patient was nourishing well and had maintained a reasonable weight. At this time, he was evacuated to the United Kingdom, where the sigmoidostomy was closed 8 weeks later.

The management of the wounds of the hip had been unavoidable in the circumstances, and the results, as had been expected, were not satisfactory. There was no gross evidence of abscess formation, but a continuous discharge of seropurulent fluid occurred. After the patient had been evacuated from the Continent, he had considerable pain in the hip, which was intensified when he moved about in bed. The temperature rose to 101° and 102° F. each afternoon, and he was obviously toxic. Roentgenograms showed that the joint margins were becoming irregular and obscure. Drainage was instituted on the 33d day after wounding, through a posterior incision; 100 cc. of greenish-white, purulent fluid was evacuated. Culture revealed mixed organisms, chiefly *Bacterium coli* and *Bacillus proteus*.

Seven weeks after wounding, roentgenograms showed resorption of a large part of the surface of the femoral head, with erosion of the superior portion of the acetabulum. The head was beginning to rise out of the joint. By the 18th week after wounding, drainage had ceased, and all the wounds in the region of the hip had healed by secondary intention. Roentgenograms at this time showed further resorption of the femoral head, with definite subluxation. During the maneuvers necessary for securing the last set of films, the foreign body, which had been present in the hip joint in all previous roentgenograms, apparently migrated into the pelvis from its original bed. Active motion consisted of 50 degrees of flexion and 15 degrees of abduction and adduction, with limitation of rotation in both directions.

At the end of 6 months, because of complications related to the abdominal wounds and the additional surgery which they had required, this patient was still on full bed rest. He had received sulfadiazine for 3 weeks and penicillin for 8 weeks after wounding.

Resection of the femoral head.—Resection of the femoral head was performed in 3 cases of suppurative arthritis, including 1 case in which incision and drainage through a posterior incision had failed to effect a cure. The operation was performed through an anterior incision in 2 cases and through a posterior incision, derived from enlargement of the original wound, in the third. Opinions differed as to the relative value of these two incisions in military surgery. In World War I,²⁸ United States Army surgeons preferred the posterior route, while British²⁹ and Continental³⁰ surgeons preferred the anterior incision. In World War II, posterolateral and lateral incisions were also used for resection of the femoral head.

This operation was first performed for pyoarthrosis during the wars of the 19th century. It has naturally become a safer procedure as time has passed, but even when the case fatality rate was prohibitively high, there was universal agreement as to its value. Its prompt employment is amply justified for a number of reasons: Whether or not reconstructive procedures are contemplated the femoral head, when it is badly damaged, is a functionless structure and a nidus of infection, as well as a poor aid for joint fusion. After it is eliminated, drainage ceases and, when the greater trochanter has healed in traction, a functional articulation remains, which permits weight bearing and has a useful range of motion. There is resultant shortening, it is true, but this is easily remedied by an elevation of suitable height attached to the shoe. It is also true that for young men the result may not be as satisfactory in some ways as fusion of the hip joint, but it is still desirable to give resection of the femoral head a fair trial, preferably for a year or longer. If at the end of that period the outcome is not satisfactory, arthrodesis can then be performed.

In 1943, during the course of the war, Girdlestone³¹ described a technique for pyoarthrosis which permits saucerization of the entire hip joint on the lateral aspect by resection of the greater trochanter and the head of the femur, with minimum interference with muscle and minimum risk to the sciatic nerve and femoral blood vessels. Wheeler³² and Ellis³³ both reported excellent results with it, and it is perhaps unfortunate that American surgeons did not give this method more recognition and a wider trial. It seems the logical procedure in cases in which the hip joint and gluteal region are so peppered with foreign bodies that their removal is impossible and there is nothing to do but wait for exfoliation of the infected areas. Girdlestone's operation also

²⁸ See footnote 2, p. 225.

²⁹ See footnote 3, p. 226.

³⁰ (1) See footnote 25, p. 239. (2) Auvray, M.: The Immediate Results of Surgical Intervention in 111 Cases of Purulent Arthritis of the Large Articulations. *Bull. et mém. Soc. nat. de chir.* 43:683-690, 1917. In *Abstracts of War Surgery; An Abstract of War Literature of General Surgery That Has Been Published Since the Declaration of War in 1914*. Prepared by the Division of Surgery, The Surgeon General's Office. St. Louis: The C. V. Mosby Co., 1918, pp. 304-305.

³¹ Girdlestone, G. R.: Acute Pyogenic Arthritis of the Hip. An Operation Giving Free Access and Effective Drainage. *Lancet* 1: 419-421, 3 April 1943.

³² See footnote 8, p. 226.

³³ See footnote 10, p. 226.

has other advantages. For one thing, it circumvents pressure by the weight of the body on the bed, which is a problem when posterior incisions are used. For another, it prevents the puddling of exudates frequently observed when anterior incisions are used. When it is employed in cases in which both the hip joint and the sciatic nerve have been destroyed by infection, it really amounts to a first-stage disarticulation of the hip joint.

Surprisingly good results, as the following case shows, are sometimes secured with resection of the femoral head.

Case 7.—An infantryman sustained a perforating wound in the region of the right hip (fig. 59) from a bullet which entered the inferior medial aspect of the right buttock and made its exit on the upper anterolateral aspect of the right thigh. Roentgenograms taken at a field hospital 3 hours later showed a comminuted fracture of the hip joint, with displacement of bone into the anterior muscles and soft parts. The wound was cleansed superficially with antiseptics, and arthrotomy was omitted.

Three days later, the wounds were debrided superficially at a general hospital in Belgium. Before the patient was evacuated to the United Kingdom Base by air, his temperature had risen to 101.6° F. (it had been 100.8° F. when he was first seen), and he had begun to complain of pain in the hip and the inner aspect of the thigh and knee. At the general hospital, a diagnosis of "acute catarrhal asthmatic bronchitis" was recorded.

The patient continued to feel and look very ill, and the temperature elevations persisted. On the 10th day after wounding, a tender, swollen, fluctuant area in the right buttock was incised, by enlarging the original wound, and about 75 cc. of greenish-white pus was evacuated. Culture showed a mixture of organisms, predominantly *Bacillus proteus* and *Bacterium coli*. Skeletal traction was instituted by means of a Kirschner wire inserted through the tibial tubercle, and the extremity was put up in a Rouvillois splint. On the 15th day after injury, the temperature was normal; the chest was clear; and the patient felt comfortable. Sulfadiazine was discontinued on the 20th day after wounding, but penicillin was continued through the 5th week.

Drainage continued to be profuse through the eighth week. Then it began to diminish, and for several days the temperature again rose to 101.8° F. daily. There was no tenderness on palpation of the buttock, but deep, rather indefinite fluctuation could be made out. When a probe was introduced into the wound, it went directly down to the bone. No active motion was possible in the joint, and attempts at passive motion, which were accompanied by considerable pain, resulted in only slight flexion.

On the 50th day after injury, exploration was carried out through an anterior iliofemoral incision. The head of the femur was found shattered into multiple fragments by fracture lines, but the pieces were well glued together and the head could be removed en masse. Several fragments of bone were found in small pools of pus in the substance of the adductor muscles anterior and medial to the joint.

Purulent drainage continued for another 3 months through the posterior incision. At the end of 6 months, the wounds were completely healed. The patient was wearing a non-weight-bearing caliper brace and had 30 percent motion in various directions in the hip joint. At the end of 28 months after the last operation, he was able to walk with a cane and had a useful range of motion. Although he suffered from some pain and instability, he preferred his present status to the possible improvement which might be accomplished by arthrodesis.

Amputation (disarticulation).—Neither amputation nor disarticulation was performed in any case in this series. Amputation was considered in 1 case, in which a series of pelvic abscesses with coxarectal fistulas developed after performance of the hip joint and rectum, but excisional surgery proved ade-

quate. In another case, however, in which the followup was indirect, the patient died 2 years after injury, of chronic sepsis and other causes. According to a local newspaper, he had had 40 operations in various hospitals in the Zone of Interior.

It may be that this man would have fared better if amputation had been performed promptly after injury. It is easy to understand the desire to be conservative in such cases, particularly if the limb distal to the injured joint is intact. There are, however, a number of arguments against this policy:

1. When there has been great mechanical destruction of the bone and soft parts and when retained foreign bodies carrying fragments of clothing cannot be removed, foci of infection are maintained for indefinite periods of time.

2. A prolonged delay before amputation merely results in exhaustion of the patient, so that, when the operation is eventually performed, it often poses a serious threat to life. Successful results are sometimes attained with late amputation, but they are by no means the rule. It must be assumed that patients with large areas of mixed, penicillin-resistant infection deteriorate every day that they live and that their chances of survival after major surgery become progressively less as time passes. All the experience of World War II was to the effect that penicillin can prevent septicemia and perhaps limit local extension of sepsis, but that it has no appreciable effect in a persistent mixed infection sown in the substance of tissue and associated with massive necrosis. Toxins are dispersed through the body, regardless of chemotherapeutic measures, and cachexia is the inevitable result and is very often fatal.

3. Amyloidosis has been reported in destructive injuries of the hip joint in which infection persisted even though drainage was satisfactory. In these cases, the patients were thought to be living in symbiosis with, or even to be slowly conquering, the local and general infection by virtue of their own immune resources. The assumption was unwarranted.

4. Observation of numerous instances of pyoarthrosis of the hip joint at United States Army amputation centers made it clear that when the sciatic nerve is lacerated the indication for early disarticulation of the hip is particularly strong.

Avascular Necrosis

Avascular necrosis is a possibility in every instance of battle-incurred injury of the hip joint. When the substance of the head of the femur has suffered a direct impact fracture, the irregularities in the bone structure and alterations in bony density suggest that this process is developing in this area, exactly as it may develop at the line of fracture of cancellous bone anywhere else in the skeleton. The difference between the reaction in the head of the femur and in joints with less intra-articular bone is quantitative, not qualitative. Another obvious reason for the appearance of avascular necrosis in injuries of the hip joint is anatomic: in adults this joint has insufficient collateral circulation in the femoral head, if indeed it has any at all, and the injury may destroy its end arteries temporarily or permanently.

Avascular necrosis occurred in 15 cases in this series. This number includes almost every instance in which the head of the femur was struck by a bullet or shell fragment, as well as some cases in which the damage was chiefly to the neck of the femur. In one or two of these cases, it seemed reasonable to speculate that both the bony injury and the loss of circulation were the result of blast or concussion from a bullet which passed through the limb.

The roentgenologic picture of avascular necrosis varied. Subchondral fractures and undisplaced fractures were sometimes so neatly contained in position in the acetabulum that they did not show up on routine roentgenograms and became apparent only at arthrotomy and debridement, or, even later, when avascular necrosis developed. In 3 cases in which the fractures were limited to the inferior portion of the femoral head, roentgenograms showed no evidence of this change until between 6 and 12 months after injury. Roentgenograms, when the condition became evident, always revealed rarefaction, resorption, and sclerosis of the head of the femur. When the fracture involved the femoral neck, stellate, incomplete fracture lines extended to the head of the bone. With healing, the roentgenograms showed increased density or patchy sclerosis. Since all of these patients were receiving penicillin in large dosages, it was often difficult to exclude the possibility of previous or controlled infection in certain cases in which resorption of parts of the femoral head had occurred. One point of distinction was that when there was clinical evidence of established suppuration, the bone substance was absorbed much more rapidly and more extensively than in clean cases. In the latter type of case, the pattern of bone rarefaction more nearly corresponded to the typical picture of creeping replacement seen in civilian fractures of the neck of the femur. In clinically clean cases, these changes appeared late. When infection was present, on the contrary, bone destruction was evident within a few weeks after injury.

In several cases, suppurative arthritis was followed by spontaneous subluxation or resorption of almost the entire femoral head. These patients were treated early, in skeletal traction, on the theory that this method supplied mechanical protection to the necrotic head during the active stages of infection. Although traction was maintained as long as possible during the period of healing and creeping replacement, the joint surfaces were almost invariably destroyed or irreversibly damaged within a period of a few weeks.

When the infection was mixed, particularly when *B. coli* was present in fractures associated with extensive necrosis of the entire head of the femur, the constitutional reaction was extremely severe, and the patients (as in case 5) deteriorated rapidly.

The following case is an excellent illustration of avascular necrosis in a compound fracture of the hip joint.

Case 8.—An infantryman, hit by a high-velocity bullet, sustained a fracture of the neck of the femur, with fissures into the head of the bone (fig. 59). The bullet entered on the lateral aspect of the left hip, perforating the joint, ischium, and pubic bones, and tearing the bladder and prostate. It then made its exit laterally below the greater trochanter on the right. The bladder was repaired and the space of Retzius drained in a field hospital

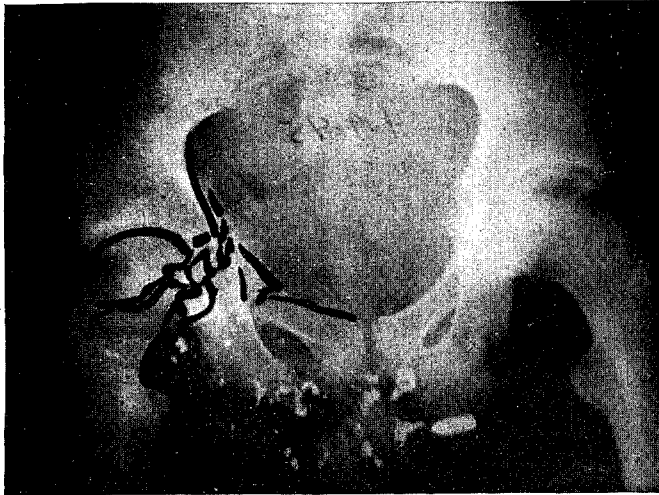


FIGURE 66 (case 8).—Roentgenogram [retouched] showing fracture of neck of femur extending into head, with associated fractures of ischial and pubic rami and coxa vara deformity.

on the same day. The wound of the hip was treated by debridement, and a hip spica was applied, in which the patient was evacuated to a general hospital, in the United Kingdom on the fifth day. Progress had been satisfactory, except for daily afternoon temperature elevations to 100.8° F.

Roentgenologic examination at the hospital in England showed a fracture of the base of the femoral neck extending up into the head, with coxa vara deformity (fig. 66). The fracture was reduced on the sixth day after injury by manipulation on a fracture table. It was then immobilized in skeletal traction with balanced suspension in the Rouvillois splint. The patient developed a urinary-tract infection which required drainage by an indwelling urethral catheter for 5 weeks. The hip joint showed no evidence of sepsis at any time and healing was satisfactory.

Roentgenologic examination 6 weeks after wounding showed the fracture of the neck of the femur in excellent position and beginning to heal. There was, however, a uniform increase in the density of the femoral head.

Two weeks later (8 weeks after injury), the patient was evacuated to the Zone of Interior in Whitman's position in a hip spica. At 6 months, he was walking in a non-weight-bearing ischial caliper brace. Two years later, although the head of the femur was nearly revitalized, the joint space was lost. The normal range of motion was limited by 50 percent, and the man was still on a total-disability pension.

Early Reconstructive Surgery

Attempts to salvage function in compound fractures of the femoral head by the use of reconstructive procedures soon after injury were not encouraged in military practice, because of the ever-present risk of actual or potential infection. In this type of case, avascular necrosis was frequent, and the tissues exposed had a minimum amount of resistance to infection. When fractures were limited to the trochanteric and subtrochanteric regions, conditions were different, and early open operation was regarded as justified if the associated

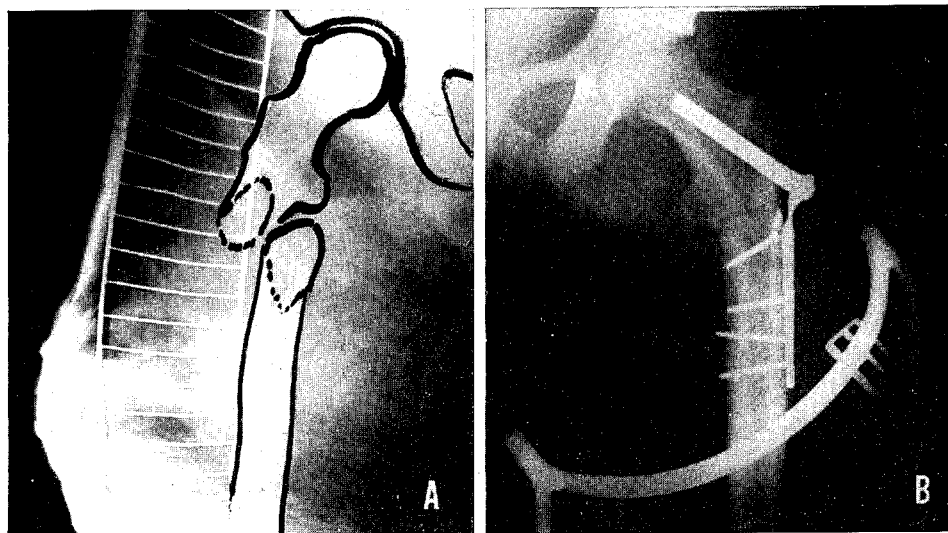


FIGURE 67 (case 9).—A. Roentgenogram [retouched] showing subtrochanteric fracture of femur caused by accidental, self-inflicted pistol shot wound. B. Roentgenogram of subtrochanteric fracture of femur shown in figure 67A, 7 weeks after wounding, 6 weeks after successful delayed primary closure of wound, and 1 week after open reduction and internal fixation with McKee nail and single transfixing screw.

soft-tissue wounds had been successfully closed by delayed primary suture. In some cases in this series, it was possible to align subtrochanteric fractures by internal rotation, 90-degree flexion, and wide abduction of the hip in skeletal traction. In other instances, however, the need for open reduction became clear soon after conservative therapy had been instituted.

This policy was followed in only 4 cases in this series, all of which were treated by internal fixation by means of a Smith-Petersen, a McKee, or a Liverpool nail 4 to 6 weeks after delayed primary suture of the wound. The McKee and Liverpool nails are basically Smith-Petersen nails with plates attached. In the Liverpool nail, ordinary plates are attached at the angle of the average neck of the femur. In the McKee nail, wide curved plates are similarly attached (fig. 67B).

In all 4 cases treated by nailing, extra-articular methods were used. When a plate was employed, it was attached at the same time, through a lateral incision. The results in these cases, in which weight bearing and approximately 90 percent of function were achieved within a year of wounding, encourage the attempt at early functional salvage by the use of reconstructive measures in carefully selected cases of fractures of the trochanteric and subtrochanteric regions.

The following case is an illustration of the good results of an early reconstructive procedure in a properly selected patient.

Case 9.—A soldier from an armored unit accidentally shot himself while returning his pistol to the holster. The bullet penetrated the anterior capsule of the left hip joint, fractur-

ing the femur below the lesser trochanter and lodging in the posterior margin of the fascia lata at the middle third of the thigh (figs. 59 and 67). Arthrotomy and debridement, with removal of the bullet, were performed in a field hospital a few hours later. Penicillin (10,000 units) was instilled into the joint at the conclusion of the operation. Five days later, delayed primary closure of the wound of the soft parts was carried out at a general hospital in the United Kingdom. The patient was then immobilized in skeletal traction in a Balkan frame by means of Kirschner wire through the tibial tubercle.

The fracture was reduced by manipulation twice within the next 3 weeks, but position could not be maintained for any length of time. Open reduction and internal fixation with the McKee nail (fig. 67B) were therefore carried out 7 weeks after wounding. Weight-bearing exercises were begun at 6 months. When the nail plate was removed a month later, the patient had 75 percent of normal motion in the joint. At 9 months, the fracture was solidly united, and disability was minimal.

An Ideal Plan of Management

The experience of World War I and World War II suggest the following routine as an ideal plan of management for battle-incurred injuries of the hip joint:

1. Initial surgery should consist of debridement, arthrotomy, exploration of the joint, irrigation if gross suppuration is not present, and primary closure of the joint if loss of substance does not prevent it.

2. The approach is preferably the anterior iliofemoral incision described by Smith-Petersen or the posterior approach described by Kocher.

3. The operation should be carried out as promptly as possible after wounding, but neither impending nor established sepsis contraindicates its delayed performance, regardless of the length of time since injury.

4. Debridement should consist of complete excision of blood clots, devitalized muscle, fatty tissue, bone fragments, foreign bodies, and other foreign material along the track of the wound. This is the general principle. In the special case, the surgeon must use his judgment in deciding how much chiseling, scraping, and curetting are necessary to secure clean, bleeding bone surfaces. In the hip joint almost more than in other areas, the wounds of the soft parts, the maceration of muscle, and the retention of shell-borne particles of clothing and other foreign material may be even more important than the articular damage. All tissue, including bone, which has no remaining circulation must be excised, to eliminate soil for infection.

5. The deeper soft parts should be closed over the joint, but the skin wound should be left open, to be closed within 4 to 10 days by delayed primary suture.

6. The extremity should be extended and suspended, preferably by skeletal traction in the Rouvillois splint, for 8 to 12 weeks.

7. Active motion should be begun in traction as early as this is practical and can be accomplished without undue risks or pain.

8. In cases in which sepsis is established when the patient is first seen, open operation by the Smith-Petersen approach, with thorough debridement, is the method of choice. If it fails, excision of the joint by Girdlestone's

method, combined with drainage or disarticulation, should be done. The operation should not be unduly delayed if sepsis is severe, since the patient's condition deteriorates rapidly in these circumstances.

9. Whole blood should be used in liberal amounts as long as it is indicated. Other supportive measures, including measures to correct protein deficits, should also be used according to the indications.

10. Penicillin and sulfadiazine should be used parenterally before and after surgery. Local chemotherapy is not indicated. Both drugs are adjuncts to surgery, not a substitute for it.

11. In occasional carefully selected cases, reconstructive procedures with internal fixation may be employed 4 to 6 weeks after successful delayed primary suture of the wound.

CHAPTER XIX

Jeep Injuries of the Hip Joint

Marshall R. Urist, M. D.

Basic Information

This chapter is based on an analysis of 58 injuries of the hip joint originating under generally similar circumstances of military traffic. They were observed over a period of 18 months in the 802d Hospital Center in the European Theater of Operations, which, over the same period, admitted approximately 25,000 combat and noncombat casualties. Both before and after the institution of definitive treatment, these men, as is inevitable in time of war, were treated by various medical officers, who ranged from general practitioners trained in the emergency to handle military casualties to experienced orthopedic surgeons whose views and practices, however, were frequently at wide variance concerning the management of such injuries.

Although this series consists of only a small number of cases, they furnish an amply sufficient background for this chapter for several reasons:

1. This series includes as many instances of this type of injury as would usually be admitted to any large urban hospital over a period of 10 to 15 years.
2. No single surgeon in civilian life would be likely to have as large an experience as this in the course of a professional lifetime.
3. It is possible to derive from a detailed clinical analysis of these cases enough material for an evaluation of the teachings and practices concerning these injuries when the United States entered World War II. There was then no uniform teaching concerning them, and no Army directives for their management were issued.
4. Because of the many different medical officers who participated in one phase or another of the treatment of these casualties, the series is of historic interest and may be accepted as an overall picture of the management of traffic injuries of the hip in World War II.

Classification

For convenience of analysis, these 58 cases have been divided into 3 groups (tables 11 through 15), as follows: (1) Dislocations of the hip joint (15 cases); (2) fractures of the acetabulum without dislocations (16 cases); and (3) fracture-dislocations of the hip joint (27 cases). The dislocations, in effect, serve as a control group for the fracture-dislocations, while the fractures of the acetabulum similarly serve as a control group for the injuries to the articular surfaces in the group of fracture-dislocations.

These three groups of cases have been analyzed from a variety of points of

view, with particular emphasis on the nature of the traumatic lesion, methods of treatment, complications, and followup studies. Followup reports were obtained in various ways, including personal examinations, letters and roentgenograms submitted by patients and their local physicians, and reports of examinations in Army and veterans' hospitals.

The end results in these 58 military injuries were compared with the end results of 18 similar injuries sustained in civil life and treated at the Massachusetts General Hospital. The rarity of this type of injury in civilian practice is evident in the fact that these 18 cases represent a 12- to 16-year experience in a thousand-bed civilian hospital.

Circumstances of Injury

All of these casualties sustained their injuries in traffic accidents, and 40 of the 58 received them while they were riding in jeeps. Curiously, although jeeps were used in all theaters of operations, the impression was gained from communications with other orthopedic surgeons working in other theaters that this type of injury was frequent only in the European theater. This is perhaps to be explained by the excellent concrete highways which are a part of the European scene but which are less frequent or nonexistent in other parts of the world. These highways permitted and encouraged travel at high rates of speed and help to explain the high incidence of traffic injuries in this theater.

Other contributing factors were also operative. The excitement and recklessness of men at war, most of whom were young men, were responsible for a high incidence of all types of severe injury. In this series, one patient was 51 years of age, but all the others were between 19 and 33 years, the period of life in which trauma always exacts its greatest toll.

Soldiers were constantly involved in accidents in trucks, tanks, and other types of mechanized motor vehicles, under conditions which seemed just as hazardous as those which prevailed when they were riding in jeeps. Nonetheless, the fact that the jeep was the most commonly used of all Army vehicles cannot be overlooked as an explanation of the relatively high incidence of the special injuries to be discussed in this section, particularly the dislocations, which were present in 42 of the 58 cases.

The United States Army truck, one-fourth ton, more popularly called the jeep, seemed to possess special structural characteristics which put its riders into a favorable anatomic position for the production of this special type of injury. A review of recorded experimental studies, beginning with Allis'¹ in 1896 and Bigelow's² in 1900, shows that it provided the exact conditions necessary for the production of dislocations of the hip joint (fig. 68). It is constructed like an old-fashioned wagon, with a minimum of protective framework, and passengers readily fall out of it. Its seats are so low that when passengers are seated their hips are flexed more acutely than in other automobiles.

¹ Allis, Oscar H.: *An Inquiry Into the Difficulties Encountered in the Reduction of Dislocations of the Hip*. Philadelphia: Dornan, Printer, 1896, pp. 45-61, 91-103.

² Bigelow, Henry J.: *The Mechanism of Dislocation and Fracture of the Hip*. Boston: Little, Brown and Company, 1900, pp. 1-16.




FIGURE 68.—Artist's interpretation of patients' positions and attitudes at time of injury, derived from their own descriptions. The accident was most often a head-on collision. A. A rider in this position could fall out, striking the pelvis and incurring a fracture-dislocation or a fracture. B. A rider sitting with legs abducted could sustain a fracture of the acetabulum or a fracture-dislocation from a dashboard blow on the knee. C. A rider sitting with hips acutely flexed and adducted could sustain a dislocation of the head of the femur with minimal damage to the bony rim of the acetabulum.

While the riders are in this position, the head of the femur is in internal rotation, directed posteriorly and disposed toward posterior dislocation. The instrument board, or the back of the front seat, depending upon where the rider is sitting, is so close to his flexed knees that in case of accident it is difficult to avoid the so-called dashboard type of blow, which has become a classical injury in this modern mechanized age. There seems no doubt, therefore, that the jeep, because of its special structure, must be assumed to be primarily responsible for the appearance of as many dislocations of the hip over an 18-month period in military experience as would occur over a 10-year period, or longer, in civilian practice.

Anatomic Considerations

Fractures and fracture-dislocations of the acetabulum cannot be properly discussed, any more than they can be properly evaluated and treated, without a recollection of certain anatomic considerations. The acetabulum, viewed from within the joint cavity, consists of a semilunar or horseshoe-shaped platform of bone covered with articular cartilage. This platform, which is the weight-bearing surface, is formed mainly from the body of the ischium, which receives the attachment of the posterior capsule of the hip joint on its outer surface, several millimeters from the edge and well separated from, and proximal to, the cotyloid ligament.

The anterior portion of the horseshoe, which is formed from the body of the pubis, is about half as wide as the superior portion. The capsule on the anterior, superior, and inferior aspects is attached close to the edge of the rim, in contrast to its attachment on the posterior aspect, and blends closely with the fibers of the cotyloid ligament. Only areolar and synovial tissue covers the central portion of the acetabulum.

The integrity of the posterior rim of the acetabulum is essential for the stability of the joint. The rim of the anterior portion may be excised, as in arthroplastic operations, without any serious harm to the weight-bearing function, but the superior shelving portion, which is the thickest part of the innominate bone, is also vital if function is to be preserved.

The retinacula are three flattened bands of loose fibrous tissue which are covered with synovial membrane and which lie partly within and partly outside the reflected capsule on the inferior, posteroinferior, and posterosuperior aspects of the joint. They contain many blood vessels and serve literally as aqueducts in that they carry the blood supply to the head of the femur from the numerous branches of the medial femoral circumflex vessels in the intertrochanteric region. They pass through the superior and inferior pads of fat at the margin of the articular cartilage and form a great many of the terminal arterial branches to the head of the femur. A plexus of veins which drain the superior capital epiphysis is also found in the retinacula. The clinical importance of the retinacula, which is considerable, is frequently overlooked in injuries of the hip joint (pp. 275, 293).

Dislocations

Nature of the Lesion

As has already been pointed out, the hips of the rider in a jeep are flexed more acutely than in any other type of car, because jeep seats are so low. In this position, the head of the femur is in internal rotation, directed posteriorly and disposed toward posterior dislocation. Trauma could be received by the greater trochanter or transmitted through the femur from the knee flexed against the dashboard, or from the foot on the floorboard, or could be received posteriorly and transmitted to the hip by the sacrum. Cases have been recorded of injuries received under all of these conditions. Specific inquiries into

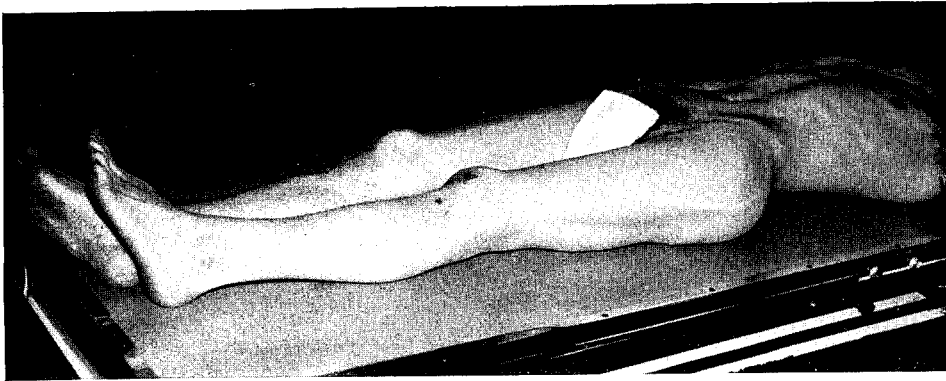


FIGURE 69.—Typical posterior dislocation of hip as result of jeep accident. Note unequal length of legs, internal rotation of knee, and adduction of hip on affected side. Note also severe bruises in both prepatellar regions.

the circumstances of injury in this series showed that in many instances the head left the joint with minimal damage to the bony structure when the hip was adducted and flexed, as it is when a man is riding in a jeep, perhaps with his legs crossed. The result in these cases was an ordinary dislocation without a gross fracture (table 11).

Traumatic lesions of the soft parts were evident in many of these cases (fig. 69), but otherwise, since the method of treatment was always closed manipulation, there were no opportunities for direct observation of the damage caused to the joint structures by the dislocations. From the standpoint of accumulation of knowledge this was unfortunate. Observations in fresh injuries might have supplied information which would indicate why some dislocations are followed by avascular necrosis of the head of the femur while others are not.

Roentgenologic studies, however, supplied information which, combined with accumulated experience with experimental dislocations, seems significant and relevant. These observations were as follows:

1. Prereduction roentgenograms revealed serrations of the rim or avulsion-chip fractures in three cases (fig. 70, case 11; cases 2 and 6). The location of these injuries suggested that the joint capsule might have been torn away at its acetabular attachment. Avulsion fractures in the posterior intertrochanteric region in two other cases (fig. 71, case 7; case 9) indicated that the femoral attachment of the capsule was torn. Allis³ described both of these capsular lesions in his experimental study of dislocations, but further investigation is needed to clarify the pathologic process. The location of the capsular tear may play some role in the damage suffered by the local blood supply, especially by the branches of the medial circumflex femoral artery which enter the hip joint in the intertrochanteric area posteriorly, and may explain the later development of avascular necrosis of the bony structures.

³ See footnote 1, p. 252.

TABLE 11.—Dislocations of hip joint without significant fractures

Case No.	Age	Fractures (X-ray)	Other injuries of ipsilateral extremity	Traction Weeks	Weight bearing Months after injury	2-year results
1	21	None	Contusion, knee	5	4	Pain.
2	20	Serration, posterior rim		6	(1)	Do.
3	27	None	Contusion, knee; dislocation, patella	5	3	Unknown.
4	27	do	Fracture, patella; posterior dislocation, knee	8	4	Pain.
5	21	do			2	Unknown.
6	20	Serration, posterior rim	Lacerated wound, knee	8	3	Do.
7	51	Avulsion-chip, femur	Fracture, upper tibia, fibula, and patella; posterior dislocation, knee.	12	6	Do.
8	33	None	Dislocation, midtarsus	8	4	Pain.
9	20	Avulsion-chip, femur		8	2	Night pain.
10	25	None		6	(1)	Unknown.
11	24	Avulsion-chip, inferior rim		8	3	Do.
12	20	None	Lacerated wound, knee	4	4	Good.
13	20	Undisplaced, incomplete rim		8	3	Do.
14	21			8	3	Unknown.
15	19	Pubic symphysis	Lacerated wound, knee	5	(1)	Do.

¹ Unknown.

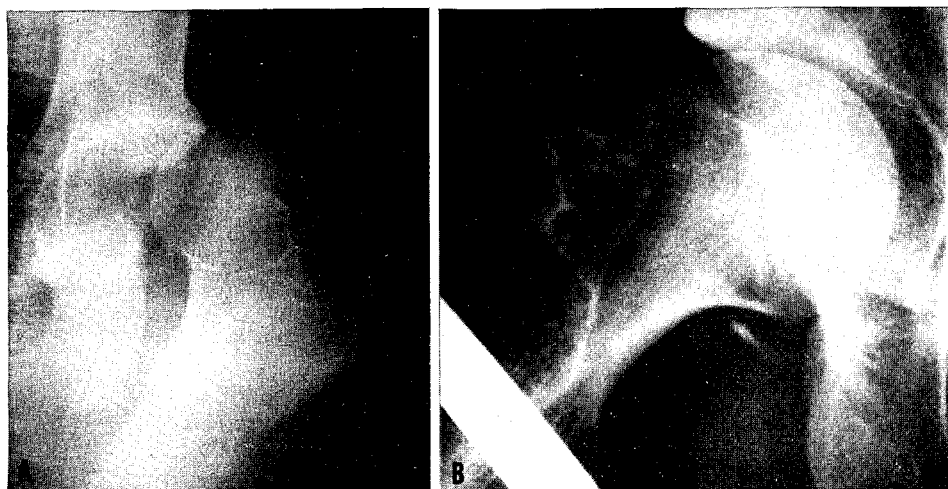


FIGURE 70 (case 11).—A. Emergency postero-oblique roentgenogram showing posterior dislocation of hip joint. Film is of average quality for roentgenograms made under field conditions. In these circumstances, bone detail was often lacking, and minor fractures were not suspected. B. Anteroposterior roentgenogram of posterior dislocation shown in figure 70A after manipulation and reduction of dislocation by Stimson's maneuver. Note improvement in quality of film (made in fixed hospital), which now reveals avulsion-chip fracture, probably of posteroinferior rim of acetabulum. The acetabular attachment of the joint capsule has presumably been torn away.

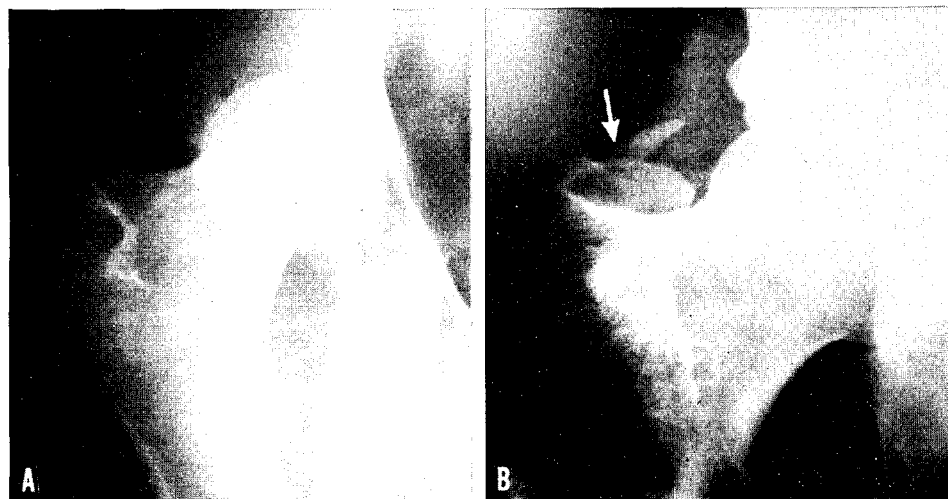


FIGURE 71 (case 7).—A. Emergency postero-oblique roentgenogram showing posterior dislocation of hip joint, with possible fracture of femur. B. Anteroposterior roentgenogram of posterior dislocation shown in figure 71A after manipulation and reduction by Stimson's maneuver. Improvement in the quality of the film now permits the demonstration of an avulsion fracture of the superior portion of the intertrochanteric ridge, in the line of the femoral attachment of the joint capsule posteriorly.

2. Prereduction and postreduction roentgenograms also revealed other minor fractures in the form of incomplete fissures of the posterior acetabular rim. There were, in fact, only 8 of the 42 dislocations and fracture-dislocations in which there was no roentgenologic evidence whatsoever of bony damage. Since roentgenograms of the hip joint usually show only gross defects, it seems reasonable to assume that even in these 8 cases there was some damage to the rim of the acetabulum and the head of the femur and to assume, further, that a fracture, which may be major or minor, is an almost invariable accompaniment of a dislocation of the hip joint.

Dollinger's⁴ description of the traumatic lesion in 12 instances of inveterate dislocation of the hip joint managed by surgery, although it was published in 1911, still remains the most complete on record. In these cases, tears were found in all the posterior muscles, including the quadratus femoris. A few other notes on findings at operation for irreducible dislocations and a few autopsy observations, all in the older literature, suggest that in these injuries the head of the femur most often escapes between the piriformis and obturator internus and then tears the fragile gemelli muscles. When it finally comes to rest, the more durable obturator tendons are stretched over and under the protruding femoral neck. Damage to the intertrochanteric attachment of the posterior capsule at the insertion of these muscles, the point at which the largest part of the blood supply enters the hip, seems never to have been described. Yet avulsion fractures are repeatedly observed in this region in postreduction roentgenograms and furnish proof that the damage exists and that the fractures should be searched for, by repeated roentgenograms, if they are not immediately evident.

Before the era of roentgenology, there were a number of elaborate pathologic classifications of traumatic dislocations of the hip, all based on the position of the head of the femur as determined by the position of the lower extremity. Clinical diagnosis was made on the same basis. The advent of roentgenologic examination made it clear that many of the types of injury described were chiefly theoretic possibilities, and that the only really important consideration is whether the dislocated head lies anterior or posterior to the acetabulum.

Posterior dislocations (Bigelow's regular dislocations) are the most frequent variety. They were present in 14 of the 15 cases in this series. When no fracture occurs in a posterior dislocation, the head of the femur probably does not displace farther than just over the rim of the acetabulum, which was its position in all 14 cases in this series. In the single anterior dislocation, the head rested opposite the obturator foramen, but its position could not be determined by rectal examination. There were no instances in the series of Bigelow's irregular dislocations in which the head of the femur is displaced into the scrotum or is found in other bizarre locations.

A case reported by Kleinberg⁵ in 1923 suggests that the excursion of the

⁴ Dollinger, J.: Die veralteten traumatischen Verrenkungen der Schulter, des Ellenbogens und der Hüfte. *Erg. Chir. Orthop.* 3: 83-194, 1911.

⁵ Kleinberg, S.: Fracture of the Acetabulum With Central Luxation of the Hip. *Ann. Surg.* 78: 806-813, December 1923.

head may be less than the length of the ligamentum teres, which may not be torn if the head escapes by way of the cotyloid notch. This possibility is easily verified by a fresh anatomic preparation of a hip joint after circumcision of the capsule. In most of the cases (fracture-dislocations) in this series which were examined at open operation, this was not true. The ligamentum teres was stretched and was partially torn if not completely severed.

There were no instances of bilateral dislocation of the hip in the series. There was also no apparent damage to the vascular structures of the joint capsule in any of the 15 cases. Theoretically, this variety of damage would occur only in dislocations and fracture-dislocations.

Management

First aid and transportation.—First aid was well handled in all 15 cases. The clinical picture is so striking in this condition, and the deformity (fig. 69) is so obvious, that most of the dislocations were promptly diagnosed in battalion aid stations and field hospitals. In most instances, preventive treatment for shock was instituted, and the leg was bandaged to the litter or the patient was otherwise protected against further trauma until an installation in the rear was reached. In one or two cases, a Thomas splint was used for immobilization. Six patients had severe injuries, which of themselves required immobilization, of other parts of the ipsilateral extremity.

Reduction.—Although the records are not complete in all respects and it is not clear in some cases how many attempts at reduction were made or how long a time they took, considerable information is still available on these points. In 1 instance, spontaneous reduction occurred, without anesthesia; this patient, who had sustained injuries of all 4 extremities, was in shock. In 1 instance, the first attempt at reduction was unsuccessful, and a second surgeon later accomplished it. In 12 of the remaining 13 cases only Pentothal Sodium (thiopental sodium) was used for anesthesia, which suggests that reduction was accomplished without special difficulty, in spite of the relative inexperience of most of the surgeons who were obliged to undertake it.

In some cases, reduction was accomplished by gravity alone after the joint had been properly flexed and relaxation obtained under anesthesia. The records indicate that 5 posterior dislocations were successfully reduced at the first attempt by Stimson's maneuver, which was also employed secondarily in 2 other cases, after the Bigelow method of circumduction and the Allis supine method had failed. The technique was not difficult if Stimson's description was closely followed: nothing was done until the muscles were fully relaxed under anesthesia. Then, with the patient prone, the thigh was rocked slightly to and fro to accomplish gentle internal and external rotation. The weight of the hanging limb, supplemented by slight downward pressure on the upper posterior tibia, supplied the needed traction. In every instance in which this method was used, the head of the femur promptly slid down in the acetabulum.

The single anterior dislocation was easily reduced, with the patient supine, by the reverse circumduction method of Bigelow. The essential feature of the

circumduction technique is flexion of the hip to relax the Y-ligament, which then can be used as a fulcrum. Bigelow's post mortem studies showed that this ligament is usually intact in posterior dislocations. After his demonstration of this method, traction, which had been regularly employed up to that time, came to be regarded as unnecessary and actually harmful.

However it was brought about, dislocation of the hip joint furnished no particular difficulties in reduction if there were no obstacles in the pathway of the displaced femoral head and if the acetabulum had not been distorted. As this series demonstrates, Stimson's method, or some one of its variants, is the simplest and gentlest method of obtaining traction by manipulation. The satisfactory results achieved by it, as this series also demonstrates, suggest that inexperienced surgeons would always do well to use it in preference to any other technique. Experienced orthopedic surgeons naturally based their procedures in the special case on the clinical and roentgenologic findings and did not adhere to any standardized technique. The modifications of the Allis and Bigelow methods are not well known and most of them were not tested in World War II.

Immobilization.—When these patients were received at general hospitals, at periods varying from a few hours to 10 days after injury and reduction of the dislocation, it was found that a variety of methods had been used to immobilize them during transportation from evacuation hospitals. Five, chiefly those who had suffered fractures and other injuries of distal joints of the injured extremity, were evacuated in plaster-of-paris hip spicas. One patient was transported with his legs bound together in a swathe. The others were not immobilized by any special methods but were required to maintain complete recumbency.

Definitive treatment.—Treatment at general hospitals was limited to traction, in the form of (1) skin traction, accomplished by bilateral Buck's extension or Russell's suspension, or (2) vertical skeletal traction, accomplished by means of a Kirschner wire through the tibial tubercle, with 10 pounds' pull. Traction was continued from 4 to 8 weeks. The optimum time would seem to be 6 weeks, which is the period theoretically required for complete healing of the joint capsule and its ligaments. The wide variation in this series was not intentional but was unavoidable because of irregularities in the evacuation schedule caused, in turn, by the weather and the tactical situation in the theater. Every patient with a dislocation of the hip was a candidate for evacuation; treatment was necessary for at least a year after injury, and often longer, which far transcended the holding period permitted for the theater.

Traction was employed arbitrarily in the management of these cases because it seemed logical. In view of the complications which could arise from injury to the vascular structures of the joint and which, at least theoretically, could be avoided by maintenance of the circulation and healing of the blood vessels, rest in traction seemed highly desirable. The literature,

however, offers no evidence to support this point of view and supplies no control studies. At the start of the war, methods recommended for the management of dislocations of the hip varied widely, as follows: That the limb be immobilized in a hip spica for 2 to 4 weeks; that traction be applied for 2 to 4 weeks; and that the patient be kept at bed rest but otherwise be permitted complete freedom of motion. There is no evidence that any of these methods, including the techniques of traction used in this military series of injuries, is superior to any other method.

Weight bearing.—All patients, when they were evacuated to the Zone of Interior, were instructed not to put weight on the injured extremity until at least 6 months after injury without specific permission from a medical officer who had examined recent roentgenograms. They were also strongly urged not to dispense with crutches until at least 6 months had passed. They were told, in very plain words, that failure to follow these instructions might be detrimental to recovery. In about half the cases, as might have been expected, weight bearing was practiced as early as 3 months after injury, either because of the patients' own restlessness or because of advice from medical officers in Zone of Interior hospitals. Only patients with associated fractures of the knee or the foot are known to have refrained from weight bearing for 6 months or longer.

Again, the literature was of no help in formulating policy. In the reported cases, weight bearing was arbitrarily forbidden for periods ranging from 6 weeks to 6 months. Neither the cases recorded in the literature nor any cases in this series suggest that early weight bearing was harmful or that abstinence from weight bearing contributed to recovery.

Complications

Recovery was uncomplicated in every case in this series, and there were no sequelae in the immediate period of observation. Avascular necrosis and degenerative arthritis appeared in a number of cases of fracture-dislocation of the hip joint (p. 293), and whether their absence in this group of dislocations is significant or accidental it is not possible to say. The literature suggests that avascular necrosis is almost as common in simple dislocations as in fracture-dislocations, but the presence of associated fractures is frequently not mentioned, and there is some doubt, therefore, as to the validity of the observation.

Certainly, as already intimated, the absence of complications in this series cannot be attributed to the method of treatment employed, which was entirely arbitrary. The literature suggests that when these complications, as well as ossification of the joint capsule, have developed, they are symptomatically aggravated by early weight bearing. No comment is possible from the standpoint of this series.

Restriction of weight bearing is generally believed to produce disuse atrophy of the base of the neck of the femur, which accentuates the density

of the dead parts of the head and therefore aids in earlier diagnosis of avascular necrosis. Again, no comment is possible from the standpoint of this series, since disuse atrophy was not evident in any case in it.

Fractures of the Acetabulum Without Dislocation

Classification

The 16 fractures of the acetabulum (table 12) which occurred in these 58 injuries of the hip joint fall into 3 classes:

1. Fracture of the rim of the acetabulum, 5 cases, including 3 of the superior and 2 of the posterior rim.
2. Central fracture, 8 cases, including 7 of the body of the pubis and inner table of the pelvis, and 1 of the anterior rim and superior ramus of the pubis, with intrapelvic protrusion of the head of the femur.
3. Comminuted or bursting fracture, with disorganization of the entire joint cavity, 3 cases.

This classification is practical, not theoretical, and is therefore not open to the objection that is attached to the purely morphologic classifications. It takes cognizance of the morbid and roentgenologic anatomy of the region, as well as the physiologic considerations having to do with the localization of function of various parts of the acetabulum (p. 254). It also takes cognizance of therapeutic problems.

The injury in every case was of the so-called dashboard type, with consequent incongruity of the joint surfaces. As is pointed out elsewhere (p. 276):

1. Fractures limited to the anterior portion of the articular surfaces are suitable for conservative management, in traction.
2. Fractures which destroy a significant part of the superior and posterior rims of the acetabulum require open operation.
3. More extensive fractures, which destroy the entire joint surface, do not respond well to any form of treatment and usually result in great disability, frequently with associated ankylosis and degenerative arthritis (cases 29 through 31).

Nature of the Lesion

Fractures of the posterior rim of the acetabulum, of which there were 2 in this series, are not uncommon. They vary in magnitude and in the particular portion of the lunate articulate surface involved. Fractures of the superior rim, of which there were 3 in this series, are extremely uncommon, presumably because of the volume of the bone and the adaptation of the stress lines of the trabeculae in this region to the burden of the weight of almost the entire torso. In 1 instance of superior rim fracture in this series (case 18, table 12), in which open operation was required, 0.5 cm. of the full width of the articular cartilage was attached to the fragment, while the entire iliofemoral ligament was attached to the outer cortex of its rim.

The 8 fractures of the central portion of the acetabulum showed an infinite number of patterns and degrees of displacement. The single instance of intrapelvic protrusion of the head of the femur (case 28) was, like most reported cases, only partial, which was fortunate, as the highly comminuted, bursting type of fracture is almost irreparable. In the majority of reported cases, as in this case, there was a fracture of the anterior rim and body of the pubis, associated with a second fracture of the superior ramus of the pubis. This fracture acted as a hinge and was responsible for the displacement of the inner table of the pubis. In such cases, the head of the femur escapes into the fracture site (that is, the anterior portion of the acetabulum) and the vital superior and posterior lunate cartilages sustain relatively little damage.

It might be expected that intrapelvic protrusion of the femur would occur in jeep accidents. The injury can be produced experimentally and accidentally by a blow on the flexed knee transmitted to the head of the femur, and it has been reported, by Haines,⁶ during convulsions from shock therapy, possibly as the result of indirect force produced by abnormal muscle action. Most often, however, it follows a blow on the greater trochanter. The degree of abduction of the limb at the time of the accident, as well as the amount of internal and external rotation of the head of the femur, determines the pattern of the lesion and the portion of the rim of the acetabulum involved. If the head is in external rotation, a blow on the greater trochanter would drive it into the anterior portion of the acetabulum, where, as in the case in this series, intrapelvic protrusion is possible with minimal damage to the weight-bearing, lunate-shaped articular cartilage.

In each of the 3 cases (cases 29, 30, and 31) in which comminuted fractures involved all portions of the acetabulum, the joint was completely disorganized and incongruent. In 2 of these cases, there was also an associated fracture of the ipsilateral femur.

Management

Fractures of the rim of the acetabulum.—The 5 patients with fractures of the rim of the acetabulum received no treatment in forward installations other than such first-aid measures as were indicated. All were immobilized for transportation in hip spicas, in 30-degree abduction, 20-degree flexion, and neutral rotation.

The treatment employed in the fixed hospital depended upon the degree of displacement of the fracture and the size of the fragment of rim. In every case, the diagnosis had been made by emergency roentgenograms taken in field or evacuation hospitals, but repeated examinations, with more elaborate equipment, revealed further details. Postero-oblique views were particularly informative. In 2 instances the fractures were found displaced. In 2 others there was either no displacement at all or very slight displacement. In the

⁶ Haines, H. H.: An Unusual Complication of Convulsive Therapy. Fracture of an Abnormal Acetabulum (Otto pelvis). *Psychiatric Quart.* 18: 273-277, April 1944.

TABLE 12.—*Fractures of acetabulum without dislocation*

Case No.	Age	Fractures (X-ray)	Other injuries ipsilateral extremity	Treatment	Weight bearing <i>Months after injury</i>	2-year results
16	21	Undisplaced fracture, superior rim.	Lacerated wound, thigh, leg, knee.	Traction 8 weeks.	3	Normal hip; slight pain.
17	20	Slightly displaced fracture, superior rim.		do.	4	Pain and difficulty standing for long periods.
18	32	Displaced fracture, superior rim.	Hemarthrosis; lacerated wound, knee.	Open reduction, internal fixation.	5	Normal hip; occasional mild joint pains.
19	29	Widely displaced fracture, posterior and inferior rims.	Pott's fracture.	Traction 8 weeks; fracture not reduced.	4	Snapping hip, severe pain, slight limitation of motion.
20	20	do.	Fracture, patella.	Traction 8 weeks; fracture not reduced. ¹	(²)	Unknown.
21	35	Undisplaced central fracture.		Traction 6 weeks.	6	Normal joint.
22	24	do.		Bed rest 3 weeks.	3	Normal motion joint, slight pain and clicking.
23	26	do.	Severe contusion, knee.	Traction 8 weeks.	(²)	Unknown.
24	21	do.	Lacerated wound, knee.	do.	3	Normal motion, slight pain; unable to lift heavy objects.
25	42	Displaced central fracture.		do.	5	Normal joint.
26	22	do.	Fracture, patella.	do.	6	Normal motion, joint pains, difficulty on standing for long periods.
27	29	do.		do.	(²)	Unknown.
28	39	Central fracture, fracture body and descending ramus pubis, intrapelvic protrusion, femoral head.		Lateral and longitudinal traction 8 weeks.	4	Do.

29	Comminuted fracture, displacement all parts and superior and posterior rims. ³	Fracture, midshaft femur.	Traction 8 weeks.	9	Severe pain, ankylosis.
30	do ³	Compound fracture, upper third femur.	Traction 12 weeks.	18	Do.
31	Comminuted fracture, displacement all parts and superior and posterior rims. Multiple bilateral fractures pelvic ring. ⁴	do	do	4	Do.

¹ This patient had no treatment for 2 months, while he was a prisoner of war.

² Not known.

³ Injury of kidney, persistent hematuria.

⁴ Suprapubic cystostomy required for laceration of posterior urethra. Crushing injury of testicle required extirpation.

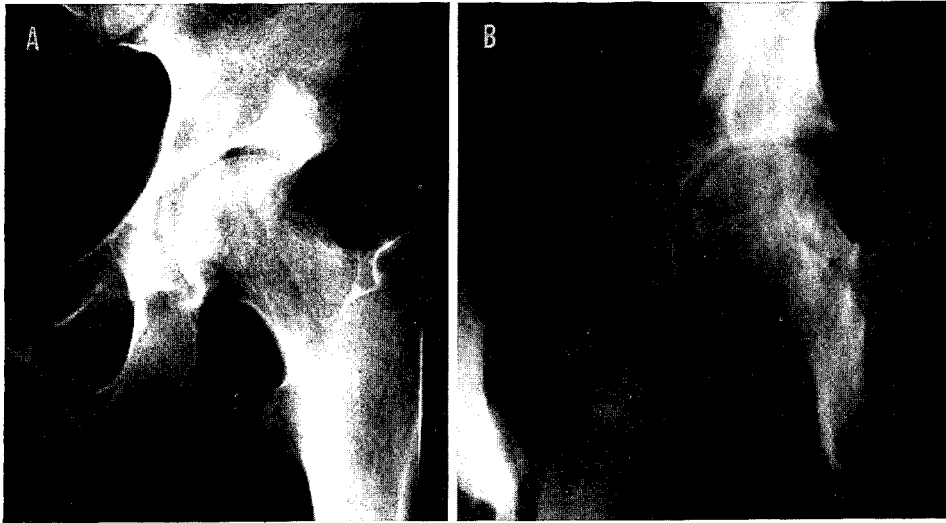


FIGURE 72 (case 19).—A. Anteroposterior roentgenogram showing fracture of posterior rim of acetabulum shortly after injury. In this view, the displacement of the fracture does not seem significant. B. Postero-oblique roentgenogram of fracture shown in figure 72A, showing displacement. When the hip was examined in flexion in this case, the joint was stable, but little more than half of the original lunate cartilage of the acetabulum articulated with the head of the femur.

remaining case (fig. 72, case 19) the patient had been a prisoner of war, and the existence of the displacement was not realized until 6 weeks after injury because of failure of enemy surgeons to study the important postero-oblique roentgenogram.

Four of the 5 patients with fractures of the rim of the acetabulum (cases 16, 17, 19, and 20) were treated conservatively, in traction suspension, for periods varying from 3 to 8 weeks, the duration of traction depending upon the extent of the lesion. Operative treatment would have been desirable, because of the extent of the displacement, in 1 of these cases (case 20), but it was contraindicated because of serious head and chest injuries.

Open reduction and internal fixation were carried out primarily in the remaining case (fig. 73, case 18) because a vital portion of the acetabulum had been injured. The anterior iliofemoral approach, which gave excellent exposure, revealed the joint capsule in the sulcus between the sartorius, tensor fascia femoris, and rectus femoris. After irrigation and curettage, to remove the blood and blood clots which obscured the fracture lines, it was possible to return the main fragment to its normal anatomic position, with its attachments to the capsule and anterior iliofemoral ligament intact. The surgical approach did not permit the insertion of the transfixing screw, and a lateral stab wound was therefore made in the gluteus medius, large enough to permit the introduction of a long drill-point screw driver at right angles to the middle of the fracture line. The parts dovetailed perfectly, and the fragment could be

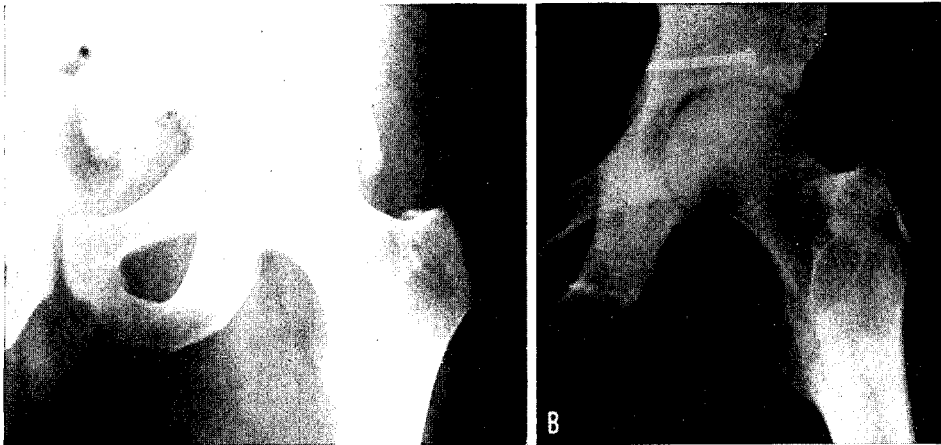


FIGURE 73 (case 18).—A. Anteroposterior roentgenogram showing fracture of superoposterior rim of acetabulum before joint repair. B. Anteroposterior roentgenogram showing fracture shown in figure 73A a week after anatomic repair of joint surface and internal fixation of fracture. Note that screw penetrates inner table of pelvis; if it does not, immobilization of the fragment will not be reliable.

compressed into position so accurately that the fracture line was scarcely visible in the postoperative roentgenogram (fig. 73B). Since the superior rim is the strongest part of the acetabulum, fractures in it are correspondingly uncommon, and it is not surprising that no case similar to this one seems to be on record in the literature.

Central fractures of the acetabulum.—The 8 patients with central fractures of the acetabulum received only necessary first-aid measures in forward installations. All were immobilized in either a Thomas splint or a plaster spica, with the joint in neutral position. A second roentgenologic examination at the fixed hospital revealed that in 4 fractures there was no displacement. In 3, all involving the dome of the acetabulum, the inner table of the pelvis was displaced for a distance about equal to the width of the cortex. The remaining fracture (fig. 74, case 28) was, as already noted, a typical fracture of the anterior acetabulum and body of the pubis, with intrapelvic protrusion of the femoral head and wide displacement of the inner table of the pelvis.

All 8 patients in this group were treated conservatively, by suspension and skeletal traction, for 6 to 8 weeks. The fracture complicated by intrapelvic protrusion of the head of the femur required special management. Reduction was accomplished by means of a vertical Kirschner wire placed just inside the lateral cortex of the trochanter. The head of the femur was then restored to its normal relationship with the rim of the acetabulum by the use of the large-sized wire-tautening spreader. The hip was suspended in a Balkan frame with 5 pounds' lateral traction and 10 pounds' bilateral skin traction through the lower extremities. The ipsilateral side of the bed was elevated slightly to provide lateral countertraction. Suspension traction was maintained for 8

weeks. The failure of the fragments to follow the femoral head after its extraction (fig. 74B) was not unexpected; this observation has been made in almost every case recorded in the literature. The displacement of the inner table of the cortex was not modified by the technique employed, but the fracture site and the anterior portion of the joint had been filled in with abundant callus and healed with the formation of new bone and fibrocartilage before the patient was evacuated to the Zone of Interior, 4 months after wounding.

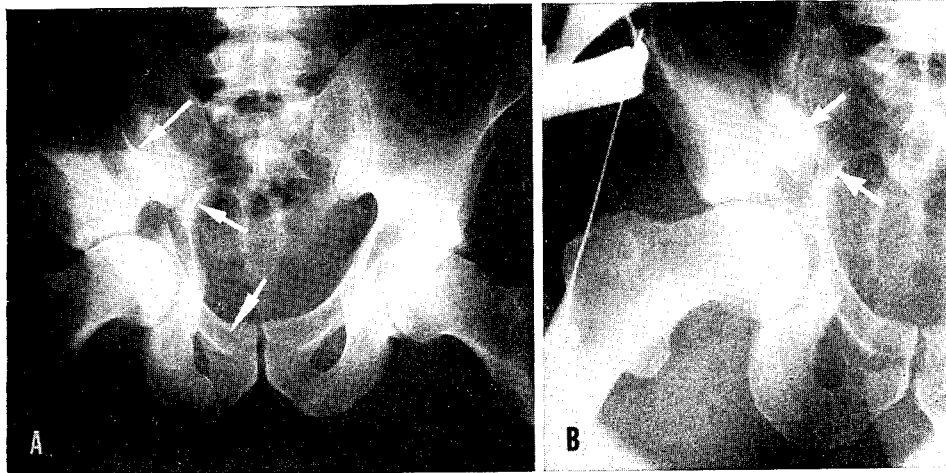


FIGURE 74 (case 28).—A. Anteroposterior roentgenogram showing central fracture of acetabulum with intrapelvic displacement of anterior acetabular rim and inner table of pelvis. Lowest arrow shows how the fracture of the superior ramus of the pubis acts as a hinge and causes displacement of the inner pelvic table. Other arrows indicate the main fragments. B. Anteroposterior roentgenogram of fracture shown in figure 74A after withdrawal of head of femur from fracture site by lateral skeletal traction through a vertical Kirschner wire in the greater trochanter. In this type of fracture, the main fragments of the fracture do not follow the femoral head.

Extensive comminuted fractures of the entire acetabulum.—The emergency management of the 3 patients with extensive comminuted fractures of the entire acetabulum (cases 29, 30, and 31) was limited to measures to forestall shock. They were evacuated from the combat zone as promptly as possible, with the limbs immobilized in hip spicas in slight abduction.

Definitive treatment was conservative, by traction, in all 3 cases. Skeletal traction by means of a Kirschner wire through the supracondylar region brought the fractures of the shaft of the femur into alinement but had little effect upon the fractures of the acetabulum. It was realistically assumed, from the time these patients were first examined, that arthroplasty or fusion of the joint would be necessary at a later date in Zone of Interior hospitals. In each case, at the time of the 2-year followup, the joint was ankylosed and painful.

Fracture-Dislocations

Classification

The 27 cases of fracture-dislocation in these 58 chiefly jeep injuries of the hip joint fall into 3 groups when they are classified according to the standard textbook categories:

1. Fifteen cases of posterior dislocation, with fractures of the posterior rim of the acetabulum (table 13).
2. Eight cases of fracture-dislocation of various types, with the common denominator of irreducibility by closed manipulation (table 14).
3. Four cases of posterior dislocation associated with fracture of the head of the femur (table 15).

Nature of the Lesion

The necessity of performing open operation in 15 of the 27 fracture-dislocations in this group of cases provided opportunities for direct examination of the traumatic lesion from both the anterior and the posterior aspect of the hip joint. The description which follows is based upon the observations made at operation:

The major damage was sustained by the acetabulum, periarticular ligaments, tendons and muscles, ligamentum teres, and retinacula of the joint (figs. 75 and 76).

Damage to the acetabulum could be assumed to represent the first stage of a fracture-dislocation of the hip joint. It was particularly likely to occur if the hip was in abduction and the knee was flexed, so that the knee received the full force of the dashboard blow and transmitted it proximally to the acetabulum. The second stage of the injury, the excursion of the head of the femur, explained the tearing of the soft parts of the joint and the laceration of the periarticular structures.

Damage to the posterior rim of the acetabulum ranged in magnitude from insignificant bruises or chip fractures, which can be assumed to be present in practically all ordinary dislocations (p. 258), to fractures in which small fragments of the edge of the cotyloid labrum were separated and more extensive fractures, with disruption of large, crescent-shaped pieces of the articular cartilage and wide areas of the posterior and superior portions of the acetabulum associated with massive disruption of the whole width of the horseshoe-shaped articular cartilage. Since less than half of the head of the femur normally lies outside the bony acetabulum, the integrity of the posterior and superior portions of the rim appeared to be of increased importance to the stability of the hip after many of the supporting structures in the capsule had been ruptured.

Small fragments from the edge of the rim of the acetabulum usually contained little or no articular cartilage but were coated with cotyloid ligament on two sides. Frequently, they lay free in a hematoma in or around the joint cavity or were attached only by a few fibers of periosteum or ligament. Larger fragments, measuring a centimeter in diameter on one aspect or the

TABLE 13.—Fractures of posterior rim of acetabulum with reducible posterior dislocations of hip

Case No.	Age	Other injuries of ipsilateral extremity	Treatment after closed reduction; operative findings	Weight bearing Months after injury	2-year results
32	28	Fracture, upper third tibia and fibula.	Open reduction, internal fixation; 3 small bone chips removed.	9	Excellent; occasional minor pains.
33	26	-----	Open reduction, internal fixation; extensive comminuted fracture, acetabulum; large fragments replaced, small chips removed.	9	Good; occasional minor pains.
34	25	-----	Open reduction, internal fixation; large single fragment.	9	Excellent.
35	22	Contusion, knee.	do.	4	Do.
36	33	"Bumper fracture," upper tibia and fibula.	Open reduction, internal fixation; 3 large fragments comprising entire superior and posterior rims.	6	Good; occasional joint pain.
37	25	-----	Open reduction, internal fixation; large fragment replaced; 3 small fragments of inferior rim excised.	(1)	Unknown.
38	25	Supracondylar fracture, femur.	Open reduction, internal fixation; large fragment replaced.	(1)	Do.
39	24	Lacerated wound, prepatellar region.	Traction, 8 weeks; imperfection reduction (X-ray).	12	Poor; early degenerative arthritis.
40	25	Compound dislocation, tarso-metatarsal joints.	do.	10	Do.
41	25	-----	do.	(1)	Unknown.
42	25	-----	do.	(1)	Do.
43	29	Lacerated wounds, leg and knee.	do.	(1)	Do.
44	25	-----	Excision, comminuted fractures of rim; large fragment without soft-tissue attachments; corrugated articular cartilage; 3 small chips.	9	Fairly good; occasional joint pain; early degenerative changes.

45	22	Excision, comminuted fractures of rim; 3 small intra-articular fragments.	5	Fairly good; occasional joint pain.
46	19	Lacerated wounds, knee.	6	Poor; avascular necrosis, head of femur.

¹ Unknown.

TABLE 14.—*Comminuted fractures of acetabulum with irreducible dislocations of hip joint*

Case No.	Fractures (X-ray)	Other injuries of ipsilateral extremity	Definitive treatment	Chief operative findings	Complications	2-year results
1 47	Seven fragments, posterior or rim, distributed in and around joint.	Lacerated wound, knee.	Arthrotomy, anterior iliofemoral approach; fragments excised.	Minor subchondral compression fractures, head femur.	Sciatic neuritis.	Poor; painful hip.
2 48	Four fragments, posterior rim, folded into joint.	Severe contusion, knee.	do	Posterior soft parts macerated and torn.	None.	Fairly good.
1 49	One large and three small fragments in and around joint.		do	Massive hemorrhage into reflected capsule, hip joint.	Avascular necrosis, collapse head femur.	Poor; arthrodosis.
2 50	Multiple fractures, acetabulum and pelvis.	Contusion, injury knee.	Vertical skeletal traction.		Peroneal palsy; edema recum.	Do.
1 51	do	Fracture, patella.	None.		do	Death, head injury. Massive retroperitoneal and subdiaphragmatic hemorrhage found at autopsy.
2 52	Multiple fractures, acetabulum and pelvis; separation of symphysis pubis.	Severe contusions, hemorrhosis, both knees.	Vertical skeletal traction.		Peroneal palsy. Edema rectum. Traumatic stricture posterior urethra. Hematuria.	Poor; arthrodosis.
2 53	do	do	Open reduction, anterior iliofemoral approach; vertical skeletal traction.		Extensive ossification all periarthicular soft parts.	Poor; Vitallium cup arthroplasty.
1 54	Displacement, inferior and posterior rims across acetabular fossa.	Avulsion and ischemic slough, skin, dorsum of leg.	Open reduction, internal fixation, posterior approach.	Inferior rim and superior ramus ischium formed single large fragment, displaced toward and obliterating acetabulum.	Peroneal palsy; thrombophlebitis.	Unknown.

¹ Two unsuccessful closed manipulations.

² Three unsuccessful closed manipulations.

TABLE 15.—Fractures of head of femur with posterior dislocation of hip joint

Case No.	Age	Fractures (X-ray)	Other injuries of ipsi-lateral extremity	Definitive treatment	Weight bearing <i>Months after injury</i>	Complications	2-year results
55	25	Avulsion fracture, inferior head; fragment attached to ligamentum teres.	Posterior dislocation, knee.	Reduction; traction, 8 weeks.	12	None	Good; occasional minor pain.
56	25	Slightly displaced, extensive, impacted fracture, entire head.		do	6	Degenerative arthritis.	Fair; painful hip.
57	25	Slightly displaced, extensive, impacted fracture, entire head; inferior portion impinged on anterior rim, acetabulum.		Arthrotomy, anterior iliofemoral approach; resection anterior inferior head.	6	do	Do.
58	25	do	Fracture, patella	Traction, 8 weeks	5	do	Poor; severe pain.

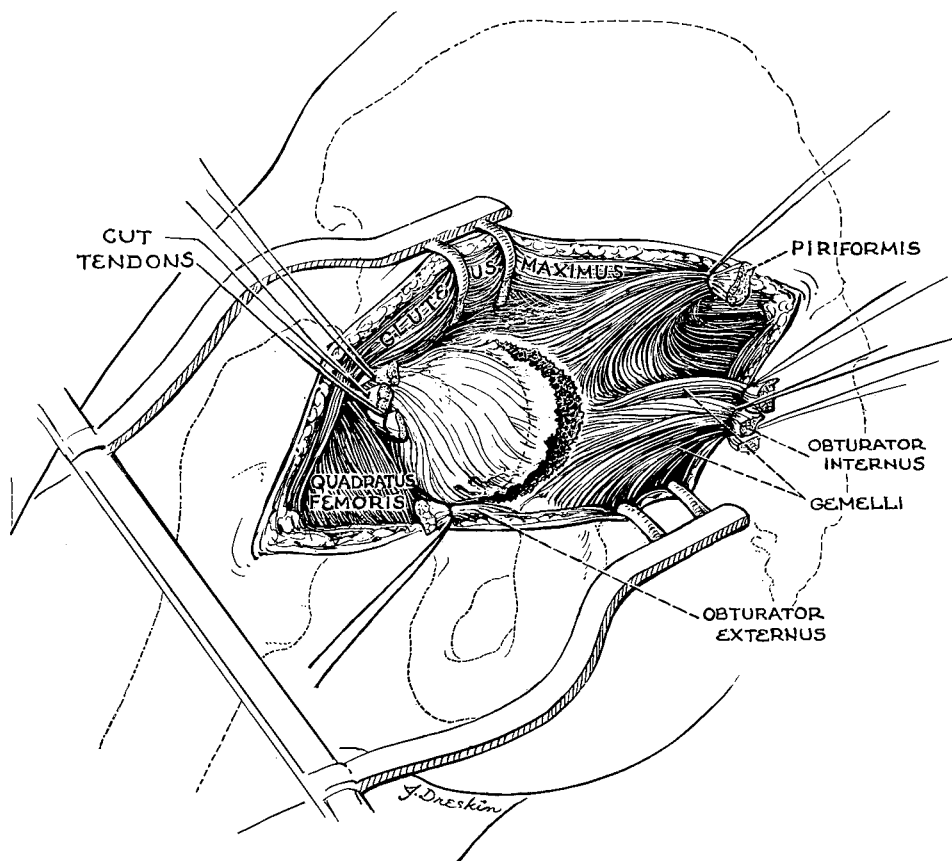


FIGURE 75.—Arthrotomy for fracture of posterior rim of acetabulum. Limits of exposure in posterior approach to injured joint. Sketch shows fracture in posterior rim of left acetabulum and posterior joint capsule. [From The Journal of Bone and Joint Surgery, vol. 30-A, pp. 699-727, July 1948.]

other, were usually attached to strips of capsule, and thin arcs of articular cartilage could be seen on their inner aspects. Only large fragments, approximately 4 to 7 cm. long, were broadly attached to the capsule. These bled on curettage and could be assumed to have sufficient blood supply to survive when they were replaced. The larger the fragment appeared in the roentgenogram, the more articular cartilage could one expect to find upon it at operation.

In addition to the changes listed, comminuted fractures of the rim of the acetabulum were always accompanied by extensive, contused, lacerated wounds of the posterior soft parts.

In almost every injury in this series, the parietal or external portion of the capsule, rather than the visceral or reflected portion, sustained the major damage. This is a significant observation, since it is the visceral portion of the

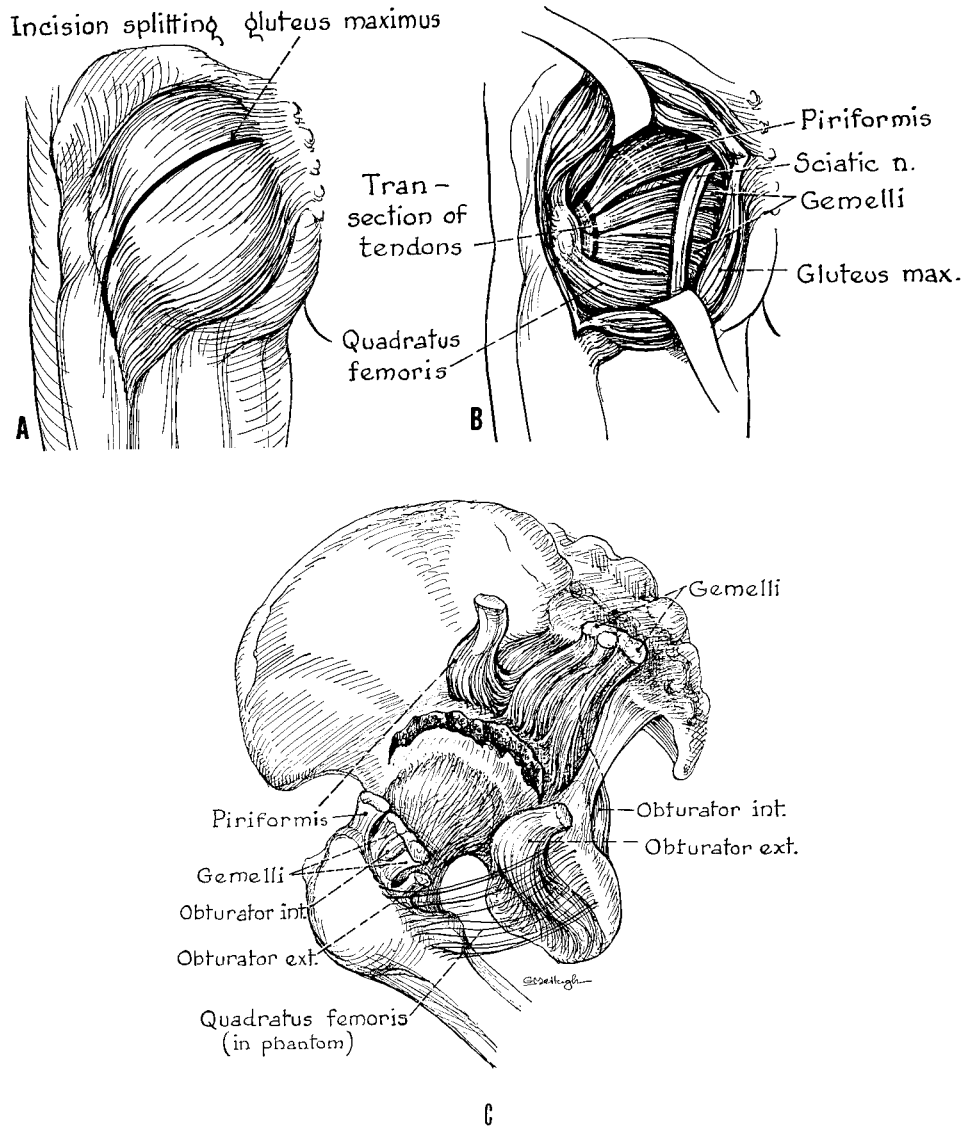


FIGURE 76.—A. Superficial anatomic relationships on posterior aspect of hip joint. The reflection of a segment of the trochanteric insertion of the gluteus maximus provides the relaxation necessary to develop a large window in this muscle. B. Demonstration of small, deep muscles and relationships of sciatic nerve. The piriformis, when reflected medially, envelops the sciatic nerve, and all further dissection is deep and lateral to the short external rotator muscles of the hip. C. Demonstration of skeletal relationships, fracture site, short external rotator muscles reflected medially, and rent frequently found after injury in inferoposterior portion of joint capsule. [Parts A and B, from Campbell, Willis C.: *Operative Orthopedics*, The C. V. Mosby Company, as redrawn and modified for *The Journal of Bone and Joint Surgery*, vol. 30-A, pp. 699-727, July 1948. Part C from *The Journal of Bone and Joint Surgery*, vol. 30-A, pp. 699-727, July 1948.]

capsule which carries the greater part of the blood supply to the head of the femur. When a large segment of bone was detached from the rim, the capsule was essentially intact except for a single tear in the posterior portion. The short external rotator muscles, however, sustained considerable damage; the belly and tendon of the piriformis were stretched over the head of the femur, which was dislocated into the fracture site. The tendon of the obturator internus was stretched over the neck. The gemelli were torn and shredded. All of these structures were so infiltrated with blood and so matted together with fibrinous exudate and granulation tissue when the patients were seen at general hospitals that dissection was difficult, if more than 2 weeks had elapsed since injury.

The head of the femur could be examined thoroughly at operation by rotating it through its range of motion in all directions at the fracture site. Almost every inspection revealed some damage to the articular surface of the head, though many of the lesions were small and not visible roentgenographically. Some fractures of even greater magnitude had not been demonstrated in anteroposterior views alone and, of course, were not demonstrated in films made by routine or imperfect techniques.

In 5 cases in which the rim had been fractured, lunate-shaped indentations were seen in the anterior aspect of the head of the femur and presumably represented cleavages caused by the edge of the rim. In a subchondral compression fracture, a circular, flat depression 2 cm. in diameter was noted on the anterior aspect of the femoral head, almost as if it had been tapped by a mallet. The surface of the bruised cartilage was dotted with spots the size of a pinhead and of uniform distribution, which represented the tufts of granulation tissue known to form early in the process of repair.

In 3 cases in which the posterior portion of the acetabulum had been removed, the ligamentum teres was found stretched and frayed. Complete visualization was possible in only 2 of these, in both of which disarticulation of the hip was necessary. In both of the cases, the ligamentum teres had been torn across. In the third case, in which complete visualization was not possible, it may have been only stretched. In many instances, the excursion of the femoral head was not as great as the roentgenograms had suggested.

Blood clot and organizing hemorrhage were observed in the retinacula in 2 cases, in 1 of which this structure was completely infiltrated with a large, subsynovial, dark-red blood clot. The significance of these findings was not realized until a year later, when the records were reviewed in preparation for this presentation, and the roentgenograms in both cases showed avascular necrosis of the head of the femur.

Management

In distinct contrast to dislocations without fractures, which responded readily to conservative measures, the management of fracture-dislocations was often complicated and difficult. The dislocation presented one set of problems and the fracture another. Each required different management. The presence

of the fracture always prevented reduction of the dislocation. When the dislocation was reduced by closed manipulations, the fracture remained displaced. If the fracture was extensive, open reduction and internal fixation were required before an acceptable repair could be secured. Obviously, the end results in these cases of fracture-dislocation could not be expected to be better than the end results of dislocations without fractures or of fractures without dislocations.

Some cases in each category of fracture-dislocations were treated conservatively and some by open operation, the decision depending upon (1) the surgeon's clinical judgment and experience, (2) his evaluation of the individual cases, (3) the physical and tactical circumstances in which treatment had to be carried out, and (4) the results obtained from conservative treatment, which was usually, though not invariably, given a trial. As experience was accumulated, the decision to resort to surgical treatment promptly in certain types of fractures was arrived at more readily and with less anxiety than early in the war.

Posterior dislocation with fracture of posterior rim of acetabulum.—In all posterior dislocations associated with fractures of the rim of the acetabulum, the dislocation was reduced by closed manipulation, just as the 15 simple dislocations in this series had been reduced, and with as little difficulty.

The management of the fracture was another matter. In 4 instances, its existence does not seem to have been recognized when the reduction was done. In several other instances, its extent was not appreciated by the surgeons who administered emergency treatment and manipulated the dislocation. This is easy to understand. Unless crepitation was present or the rim fragment was very large and consisted of the entire posterior aspect of the joint, as it occasionally did, physical examination did not reveal the presence of the fracture. Furthermore, roentgenologic interpretation was often difficult because no one had had experience with this type of injury. Unless one knew the roentgenologic anatomy of the hip joint intimately and in detail, the fracture was likely to be obscured by the head of the femur in the roentgenograms taken before reduction. Even when it was evident in postreduction films, a false idea of the apposition of the fracture lines was sometimes conveyed, if only the antero-posterior roentgenograms were examined. A true picture of the displacement of the rim fragments was best obtained in a postero-oblique view, with the patient lying supine on the cassette and the injured side tilted 60 degrees. In this position, the posterior portion of the acetabulum could be visualized in profile.

In 5 of the 15 posterior fracture-dislocations, the hip was suspended in traction for 8 weeks, in a Thomas splint with Pierson attachment. In 3 of these cases, the method of treatment was dictated by circumstances. The patient had head or abdominal injuries which took precedence over the hip injuries. In the 2 remaining cases, the fractures of the rim, although they were larger than chip fractures or avulsion fractures, were still not extensive enough to affect the stability or the range of motion of the joint.

Quadriceps, hip flexion, and abduction exercises were begun 2 weeks after injury. Weight bearing was not attempted during the approximately 6 weeks

these patients were under observation overseas. At the end of this period, when they were evacuated to the Zone of Interior as litter patients, they had no special complaints to indicate joint irritation, but there was, in each case, approximately 25-percent limitation of motion, and internal rotation of the hip was associated with some muscle spasm.

Ten other patients with dislocations associated with fractures of the rim of the acetabulum were treated by arthrotomy, after the dislocation had been reduced by closed methods. In seven cases in which the fragment of the rim was large, viable, and attached to the parietal portion of the capsule, the fracture was reduced and immobilized by internal fixation with a screw (figs. 77,

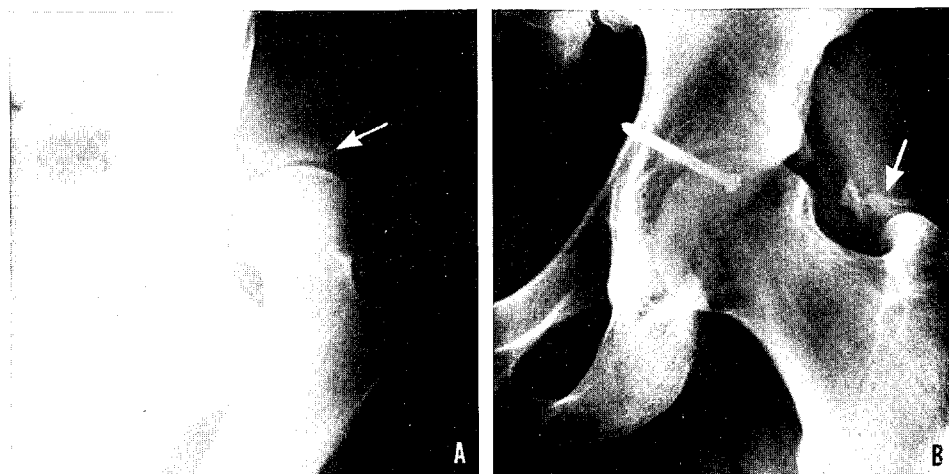


FIGURE 77 (case 34).—A. Postero-oblique roentgenogram showing posterior dislocation of hip with fracture of rim of acetabulum and displacement of fragments. A large fragment from the rim, with its capsular attachment, lies above the head of the femur. B. Antero-posterior roentgenogram of fracture and dislocation shown in figure 77A, 2 years after open reduction and internal fixation. Arrow indicates ossification of attachments of joint capsule and small muscles.

case 34, and 78, case 37). In the three remaining cases, (cases 44, 45, and 46) the injury was irreparable; the main fragments were detached from their blood supply or the articular cartilage was so severely damaged that removal of the posterior rim was thought advisable (fig. 79).

The modern literature, including modern textbooks, was not in agreement at the outbreak of World War II about the best approach for operations on old fracture-dislocations of the hip. This sometimes confused the clearly defined problem of open reduction or the necessity for removal of extra-articular bone fragments following fresh fractures of the posterior rim of the acetabulum. In all of these cases in this series, the indications were clear cut. When a large single fragment of the posterior rim was attached to the posterior intertrochanteric region by a large flap of parietal capsule, the flap served as a hinge, and the

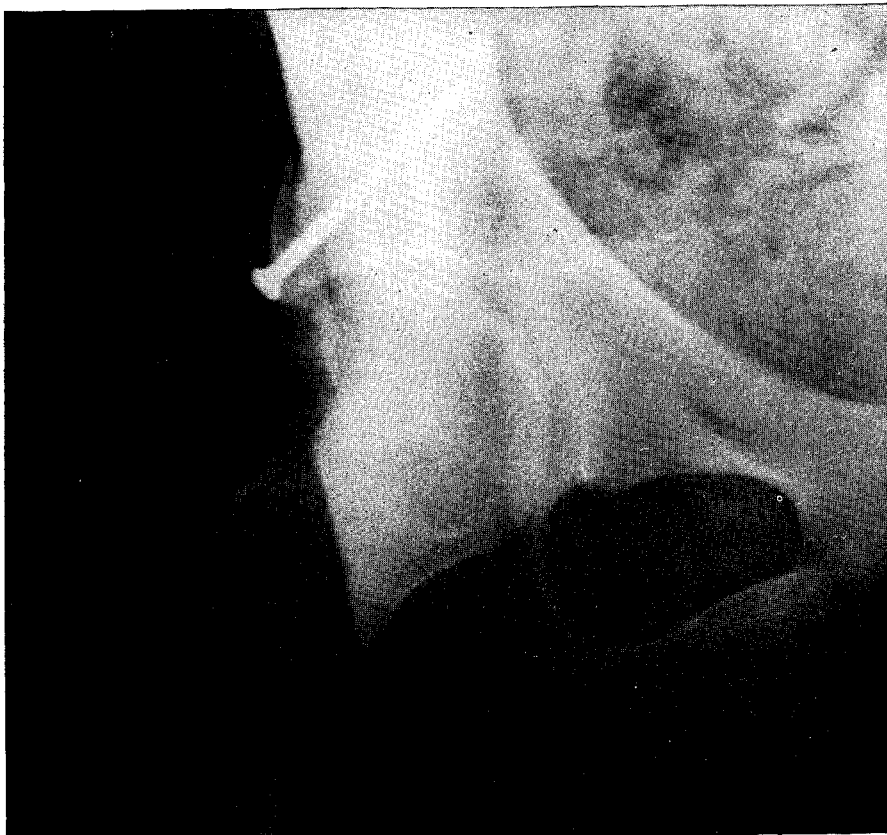

FIGURE 78 (case 37).—Postero-oblique roentgenogram of fracture-dislocation 2 weeks after closed reduction of dislocation and 3 days after open reduction of fracture of rim of acetabulum. Note penetration of screw through both cortices and accuracy of repair. Both of these criteria must be met for sound fixation and a good end result.

bone could readily be swung back and dovetailed into place. In 1 such case, although the fragment was large, the articular cartilage and cotyloid ligament had been ripped apart and were so roughened that replacement of the fragment would obviously have resulted only in an incongruent and perhaps painful joint, and it was therefore removed. When multiple small fragments were present, they were practically always lying loose or very loosely attached, and for the most part they had no blood supply. They therefore had to be removed to prevent ossification of the periarticular structures, migration of loose bone, and probably, in later years, a painful joint. In short, the decision as to replacement and fixation of the fragments or their excision had to be made at operation and was made chiefly upon the presumed vitality of the bone fragments.

The operation was performed with the patient prone, with small pillows placed along the anterolateral aspect of the chest. The operating table was equipped with a dropleaf under the hip, so that the surgeon could use flexion in his manipulations. The posterior approach described by Kocher,⁷ the similar approach described earlier by Von Langenbeck,⁸ or Osborne's⁹ modification of these incisions was used in all cases (fig. 75). Although the number of reported surgical repairs of fractures of the acetabulum was still less than a hundred in 1944-45, several of the more recent case reports had indicated that this approach is particularly well suited to posterior dislocations associated with fractures of the rim of the acetabulum, and it proved entirely satisfactory in these cases.

The incision was begun along a line drawn between the posterosuperior spine of the ilium and the inferior portion of the greater trochanter. At the latter point, it was turned distally for 2 inches along the posterolateral aspect of the thigh. The gluteus maximus was split along its fibers for its whole length above the line of the neck of the femur. Through this opening, the deep fascia covering the short external rotator muscles of the hip was widely exposed with the aid of a Balfour self-retaining retractor. A window 2 inches square was thus provided in the gluteus maximus. If larger exposure was desired, a part of the insertion of the muscle was also divided.

At this stage of the incision, the traumatic lesion in the short external rotator muscles, the capsule, and the joint were usually visible. The joint, as a rule, was found filled with blood clots, the volume sometimes amounting to as much as 75 cc. Removal of the hematoma exposed the fracture line and the glistening white head of the femur.

Both sides of the fracture line were next fully exposed by section of the tendinous insertions of the piriformis, obturator internus, gemellus superior, obturator externus, and gemellus inferior. Stubs of all tendinous insertions were left in situ on the trochanter for later repair. Heavy black silk sutures were placed in each end of each transected tendon to facilitate retraction and reflection of the short external rotators. In each one of these cases, the sciatic nerve passed across the medial aspect of the operative field, in the plane between the piriformis and superior gemellus, about 4 cm. medial to the superior edge of the acetabulum and 1 cm. medial to its inferior rim. Reflection of the muscles medially (fig. 76C) afforded sufficient protective covering for it. Reported variations in the course of the sciatic nerve in this region were not observed in any of these cases.

Further dissection was limited to the region anterior or deep to the external rotator muscles and was carried out subperiosteally, on the pelvic side of the fracture line. In order to prevent injury to the blood supply, neither the periosteum nor the joint capsule attached to the rim fragments was lifted from them.

⁷ Kocher, T.: *Chirurgische Operationslehre*. Jena: Gustav Fischer, 1897, pp. 323-327.

⁸ Von Langenbeck, Bernhard: *Vorlesungen über Akiurgie*. Berlin: August Hirschwald, 1888, pp. 147-149.

⁹ Osborne, R. P.: *The Approach to the Hip Joint: A Critical Review and a Suggested New Route*. *Brit. J. Surg.* 18: 49-52, July 1930.

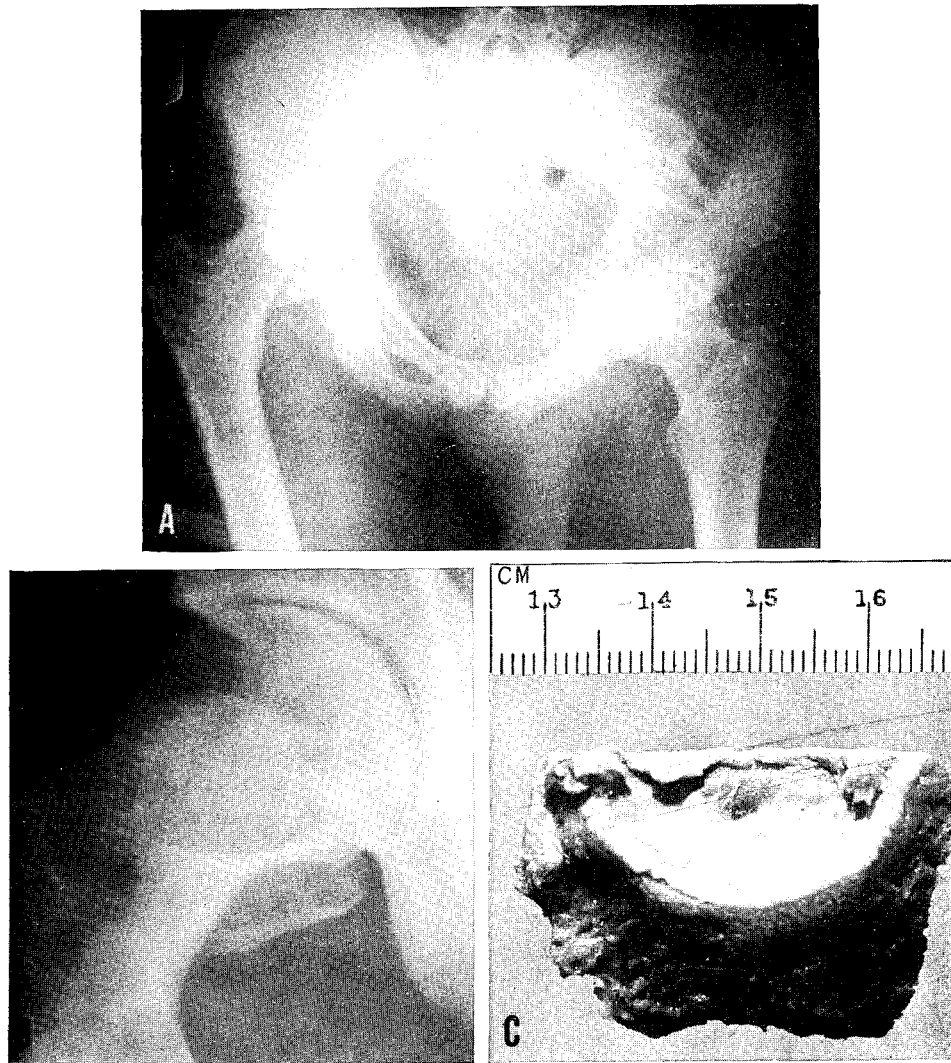


FIGURE 79 (case 46).—Posterior dislocation of hip joint with fracture of rim of acetabulum. A. Anteroposterior roentgenogram taken immediately after injury. B. Anteroposterior roentgenogram following manipulation and reduction of dislocation. Rim fragment remains displaced inferiorly. This position, rather than a position superior and lateral to the head, which is the usual location in displacements of the posterior rim, indicates that in this case the capsular attachments of the bony fragment have either been subjected to extensive injury or have been destroyed. C. Specimen of posterior rim of acetabulum removed at operation. The fragment, which was avascular and completely devoid of blood supply, was attached to a torn and twisted pedicle of joint capsule. In this case, the lost segment amounted to almost the complete width of the acetabular cartilage. A hemorrhagic lesion of the retinaculum was also observed at operation.

After loose chips of bone and flakes of articular cartilage had been removed, the main fragment could always be fitted accurately into place by apposing the dorsal edges as closely as possible. A position of adduction, 10 degrees of flexion, and slight external rotation provided maximum relaxation of the

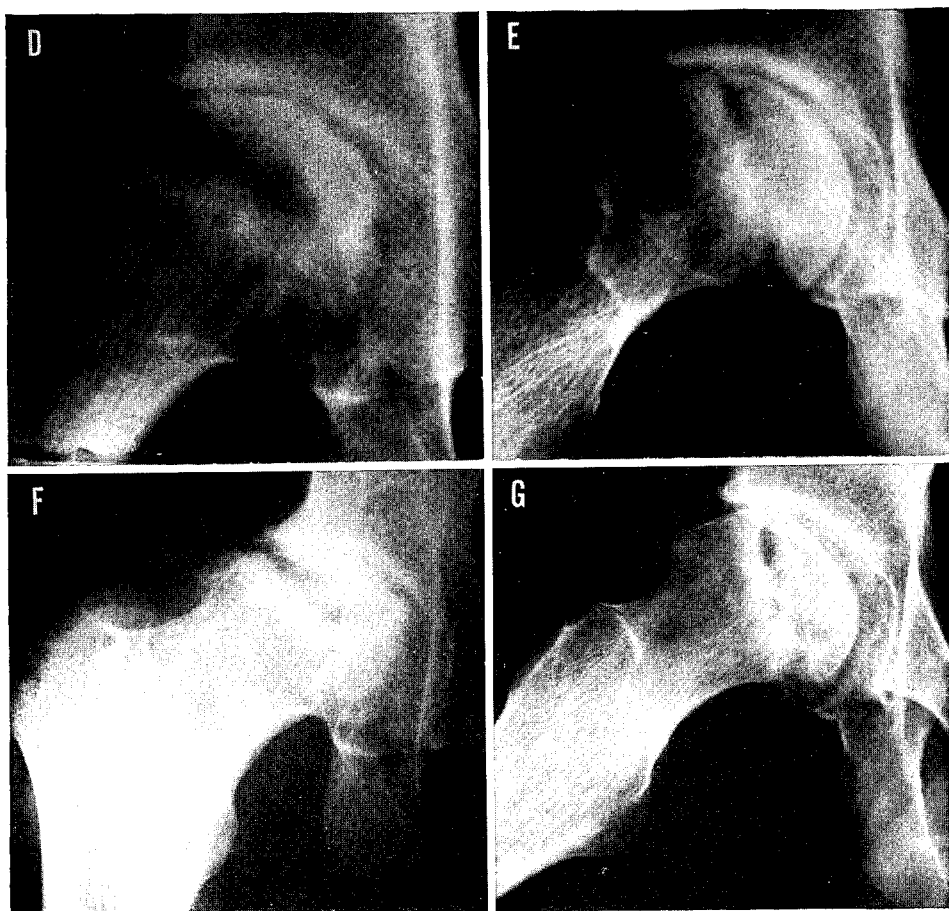


FIGURE 79.—Continued. D. Anteroposterior roentgenogram 2 years after original injury, showing necrosis of superior segment of femoral head. E. Lateral roentgenogram showing avascular necrosis of head of femur. Note cleavage line between necrotic and viable portions of head. Dead bone is in process of separation and replacement by new bone. F. Anteroposterior roentgenogram 2½ years after injury, showing additional absorption, separation, and replacement of necrotic portion of femoral head. G. Lateral roentgenogram 3 years after injury, showing sheering of dead portion of head away from living bone, posteriorly, at line of absorption and regeneration. In retrospect, the significance of the hemorrhagic lesion of the retinaculum observed at operation became apparent. It had been ignored at the time but undoubtedly furnished the genesis of the avascular necrotic process which later occurred in the femoral head.

posterior capsule and eliminated pressure of the head of the femur on the posterior rim, so that the circumstances for maintaining the reduction while internal fixation was applied were optimum.

The location for the application of the screw was carefully calculated, so that it would not be placed too near the articular cartilage. It was inserted almost horizontally, at right angles to the plane of the fracture and was directed somewhat superiorly. A depth finder was used to make certain that it had penetrated the cortex of the inner table of the pelvis. Bicortical penetration (fig. 78) was necessary to secure fixation capable of withstanding the test of cautious rotation and flexion, which were carried out at the conclusion of the operation. Reduction of the fragments also closed the defect in the posterior capsule. The operation was concluded by the excision of small amounts of shredded muscle tissue, the repair of the tendons of the small deep muscles, and closure of the wound in layers with black silk sutures.

Immediate postoperative care was instituted with the patient prone and the hip flexed 20 degrees over a pillow. Gluteal setting-up exercises were begun as soon as the sutures were removed. At the end of 5 to 10 days, the patient was turned to the recumbent position, and the hip was suspended in 10 pounds' skin traction in a Thomas splint with Pierson attachment. Uncomplicated wound healing resulted in every instance in this series.

Irreducible fracture-dislocations.—Before roentgenograms were available, the diagnosis of unreduced or irreducible dislocations of the hip was usually established by assumption, based on failure of multiple attempts at reduction. In most of the recorded cases, so few data are supplied that it is difficult to determine why conservative therapy failed, beyond the fact that the injuries are uncommon and treatment was carried out by physicians who had had little or no experience with them.

The eight patients in this series with irreducible fracture-dislocations (figs. 80, 81, and 82, cases 47 through 54, table 14), all arrived in general hospitals after at least two unsuccessful attempts at reduction had been made in field and evacuation hospitals. Improved roentgenograms, including stereoscopic films, at once revealed the difficulty: either the replacement of the femoral head was obstructed by bony fragments detached from the rim or the joint cavity had become so deformed and distorted by the injury that it could no longer receive the head of the femur. For anatomic reasons, it was therefore impossible to effect reduction by closed manipulation in any of these cases. Under the circumstances, conservative therapy in traction was of limited value, but it was employed consistently, partly for the patient's comfort and partly because it was necessary to retain anatomic approximation between the head of the femur and the fractured pelvis.

In three cases (cases 47, 48, and 49) bone fragments had lodged between the head of the femur and the joint cavity and provided an obstacle to reduction. In one of these cases (fig. 80, case 49) an attempt was made to disengage the fragments by pulling the head of the femur down over them and thrusting it inward with grinding and scooping movements. These maneuvers, in addition

to being futile, were obviously harmful to the joint surfaces. They were therefore not employed in any other similar case. Instead, immediate open reduction was resorted to.

The anterior iliofemoral approach was employed for arthrotomy in all 3 cases. In each instance, the anterior portion of the capsule was found intact, but the superior and posterior portions were stretched, frayed, and torn. Small fragments of bone were removed, but all fragments 1 sq. cm. or larger which were found attached to pedicles of torn capsule or strips of the short external rotator muscles were left in situ. In order to replace the head of the femur in the joint, it was necessary, in addition to employing traction, to pry loose interposed capsule, muscle, and torn tendon with the aid of a smooth, flat instrument. In 1 case (case 49) a large fragment of bone became lodged in the acetabular fossa during the manipulations, and, to remove it, it was necessary to make an incision in the intact anterior portion of the capsule and disarticulate the hip. In all of these cases, however, the obstruction to replacement of the head of the femur in the joint was not fragments of bone, but the interposition of the soft part attachments of these fragments.

In the five other cases of irreducible fracture-dislocation (cases 50 to 54) the problem was not only the dislocation of the hip but also the extensive fractures involving the entire acetabulum and the adjacent pelvis. In two cases (fig. 81, case 52, and case 53) manipulations were undertaken to restore the length of the extremity and place the head of the femur in a more suitable anatomic relationship to the pelvis. They were carried out with great caution because the risk of injury to the sciatic nerve was fully realized. The result did not justify the hazard.

In 4 of the 5 patients with disorganized hip joints, traction and suspension were employed for several weeks, until improvement in the general condition permitted either a major reconstructive procedure or transportation to a hospital for prolonged convalescent care. In the remaining case (fig. 82, case 54) peroneal palsy developed while the patient was still in the fixed hospital. Exploration was clearly indicated and was performed by the following technique:

The hip joint was exposed through the posterior approach already described. The sciatic nerve, which was intact, was discolored by ecchymosis for about an inch. It was stretched over a large fragment of bone which represented the entire posterior portion of the acetabulum, and it seemed reasonable to assume that the peroneal palsy was the result of compression of the nerve, because of traction on the femur in the soft parts between the head of the femur and the fragment of rim. The nerve was retracted medially in order to expose the joint cavity. The head of the femur was adducted and internally rotated beyond the normal range, and the rim fragment was retracted laterally with a bone hook. The acetabulum was obliterated by a displaced, impacted fragment of the body of the ischium. A second fracture of the superior ramus of the ischium was then found. In order to disimpact and reduce these fragments, it was necessary to mobilize and reflect the origin of the quadratus femoris. The body of the ischium could then be pulled down, and this maneu-

ver immediately reestablished the joint cavity and permitted reposition of the femoral head in the joint. The rim fragment was fixed in position with a single screw. Function of the hip was regained in this case, but in many similar injuries, although the immediate surgical result may be good, fusion of the joint or arthroplasty is necessary within a few years of operation.

Posterior dislocation with fracture of the head of the femur.—Gross fractures of the head of the femur, in contrast to minor bruises, fissures, and subchondral fractures, are uncommon in dislocations of the hip. There were four in this series (table 15). In two impacted fractures (cases 56 and 58)

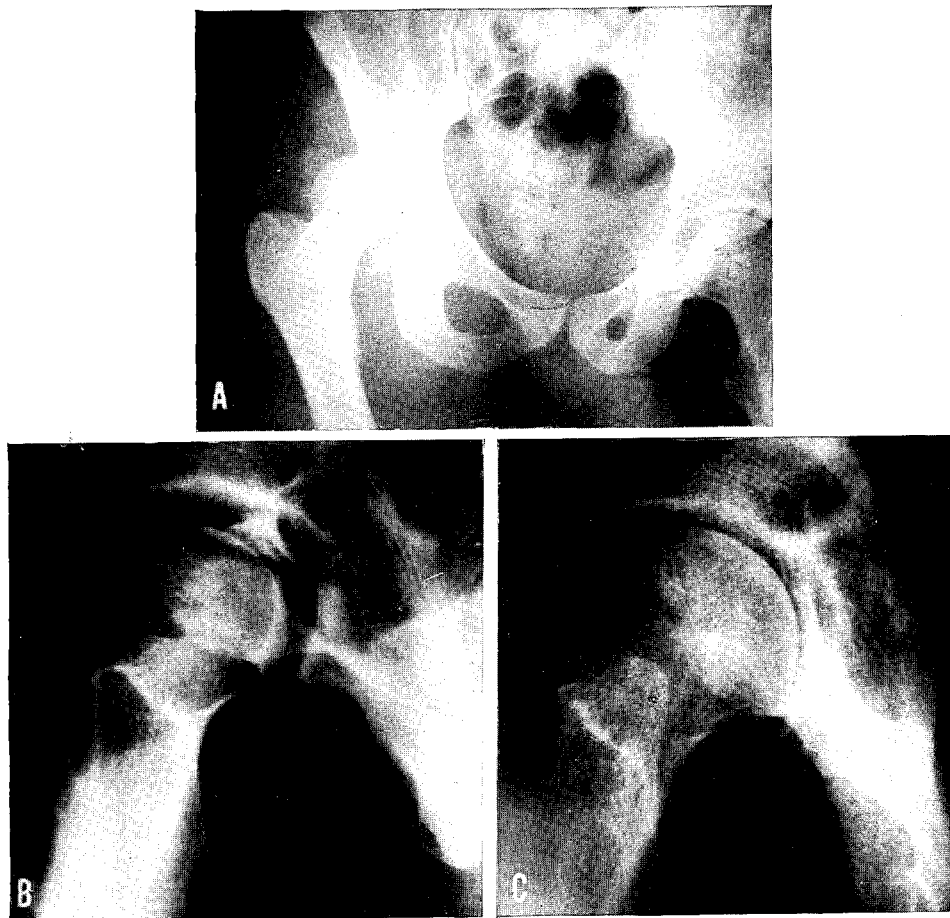


FIGURE 80 (case 49).—Posterior dislocation of hip joint with comminuted fracture of posterior rim of acetabulum. A. Postero-oblique roentgenogram shortly after injury. B. Antero-oblique roentgenogram after closed reduction of dislocation, which was accomplished immediately after injury. Note fragment of bone carried into acetabular fossa during manipulations. This view of the joint provided the best demonstration of the fragment and of its relation to the head of the femur. C. Lateral roentgenogram after removal of bone fragment at open reduction, 3 weeks after injury.

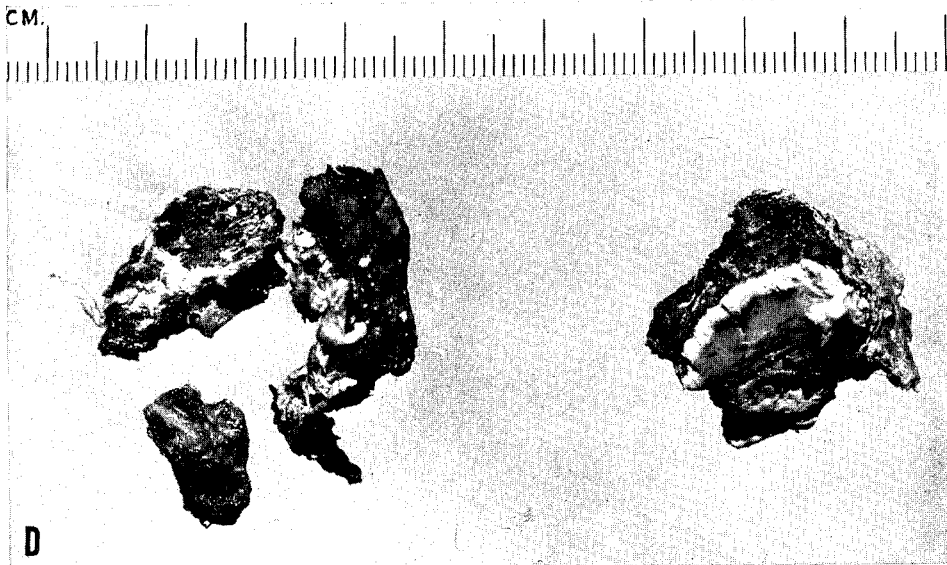
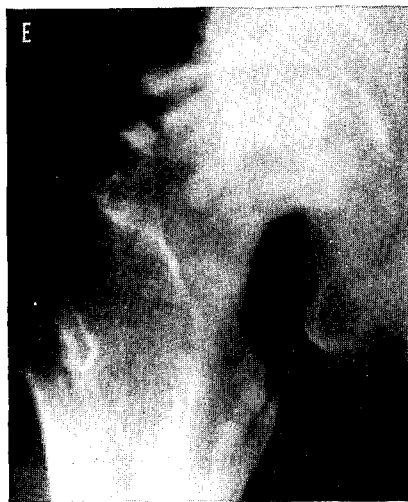

FIGURE 80.—Continued. D. Bone fragments removed from joint by anterior iliofemoral arthrotomy. The large fragment on the right was removed from the acetabular fossa. The three smaller fragments on the left were embedded in the posterior soft parts and were held in situ only by shreds of capsule or cotyloid ligament. The size of the fragments removed is in striking contrast to the apparently slight loss of articular surface demonstrated in figure 80C. E. Anteroposterior roentgenogram 20 months after arthrotomy, showing avascular necrosis of head of femur. The patient had used crutches ever since he became ambulatory, but this precaution did not prevent collapse of the bone structure.



there was little displacement. In the third case (fig. 83, case 55) the antero-inferior portion of the head, including the fovea capitis femoris and its attachments to the ligamentum teres, remained in the acetabulum. In the fourth case (fig. 84, case 57) there was appreciable limitation of motion of the joint under anesthesia, an observation not made in any of the other cases in this group. Open reduction was therefore performed at once to reduce the size and diameter of the deformed head and establish free motion as soon as possible. The following technique was employed:

The entire joint was exposed by the anterior iliofemoral approach and disarticulation was carried out as in a Smith-Petersen arthroplasty. The head

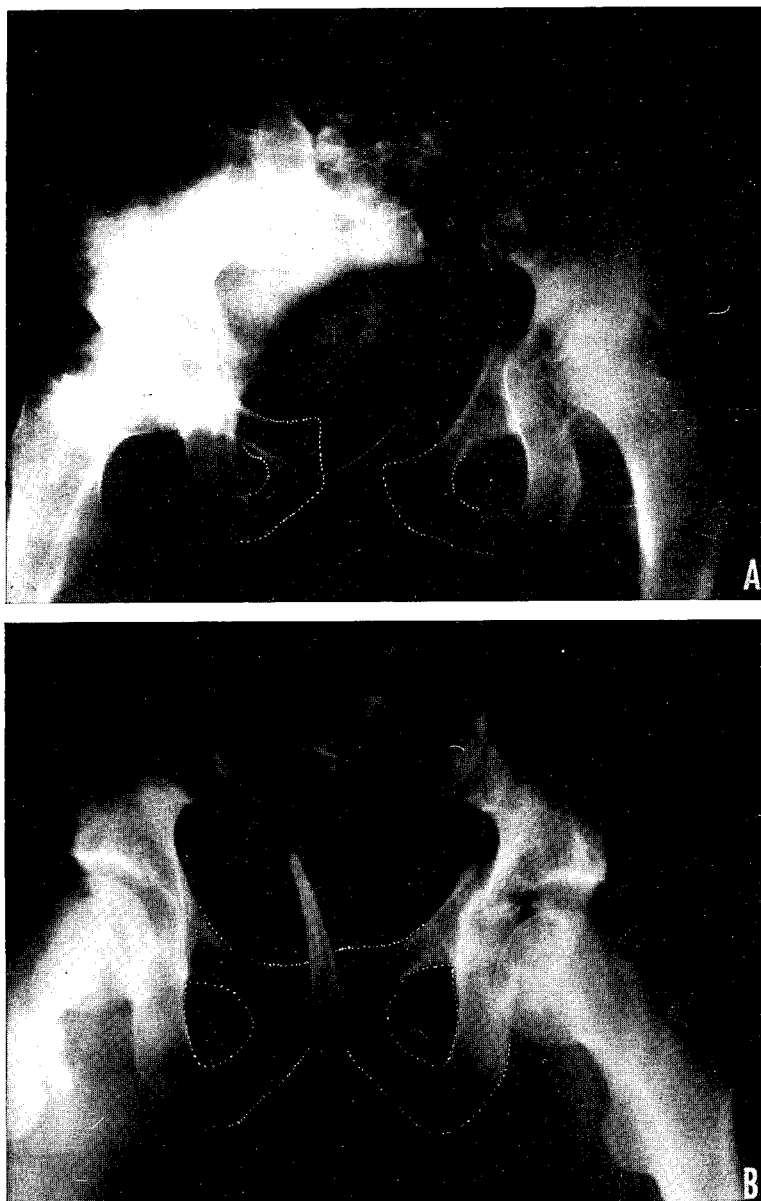


FIGURE 81 (case 52).—Extensive fracture of acetabulum with dislocation of hip joint. A. Anteroposterior roentgenogram [retouched] showing fracture and dislocation, with disorganization of hip joint and separation of symphysis pubis. B. Anteroposterior roentgenogram showing patient in vertical skeletal traction after reduction of dislocation by closed manipulation.

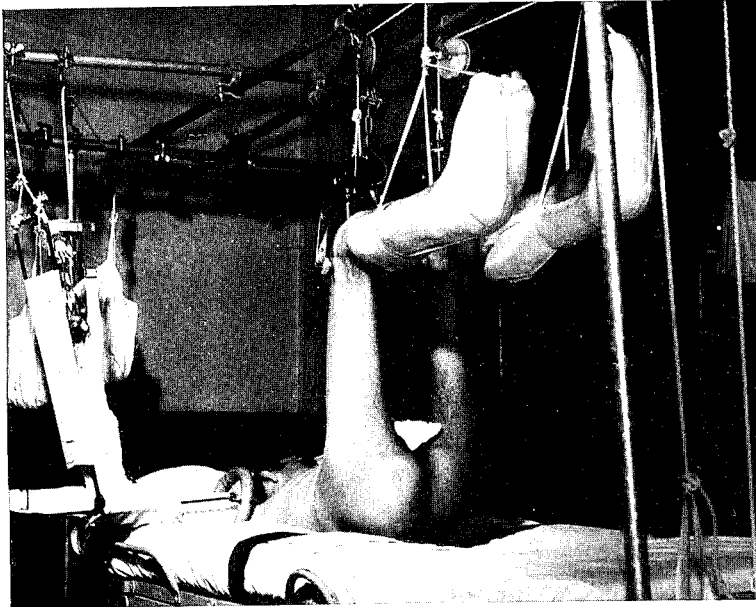


FIGURE 81.—Continued. C. Patient in vertical skeletal traction. This was the only position which would prevent redislocation of the head, with pressure on the sciatic nerve and severe pain radiating down the leg. The virtue of this method of suspension was the patient's own comfort and the simplification of nursing care. He could actively lift himself off the bed. Note the immobilization of the right arm and forearm in skin traction, for the management of other fractures. The patient also had an injury to the posterior portion of the urethra, for which urologic surgery and treatment were necessary.

of the femur was the site of an impacted stellate fracture, and the articular cartilage was split into six segments which were separated by intermediate areas of raw cancellous bone. The anteroinferior portion of the head protruded from the acetabulum and was crushed against the rim. The ligamentum teres was torn apart and was pressed into the substance of the crushed bone in the fovea. The fractured, impacted bone which protruded from the head of the femur was removed with a sharp osteotome, and the head was thus reduced, as nearly as possible, to its normal size and shape. The profuse bleeding which occurred during this step of the procedure suggested that the greater part of the circulation, or at least its capsular source, was still intact. After hemostasis had been obtained by compresses soaked in warm physiologic salt solution, the head was replaced and was now found to revolve freely in the acetabulum.

The management of these 4 fractures of the head of the femur with posterior dislocation was in accord with current trends. Such fractures must, properly, all be regarded as serious, but the treatment instituted and the results obtained necessarily vary with the exact type of lesion. Conservative management is

obviously preferable whenever it is possible, as it was in 3 of these 4 cases. Arthrotomy with removal of displaced bone fragments is likely to be successful only when the fracture is limited to the anteroinferior portion of the head, as it was in the fourth case. Had the weight-bearing surface of the head been involved, failure would have been inevitable.

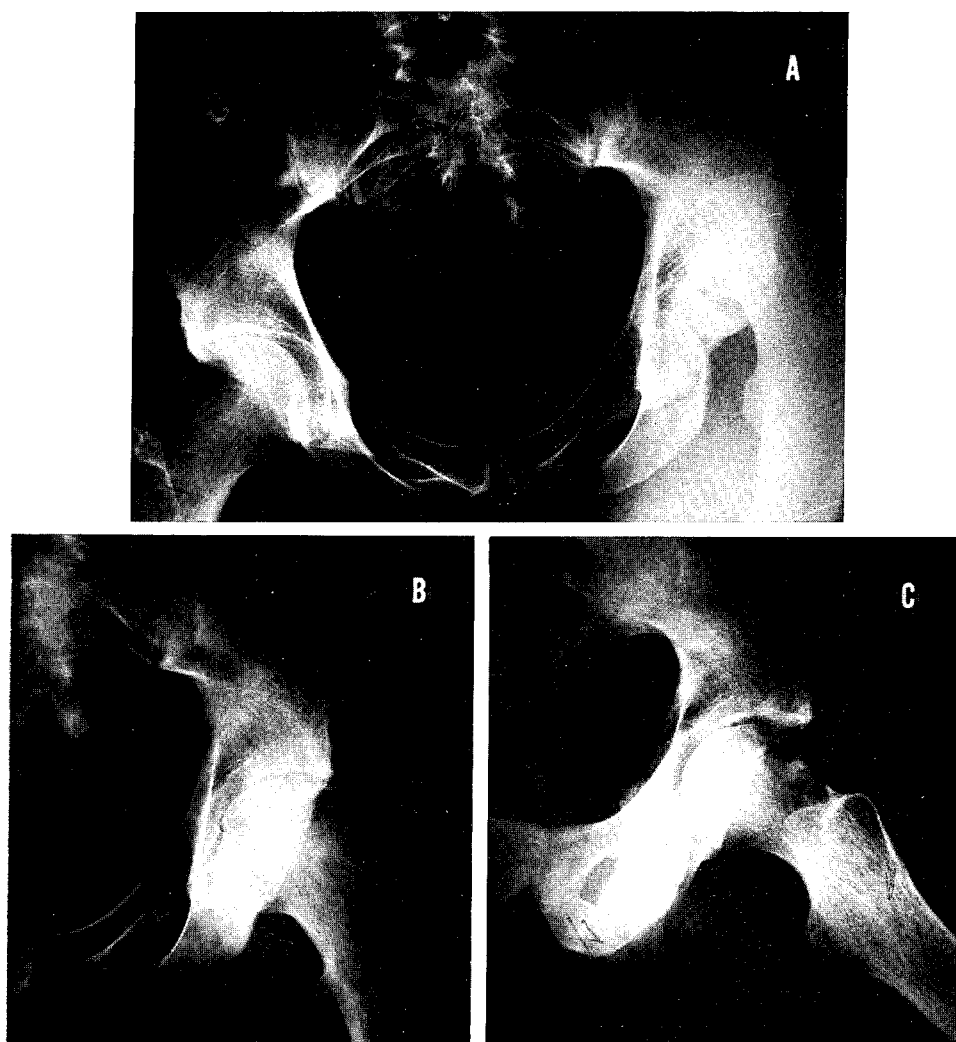

FIGURE 82 (case 54).—Irreducible fracture-dislocation of hip joint. A. Anteroposterior roentgenogram showing fracture-dislocation. The body of the ischium is impacted into the body of the ilium, and there is an associated fracture of the superior ramus of the ischium. The joint cavity is totally obliterated. B. Anteroposterior roentgenogram 3 weeks after open reduction of dislocation and internal fixation of fracture of acetabulum. Note that a single screw holds the posterior portion of the acetabulum in accurate position. C. Lateral roentgenogram showing repair.

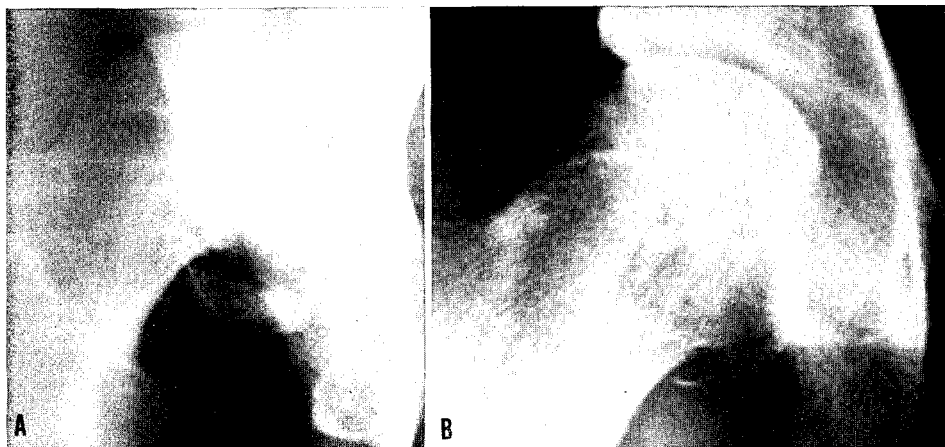


FIGURE 83 (case 55).—Fracture-dislocation of hip. A. Anteroposterior roentgenogram showing posterior dislocation of hip and fracture of head of femur. The separated segment of the inferior portion of the head includes the fovea. It is attached to the ligamentum teres, in the acetabulum. B. Anteroposterior roentgenogram 2½ years after original injury. The proximal fragment, which is demonstrable only with the femoral head in extreme internal rotation, has become reattached to the femoral head and does not interfere with the normal function of the joint.

Complications

Complications of fracture-dislocations of the hip may be either early or late. In these 27 cases, early complications, some of which were actually part of the original injury, included urinary-tract injuries, retroperitoneal hemorrhage, thrombosis of the hemorrhoidal veins, thrombophlebitis, sciatic neuritis, and sciatic-nerve palsy. Late complications encountered within a period of 6 weeks to 2 years after injury included ossification of the joint capsule, synovitis, traumatic arthritis, and avascular necrosis of the head of the femur. From the standpoint of possible late complications, injury to the soft parts proved fully as important as injury to the articular cartilage.

Urinary-tract injuries.—Nine of the twenty-seven fracture-dislocations of the hip joint were associated with multiple fractures and other injuries of the pelvis, including displaced fractures of the superior and inferior pubic rami, separation of the symphysis pubis, and dislocations of the sacroiliac joint. In several of these cases, the urethra was obstructed or lacerated. A number of patients had symptoms evidently caused by irritation of the bladder, and, in 1 instance, gross bladder injury required suprapubic cystostomy. In all these cases, treatment of the urinary-tract injury took precedence over treatment of the skeletal injury.

Retroperitoneal hemorrhage.—Blood is probably extravasated into the retroperitoneal space in all comminuted fractures of the acetabulum and may diffuse upward to the under surface of the diaphragm. This observation was

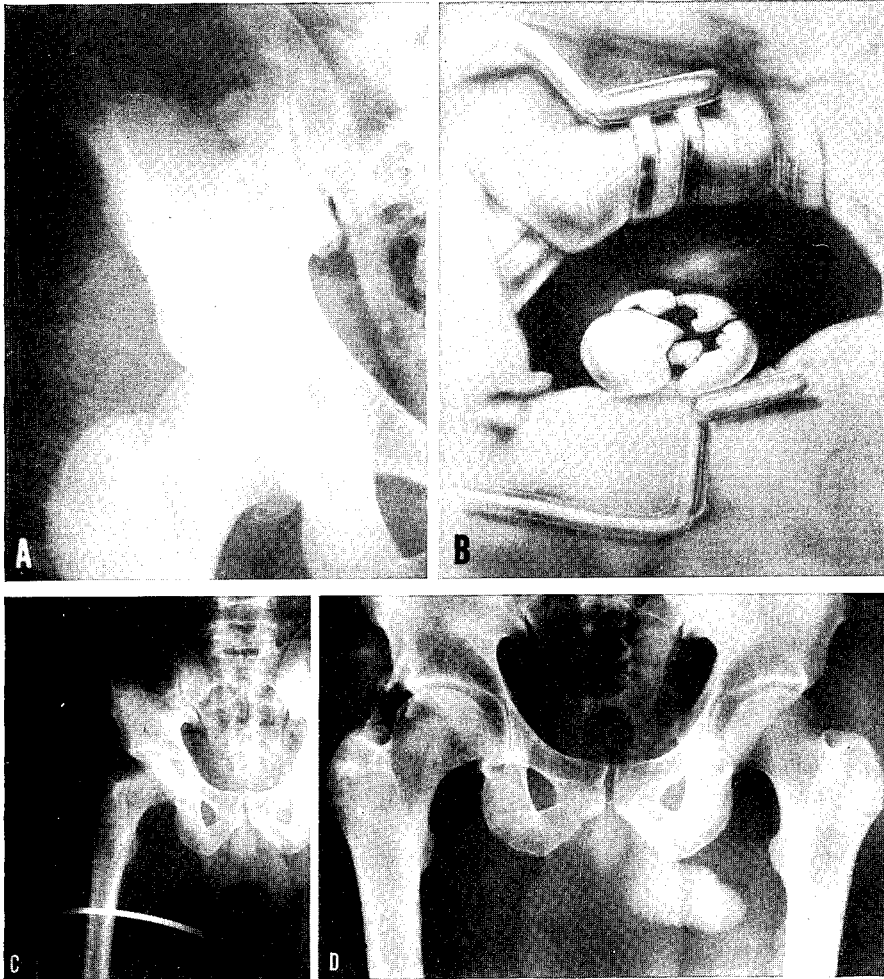


FIGURE 84 (case 57).—Fracture of head of femur with posterior dislocation of hip joint. A. Anteroposterior roentgenogram showing fracture-dislocation 2 weeks after closed manipulation. Rotation of the hip was painful and the total range of motion was less than 75 percent of normal. B. Hip joint after exposure and disarticulation through anterior iliofemoral approach. Note the impacted stellate fracture of the head of the femur, with segmentation of the articular cartilage. The photograph has been retouched for clarity. C. Anteroposterior roentgenogram of hip joint after anteroinferior portion of mushroom-shaped femoral head has been sculptured down to normal size at open operation, 2 weeks after original injury. D. Anteroposterior roentgenogram of both hips, 2 years and 8 months after open operation. The head of the right femur shows normal density, but the articular cortex is slightly irregular, and the old epiphyseal line is partially obliterated. Avascular necrosis of the entire head of the femur probably has not occurred in this case.

made at autopsy in 1 case in this series (case 51), in which death occurred several days after wounding, from a concurrent head injury. The possibility of retroperitoneal hemorrhage is one of the reasons why a period in traction for 5 to 10 days is always advisable before surgery on the hip joint is undertaken. If distention, vomiting, and fever are present in the first few days after extensive fractures of the acetabulum have occurred, the possibility of retroperitoneal hemorrhage should be considered in the management of the case.

Thrombosis of the hemorrhoidal veins.—This complication, which does not seem to have been reported previously in association with fracture-dislocations of the hip, occurred in 3 cases in this series. In 2 cases, including the fatal case just mentioned, it was transient and minor. In the third case (case 52), massive edema of the rectum and anal orifice developed a few days after the patient had sustained an extensive fracture of the left acetabulum, complicated by dislocation of the sacroiliac joint on the same side. There was no previous history of hemorrhoids, and the manifestations were far more severe than would ordinarily be observed in that condition. The edema diminished after treatment with hot compresses and disappeared entirely within 3 weeks. There was no recurrence within a 2-year period of observation.

Thrombophlebitis.—There was only 1 instance (case 54) of thrombophlebitis in the series. It was severe but was treated successfully with Dicumarol (bishydroxycoumarin). This is a complication which is a possibility in all injuries of the lower extremity but is probably no more likely to occur in injuries of the hip than in any other injuries.

Sciatic neuritis.—Four patients complained of severe pain over the lateral aspect of the lower extremity. In each case, it began shortly after wounding and persisted for several months. There was no motor weakness, and the changes of sensation which were observed were inconsistent and followed no pattern. Repeated neurologic examinations furnished no indication for exploration, and it was assumed that the sciatic nerve had suffered minor damage from the dislocated femoral head or from displaced fragments of the rim of the acetabulum.

Sciatic-nerve palsy.—Attention has already been called (p. 283) to the single case (case 54) in which the sciatic nerve was explored during open operation for an irreducible fracture-dislocation, and to the remarkable fact, in view of the close relationship between the nerve and the displaced fragments of the rim, that sciatic-nerve palsy did not occur almost uniformly in comminuted fractures of the posterior portion of the acetabulum. In all such cases, the shelf of bone which protects the nerve from the trauma of motion of the head of the femur is missing. In this series there were no instances of permanent damage to the sciatic nerve in the 15 simple dislocations and only 4 instances in the 27 fracture-dislocations. In all 4 cases, the dislocations were irreducible by closed manipulations (table 14).

In all 4 cases in which it was present, the palsy was a delayed phenomenon. One patient, who had had good motor function and sensation in the foot immediately after injury, began to complain of pain and foot drop after he had been en route for several hours from a forward hospital to a fixed installation.

In another instance, the foot drop became apparent after several hours of pain which radiated down the extremity following manipulation of the dislocated hip. In the 2 remaining cases, the palsy appeared only after a second manipulation of the dislocated hip. All 4 cases illustrate the well-known, but as yet inexplicable, fact that in all forms of trauma to the sciatic nerve at the level of the hip joint, the peroneal portion is apparently more vulnerable than the remainder of the nerve. This portion is more commonly affected than the posterior tibial portion, and paralysis becomes evident sooner after injury.

Only 1 of the 3 surviving patients had any return of function of the peroneal nerve. The other 2, at the end of 2 years, presented extreme atrophy of the affected extremity and still had complete paralysis of the extensors and evertors of the foot. The discouraging functional results are in correspondence with those recorded in the literature, which show that return of function is always slow and is usually incomplete if it occurs at all.

The significant feature of these 4 instances of peroneal palsy is that in every case it had been preceded by one or more attempts at manipulative reduction of the dislocation. Obviously, the risk of nerve injury is so great in these circumstances that manipulations should be avoided and dislocations reduced under full vision at primary open operation, whenever the acetabulum is too distorted by the injury to receive the head of the femur or there is other evidence that manipulation will be difficult or unsatisfactory. Careful examination of even emergency roentgenograms will usually provide enough information to determine these points.

Calcification of the joint capsule.—Ossification of the joint capsule, which occurred in only 2 simple dislocations without fracture, occurred in 14 of the 27 fracture-dislocations. In 12 of the 14 cases, the fracture was in the rim of the acetabulum, and in 2 instances it involved the femoral head. Roentgenograms revealed new bone formation in the posterior and superior portions of the capsule, but in every instance the clinical limitation of motion of the joint was slight. Almost all of the other patients with fracture-dislocations also showed deposits of new bone in either the femoral or the acetabular attachment of the capsule, but they were small and had no detectable effect on the range of motion of the joint.

Synovitis.—A number of patients with simple dislocations of the hip joint complained of minor aches and pains, discomfort in inclement weather, clicking or snapping sensations in the joint, or severe pain when heavy objects were lifted (p. 297). Similar complaints were made by a number of the patients with displaced fractures of the acetabulum (p. 302). These complaints were almost universal in the 27 patients with fracture-dislocations, even in those who had a normal range of motion. Slight muscle spasm was noted in some cases, even when the roentgenograms showed flawless joint surfaces and no bone atrophy. These symptoms and signs were regarded as indicative of traumatic synovitis, and the tentative diagnosis was substantiated by the fact that in a number of cases they disappeared within a year or two after injury. Whether the other patients who still complained of them at the 2-year followup will

eventually be rid of them, or will present traumatic arthritis 5 or 10 years after injury, is not possible to say. The literature is not helpful, as a search of it revealed no cases followed for these periods of time.

Traumatic arthritis.—Degenerative joint changes secondary to trauma were observed in 12 of the 27 fracture-dislocations of the hip, sometimes within 6 weeks of injury and always within the 2-year followup period. Clinically, it was not possible to distinguish this complication from traumatic synovitis or from the early stages of avascular necrosis of the femoral head. Roentgenograms clarified the diagnosis by revealing evidences of abnormal wear and tear on the defective joint surfaces, in the form of irregularities on the articular surface opposite the defect on the injured side.

In 6 of the 12 patients with traumatic arthritis, the defects revealed roentgenologically in the posterior rim of the acetabulum could be explained by unreduced fractures (cases 39 and 40), operative removal of bone fragments (fig. 85, case 44), and healed fractures of the head of the femur (cases 56, 57, and 58). All of these patients complained of painful crepitations and clicking sensations and had special discomfort when they climbed stairs or lifted heavy objects. Some also complained of morning stiffness, pain during inclement weather, and inability to stand for long periods without discomfort. These complaints were not easy to evaluate and in some instances seemed more closely related to the compensation aspects of the injury than to the pathologic process.

The other 6 patients with traumatic arthritis began to complain of severe pain in the joint, with increasing limitation of motion, within a year after injury. All had extensive fractures of the acetabulum (table 14). Roentgenograms in every instance demonstrated irregularities and subsequent loss of the entire joint space. All of these patients were regarded as immediate candidates for arthrodesis or mold arthroplasty, depending upon their individual requirements. In 4 instances (cases 49, 50, 52, and 53) it is known that these operations were done at Army or Veterans' Administration hospitals.

Avascular necrosis of the head of the femur.—There were no instances of avascular necrosis of the femoral head in the 15 simple dislocations in this series (p. 261). This complication appeared, however, in 2 patients with fracture-dislocations. In one instance (case 46, fig. 79) a line of demarcation separated living bone tissue of the femoral head and neck from an area of increased density and necrosis in the superior portion. In this case, as already noted (p. 275), the significance of the large blood clot present in the retinaculum at the margin of the articular cartilage at the head of the femur was not appreciated when it was observed shortly after injury. In the other (case 49, fig. 80), ecchymosis, new granulation tissue, and thickening of the entire posterior portion of the reflected capsule had been observed at operation, as in the case just described, again without appreciation of the importance of the findings. In this case, there was nearly complete disintegration of the bony structure of the femoral head. The observations made at operation seem to supply sufficient evidence that avascular necrosis is associated with thrombosis of either the retinaculum or the intertrochanteric branches of the medial

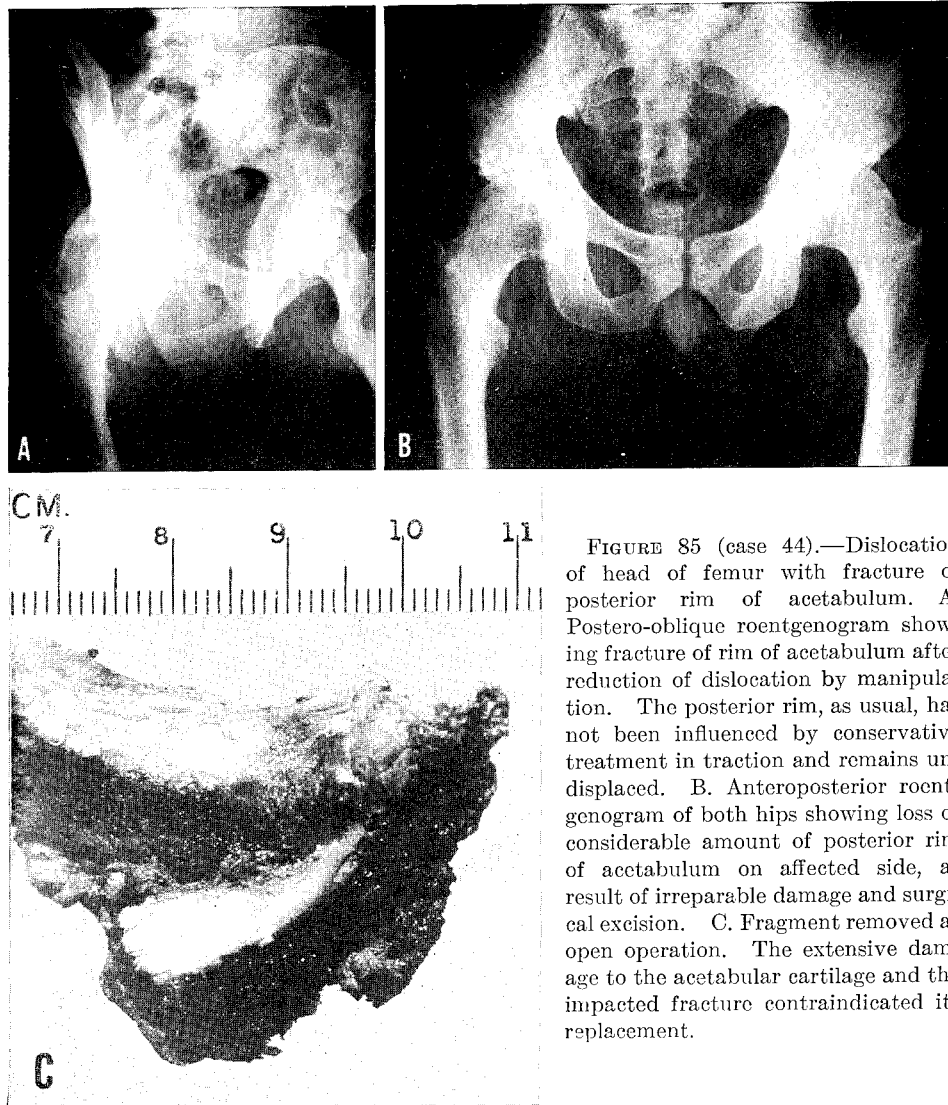


FIGURE 85 (case 44).—Dislocation of head of femur with fracture of posterior rim of acetabulum. A. Postero-oblique roentgenogram showing fracture of rim of acetabulum after reduction of dislocation by manipulation. The posterior rim, as usual, has not been influenced by conservative treatment in traction and remains undisplaced. B. Anteroposterior roentgenogram of both hips showing loss of considerable amount of posterior rim of acetabulum on affected side, as result of irreparable damage and surgical excision. C. Fragment removed at open operation. The extensive damage to the acetabular cartilage and the impacted fracture contraindicated its replacement.

circumflex vessels. This proof is in line with the damage which can be done experimentally (p. 255) by traction and tearing of the capsule in the posterior intertrochanteric region.

Up to 1947, approximately 50 well-documented cases of avascular necrosis had been encountered in a total of 270 recorded posterior dislocations of the hip joint. The lesion was usually observed within 6 to 18 months after injury. In the 2 cases in this series it occurred within 6 to 12 months. This time span does not bear out the theories of some observers that avascular necrosis may be a late complication, occurring 5 years or more after injury, though serial

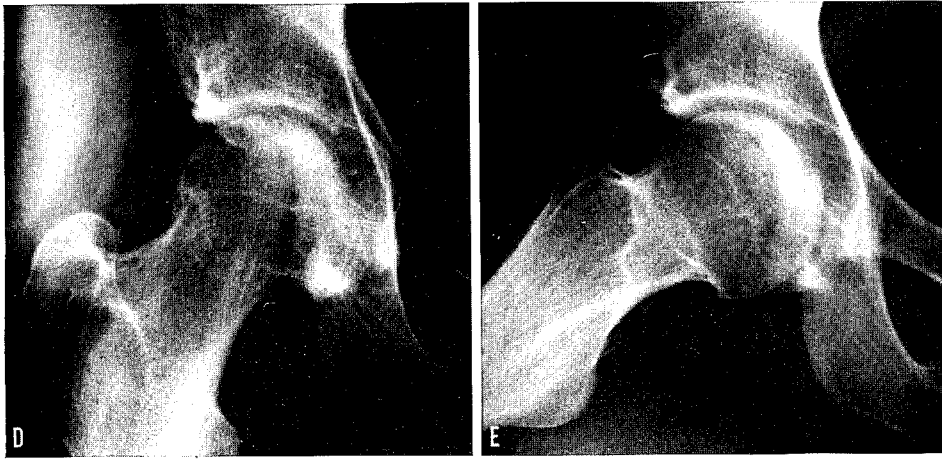


FIGURE 85.—Continued. D. Anteroposterior roentgenogram 2 years and 10 months after excision of posterior rim. Note irregularities and slight necrosis of surface of femoral head, presumably due to irregular wear and tear on the articular surfaces. E. Lateral roentgenogram showing area of degenerative changes in head of femur, corresponding to area of fracture defect of articular surface of acetabulum. As yet, there is little if any narrowing of the joint space. There is no evidence of avascular necrosis, and it is significant that retinacular hemorrhages were not observed at operation. These roentgenograms should be compared with those shown in figure 79, case 46, in which retinacular hemorrhages were observed at operation, and avascular necrosis followed.

roentgenograms have not been studied in a large enough group of cases to determine the true incidence of the complication in adults. It is known that it is relatively commoner in childhood and adolescence, probably because of the larger and more vulnerable vascular network in the reflected capsule at these periods of life.

Since avascular necrosis occurs in a variety of injuries of the hip joint, the microscopic changes associated with it have been described in detail. The literature concerning its pathogenesis is vast and highly controversial. A survey of 135 contributions published up to 1945 may be summarized about as follows:

1. The blood supply to the superior portion of the head of the femur comes a long distance, through the reflected capsule, which receives it from numerous branches of the medial femoral circumflex vessels in the posterior and posterosuperior aspects of the intertrochanteric region.

- 2 The pathologic and roentgenologic appearance of avascular necrosis in man differs from the process produced experimentally in rabbits, dogs, and goats by surgical severance of all the arteries and veins which enter the hip joint. In man, collapse of bone structure occurs relatively early, but revascularization of the area and replacement of dead bone begins relatively soon, so that there is only temporary interruption of the arterial circulation or venous return. Repair is, however, imperfect, and the joint is permanently defective.

3. The possibility that contusions and subchondral compression fractures may be etiologic factors has been entertained, but the evidence is circumstantial and inadequate.

4. The condition has been reported not only after posterior dislocations, after which it occurred in the 2 cases in this series, but also after anterior dislocation and central fracture of the acetabulum with prolonged intrapelvic protrusion.

5. Abstinence from weight bearing has been suggested as a method of prevention, but there is considerable doubt that it would be effective. One of the patients in this series began weight bearing within 3 months of injury, but it was not permitted in the other case because roentgenograms showed some loss of substance and irregularity of contour of the head of the femur. One is forced to assume, therefore, that a certain amount of necrotic bone is crushed, independently of weight bearing, by the action of the pelvifemoral muscles upon the head of the femur, just as happens in other ischemic and destructive lesions of the hip.

6. There is doubt that so-called creeping bone replacement can restore the joint structure in adults with avascular necrosis as effectively as it does in children with Legg-Calvé-Perthes disease, or in the occasional adult with an impacted fracture of the neck of the femur.

The only treatment now available for avascular necrosis of the head of the femur is restriction of full weight bearing. This is not a practical method for, as in these cases, there is a lack of premonitory symptoms, and the prohibition usually begins only when roentgenograms show the process in the articular surface of the femoral head. Then the damage has already been done. Nonetheless, weight bearing should be prohibited, even after the process is established, to prevent torsion of the necrotic femoral head during the period of new bone replacement.

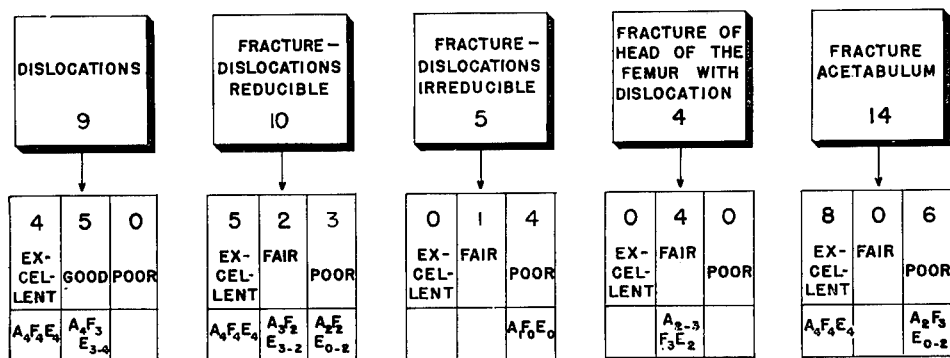
Followup Studies

The value of the methods of treatment used in these 58 jeep injuries of the hip joint can be determined only by the end results. Even with all the resources available for tracing former military personnel, it was possible to secure results in only 42 cases (chart 1; tables 11 to 15, inclusive). Furthermore, the followup covers only a 2-year period, and there is much to be said for the position of the observers who maintain that the results of such injuries cannot be determined conclusively until 5 to 10 years have elapsed. On the other hand, although very few cases in the literature have been followed for longer than 2 years, as a practical consideration, only traumatic arthritis is likely to become evident after a longer period.

In order to compare the results obtained in these three groups of military injuries with those obtained in civilian practice, a comparison was made with patients treated on the fracture service of the Massachusetts General Hospital who had sustained similar injuries in civilian life and who had been followed up for 2 years or more (tables 16, 17 and 18). To secure the civilian cases for

CHART 1.—Summarized results in 42 dislocations, fractures, and fracture-dislocations of the hip joint followed up for 2 years or more after original injury.¹

2 YEAR FOLLOW UP — 42 CASES — AUGUST 1947



UNREDUCED FRACTURES
OF THE RIM OF THE ACETABULUM
ALL TYPES

RIM OF THE ACETABULUM
REPLACED AT OPEN OPERATION

14 CASES		
1 EXCELLENT	2 FAIR	11 POOR
A ₄ F ₄ E ₄	A ₂₋₃ F ₃ E ₃	A ₂ F ₃ E ₂

6 CASES		
5 EXCELLENT	1 FAIR	0 POOR
A ₄ F ₄ E ₄	A ₂₋₃ F ₃ E ₃	

¹ The results are based on a review of complete case histories and serial roentgenograms, supplemented by personal letters from the patients specifying their symptoms and joint function (12 cases); personal letters and roentgenograms from the patients or their personal physicians (6 cases); detailed examinations by Army or private physicians, including measurements of the joint range and serial roentgenograms (14 cases); and personal examination of the patients (10 cases). The summary of results follows the method of grading used on the fracture service of the Massachusetts General Hospital, which includes the anatomic (A), functional (F), and economic (E) results in each instance. A grade of excellent requires that all 3 results be estimated as 4. A grade of fair or good is applied to any combination of grades of 4, 3, or 2. A grade of poor is applied to ratings of 2 or less.

comparison, it was necessary to go back for a period of 12 to 14 years. The chief difference in therapy in the two series is that patients in civilian life were immobilized for briefer periods than Army patients and were permitted earlier weight bearing.

Dislocations

The 9 (of 15) patients in the military series with simple dislocations of the hip who could be followed up were compared with 7 patients with similar injuries treated at the Massachusetts General Hospital. The results (tables 11 and 16) were essentially similar. No immediate benefits were derived from the extended period in traction and the extended restriction of weight bearing practiced in the military group. Five of the nine patients in this group and 2 of the 7 in the civilian group complained of slight aches and pains in the joints

TABLE 16.—Selected traumatic dislocations of hip joint, Massachusetts General Hospital, 1931-47

House unit No.	Age	Fractures (X-ray)	Other injuries of ipsilateral extremity	Treatment	Results
232707	11	Posterior dislocation	Sciatic nerve contusion, temporary peroneal palsy.	Non-weight-bearing caliper splint, 6 months.	Normal hip at 7 years.
13739	14	do		Crutches, 3 months.	Avascular necrosis and complete collapse, femoral head, at 18 months.
225358	18	do		Bed rest, 8 weeks.	Normal hip at 2 years.
330426	22	Posterior dislocation; chip fracture, rim acetabulum.	Head injury; fracture, shaft femur.	Reduction in Soutter apparatus; bed rest, 6 months.	Occasional mild joint pains; normal X-ray at 5 years.
399281	22	Posterior dislocation		Hip spica, 2 weeks; crutches, 6 weeks.	Normal hip at 4 years.
235958	28	Anterior dislocation		Hip spica, 3 weeks.	Night pain and slight limitation of motion at 5 years; normal X-ray.
543012	35	do		Bed rest, 3 weeks.	Normal hip at 1 year.

TABLE 17.—Selected fractures of acetabulum, Massachusetts General Hospital, 1932-46

House unit No.	Age	Fractures (X-ray)	Treatment	Weight bearing	Results
493496	14	Central fracture, slightly displaced	Traction, 4 weeks	Months after injury	Normal hip at 2 years.
78702	60	do	do	2	Normal function at 2 years; tires easily because of mild pain.
345913	64	Central fractures; medial displacement, body of pubis and anterior acetabulum.	Bed rest	3	Moderately painful hip, narrowing joint space (X-ray).
320953	50	do	do	3	No symptoms at 1 year.
514457	40	Central fractures; medial displacement, body pubis and anterior acetabulum; intrapelvic protrusion, head femur.	Lateral and longitudinal traction, 4 weeks.	3	Normal function, slight limitation of flexion at 1 year.
353469	22	do	Traction	3	Normal function, slight limitation of flexion at 3 years.
537224	52	Central fracture, comminuted, bursting type.	Open reduction	12	Painful hip, moderate ankylosis at 1 year.

TABLE 18.—Selected fracture-dislocations of hip joint, Massachusetts General Hospital, 1933-45

Unit No.	Age	Fractures (X-ray)	Other injuries of ipsilateral extremity	Treatment	Complications	Results
523309	25	Large, single fragment, posterior rim.	-----	Open reduction, internal fixation, posterior approach.	Sciatic neuritis.-----	Excellent at 1½ years.
128308	47	Comminuted fracture, acetabulum; displacement, posterior rim.	Fracture, patella.-----	Traction.-----	Peroneal palsy.-----	Vitallium cup, arthroplasty.
104952	39	-----	-----	Acetabuloplasty.-----	None.-----	Hip fusion.
131819	25	-----	-----	Open reduction, replacement large fragments, removal small chips.	-----do-----	Fair; degenerative arthritis at 6 years.

at irregular intervals. In both groups, patients who did hard labor or who worked on farms were uncomfortable when they had to lift heavy objects. During the first few months of weight bearing, 4 in each group complained of pains in the joint when the weather was rainy, when they were engaged in sports, or when they climbed stairs, but at the end of 2 years these symptoms had disappeared. One patient in the military group complained of night pain, for which roentgenograms furnished no explanation. The only patient with avascular necrosis in either series was a 14-year-old boy in the Massachusetts General Hospital group. This complication, as already noted, is more common in adolescence than in adult life. There was no evidence of degenerative arthritis in either group.

Fractures Without Dislocation

The 14 (of 16) patients with fractures of the acetabulum without dislocation who could be followed up in the military series were compared with 7 patients with similar injuries treated at the Massachusetts General Hospital (tables 12 and 17). When like fractures were compared, the results in both series were much the same.

At the end of 2 years, 11 of the 14 military patients had no serious disability, though many complained of mild pain, snapping or clicking sensations in the joint, stiffness early in the morning, and discomfort when lifting heavy objects. Those with displaced fractures of the superoposterior rim of the acetabulum appeared to have more symptoms and more disability than those with anterior rim or central fractures. One patient (case 19) with an unreduced fracture of the posterior rim had severe pain and some limitation of motion at the extremes of normal range in all directions. Another (case 18), whose joint was accurately repaired at operation, had a normal hip. The 2 cases were similar in that in both the displaced rim fragment was relatively large. The assumption is that when the fragments were thin and small and carried less articular cartilage with them as disruption occurred, the important function of the joint was not affected, regardless of whether the fragments were or were not replaced. The 3 patients with extensive fractures of the acetabulum and destruction of the joint cavity (cases 29, 30, and 31) had ankylosis and complete disability 2 years after injury and were thus candidates for arthrodesis or arthroplasty. Neither avascular necrosis nor degenerative arthritis was present in any instance of fracture without dislocation at the end of 2 years.

It is unfortunate that the single patient in the military series with an intrapelvic protrusion at the head of the femur could not be followed up. There were 2 such injuries in the comparative series from Massachusetts General Hospital, both of which were treated by the plan employed in the single case in the military series. Neither of the civilian patients had any disability at the end of 1 year and 3 years, respectively. It is difficult to understand why, in this type of central fracture, with intrapelvic protrusion of the head, healing could occur without functional disability, regardless of the displacement of the inner table of the pelvis. The explanation may be that in

these successful cases the fracture affects the anterior rim of the acetabulum, which is a nonessential part of the joint, while the posterior and superior portions of the horseshoe-shaped articular cartilage, which are vital to function, are spared. On the other hand, when intrapelvic protrusion of the femoral head is associated with extensive fractures of the acetabulum and bursting of the triradiate seam of ilium, ischium, and pubis, or with distortion of the rim of the acetabulum, the functional results, as might be expected, are poor. Classification of these injuries into these two categories would do away with the difficulty in explaining the discrepancies in results reported in the literature.

Fractures With Dislocation

The 19 (of 27) patients with fracture-dislocations of the hip who could be followed up for 2 years were compared with 4 patients with similar injuries treated by similar methods at the Massachusetts General Hospital (tables 13 to 15 and 18). It is interesting that, over a 12-year period at the civilian hospital, it was possible to locate only 4 patients with this sort of injury, while several times as many had been observed over an 18-month period in a single military-hospital center.

The 4 civilian patients showed, variously, excellent results, fair results, and, in 2 cases, poor results, with hip fusion necessary in one and mold arthroplasty in the other. In the military series, the results were also varied. Dislocations without displacement of fragments or associated with only minor fractures of the rim of the acetabulum showed, as would be expected, results which did not differ from the best and worst results observed in uncomplicated dislocations. Most of the patients, presumably because of scarification in the synovial membranes and the joint capsule, complained of aching pains, morning stiffness, and snapping of the hip, just as the patients with simple dislocations. In both groups of cases, the integrity of the lunate acetabular cartilage and of the rim of the acetabulum was presumably the critical factor in the end results. In matched cases of fractures treated conservatively and treated by open operation, good function and little or no disability were accomplished when the joint surfaces were restored as precisely as possible, but one could be certain that this had been achieved only when open operation had been done.

Dislocations which were reduced, associated with significant fractures of the rim of the acetabulum which were not reduced, gave, for the most part, fair to poor results after surgical removal of the entire posterior rim. Late degenerative changes in the joint were the rule. When, however, a single large fragment of the posterior or superior portion of the acetabulum had been detached and could be replaced precisely, with the capsular attachment intact, the results were excellent and were fully as satisfactory as the results of uncomplicated dislocations without fractures (fig. 86, case 32). Comminuted fractures which disrupted the acetabulum produced serious disability, and arthrodesis or arthroplasty was required in almost every case within 2 years.

In all 4 cases in which fracture-dislocations were associated with distortion of the femoral head, slowly progressive degenerative changes occurred over the

2-year followup period (table 15). One patient, whose injury was limited to the anteroinferior portion of the head, had practically normal function and in the 3 other cases, in which the entire head was involved, the range of motion was still useful.

Traumatic arthritis occurred in 12 patients during the period of observation (p. 293) and avascular necrosis in 2 others (p. 293).

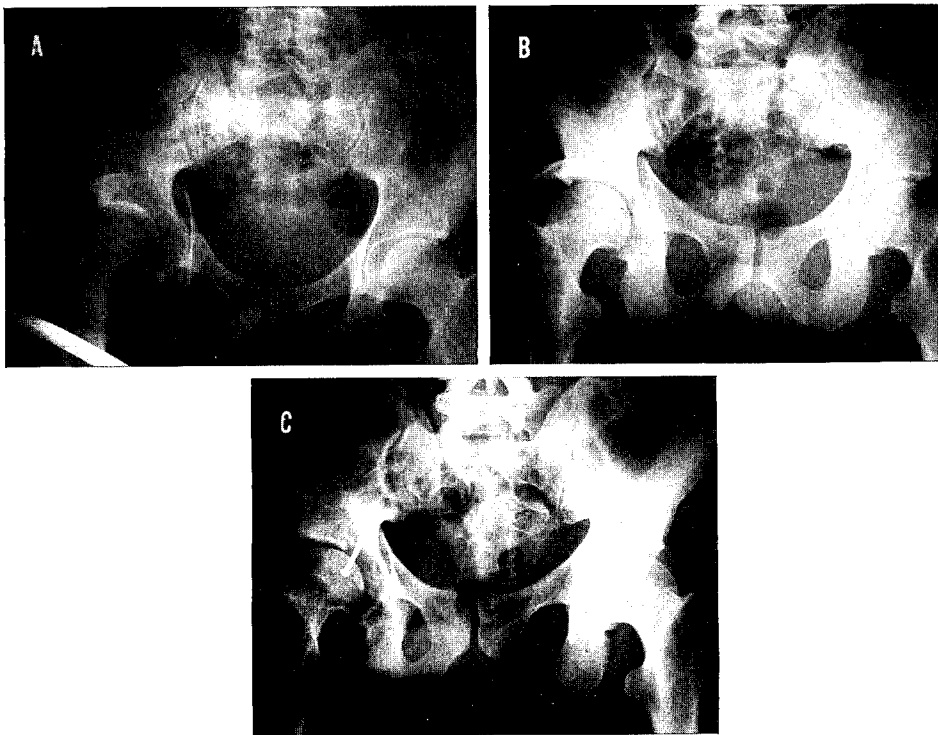


FIGURE 86 (case 32)—A. Anteroposterior roentgenogram showing central fracture of posterior rim of acetabulum and inner table, with posterior dislocation of hip joint. B. Anteroposterior roentgenogram of fracture and dislocation shown in figure 86A, after manipulation and reduction of dislocation on day of injury. Note that posterior rim fragment remains widely displaced and unaltered by treatment of dislocation. C. Anteroposterior roentgenogram of fracture and dislocation shown in figure 86A and B, 2 weeks after injury, after open reduction of fracture and internal fixation with a single screw.

Prognosis

At the end of 2 years of observation, the results in the 42 Army patients with dislocations, fractures, and fracture-dislocations of the acetabulum who could be traced corresponded closely with the results in the 18 similar patients studied comparatively from the fracture service of the Massachusetts General Hospital. The conclusion seems warranted that except in fractures of the posterior rim treated promptly by primary open reduction and internal fixation;

the nature and magnitude of the traumatic lesion, and not the technical procedure, determines the final outcome.

The experience gained in the management of these cases supports the impression derived from a survey of the literature that the seriousness of a fracture of the acetabulum depends upon whether the superior or the posterior portion of the lunate articulate cartilage has been injured. In the past, the tendency was to accept the imperfect results of conservative therapy because of the formidable nature of surgical management and also because there was no understanding of late degenerative changes in the joints. Now that the Army experience in World War II has shown the possibility of these changes, as well as the better results possible with surgical management in properly selected cases, there should be more willingness to adopt the principle that reposition of the bony fragments is as necessary in injuries of the hip joint as it is in injuries of other weight-bearing joints.

CHAPTER XX

Injuries of the Knee Joint

*Mather Cleveland, M. D.*¹

In the European theater, as in all other theaters, wounds of the knee joint presented a major problem. They were relatively frequent battle injuries, but none of the surgeons who were obliged to handle them had seen, in civilian practice, a sufficient number to standardize treatment, nor had they learned from personal experience the precautions and safeguards to prevent the development of infection. Furthermore, the devastating type of battle-incurred injury of the knee joint observed in military surgery does not occur in civilian practice. Suppuration of the joint was always the most dreaded complication of wounding, and all treatment was directed toward its prevention. Improper or inadequate care could mean the loss of the limb, and even death from sepsis.

Nature of the Injury

The most frequent cause of wounds of the knee joint was shell fragments, followed in order of frequency by bullets, fragments of rock or gravel, wooden splinters, and pieces of plastic from a certain type of German land mine. Other varieties of plastics, as well as wood fragments, were seldom encountered. The latter varieties of foreign bodies were readily overlooked because of the difficulty of visualizing them by roentgenograms. Rock and gravel were seldom driven into the joint by force of an explosion or the impact of a missile, unless the knee was in close contact with the ground.

The amount of initial damage which a penetrating fragment inflicted upon the joint depended in large measure not only on the size of the object but also on the velocity of its penetration. A small fragment, which had barely penetrated the joint and which had produced, according to roentgenologic evidence, little damage to the bony structures sometimes caused fulminating suppuration, depending upon the material which it carried in with it and the judgment with which the injury was managed.

Penetrating injuries of the knee joint were either direct or indirect. They were direct when the missile itself entered or perforated the joint. They were indirect when the missile fractured the femur, the tibia or the patella and thus established a communication between the synovial cavity of the joint and the compound fracture. Single or multiple structures could be damaged in either type of injury.

¹ The material in this chapter was secured from two reports made to the senior consultant in orthopedic surgery in the European Theater of Operations, one by Lt. Col. James E. Thompson, MC, Maj. William H. Cassebaum, MC, and Capt. (later Maj.) Charles F. Stewart, MC, of the 9th Evacuation Hospital; and the other by Maj. (later Lt. Col.) Louis A. Goldstein, MC, of the 19th General Hospital.

Indirect injuries took a wide variety of forms. Sometimes a single long fracture in a remote part of the shaft extended through the condyles into the joint. Frequently the indirect injury was a compound fracture of the patella, which was likely to be overlooked because of the difficulty of demonstrating, by roentgenograms, fracture lines extending into the joint surface. Unsuspected penetration of the joint was often discovered at operation when the compounding wound was at a considerable distance from the knee joint and the missile also lay at some distance.

Although the capsule and collateral ligaments of the medial and lateral aspects of the joint, together with some of its tendons, were frequently damaged, the damage was seldom of considerable extent. On the anterior aspect of the knee, there was greater opportunity for penetration. The capsule in that area is normally much laxer, to allow greater mobility, and the suprapatellar pouch extends for some distance above the level of the joint.

Small and compact patellar ligaments were often severed or almost completely destroyed by the passage of a fragment of any size. The lateral expansions of the larger quadriceps tendon, which blend with the capsule, made damage to this tendon less of a problem of management. Because of its structure, retraction was minimized and future function more readily resumed.

A missile which entered the knee on the mediolateral aspect and lodged in the condyle of the femur might not have traversed the joint before reaching its destination. An accurate knowledge of the anatomic reflection of the synovial membrane at that point was necessary before any opinion could justifiably be expressed. A fragment which had passed through one condyle might damage it only slightly but might completely demolish the other condyle.

The main vessels and nerves to the lower extremity, because they lie in the popliteal fossa, are safely protected from ordinary forms of injury, but they were so frequently injured by penetrating wounds about the knee that their integrity was suspect in any wound in the area. This was particularly true of the popliteal artery, injury to which took precedence over the treatment of any other injury. Damage to the vessels almost invariably meant loss of the limb; reparative procedures were seldom satisfactory. Damage to the nerves, if the injury was irreparable, resulted in a paralyzed limb, even if the blood supply remained intact.

Diagnosis

Diagnosis of injury of the knee joint was based on a combination of clinical and roentgenologic evidence. The experience of the surgeon, combined with his knowledge of the regional anatomy, often provided a considerable part of the proof. Many times the question of whether or not the joint was penetrated was not settled until operation. In such cases, exploration was actually part of the diagnostic routine.

Motion in the wounded joint was likely to be limited and painful. Local tenderness could be elicited at various points. There was always an evident

excess of intra-articular fluid, which was usually bloodstained on aspiration. The amount present was usually in direct proportion to the severity of the injury.

Roentgenograms could be misleading because they showed only bony damage. They did not demonstrate cartilaginous coverings of the condyles, and it was therefore necessary to bear in mind that the profile of the femur or tibia observed in the joint was the representation of the cortex of the underlying bone and provided no information about the state of the cartilage. When adequate exposure was obtained at operation, it was often surprising to see the extent of the damage to important cartilaginous structures that had been completely invisible on the roentgenograms.

Evaluation of the damage to the knee joint was based on the relative importance of the structures damaged. Damage to the cartilaginous structures of the tibial and femoral condyles and the inner surfaces of the patella was of major importance. Damage to the menisci was of almost equal importance. Damage to the synovial membrane and the cancellous bone of the condyles was of lesser importance. These structures are rich in blood supply and therefore offer more resistance to infection than cartilage, which is notoriously poor in blood supply, and which, when it was detached and devitalized, served as an excellent nidus of infection.

Initial Wound Surgery

Treatment of injuries of the knee joint fell into three categories, as follows:

(1) First aid, given in forward aid stations; (2) initial wound surgery, performed in the evacuation hospital or, occasionally, in the field hospital; and (3) definitive surgery, performed in the general hospital in the rear.

First aid consisted simply in the control of bleeding, if that was necessary; the application of a Thomas splint, if it was available, otherwise of some other form of immobilization; and, until it was forbidden late in the war, the local application of sulfanilamide crystals to the wound. Until late in the war, each soldier was provided with sulfonamide pills which he was supposed to take, if he was conscious, as soon as he was injured.

If the knee injury was associated with a vascular injury, which always demanded immediate attention, the casualty was cared for in a field hospital unless there was an evacuation hospital in the immediate vicinity. In the great majority of injuries of the knee joint, initial wound surgery was performed in an evacuation hospital, in which these wounds had a high priority. Consultants and experienced traumatic surgeons lost no opportunity to emphasize to more inexperienced officers that the ultimate outcome of the injury was decided in the forward hospital. The treatment the soldier received at this point would determine whether he would recover with a normal joint or a stiff joint, whether he would lose his limb, or whether he would lose his life as the result of prolonged sepsis.

If a vascular injury was present, it was always attacked first, regardless

of the amount of damage to the knee joint. Otherwise, whatever the nature of the injury, the first procedure was debridement of the soft tissues and the joint. An occasional officer believed, until the end of the war, that perforating wounds caused by high-velocity missiles, with only small wounds of entrance and exit and no demonstrable bone damage, did not require arthrotomy. This was not official policy, and it was not sound policy. The only safe plan, when penetration of the knee joint had obviously occurred or was suspected, was to open the joint and determine, by direct inspection, the conditions present. This policy held whether the injury was direct or indirect and regardless of the size of the wound.

Technique of debridement.—Operation on the joint was best performed with a tourniquet in place, so that the intra-articular structures would not be obscured by troublesome bleeding. The incision into the joint was sometimes made through the original wound; when it was on the medial, lateral, or posterior aspect of the knee, this was frequently possible. Most often, however, the original wound was merely debrided, either at the beginning or the end of the operation, and the exploratory incision was separate and elective.

The incision of choice was a long medial or lateral parapatellar incision, which was regarded as giving the most satisfactory exposure. If a satisfactory operation could not be performed through one incision, another was made on the opposite aspect of the patella. At times it was necessary to combine a medial or lateral parapatellar incision with a posteromedial, posterolateral, or posterior midline incision, in order to care for damage in the posterior compartment of the knee joint. The trauma caused by multiple incisions was insignificant in comparison with the bad effects of inadequate surgery.

If the foreign body lay in the condyle of the femur, the approach of choice was through the lateral extracartilaginous portion. If it had entered the cartilage, the direct approach to it was usually best.

When the joint was entered, fluid and blood clots were evacuated, and the cavity was thoroughly irrigated with warm physiologic salt solution until the fluid returned clear. Then the extent of the damage was determined by inspection and palpation. If exposure was not adequate, the incision was extended or another was made.

Thorough debridement of the joint was the keystone of the whole operation. It had to be both careful and complete. The initial irrigation removed only blood clots, free bits of cartilage, and other debris from the recesses of the synovial cavity. Then all loose and devitalized portions of articular cartilage, bone, and menisci were removed. Traumatized surfaces were debrided down to healthy tissue with a knife or curette; leaving devitalized cartilage and bone fragments in the joint was an invitation to suppurative arthritis.

Whether penetration of the knee joint was direct or indirect, the damaged articular elements required exactly the same careful excision.

Snug closure of all synovial defects, whether traumatic or surgical, was mandatory. Leakage after operation invited ascending infection. The syno-

vial membrane, like the peritoneum, has a great capacity for resisting infection, but once infection is established in the joint, this resistance is no longer effective. With these principles in mind, the policy was to close the synovial capsule and membrane so tightly that leakage could not occur.

Large defects in the capsule, especially in the medial and lateral aspects, introduced special problems in closure which demanded special techniques. Anything was preferable to leaving the wound in the joint open. If large capsular defects were not closed initially, the risk of infection was always present, and it was usually impossible to close them successfully later by any form of surgical procedure.

Plastic procedures often made prompt reconstructive surgery possible and allowed the patient to recover such joint function as was compatible with the degree of articular damage. Frequently, the best that could be done was to approximate the synovial membrane and capsule as completely as possible, then cover the remaining defect with one or more sliding grafts of skin and subcutaneous tissue from the adjacent area. Results were usually excellent with this technique, while closure under tension inevitably resulted in breakdown of the wound. If capsular substance had been lost and not enough deep tissue was available to cover the defect, closure with skin was attempted, relaxing counterincisions being made if they seemed necessary.

After closure, penicillin solution (10,000 units in 5 cc. of physiologic salt solution) was injected into the joint cavity, preferably through a needle previously passed through the anterolateral aspect beneath the patella and known to be in the joint cavity. A less desirable technique was to close the synovial membrane around a small catheter or cannula, make the injection through it, and then, after it was removed, seal the opening with a purse-string suture.

The soft tissues and skin were left open, as in the usual debridement, and the wound edges were separated with a light, loose packing of dry, fine-mesh gauze.

After operation, the knee was immobilized in a hip spica. Many surgeons at this time cut a large anterior window into the plaster to permit direct access to the joint for inspection and treatment. A modified Tobruk splint was also satisfactory for transportation splinting.

Whenever a penetrating wound of the knee joint was diagnosed or suspected, penicillin in 25,000-unit doses was instituted routinely every 3 hours. Sulfadiazine was usually added after initial wound surgery. Treatment by this routine was continued until after definitive surgery had been performed in a general hospital.

Other techniques.—Penetrating wounds through the patella which had produced extreme comminution were best treated by complete excision of the patella. After debridement of the joint, the synovial membrane and the capsule were closed in the midline.

When destruction of the femoral and tibial condyles, or both, was so complete that restoration of the joint was obviously impossible, the wisest plan was to proceed at once with primary resection. This course was justified,

however, only if the structures were so hopelessly destroyed that reparative surgery offered no possibility of securing a functioning joint.

If the injury was such that it was not possible to seal off the joint cavity without internal fixation of the fracture, a hip spica or Tobruk splint was applied and the patient was dispatched to the rear as soon as his condition permitted. This type of problem was not suitable for management in an evacuation hospital but was, instead, the responsibility of a general hospital.

Treatment in the General Hospital

As a rule, a patient in good general condition could be evacuated in plaster to a general hospital within 48 hours after debridement. Here, the next phase of treatment was instituted. The knee was examined for excess fluid, which was usually present. The fluid was aspirated and the joint irrigated with physiologic salt solution, introduced through one or two needles. When the irrigation had been concluded, penicillin solution (10,000 units in 5 cc. of physiologic salt solution) was introduced into the joint. This procedure was repeated at 24- to 48-hour intervals, depending upon the temperature reaction, the degree of edema in the tissues, the character of the fluid from the joint, and the patient's general condition. If for any reason the patient could not be evacuated, the procedure just described was carried out in the evacuation hospital.

Delayed primary closure of the skin was performed anywhere between the 4th and 10th days, depending upon the local condition of the wound and the presence or absence of joint complications.

If the patient could not be evacuated within 2 weeks, a remedial regimen was begun while he was still in traction, the exact time depending upon the circumstances of the individual case. In the occasional case in which the joint had not been opened, movement was begun within a few days after wounding. If arthrotomy had been performed but no fracture was present, exercise was begun as soon as the wound had healed, which was usually within 2 or 3 weeks. If a fracture was present, movement usually had to be deferred for a somewhat longer period, depending upon the type and location of the fracture and its current status.

The chief emphasis was on quadriceps-setting exercises. Failure to employ them for all patients with any kind of disability of the knee accounted for many inferior results. This was not, however, always the fault of the orthopedic staff. When admissions were at a peak, casualties with bone and joint injuries had to be dispersed to other surgical wards and to medical wards, and trained personnel was not usually sufficient to supervise them.

Suppurative Arthritis

If an infection of the soft tissues did not involve the joint capsule or communicate with the joint, the end results of joint surgery were unlikely to be

affected by it. Suppurative arthritis, however, was a constant hazard in military practice in all joint surgery and was the most dreaded complication of penetrating wounds of the knee joint. A normal joint was almost impossible of attainment after it had occurred. If the infection persisted for any length of time, extensive destruction of cartilage and bone was almost inevitable. In earlier wars, amputation was often required to save the patient's life. With the improved technical methods and efficient drugs available in World War II, deaths were rare and amputation was almost never necessary, but the functional results were none too good.

Suppurative arthritis usually appeared within the first week after operation or injury. The patient first complained of extreme discomfort in the joint, then of excruciating pain on the slightest movement. Swelling and tenderness were progressive. The rise in temperature was often abrupt. If the rise was gradual, the fever reached a peak of 103° to 104° F. within a few days and then rapidly assumed septic (picket fence) characteristics, with the trend generally upward.

All military experience has proved that there is no satisfactory method of draining the knee joint. Some surgeons attempted it by the use of two large parapatellar incisions, with a third incision behind the medial ligament and a fourth just posterior to the lateral ligament. These relieved the tension of the purulent exudate, but pools of it still remained in the deep recesses of the joint and a film was maintained between the surfaces in close contact, where it was held by capillary attraction between the condyles and between the menisci and the condyles. It is at these points of contact between bones that the earliest destruction of cartilage occurs in suppurative arthritis of the knee joint and that the greatest damage occurs as the lesions advance. The medial femoral condyle is usually the first affected.

What the French termed secondary resection, to distinguish it from primary resection of the knee joint practiced immediately after injury, was employed in an occasional case of suppurative arthritis of the knee joint. The French had employed this procedure even before World War I, but American surgeons were slow to take it up in World War II. To cut through infected soft tissue, bone, and cartilage, and to disturb areas of resistance seemed a violation of surgical principles, even though the objective of the operation was to shorten the septic course by removing feebly resistant cartilage, as well as infected bone and synovia. Once these structures had become infected, infection was likely to be persistent. Life and limb could therefore be saved by accepting the fact that suppurative arthritis results in a permanently damaged joint which is either ankylosed or is extremely painful on motion. Resection eliminated tissues of low vitality which harbored infection and at the same time secured really adequate drainage. French surgeons were more liberal in their indications than American surgeons, who limited the method to suppurative arthritis of the knee joint which was so extensive that there was no hope of regaining joint function. The optimum time for its performance was within the first 2 weeks.

Of the various incisions through which resection could be done, the most satisfactory was an elliptical transverse incision, through which the patella could be removed. Operation was preferably performed with a tourniquet in place. The anterior and posterior cruciate ligaments were divided and the knee joint was flexed and supported with a rolled towel in the bend. The femoral condyle was sawed off at the highest possible level, that is, just proximal to the intercondylar fossa, and the remaining cartilage was stripped free from the underlying bone. The tibial condyles were then sawed off, the excision being as conservative as was consistent with complete removal of all joint surfaces. Cuts were made so that flexion of 5 to 10 degrees resulted at the knee. The synovial membrane was completely excised.

If a tourniquet had been used, it was removed at this stage of the operation. Drains were placed at the angle of the incision. A single heavy wire suture was sometimes placed through the anterior margins of the bones, to prevent their slipping forward and backward. A few sutures were also inserted to approximate the skin loosely and prevent retraction. If the original wound was posterior, it was enlarged and used for dependent drainage. After the wound had been dressed, the limb was put up in a plaster-of-paris spica.

If posterior drainage had not been instituted, the patient was placed in the prone position at intervals. Drains were removed in from 5 to 10 days. The plaster spica was changed as often as necessary. If abscess formation developed, additional drainage was instituted.

Analysis of Cases

The management of 50 penetrating and perforating wounds of the knee joint in 49 patients treated at the 19th General Hospital during a 3-month period in the spring of 1945 is typical of the problems presented by this type of injury in the late months of World War II in the European theater.² Sixteen of the patients were United States Army personnel, and 33 were prisoners of war. From that standpoint, as already noted (p. 63), conditions of treatment were less favorable than they probably would have been in a group of patients which did not include prisoners of war.

In 19 of the 50 cases, there were no associated fractures of the patella or the articulating ends of the tibia and femur. From that standpoint, conditions of treatment were somewhat more favorable than they frequently were in such injuries. In the remaining 31 cases, the fractures were distributed as follows: Femoral condyles, 12; patella, 6; tibial condyles, 4; patella and femoral condyles, 4; patella and tibial condyles, 3; patella, femoral and tibial condyles, 1; and femoral and tibial condyles, 1.

Initial surgery.—In 40 of the 50 injuries, formal arthrotomy had been done at the time the wounds were debrided, most often through an incision separate from the original wound; in the remaining cases, the arthrotomy incision was incorporated in the battle-incurred wound. In 34 instances, the

² Semiannual Report, 19th General Hospital, European Theater of Operations, 1 January-30 June 1945.

joint was explored through either a medial or a lateral parapatellar approach; in 6 instances, both a medial and a lateral incision were necessary.

In 7 of the 10 cases in which arthrotomy was omitted at initial wound surgery, the patients were prisoners of war. In 2 other cases, penetration of the joint was not recognized in the forward installation, and the injury was thought to be only a soft-tissue wound. In the other case, the omission was deliberate.

While the records were not always clear on these points, it seemed likely that all but 2 or 3 of the 40 arthrotomized patients had been treated by the instillation of penicillin (10,000 to 50,000 units) into the joint at the time of debridement and that most of them had received both penicillin and sulfadiazine at this time. At the general hospital, prisoners of war received sulfadiazine systemically both before and after reparative surgery but were given penicillin only when necessary to control severe infections. United States Army patients received both penicillin and sulfadiazine systemically before and after operation.

Management of these 50 injuries in the 19th General Hospital is analyzed from several standpoints. There is necessarily some overlapping of figures.

Delayed primary closure of soft-tissue wounds.—Delayed primary closure of the soft-tissue wounds was undertaken in 32 cases in which initial arthrotomy with closure of the capsule had been done. In 30 cases, there was no special problem. The edges of the wound could be brought together without tension and very little manipulation was necessary. Drainage was seldom necessary because dead space could be obliterated. The interval between closure of the wound and initial wound surgery ranged from 4 days in 5 cases to 16 days in 1 case. In all but 8 of the 32 cases, closure was effected between the 5th and 10th days. After operation, the knee was immobilized in a single plaster-of-paris spica. If the patient had not been evacuated at the end of 2 weeks, knee motion was started, usually while skin traction was still in effect.

In 20 of these 32 cases, primary healing followed reparative surgery. In 3 instances, the wounds became superficially infected. In the other cases, evacuation was necessary in from 4 to 6 days, and evaluation of the end results of wound closure was not possible within this period; there was, however, no evidence of infection in any instance when the patient was evacuated. In the cases in which the patients were under observation long enough to permit some evaluation of end results, it seemed likely that satisfactory function would be secured.

Delayed primary closure of capsule.—In 10 cases, delayed primary closure of the capsule of the knee joint was carried out in the general hospital, in 2 instances with closure of the skin wound at the same time. In 4 other cases, the soft-tissue wound was closed 4 to 5 days after closure of the capsule. In all 6 cases, the immediate results were good, the wounds being completely healed within 2 to 3 weeks after the original injury had been sustained. In 2 other cases, the patients had to be evacuated before closure of the soft-tissue wound could be accomplished.

In the 2 remaining cases, the attempt at delayed closure of the capsule failed. Both patients were prisoners of war.

Case 29.—In this case the synovial membrane had been sutured but the capsule had been left open at initial wound surgery. The synovial closure did not heal well, and, when the patient was admitted to the general hospital 6 days after wounding, there were 3 openings into the joint. Penicillin had been instilled into the joint at debridement, but systemic penicillin therapy had apparently not been instituted.

Although the soft-tissue wound appeared clean and ready for closure when the patient was received, doubt was felt about the status of the joint. The openings in the synovial membrane did not permit adequate visualization, and wide arthrotomy was done 3 days later. The degree of intra-articular destruction revealed made it clear that initial wound surgery had not been adequate. Six days after this operation, infection in the joint was evident, and drainage of the wound had to be instituted.

There are three lessons in this case: (1) Complete removal of all intra-articular devitalized tissue and foreign material is essential in all wounds of the knee joint. This is not possible if arthrotomy is not carried out. (2) Closure of the joint cavity is best accomplished by closure of the capsule, and not only of the delicate synovial membrane, which frequently permits leaks at the suture line. (3) Penicillin, no matter how administered, is not a substitute for adequate surgery.

Case 42.—This patient had reparative surgery 7 days after wounding. The capsule was closed under moderate tension, and the very extensive soft-tissue wound was partly closed at the same time. The newly sutured portion of the capsule was left exposed, for subsequent coverage with a skin graft. The capsular wound broke down in part, and a second attempt at suture also failed. When the third attempt was made, the edges of the capsular defect were found to be so friable that a third failure was regarded as inevitable.

When the patient was evacuated, there seemed little doubt that the end result would be loss of function, partly because of the original bone and joint wound and partly because of failure to close the joint capsule at initial wound surgery. Regardless of the status of the articulation, the open capsule, with contamination and inevitable low-grade infection, was an additional liability. In this case, successful closure might possibly have been accomplished without tension by mobilization of muscle, fascia, and some capsular substance, the capsular mobilization being accomplished through partial tissue thickness in order to avoid a new opening into the joint.

In 3 cases, all in prisoners of war, closure of the joint cavity was accomplished by the use of skin; the considerable loss of capsular tissue would have made closure impossible otherwise. In the first case, a portion of the skin wound was sutured over the portion of the defect which could not be closed; the portion of the skin wound overlying the sutured capsular defect was left open. In the second case, flaps of skin were brought down over the capsular defect, the remainder of the skin wound being left open. In this case, there was an associated comminuted fracture of the lateral femoral condyles, but most of the articular surface was intact and extensive redebridement was not necessary. In the third case, the same technique was used. In all 3 cases, the joint capsule was successfully sealed off, and the portions of the skin wounds which had been left open were closed between the fifth and seventh days after closure of the capsule. In the first and second cases, healing was satisfactory. In the third, superficial necrosis of the skin flaps occurred but was not serious. It did, however, delay recovery. The other patient whose

capsular wound had been closed by means of skin flaps was discharged 45 days after operation, with function from 180-degree extension to 100-degree flexion.

As all these cases show, the first essential of management of a wound of the knee joint is adequate debridement of the joint as well as of the soft-tissue wound. The second essential is the complete, tight closure of the joint capsule. If capsular defects do not permit this kind of closure, closure must be effected by mobilization of whatever deep structures may be available. If this is not possible, then closure of the defect with skin must be attempted, counter-relaxing skin incisions being used as necessary. If large capsular defects are left open at the initial operation, they cannot be closed as successfully at a later date.

Omission of initial arthrotomy.—In 6 of the 10 cases in which formal arthrotomy was omitted at debridement, the wounds were penetrating and in 4 they were perforating. Associated fractures were present in 4 cases (2 comminuted fractures of the patella, 1 fracture of the medial femoral condyle, 1 fracture of the patella and tibial plateau).

In the 6 cases in the nonarthrotomized group in which fractures were not associated with the joint injuries, conditions were favorable for uncomplicated recovery. In all these cases, the joint injury was caused by small shell fragments of high velocity, and intra-articular damage was apparently slight. Aspiration of blood from the joint, with instillation of 10,000 to 20,000 units of penicillin into the joint and a short course of systemic penicillin, was the treatment of choice. Early motion (within the first week after wounding) in traction resulted in rapid return of function.

In 3 of the 4 instances in which fractures were associated and in which free fragments of bone were found in the joint, infection did not occur, although in all of them soft-tissue damage was quite extensive. In the fourth case, an instance of a comminuted compound fracture of the patella and tibial plateau in a prisoner of war, the joint was not opened widely when the original debridement was done, and foreign bodies were permitted to remain in situ. The patient had received systemic penicillin, with local instillations into the joint, and sulfadiazine by mouth. The knee joint became infected, and a spreading cellulitis of the thigh developed. Treatment consisted of penicillin and sulfadiazine therapy, local heat, and traction. When arthrotomy was subsequently carried out, metallic foreign bodies and loose bone fragments were removed from the joint. The synovial membrane was closed, and early joint motion was started in traction. Two months later, the wounds were healed, and the range of motion was from 180-degree extension to 24-degree flexion.

The results in these 10 cases were, on the whole, better than might have been expected in the light of the omission of arthrotomy at initial wound surgery. They must not, however, be assumed to be the rule when this practice is followed. Battle wounds of the knee joint are best treated by (1) formal arthrotomy, which permits adequate debridement through an incision which provides visualization of the entire interior of the joint, and (2) tight closure of the capsule. Failure to close the capsule is always an invitation to infection.

Wound infections.—Eight of the fifty wounds of the knee joint in this series were infected when the patients were received in the general hospital. In 1 instance, the infection was limited to a small, localized collection of purulent exudate in a medial wound. The infection did not communicate with the joint, and the lateral wound in the same knee was clean. Delayed primary closure of both wounds was promptly accomplished, and, while the end result is not known, it was thought that the infection would not influence the outcome of the injury in any way.

In the other 7 cases, in all of which compound comminuted fractures were also present, the infection was serious and involved the joint. In 5 cases, debridement and arthrotomy had been performed from 24 to 72 hours after wounding. In the 2 other cases, debridement of the soft-tissue wound had been performed 48 hours after wounding, but in each instance arthrotomy had been omitted. The amount of necrotic debris found in these wounds and joints when reparative surgery was undertaken in the general hospital was a clear indication of the inadequacy of the initial wound surgery. The basic cause of each of these 7 infections was a severe joint injury, considerable soft-tissue and intra-articular damage, late and inadequate debridement or both, and, in 2 cases, omission of arthrotomy.

In 6 of the 7 infected cases, the records indicated that chemotherapy and antibiotic therapy had been administered both locally and systemically, according to a satisfactory regimen. In the seventh case, the patient had been operated on in a German hospital and had certainly received no penicillin; the record did not indicate whether he had had sulfadiazine. In the eighth case, the record contained no information at all about chemotherapy.

There were 4 postoperative infections. One, in a United States soldier, was a trivial-stitch abscess, readily controlled by removal of the sutures and the application of heat. Two of the 3 infections in prisoners of war were also superficial and readily controlled. In the remaining case (case 29, already described), a severe infection of the joint and a spreading periarticular infection required radical surgery. The infection at one time threatened the vitality of the limb, but it was eventually controlled by combined surgery and penicillin therapy.

Immediate functional results.—The final outcome of these 50 wounds of the knee joint is not known. Under the theater holding policy, particularly in the last days of the war, patients had to be evacuated too promptly to permit the necessary observation. In 10 cases, however, early functional results could be evaluated. In 1, in which there was a compound comminuted fracture of the femoral condyle, movement 42 days after wounding was from 180-degree extension to 100-degree flexion. The immediate results in the other 9 cases, in none of which fractures were present, are summarized in table 19.

TABLE 19.—*Immediate functional results in 9 penetrating wounds of the knee joint*

Case No.	Days after wounding	Range of motion in degrees (expressed in extension to flexion)
1.....	18	180-140.
2.....	35	180-90.
22.....	60	All movements free; to duty. ¹
33.....	56	180-90.
34.....	42	180-55. To duty.
37.....	52	175-85.
41.....	48	180-150.
43.....	60	180-40.
46.....	120	180-35.

¹ Information secured by followup letter.

APPENDIX A
Pertinent Directives

Cir 96

Hq ETOUSA

15 Dec 1943

* * * * *
II—ENLISTED MEN: DISPOSITION OF WHEN PHYSICALLY OR
MENTALLY UNQUALIFIED.

1. When an enlisted man is considered by his immediate commanding officer to be physically or mentally unqualified to perform his assigned duties or any other appropriate duty within the unit, under the general policy as contained in Par 2, WD Cir 293, 11 Nov 1943, action will be taken as follows:

a. A physical examination will be made to determine whether the subject enlisted man is physically or mentally qualified to perform any duty within his unit.

b. In event the enlisted man is found to be physically or mentally unqualified to perform any appropriate duty within the unit, his case will be reported through channels with applicable recommendation for his reassignment within the command or his transfer to the detachment of patients of an SOS, ETOUSA, hospital. When the enlisted man is transferred to an SOS, ETOUSA, hospital, the report of physical examination directed under a above, together with his service records and allied papers, will be forwarded to the commanding officer of the hospital.

c. The commanding officer of the hospital will determine whether the man can be utilized in the service or is to be discharged under current regulations.

d. Enlisted men who are to be retained in the service will be transferred from the hospital to the 10th Replacement Control Depot, SOS, ETOUSA, if formerly assigned to the ground forces or SOS, or to the 12th Replacement Control Depot, Eighth Air Force, if formerly assigned to the army air forces. At the time of transfer the commanding officer of the hospital will forward to the depot commander a report concerning the man, which will include a statement as to physical and mental qualifications and duty limitations.

e. The commanding officer of the replacement depot will take the necessary action to effect reassignment of such enlisted men to appropriate units.

2. The CG, Iceland Base Command, is authorized to make such modifications as are necessary to accomplish the above directed action.

* * * * *

BY COMMAND OF LIEUTENANT GENERAL DEVERS:

DAVID G. BARR,
Brigadier General, GSC, Chief of Staff

OFFICIAL:
s/ RALPH PULSIFER
HRS.

RALPH PULSIFER
Brigadier General, USA, Adjutant General.

DISTRIBUTION: "B"

OFFICE OF THE CHIEF SURGEON
EUROPEAN THEATER OF OPERATIONS

File: 704. X 701.

15 May 1944

CIRCULAR LETTER NO. 71

SUBJECT: Principles of Surgical Management in the Care of Battle Casualties.

* * * * *

5. *Surgical Procedures.*

a. Dressings. Ideally, the primary phase of treatment will be completed in the first unit reached that is equipped to provide it. The dressing is to then be left undisturbed until the patient reaches a third echelon unit for operation. There are certain safeguards and adjustments that must take place en route, but these *do not include inspection of the wound by removal of the dressing unless definite indications for so doing are present.* A compound fracture case may be halted at the Clearing Station for more adequate immobilization or resuscitation, but the wound should not be re-dressed unless necessary to arrest continuing hemorrhage. A wound will not be re-dressed solely for the purpose of re-applying local sulfonamide. Oral administration is sufficient safeguard.

The same principles apply after operation has been completed and the patient is being evacuated to the rear. Uninformed hands do unnecessary dressings. The best safeguard for a patient is an adequate and legible record that accompanies him, which makes it possible for a receiving officer to refer to the record rather than looking at the wound. Infection arising from contamination incurred at the time dressings are changed, may make impossible secondary suture of wounds after debridement and arrival at a third echelon unit.

b. Debridement of wounds. This is the basis of the proper treatment of all battle casualties. It is definitely more important than chemotherapy, and reliance on the latter *must not* diminish devotion to the proper surgical treatment of wounds. Use *ample incisions*, practice *minimal removal of skin and bone*, and *maximum removal of all dead and devitalized muscle.* *Never close primarily wounds debrided under field conditions.* Pack wounds open lightly, *never plug tightly.*

Under favorable circumstances, it is desirable that severed nerves and tendons should be approximated, preferably with metallic or non-absorbable sutures (see Manual of Therapy, ETO).

c. Amputations. Amputations for trauma will be a circular open (guillotine) amputation at the lowest possible level, followed by the application of skin traction. Skin traction will be applied immediately and must be maintained during all stages of evacuation, including evacuation to the Zone of Interior, and until the stump is completely healed. Skin grafting will not be used as a substitute for skin traction.

* * * * *

8. *Secondary Closure.*

a. Although the first principles for the military surgeon to bear in mind is not to close the wound he has freshly debrided, it is essential that he close this wound at the earliest moment that is safe. Early closure means limitation of infection and fibrosis, and an earlier restoration to duty. If the primary debridement has been thorough, small wounds may be closed as early as the third day, though the average wound not until the fifth day. Observation of the signs of inflammation, such as discharge, reddening, pain and swelling, will determine whether or not a wound can be closed. It is wiser not to dress the originally debrided wound until the day when secondary closure might be practical, since each dressing invites contamination of the wound. If closure is considered safe, it should be done loosely without undermining the edges or using sharp instruments, and by using retention sutures of silk, or silk-worm gut, spaced widely apart and loosely tied. Should mild infection appear, hot, moist dressings may save breaking down of the wound and hasten the healing process. Any signs of severe infection require immediate removal of the sutures.

b. Closure of wounds with fractures should only be undertaken when full penicillin therapy is being practised and when all the signs of infection are absent.

c. Wounds closed early, before the establishment of granulation tissue or scar tissue, are easier to close than those closed after one or two weeks. In wounds that have been open for a long time, skin grafting is often better than closure by suture. If the original debridement has been practised with the minimal of skin removal, as suggested above, closure by sutures will be simple.

d. Removal of sutures from such secondary closures should not take place before 10 days unless stitch infection develops. After removal of the sutures it may be wise to maintain approximation of the wound edges with adhesive plaster.

9. *General Principles to be followed in the Use of Plaster Casts.*

a. No circular bandages, dressings, or strips of adhesive shall be used under a plaster cast, as these constrict the extremity and may cause extensive damage if swelling of the part occurs.

b. Adequately padded plasters are probably safer in average hands. Padding should be applied to all bony prominences such as malleoli and heels, knees, particularly over the head of the fibula, wrists and elbows. In addition, sufficient padding should be used over the soft parts to permit some swelling within the cast.

c. *All layers of plaster, sheet wadding or dressings must be cut thru down to the skin immediately after the application of a cast following an operation or manipulation. Swelling of the part will occur and unless all layers of the plaster padding and dressings are cut thru, it will be impossible to spread the cast to prevent extensive damage when swelling occurs.*

d. Attention should be paid to the position of the extremity encased in plaster. The foot should be at a right angle to the leg, the knee should be in 10-15° of flexion, the hip should be in neutral position or slight flexion. The wrist should be supported in neutral position to prevent wrist drop, and the elbow ordinarily is best supported at a right angle. In these positions the patient will transport comfortably, will not take up undue space, and the tendency to develop troublesome fixed deformities will be minimized.

e. A line diagram in indelible pencil should be inscribed on the cast, indicating the approximate location of fracture and position of fragments. The number of the unit, date of injury, date of operation and type of operations should likewise be written on the cast so that if the Field Medical Record is lost, a reasonable satisfactory substitute record will be readily available.

f. Either a platform or a loop or wicket of plaster should be applied to the foot of the cast in order to protect the toes from pressure of blankets, bed clothes, etc. Plaster applied to the hand should be trimmed back to the proximal palmar crease to permit full flexion of the fingers and metacarpal phalangeal joints.

* * * * *

For the Chief Surgeon:

s/J. H. McNINCH
J. H. McNINCH
Colonel, Medical Corps,
Executive Officer.

OFFICE OF THE CHIEF SURGEON
EUROPEAN THEATER OF OPERATIONS

File: 704.

30 July 1944

CIRCULAR LETTER NO. 101

Care of Battle Casualties

1. The information contained herein is supplemental to Manual of Therapy, ETO, 5 May 1944, and Circular Letter No. 71, Office of the Chief Surgeon, subject: "Principles of Surgical Management in the Care of Battle Casualties," dated 15 May 1944, and is based on the experience acquired during the first five weeks of operations.

* * * * *

3. *Wounds.*

a. Wounds will not be plugged or packed with vaseline gauze. Only sufficient gauze should be used to keep the wound temporarily open.

b. Sulfonamides are being dumped in excessive quantities in wounds, and this makes subsequent repair difficult.

c. Wounds *must not be closed by sutures* at the time of the first debridement, except for the following:

(1) Neurosurgical injuries.

(2) Thoracic injuries.

(3) Wounds of eyelids.

(4) Certain maxillofacial injuries, as outlined in the Manual of Therapy, ETO.

d. Penetrating wounds of the paranasal sinuses should be thoroughly explored, foreign bodies and blood removed and external drainage provided at the original operation. Drainage of the antrum into the nose is the method of choice unless the wound has destroyed so much tissue that external closure is not possible. The frontal sinuses should be drained through the wound or through an incision to allow opening in the floor of the sinuses.

e. The routine culture of wounds is unnecessary, and wasteful of time and materials. Cultures should be limited to those wounds where there is clinical evidence of infection and where they may contribute to its subsequent clinical management.

f. Wounds seen late, after wounding, without debridement, may be debrided in the usual manner.

g. Wounds can usually be closed within 3 to 5 days after debridement. A satisfactory preparation of the wound for secondary closure has been the application of warm saline dressings. Chemotherapy locally in the wound at the time of secondary closure is not necessary; penicillin therapy should be resumed before and after secondary closure in all large wounds.

h. As a rule, foreign bodies which interfere with function or wound healing should be removed. Modern chemotherapy obscures the signs of local infection only *temporarily* and many times delayed infection, with breakdown of the wound, may result after a long interval.

i. Continued local and excessive applications of sulfonamides in wounds are detrimental to wound healing, produce dermatological lesions, often increase blood levels above safety limit, and are unsupported scientifically as the proper therapy.

* * * * *

5. Gas Gangrene.

a. Incidence of serious infection with clostridia is fortunately low up to the present time, and surgeons have shown a wise discrimination between diffuse myositis and cellulitis. This has restricted amputation, led to recovery by simple incision, excision of involved muscle and adequate drainage.

b. Routine culture of wounds is unnecessary unless there is clinical suspicion of gas bacillus infection. Gas-forming organisms can commonly be cultured from a wound, and such findings should not influence the surgical treatment unless consistent with the clinical diagnosis. Only in clinical cases of gas gangrene infection should cultures be taken and sent to the First Medical General Laboratory for final identification of the organisms.

c. Amputations have in some cases been too radical. Always demand a consultation and always explore locally in wound before amputation. In many cases the apparent diffuse involvement, as shown by a swelling, crepitation and discoloration of the skin, has extended far above the actual muscle involvement. Failure to appreciate that amputation or muscle excision can be carried out at a much lower level has at times resulted in the needless high amputation of the thigh or upper arm. Extensive incision and drainage above the level of amputation is commonly required in such instances.

d. Following amputation for widespread clostridial myositis, skin traction should not be applied for the first 24–48 hours, since some cases thus treated have had unfortunate results because of restricting dressings. Such cases should be held as non-transportable until skin traction is applied.

e. In performing the circular amputation, the skin should always, if possible, be longer than the underlying soft tissue and bone. Except in amputations following clostridial infection, skin traction should in every instance be applied immediately. The following dressing is suggested as an adequate and comfortable method of protecting the stump and securing skin traction during the period of evacuation or hospitalization:—

- (1) Dress the stump with fine mesh gauze.
- (2) Apply circular roll of stockinet to the stump; roll this proximally.
- (3) Apply tincture of benzoin to the skin up to the cut edge.
- (4) To the distal 1" of skin apply an ointment of equal parts of zinc oxide and castor oil.

(5) Apply ace-adherent to the skin of the stump up to the ointment, and then roll the stockinet over the stump and dressing.

(6) Apply several layers of sheet wadding on the stockinet and a light plaster of paris cuff over this, incorporating a wire ladder splint anchored at both ends. Traction is obtained by tying the stockinet to this wire. In case there is a short arm or high thigh stump, the wire ladder splint may be incorporated in a short shoulder or hip spica plaster of paris bandage. In case drainage is excessive, the stockinet distal to the amputation may be split into two or more tails and a spreader employed if desired. The intact stockinet tends to cone the stump down to desirable size and may be preferable.

* * * * *

6. *Plaster Splints.*

a. These are being applied too thick, wasting material and time both in application and removal.

b. If bilateral spicas are applied, they must be litter width, reinforced with a strut placed posteriorly.

c. All initial circular plaster of paris dressings, following trauma manipulation or operation, must be *split to the skin* and *slightly spread*.

d. In arm casts used for forearm or wrist injury, always trim the cast

back to the proximal palmar crease so that full metacarpophalangeal flexion can be maintained.

* * * * *

For the Chief Surgeon:

s/ J. H. McNINCH
J. H. McNINCH,
Colonel, Medical Corps,
Executive Officer.

HEADQUARTERS
EUROPEAN THEATER OF OPERATIONS
UNITED STATES ARMY

Office of the Chief Surgeon

File: 304

8 November 1944

CIRCULAR LETTER NO. 131

Care of Battle Casualties

The following instructions are supplemental to Manual of Therapy ETO, 5 May 1944; Circular Letter No. 71, 15 May 1944; and Circular Letter No. 101, 30 July 1944, Office of the Chief Surgeon.

* * * * *

1. *Treatment of Wounds of Bones and Joints*

The proper treatment of those wounds involving bones and joints may be divided into the early stage in Field or Evacuation Hospitals and the later stage when the wounded arrive at a General Hospital. The early treatment entails:

a. Debridement of the wound. Skin and bone will be conserved to the maximum degree. Devitalized muscle will be excised, leaving viable muscle. Fascial planes should be widely opened by longitudinal and transverse incisions so that no tension exists. All bits of clothing and available metallic bodies are to be removed but a prolonged search for metallic foreign bodies will not be made at this time. The wound will be lightly dressed with vaseline gauze, introduced into the depths but not packed.

b. Immobilization of fractures for evacuation. Field and Evacuation Hospitals and any type of medical unit acting as a "transit" hospital will prepare fractures for early evacuation with comfort and safety to the patient. They will not be responsible for the anatomic reduction of these fractures.

(1) *Fractures of the femur* are for the most part most comfortably immobilized in a double circular plaster of Paris spica bandage extending from the toes of the affected leg and from the knee of the sound leg. This should be re-enforced by a strut placed *posteriorly*, and the legs should not be spread more than litter width. The knee should be slightly flexed.

The Army ring splint is, for the most part, to be employed as an emergency measure. The traction strap or clove hitch, when left on the foot for periods of time exceeding 6 or 8 hours, almost invariably results in skin necrosis. If it is necessary to leave the Army ring splint on beyond the Field, Evacuation or other "transit" hospital, *adhesive plaster must be applied to the leg as a means of traction.* The Army hinged splint for upper extremity fractures is extremely uncomfortable and it should be discarded at the first installations where a plaster of Paris splint can be employed.

The use of the Army ring splint with adhesive plaster traction, a posterior moulded plaster of Paris splint applied from ankle to buttock and re-enforced and stabilized with a few rolls of plaster over the metal side arms of the splint, may be a satisfactory means of transportation in selected fractures of the femur in this theater. It should not be used for fractures of the upper third of the femur and it can not be employed if there are wounds below the knee as well as above. No patients will be returned to the Zone of the Interior with this form of splint.

(2) *Fractures of the tibia and fibula* should be immobilized in a circular plaster of Paris bandage from toes to groin; knee flexed 15 degrees, the foot in neutral position at 90 degrees to the long axis of the leg.

(3) *Fractures of the feet* should be immobilized in a circular plaster of Paris boot extending from the toes to just below the knee, with foot in neutral position at 90 degrees to long axis of leg. Gentle soap and water scrubbing of these wounds of the feet will minimize the chance of infection.

(4) *Fractures of the humerus* should be immobilized by a plaster of Paris spica bandage with arm held forward and medially rotated so that the forearm rests in front of the body. A plaster of Paris Velpeau bandage may be used for evacuation within this theater, but not to the Zone of the Interior. *The hanging cast is not an acceptable means of fixation for transportation and will not be so employed.*

(5) *Fractures of the forearm and wrist* should be immobilized by a circular plaster of Paris bandage extending from mid-brachial region, with the elbow flexed at from 90 to 110 degrees to long axis of humerus. This splint should not extend distal to the metacarpo phalangeal joints.

* * * * *

ALL PRIMARY CIRCULAR PLASTER OF PARIS DRESSINGS WILL BE SPLIT TO THE SKIN AND SLIGHTLY SPREAD. NO CIRCULAR BANDAGE OR ADHESIVE PLASTER OR SHEET WADDING WILL BE LEFT UNDIVIDED UNDER A SPLIT PLASTER OF PARIS BANDAGE.

* * * * *

c. Treatment of wounds of bones and joints in General Hospitals. As soon as the patient arrives at a general hospital the plaster of Paris dressing and all vaseline gauze should be removed.

(1) *Fractures of the femur, tibia, fibula, and humerus* will be treated by skeletal traction in every instance where it is possible to achieve a beneficial result within a reasonable length of time.

(2) *Compound fractures of the forearm* may be treated with circular plaster of Paris splints or traction when feasible. Badly displaced simple forearm fractures, which cannot be reduced by other means, may require open reduction and internal fixation. Such open reduction may be applied in some instances in compound fractures of the forearm after successful secondary closure has resulted in wound healing.

* * * * *

(4) *Fractures of the foot.* Simple fractures involving the metatarsals and phalanges should not be immobilized for prolonged periods. Many of these undisplaced or slightly displaced fractures are best treated by mobilization without weight bearings. In compound fractures of the foot, every effort should be made to heal the wounds by secondary suture or skin graft. Pulp traction to the toes should be avoided. Early active motion of toes and feet should be encouraged wherever possible.

(5) *Compound fractures of long bones with loss of bone substance.* In fractures of the long bones with large initial loss of bone substance, traction because of the limited evacuation policy of this theater, will be of little benefit, and so should not be employed. Distraction in these cases is a common cause of non-union. Such patients should be returned *at an early date* to the Zone of the Interior, in appropriate circular plaster of Paris splints with every effort made in this theater to close the wound secondarily.

(6) *Compound fractures of long bones with major nerve injury.* In compound fractures of the long bones with associated injury to major peripheral nerves, the nerve injury takes precedence, and these cases should be treated as outlined in paragraph 2, a(2) below.

(7) *Holding periods required for long bone fractures treated by skeletal traction.* Compound fractures of the femur, tibia and fibula, and humerus that may be treated with skeletal traction comprise slightly less than 10% of all battle casualties. The holding periods for these fractures in the ETO are roughly as follows:

- | | |
|--|------------|
| (1) Fractures of the femur..... | 6-9 weeks. |
| (2) Fractures of the tibia and fibula..... | 5-7 weeks. |
| (3) Fractures of the humerus..... | 4-6 weeks. |

At the expiration of the indicated periods, these fractures should be "frozen" or "fixed" sufficiently so that they will not displace during transportation if placed in circular plaster of Paris splints as described in paragraph 1b, above.

Base Sections of this theater which have an authorized holding period insufficient to allow completion of skeletal traction on these long bone fractures should immediately evacuate these patients to a Base Section where such skeletal traction may be initiated and maintained for the indicated period of time. At this date these long bone fractures may be treated by skeletal traction

only in the UK Base, and so these cases should be evacuated from the continent at the earliest practicable moment.

(8) *Metallic external fixation of fractures.* The use of Steinmann pins incorporated in plaster of Paris, of metallic external fixation splints has led to gross infection and/or ulceration in a high percentage of cases. This method of treatment will *not* be employed in the ETO.

(9) *Open reduction and internal fixation* of long bone fractures must be reserved for those few cases in which skeletal traction has failed to secure or maintain reduction after adequate trial. Such open reductions may be performed only on simple fractures or on compound fractures where the wound has healed. Open reduction should not be attempted until 2-3 weeks have elapsed following healing of the wound.

(See paragraph 1*d* below)

(10) *Wounds involving major joints.* These wounds should be closed at the earliest moment by secondary suture or skin graft. The synovia should, if possible, be closed at time of debridement. If the joint surfaces are not badly damaged, early active motion should be insisted upon. If, however, the joint surfaces are so badly damaged that bony ankylosis is inevitable, the various joints should be immobilized in the following positions:

Hip joint 25 degrees of flexion. 0-5 degrees of abduction.

Knee joint 10-15 degrees of flexion.

Ankle joint 10 degrees of equinus.

Upper extremity joints should be immobilized in the positions as outlined for evacuation in paragraph 1, *b*, above. The wrist should be dorsiflexed about 40 degrees. The spontaneously ankylosed elbow joint offers the most serious problem in the upper extremity. Many of these stiff elbows may be treated later by resection.

d. Secondary closure of wounds over compound fractures. This is the greatest single advance in the treatment of this type of fracture. The incidence of serious infections is extremely low, and therefore many of the wounds may be closed by secondary suture or skin graft as early as the time of the first dressing in the general hospital. However, closure of wounds 10 days or less from the date of injury is considered to be early closure. The skin edges at this time are still mobile and, if there is little loss of skin, may be readily approximated. Closure should be accomplished by widely spaced, deeply placed, non-absorbable sutures without tension. If a skin graft is done, it may be well to clean up surface debris and small sloughs by moist dressings for 2 or 3 days prior to grafting. Delayed closure of wounds is that performed after 10 days. The new epithelium at the margin of these wounds must be excised and the edges undercut to approximate the skin edges. With large loss of skin, necessitating skin graft, no mobilization of the skin edges should be required. All patients with compound fractures subjected to secondary closure should receive penicillin parenterally, and sulfadiazine for 1-day prior to and several days after operation. Approximately 50% of these compound fractures are converted into simple fractures at the first attempt, with additional subse-

quent attempts another 35% will heal, and failure to secure healing to any appreciable extent has occurred in only 15% of those attempted.

Secondary closure of these wounds minimizes the incidence of osteomyelitis, conserves bone, and hastens convalescence. Two or three weeks after secondary closure is accomplished, neurosurgical procedures may be performed, and such few fractures as require open reduction may be so treated.

e. Amputations. The circular amputation and its subsequent treatment has been described in Circular Letter No. 101, Office of the Chief Surgeon, dated 30 July 1944. These amputations are often traumatic and the skin edges are irregular. Traction will, in most instances, effect closure of these stumps if it is adequately performed. Secondary closure of these amputation stumps by suture often leads to infection and necrosis of the skin, *and will not be performed in this theater.* Where the skin sleeve is inadequate to allow closure by traction, or the bone ends are obviously too long and protrude, revision of the stump should be performed at the lowest possible level. The skin edges should be mobilized by undercutting and the bone and soft tissues should be reamputated just sufficiently to allow closure by traction, which should be promptly re-applied *and continued.* Amputations should be evacuable to the Zone of the Interior 2-3 weeks after admission to a general hospital. It is not necessary for the stump to be completely healed prior to evacuation to the Zone of the Interior, *but skin traction must be continuous.* Split thickness skin grafts of the lower extremity will not tolerate a prosthesis and their use to cover amputation stumps is prohibited unless there is an unusual indication.

* * * * *

2. Neurosurgical Problems.

a. Peripheral nerve injuries. All available information indicates that *early repair* of a severed major nerve contributes to the perfection of the ultimate result. Not only does regeneration proceed more satisfactorily, but the surgical problem of "making up" gaps between the severed ends is tremendously simplified. An attempt is being made in this theater to repair early, through the facilities of the special treatment hospitals for neuro-surgery, as many of these cases as is practicable. The following rules for the treatment and evacuation of peripheral nerve injuries will be followed by the commanding officers of all hospitals in this theater:

(1) All wounds with associated peripheral nerve palsies uncomplicated by fractures of long bones, should be closed by secondary suture and the patient then promptly transferred to the nearest special treatment hospital for neurosurgery for definitive treatment.

(2) All major nerve injuries complicated by fractures should have early closure of wounds and adequate splinting without attempting to secure anatomic reduction of the fracture. This plan permits early suture of the nerve with later reduction of the fracture by open operation if necessary. The

restoration of length before the nerve repair is accomplished, may defeat the possibility of end-to-end suture of the nerve.

(3) There is no necessity for prolonged immobilization of extremities with peripheral nerve injuries uncomplicated by fractures. A plaster splint may be used, provided it is removed at regular intervals during the waking hours.

* * * * *

8. *Condition of Patients Evacuated to the Zone of the Interior.*

Commanding officers of hospitals returning patients to the Zone of the Interior will pay careful attention to the general physical condition of the patients, and in those cases in casts, to the condition of the plaster of Paris dressings in which they are to travel. Circular plaster of Paris splints over open wounds should be changed just prior to departure from the hospital. Careful attention to plaster technique is constantly necessary. Secondary closure of wounds will prevent plaster splints from becoming soiled and foul smelling. Secondary plaster of Paris circular splints applied weeks after injury or operation do not need to be split.

By order of the Chief Surgeon:

s/ H. W. DOAN
H. W. DOAN,
Colonel, Medical Corps,
Executive Officer.

HEADQUARTERS
EUROPEAN THEATER OF OPERATIONS
UNITED STATES ARMY
Office of the Chief Surgeon

Ch Surg 704

17 March 1945

CIRCULAR LETTER NO. 23
Care of Battle Casualties

The following instructions are supplemental to Manual of Therapy, ETO, 5 May 1944; Circular Letter No. 71, 15 May 1944; Circular Letter No. 101, 30 July 1944, and Circular Letter No. 131, 8 November 1944, Office of the Chief Surgeon.

* * * * *

2. *Orthopedic Surgery*

a. *Notes for disposition boards.*

Under the present evacuation policy to the Zone of the Interior, very few simple or compound fractures can be rehabilitated to full duty in this theater. Among the exceptions may be certain fractures incurred by key personnel occupying sedentary positions. A fracture of the clavicle, an un-

displaced fracture of the head of the radius or of the lateral malleolus, some fractures of the metacarpal bones, metatarsal bones or phalanges are cited as examples of fractures that may be returned to full duty within the present evacuation policy. There may be a few other instances of minor fractures which will require careful evaluation in order to determine whether there is any possibility of salvaging the officer or soldier involved for further duty in this theater within the time allowed.

Patients requiring elective surgical procedures for internal derangement of the knee joint or recurrent dislocation of the shoulder joint should almost invariably be returned to the Zone of the Interior for this surgery. The utmost care should be exercised in arriving at a diagnosis of either of these conditions. A sprain of the knee joint which may be rehabilitated should not be confused with an internal derangement. A recurrent dislocation of the shoulder joint should be thoroughly authenticated before this diagnosis is made.

Osteo-arthritis of a major joint with definite disability as a result, should be returned to the Zone of the Interior.

b. Amputations.

Skin traction on amputation stumps must be instituted immediately and maintained adequately and continuously except as stated in par 5d, of Circular Letter No. 101, this office, subject: "Care of Battle Casualties," dated 30 July 1944. In general hospitals this traction may be advantageously maintained by a weight suspended over a pulley. This form of traction must also be continuous. The most effective means of maintaining skin traction on the amputation stump during transportation has been described in par 5e, Circular Letter No. 101, Office of the Chief Surgeon, 30 July 1944. This skin traction should be inspected in each medical unit charged with the care or the evacuation of the patient, and if found to be inadequate, it should be reapplied immediately.

Closure of amputation stumps by suture or skin graft is not authorized in this theater. Amputees should be evacuated to the Zone of the Interior as promptly as possible with skin traction maintained throughout all stages of their journey.

c. Wounds involving the knee joint.

These wounds have been most satisfactorily treated in the following manner:

(1) A thorough exploration of the joint is performed through adequate medial and/or lateral incisions. A bloodless field should be insured by the use of a tourniquet if there is no associated damage to the femoral or popliteal arteries. The joint is completely irrigated with saline solution which should remove all blood and debris. With adequate retraction, a careful debridement of all damaged tissue, bone, cartilage and synovia is performed with removal of all foreign bodies from the joint cavity. If a meniscus is detached or damaged it should be excised. After further irrigation the synovia and capsule are snugly closed with a single layer of interrupted sutures. If there is loss of capsular substance, the closure may require, in some instances, the utilization of a fascial flap.

(2) After closure of the capsule 10,000 units of penicillin in 5 cc of normal saline are injected into the joint cavity. The tourniquet should be released and hemostasis insured by the ligation of all bleeding vessels. The knee joint should be immobilized by means of a plaster of paris spica bandage, knee slightly flexed, with a window over the joint. The joint is aspirated 48 hours after operation, gently washed with saline solution and another 10,000 units of penicillin instilled into the joint cavity. This procedure may be repeated several times at intervals of 24 to 48 hours if necessary. Parenteral penicillin therapy is carried on throughout this period. The skin wounds may be closed 5 days after primary surgery if there is no evidence of infection.

d. Compound fractures.

(1) Supracondylar fractures of the femur with sharp spicules of bone which may damage the popliteal vessels should be immobilized with the knee flexed at 20-25 degrees to minimize the danger of this complication. At the time of primary debridement if there is found to be direct pressure against the popliteal vessels by a sharp spicule of bone, it should be excised. The excised piece of bone should be replaced at the fracture site and not discarded.

(2) *Internal fixation of compound fractures.*

A recent report from the Office of the Surgeon General on the condition of battle casualties returning from the ETO has been received February 1945. The consensus of opinion expressed by qualified chiefs of orthopedic sections, chiefs of surgical services and consultants in nineteen named general hospitals in the Zone of the Interior was that metallic internal fixation of compound fractures resulted in infection in 25 to 50% of the cases so treated. The metallic fixative agent in all of these infected cases had to be removed. Delayed or non-union has resulted in many of these patients.

In view of the adverse report on the progress of these casualties, internal fixation of compound fractures is prohibited as a routine procedure. It should be resorted to only after a thorough trial of skeletal traction has failed to secure adequate reduction, and after healing of the skin has been accomplished by suture or skin graft. The concurrence of the local orthopedic or surgical consultant will be secured in each instance where internal fixation of a compound fracture is deemed necessary. Combined injuries involving compound fractures and peripheral nerves present special problems. These will be treated at specialized hospitals designated for neurosurgical problems.

3. Penicillin Therapy.

* * * * *

c. The use of penicillin locally in all wounds is not required, but its local use in joints and chests is necessary for best results.

* * * * *

By order of the Chief Surgeon:

s/ H. W. DOAN.
H. W. DOAN,
Colonel, Medical Corps,
Executive Officer.

HEADQUARTERS
EUROPEAN THEATER OF OPERATIONS
UNITED STATES ARMY
Office of the Chief Surgeon

Ch Surg 730 x 383.6

5 May 1945

CIRCULAR LETTER NO. 39

* * * * *

SECTION II. *PROFESSIONAL POLICIES IN THE CARE OF POW'S*

1. Adherence to the basic principles of ETO policies of professional management in the care of sick or wounded enemy prisoners is desirable. Where POW's are cared for by US Army personnel, ETO professional policies will be adhered to except as noted below. Where POW's are cared for by protected prisoner personnel, greater latitude will be granted and the POW medical personnel may practice their methods of therapy unless such are found to be contrary to reasonable medical care.

2. The Manual of Therapy, European Theater of Operations, and Circular Letters Nos. 71, 15 May 1944; 101, 30 July 1944; 131, 8 November 1944; and Circular Letter No. 23, 17 March 1945, will be made available to German medical officers as guides for treatment.

3. The Commanding Officers of hospitals utilizing protected prisoner medical personnel will instruct German medical officers that skeletal traction in the treatment of long bone fractures, and closure of wounds by suture and/or skin graft is the treatment to be followed. In the hands of US Army medical officers, this treatment reduced the period of hospital treatment and subsequent disability.

4. *Treatment of fractures.*

a. Equipment for the treatment of long bone fractures by skeletal traction will be furnished German medical officers who are capable of using it. Steinmann pins or Kirschner wires may be employed. External fixation splints such as the Roger Anderson, Haines or Stoder types will not be distributed to German surgeons.

b. When skeletal traction is not employed in the management of compound fractures of long bones, treatment will be by means of circular plaster of paris splints. If wounds are not closed by delayed primary suture, the Orr-Trueta technique will be employed. Healing ordinarily takes place in time.

c. Internal fixation of simple and of compound fractures after the wounds have healed will be performed only after approval by a US Army medical officer.

* * * * *

7. *Penicillin therapy in POW's:*

a. The only indications for the administration of penicillin to POW patients will be the saving of life or limb.

b. Penicillin will not be used in the treatment of venereal disease.

c. Penicillin will *not* be issued to protected enemy personnel. It will be kept under the control of US Personnel. The Commanding Officer of the hospital concerned must approve the use and dosage of penicillin recommended in every instance where it is prescribed.

By order of the Chief Surgeon:

s/ H. W. DOAN
H. W. DOAN,
Colonel, Medical Corps,
Executive Officer.

APPENDIX B

Proposed Revision of Manual of Therapy¹ (Orthopedic Section)

CARE OF BATTLE CASUALTIES AND INJURIES INVOLVING BONES AND JOINTS

Foreword

The Manual of Therapy, European Theatre of Operations, served a useful purpose as a professional guide during the military operations in Europe. Some of the policies of treatment were changed from time to time because of the lessons learned from experience. These changes were published in Circular Letters by the Office of the Chief Surgeon. In an attempt to summarize the principles of orthopaedic treatment which were evolved in the course of the various campaigns in the European Theatre of Operations, those sections of the Manual and the Circular Letters which pertain to bone and joint injuries in battle casualties have been combined. Policies which conflict have been deleted, and a considerable amount of material which appeared to be important prior to the campaigns has been omitted in the interest of brevity.

The material has been divided into three sections:

A. Therapy in Division Installations (Battalion Aid Station, Collecting Company, Clearing Company).

B. Therapy in Army Installations (Field Hospitals, Evacuation Hospitals, Convalescent Hospitals).

C. Therapy in Communication Zone Installations (General Hospitals, Station Hospitals).

SECTION A

Therapy in Division Installations (Battalion Aid Station, Collecting Company, Clearing Company)

I. Strains and Sprains

1. *Diagnosis*: Great care must be taken to exclude the possibility of fracture. Sharply localized tenderness over bone, rather than ligament,

¹ As noted in the text (p. 161), the orthopedic section of the Manual of Therapy prepared for use in the European Theatre of Operations required considerable modification as the experience increased. A completely revised draft of this section was prepared in June 1945 by the senior consultant in orthopedic surgery, with the assistance of Lt. Col. John G. Manning, MC, and Lt. Col. William J. Stewart, MC, but was not published because of the end of the fighting in the Pacific. It is reproduced in this appendix precisely as it was prepared for publication in June 1945.

muscle, or tendon, and pain at the site of injury upon manipulation of bones at a distance from the injury are more characteristic of fracture than of sprain. If there is any doubt as to the diagnosis, the patient should be evacuated to an Army hospital where a roentgenographic examination can be made.

2. *Treatment:* The objects of treatment are:

- a. To prevent oedema and hematoma formation;
- b. To disseminate, for more rapid absorption, any hematomata which have formed.

This is best accomplished by the application of cold (where possible) to the fresh injury, by compression, and by rest to the injured part. Heat in any form as a primary treatment is illogical and harmful and *should not be applied*.

All patients with strains and sprains which do not respond rapidly to conservative treatment should be evacuated to the rear. Treatment of moderate and severe sprains of the major joints and of the back should not be attempted in the forward areas.

II. *Dislocations*

No attempt should be made to manipulate or reduce dislocations prior to a roentgenographic examination or without anaesthesia. Pain should be relieved with morphine. The patient should be placed in a litter and the affected part splinted by use of folded blankets in the position of maximum comfort. The patient should then be transferred as rapidly as possible to an Evacuation Hospital.

III. *Simple Fractures*

Simple fractures should be splinted. These patients should be transported to the Evacuation Hospital as soon as conditions will permit, but in general these are low priority evacuation cases.

IV. *Compound Fractures*

The following suggestions are made for the initial handling of patients with compound fractures due to battle injuries:

1. *Examination:* A rapid but careful examination of the patient should be made to determine the site of the injury or injuries, so that proper splinting can be applied. It is not advisable to remove the clothing from the patient for this examination. Each extremity should be examined separately, and the thorax and the back should be checked carefully.

2. *Treatment:*

- a. Shock should be treated promptly by infusion of plasma or blood.
- b. Morphine should be administered in sufficient quantities to relieve pain, but morphinism must be avoided. Subcutaneous injections of morphine are not easily absorbed by patients who are cold or who have low blood pressure and are in shock. If these conditions are present, the morphine should be administered intravenously to assure immediate relief of pain, but overdosage must be avoided. The dosage must be recorded on the Emergency Medical tag.
- c. *Wound*

(1) *Hemorrhage*: The first consideration in the local treatment of the wound should be the control of hemorrhage. Unless a large vessel has been severed, this can be done by the application of a pressure dressing. If this fails, a tourniquet must be applied. If a tourniquet is required, every precaution should be taken to guard against the dangers of resulting ischaemia of the extremity.

(a) Place the tourniquet at the lowest possible level.

(b) Attach a red tag to the tourniquet and record the time of application.

(c) Release the tourniquet and reapply it every hour. In the lower extremity it may be left in place for two hours.

(d) Evacuate the patient rapidly to a point where the hemorrhage may be controlled surgically.

(2) *Chemotherapy*: Do not place sulfonamides in the wound, but start oral administration if the patient does not have an associated belly wound.

(3) Cover wound with an ample sterile dressing.

(4) Immobilize extremity in the appropriate splint.

d. *Tetanus Toxoid*: Administer 1 cubic centimeter of tetanus toxoid to any member of the United States Forces and record on Emergency Medical tag. Administer 3,000 units of anti-tetanic serum to any other patient, unless otherwise instructed.

V. Amputations

Amputations should not be attempted in the forward treatment stations unless the extremity is almost completely detached. Complete or incomplete traumatic amputations should be treated like other compound fractures. Control pain, shock, hemorrhage and apply sterile dressing and adequate splint.

VI. Immobilization of Fractures

The following splints are recommended as emergency measures for application in the field and for immobilization during initial transportation.

1. *Femur, Knee, and Proximal Half of Tibia*: Apply the Army half-ring hinged splint and foot traction strap. The shoe must not be removed. A tendency to apply too great a degree of traction must be guarded against. If too much traction is applied, there is great danger of causing severe and disabling pressure sores over the heel cord and dorsum of the foot. If the patient is detained at any station, the ankle strap should be released temporarily.

2. *Distal Half of Tibia, Ankle, and Foot*: Apply well-padded wire ladder splints in the following manner:

a. The first one should be applied posteriorly from the tip of the toes to well above the knee.

b. The second wire ladder splint should be applied like a sugar tong, extending down the outer side of the leg around the sole of the foot (crossing over the first splint) and back up the inner side of the leg.

c. Bandage the two splints together snugly.

3. *Shoulder, Humerus, and Elbow:* Bind the injured extremity to the chest wall with triangular bandages or with a Velpeau dressing made from gauze or muslin bandages. Do not use the Murray-Jones hinged ring splint, as it is painful, difficult to apply, and dangerous.

4. *Forearm:* Apply a well-padded sugar-tong wire ladder splint, supported with an arm sling.

5. *Wrist and Hand:* Apply a well-padded wire ladder splint to the volar surface of the forearm and palmar surface of the hand.

6. *Lumbar and Dorsal Spine:* Place the patient gently on a litter, in the prone position if possible.

7. *Cervical Spine:* Place a blanket (folded so that it makes a pad three inches thick) beneath the shoulders, thus permitting the head to fall backward slightly. Place folded blankets, articles of clothing, or any other convenient object on either side of the head to reduce lateral motion of the head.

SECTION B

Therapy in Army Installations (Field Hospitals, Evacuation Hospitals, Convalescent Hospitals)

I. Strains and Sprains

1. Acute Strains

Acute strains as a rule respond rapidly to rest. The most common strain is probably that of the lumbar muscles. Absolute rest until all tenderness has subsided is recommended. The patient is allowed to become ambulatory if the pain and spasm do not return; if he continues to improve, he should be transferred to the Army Convalescent Hospital. Those patients with strains which do not respond promptly to conservative therapy should be evacuated to General Hospitals for study and treatment. Patients with chronic disabling strains should be immediately evacuated to General Hospitals for study and disposition.

2. Acute Sprains

a. *Wrist Joint:* An injured wrist should never be treated as a sprain until fracture of the navicular has been absolutely excluded. Roentgenograms in three planes should be taken. Even if no fracture line is seen in the first roentgenograms, a clear-cut history of a fall on the outstretched hand, with tenderness in the anatomical snuff box, is usually sufficient to justify immobilization in plaster for ten days. At the end of this period, sufficient absorption will have occurred to make the fracture line visible in a re-check x-ray.

b. *Ankle and Knee Joint:* Some minimal sprains may be treated in Army installations. Patients with moderate and severe sprains should be evacuated immediately, as they cannot be returned to duty within any normal holding period. Any markedly distended joint should be aspirated under aseptic precautions. The involved joint should be immobilized in the appropriate circular plaster-of-Paris splint for evacuation.

II. *Dislocations*

Dislocations of major joints should be treated as surgical emergencies. As soon as possible after the diagnosis has been confirmed by roentgenographic examination, a closed reduction under general anaesthesia should be performed. After reduction, the joint should be immobilized in the appropriate circular plaster-of-Paris splint and the patient should be evacuated as soon as possible. If closed reduction cannot be accomplished or if, for any other reason, open reduction is indicated, the patient should be transferred as rapidly as possible to the nearest General Hospital. Open reductions should not be performed in Army installations.

III. *Simple Fractures*

Only a few of the simple fractures lend themselves to reduction by manipulation in Army installations. In fractures of the long bones, it is futile to attempt reduction by manipulation if it is known that reduction cannot be maintained by the use of a circular plaster-of-Paris splint. Fractures should be immobilized and the patient should be evacuated as soon as possible to a General Hospital where he can have definitive reduction by skeletal traction and where he can remain until the fracture has become stable. No open reductions should be performed in Army installations.

IV. *Compound Fractures*

1. Because of the high morbidity and permanent disability which result from infection of compound fractures, it is essential that they receive a high priority for surgery. Only by an early, thorough, and adequate débridement can infection be prevented.

2. Shock following compound fractures of the long bones is usually severe due to the great loss of blood; this is especially true of fractures of the femur and fractures of more than one of the long bones. Sufficient replacement of whole blood is essential. Although it may appear that the patient has been adequately resuscitated prior to the time of surgery, he may easily drop back into a state of shock during the time of operation. It is frequently necessary, therefore, to continue the administration of blood during the procedure.

3. Preoperative roentgenographic examination is of value in determining bone damage and providing information as to the number, size, and location of opaque materials, besides giving some information as to the degree of soft-tissue disruption which has occurred. The x-ray films should accompany the patient to the operating pavilion, so that they will be available to provide information to the surgeon both before and during the operation.

4. *Débridement*: The value of an adequate and thorough débridement cannot be overemphasized. An adequate débridement cannot be performed unless the surgeon is able to see and differentiate what is healthy and what is devitalized tissue. It is essential to avoid further insult to the wound, endangering vital structures which, although fortunate enough to have escaped the enemy shell fragment, may not escape the careless surgeon's instruments.

The following principles of débridement in connection with compound fractures are therefore emphasized:

a. An adequate débridement cannot be performed under local infiltration anaesthesia.

b. Skin must be conserved. Excise only a very narrow margin. Rarely will it be necessary to excise more than one-eighth of an inch.

c. *Incision:* Every wound, with few exceptions, will require enlargement by incision, so that underlying damage can be visualized and dealt with properly. Incisions for enlargement of the wound ordinarily are made in the long axis of the extremity, but should be so placed that they will assist the surgeon in the General Hospital in performing the delayed primary wound suture.

d. *Subcutaneous Fat:* Remove all contaminated and crushed subcutaneous fat.

e. *Fascia:* Linear incision of the enveloping fascia is not sufficient to afford adequate drainage and prevent accumulation of blood and hematoma formation. It is, therefore, necessary also to incise it transversely. All crushed and devitalized fascia must be excised.

f. *Muscle:* Excise all devitalized muscle. Non-viable muscle does not contract when stimulated, or bleed when cut. Never cross-cut viable muscle bellies to provide exposure. Adequate exposure can be obtained by muscle-splitting incisions which are made parallel to the muscle fibers.

g. *Retraction:* The importance of retraction for visualization cannot be overemphasized.

h. *Irrigation:* This should be utilized to the utmost. It is realized that many times, due to actual water shortage, it will be impossible.

i. *Foreign Bodies:* All foreign bodies of any size should be removed. If adequate exposure has been provided, their removal will not present any problem. Blind probing and prolonged searches for very small metallic foreign bodies are condemned.

j. *Bone:* Do not remove bone fragments. Any obviously dirty bone fragments should be cleaned. If detached bone fragments are left *in situ* they act as a framework for new bone formation.

k. *Internal Fixation:* No internal fixation is to be performed. Reduction of fractures is not of importance at this time.

l. *Wound dressing:* Cover the wound with a dry, fine-mesh gauze dressing. In no case should the wound be packed or plugged. Place a large absorbent dressing over the entire wound and fix it in place by use of circular wraps of sheet wadding.

m. *Immobilization:* Immobilize the extremity in the appropriate circular plaster-of-Paris splint.

V. Amputations

1. Indications for Amputation

a. Complete destruction of the blood supply. This means the loss of the main artery and most of the collateral arteries.

b. Diffuse clostridial myositis.

2. *Level of Amputation:* Amputation should be performed at the lowest possible level which the nature and situation of the wound will permit.

3. *Type of Amputation:* Experience has shown that the open circular amputation is the procedure of choice in the treatment of war wounds. The guillotine amputation has not been found as satisfactory and it should not be used. The skin, muscle, bone and all tissues are divided at exactly the same level in a guillotine amputation, while in a circular amputation each tissue layer beneath the skin is allowed to retract before it is severed, so that, after amputation has been completed and traction has been applied to the skin, the stump has the appearance of a shallow inverted cone or saucer.

4. *Technique of Open Circular Amputation*

a. Prepare skin of extremity for surgical procedure.

b. Apply tourniquet.

c. Skin incision is made at the lowest possible level in circular manner down to the deep fascia. The incision may be made obliquely where indicated in an effort to conserve skin and length of extremity.

d. Allow skin to retract and next divide deep fascia at the level to which the skin had retracted.

e. Divide muscle in circular sweeps, cutting about three-fourths of an inch deep with each sweep, so that as the muscle retracts the next muscle division takes place at a slightly higher level.

f. Cut the periosteum of the bone circularly at the level to which the last muscle layer has contracted.

g. Saw the bone off cleanly at this level. Do not elevate, strip, or attempt to remove the periosteum at a level higher than the saw cut.

h. Nerves should be severed cleanly at the level of surrounding muscle division. Do not crush or ligate the nerve ends, or inject them with alcohol.

i. Hemostasis of the stump is essential. All large veins and arteries should be doubly ligated, each one separately, and extreme care should be taken not to include large amounts of muscle when ligating small vessels. After all the larger vessels have been ligated, the tourniquet should be removed and all remaining bleeders ligated.

j. Cover stump end with dry fine-mesh gauze. Do not "dust" or "frost" the stump with sulfonamide.

k. Skin traction should be applied immediately and be maintained continuously, while the patient is being evacuated and until healing takes place. There is one exception to this rule. In those cases where amputation is for clostridial myositis, skin traction should not be applied for the first twenty-four to forty-eight hours. No patient, however, should be evacuated from an Army installation until skin traction has been applied. Skin traction for transportation has been found to be most satisfactory if applied in the following manner:

- (1) After the stump end has been covered with a sterile fine-mesh

gauze, apply a circular roll of stockinette to the stump and roll this proximally as far as possible.

(2) Paint the skin with tincture of benzoin and allow it to dry.

(3) Apply an adherent to the skin down to the cut skin edge, then unroll the stockinette down on the stump. Allow it to adhere to the skin. Then place traction on the stockinette and put more dressings inside the stockinette up against the end of the stump.

(4) While an assistant continues to apply traction on the stockinette, apply several layers of sheet wadding loosely over the stockinette which covers the stump. Then apply a circular plaster pylon with an outrigger made of a wire ladder splint. Tie the end of the stockinette to the outrigger with a short piece of elastic traction cord. Plasma tubing may be substituted if elastic traction cord is not available.

(5) The plaster pylons indicated in each instance are as follows:

(a) *Below-the-Knee Stump*: Below-the-knee-to-groin pylon, with the knee in full extension;

(b) *Thigh Stumps*: Single hip spica pylon, with the hip in neutral position;

(c) *Forearm Stumps*: Full-arm pylon with the elbow flexed at 90 degrees;

(d) *Arm or Humerus Stump*: Shoulder spica pylon with as little abduction as possible. The axilla should be well padded to avoid pressure.

5. *Consultation*: Decision for amputation should not be made without consultation with the Chief of the Surgical Service, or the Senior Surgeon present. The consultation should be noted in the patient's medical record.

6. *Psychotherapy* is of utmost importance in the rehabilitation of the amputee, and the surgeon, by a few words, can help in this program. It is important that the operating surgeon himself verbally inform every amputee of the following before the patient is evacuated from the hospital:

a. That the amputation was necessary as a life-saving procedure;

b. That it was decided upon after consultation;

c. That further surgery for revision of the stump will probably be necessary;

d. That he will be sent to a center where he will be given a limb and where there are other facilities for his rehabilitation.

7. *Disarticulation*: A disarticulation should be performed only when absolutely necessary. The stumps are difficult to handle, discharge profusely, and skin traction is most difficult to maintain. The stumps all need extensive revision and the majority of these revisions have to be performed in two stages. Disarticulation of the knee may be undertaken as an emergency measure, but should not be done routinely.

VI. *Immobilization of Fractures for Evacuation*

1. *General Principles*

a. No bandage, dressing, or adhesive tape which encircles an extremity, other than *sheet wadding*, is to be used under a plaster splint.

b. Adequately padded plasters are safer in average hands; therefore, padding should be used over all bony prominences, and sufficient sheet wadding should be over the soft parts to allow for some swelling.

c. All layers of plaster and sheet wadding encircling the affected extremity must be cut through down to the skin immediately after the application of the splint, and the splint must be slightly spread. In a large percentage of cases, swelling of the extremity will occur and, unless all layers of the plaster and sheet wadding are cut through, it will be impossible to spread the cast sufficiently to prevent extensive damage. This is a safety measure which must be strictly and universally adhered to.

d. Attention should be paid to the position of the extremity encased in plaster. Ordinarily the *foot* should be at a right angle to the leg, the *knee* should be in flexion of 10 degrees to 15 degrees, and the *hip* in flexion of 20 degrees. The *wrist* should be supported in slight dorsal flexion, and the *elbow* ordinarily at a right angle. Plaster applied to the hand should be trimmed back to the proximal palmar crease to permit full flexion of the fingers and metacarpophalangeal joints. A loop of wire or wicket of plaster should be applied to the foot of the plaster splint to protect the toes from pressure exerted by blankets. A plaster splint must never extend beyond the width of the litter.

e. A line diagram in indelible pencil should be inscribed on the circular plaster splint to indicate the approximate location of wounds and fractures. The date of injury, date and type of surgical procedure, and the name of the unit to which the patient belongs should be written on every circular plaster splint.

2. *Circular Plaster-of-Paris Splints*: Experience has shown that the best form of splint for use in immobilizing fractures for transport from Army installations to the Communication Zone is the circular plaster-of-Paris splint. The following splints are recommended for the fractures indicated:

a. *Double Hip Spica*: Any fracture involving the *hip joint*, *femur*, *knee joint*, and *proximal end of the tibia* should be immobilized in a hip spica. The spica should extend to the toes on the affected extremity and to just above the knee on the unaffected extremity. Abduction at the hips must not exceed that which would cause the extremities to spread beyond the width of the litter. A strut should be placed posteriorly to anchor the thigh sections together and to furnish strength. This should be placed as far distally as possible so that a bed pan can be used. The body portion of the spica need not extend higher than the rib margin. A folded bath towel should be placed over the abdomen during application of the splint, and removed when the splint is completed, so that there will be room for some abdominal distention. The posterior portion should be trimmed adequately to allow for bowel movements. A patient with *fracture of the pelvis* will be most comfortable in a full-length double hip spica. The Army hinged half-ring splint should be used only as an emergency measure and should not be used for transportation of patients from the Army installation to the General Hospital. If it is necessary, because of the tactical situation, to use this splint for evacuation of patients from the Army Zone,

the traction strap must not be used; adhesive plaster applied to the skin of the leg should be substituted for the traction strap to provide maintenance of traction.

b. *Toe-to-Groin Circular Plaster Splint:* All fractures of the *lower half of the tibia*, of the *fibula*, and of the *ankle joint* should be immobilized in a toe-to-groin splint. A toe-to-groin cast should extend up to within an inch of the groin. However, this type of splint is not sufficient immobilization for *fractures involving the knee joint* and the *proximal end of the tibia*.

c. *Toe-to-Knee Circular Plaster Splint:* All fractures of the fore part of the foot should be immobilized in a toe-to-knee splint. The plaster should extend up to a point approximately two inches from the knee joint. *Mid-calf plaster boots are very uncomfortable and should never be applied.*

d. *Plaster-of-Paris Velpeau Bandage:* Patients with fractures of the scapula, shoulder joint, and the proximal two thirds of the humerus, travel very comfortably in this type of splint. Adequate padding about the elbow and over the bony prominences of the shoulder is essential. Care should be taken not to bind the arm too tightly to the chest. However, the splint is not comfortable if the patient is expected to be ambulatory. It is not an adequate splint for fractures in the distal third of the humerus, and those involving the elbow joint.

e. *Shoulder Spica Splint:* This is the best immobilization for all fractures of the shoulder joint, humerus, and elbow joint. It should be applied with the arm held forward and internally rotated, so that the forearm rests in front of the body and slightly below the level of the nipple line. The medial epicondyle of the humerus must be adequately and carefully padded. The elbow should be flexed to or slightly beyond 90 degrees.

f. *Circular Arm Plaster Splint:* All fractures of the *radius, ulna*, and *wrist joint* should be immobilized in a circular arm splint. The splint should extend from the proximal palmar crease to within an inch of the axillary folds, with the elbow in flexion of 90 degrees. The forearm should be in slight pronation. A circular arm splint applied for transportation should not be employed as a hanging cast for fractures of the humerus.

g. *Anterior Molded Plaster Splints:* Fractures of the metacarpals and phalanges are best splinted for transportation by the use of an anterior molded plaster splint, with the hand and fingers in a position of function, — the wrist slightly dorsiflexed, and the fingers flexed approximately 30 degrees to 40 degrees at all joints, the thumb adducted and slightly flexed. Only those fingers involved should be immobilized.

h. *Body Jacket:* Compression fractures of the vertebrae in which the spinal cord is not involved, or in which there are no accompanying fractures of the laminae or pedicles, should be reduced by hyperextension, and a plaster-of-Paris jacket applied with the patient in this position. For fractures of the lumbar or lower thoracic vertebrae, the jacket should extend from the symphysis pubis to the sternal notch. Cervical and upper thoracic spine fractures will require an extension of the jacket to include the head. If there are fractures of the pedicles or laminae without involvement of the spinal cord, manipu-

lation or hyperextension must not be performed, and the spine should be immobilized in a plaster jacket in neutral position. Plaster-of-Paris jackets should not be applied in cases of paralysis caused by gunshot wounds of the spine unless the stability of the spine has been destroyed.

3. The following forms of immobilization will not be used:
 - a. Any form of internal fixation.
 - b. Any form of skeletal fixation with wires or pins.
 - c. Murray-Jones hinged ring splints for the upper extremity.
 - d. Unpadded splints.
 - e. Unsplit circular plaster splints.
 - f. "Pulp" or finger-nail traction.

VII. *Treatment of Joint Wounds*

The following principles will be followed in the treatment of battle wounds involving joints.

1. All joint wounds must be debrided thoroughly.
2. A bloodless field should be obtained by the use of a tourniquet whenever possible.
3. Where adequate exposure cannot be obtained by enlargement of the wound, it should be assured by use of a standard arthrotomy approach.
4. All foreign bodies, loose fragments of bone and cartilage, including damaged intra-articular cartilages, must be removed.
5. All small debris and blood must be removed by thorough irrigation of the joint with normal saline solution.
6. The synovium and joint capsule should be closed with a single layer of interrupted non-absorbable sutures. (Sometimes it will be necessary to close defects in the capsule by swinging a fascial flap from the outermost layer of the capsule.)
7. If the patella has been badly shattered it should be excised, and the quadriceps and patella tendons sutured together with interrupted non-absorbable sutures.
8. After the joint capsule has been closed, aspirate the joint and inject 10,000 units of penicillin in 5 cubic centimeters of distilled sterile water.
9. Do not close the skin wound.
10. Do not place sulfonamides into the joint.
11. Do not leave drains in the joint cavity.
12. Arthrotomies should not be performed for recovery of very small metallic foreign bodies; in the majority of instances they would not be found. In these cases, aspirate the joint and inject 10,000 units of penicillin.
13. Immobilize the joint by use of the appropriate circular plaster-of-Paris splint.
14. Aspiration of the joint and re-injection of penicillin should be carried out at the end of twenty-four to forty-eight hours, or as may be indicated in each individual case.
15. The skin wound may be closed at the end of five days if no evidence of infection is present.

16. If the tactical situation permits these cases should be held for a minimum of ten days.

VIII. *Care of Hand Wounds*

The hand is an extremely useful member of the body and great disability results from its loss or its relative loss due to dysfunction. Experience in civilian and military fields has shown that early closure of wounds of the hand is essential to recovery of good function. In selected cases, primary closure may be performed in Army installations. Good surgical judgment and technique must be exercised in this procedure. Therefore, this type of work should not be relegated to the untrained and unqualified surgeon. The following instructions are guides to be followed in early surgical treatment of battle wounds of the hand.

1. *Surgical procedure*

a. Thorough cleansing of the entire hand with soap and water is essential. This should include the clipping of the fingernails.

b. Débridement must be thorough, but should be done with meticulous care to avoid further damage. It is essential that the surgeon have an assistant. All devitalized tissues and foreign bodies must be carefully removed. Hemostasis must be complete and should be accomplished by ligation of all severed vessels with the finest ligature available (silk, cotton, or chromic catgut). Do not remove bone fragments. Only that portion of the tendon which is macerated should be excised. The suture of tendons at this time is not indicated.

c. Closure should be performed with widely placed interrupted sutures without tension. Drains should not be inserted into the wound. If it is impossible to close the wound without tension, approximate the skin edges as closely as possible with a few well-placed stay sutures. It is important that bone and tendons be covered by soft tissue wherever possible. In a few selected cases, a thin split-skin graft may be taken to cover large denuded areas.

d. *Amputation of Fingers:* Amputate only those fingers which are irretrievably destroyed. It is possible sometimes to save some skin from a finger which must be amputated; this will aid in the closing of the remainder of the hand. It is important to salvage every possible portion of the thumb.

2. *Dressings*

a. Dressings will be applied snugly but not tightly and will adequately cover the entire wound.

b. *Immobilization:* The hand will be supported on a molded anterior plaster splint, with the hand and fingers in the position of function, — that is, wrist in slight dorsiflexion, the fingers flexed approximately 30 to 40 degrees at all joints, and the thumb slightly flexed and in moderate adduction and apposition.

3. *Aftercare*

a. If primary suture of a hand is done, the patient must be held a minimum of five days for close observation.

b. The hand must be kept elevated continuously during this period to minimize swelling and oedema.

c. Penicillin is to be administered throughout the entire period.

d. The primary dressing should not be disturbed until the fifth day, unless there is evidence of sepsis. If fever or increase of pain occurs, the wound should be inspected; and, if infection is present, enough sutures should be removed to allow adequate drainage.

e. Change dressing on the fifth day and inspect the wound under aseptic conditions. This is to avoid placing in the chain of evacuation the occasional patient who may have a low-grade infection without clinical manifestations.

f. Instruct the patient to keep the hand in a position of elevation during his evacuation.

IX. Gas Gangrene

1. *Types of Wound*: Wounds destroying muscle, either directly or by interruption of the blood supply, are articularly susceptible to anaerobic or clostridial infections.

2. *Types of Infection*: The following types of infection must be recognized, since they require different methods of treatment.

a. *Clostridial Gas Gangrene*

- (1) Diffuse myositis;
- (2) Localized myositis;
- (3) Cellulitis or "gas abscess".

b. *Streptococcal Gas Gangrene* (rare): Myositis.

3. *Diagnosis*

a. *Clinical*: Differential diagnosis of the various types of clostridial gas gangrene and streptococcal myositis must be made to avoid unnecessary or radical surgical treatment.

(1) *Clostridial myositis, diffuse*: This may develop within six hours from the time the wound was received and usually develops within three days. The onset is acute, with a severe systemic reaction. Locally there is *pain, marked swelling*, frequently profuse serous *exudate, slight gas formation, variable odor of decay*, and pale or blue-gray appearance of the involved muscle. The skin is tense and often white, but may be mottled with a livid appearance if the process is widespread.

(2) *Clostridial myositis, localized*: Symptoms and signs are the same as for the diffuse type except that the process is restricted to a single muscle or group of muscles.

(3) *Clostridial cellulitis*: This process is limited to the immediate area of the wound. The onset is gradual, usually three days after injury, with slight systemic reaction. Locally there is abundant gas formation with a foul odor and slight swelling, and little local change of the muscle and overlying skin is present.

(4) *Streptococcal myositis*: The onset is delayed for three or four days, and severe systemic reactions do not appear until the late stages of infection. Locally, there is *marked swelling, with profuse purulent discharge, slight gas formation, and slight odor*. The involved muscle is slightly oedematous and the

overlying skin is *tense*, often with a coppery tinge. Streptococcal myositis comprises only a few of the cases of gas gangrene.

b. *Laboratory Evidence*: Recognition of the infections mentioned must be made on the basis of clinical findings because adequate laboratory facilities are not usually immediately available. Confirmatory laboratory evidence is of statistical importance only and should be obtained when possible, but should not influence the treatment.

c. *Roentgenographic Evidence*: The mere presence of gas shadows in a roentgenogram is not sufficient evidence of gas gangrene infection.

4. *Prophylaxis*: Early adequate débridement of wounds is the best prophylaxis for anaerobic infections. Débridement in cases where there has been massive destruction of tissue, more particularly in the region of the perineum and the proximal portion of the femora, and in cases where major vessels are injured, must be radical and thorough, and long incisions must be made.

5. *Treatment*

a. *Surgical*: This depends upon the extent of the disease and the type of anaerobic infection.

(1) *Clostridial myositis, diffuse*: Amputation well above the site of involvement *must be carried out immediately*, using the circular method, and leaving the wound open. Do not apply skin traction for forty-eight hours.

(2) *Clostridial myositis, localized*: Extirpation of the involved muscle, or group of muscles, is indicated.

(3) *Clostridial cellulitis*: Incise the localized area and remove the devitalized tissue. Radical surgery is not indicated.

(4) *Streptococcal myositis*: Extensively incise and drain the involved muscles. Radical extirpation or immediate amputation are not indicated.

b. *Serum Therapy*

(1) Gas-gangrene antitoxin is only effective in combatting the toxin. Its use is not indicated in those cases in which toxic manifestations are not present. When indicated, it should be administered intravenously and the dosage should be governed by the degree of toxicity manifested. Precaution should be taken to guard against allergic reaction, both *early* and *delayed*.

c. *Antibiotics and Chemotherapy*: None of the sulfonamides nor the various antibiotic agents have any specific action against clostridial infection, but they may be used parenterally or by mouth to help control other bacteria present in these wounds. In the European Theatre in 1944 and 1945, when only penicillin and sulfonamides were available, the following routine was used:

(1) *Penicillin*: Give an initial dose of 20,000 units intravenously and 20,000 units intramuscularly, followed by 20,000 units intramuscularly every two hours for a period of three days. Period of therapy may be modified as necessary.

(2) *Sulfonamides*: Give 6 grams of sulfadiazine by mouth initially and 1 gram every four hours thereafter.

d. X-ray irradiation is not indicated.

e. Supportive treatment: Since there is a rapid destruction of erythrocytes, frequent whole-blood transfusions will be necessary.

f. All instruments used in cases of anaerobic infections should be sterilized by autoclaving, whenever possible. The instruments must not be covered with oil, since bacteria surrounded by oil are protected against moisture and therefore are not killed at the usual temperature.

g. If gas-gangrene antitoxin is used, record the number of ampules used and the name of manufacturer.

X. *Vascular Injuries*

All patients whose extremities are affected and who have had injuries or ligatures of major arteries should be held in Army hospital installations for treatment and observation until the danger of either circulatory or gas gangrene is past. In most cases, this time interval is approximately ten days. If either gas or circulatory gangrene develops, amputation and other indicated procedures should be carried out before the patient is evacuated.

Patients with a damaged popliteal artery and exhibiting a cold extremity, with hard muscles and loss of sensation distal to the lesion, should have a transcondylar amputation as a primary procedure.

SECTION C

Therapy in Communication Zone Installations (General Hospitals and Station Hospitals)

I. *Strains and Sprains*

1. *Strains*: Those strains which do not recover rapidly with conservative treatment should be studied thoroughly for a definite diagnosis or to establish the cause of continued symptoms.

2. *Sprains*

a. *Ankle joint*: Severe sprains lead to partial permanent disability if they are not properly diagnosed and treated early. The possibility of diastasis of the inferior tibiofibular joint and rupture of the collateral ligaments must be considered.

b. *Knee joint*: A differential diagnosis of the pathological findings in the joint must be made. Treatment and disposition will depend upon the evacuation policy. If the patient has a sprain of the knee, he may be returned to duty within six weeks. If the injury is more serious, such as an internal derangement, the period required for recovery and return to full duty will be four to six months. Many will never be able to return to full duty. No purely *exploratory arthrotomy* of the knee joint will be performed.

II. *Dislocations*: Ordinarily reduction will be performed by manipulation under general anaesthesia. Open reduction may be resorted to, after adequate consultation, when closed reduction has failed.

III. *Simple Fractures*: Fractures of the long bones should be treated by skeletal traction. Open reduction is not to be performed routinely, but only after an

adequate trial of reduction by skeletal traction has failed. After these fractures have become stable, they should be placed in the appropriate circular plaster-of-Paris splint and the patients will be evacuated to the Zone of the Interior. Double pin and plaster fixation is not to be used. Badly displaced fractures of the radius and ulna which cannot be reduced by other means may be treated by open reduction and internal fixation.

Fractures of the metatarsals and phalanges should not be immobilized for long periods of time in plaster casts. "Pulp" traction should not be used.

IV. *Compound Fractures*

1. *Delayed Primary Wound Closure*: This is the greatest single advance in the treatment of compound fractures due to battle wounds. Experience has shown that it is desirable to close these wounds as early as possible after the patient arrives in the General Hospital. This should be performed at the time of the first wound dressing, providing the wound is clean and there is no gross evidence of infection. If infection is present, it should be treated; and, as soon as the infection has been controlled, the wound may be closed. Some wounds may require secondary débridement to control or eliminate infection before they are ready for delayed primary closures. If the closure is done within the first ten days, the skin edges are usually still mobile and may be readily approximated with widely spaced and deeply placed non-absorbable sutures without undue tension. Where wounds cannot be closed without tension because of loss of skin, the closure should be completed with skin grafts. If the wound is ten days old or older, it will usually be necessary to excise the new epithelium at the margin of the wound and undercut the skin edges to make them mobile so that they may be approximated. Penicillin or other antibiotics parenterally or by mouth should be administered one day prior to and several days after the operation. Sulfonamides should *not* be placed in the wound.

2. *Reduction and Immobilization*

a. *Fractures of the Long Bones*: Fractures of the femur, tibia and fibula, and of the humerus will be treated by skeletal traction in every instance where it is possible to achieve a beneficial result within a reasonable length of time. Skeletal traction will be maintained until the position of the fragments has become sufficiently stable so that they will not displace or angulate during transportation in a circular plaster-of-Paris splint. The average periods during which patients with these fractures were held in the European Theatre of Operations are as follows:

Femur	9 to 12 weeks
Tibia and fibula	5 to 7 weeks
Humerus	4 to 6 weeks

b. *Fractures of the Long Bones with Loss of Bone Substance*: Those patients who have had large loss of bone substance should not be placed in skeletal traction. The part affected should be allowed to shorten so that there will be bone contact. This method is far from ideal. Alignment should be maintained

by plaster immobilization and every effort made to effect an early primary closure of the wound. These patients need not be held until the fracture becomes stable, but should be returned to the Zone of the Interior at an early date in the appropriate circular plaster-of-Paris splints.

c. *Fractures of the Long Bones with Severe Nerve Paralysis*: In these patients, the nerve injury takes precedence; therefore, they should immediately be transferred to a neurosurgical center where they will be handled in the following manner:

Do not overcome shortening by application of skeletal traction as it may defeat the possibility of accomplishing an end-to-end suture of the nerve. Splint the fracture in good alignment and perform a primary delayed wound closure at the earliest possible date. If closure is successful and there is no evidence of residual infection at the end of three weeks from time of closure, a combined operation should be done, suturing the nerve end to end, performing open reduction of the fracture and using internal fixation when indicated.

d. *Internal Fixation in Compound Fractures*: Internal fixation of compound fractures is prohibited as a routine procedure. It should be resorted to only after a thorough trial of skeletal traction has failed to secure adequate reduction, and after healing of the compound wound has been accomplished by suture or skin graft.

e. *Fractures of Forearm*: These may be treated by circular plaster splints or by skeletal traction when feasible. Badly displaced fractures may require open reduction with internal fixation if other methods have failed. This will not be performed until three weeks after a successful delayed primary closure of the compound wound.

f. *Fractures of the Hand and Fingers*: In no case should they be immobilized for more than two weeks (see Care of Hand Injuries, VIII).

g. *Fractures of the Foot*: The primary consideration should be the healing of the wounds through treatment by suture or skin grafting, followed by early active motion of toes and tarsal joints.

h. *Steinmann Pins and Plaster, Anatomical Splint*: The use of double Steinmann pin with plaster-of-Paris fixation and external metallic fixation splints is not to be permitted as a routine procedure. This method of reduction and immobilization has led to gross infection and ulceration about the pin wounds in a high percentage of cases.

V. *Amputations*: The same principles for amputation as are outlined in Section B will also be followed in General Hospitals. All amputations performed are to be done by the open circular technique. (In cases where traumatic amputations were followed by amputations done in the forward areas, the stumps showed irregular skin edges.) In most instances, skin traction will effect closure if it is adequately applied and maintained. Secondary closure of these stumps will not be performed in this Theatre. If the skin sleeve is inadequate for closure by traction, or if the bone ends are obviously too long, revision of the stump should be performed. The skin edges should be mobilized by undercutting. The protruding muscle and bone should be re-amputated just sufficiently to

allow closure by continuous skin traction. Split-thickness skin grafts on stumps of the lower extremity will not tolerate a prosthesis. The use of such grafts to cover amputation stumps is prohibited unless there is an unusual indication. Skin traction should be maintained continuously. As soon as possible after an amputation case is admitted to a General Hospital, the temporary pylon splint and skin traction should be removed and replaced. In the General Hospital traction is best applied by use of weights and pulleys attached to the bed. The traction apparatus should be arranged so that in thigh and leg stumps a greater degree of skin traction is exerted on the posterior portion of the stump. Patients with amputations should be in a condition to be evacuated to the Zone of the Interior two or three weeks after admission to a General Hospital. Stumps do not have to be completely healed. However, skin traction is to be maintained during evacuation by the reapplication of the plaster splint pylon with outrigger as described in Section B.

VI. *Splinting of Fractures for Transfer to the Zone of the Interior*

The same general principles (Section B, VI) will be followed in the application of circular plaster-of-Paris splints for evacuation to the Zone of the Interior, with the exception that these are secondary plaster-of-Paris splints applied weeks after the injury or operation and therefore *need not be split*. All patients should have new plasters applied just prior to departure.

VII. *Joint Wounds*: These wounds should be closed at the earliest possible moment by suture or skin graft. If the joint surfaces are not badly damaged, early active motion should be insisted upon. If, however, the joint surfaces are so badly damaged that ankylosis is inevitable, the various joints should be immobilized in the best position for function. The following positions are recommended.

1. *Hip Joint*: Flexion of 25 degrees and abduction of 5 degrees, and neutral position without medial or lateral rotation.
2. *Knee Joint*: Flexion of 10 to 15 degrees.
3. *Ankle Joint*: Foot, 10 degrees less than right angle for males; 20 degrees less than right angle for females.
4. *Shoulder Joint*. Abduction of humerus of 65 degrees, 45 degrees forward of the transverse body axis, and in midrotation. This position enables the patient to reach his face with his hand.
5. *Elbow Joint*: Flexion of 90 degrees. In bilateral cases immobilize the more seriously damaged joint at 90 degrees and the other at 130 degrees.
6. *Wrist Joint*: Dorsiflexion of 40 degrees without radial or ulnar deviation.

VIII. *Hand Injuries*:

Centers have been established to care for hand injuries, as these present special problems. Those hand wounds which have not had a primary closure in hospitals in the forward areas should be closed by delayed primary closure or with skin grafts as early as possible. The danger of prolonged immobilization of the hand and fingers cannot be overemphasized. A useful hand with imperfect bone alignment is far more desirable than a stiff hand with

perfectly reduced fractures. In selected cases, skeletal traction may be used, but every effort should be made to maintain active motion of the uninvolved fingers. Such traction should not be employed longer than two or three weeks. In no instance should "pulp" traction be used. Amputations should be performed early if there is no possibility of restoring some useful function. Whenever possible, any portion of the thumb should be saved. Effective active exercises under the supervision of a physical therapist must be instituted early and pursued with diligence.

IX. *Gas Gangrene*: Same principles of treatment apply as outlined in Section B, IX.

X. *Vascular Injuries*: These are not considered to be orthopaedic problems except for those cases which require amputation, and those which require treatment of an associated fracture.

XI. *Elective Orthopaedic Surgical Procedures*: It must be borne in mind that any major procedure of this kind requires a relatively long period of convalescence and that there are few which will result in complete elimination of a partial permanent disability. As a rule patients requiring the following procedures will be transferred to the Zone of the Interior:

1. Arthrodesis of the spine or of any major joint;
2. Bone grafts for non-unions;
3. Any type of operation for recurrent dislocation of the shoulder;
4. Arthroplasties, including bunion and hammer-toe operations;
5. Arthrotomies for correction of internal derangement of the knee joint.

Certain exceptions may be made for the possible salvaging of key personnel. In such cases the concurrence of the local orthopaedic or surgical consultant will be secured before such a procedure is carried out.

MEDICAL DEPARTMENT, UNITED STATES ARMY

The volumes comprising the history of the Medical Department of the United States Army in World War II are divided into two series: (1) The administrative and operational series, which constitutes a part of the general series of the history of the United States Army in World War II, prepared by The Surgeon General and published under the direction of the Chief of Military History; and (2) the professional, or clinical and technical, series prepared by and published under the direction of The Surgeon General. This is one of the volumes published in the latter series.

INDEX¹

- Aachen, 28
Abdomen, wounds of, 10, 55, 56, 59, 78, 81, 223, 276
Abduction—
 in fractures of humerus, 24
 of plaster spica, 110
Abduction exercises, 276
Abduction force in fractures of radial head, 122, 123
Abrasions in acromioclavicular dislocations, 198
Abscess formation after secondary resection of knee joint, 312
Abscess of clostridial origin, 174
Access to wounds in plaster for dressings, 46, 52, 105, 114, 175
Acetabulum:
 anatomy of, 254
 damage to, in jeep dislocations, 255–256, 258
 fracture-dislocations, 254, 269–273
 fractures of, 251, 254, 262–268, 269, 275, 276, 292, 301–302
 function of, 254, 262, 301
 resection of, 232, 302
 retroperitoneal hemorrhage with fractures of, 289–291
Achilles tendon, 187
Acromioclavicular cartilages, resection of, 210
Acromioclavicular joint(s):
 anatomy of, 195–197
 ankylosis of, 202, 210, 212, 218
 arthritis of, 202
 compression fractures of, 203
 dislocation(s) of:
 acute, 191
 chronic, 185–186
 complete, 191–219
 complications of, 216–219
 incidence of, 191
 management of, 195, 202–215
 effusion into, 202
 function of, 201
 fusion of, 212
 healing of, 199
Acromioclavicular joint(s)—Continued
 roentgenologic examination of, 195–197
 sprains of, 207
 subluxation of, 196, 207
 congenital, 196
 synovitis of, 202
 variations in, 195–197
Acromioclavicular ligaments, 195
 calcification of, 211
 experimental studies on, 200
Acromion process:
 fractures of, 191, 199, 206, 215
 manipulation of, in shoulder dislocations, 203
 relation of clavicle to, 195
Adhesions:
 after acromioclavicular dislocations, 219
 prevention of, in fractures of radial head, 130
Adhesive strappings in acromioclavicular dislocations, 205, 207, 211
Adjunct therapy, 114, 167–171, 237–238.
 See also Blood replacement, Fluid balance.
Adjustments to shoes, 44–45
Administrative considerations:
 consultant system, 7–18
 hospital facilities and orthopedic equipment, 41–54
 management of bone and joint injuries in prisoners of war, 63–66
 mass management of casualties with bone and joint injuries, 55–61
 representative hospital experiences, 67–70
 tours of hospitals, 19–34
 training of personnel, 35–39
Adolescence, avascular necrosis of femoral head in, 295, 301
ADSEC Headquarters, 30
Aerial bombs, 69
Affiliated hospitals, 14, 17, 18
Age:
 and incidence of avascular necrosis, 295, 301
 and incidence of civilian-type lesions, 68

¹ Unless it is otherwise specified, all references in this index are to (1) orthopedic surgery, (2) the senior consultant in orthopedic surgery, (3) battle-incurred compound fractures, and (4) the European Theater of Operations in World War II.

- Age—Continued
 as factor in jeep injuries, 252
 effect of, in reaction to trauma, 134
 influence of, in delayed primary wound closure, 100
- Air evacuation, 22, 30, 32, 55-56, 58, 70, 78, 191
- Airway, patency of, at surgery, 167
- Aldershop, 116
- Alinement of fractures—
 by internal fixation, 116
 in plaster traction splint, 47
 in traction cradle, 50
- Allied wounded:
 amputation in, 157
 penicillin therapy in, 169
 preferential care of, 63
- ALLIS, OSCAR H., 252, 255
- Allis technique in dislocations of hip joint, 259
- Ambulation—
 after use of plaster traction splint, 47
 in fractures of ankle, 152
- American Board of Orthopaedic Surgery, 11
- American Board of Surgery, 11, 20
- Amputation, 25-26, 32, 155-166
 after ligation of popliteal vessels, 106
 after use of Tobruk splint, 113
 anemia after, 87
 application of tourniquet at, 164
 at elective site, 159, 161, 165
 case fatality rates for, 157-158
 consultation before, 165
 errors in, 25-26
 evolution of technique of, 158-165
 frequent use of, by German medical officers, 66
 in civilian practice, 157
 in combined nerve-bone injuries of femur, 104
 in injuries caused by land mines, 166
 in noncombat injuries, 67
 in suppurative arthritis of—
 hip joint, 244-245
 knee joint, 311
 in World War I, 157
 in wounds of knee joint, 306, 311
 incidence of, 157-158
 indication(s) for, 155-157, 158-159, 174
 ankylosis of elbow as, 77
 clostridial myositis as, 156, 157, 159, 161, 165, 174
 gangrene as, 26, 159
 massive tissue damage as, 113, 155
- Amputation—Continued
 indication(s)—continued
 revised, 161-165
 trauma as, 157, 158-159
 vascular damage as, 113, 144, 155, 157, 161, 166
 wounds of foot as, 156
 level of, 159, 161, 165
 of foot, 26, 154
 of functionally useless viable limb, 26
 of upper extremity, 156, 159
 psychotherapy at, 165
 skin traction after, 165-166
 statistics on, 157-158
 technique of, 77, 162-163, 165-166
 transportation splinting after, 165-166
 traumatic, 77, 166
See also Disarticulation, Primary amputation.
- Amputation centers, 162
- Amputation stump:
 closure of, 25-26
 revision of, 162, 163
- Amputees:
 morale of, 8, 61, 154, 162, 165
 priority of evacuation of, 32
 rehabilitation of, 162
 segregation of, 59, 170
- Amyloidosis, 245
- Anaerobes, growth of, in devitalized tissue, 173
- Anastomosis of—
 major arteries, 155-156
 popliteal artery, 155
- Anatomic distribution of fractures of femur, 112
- Anatomic pathology of jeep injuries of hip joint, 254
- Anatomic predisposition to jeep injuries of hip joint, 252-253
- Anatomy of—
 acetabulum, 254
 acromioclavicular joint, 195-197
 hip joint, 276
 knee joint, 306
 radial head, 121-122, 128
- Anemia—
 after amputation, 87
 in fractures about hip joint, 238
- Anesthesia:
 for aspiration of elbow joint, 127
 for debridement, 87
 for inspection of wounds before surgery, 102
 for reduction of fractures, 114

- Anesthesia—Continued
 in jeep dislocations of hip joint, 259
 in transit hospitals, 58
 maintenance of free airway during, 167
See also special types and agents.
- Aneurysm, 174
- Anglo-American consultants, meeting of, 31
- Anglo-Boer War, 221
- Angulation of fractures, 89
- Ankle:
 arthrodesis of, 153
 fracture-dislocations of, 153
 fractures of, 56, 76, 102
 mobilization of, during skeletal traction, 25
 sprains of, 151
- Ankylosis of—
 acromioclavicular joint, 202, 210, 212, 218
 elbow joint, 77
 hip joint, 262, 268, 301
 knee joint, 311
- Anorexia during chemotherapy, 239
- Anterior dislocation of hip joint, 258
- Anterior iliofemoral (Smith-Petersen) incision, 232-233, 241, 243, 244, 249, 283
- Anterior lateral muscles of leg, 106
- Antibiotic therapy, 114, 168-170
 in delayed primary wound closure, 103-104
 in fractures about hip, 223, 238
 in wounds of knee joint, 316
See also Penicillin.
- Anti-gas-gangrene serum, 173
- Aponeurosis of deltoid muscle, 199
- Appendectomy, 21
- Appetite, effect of transfusion on, 167
- Appliances for—
 management of compound fractures, 45
 54
 shoes, 39
- Application of—
 dressings on battlefield, 167
 plaster casts by ward attendants, 38
 skeletal traction by ward attendants, 38
 tourniquet on battlefield, 159
- Arch supports, 44-45, 188
- Arches, congenital malformations of, 187
- Ardennes campaign, 70
- Arm:
 position of, in plaster spica, 76
 wounds of, 102
- Armored units, 69
- Army Air Forces, 74
- Army areas:
 consultants in, liaison between, 10
 holding time in, 25
 orthopedic consultants in, 10-11, 15
 orthopedic surgeons in, 18
- Arrival of hospitals—
 in United Kingdom Base, 14, 16, 17, 35
 on Continent, 17
- Arthritis:
 after acromioclavicular dislocations, 202, 216-217
 after fractures of radial head, 127
 degenerative, 138, 139
 excision of clavicle in, 212
See also specific types.
- Arthrodesis—
 after injuries of hip joint, 243, 292, 301, 302
 in acromioclavicular dislocations, 210
 in fractures of foot, 154
 of ankle, 153
- Arthroplasty of hip joint, 254, 268, 284, 285, 293, 301, 302
- Arthrotomy in—
 acromioclavicular dislocations, 210
 fractures of femur, 150
 injuries about hip, 224-232, 234, 249, 277, 288
 wounds of knee joint, 185, 186, 308, 312-313, 315, 316
- Articular cartilage, damage to—
 in fractures of radial head, 128-129
 in injuries of hip joint, 269
- Articulation of radial head, 121
- Artificial limb. *See* Prosthesis.
- Aspiration of—
 elbow joint, 127, 128, 130, 131
 knee joint, 150, 307
- Assignment of—
 beds for orthopedic casualties, 16
 consultant to field army, 15
 orthopedic personnel, 7, 8, 9, 10, 11, 14-18, 57, 59, 60
 technicians for plaster work, 38-39
- Associated injuries. *See* injuries of special viscera, structures.
- Astraglectomy, 153
- Astragalus:
 fractures of neck of, 153
 recurrent luxation of, 151
- Atrophy of—
 clavicle after acromioclavicular dislocations, 217
 limbs treated in plaster, 50

- Atrophy of—Continued
 muscles, 114, 178
- Autogenous bone grafts, 27, 105
 in carpal scaphoid fractures, 140-142
- Autopsy observations in injuries about hip,
 258, 260, 281
- Auxiliary surgical groups, 11, 15-16, 37-38,
 56
 3d—111
 4th—86
- Avascular necrosis—
 after acromioclavicular dislocations, 217
 after carpal scaphoid fractures, 137
 after injuries about hip joint, 245-247,
 255, 261, 275, 289, 293-296, 301
 of astragalus, 153
- Avascular sclerosis, 142
- Avulsion fractures of—
 acetabulum, 255, 258, 276
 clavicle, 207
 coracoid process, 215
 trapezoid ridge, 215
- Azochloramid (chloroazodin), 175
- Bacillus proteus*, 233, 239
- Back, noncombat disability of, 68
- Bacterial contamination in injuries about
 hip joint, 225
- Bacteriology of—
 joint infections, 233, 239
 wound infections, 97
- Bacterium coli*, 233, 239, 246
- Balanced suspension in combined nerve-
 bone injuries, 104, 105-106
- Balkan frames, 42, 46, 50, 56, 205, 267
 in decubitus ulcers, 175
 in tented hospitals, 41
- Ballottement of clavicle, 209
- Bandages—
 in acromioclavicular dislocations, 205
 in transportation splinting, 224
- Barbiturates, 170
- Battalion aid stations, 170, 259
- Batley General Hospital, 101
- Battle casualties:
 British arrangements for care of, 36-37
 management of, 19, 73, 75, 81
- Battle exhaustion, 170
- Battle of Bulge, 79
- Bed capacity of tented hospitals, 41
- Bed space for orthopedic casualties:
 allotment of, 16, 41, 57
 location of, 42
- Belgian medical service, 39
- Belgium, 22, 67, 68, 78, 112
- Berkshire, 36
- BIGELOW, HENRY J., 252
- Bigelow reduction of dislocations of hip
 joint, 259-260
- Bigelow's dislocations of hip joint:
 irregular, 258
 regulation, 258
- Bilateral dislocation of hip joint, 259
- Bilingual order forms for shoe corrections,
 45
- Bipartite scaphoids, 134
- Bivalving of transportation casts, 84, 109
- Bladder, wounds of, 34, 97, 227, 233, 237,
 289
- Blake traction, 143, 144
- Blandford, 42, 45, 191
- Blast injuries, 166, 167
 uremic syndrome after, 70
- Bleb formation, 120
- Bleeding point, ligation of, in secondary
 hemorrhage, 175
- Blister formation on feet, 187
- Blood loss:
 at debridement, 147
 in fractures of femur, 147, 167
 in injuries about hip, 70
- Blood replacement, 114, 167-168, 169, 223
 after amputation, 87
 before initial wound surgery, 167
 before internal fixation, 117
 before reparative surgery, 95, 100, 102,
 103, 167-168
 in injuries about hip joint, 224, 238, 249
- Blood supply:
 damage to—
 in clostridial infections, 173
 in injuries about hip joint, 224, 225,
 227-228, 259, 260, 275, 279-280
 in wounds of knee joint, 306, 307-308
 destruction of, 155-156
 of head of femur, 254, 275, 295
 of hip joint, 245, 255, 278, 295
 of knee joint, 307
 of retinacula, 293
- Blood vessels:
 damage to, by splints, 174-175
 erosion of, 174
- Blown-straw fractures of femur, 149
- Boeck's sarcoid, 28
- Böhler-Braun frame, 47, 49
- Böhler-Braun technique in fractures of
 bones of leg, disadvantages of, 151
- Böhler-Braun traction cradle, 27, 50

- Bombings in Great Britain, 37
- Bone, shortening operations on, 104, 105-106, 144, 146
- Bone and joint injuries, casualties with.
See Orthopedic casualties.
- Bone fragments:
adjustment of position of, 67
conservation of, 84, 85
displacement of, 123, 151
distraction of, in skeletal traction, 25
excessive removal of, 85, 102
management of, 27, 277
position of—
after internal fixation, 118
in fractures of femur, 149
- Bone grafts, 83, 102, 106
bone chips used as, 84
elective, 185
in carpal scaphoid fractures, 141-142
in fractures of—
bones of forearm, 121
humerus, 27, 144, 146
in prisoners of war, 66
See also special types.
- Bone nails, 43
- Bone punches, 43
- Bone replacement in avascular necrosis, 296
- Bones of arm (leg). *See* Humerus, Tibia, etc.
- Bony prominences, protection of, during transportation, 109
- Bony spurs, 132
- Boobytraps, 69
- BOSWORTH, BOARDMAN M., 211
- Braces, 44-45, 205
- Braceshops, 39
- Brachioclavicular splint, 204, 206
- Bradford frame, 52, 236
rotating type, 27
- Bristol, 67
- British, air evacuation by, 22
- British Army consultants, 39, 111
- British Emergency Medical Service, 36
- British hospitals, 23, 36-37
- British incision for resection of femoral head in World War I, 243
- British Isles. *See* United Kingdom Base.
- British management of—
battle casualties, 36-37
injuries about hip in World War I, 226
- British Orthopaedic Association, 36
- British orthopedic experience used in training United States personnel, 36-37
- British prisoners of war, 66
- British provision of supplies in United States hospitals, 42, 44
- British use of Tobruk splint, 110-111
- Brodie's abscess of radius, 28
- Bromsgrove, 177
- Buck's apparatus, 235, 261
- Buerger's exercises, 32
- Bunions, 187
- Buried sutures, 88
- Bursitis, 67
- Bursting fractures of hip joint, 262, 263
- Buttocks, wounds of, 34, 84, 111, 157, 235
- Buzz bombs, 69
- Cachexia, 245
- CADENAT, F. M., 201
- Calcification of—
acromioclavicular ligaments, 211, 216, 219
capsule of hip joint, 289, 292
conoid ligaments, 217
fascia lata, 211
soft tissues of shoulder joint, 217-218
trapezoid ligaments, 217
- Calcium gluconate, 168
- Callus formation in—
fractures of femur, 149
fractures of humerus, 145, 146
plaster traction splint, 47
- Canadian Army consultants, 39, 113
- Cancellous bone chips, 174
in radial head, 121
- Capitate bone, 28
- Capitellum, 121, 123, 132
- Capsular ligament:
calcification of, 216, 219
role of, in acromioclavicular dislocations, 200, 201
- Capsule of—
acetabulum, 254
acromioclavicular joint, 199, 200
hip joint:
blood supply of, 295
calcification of, 289, 292
closure of, 234
damage to, in jeep injuries, 255, 258, 259, 269, 272-275
experimental damage to, 294
ossification of, 261
knee joint, closure of, 306, 308, 309, 313-315
- Care of protected German prisoner personnel, 63-66
- Carentan, 69

- Carpal navicular fractures. *See* Carpal scaphoid fractures.
- Carpal scaphoid fractures, 28, 119, 133-143
 classification of, 134
 diagnosis of, 141-142
 factors influencing healing in, 137-142
 function after, 135
 management of, 134-135, 138, 140-142
 mechanics of, 133-134
 prognosis of, 142-143
 results in, 135-142
 statistics on, 134-143
- Carpometacarpal joints, 120
- Carpus:
 application of traction through, 120
 dislocation of, 28
- Cartilages of knee joint, damage to, 307, 311
- Case fatality rates in—
 amputation, 157-158
 clostridial myositis, 174
 fractures about hip joint, 221, 223, 224
 fractures of long bones, 157
 wounds of extremities, 81
 wounds of knee joint, 305
See also Statistics.
- Case histories:
 complete dislocation of acromioclavicular joint, 206, 210, 213-214, 214-215
 compound fractures about hip joint:
 avascular necrosis, 246-247
 inadequate debridement, 228, 229, 241-243
 infection from colostomy, 240
 reconstructive surgery, 248-249
 resection of femoral head, 244
 Smith-Petersen approach, 232-233
 errors of management, 27-29
 fractures of radial head, 132-133
 wounds of knee joint, delayed closure of capsule, 314
- Caseload of—
 evacuation hospitals, 15, 81
 field hospitals, 32
 forward hospitals, 10
 general hospitals, 67-70
 hospitals in United Kingdom Base, 22
 hospitals on Continent, 29, 78-79
 hospitals, relation of, to—
 mass management of casualties, 55
 orthopedic personnel, 14, 60
 station hospitals, 56, 57
- Causalgia, 107
- Casualties with bone and joint injuries.
See Orthopedic casualties.
- Causes of secondary hemorrhage, 174
- Cavus foot, 187
- Cellulites, 315
- Centers for specialized care, 21, 25, 59, 61, 86, 104, 162, 177
- Certificate of disability discharge, 106
- Cervical spine, fractures of, 53, 147
- Change of casts—
 after delayed primary suture, 109
 in carpal scaphoid fractures, 135
 in evacuation hospitals, 30
- Chaplains, 171
- Character of compounding wounds, 81
- Check of digits during evacuation, 109
- Chemotherapy, 67, 168-169
 in delayed primary wound closure, 103-104
 in fractures about hip joint, 223, 238, 241
 in wounds of knee joint, 307, 316
 limitations of, 173
 studies on, in primary wound closure, 74
See also special agents.
- Cherbourg, 68
- Chest, injuries of, 10, 32, 55, 56, 59, 78, 81, 223
- Chief Surgeon, European Theater of Operations. *See* Theater Chief Surgeon.
- Chiefs of orthopedic section, utilization of, in training programs, 16
- Chiefs of surgical services, 19
- Childhood, avascular necrosis of femoral head in, 295
- Chip fractures of—
 acetabulum, 269, 276
 acromion process, 215
 clavicle, 215
- Chronic dislocations of acromioclavicular joint, 185-186
- Cicatrices, 67
- Cicatricial formation in coracoclavicular ligaments, 199
- Circular incision for debridement, 85
- Circular letters, 7, 33, 36, 63, 66, 68, 75, 77, 163, 169
- Circular plaster splints, 23, 24, 76, 110
 necessity for spitting of, 33-34, 109
- Circular plaster type of countertraction, 165
- Civilian care of British battle casualties, 36-37
- Civilian concept of medical care, 77

- Civilian orthopedic practice:
 amputations in, 157
 closed plaster technique in, 73
 dislocations of shoulder in, 191
 fractures of femur in, 246
 injuries about hip joint in, 251, 252, 253, 296-304
 results of arthrotomy of knee joint in, 186
 wounds of knee joint in, 305
- Civilian traffic accidents, 14, 68, 224
- Classification of—
 fractures of—
 carpal scaphoid, 134
 humerus, 144-146
 radial head, 123
 jeep injuries of hip joint, 251-252, 258, 262, 269
 wounds of knee joint, 305
- Clavicle:
 atrophy of, 217
 avulsion fractures of, 207
 ballottement of, 209
 congenital absence of, 212
 displacement of, in dislocations of shoulder, 201
 excision of, 185-186, 204, 209, 212-216, 217, 218, 219
 experimental studies on, in acromioclavicular dislocation, 200-201
 fixation of scapula to, 202
 fractures of, 95, 143, 191, 198, 199, 215
 function of, 210, 212
 management of injuries of, 117, 203, 204, 206, 212
 overriding of acromial end of, 196, 203
 position of, in acromioclavicular dislocations, 204, 206, 207
 rarefaction of, 217
 relation of, to acromion process, 195
 synostosis of, with scapula, 218
- CLEVELAND, Col. MATHER. *See* Senior consultant.
- Clinical data, collection of, 8, 9
 Clinical investigations, supervision of, 7
 Clinical policies, 73-80
 Closed fractures. *See* Simple fractures.
 Closed plaster technique, 63, 67, 73, 82
 prolonged timelag as indication for, 67
 Clostridial infections, 26, 173-174
 Clostridial myositis, 26, 80, 110, 174
 as indication for amputation, 156, 157, 159, 161, 163, 165
Clostridium welchii, 26, 156, 167
- Closure of—
 amputation stump, 25-26, 77
 hip joint, 234, 249, 314
 knee joint, 306, 308-309, 313-315
 wounds—
 by skin grafts, 88-89, 104
 in prisoners of war, 66
 of joints, 77
See also Delayed primary wound closure.
- Clot formation in fractures of radial head, 130
- Colchicine, 28
- Collapse of radius in comminuted fractures, 120
- Collateral circulation of femoral head, 245
- Collateral ligaments of knee joint, 306
- Collection of clinical data, 8, 9
- Colles fracture, 121, 134
- COLLOM, Maj. SPENCER A., Jr., 239, 241
- Colostomy, 52, 60, 81, 146, 237, 240
- Columnar bone in radial head, 121
- Combat fatigue, 191
- Combat soldiers:
 arch supports for, 44
 return of, to duty after elective surgery, 185, 186
- Combat training, injuries in, 14
- Combined penicillin-sulfonamide therapy, 169, 174, 309, 313, 315, 316
- Command responsibility in cold injury, 32
- Commercy, 41, 69
- Comminution:
 as indication for excision of patella, 309
 cause of, in fractures about hip joint, 225
 in combat injuries, 119
 in fractures—
 of bones of foot, 154
 of bones of leg, 151
 of femur, 149
 of humerus, 144
 of pelvis, 146
 of radial head, 120, 122, 128
 resulting from land-mine explosions, 166
- Comparison of 1944-45 techniques of amputation, 163-165
- Compensation aspects of injuries of hip joint, 293
- Complete dislocations of acromioclavicular joint, 191-219
 arthritis after, 216-217
 case histories, 206, 209, 213-215
 complications of, 216-219

- Complete dislocations of acromioclavicular joint—Continued
 diagnosis of, 202
 etiology of, 191
 experimental observations in, 200-201, 210
 fractures associated with, 215-216
 literature of, 194, 195, 198, 201, 210
 management of, 195, 199, 202-215
 nature of lesion of, 197-199
 pathologic process in, 199-201
 prognosis of, 195, 203
 prognostic tests in, 207-209
 results in, 202, 204, 205, 206, 207-210, 211, 212, 217
 roentgenologic examinations in, 199, 202, 207, 216, 217, 219
 subluxation after, 209
 surgery in, 203, 204, 207, 210-215
- Complications of—
 combined bone-vascular injuries, 107
 dislocations of acromioclavicular joint, 216-219
 external fixation, 116
 injuries about hip joint, 238-247, 261-262, 289-296
 Tobruk splint, 113
- Compounding wounds, nonclosure of, 76, 150, 151
- Compresses in—
 osteitis, 173
 osteomyelitis, 174
 wound infections, 23, 89, 173
- Compression fractures of—
 acetabulum, 275
 acromioclavicular joint, 203
 clavicle, 199, 215
 femur, 296
 os calcis, 154
- Concepts of orthopedic surgery, 19
- Concurrent illness, 170
- Concussion injuries, 167
- Conditions—
 governing timelag, 78
 of wounding, 74
- Condyles of—
 femur, 306, 307, 308, 309
 knee joint, 306, 309, 311, 312
- Conferences—
 with senior consultant, 8, 20
 with British and Canadian consultants, 29
See also Meetings.
- Congenital absence of—
 clavicle, 212
 diarthrosis of shoulder joint, 196
- Congenital malformations of bones of feet, 187
- Congenital subluxation of shoulder joint, 196
- Conoid ligaments, 198, 200, 201, 211, 217
- Conservation of—
 bone fragments, 28, 84
 skin, 84, 160
- Conservatism in amputation of upper extremity, 156, 159
- Conservative management of—
 acromioclavicular dislocations, 195, 199, 203-210
 carpal scaphoid fractures, 134-135, 138-139, 142-143
 injuries about hip joint, 226, 227-228, 262, 266, 275, 282, 287, 304
 radial-head fractures, 123, 127-129
 vascular-bone damage, 155-156
- Constitution of hospital centers, 10, 11, 16, 17
- Constriction as cause of cold injury, 31
- Construction of—
 lumbosacral splint, 236
 plaster traction splint, 45-56
 revolving orthopedic frames, 52-53, 236
 traction cradle, 50
 Urist splint for acromioclavicular dislocations, 206-207
- Consultant(s):
 access of, to army areas, 10
 access of, to higher medical authority, 7
 Anglo-American, meeting of, 31
 in medicine, 7
 in orthopedic surgery:
 Ninth U. S. Army, 10, 29
 Royal Air Force, 36
 in surgery, 7, 10
 Ninth U. S. Army, 10, 29
- Consultant system, 7-18, 37, 73
- Consultation—
 before amputation, 161, 165
 with psychiatrist, 170
- Continent, the:
 evacuation from, 22, 58, 78, 165
 air, 32, 55-56
 holding period on, 68, 78-79, 113
 hospital centers on, 17
 hospitals on:
 administration of, 30
 arrival of, 17, 55, 70

- Continent, the—Continued
hospitals on—continued
utilization of, 17
visits of senior consultant to, 8, 19,
29-34
inadequate debridement on, 89
invasion of, 14, 16, 17, 55, 73, 74
junior consultants on, 8-9, 39, 75
orthopedic facilities on, 41, 43-44
provision for shoe corrections on, 45
use of skeletal traction on, 79, 113
- Contraindications to—
delayed primary wound closure, 79, 82,
83
internal fixation, 120
local anesthesia at debridement, 87
surgery in injuries about hip joint, 247,
266
Tobruk splint, 111
wound closure in injuries about hip joint,
234
- Control of—
hemorrhage, 167, 224, 307
trenchfoot, 32
- Contusions of nerves, 104, 105
- Convalescent installations:
4th Convalescent Hospital, 32
827th Convalescent Center, 134-143
- Convalescent wards, 60
- CONWELL, H. EARLE, 205, 206
- Copper sulfate hematocrit determinations,
167
- Coracoacromial syndesmosis, 195
- Coracoclavicular ligaments, 199, 200, 201,
216, 218
- Coracoclavicular screw, disadvantages of,
211-212
- Coracoid process, fractures of, 191, 198-
199, 206, 211, 215
- Coronary ligament of elbow, 122
- Cortex of bone, damage to, in war wounds,
307
- Cotton sutures, 88
- Cotyloid labrum, 269
- Cotyloid ligament, 254, 278
- Cotyloid notch, 259
- Counterdrainage, 84, 88, 173
Ocounterincisions for dependent drainage, 95
- Counterpressure in management of frac-
tures, 49, 165
- Countertraction, 235
- Coxarectal fistula, 244
- Coxa vara, 149, 235
- Cramer wire, 46
- Creeping bone replacement, 296
- Crepitation in—
acromioclavicular dislocations, 202, 219
injuries of hip joint, 276, 293
- Crimean War, 221
- Criteria of—
delayed primary wound closure, 82, 86
discharge in fractures of radial head, 130
evacuation in trenchfoot, 32
wound closure after secondary debride-
ment, 88
- Cross union in fractures of forearm, 119
- Cruciate ligaments of knee joint, 312
- Crutchfield tongs, 53
- Curettage in osteomyelitis, 174
- Cystic bone changes in carpal scaphoid
fractures, 137, 138, 142
- Cystostomy, 146, 237
- Damage to—
blood supply in—
injuries about hip joint, 275, 278
wounds of knee joint, 306
capsule of knee joint, 306
collateral ligaments of knee joint, 306
nerves in popliteal fossa, 306
quadriceps tendon, 306
retinacula in injuries about hip joint, 269
sciatic nerve, 283
soft tissues in injuries about hip joint, 255,
258, 269, 270
- Dashboard blow, 253
- Dashboard fractures of acetabulum, 262
- Data. *See* Statistics.
- Data of injury recorded on cast, 109
- D-day, 19, 91, 168
amputation caused by special missiles
after, 166
caseload of general hospitals after, 57
caseload of transit hospitals after, 56
chemotherapy after, 169, 238
correction of errors in transportation
splinting before, 110
directions for amputation before and
after, 158-161, 162-163
elective surgery before and after, 185
hospital staff conferences before, 39
incidence of noncombat injuries before
and after, 119
management of special fractures before,
143, 144, 152, 154, 224-225
preparation of Manual of Therapy be-
fore, 36, 74-75, 82
professional training before, 35-39, 110

- D-day—Continued
 provision of arch supports before, 44
 psychiatric therapy after, 170
 rehabilitation program after, 177
 use of internal fixation before, 117
- Dead space, obliteration of, 88
- Deaths—
 from clostridial myositis, 26, 156, 174
 from orthopedic injuries, 69, 70, 240, 305, 307
 from transfusion reactions, 113
 from wounds of—
 buttocks, 84
 thigh, 84
See also Case fatality rates.
- Debridement, 15, 23, 55, 57, 68, 73, 74, 83-87
 before amputation at elective site, 164
 by nonorthopedic personnel, 15
 delayed, 43, 67
 edema after, 168
 errors at, 37, 101-102
 in clostridial infections, 26, 174
 in fractures, 76
 about hip joint, 224-232, 249
 of femur, 147
 in transit hospitals, 58
 in wounds of knee joint, 315
 inadequacy of, with local anesthesia, 87
 influence of, 86, 89, 100, 169-170, 173, 174, 226-227, 316
 ligation of popliteal vessels at, 113
 omission of, 23, 307
 principles of, 37, 83-85, 103-104
 secondary hemorrhage after, 175
 technique of, 84-85, 308-310
 wound closure after, 82
 wound infection after, 173
See also Initial wound surgery, Secondary debridement.
- Decubitus ulcers, 52, 109, 113, 168, 176
- Deficiencies in orthopedic supplies, 43
- Definitive splinting after reparative surgery, 109-110
- Definitive surgery—
 in combined nerve-bone injuries, 105
 in United Kingdom Base, 43
 in Zone of Interior, 26
 on prisoners of war, 66
- Deformity—
 after acromioclavicular dislocations, 199, 202, 211
 after closed plaster management, 73
 after wounding, 171
- Deformity—Continued
 in fractures of—
 clavicle, 143
 shaft of femur, 149
 in supracondylar fractures of femur, 149
- Degenerative arthritis after—
 carpal scaphoid fractures, 138, 139
 injuries about hip joint, 261, 262, 301
- Delay in—
 delayed primary wound closure, 85-87, 88, 91, 95
 because of infection, 87
 evacuation because of vascular damage, 175
 wound healing, 87
- Delayed primary closure of capsule of knee joint, 313-315
- Delayed primary wound closure, 22-24, 37, 61, 73, 82-83, 85-89, 168
 by pedicle grafts, 89
 by split-thickness skin grafts, 88-89
 contraindications to, 79, 82, 83
 definitive splinting after, 109-110
 evolution of, 81-83
 in fractures—
 about hip joint, 234, 240-241, 248, 249
 of bones of leg, 151
 of femur, 147, 150
 in Mediterranean theater, 81-82, 83
 in osteitis, 173
 in prisoners of war, 63, 66, 103
 in unfavorable cases, 101-104
 in wounds of—
 forearm, 119
 knee joint, 310, 313, 316
 incidence of infection after, 118
 management of fractures at, 89-91
 removal of sutures after, 109
 results of, 82, 83, 91-104, 313
 shock after, 115
 skeletal traction after, 114
 tactical situation in relation to, 79
 technique of, 87-89
- Delayed wound healing—
 in closed plaster technique, 73
 with foreign bodies in situ, 23-24
- Deltoid muscle, 199, 201, 209
- Demonstration of corrective exercises, 178
- Dentate fractures of femur, 149
- Dependent drainage—
 after secondary resection of knee joint, 312
 by counterincision, 95
 in fractures of femur, 117

- Derwin Training School, 38
 Desert areas, wounds sustained in, 74
 Destruction of tissue as indication for amputation, 155
 Developmental malformations of feet, 187
 Deviation of—
 radius, 120
 ulna, 120
 Diagnosis of—
 carpal scaphoid fractures, 21-22, 133-134, 138, 141-142
 clostridial myositis, 156
 complete acromioclavicular dislocations, 202
 diastasis of inferior tibiofibular joint, 153
 fractures of radial head, 126-127
 injuries about—
 ankle, 152
 hip joint, 263, 282, 292
 trenchfoot, 31
 wounds of knee joint, 306-307
 Diarthrosis, 195, 196
 Diastasis of inferior tibiofibular joint, 153
 Dicumarol (bishydroxycoumarin), 291
 Diddington, 14
 Dietary supplements, 114
 Differential diagnosis of—
 clostridial infections, 156
 traumatic arthritis, 293
 Difficulties—
 in management of injuries about hip joint, 275-276
 in reduction of acromioclavicular dislocations, 204
 in rotation of orthopedic personnel, 18
 in training of orthopedic personnel, 35, 37
 of supply, 43
 of surgery for vascular injuries, 155-156
 Digits, circulatory status of, during transportation, 109
 Dilatation of peripheral vessels by whisky, 107
 Dillehunt torso cast, 206
 Diplomates of American Board of Orthopaedic Surgery, 11
 Direct injuries of knee joint, 305
 Directives, 7, 82, 88
 Dirty wound after inadequate debridement, 83
 Disability:
 after acromioclavicular dislocations, 199, 202, 207
 after arthrotomy of knee joint, 186
 Disability—Continued
 after fractures of radial head, 121, 130-132
 after injuries about hip joint, 262, 268, 301-302
 after resection of clavicle, 212
 after wounding, 171
 of feet, 187-188
 reduction of, by proper methods of wound closure, 63
 Disarticulation:
 disadvantages of, 162
 of hip joint, 244-245, 249, 275, 283, 285
 Dislocations:
 civilian type, 67
 of carpus, 28
 of clavicle, 201, 206, 207-209
 of elbow joint, 27
 of hip, 28, 70, 258, 260-261, 275-288
 of knee joint, 166
 of sacroiliac joint, 289
 See also Complete dislocations, Incomplete dislocations.
 Dispensaries, general:
 9th—45
 10th—45
 Displacement—
 in fractures of—
 femur, 149, 150, 258, 263, 269, 275, 282, 284-288, 291
 foot, 154
 inner table of pelvis, 263
 leg, 151
 neck of astragalus, 153
 posterior malleolus, 152
 radial head, 122, 123
 scapula, 198, 199
 of fractures during transportation, 148
 Disposition boards, 179, 186
 Dissemination of policies, 7, 8, 74-77
 Distal traction in fractures of pelvis, 146
 Distraction of bone fragments, 25, 115, 116
 Disuse atrophy of neck of femur, 261
 DIVELEY, Col. REX L., 7, 177, 187
 Division clearing stations, 29, 78
 battle exhaustion in, 170
 penicillin therapy in, 169
 Division medical units, training of, 36
 Division of Rehabilitation, Office Theater Chief Surgeon, 7
 DOLLINGER, J., 258
 Donor site, 89

- Drainage:
 after debridement, 84
 after delayed wound closure, 83, 88, 95, 173, 313
 after inadequate debridement, 83
 after internal fixation, 118
 after secondary debridement, 88
 after secondary resection of knee joint, 312
 in fractures—
 about hip joint, 234
 of femur, 25
 in osteomyelitis, 26
 in superficial wound infections, 173
 in suppurative arthritis of hip joint, 249
 in wounds of buttocks, 84
 of knee joint, 311
 prolonged timelag as indication for, 67
See also special types.
- Drainage fluid, loss of serum in, 95
- Draining sinuses, 173
- Drains, secondary hemorrhage from pressure of, 174
- Dressing of—
 amputation stump, 161, 162
 wounds in skeletal traction, 114, 235
 wounds on battlefield, 167
- Dressings, access to wounds in plaster for, 46, 52, 105, 114, 175
- Drill points, 43
- Duration of—
 conservative management in acromioclavicular dislocations, 203
 drainage in superficial infections, 173
 elevation of extremity after debridement, 168
 evacuation splinting, 84
 fracture operations, 114
 hospitalization:
 in combined nerve-bone injuries, 105, 106
 in fractures of radial head, 129-132
 reduction of, by proper methods of wound management, 63
 immobilization—
 after resection of radial head, 129
 in acromioclavicular dislocations, 204, 205, 207
 in carpal scaphoid fractures, 135-138, 139, 143
 in disastasis of inferior tibiofibular joint, 153
- Duration of—Continued
 immobilization—Continued
 in fractures of—
 bones of foot, 153-154
 bones of forearm, 120
 humerus, 146
 radial head, 127, 128
 in injuries about ankle, 151
 in injuries about hip joint, 249, 260-261, 266
 in Tobruk splint, 112
 skin traction after amputation, 161, 163
- Dysfunction after closed plaster technique, 73
- Early secondary closure. *See* Delayed primary wound closure.
- East Anglia, 14, 73
- Eburnation after acromioclavicular dislocation, 199
- Echymoses in—
 acromioclavicular dislocations, 198
 injuries about hip joint, 293
- Edema:
 after delayed primary wound closure, 109
 after ligation of popliteal vessels, 106
 after wounding, 168
 as manifestation of protein deficiency, 168
 control of—
 by elevation of limb, 95, 105-106
 by sympathetic block, 107
 in vascular injuries, 86
 of rectum, 291
- Edinburgh, 177
- Effect of—
 antibiotic therapy, 103-104
 chemotherapy, 103-104
 delay in reparative surgery, 91
 high-velocity missiles, 84
 land mines, 157
 location of wound on healing, 102, 103
 poorly fitted shoes, 187, 188
 size of wound on healing, 103
- Effusion into—
 elbow joint, 127
 knee joint, 307, 310
 shoulder joint, 202
- Elastoplast, 205
- Elbow:
 ankylosis of, 77
 aspiration of, 127, 128, 130, 131
 coronary ligament of, 122

Elbow—Continued

- disability in, after acromioclavicular dislocation, 207
- dislocation of, 27
- exposure of, in Monteggia fractures, 119
- flexion, of, in occurrence of radial-head fractures, 121
- hemorrhage into, 126, 127, 128, 130
- involvement of, in fractures of humerus, 146

Election, site of, 160, 164, 165

Elective bone grafts, 185

Elective surgery, 68, 185-186, 188

Electric nerve stimulation, 104, 106

Elevation of limb—

- after debridement, 168
- in vascular injuries, 86

Elevator, pelvic, disadvantages of, 235

ELLIS, J. S., 226, 235, 239, 243

Emergency splinting, 167

Emergency surgery in transit hospitals, 55

Emotional status of orthopedic casualties, 170

Emptying of stomach before surgery, 167

Endothermy, 147

England, 36, 50, 67, 68, 121, 177, 191

Enlisted personnel as—

- surgical technicians, 60
- ward attendants, 38

Equinus varus position, 110, 154

Equipment for care of orthopedic casualties, 42-54

Erosion of blood-vessel wall, 174

Errors—

- at debridement, 37, 85-87, 101-102, 174
- in application of plaster casts, 110
- in assignment of—
 - orthopedic personnel, 61
 - soldiers for limited duty, 179, 187-188
- in closure of infected wounds, 173
- in delayed primary wound closure, 82
- in diagnosis of carpal scaphoid fractures, 133
- in evacuation practices, 8, 11, 22, 33-34, 79-80
- in insertion of Kirschner wire, 115
- in management of—
 - amputation stumps, 25-26
 - battle casualties, 8, 19, 73
 - dislocations of elbow joint, 28
 - fractures of clavicle, 143
 - fractures of foot, 154
 - fractures of forearm, 119
 - fractures of leg, 33

372572°—56—25

Errors—Continued

- in management of—Continued
 - fractures of long bones, 34
 - fractures of metacarpals, 33
 - injuries about hip joint, 224, 227-228
 - secondary hemorrhage, 175
 - vascular injuries, 86
 - wounds of knee joint, 307, 310, 314, 315, 316
- in performance of elective surgery, 185
- in placing of—
 - colostomy stoma, 240
 - drains, 174
- in rehabilitation program, 177
- in splinting, 85, 174-175
- in use of—
 - internal fixation, 118
 - penicillin, 85
 - traction, 25, 148-149, 165-166
- of surgical judgment, 27

Establishment of—

- clinical policies, 74-77
- consultant system, 7
- junior consultant system, 8

Etiology of—

- acromioclavicular dislocations, 191
- avascular necrosis of femoral head, 245-246, 295-296
- clostridial infections, 173
- injuries about hip joint, 252-253, 269
- trenchfoot, 31
- wounds of knee joint, 305

Evacuation:

- change of casts before, 109
- delay in, because of possible bleeding, 175
- errors in, 8, 11, 22, 33-34, 79-80
- from Continent, 22, 30, 58, 68, 70, 78
- from transit hospital, 55, 56-57
- hospitals, 10, 11, 13, 15-16, 29-32, 36, 38, 43, 44, 55, 68, 73, 76, 78, 79, 81, 109, 111-113, 157, 167, 169, 170, 263, 282, 307, 310
- influence of tactical situation on, 260
- of casualties—
 - managed by closed plaster, 83
 - with fractures of clavicle, 143
 - with injuries about hip joint, 260, 277
 - with trenchfoot, 32
- policies of, 8, 78-80
- skin traction during, 163
- to Zone of Interior, 12, 23, 26, 44, 53, 61, 83, 89, 92, 105, 109, 114, 135, 140, 142, 147, 153, 154, 170, 174, 236, 268, 277

- Evacuation hospitals. *See* Hospitals, evacuation.
- Evaluation of—
 candidates for arthrotoomy of knee joint, 186
 damage in wounds of knee joint, 307
 emotional status, 170
 orthopedic personnel—
 by senior consultant, 11-14, 20
 in training, 16
 surgical risk in blast injuries, 166
 Tobruk splint, 112-133
- Evolution of—
 acromioclavicular joint, 195
 clinical policies, 73-74
 delayed primary wound closure, 81-83
 management of injuries about hip joint, 226
 technique of amputation, 158-165
- Exchange of orthopedic personnel, 37
- Exercises, 50, 114, 127, 143, 236, 237, 276, 282, 310
- Experimental observations in—
 acromioclavicular dislocations, 200-201, 210
 avascular necrosis of femoral head, 295
 injuries about hip joint, 263, 294
 wounds of hand, 27
- Exploration in—
 nerve injuries, 105
 secondary hemorrhage, 174
 wounds of knee joint, 306
- Exposure, protection from, during resuscitation, 167
- Extension exercises, 127, 130
- Extension, limitation of, in fractures of radial head, 126
- External fixation, 25, 63, 77, 114, 116, 154
- External lateral ligament of ankle, 151
- External malleolus, 152
- External rotator muscles, 275, 279
- Extremities:
 incidence of wounds of, 10, 81
 position of, in transportation splinting, 109
- Face, fractures of, 95
- Facilities for orthopedic care, 41-54
- Factors influencing healing in carpal scaphoid fractures, 135-142
- Failure of wound healing—
 after delayed primary wound closure, 23-24, 96-97, 99, 101, 103-104
 due to protein deficiency, 168
- Failure of wound healing—Continued
 in fractures of—
 bones of foot, 97
 bones of leg, 97
 femur, 97
 pelvis, 97
- Failure of conservative management in—
 carpal scaphoid fractures, 135, 138, 142
 injuries about hip joint, 282
- Failure of split-thickness skin grafts, 89, 96
- Fascia:
 inadequate removal of, at debridement, 86
 transfer of, in dislocations of shoulder, 211
- Fascia lata:
 isograft, 211
 use of, in ligamentous repair, 200
- Fascial planes, opening of, at debridement, 84
- Favorable factors in orthopedic injuries, 170
- Femoral artery, ligation of, 106
- Femur:
 anatomic distribution of fractures of, 112
 association of nerve injuries with fractures of, 104, 105, 291
 avascular necrosis of head of, 245-247, 255, 261, 275, 289, 293-296, 301
 blood loss in fractures of, 147, 167
 blood supply of head of, 254, 275, 295
 clostridial myositis after fractures of, 174
 damage to condyles of, 307, 309
 displacement of head of, 149, 150, 258, 263, 269, 275, 282, 284-288, 291
 disuse atrophy of neck of, 261
 drainage in fractures of, 25, 117
 failure of delayed primary closure in fractures of, 97
 foreign bodies in condyles of, 308
 fractures of, 22, 23, 33, 70, 95, 101, 147-150, 239, 269, 284-288, 292, 305, 306, 312, 315
 function of head of, 243
 impact fracture of head of, 245
 impacted fractures of head of, 284-285
 indications for resection of head of, 243
 internal fixation in fractures of, 27, 117
 intrapelvic protusion of head of, 262, 263, 296, 301-302
 management of fractures of, 24-25, 27, 105, 114, 117, 148-149
 necrosis of, in fractures about hip joint, 246

Femur—Continued

- position of head of, in jeep transportation, 253, 254
- posterolateral incision in fractures of, 117
- rarefaction of head of, 246
- repeated application of skeletal traction to, 115
- resection of head of, 232, 243-244, 249
- resorption of head of, 246
- sclerosis of—
 - head of, 246
 - neck of, 246
- stellate fractures of, 287
- subchondral compression fractures of, 296
- subluxation of head of, 246
- supracondylar fractures of, 31, 106, 115, 149-150
- Tobruk splint in fractures of, 30, 33, 110-113
- traction through, in pelvic fractures, 146
- transportation splinting in fractures of, 76, 147-148

FERGUSON, M. Sgt. ROBERT, 52

Fever in pyoarthrosis of knee joint, 311

Fibula:

- fractures of, 24, 25, 45-49, 70, 76, 151
- See also* bones of leg.

Fibrocartilage, excision of, in carpal scaphoid fractures, 141

Field hospitals. *See* Hospitals, field.

Fifteenth U. S. Army, 10, 70

Figure-of-8 bandage, 143

Findings at operation in fracture-dislocations of hip, 269-275, 279

Fine-mesh gauze, 84, 102, 147, 165

Fingers:

- mobilization of, in splinting, 76, 120, 139
- wounds of, 26, 27

First aid:

- in injuries about hip joint, 223-244, 259, 263, 267
- in wounds of knee joint, 307
- speed of, 223

First U. S. Army, 29, 32, 86

Fissure fractures of—

- acetabulum, 258
- acromion process, 215

Fixation of carpometacarpal joints, 120

Fixed hospitals:

- mission of, 85
- tented hospitals serving as, 41
- See also* General hospitals, Station hospitals.

Flexion:

- limitation of, in fractures of radial head, 126
 - of elbow, in etiology of fractures of radial head, 121
 - of hips in—
 - fracture management, 146, 235
 - jeep transportation, 252, 254
 - plaster traction splint, 46
 - of knee in Tobruk splint, 30
- Flexion exercise, in fractures of radial head, 127, 130

FLINN, Maj. IRVINE M., Jr., 188

Fluid balance, maintenance of, 114

FOISIE, Lt. Col. PHILIP S., 179

Followup—

- in fractures of forearm, 121
- in injuries about hip joint, 296-304
- of nontransportable casualties, 30

Foot:

- amputation of, 26, 154
- disabilities of, 68, 187-188
- edema of, after wounding, 168
- elective surgery on, 185, 186, 188
- failure of delayed primary wound closure in wounds of, 97
- fractures of bones of, 76, 102, 153-154
- malformations of, 187
- position of, in splint, 76, 110
- soft-tissue lesions of, 187
- strain from overtraining, 187
- training in disabilities of, 188

Foot drop, 291-292

Footgear, relation of, to cold injury, 31

Forearm:

- edema of, after wounding, 168
- fractures of bones of, 113, 114, 119-133
 - statistics on, 120
- position of, in occurrence of fractures of radial head, 121, 126
- transportation splinting in injuries of, 76
- wounds of, 102, 119

Foreign bodies:

- in wounds caused by land mines, 166
- management of—
 - in joint injuries, 23-24, 37, 77, 87, 225, 227, 233-243, 305, 308, 315
 - in soft-tissue wounds, 84, 164, 173
- retention of, as cause of—
 - secondary hemorrhage, 174
 - wound infections, 173

Forward hospitals, 10, 84, 85. *See also* Evacuation hospitals, Field hospitals.

Fovea capitis femoris, 285

- Foxhole foot, 31
- Fracture beds, supply of, by British, 42
- Fracture-dislocations of—
 ankle, 153
 hip joint, 254, 269-304
- Fracture Facts, 179
- Fracture tables, 42, 43, 44, 60
- Fractures:
- associated with acromioclavicular dislocations, 215-216
 - associated with nerve injuries, 21, 59, 81, 83, 84, 85, 86, 104-106, 114, 144, 146, 306
 - associated with vascular injuries, 59, 78, 80, 81, 85, 86, 106-107, 113, 155-156, 166, 306
 - delayed primary wound closure in, 23-24, 82-83
 - distraction of, in external fixation, 116
 - early management of, in Mediterranean theater, 73
 - errors in management of, 79
 - external fixation of, 116
 - in transport pilots, 56
 - incidence of, 29, 81
 - instruction on, in London hospitals, 36-37
 - internal fixation of, 116-118
 - location of, in relation to management, 114
 - management of, 109-154
 - by nonorthopedic personnel, 16
 - by plaster techniques, 38-39
 - by skeletal traction, 22, 113-116
 - of acetabulum, 254, 276-282, 301-302
 - of acromion process, 191, 199, 206, 215
 - of ankle, 56, 76
 - of bones of—
 - face, 95
 - foot, 76, 153-154
 - leg, 101, 112, 151
 - disadvantages of Böhler-Braun technique in, 151
 - of carpal scaphoid, 28, 119, 133-143
 - of cervical spine, 53, 147
 - of clavicle, 95, 117, 143, 191, 198, 215
 - of condyles of—
 - femur, 306, 307, 308, 309, 315
 - tibia, 309, 312
 - of coracoid process, 191, 206, 215
 - of external malleolus, 152
 - of femur, 22, 23, 24-25, 27, 30, 33, 70, 76, 95, 101, 104, 105, 110-113, 114, 115, 117, 147-150, 167, 174, 305, 312
- Fractures—Continued
- of fibula, 24, 25, 45-49, 70, 76, 151
 - of head of femur, 269, 284-288, 292, 296
 - of humerus, 24, 25, 27, 76, 95, 101, 104, 105, 106, 114, 117, 144-146
 - of ilium, 302
 - of ischium, 282, 302
 - of long bones, 25, 33-34, 41, 63, 100-101, 113-116, 157
 - of metacarpals, 33
 - of neck of—
 - astragalus, 153
 - femur, 149
 - of noncombat origin, 119-154
 - of os calcis, 153-154, 166
 - of patella, 34, 95, 117, 305, 309, 312
 - of pelvis, 26, 50-54, 146-147, 283, 289
 - of posterior malleolus, 152
 - of pubis, 302
 - of radial head, 119, 121-133
 - of radial neck, 121
 - of radius, 34, 70, 117, 120
 - of scapula, 95
 - of shaft of femur, 112, 149
 - of spine, 95, 147
 - of tibia, 24, 25, 33, 45-49, 70, 76, 95, 114, 117, 151, 166, 305, 312, 315
 - of trapezoid ridge, 215
 - of trochanter, 28, 247
 - of ulna, 34, 117, 119
 - of vertebrae, 95
 - problems of, 81
 - reduction of, by manipulation, 114-155
 - regional, 119-154
 - transportation splinting in, 67, 76, 84, 85, 87, 109-113, 144, 147-148, 165-166, 222-224, 234-235, 236, 237, 259-260, 263, 267, 309, 310
- Fractures about hip joint, 221-304
- adjunct therapy in, 237-238
 - amputation in, 244-245
 - antibiotic therapy in, 22, 238, 239, 245, 246, 249
 - arthrotomy in, 226-232, 249
 - association of other wounds with, 225, 239-240, 241, 244
 - bacteriology of infections of, 233, 239
 - blood replacement in, 223, 224, 238, 249
 - case fatality rate in, 221, 223, 224, 239, 240-241
 - case histories:
 - avascular necrosis of femoral head, 246-247

- Fractures about hip joint—Continued
 case histories—Continued
 inadequate debridement, 228, 229, 241-243
 infection from colostomy, 240
 reconstructive surgery, 248-249
 Smith-Petersen approach, 232-233
 chemotherapy in, 238, 239, 241, 249
 complications of, 236, 237, 238-247, 249-250
 delayed primary wound closure in, 234, 248
 disarticulation in, 244-245
 errors in management of, 227-228
 first-aid measures in, 223-224
 history of, 221
 in Mediterranean theater, 239
 incidence of, 239-240
 incision in, 232-233
 initial wound surgery in, 224-232, 249
 literature of, 226
 management of, 28, 223-250
 in revolving frames, 50-54
 in World War I, 224, 225-226, 235, 239, 241, 243
 mechanics of injury in, 225
 nutritional status in, 237-238
 principles of management of, 235, 291
 protein deficiency in, 238
 reconstructive surgery in, 247-249
 results of, 221-222, 228-232, 233, 241, 248-249
 roentgenologic examination in, 233, 246
 saucerization in, 227, 243
 shock in, 224, 227
 skeletal traction in, 246, 248, 249
 suppurative arthritis in, 238-245
 transportation splinting in, 223-224, 234-235
- France, 67, 69, 74, 78, 112, 146, 174
 FRANKAU, C. H. S., 235, 239
 Frankfurt, 191
 FRANZ, C., 239
 Free French, 21
 French civilians, 56
 French management of fractures about hip in World War I, 226
 French medical service, 39
 French techniques in suppurative arthritis of knee joint, 311
 French use of lumbosacral splint, 236
 Frenchay Park, 67
 Frequency. *See* Incidence.
 Fresh fractures of carpal scaphoid, 134-138
- Full-ring leg splint, 76, 111, 112
 Full-thickness skin grafts, 88, 105, 174
 Function(s) of—
 acetabulum, 254, 262, 301
 acromioclavicular joint, 201
 articulations of clavicle, 210
 clavicle, 212
 coracoacromial syndesmosis, 195
 femoral head, 243
 hand, 156, 159
 orthopedic surgeons in evacuation hospitals, 15-16
 senior consultant, 7-8, 19
 surgeons in—
 fixed hospitals, 85
 forward hospitals, 85
- Functional results in—
 carpal scaphoid fractures, 135, 138
 closed plaster technique, 83
 fractures—
 about hip joint, 221
 of ankle, 153
 of forearm, 120
 of humerus, 146
 injuries of—
 peroneal nerve, 292
 radial nerve, 106
 resection of femoral head, 243
 wounds of knee joint, 313, 316
- Fusion:
 in fracture-dislocations of hip joint, 284, 302
 in fractures of acetabulum, 268
 of acromioclavicular joint, 212
 See also Arthrodesis.
- Gangrene:
 as indication for amputation, 26, 159
 evacuation of casualties with, 79
 of circulatory origin, 113, 156, 159
- Gas bacillus infection. *See* Clostridial infections.
- Gastrocnemius muscle, 149, 150, 156
 Gastrointestinal tract, injuries of, 52
 Gemelli, 258, 272, 275, 279
 General considerations of professional training, 35
 General dispensaries:
 9th—45
 10th—45
 General hospitals, 11, 13, 15, 16, 24, 38, 43, 44, 55-56, 57, 58-61, 73, 78, 79, 83, 87, 166, 177, 310
 See also Hospital(s), general.

- General medical policies, 77-78
 General practitioners, 113
 General surgeons, 15
 Genitourinary surgery, 59
 Genitourinary tract, injuries of, 52
 Georgia, 101
 German civilians, treatment of emergency conditions in, 70
 German management of injuries about hip in World War I, 226
 German medical officers, care of protected prisoner personnel by, 63-66
 German prisoners of war, 56, 63-66, 69
 German use of pelvic suspension, 236
 Germany, 78, 91, 157, 191
 GEROW, Maj. Gen. LEONARD T., 187
 Gibben splint, disadvantages of, 205
 GIRDLESTONE, G. R., 243
 Girdlestone technique for resection of femoral head, 243-244, 249
 advantages of, 243-244
 Glasgow, 69
 Gluteal setting-up exercises, 282
 Gluteus maximus, 279
 GOULD, Maj. NATHANIEL, 121
 Gout, 28
 Granulation, wound healing by, 82, 83
 Grasping pose of hand, 134
 Gravity reduction of dislocations of hip, 259
 Great Britain. *See* United Kingdom Base.
 GROVE, Lt. Col. JOHN A., 91, 95
 Guided missiles, 166
 Guillotine amputation, 159-161
 GURD, F. B., 199
- HAINES, H. H., 263
 Haines apparatus, 63
 Half-ring splint, 76
 Hammertoes, 185
 HAMPTON, Col. OSCAR P., Jr., 239, 241
 Hand:
 function of, 156, 159
 after fractures of forearm, 120
 mobilization of, in wounds of forearm, 26
 position of—
 in occurrence of fractures of radial head, 121, 126
 in splinting, 134-135, 143
 Hand centers, 21
 Hand grenades, 225
 Hand injuries, 21, 26-27, 59, 60, 102, 168
 Hanging cast, 76, 144, 145
 Harnesses, 205
 HAYS, Maj. Gen. S. B., 43
- Hayes splint, 224
 Head of femur:
 avascular necrosis of, 255, 275, 289, 293-296, 301
 displacement of—
 in jeep injuries, 258, 263, 269, 275, 282, 284-288
 into scrotum, 258
 fractures of, 269, 284-288, 292
 impact fracture of, 245
 impacted fractures of, 284-285
 intrapelvic protrusion of, 262, 263, 296, 301-302
 necrosis of, 246
 position of, in jeep transportation, 252, 254
 resection of, 243-244, 249
 resorption of, 246
 stellate fractures of, 287
 subluxation of, 246
 Head of radius. *See* Radial head.
 Head wounds, 32, 276, 290
 Healing—
 after delayed primary wound closure, 23-24, 83, 91-104
 by granulation, 82, 83, 99
 in acromioclavicular dislocations, 199, 201, 209, 210, 217
 in injuries about hip joint, 221, 260, 268
 in osteomyelitis, 26
 of wounds of forearm, 119
 Health of troops, 170
 Hemarthrosis of—
 elbow joint, 126, 128, 130
 knee joint, 150, 307, 315
 Hematocrit level before reparative surgery, 117, 167
 Hemoglobinuria, 168
 Hemolytic streptococcal infection, 239
 Hemopneumothorax, 32
 Hemorrhage, control of—
 in injuries of hip joint, 224
 in injuries of knee joint, 307
 on battlefield, 167
 Hemorrhage, failure of resuscitation because of, 167
 Hemorrhoidal veins, thrombosis of, 289, 291
 Hemorrhoidectomy, 21
 Hemostasis at—
 amputation, 160, 162
 debridement, 84
 Hemothorax, 81
 Herniation of intervertebral disk, 185, 186

- Hernioplasty, 21
 Hessen, 70
 High altitude, wounds sustained at, 74
 High-caloric diet, 238
 High-velocity projectiles, 84
 Hip joint:
 anatomy of, 254, 276
 ankylosis of, 262, 301
 anterior dislocation of, 258
 arthroplasty of, 254
 blood supply of, 245, 255, 295
 calcification of capsule of, 289, 292
 degenerative arthritis of, 262
 disarticulation of, 244-245, 249, 275, 283, 285
 exarticulation of, 232
 flexion of, in jeep transportation, 254
 fractures of, 28, 37, 46, 50-54, 69, 70, 221-250
 jeep injuries about, 251-304
 History, clinical, in fractures of radial head, 121, 126
 History of World War I, 185
 Holding hospitals, 22, 32, 68
 Holding period—
 for fractures of femur, 148
 in army area, 32
 in European theater, 99, 143, 154, 186, 260
 in forward hospitals, 85
 in relation to use of skeletal traction, 78
 in station hospitals, 127
 In United Kingdom Base, 78
 on Continent, 68, 78-79, 113
 Holland, 22, 31
 Homologous serum hepatitis, 240
 Hôpital de la Pitié, 41, 66
 Hospital center(s), 9-10, 17, 58-61
 advantages of, 58
 15th—23, 24, 91-100
 801st—119, 188
 802d—8, 9-10, 16, 42-45, 59-61, 120, 144, 147, 150, 151, 154, 178-179, 191, 221, 239, 251
 803d—58-59, 119, 168, 174
 804th—156
 814th—69-70
 Hospital trains, 22, 24
 Hospitalization, duration of:
 in combined bone-nerve injuries, 105-106
 in fractures of radial head, 129-132
 reduction of, by proper methods of wound closure, 63
 Hospitals:
 arrival of—
 in United Kingdom Base, 14, 16, 17, 35
 on Continent, 17
 caseload of, 55
 evacuation:
 2d—14, 29, 30, 74, 157
 41st—30, 69
 44th—29, 30, 32
 45th—33, 104
 77th—29, 31
 102d—31
 111th—33
 exchange of personnel between, 37
 field:
 8th—32, 33, 34
 46th—33
 51st—34
 53d—29
 for prisoners of war, 21
 general:
 19th—101-104, 150, 312
 22d—9-10, 22, 24, 25, 27, 28, 45, 47, 50, 52, 115, 151, 236
 23d—117
 40th—33
 46th—117
 48th—34
 50th—41, 69
 62d—29, 30
 67th—23, 24, 26, 27, 28
 68th—42, 43, 44, 144, 155
 74th—22, 25
 76th—33
 79th—22
 94th—86
 97th—25, 45, 191
 102d—21, 23, 25
 103d—23, 25, 26
 104th—22, 24
 106th—24, 25
 110th—56
 112th—24
 117th—21, 27
 121st—22, 23, 26, 27
 129th—179
 140th—28
 159th—25
 187th—23
 192d—22, 23
 203d—33
 216th—22, 23, 25, 26, 28, 168
 217th—41, 42, 55, 66, 69-70
 298th—67-69, 120, 185

- Hospitals—Continued
 in army area, 10-11, 70
 in United Kingdom Base, 9, 14, 15, 16, 17, 19-29
 on Continent, 9, 17, 30, 70
 orthopedic space in, 15-16, 42
 professional conferences in, 39
 relation of bed capacity to officers' rank, 18
 relation of timelag to location of, 78
 representative experiences of, 9-10, 67-70
 staging of, 17
 station:
 38th—56
 49th—74
 65th—121-133
 110th—22
 168th—121-133
 tented, for orthopedic casualties, disadvantages of, 41
 utilization of qualified orthopedic personnel in, at invasion, 17
 visits of consultants to, 8, 19-34, 73
 with excess of orthopedic personnel, 15
- Howard splint, 206
- Humerus:
 association of fractures of, with nerve injuries, 104, 105, 106
 fractures of, 24, 25, 27, 76, 95, 101, 117, 144-146
 function of articulations of, 210
- Hunkin cast, disadvantages of, 205
- Hunts, 14
- Hyperpyrexia in suppurative arthritis, 239, 311
- Ideal management of fractures about hip joint, 227-228
- Identifying sutures in nerve injuries, 84
- Iliac crests, traction through, 146
- Iliofemoral ligaments, 262
- Ilium, fractures of, 302
- Immediate flap amputation, 164
- Immersion foot, 28
- Immobilization—
 after debridement, 84
 after resection of radial head, 129
 after secondary resection of knee joint, 312
 as cause of trenchfoot, 31
 in acromioclavicular dislocations, 202, 204-210
- Immobilization—Continued
 in carpal scaphoid fractures, 134-135, 136-138, 139, 142-143
 in diastasis of inferior tibiofibular joint, 153
 in fractures of bones of—
 foot, 153-154
 forearm, 120
 in fractures of clavicle, 143
 in fractures of external malleolus, 152
 in fractures of femur, 245, 284-285, 296
 in fractures of humerus, 146
 in fractures of pelvis, 146
 in fractures of radial head, 127, 128
 in fresh fractures about hip joint, 224
 in injuries about ankle, 151
 in Tobruk splint, 110-113
 in wounds of—
 knee joint, 309, 313
 joints, 77, 109
- Improvisations in—
 equipment, 45-54
 footgear, 31
 shoe corrections, 44-45
 splinting, 224
- Inadequate debridement, 83, 85, 86, 87, 89, 173, 174, 226-227
- Incidence of—
 amputation, 157-158
 among German prisoners of war, 66
 avascular necrosis of femoral head, 246, 294
 clostridial myositis, 26, 156, 174
 complete acromioclavicular dislocations, 191
 disability after acromioclavicular dislocations, 202
 disability of feet, 187-188
 draining sinuses, 173
 failure of healing after reparative surgery, 99, 101
 fractures of radial head, 126
 infection after reparative surgery, 118
 internal fixation, 117
 jeep injuries of hip joint, 251, 252, 253, 262-263, 269, 302
 nerve-bone injuries, 106, 146
 noncombat injuries, 119
 orthopedic injuries, 29, 41, 42, 67, 81
 osteomyelitis, 26, 99, 100, 101
 posterior dislocations of hip joint, 258
 recurrent acromioclavicular dislocations, 202

- Incidence of—Continued
 shortening operations in nerve-bone injuries, 106
 suppurative arthritis, 238-239, 239-240
 transfusion reactions, 168
 trauma in youth, 252
 trenchfoot, 31-32
 wound infections, 74, 225
 wounds of—
 extremities, 10, 81
 knee joint, 305
- Incision and drainage in clostridial infections, 156
- Incision—
 for combined nerve-bone surgery, 105
 for debridement, 84, 86
 in fractures of radial head, 128-129
 in injuries about hip joint, 225, 232-233, 241-243, 249, 279
 in Monteggia fractures, 119
 for open circular amputation, 162
 for resection of femoral head, 243
 for secondary resection of knee joint, 312
 in wounds of knee joint, 308, 311, 312-313
- Incomplete fractures:
 of carpal scaphoid, 134
 use of traction cradle for, 50
- Incongruous joint surfaces, 197
- Indications for—
 amputation, 77, 113, 144, 155-157, 158, 159, 161-162, 177, 244-245, 311
 aspiration-instillation penicillin therapy, 310
 bone grafting in carpal scaphoid fractures, 141-142
 excision of patella, 309
 external fixation, 25, 116
 internal fixation, 116, 118, 121, 151, 277
 omission of delayed primary wound closure, 91
 penicillin therapy in German prisoners of war, 66, 169
 primary resection of knee joint 309-310
 resection of—
 clavicle, 213-215
 femoral head, 243-244
 secondary resection of knee joint, 311
 skeletal traction, 114, 120, 291
See also Selection of cases.
- Indirect injuries of knee joint 305-306
- Indirect violence in fractures of femur, 149
- Infantry Division(s):
 28th—31
 29th—187
 814th—32
- Infection:
 after amputation for clostridial infection, 163
 after arthrotomy, 150
 after debridement under local anesthesia, 87
 after delayed primary wound closure, 83
 after external fixation, 77
 after inadequate debridement, 83
 after internal fixation, 117, 118
 after secondary closure of amputation stump, 163
 after skeletal traction, 211
 as cause of secondary hemorrhage, 174
 as contraindication to—
 delayed primary wound closure, 87
 early reconstructive surgery, 247
 open reduction, 89, 120
 blood transfusion in, 167
 due to errors at debridement, 84, 86
 failure of resuscitation because of, 167
 freedom from, in World War II, 169
 in closed plaster technique, 73, 82
 in combined bone-rectal injuries, 60
 in fracture dislocations of ankle, 153
 in fractures of—
 femur, 23, 149, 150
 humerus, 146
 in injuries about hip joint 70, 233, 234, 236, 237, 238, 239, 249
 in prisoners of war, 73
 in wounds of—
 buttocks, 84
 knee joint, 305, 308-310, 313
 thigh, 84
 influence of location of fracture on, 239
 protein replacement in, 168
 risk of, with prolonged timelag, 49
 with use of pins, 115
See also Wound infections.
- Inferior tibiofibular diastasis, 153
- Influence of—
 age on delayed primary wound closure, 100
 antibiotic therapy on wound infection, 100
 blood replacement in reparative surgery, 100
 chemotherapy on wound infection, 100

- Influence of—Continued
 debridement, 100
 location of carpal scaphoid fractures, 135, 137, 138
 reduction of carpal scaphoid fractures, 137, 138
 vascular changes in carpal scaphoid fractures, 137-138, 139
- Inhalation anesthesia, 87
- Initial treatment of casualties in transit hospitals, 56
- Initial wound surgery, 15, 83-87, 167, 224-232, 249, 307-310, 312-313. *See also* Debridement.
- Injuries—
 associated with orthopedic injuries, 55
 due to mechanized equipment, 119
 due to land mines, 68
 in armored units, 69
 in mass combat training, 14
 of gastrointestinal tract, 52, 60
 of hand, 60
 of head, 32, 276, 290
 of sciatic nerve, 244, 245
 of soft tissues of feet, 187
 of spine, 42, 53
 sustained on D-day, 56
See also Wounds, special wounds.
- Innervation of wrist joint, 126
- Inspection of wounds, 87
- Instillation of penicillin into joints, 87, 169, 232, 309
- Inter-Allied medical meetings, 36
- Interaction of joints of hand, 120
- Internal derangements of knee joint, 186
- Internal fixation, 116-118
 in acromioclavicular dislocations, 210, 211
 in combined nerve-bone injuries, 105
 in fractures of—
 bones of leg, 151
 femur, 27, 117, 149, 150
 humerus, 117, 144
 neck of astragalus, 153
 patella, 117
 posterior malleolus, 152
 radius, 117, 121
 tibia, 49, 117
 ulna, 119
 in injuries about hip joint, 249, 262, 266-267, 269, 277, 279-282, 283-284, 292, 302, 303
 in Mediterranean theater, 118
 in Monteggia fractures, 119
- Internal fixation—Continued
 in wounds of knee joint, 310
 prohibition of—
 in forward hospitals, 76
 in prisoners of war, 66
- Intertrochanteric fractures, 149
- Intervertebral disk, 186
- Intestine, injuries of, 97, 227, 237, 239-240, 241
- Intramuscular penicillin therapy, 169, 173, 174
- Intrapelvic protrusion of head of femur, 262, 263, 296
- Invasion of Continent, 14, 16, 17, 55, 67, 68, 73, 143
 training of personnel for, 35-39
See also D-day.
- Invasion of Italy, 73
- Iron salts, 238
- Irreducible fracture-dislocations of hip joint, 282-284
- Irrigation at debridement, 84, 227, 249, 308
- Ischemia after use of Kirschner wire, 149
- Ischium:
 anatomy of, 254
 countertraction against, 165, 235
 fractures of, 283, 302
 pressure of Tobruk splint on, 234
- Isograft of fascia lata, 211
- Italy, 67, 73
- JACOBS, Maj. JULIAN E., 121
- Jeep dislocations of hip joint, 254-262, 297-301
- Jeep fracture-dislocations of hip joint, 269-296, 297-301
- Jeep fractures—
 in RAMP's, 266
 of hip joint, 262-268, 297-301
- Jeep injuries of hip joint, 251-304
- Jeep:
 position of rider in, 254-255
 structure of, 252
- JERGENSEN, Maj. FLOYD H., 63, 66
- Joint relationships, reconstitution of, after acromioclavicular dislocations, 201
- Joints:
 elective surgery on, 185
 fractures of long bones adjacent to, 116
 immobilization of, in transportation splinting, 109
 mobilization of, in combined nerve-bone injuries, 104
 motion of, in skeletal traction, 114

- Joints—Continued
of hand, action of, 120
removal of foreign bodies from, 87
wounds of, 77
See also special joints.
- JOLLY, DOUGLAS W., 226
- Jones abduction frame, disadvantages of, 235
- Junior consultants, 8-10, 20, 21, 39, 73, 75
- Keller-Blake half-ring splint, 149
- Keller-Blake modification of Thomas leg splint, 224
- Kennedy General Hospital, 101
- KERNODLE, Capt. HAROLD B., 121
- KEY, JOHN A., 205, 206
- Kingston-on-Thames, 177
- Kirschner wire(s), 27, 63, 114-116, 120, 144, 148-149, 150, 153, 267
advantages of, 114-115
use of, in treatment of decubitus ulcers, 175
- KLEINBERG, SAMUEL, 258
- Knee:
fatal wounds of, 69
flexion of, in plaster traction splint, 46
mobility of, in skeletal traction, 25
motion of, in suppurative arthritis, 26
noncombat disability of, 68
position of, in—
injuries about hip joint, 269
skeletal traction, 115
Tobruk splint, 30, 110
transportation splinting, 110
- Knee joint:
anatomy of, 306
ankylosis of, in suppurative arthritis, 311
arthrotomy of, 185, 186
aspiration of, 150
blood supply of, 307
disarticulation of, 162
dislocation of, 166
effusion into, 307, 310
elective surgery on, 185
internal derangements of, 186
resection of, 309-310, 311-312
suppurative arthritis of, 26, 308, 310-312
wounds of, 150, 166, 305-317
- Kocher incision, 232, 249, 279
- Korean War, 155
- Laboratory tests, 57
- Laminectomy, 147
- Landing ship tanks (LST), 55
- Land mines, 32, 33, 68, 70, 157, 166, 225, 233, 305
- Latent infection, 169
- Lateral incision for resection of femoral head, 243
- Lateral traction, 146
- Lateral (Watson-Jones) incision, 232
- Leg:
edema of, after wounding, 168
fractures of bones of, 101, 112
wounds of, 102, 111
- Legg brachioclavicular cast, 206
- Legg-Calvé-Perthes disease, 296
- Level of amputation, 159, 161
- LEVITT, V. C., 226
- Liaison:
between Army consultants, 10
between Mediterranean and European theaters, 73, 82
role of senior consultant in, 8
- Liège, 68, 112
- Ligamentopexy, 211
- Ligaments:
damage to, in—
acromioclavicular dislocations, 209, 210, 216
injuries about hip joint, 234
See also special ligaments.
- Ligamentum teres, 259, 269, 275, 285, 287
- Ligation of—
bleeding point in secondary hemorrhage, 175
femoral artery, 106
popliteal vessels, 88, 106, 113, 155-156
- Lighting of tented hospitals, 41
- Limitations of—
chemotherapy, 173
extension in radial-head fractures, 126
external fixation, 116
flexion in radial-head fractures, 126
internal fixation, 117
motion—
after acromioclavicular dislocations, 216
after resection of femoral head, 243
in fractures of radial head, 126, 130-132
in injuries about hip, 277, 292, 293, 301
in wounds of knee joint, 306, 316
penicillin therapy, 169-170, 173
plasma, 167
- Limited duty, 179
- Liston splint, 224

- Literature of—
 avascular necrosis of femoral head, 295–296
 complete acromioclavicular dislocations, 194, 195, 198, 201, 210
 dislocations of hip joint, 258, 260–261
 fracture-dislocations of hip joint, 277, 296, 304
 fractures about hip joint, 226
- Litter casualties in transit hospitals, 56
- Liverpool nail, 248
- Local anesthesia, 87
- Local chemotherapy, 74, 88, 161, 163, 165, 238, 249, 307, 316
- Local penicillin therapy, 74, 150, 169, 173, 238
- Localizing signs, absence of, during chemotherapy, 239
- Location of—
 combined nerve-bone injuries, 104
 fractures, relation of—
 to management of, 114
 to wound healing, 135–137
 hospitals, relation of, to timelag, 78
 orthopedic wards, 42
 transit hospitals, 55
 wounds:
 as indication for fracture management, 149
 influence of, on healing, 102, 103
- London, 36, 37, 39, 44, 45
- Long bones:
 blood replacement in fractures of, 167
 fractures of, 25, 32, 41, 63, 89, 104, 113–116, 157
See also Humerus, Tibia.
- Long leg cast, 47, 86, 151, 165–166
 for transportation splinting, disadvantages of, 165–166
- Lorient-Saint Nazaire pocket, 70
- Loss of—
 bone substance in fractures of humerus, 146
 duty days in—
 carpal scaphoid fractures, 143
 fractures of radial head, 121
 soft tissues in fractures of humerus, 146
 position in skeletal traction, 115–116
 serum via drainage, 95
 skin in splints, 24
- Lumbar sympathetic block, 32, 106–107, 156
- Lumbosacral splint, 146, 149, 236, 249
 advantages of, 236
- Lunate cartilage, 263, 304
- Lysis of thrombus, 174
- McKee nail, 248
- Maintenance of—
 fluid balance, 114
 skeletal traction, 115–116
 skin traction, 166
- Malformations. *See* special types.
- Malingering, 31
- Malunion, 100, 101
- Management of—
 abdominal injuries, 55, 56
 acromioclavicular dislocations, 196, 199, 202–215
 amputees, 8, 165
 avascular necrosis of femoral head, 296
 battle casualties, 8, 19, 73, 81
 bone fragments, 27, 84, 85, 102, 277
 carpal scaphoid fractures, 134–135, 138, 140–143
 chest injuries, 55, 56
 clostridial infections, 174
 combined bone-nerve injuries, 84, 104–106, 144
 combined bone-vascular injuries, 55, 86, 104–106
 combined nerve-bone injuries, 104–106
 decubitus ulcers, 109, 175
 draining sinuses, 173
 fractures, 61, 73, 76–77, 89–91, 95–100, 109–151
 in Mediterranean theater, 73, 239
 of bones of foot, 153–154
 of bones of forearm, 114, 119–133
 of bones of leg, 114, 151
 of clavicle, 143
 of femur, 114, 148–150
 of humerus, 114, 144–146
 of long bones, 89, 104, 113–116
 of pelvis, 50–54
 of radial head, 122, 123, 127–129
 immersion foot, 29
 injuries about ankle, 151–153
 injuries about hip joint, 28, 50–54, 223–250, 255, 259–261, 262, 263–268, 275–288
 in World War I, 224, 225–226, 241, 243
 mass casualties, 58–61
 planned, advantages of, 57
 orthopedic injuries, 8, 19, 78
 evolution of, 81–83
 in prisoners of war, 63–66
 osteomyelitis, 174

- Management of—Continued
 psychiatric complications, 170
 regional injuries in relation to D-day, 119
 retained foreign bodies, 233, 234, 245, 249, 308
 simple fractures, 116
 wound edges at reparative surgery, 88
 wound infections, 89, 173
- Management. *See also* special treatments and techniques.
- Manipulation in—
 acromioclavicular dislocations, 203-204
 fractures, 114-115, 149, 154, 235
- MANNING, Lt. Col. JOHN C., 75, 111, 112, 113
- Manpower losses in—
 carpal scaphoid fractures, 143
 disabilities of feet, 187
 fractures of radial head, 121
- Manpower, wastage of, 179
- Manual of Therapy, 36, 63, 74-75, 82, 165
 revision of, 36, 75, 161-165
- Masking, 239, 246
- Massachusetts General Hospital, 252, 296-304
- Mass admissions to general hospitals, 79
- Mass evacuation, 79
- Mass management of—
 casualties in—
 general hospitals, 58-61
 hospital centers, 59-60
 transit hospitals, 57-58
 fractures, 11, 35, 55-61, 113-116
- Massage, 127
- Maxillofacial injuries, 32
- Mechanics of injury in—
 acromioclavicular dislocations, 197-199
 carpal scaphoid fractures, 133-134
 fractures of radial head, 121, 123
 injuries about hip joint, 225, 263
 wounds of knee joint, 305-306
- Mechanized equipment, injuries from, 68, 119, 146
- Medial capsule of radial head, 122
- Medial femoral circumflex vessels, 254, 255, 293, 295
- Medial femoral condyle, 311
- Medical Field Service School, 36
- Medical Gas Treatment Battalion, 91st—32
- Medical Group, 68th—30
- Medical officers:
 cumulative experience of, 55
 morale of, in relation to rank, 18
- Medical officers—Continued
 with combat experience, on disposition boards, 179
 without military experience, 73, 85
 without orthopedic experience, 7, 8, 13, 14, 15, 17, 19, 35, 38, 39, 61, 73, 82, 85, 110, 113, 116, 117, 119, 164, 227, 251, 260, 282, 307
 response of, to training, 37
 without surgical experience, 73, 74, 75
- Medicine, consultants in, 7
- Mediterranean theater, 18, 73, 118, 169
 delayed primary wound closure in, 81-82, 83
 evolution of management of battle casualties in, 81-82
 internal fixation in, 118
 management of fractures about hip joint in, 73, 239
- Meetings of—
 British and U. S. Army consultants, 111
 British, Canadian, and U. S. Army consultants, 113
 junior consultants, 39, 75
 U. S. Army consultants, 112
 See also Conferences.
- Memphis, 101
- Menisci of—
 knee joint, 186, 307, 308, 311
 shoulder joint, 196, 199, 204, 219
- Metacarpals:
 fractures of, 33
 position of, in carpal scaphoid fractures, 134-135
 traction through, 120
- Metal, removal of, after internal fixation, 118
- Metatarsals:
 congenital malformations of, 187
 fractures of, 154
- Midtarsal fractures, 154
- Military Government in Germany, 70
- Military Occupational Specialty (MOS), rating for orthopedic surgery, 11, 16
- Mines at sea, 166
- Minerva jacket, 147
- Minor injuries, 79, 80, 169
- Mission of—
 evacuation hospitals, 15-16, 55, 167
 field hospitals, 55
 fixed hospitals, 85
 forward hospitals, 84, 85
 hospitals before D-day, 55
 transit hospitals, 55

- Mobility during traction, 25, 249
- Movement during treatment of—
 fingers, 120, 139
 hands, 26, 109
 joints, 77, 104, 114, 146
 knees, 25, 26, 310, 313
- Mold arthroplasty, 293, 302
- Mongolian-Russian slave laborers, 56
- Monteggia fractures, 119
- Morale of—
 casualties, 61, 116, 130, 170
 medical officers in relation to rank, 18
- Morhange, 69
- Morphine, 66, 167, 224
- Morphogenesis of diarthrosis, 196
- Motion, limitation of—
 after resection of femoral head, 243
 in fractures of radial head, 126
 in injuries about hip joint, 277
- Muscle atrophy, 114, 178
- Muscle spasm, 292
- Muscle tissue:
 inadequate removal of, at debridement, 86
 interposition of, in fractures of femur, 149
 loss of, in fractures of humerus, 146
 transplantation of, in osteomyelitis, 174
- Muscles, influence of, in function of—
 acromioclavicular joint, 201
 femur, 148
- Muscles, wounds of, 114, 258
- Mushrooming of radial head, 122
- Myositis ossificans, 132
- Nail fixation in fractures of posterior malleolus, 152
- Nails. *See* special types.
- Napoleonic Wars, 221
- Nature of lesion in—
 avascular necrosis, 245-246
 complete acromioclavicular dislocations, 197-199
 fractures of radial head, 121-123
 injuries about hip joint, 225, 233, 255-259, 262-263, 269-275
 wounds of knee joint, 305-306
- Naumburg, 157
- Neck of astragalus, fracture of, 153
- Neck of femur:
 avascular necrosis of, 246
 displacement of, 258
 disuse atrophy of, 261
 fractures of, 149, 239, 296
 sclerosis of, 246
- Necrosis—
 after secondary closure of amputation stump, 163
 of head of femur, 246
 of muscles of leg, 156
 of skin, 76, 153
- Neoplasms, excision of clavicle in, 212
- Nerve injuries, 21, 59, 83, 84, 85, 86, 104-106, 114, 144, 146, 306
- Nerves, protection of, during transportation, 109
- Neuritis from use of Kirschner wire, 144
- Neurolysis, 105
- Neuropsychiatric casualties, 22
- Neurosurgical centers, 21, 59, 86, 104
- Neurosurgical procedures, timing of, 105
- Neurosurgery, senior consultant in, 186
- New-bone formation, 292
- Night pain in jeep injuries of hip joint, 301
- Ninth U. S. Army, 10, 29, 31, 86, 111
- Nomenclature of trenchfoot, 31
- Nonaffiliated hospitals, 14, 18
- Nonclosure of—
 amputation stump, 160, 164
 wound at debridement, 76, 84, 227, 309
- Noncombat disabilities, 68
- Noncombat injuries, 14, 67-68, 119-154
- Noncombat soldiers, arch supports for, 44
- Nonpathogenic *Clostridium welchii*, 156
- Normandy, 66, 78, 112, 157
- Normandy beaches, 56, 143
- Normandy campaign, clostridial myositis in 174
- North Africa, 67, 74, 110
- North African Theater of Operations. *See* Mediterranean theater.
- Nonunion of fractures, 100-101, 135, 142, 149
- Novacain (procaine hydrochloride), 29, 106-107, 127
- Nurses, rotation of, 38
- Nursing care—
 in fractures of pelvis, 146
 in injuries about hip joint, 235, 237-238
 in plaster traction splint, 47
 in revolving orthopedic frames, 53
 of mass orthopedic casualties, 59
- Objectives of—
 arthrodesis of shoulder joint, 210
 management of—
 acromioclavicular dislocations, 202
 battle casualties, 81
 reparative surgery, 37

- Objectives of—Continued
 management of—Continued
 secondary resection of knee joint, 311
- Oblique fractures of bones of leg, 151
- Obliteration of dead space at wound closure, 88
- Obstetricians, 113
- Obturator externus, 279
- Obturator foramen, 258
- Obturator internus, 258, 275, 279
- Obturator tendons, 258
- ODOM, Col. CHARLES B., 81, 157
- Old fractures of carpal scaphoid, 134, 138–143
- Olecranon process, traction through, 144
- Omission of—
 arthrotomy of—
 hip joint, 226
 knee joint, 312–313, 315, 316
 debridement, 23, 241, 307
 delayed primary wound closure, 91
 quadriceps-setting exercises, 310
- Onychogryphosis, 28
- Oozing from aneurysm, 174
- Open circular amputation, 77, 159–161, 162–163
- Open fractures. *See* Fractures.
- Open reduction of—
 dislocation of carpus, 28
 fracture dislocations of ankle, 153
 fractures, 89
See also Internal fixation.
- Open wounds, evacuation to Zone of Interior with, 91, 109
- Operating room:
 setup of, for reparative surgery, 60
 work shifts in, 55
- Orbicular ligaments, 119
- Order form for shoe corrections, 45
- Orr-Trueta technique. *See* Closed plaster technique.
- Orthopaedic Section, Royal Society of Medicine, 36
- Orthopedic caseload, 14, 29, 67, 69–70
- Orthopedic casualties, 7, 8, 10, 14, 15, 19, 41, 55
 care of, by general surgeons, 15
 collection of data on, 8
 emotional status of, 170
 evolution of management of, 81–83
 facilities for care of, 41–54
 in United Kingdom before D-day, 35
 mass management of, 11, 35, 55–61
 nursing care of, 38
- Orthopedic casualties—Continued
 priorities of—
 care of, 77–78, 81
 evacuation of, 32
 segregation of, 55, 57, 58, 59–60, 61
 advantages of, 42, 55, 57, 58, 59–60, 61, 170
- Orthopedic consultations, 70
- Orthopedic experience:
 gained before D-day, 37
 in Zone of Interior, 35
 lack of, in mass management of battle casualties, 35
- Orthopedic injuries:
 association of, with—
 abdominal injuries, 55, 56, 59, 78, 81, 223, 276
 chest injuries, 32, 55, 56, 78, 81, 223
 nerve injuries, 21, 59, 81, 83, 84, 85, 86, 104–106, 114, 144, 146, 306
 vascular injuries, 59, 78, 80, 81, 85, 86, 106–107, 113, 155–156, 166, 306
 incidence of, 41, 42
 management of, in prisoners of war, 63–66
- Orthopedic personnel:
 assignment of, 7, 8, 9, 10, 11, 14–18, 58, 59, 60
 economical use of, in plaster techniques, 49, 111
 evaluation of, 11–14, 16, 20
 excess of, on hospital staffs, 14, 15
 qualifications of, 7, 11–14, 19, 20–21
 rank of, 18
 rotation of, 15, 16, 17–18
 shortages of, 14, 16, 21, 113, 227
 training of, 16, 35–39
 in use of Tobruk splint, 111
- Orthopedic services, administration of, 21–22
- Orthopedic surgeons:
 in army areas, 18
 in field hospitals, 15
 in evacuation hospitals, 15–16
 in general hospitals, 16
 in hospital centers, 10
 psychiatric therapy by, 171
 rating of Tobruk splint by, 112–113
- Orthopedic surgery:
 concepts of, 19
 spot checks of, 15
- Orthopedic wards, location of, 42
- Osborne incision, 279
- OSBORNE, R. P., 279

- Os calcis:
 fractures of, 153-154, 166
 traction through, 151, 153
- OSMOND-CLARKE, Air Vice-Commodore, 36
- Ossification of—
 capsule of hip joint, 261
 coracoclavicular ligaments, 216, 218
 periarticular structures of hip joint, 278
- Osteitis, 173
 fibrosa cystica of tibia, 28
- Osteocartilaginous bodies in shoulder joint, 199, 216
- Osteochondritis, 67, 132, 217
- Osteomyelitis, 66, 67, 174
 after external fixation, 116
 after failure of delayed primary wound closure, 97, 99, 100, 101
 after internal fixation, 116
 after use of pins and wires, 115
 excision of clavicle in, 212
 incidence of, 26, 99, 100, 101
 of pelvis, 26
- Osteotome, 43
- Osteotomy, in fractures of forearm, 121
- Otolaryngologists, 15
- Overtreatment, risks of, 81
- Oxygen, use of, during resuscitation, 167
- Pacific theaters, 75
- Packing of wounds at debridement, 86, 102
- Packs:
 as cause of secondary hemorrhage, 174
 control of oozing by, 175
- Padding of plaster casts, 76, 109, 110
- Pain:
 in acromioclavicular dislocations, 202, 207, 209, 211, 216, 217, 219
 in feet after training marches, 187
 in fractures of—
 foot, 154
 radial head, 122, 126
 in immersion foot, 29
 in injuries about hip joint, 224, 268, 292, 293, 297, 301, 302
 in sciatic-nerve palsy, 291-292
 in suppurative arthritis of knee joint, 311
 in transportation in Tobruk splint, 24, 113
 referred to wrist in radial-head fractures, 126
- Parachute jumps, 191
- Paralysis—
 after wounds of knee joint, 306
 of muscles in compound fractures, 115
- Paralysis—Continued
 of peroneal nerve, 283
 of radial nerve in fractures of humerus, 131, 144, 146
- Parapatellar incision, 308, 311, 313
- Paraplegia, 53
- Paratroopers, 22, 56
- Paris, 39, 41, 45, 66, 69, 70, 113
- Patella:
 fractures of, 34, 95, 117, 305, 307, 312, 315
 resection of, 309, 312
- Pathologic process in—
 acromioclavicular dislocations, 199-201
 injuries about hip joint, 254
 suppurative arthritis of knee joint, 311
- Patients:
 evaluation of Tobruk splint by, 113
 morale of, 130
 role of, in rehabilitation, 178
 warning of, against secondary hemorrhage, 175
- Pearl Harbor, 116
- Pediatricians, 113
- Pedicle flaps, 59
- Pedicle grafts, 25, 66, 89
- Pelvic abscess, 244
- Pelvis:
 fractures of, 26, 95, 97, 146-147, 263, 283-289, 301
 management of, in revolving orthopedic frames, 50-54
 protrusion of femoral head into, 263, 267, 296, 301-303
- Penetrating wounds, 99
 of knee joint, 305, 306, 308, 309, 315
 suppurative arthritis after, 310-312
 of popliteal artery, 106
- Penicillin therapy, 26, 60, 67, 85, 87, 100, 169-170, 173
 errors in use of, 85
 in clostridial myositis, 156, 174
 in combined nerve-bone injuries, 105
 in fractures of femur, 150
 in injuries about hip joint, 224, 226, 232, 238, 239, 249
 in internal fixation, 117
 in osteitis, 173
 in osteomyelitis, 174
 in suppurative arthritis, 26
 in wounds of knee joint, 309, 310, 313, 315
 limitation of use of, in prisoners of war, 66

- Penicillin therapy—Continued
 limitations of, 85, 173
 masking with use of, 239, 246
 studies on, 74
- Penicillin-resistant infections, 245
- Penrose drains, 86, 241
- Pentothal sodium (thiopental sodium), 114, 152, 259
- Perforating wounds, 99
 of knee joint, 315
 of viscera, 81
 omission of debridement in, 85
- Perilunate posterior dislocation of carpus, 28
- Perineum, pain in, with Tobruk splint, 113
- Peripheral vessels, dilatation of, by whisky, 107
- Peroneal-nerve damage, 283, 291-292
- Personnel:
 failure of, in screening for evacuation, 80
 of auxiliary surgical groups, training by, 37-38
 of evacuation hospitals, training of, 36, 38
- Pfalz, 70
- Phemister transarticular wire, 211
- Physical findings in—
 acromioclavicular dislocations, 202
 suppurative arthritis of knee joint, 311
 wounds of knee joint, 306-307
- Physical therapists, shortages of, 178
- Physician-patient relationships, 61
- Physiologic salt solution for compresses, 173, 174
- Physiotherapy, 52, 57, 104, 127, 128, 129, 154, 178-179, 207, 237
- Picket-fence temperature, 311
- Pierson attachment to Thomas splint, 27, 46-47, 145, 151, 276, 282
- Pinhole osteomyelitis, 116
- Piriformis muscle, 258, 275, 279
- PITNEY, Sgt. WILLIAM, 179
- Plasma protein deficits, 168, 238
- Plasma transfusion, 57, 167, 168, 224
 homologous serum hepatitis after, 240
- Plaster, supplies of, 44
- Plaster. *See also* Immobilization, Splints.
- Plaster bandages, preparation of, 39
- Plaster body jacket, 147
- Plaster casts, 11, 38, 39, 50, 109
 change of, before evacuation, 30, 135
 constriction by, as predisposition to clostridial infection, 173
 errors in application of, 110
- Plaster casts—Continued
 provision of windows in, 46, 105, 109, 114, 175
 record of wound data on, 109
- Plaster hip spica, 24, 30, 33, 52, 76, 110, 113, 147, 148, 161, 163, 165-166, 234-235, 236, 260, 263, 267, 309, 310, 312, 313
- Plaster room, 42
- Plaster shoulder spica, 163
- Plaster techniques, 19, 24, 30-31, 36, 37, 38-39, 63, 109-110, 165
- Plaster traction splint, 45-49, 151
 advantages of, 49
- Plaster transportation splinting, 38, 67, 76
 disadvantages of, 110
 principles of, 109-110
- Plaster Velpeau, 76, 144, 205, 206
- Plastic centers, 25
- Plastic splinting, 110
- Plastic surgery, 59, 88
 on hands, 27
 on tendons, 59
- Plating of fractures, 27, 49, 76, 105
- Policies of—
 evacuation, 78-80
 management, 7, 19, 39, 74-77, 81-83
See also Clinical policies.
- Pontocaine (tetracaine hydrochloride), injection of, in immersion foot, 29
- POOL, EUGENE H., 225, 226
- Popliteal space:
 contents of, 306
 protection of, in Tobruk splint, 111
- Popliteal vessels:
 anastomosis of, 155
 damage to, 106, 166, 306
 ligation of, 86, 106, 113, 155-156
- Portable fracture tables, 43
- Portable X-ray equipment, 41, 60
- Position:
 after operations on hip joint, 282
 as factor in jeep injuries, 252-253
 in fractures of—
 femur, 22
 foot in plaster cast, 76, 154
 loss of, in skeletal fraction, 115-116
 of clavicle in acromioclavicular dislocations, 204, 206, 207
 of coracoid process in acromioclavicular dislocations, 198-199
 of femoral head in jeep transportation, 253, 254

- Position—Continued
of forearm—
in fractures of radial head, 127, 128, 129
in occurrence of fractures of radial head, 121, 126
of fragments after internal fixation, 118
of hand in occurrence of fractures of radial head, 121, 126
of heel in roentgenography of ankle, 152
of knees in—
skeletal traction, 115
Tobruk splint, 110
transportation splinting, 110
of limb after vascular ligation, 106
of patient during resuscitation, 167
of scapula in acromioclavicular dislocations, 206
of sciatic nerve in fracture dislocations of hip joint, 279
of wrist in transportation splinting, 77
Posterior dislocations of hip joint, 258, 269, 276–282
Posterior incision of hip joint, 241, 243
Posterior (Kocher) incision, 232, 249
Posterior malleolus, fractures of, 152
Posterior (Osborne) incision, 279
Posterior tibial vessels, 153
Posterior (Von Langenbeck) incision, 279
Posterolateral incision in—
fractures of femur, 117
resection of femoral head, 243
Postoperative complications, 173–175
after resection of radial head, 131
Postoperative management in fracture-dislocations of hip joint, 282
Precautions against secondary hemorrhage, 175
Preferential care of Allied wounded, 63
Preoperative care in transit hospitals, 58
Preoperative morbidity, 70
Preoperative preparation—
after prolonged timelag, 67
for reparative surgery, 100
in blast injuries, 166
of plaster bandages, 39
of skin for amputation, 162
of surgical field, 88
Pressure dressings, 84, 88, 89, 173, 174
control of bleeding by, 175, 224
Pressure of drains and packs as cause of secondary hemorrhage, 174
Pressure of Tobruk splint, 111, 113, 234
Pressure sores. *See* Decubitus ulcers.
Prevention of—
angulation of fractures, 89
contamination in injuries about hip joint, 241
decubitus ulcers, 175
edema of limb, 95, 105–106
infection in wounds of knee joint, 305, 309–310
scar-tissue formation, 88
shock, 268
Preventive Medicine Division, Office of the Surgeon, Ninth U. S. Army, 31
Pridie operation, 154
Primary amputation for vascular injuries, 155–156
Primary nerve suture, 84
Primary resection of—
hip joint, 226
knee joint, 309–310
Primary wound closure, studies of, 74
Principles of—
debridement, 37, 83–85, 103–104
initial wound surgery in injuries about hip joint, 225–226, 249
management of—
fractures about hip joint, 235, 241, 304
nerve-bone injuries, 104–105
resuscitation, 167–168
transportation splinting, 109–110
wounds of knee joint, 315
Priorities of—
evacuation, 32
management of fractures of hip joint, 227
Priorities of care of orthopedic injuries, 55, 57–58, 59–60, 77–78, 81, 87–88
Prisoners of war:
amputation in, 157
care of, in tented hospitals, 41
chemotherapy in, 169
fractures of femur in, 150
hospitals for, 21
management of injuries in, 63–66
penicillin therapy in, 66, 169
results of—
delayed primary wound closure in, 101–104
skin grafting in, 89
wounds of knee joint in, 14, 16–19, 20, 21, 312, 313, 314, 316
See also special nationalities.
Problems of—
blood replacement, 238
fracture management, 81

- Problems of—Continued
 reassignment of personnel with civilian-type disabilities, 68
 suspension management of fractures of bones of leg, 151
- Prodromal signs of secondary hemorrhage, 175
- Professional conferences, 39
- Professional Services Division, Office of Theater Chief Surgeon, 7
- Professional training of orthopedic personnel, 7, 10, 13, 16, 19, 35-39, 86
- Profundus, ligation of femoral artery below, 106
- Prognosis of—
 acromioclavicular dislocations, 195, 203, 207-209
 carpal scaphoid fractures, 142-143
 fracture-dislocations of hip joint, 303-304
- Prognostic tests in acromioclavicular dislocations, 207-209
- Prohibition of—
 external fixation, 116
 internal fixation as primary procedure, 117
 local sulfonamide therapy, 88
 primary nerve suture, 84
- Prolongation of timelag, 49, 78, 103
- Pronation in fractures of—
 bones of forearm, 119
 radial head, 121, 122, 130
- Prone position after secondary resection of knee joint, 312
- Prostheses, 162, 164, 178
- Protected prisoner medical personnel, 63-66
- Protection—
 from exposure during resuscitation, 167
 of blood supply at operation, 279-280
 of bony prominences in transportation splinting, 109
 of nerves in transportation splinting, 109
 of popliteal space in Tobruk splint, 111
- Protein deficits, 95, 168, 249
- Protein-high diet in decubitus ulcers, 175
- Protein replacement, 168
- Protusion of femoral head into pelvis, 263, 296, 301-303
- Psychiatrists, 170
- Psychologic considerations in—
 arthrotomy of knee joint, 186
 trenchfoot, 32
- Psychoneurosis, 67
- Psychosomatic conditions, 191
- Psychotherapy, 162, 165, 170-171
- Pubis, fractures of, 262, 302
- Pulp traction in metacarpal fractures, 33
- Quadrangle ligament, 122
- Quadratus femoris, 258
- Quadriceps exercises, 237, 276, 310
- Quadriceps tendon, involvement of, in wounds of knee joint, 306
- Qualifications of—
 chiefs of surgical services, 19
 orthopedic personnel, 7, 11-14, 19, 20-21
- Qualified orthopedic personnel, utilization of, 17
- Questionnaire for trenchfoot casualties, 32
- QUIGLEY, Lt. Col. THOMAS B., 45
- Radial deviation, 120
- Radial head:
 anatomy of, 121-122, 128
 case histories of fractures of, 132-133
 fractures of, 119-133
- Radial nerve:
 anatomy of, 126
 association of injuries of, with bone injuries, 104, 106, 144
 paralysis of, 131, 146
- Radio-ulnar joint, 126
- Radius:
 Brodie's abscess of, 28
 fractures of, 34, 70, 117, 120, 121
 See also bones of forearm.
- RAMP's, 70
- Rank of orthopedic personnel, 18
- Rarefaction of—
 clavicle, 217
 head of femur, 246
- Reactivation of latent infection, 169
- Reassignment of soldiers, 68, 185, 188
- Recommendation for limited duty, 179
- Reconstitution of joint relationships, 201
- Reconstructive surgery, 66, 185-186, 247-249. *See also* special operations.
- Record of—
 indications for amputation, 161, 162
 wound data on cast, 86, 109
- Recovery ward, 115
- Rectum:
 edema of, 291
 wounds of, 60, 244
- Rectus femoris, tenotomy of, 232

- Recurrence of —
 acromioclavicular dislocations, 202
 trenchfoot, 32
 Recurrent luxation of astragalus, 151
 Red Cross, 57, 171
 Redebriement, 173
 Reduction:
 in acromioclavicular dislocations, 203–204
 in fracture-dislocations of ankle, 153
 influence of, in carpal scaphoid fractures, 137, 138
 loss of, 148
 maintenance of, 114
 not function of forward hospitals, 76, 84
 of fractures—
 by manipulation, 114–115
 of bones of forearm, 119
 of bones of leg, 151
 of neck of astragalus, 153
 of pelvis, 156
 of posterior malleolus, 152
 of radial head, 119, 126
 of jeep dislocations about hip joint, 235, 259–260
 Regional fractures, 119–154
 Rehabilitation, 60, 170, 177–183
 after arthrotoomy of knee joint, 186
 after carpal scaphoid fractures, 135
 of amputees, 162
 Rehabilitation centers:
 advantages of, 177
 in general hospitals, disadvantages of, 177
 Rehabilitation Division, Office, Theater Chief Surgeon, 7, 11, 177
 Relation of—
 delayed primary wound closure to tactical situation, 79
 hospital caseload to mass management of casualties, 55
 location of fractures to fracture techniques, 114
 wounds to fracture management, 114
 Relaxing incision, 151
 Remedial exercises, 178–179
 Removal of—
 metal after internal fixation, 118
 sutures after delayed primary wound closure, 88, 109
 Reparative surgery. *See* Delayed primary wound closure, Secondary debridement.
 Replacement centers, 179
 Replacement pools, 188
 Resection of—
 acetabulum, 232, 302
 acromioclavicular cartilages, 210
 anterior lateral muscles of leg, 106
 clavicle, 185–186, 204, 209, 212–216, 217, 218, 219
 femoral head, 232, 243–244, 249
 fibrocartilage in carpal scaphoid fractures, 141
 menisci of knee joint, 186, 308
 os calcis, 154
 patella, 312
 radial head, 128–129, 131
 ulna, 121
 Reserve, evacuation hospitals held in, 15–16
 Restriction of—
 surgery for ruptured lumbar disk, 186
 use of penicillin in German prisoners of war, 66
 weight bearing in injuries about hip joint, 261–262, 296, 297
 Results—
 in acromioclavicular dislocations, 202, 204, 205, 206, 207–210, 212, 217
 in carpal scaphoid fractures, 135–138, 139–142
 in clostridial infections, 174
 in fractures of—
 bones of foot, 154
 clavicle, 143
 humerus, 146
 in injuries about hip joint, 221–222, 228–232, 233, 238, 241, 248–249, 260, 261, 275, 282, 284, 292, 296–304
 in osteomyelitis, 174
 in suppurative arthritis of knee joint, 311
 in wounds of knee joint, 186, 310, 315, 316
 of adequate debridement, 83
 of antibiotic therapy, 169, 238
 of conservative management of vascular injuries, 155–156
 of delayed primary wound closure, 82, 83, 87, 91–104, 151, 313–315
 of elective surgery, 185, 186
 of external fixation, 116
 of internal fixation, 117–118, 151
 of physical therapy, 179
 of plaster traction splint, 151
 of protein replacement, 168
 of rehabilitation, 177
 of secondary resection of knee joint, 311
 of shortening operations on bones, 106

- Results—Continued
of skeletal traction, 114, 120, 211
of split-thickness skin grafts, 89
of surgery for ruptured lumbar disk, 186
of training of orthopedic personnel, 35, 37
- Resuscitation, 167-168
- Retained foreign bodies, 23-24, 77, 84, 164, 173, 174, 225, 227, 233, 234, 243, 245, 308, 315
- Retinacula of hip joint, 254, 269, 275, 293
- Retroperitoneal hemorrhage, 289-291
- Revascularization in—
carpal scaphoid fractures, 142
fractures of—
astragalus, 153
femoral head, 295
- Revision of amputation stump, 162, 163, 164
- Revision of Manual of Therapy, 36, 75, 161
- Revolving orthopedic frames, 50-54, 236-237
advantages of, 53
- Rheinprovinz, 70
- RIES, CAPT. LINCOLN, 45
- Risks of—
internal fixation, 117
overtreatment, 81
pulp traction through fingers, 33
- Roentgenologic examination, 28, 50, 57, 84, 89, 121, 126, 127, 128, 132, 135, 138, 140, 146, 149, 152, 154, 178, 186, 195-197, 199, 202, 207, 216, 217, 219, 233, 246, 255-258, 263-264, 269, 273, 275, 276, 282, 292, 293, 295, 296, 305, 306, 307
- Roger-Anderson apparatus, 25, 63
- Rome, Ga., 101
- Rotating Bradford frame, 27
- Rotation of—
nurses, 38
orthopedic personnel, 17-18
- Routine of management of mass casualties, 57-61
- Rouvillois splint. *See* Lumbosacral splint.
- Royal Air Force, 36
- Royal Army Medical Corps, 177
- Royal Society of Medicine, 36
- Rubber-tissue drains, 88
- Ruhr pocket, 70
- Rupture of—
acromioclavicular joint, 204
coracoclavicular ligaments, 200
coronary ligament of elbow, 122
- Russell apparatus, 235
- Russell suspension, 261
- Russian prisoners of war, 69
- Russo-Japanese War, 221
- Saarland, 70
- Sacroiliac joint, dislocation of, 289
- Sacrum:
decubitus ulcers over, 52
wounds of, 235
- Saint-Lô, 69, 174
- Salient angle in fractures of foot, 154
- Salvaged material, improvised equipment from, 45-54
- Saucerization in hip-joint injuries, 227, 243
- Scanlon Morris fracture table, 43
- Scaphoid, fractures of, 121
- Scapula:
anatomy of, 212, 218
displacement of, 198, 199
fractures of, 95
function of, 210
manipulation of, 203
position of, in shoulder dislocations, 206
- Scarification of synovial membrane of hip joint, 302
- Scar-tissue formation, 38, 88
- Schrievham, 36
- Sciatic nerve, damage to, in injuries about hip, 59, 104, 113, 244-245, 279, 283, 289, 291
- Sclerosis of—
bone in carpal scaphoid fractures, 137, 138, 141, 142
head of femur, 246
- Scotland, 36
- Screw-fixation technique of internal fixation, 27, 49, 105, 144, 151, 152, 266, 277
- Scrotum, displacement of femoral head into, 258
- Seasonal wound contamination, 225
- Secondary amputation, 156, 161
- Secondary closure of—
amputation stump, 163
joint wounds, 77
- Secondary debridement, 22, 83, 87, 88, 150, 173
- Secondary hemorrhage, 155, 174-175
- Secondary resection of knee joint, disadvantages of, 311-312
- Secondary shock, 70, 166
- Secondary skin grafting, 96
- Secondary wound closure, 96, 100

- Sedation, unnecessary in radial-head fractures, 128
- Segregation of—
 amputees, 170
 casualties with combined rectal-orthopedic injuries, 60
 orthopedic casualties, 42, 55, 57, 58, 59-60, 61, 170
- Seine Base Section, 32
- Selection of cases for—
 arthrotomy of knee joint, 186
 external fixation, 116
 open reduction, 89
 skeletal traction, 114, 146
 surgery in acromioclavicular dislocations, 203
See also Indications.
- Selection of transportation splinting, 84
- Selection of treatment in injuries about hip joint, 276
- Senior consultant in—
 neurosurgery, 104, 186
 orthopedic surgery, 7-8, 9-10, 11-14, 19-34, 35, 73, 75, 85, 102, 104, 155, 177, 186, 236
- Sensitivity of organisms to penicillin, 169
- Separation of symphysis pubis, 28, 289
- Sepsis in—
 fractures about hip joint, 221, 227-228, 239
 wounds of knee joint, 305, 307
- Sequelae of—
 acromioclavicular dislocations, 216-219
 injuries about hip joint, 292, 293, 297-301, 302-304
- Sequestration—
 after external fixation, 115
 in osteomyelitis of pelvis, 26
- Shaft of—
 femur, fractures of, 112, 149
 radius, fractures of, 120
 tibia, fractures of, 151
 ulna, fractures of, 120
- Shepton Mallett, 44
- Shock, 55, 81, 115, 160, 166, 167
 in injuries about hip joint, 224, 227, 259, 263, 268
- Shock wards, 59
- Shoe corrections, 39, 44-45, 188
 and repairs at disciplinary center, 44
- Shoes, effect of poor fitting, 187, 188
- Shortage of—
 orthopedic personnel, 14, 16, 17, 21, 113, 227
 physical therapy personnel, 178
- Shortening of bone in—
 combined nerve-bone injuries, 104, 105-106
 fractures of—
 femur, 22, 243
 humerus, 144, 146
 radius, 185
- Shoulder:
 elective surgery on, 185
 spica, 144
 wounds of, 102
See also Acromioclavicular joint.
- Sicily, 67
- Simple fractures, 116, 119, 121, 123, 128, 151
 conversion of compound fractures into, 82, 88
- Site of election, 160, 165
- Skeletal traction, 8, 22, 24-25, 38, 59, 63, 89, 95, 100, 104, 115-116
 after internal fixation, 117
 application of—
 in United Kingdom Base, 78-79
 on Continent, 79
 errors in, 25
 holding periods in relation to, 78
 in acromioclavicular dislocations, disadvantages of, 211
 in combined bone-nerve injuries, 104, 105-106
 in fractures about hip joint, 235-237, 246, 248, 249, 260-261, 264, 266, 267-268, 276, 282, 283, 291
 advantages of, 235
 in fractures of bones of—
 forearm, 114, 120-121
 leg, 24, 25
 in fractures of femur, 25, 114, 148-150
 in fractures of foot, 154
 in fractures of humerus, 24, 25, 114
 in injuries of hand, 27
 in mass management of casualties, 113-116
 in tented wards, 41, 114
 in wounds of knee joint, 310
 incidence of infection after, 118
 indications for, 114, 120
 loss of position in, 115-116
 mobilization of joints in, 25
 provision for, in plaster traction splint, 49

- Skeletal traction—Continued
 shock after repeated application of, 115
 techniques of, 25, 113-116, 150
- Skin:
 conservation of, 37, 84, 160
 loss of, in Thomas leg splint, 24
 necrosis of, in fracture dislocations of ankle, 153
 preparation of, at amputation, 162
 record of loss of, 86
- Skin coverage of capsular defects, 309, 314-315
- Skin grafting, 23, 60, 63, 77, 82, 83, 95, 96, 104, 105, 151, 234, 309
- Skin traction—
 after amputation, 25-26, 161, 163, 164, 165-166
 in fractures of humerus, 144
 in injuries about hip joint, 260
 in wounds of knee joint, 313
 maintenance of, 166
- Skull, fractures of, 95
- Slings, use of—
 in acromioclavicular dislocations, 205
 in fractures of radial head, 127, 128
 in supracondylar fractures of femur, 150
 with skeletal traction, 89
- SMITH, Maj. DUDLEY W., 86
- Smith-Petersen approach to hip joint, advantages of, 232
- Smith-Petersen arthroplasty of hip, 285
- Smith-Petersen incision, 37, 232-233, 249
- Smith-Petersen nail, 28, 43, 150, 248
- Smith's fracture, 121
- Soft-tissue lesions of—
 feet, 187
 hand, 26
- Soft-tissue wounds, access to, 46, 105, 109, 114, 175
- Soft tissues:
 calcification of, 217
 damage to, in injuries about hip joint, 113, 225, 249, 255, 269, 270, 292
 paucity of, in leg, 151
- Spanish-American War, 221
- Spanish Civil War, 221
- Special studies:
 blood loss at debridement in fractures of femur, 147
 complete acromioclavicular dislocations, 191-219
 debridement, 74
 delayed primary wound closure, 91-104
 injuries about hip joint, 221-250
- Special studies—Continued
 jeep injuries about hip joint, 251-304
 management of compound fractures, 73-74
 penicillin, 74
 primary wound closure, 74
 Tobruk splint, 111-113
 wounds in prisoners of war, 14, 16-19, 20, 21, 312-316
- Specifications for plaster, 44
- Spica. *See* Plaster hip spica, Plaster shoulder spica.
- Spinal-cord injuries, 95, 147
- Spine:
 elective surgery on, 185, 186
 fractures of, 42, 53, 69, 95, 147
- Spiral fractures of femur, 149
- Splinting—
 after delayed primary suture, 109-110
 after open circular amputation, 161, 163
 in acromioclavicular dislocations, 204
 in combined bone-nerve injuries, 105
 in vascular injuries, 86
 See also special types
- Splints, vascular damage caused by, 174-175
- Splints. *See also* special types.
- Split-thickness skin grafts, 88, 89, 105, 151, 164, 174
- Splitting of circular plaster casts, 33-34, 76, 84, 85, 87, 109, 110
- Spondylolithesis, 185
- Spontaneous reduction of dislocations of hip joint, 259
- Spontaneous wound closure, 23, 97
- Spot checks of orthopedic surgery, 15
- Sprains of—
 acromioclavicular joint, 207
 ankle, 151
 coracoclavicular ligaments, 199
 elbow, misdiagnosis of, 121
 feet, 187
 noncombat type, 67
- Spur formation, 199
- Stab-wound drainage, 88
- Staging of hospitals, 17
- Staphylococci infection, 97, 239
- Station hospitals, 11, 13, 14, 15, 29, 55, 56, 57, 67, 68, 70, 73, 83, 127, 177. *See also* Hospital(s), station.
- Statistics:
 amputations, 157-158
 battle casualties, 14
 blood loss at debridement, 147

- Statistics—Continued
 blood replacement, 102
 carpal scaphoid fractures, 134-143
 chemotherapy, 74
 combined bone-nerve injuries, 104, 106
 complete acromioclavicular dislocations, 200-201
 debridement, 74
 delayed primary wound closure, 23, 91-104
 in unfavorable cases, 101-104
 fractures of—
 femur, 150
 forearm, 120
 humerus, 144-146
 radial head, 121-133
 injuries about hip joint, 221-304
 internal fixation, 117-118
 management of fractures, 73-74
 nonbattle casualties, 14
 orthopedic casualties, 14
 penicillin, 74
 plaster traction splint, 47
 regional distribution of battle fractures, 95
 Tobruk splint, 111-113
 timelag, 102, 103-104
 transfusion reactions, 168
 wound infection after reparative surgery, 102
 wounds of extremities, 81
 wounds of knee joint, 312-317
 in prisoners of war, 14, 16-19, 20, 21, 312, 313, 314, 316
 Zone of Interior hospitals, 100-101
See also Incidence, Case fatality rates.
- Steinmann pins, 63, 77, 114-115, 154, 287
 advantages of, 115
- Stellate fractures of head of femur, 287
- Stereoscopic films, 282
- STEWART, Lt. Col. MARCUS J., 75, 134, 187
- Stimson technique, 259
- Stockinet in skin traction, 32
- Stomach, emptying of, before surgery, 167
- Streptococcal wound infection, 173
- Stryker frame, 52
- Styloid process of radius, 120
- Subastragalar arthrodesis, 153, 154
- Subchondral compression fractures of—
 acetabulum, 275
 acromioclavicular joint, 203
 clavicle, 199, 215
 femur, 296
 head of femur, 284
- Subdiaphragmatic hemorrhage, 289
- Subluxation of—
 acromioclavicular joint, 202, 207, 209
 femoral head, 246
- Subtrochanteric fractures, 247
- Sulfadiazine, 57, 156, 174, 238, 249, 309, 313, 315
- Sulfonamides, 60, 100, 224, 239, 307
 local use of, 88, 161, 163, 165, 168
 undue reliance on, 85
- Superficial tissues, erroneous excision of, 37
- Superficial wound infection, 173
- Superior gemellus, 279
- Supination of forearm in fractures of radial head, 121, 122, 126, 130
- Supply, difficulties of, 43
- Suppression of virulent microorganisms by chemotherapy, 239
- Suppurative arthritis:
 of hip joint, 231, 233, 237, 238-245
 of knee joint, 305, 308, 310-312
 penicillin therapy in, 26
- Supracondylar amputation, 156
- Supracondylar fractures of femur, 31, 106, 112, 115, 149-150
- Suprapatellar pouch, 306
- Suprapubic cystostomy, 52, 289
- Surgeon General of the Army, 100, 114, 118, 227
 in World War I, 226
- Surgery, timing of, 60, 105, 106, 166
- Surgical consultant, 7, 10
 First U. S. Army, 29
 Ninth U. S. Army, 29
- Surgical field, preparation of, 88
- Surgical judgment, errors in, 27
- Surgical risk, evaluation of, in blast injuries, 166
- Surgical teams, 55
- Suspension:
 duration of, 175
 management of decubitus ulcers by, 175
 techniques of, 205, 236-237
See also Skeletal traction.
- Suspension management of—
 fractures of bones of leg, disadvantages of, 151
 limb for control of edema, 95, 106, 168
- Sutures:
 placing of, 173
 removal of, 88, 109
- Sympathectomy, 107
- Symphysis pubis, separation of, 28, 289

- Symptoms of—
 complete acromioclavicular dislocation, 202
 suppurative arthritis of knee joint, 311
 trenchfoot, 32
- Syndesmoplasty, 210-211
- Syndesmosis, 195
- Synostosis, 195, 211, 218
- Synovial membrane:
 closure of, 77, 208-309, 314
 damage to, in wounds of knee joint, 305, 307
 scarification of, 302
- Synovitis, 67
 in acromioclavicular dislocation, 202, 219
 in injuries about hip joint, 289, 292-293
- Tables of organization, 13, 16
- Tachycardia, 239
- Tactical situation, influence of, on medical policies, 63, 77, 79, 227, 260
- Taunton, 177
- Tears of ligaments of ankle, 151
- Technicians, use of, in fracture management, 38-39, 60, 115-116
- Techniques of—
 amputation, 77, 158-165
 application of—
 plaster, 36, 37, 38-39, 109-110
 plaster Velpeau, 144
 Tobruk, splint, 110-111
 traction, 148-149
 arthrotomy, 308-310
 aspiration of elbow, 127
 closure of capsule of knee joint, 309
 conservative management of acromioclavicular dislocations, 203-210
 debridement, 84-85, 249, 308-310
 delayed primary wound closure, 87-89, 102, 173
 excision of retained foreign bodies, 233
 fracture management, 19, 101-102, 109-118
 immobilization—
 in acromioclavicular dislocations, 204-210
 in carpal scaphoid fractures, 131-135
 of joints, 77
 insertion of Kirschner wire, 114-115
 internal fixation, 266, 279-282, 283-284
 reconstructive surgery of hip joint, 248
 reduction of dislocations of hip joint, 259-260
- Techniques of—Continued
 resection of—
 clavicle, 212-213
 femoral head, 243
 radial head, 128-129
 roentgenologic examination, 199, 276
 secondary resection of knee joint, 312
 skeletal traction, 25, 113-116, 150, 154, 211, 236-237, 267
 skin closure of capsule of knee joint 314-315
 skin traction after amputation, 163
 Smith-Petersen incision, 232
 syndesmoplasty, 211
 wound closure—
 after secondary debridement, 88-89
 in fractures about hip joint, 234
See also special techniques.
- Temporary skeletal traction, 115
- Tenderness in—
 acromioclavicular dislocations, 207
 fractures of radial head, 127
 suppurative arthritis of knee joint, 311
 wounds of knee joint, 306
- Tented wards, 41, 114
- Tendinous structures of fingers, 27
- Tendon repair, 43, 59
- Tendon transplantation, 11, 12, 106
- Tennessee, 101
- Tenosynovitis of feet, 187
- Tenotomy of rectus femoris, 232
- Tension:
 avoidance of, at wound closure, 88
 relief of, by incision of fascial planes, 84
- Tetanus toxoid, 105
- T-fractures of femur, 105
- Theater Chief Surgeon, 7, 8, 87, 102, 104, 112, 118
- Theater Surgeon, Mediterranean theater, 82
- Therapy, adjunct, 167-171
- Thigh, wounds of, 84, 111
- Third U. S. Army, 69, 75, 77, 81, 86, 157
- Thomas arm splint, 145
- Thomas leg splint, 24, 30, 49, 76, 110, 151, 161, 165, 235, 236, 259, 267, 276, 282, 307
 advantages of, 49
 Keller-Blake modification of, 224
- Thoracic spine, fractures of, 147
- Thoracobrachial spica, 24, 145, 205
- Thrombophlebitis, 289, 291

- Thrombosis of—
 hemorrhoidal veins, 289, 291
 medial circumflex vessels, 293
- Thrombus, lysis of, 174
- Through-and-through drains, 101
- Thumb, position of, in splinting, 135
- Tibia:
 as site of autogenous bone graft, 27
 damage to condyles of, in wounds of knee joint, 307, 309, 312, 315
 fractures of, 24, 25, 33, 45-49, 70, 76, 95, 114, 117, 151, 166, 305
 osteitis fibrosa cystica of, 28
 traction through, 146, 148
See also Bones of leg.
- Time element in carpal scaphoid fractures, 134
- Time of development of—
 avascular necrosis, 294
 suppurative arthritis, 240, 311
- Timelag:
 before debridement, 22, 70, 78, 103-104
 before delayed primary wound closure, 56, 67, 95, 102
 in acromioclavicular dislocations, 191
 prolongation of, 49, 78, 103
- Timing of—
 amputation, 245
 debridement, 167, 249
 delayed primary wound closure, 82, 310
 movement after operation in wounds of knee joint, 310
 secondary resection of knee joint, 311
 surgery in—
 blast injuries, 166
 combined nerve-bone injuries, 105
 combined vascular-bone injuries, 106
- Tincture of metaphen (nitromersol), 88
- Tobruk splint, 24, 30-31, 33, 76, 110-113, 234-235, 309, 310
 advantages of, 111-113, 234
 disadvantages of, 112-113, 234, 235
- Toenails, onychogryphosis of, 28
- Tourniquet:
 application of—
 at amputation, 162, 164
 at operation, 308, 312
 on battlefield, 159
 use of, under plaster, 175
- Torso cast, 205, 206
- Toxemia in clostridial myositis, 174
- Traction:
 after amputation, 77
 in fracture management, 60, 66, 88
- Traction—Continued
 in fractures—
 about hip joint, 224, 260-261, 266
 of ankle, 153
 of bones of leg, 151
 of clavicle, 143
 of humerus, 144-146
 of pelvis, 147
 in Tobruk splint, 30, 235
 through metacarpals, 120
 through os calcis, 151
See also special types.
- Traction cart, 57
- Traction cradle, 27, 50
 advantages of, 50
 improvised, advantages of, 50
- Traction equipment in operating room, 60
- Traffic accidents, 68, 69, 70, 119, 146, 191, 251-304
- Training marches, 187, 188
- Training:
 of enlisted men—
 as ward attendants, 38
 in special techniques, 25, 36
 of general surgeons, 37
See also Professional training.
- Transcondylar amputation, 156
- Transfusion reactions, 113, 168
- Transit hospitals, 8, 29, 36, 38, 41, 42, 55-58
- Transportability, 56
- Transportation:
 of amputees, 32
 relation of, to timelag, 78
- Transportation splinting, 67, 76, 84, 85, 87, 109-113, 144, 147-148, 165-166, 222-224, 234-235, 236, 237, 259-260, 263, 267, 307, 309, 310
- Trauma, as indication for amputation, 157, 158-159
- Traumatic amputation, 32, 77, 155
- Traumatic arthritis, 289, 293, 296
- Trapezoid ligaments, 198, 200, 201, 211, 217
- Trapezoid muscle, 199, 201, 204, 206
- Trapezoid ridge, 215
- Treatment. *See* Management, Technique.
- Trenchfoot, 31-32, 33, 170
- Triage, 55, 57, 59, 77
- Triple arthrodesis, 154
- TRIPLETT, Col. W. H., 187
- Trochanter, fractures of, 28, 247
- Troop strength, 13, 177
- TRUETA, J., 226
- Twin Bradford frame, 53

- Ulceration after—
 external fixation, 77
 pulp traction, 33
- Ulna:
 fractures of, 34, 117, 119, 120, 121
 Monteggia fractures of, 119
 traction through, 146
See also bones of forearm.
- Ulnar deviation, 120
- Ulnar nerve, protection of, in fractures of humerus, 144
- Unciform bone, 28
- Undisplaced fractures:
 about hip joint, 246
 use of traction cradle for, 50
- Union—
 in fractures of—
 bones of leg, 151
 carpal scaphoid, 138
 humerus, 144
 of fractures after reparative surgery, 100-101
- United Kingdom Base, 9, 44, 58, 73, 79, 89, 114, 157, 165
 arrival of hospitals in, 14, 16, 17, 35
 caseload of hospitals in, 22
 delayed primary wound closure in, 23
 elective surgery in, 185
 equipment in, 42-43
 evacuation to, 22, 30, 78
 holding period in, 79
 hospitals in, 9, 14, 15, 17, 41
 junior consultants in, 8-9, 39, 75
 management of British battle casualties in, 36-37
 neurosurgical centers in, 104
 rehabilitation in, 177
 shortages of orthopedic personnel in, 20
 training of orthopedic personnel in, 35-39, 67
 visits of senior consultant to hospitals in, 19-29
 wound infection in, 173-174
- United States. *See* Zone of Interior.
- United States Navy Medical Corps, 235
- United States prisoners of war, 66
- Unreduced fractures, evacuation of patients with, 79
- Upper extremity:
 amputation of, 156, 159, 166
 splinting of, 76
- Uremic syndrome, 70
- Urethra, wounds of, 289
- Urethrostomy, 146
- Urgent surgery in transit hospitals, 56
- URIST, Maj. MARSHALL R., 27, 45
- Urist splint, 206-210, 219
 disadvantages of, 206
- Utah Beach, 69
- Utilization of—
 hospitals at invasion, 17
 orthopedic personnel, 17, 57-58
- V-1 bombs, 69
- Vacuolization of bone, 137-142
- Variations in—
 acromioclavicular joint, 195-197
 holding period on Continent, 78-79
- Vascular changes in carpal scaphoid fractures, 137-138, 139
- Vascular damage:
 as indication for amputation, 144, 155-156, 157, 159, 161, 166
 associated with fractures, 78, 80, 81, 85, 86, 106-107, 144, 155-156
 errors in management of, 86
 secondary hemorrhage after, 174
- Vascular spasm, 107
- Vascular tissue, loss of, in fractures of humerus, 146
- Vaseline-impregnated gauze, 84, 86, 89, 161, 165, 173, 241
- V-E Day, 9, 19, 39, 91, 168
- Vertebrae, fractures of, 95
- Vertical acromioclavicular joints, 203
- Vertical fractures of radial head, 121
- Vertical traction, 28, 236, 260, 267
- Veterans' Administration, 20, 21, 293
- Visceral injuries, 146, 225
- Visceral wounds. *See* wounds of special organs.
- Visits of—
 junior consultants to hospitals, 8, 9
 senior consultant to hospitals, 7, 8, 19-34, 73
- Vitallium screws, 27
- Vitamin therapy, 168, 238
- Volkman's ischemia, 153
- VON LANGENBECK, BERNHARD, 279
- Von Langenbeck incision, 279
- Walking wounded, 56
- War of the Rebellion, 221, 239
- Ward, exercises on, 127
- Ward attendants, enlisted men as, 38
- Ward discipline, 170

- Ward officers:
 caseload of, 60
 in transit hospitals, 57, 58
 use of protected prisoner medical personnel as, 66
- Ward rounds, 8, 178
- Wardmaster, supervision of exercise by, 178
- Wastage of—
 manpower, 179
 orthopedic personnel, 22
- Wasting, due to protein deficiency, 168
- WATSON-JONES, REGINALD, 36, 212
- Watson-Jones incision, 232
- Weight bearing—
 after injuries about hip, 261-262, 276, 296, 297
 after resection of femoral head, 243
 in injuries of os calcis, 154
 in trenchfoot, 29
- WHEELER, W. I. DE COURCY, 226, 235, 243
- Whirlpool treatments, 127
- Whisky, use of, for dilatation of peripheral vessels, 107
- Wild West era, 221
- Windows, provision of, in casts, 46, 52, 105, 109, 175, 309
- Wire ladder loop in skin traction, 32
- Wire ladder splints, 66, 166
- Wiring of fractures of humerus, 144
- Working hours of surgical teams, 55
- World War I:
 adjunct therapy in, 238
 amputation in, 157
 arthrotomy of hip joint in, 225
 history of, 185
 management of fractures about hip joint in, 221, 224, 225-226, 235, 239, 241, 243, 311
 orthopedic surgery in, 35
 use of Thomas leg splint in, 224
- Wound closure after circular incision at debridement, 85
- Wound closure. *See also* Delayed primary wound closure.
- Wound excision in neglected fractures of femur, 150.
- Wound healing, 73, 74, 87, 114, 118, 146, 150, 168, 174
- Wound infection, 67, 86, 89, 102, 144, 173-174, 225, 316
 rebridement in, 173
- Wounding:
 conditions of, 74
 edema after, 168
 protein depletion after, 168
- Wounds:
 access to, in plaster for dressing, 46, 52, 105, 114, 175
 caused by guided missiles, 166
 exploration of, in secondary hemorrhage, 175
 exposure of, at debridement, 84
 of abdomen, 276
 of ankle, 102
 of bladder, 34, 97, 227, 233, 237, 289
 of buttocks, 34, 84, 111, 157, 235
 of chest, 32
 of extremities, 10, 27, 81
 of foot, 102, 156
 of forearm, 102, 119
 of hand, 102
 of head, 32, 276, 290
 of intestine, 97, 227, 237, 239-240, 241, 244
 of joints, 77
 of knee joint, 305-317
 in prisoners of war, 14, 16-19, 20, 21, 312, 313, 314, 316
 of leg, 102, 111
 of muscles, 114
 of rectum, 244
 of sacrum, 235
 of shoulder, 102
 of thigh, 84, 111
 of urethra, 289
 status of, after debridement, 83
- Wrist joint:
 function of, after fractures of forearm, 120
 innervation of, 126
 pain referred to, 126
 position of, in transportation splinting, 77
- Y-ligament, 260
- Youth:
 incidence of trauma in, 252
 of soldiers, 170

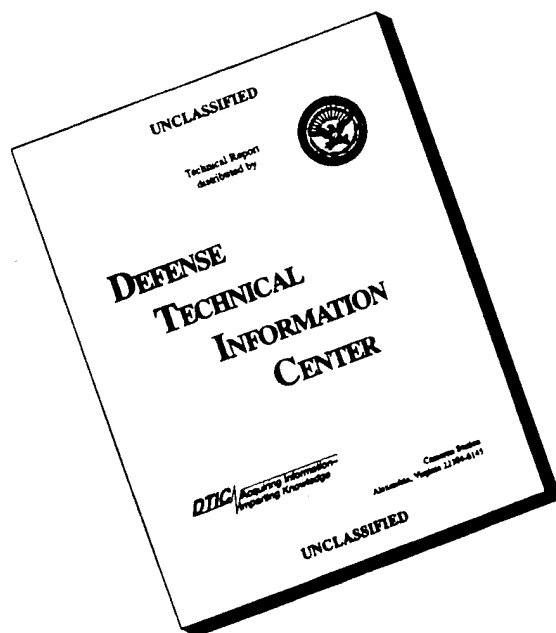Zone of Interior:

arrival of hospitals from, 55
bone grafting in, 121
definitive surgery in, 26
development of suppurative arthritis in,
240, 241
evacuation to, 22, 23, 26, 44, 53, 61,
83, 89, 92, 105, 109, 114, 135, 140, 142,
147, 153, 154, 170, 174, 236, 268, 277
hospitals of, 114

Zone of Interior—Continued

limitation of elective surgery to, 185
management of jeep injuries in, 261
mission of hospitals of, 66
orthopedic experience in, 35
restriction of—
arthrotomy of knee joint to, 186
surgery for ruptured lumbar disk to, 185
study of results of reparative surgery
in, 100-101

DISCLAIMER NOTICE



THIS DOCUMENT IS BEST QUALITY AVAILABLE. THE COPY FURNISHED TO DTIC CONTAINED A SIGNIFICANT NUMBER OF PAGES WHICH DO NOT REPRODUCE LEGIBLY.