

AD \_\_\_\_\_

GRANT NO: DAMD17-94-J-4281

TITLE: Breast Duct Endoscopy as a Means of Obtaining and  
Studying Precancerous Ductal Epithelial Cells

PRINCIPAL INVESTIGATOR(S): Susan M. Love

CONTRACTING ORGANIZATION: The Regents of the University of  
California  
Los Angeles, CA 90095-1406

REPORT DATE: 13 Sep 95

TYPE OF REPORT: Annual


PREPARED FOR: U.S. Army Medical Research and Materiel Command  
Fort Detrick, Maryland 21702-5012

DISTRIBUTION STATEMENT: Approved for public release;  
distribution unlimited

The views, opinions and/or findings contained in this report are  
those of the author(s) and should not be construed as an official  
Department of the Army position, policy or decision unless so  
designated by other documentation.

19951116 009

DTIC QUALITY INSPECTED 5



REPORT DOCUMENTATION PAGE			Form Approved OMB No. 0704-0188	
<small>Public reporting burden for this collection of information is estimated to average 1 hour per response, including the time for reviewing instructions, searching existing data sources, gathering and maintaining the data needed, and completing and reviewing the collection of information. Send comments regarding this burden estimate or any other aspect of this collection of information, including suggestions for reducing this burden, to Washington Headquarters Services, Directorate for Information Operations and Reports, 1215 Jefferson Davis Highway, Suite 1204, Arlington, VA 22202-4302, and to the Office of Management and Budget, Paperwork Reduction Project (0704-0188), Washington, DC 20503.</small>				
1. AGENCY USE ONLY (Leave blank)	2. REPORT DATE 13 Sep 1995	3. REPORT TYPE AND DATES COVERED Annual 15 Aug 94 - 14 Aug 95		
4. TITLE AND SUBTITLE Breast Duct Endoscopy as a Means of Obtaining and Studying Precancerous Ductal Epithelial Cells		5. FUNDING NUMBERS DAMD17-94-J-4281		
6. AUTHOR(S) Susan M. Love, M.D. Sanford H. Barsky, M.D.				
7. PERFORMING ORGANIZATION NAME(S) AND ADDRESS(ES) The Regents of the University of California Los Angeles, CA 90095-1406		8. PERFORMING ORGANIZATION REPORT NUMBER		
9. SPONSORING/MONITORING AGENCY NAME(S) AND ADDRESS(ES) U.S. Army Medical Research and Materiel Command Fort Detrick, Maryland 21702-5012		10. SPONSORING/MONITORING AGENCY REPORT NUMBER		
11. SUPPLEMENTARY NOTES				
12a. DISTRIBUTION / AVAILABILITY STATEMENT Approved for public release; distribution unlimited		12b. DISTRIBUTION CODE		
13. ABSTRACT (Maximum 200 words) One limiting factor for all of breast cancer prevention research has been our lack of intermediate markers of breast cancer risk. The main reason we have been unable to identify such markers is that we do not have ready, reproducible, non traumatic access to the lining epithelium. Since most breast cancer starts in the epithelial lining of one of the six-to-nine milk ducts found in each breast, breast duct endoscopy and pathological/cytological analysis is an ideal means of gaining access to the ductal epithelial cells and diagnosing, treating and studying the precancerous state. Using a flexible duct endoscope, the breast ducts of seven of nine patients with ductal carcinomas in situ (DCIS) and/or invasive breast cancer have been successfully cannulated and studied by cytological and pathological analysis. Contrast dyes including methylene blue, gastrograffin, and barium sulfate injected into the cannulated ducts have also demonstrated a number of important observations with respect to both the normal ductal system as well as DCIS. In addition, we have shown that the ductal system of the breast is a non-anastomosing three dimensional network composed of ducts and acini.				
14. SUBJECT TERMS Ductoscopy, ADH, Precancerous, DCIS, Prevention, Intermediate Markers, Humans, Anatomical Samples, Breast Cancer			15. NUMBER OF PAGES 34	
			16. PRICE CODE	
17. SECURITY CLASSIFICATION OF REPORT Unclassified	18. SECURITY CLASSIFICATION OF THIS PAGE Unclassified	19. SECURITY CLASSIFICATION OF ABSTRACT Unclassified	20. LIMITATION OF ABSTRACT Unlimited	

## FOREWORD

Opinions, interpretations, conclusions and recommendations are those of the author and are not necessarily endorsed by the U.S. Army.

( ) Where copyrighted material is quoted, permission has been obtained to use such material


( ) Where material from documents designated for limited distribution is quoted, permission has been obtained to use the material.

( ) Citations of commercial organizations and trade names in this report do not constitute an official Department of the Army endorsement or approval of the products or services of these organizations.

( ) In conducting research using animals, the investigator(s) adhered to the "Guide for the Care and Use of Laboratory Animals," prepared by the Committee on Care and Use of Laboratory Animals of the Institute of Laboratory Animal Resources, National Research Council (NIH Publication No. 86-23, Revised 1985

(X) For the protection of human subjects, the investigator(s) have adhered to policies of applicable Federal Law 45 CFR 46.

( ) In conducting research utilizing recombinant DNA technology, the investigator(s) adhered to current guidelines promulgated by the National Institutes of Health.

  
Principal Investigator's Signature

9/13/95  
Date

Accession For	
NTIS	CRA&I <input checked="" type="checkbox"/>
DTIC	TAB <input type="checkbox"/>
Unannounced <input type="checkbox"/>	
Justification _____	
By _____	
Distribution /	
Availability Codes	
Dist	Avail and/or Special
A-1	

## Table of Contents

Front cover .....	Page 1
Report Documentation Page .....	2
Foreword .....	3
Table of Contents .....	4
Introduction .....	5
Research Questions .....	6
Methods of Approach .....	7
Materials and Methods .....	8
Results .....	9
Conclusions .....	11
Future Work .....	13
List of References .....	15
List of Appendices .....	17
Table 1 .....	18
Schematic I .....	19
Illustrations .....	20
FDA IDE .....	23
UCLA HSPC correspondence and Amendment C .....	25

## Introduction

There is an enormous need for intermediate markers in the study of breast cancer. If there were changes which could be reliably identified short of cancer, a prevention research program could proceed much more rapidly. Although there are conventional histological changes such as intraductal hyperplasia which convey an increased risk for breast cancer, it is not easy to blindly obtain breast tissue to look for these changes. In addition, it is not clear that the changes identified in one part of the breast are representative of all breast tissue. We know, for example, that intraductal hyperplasia with atypia<sup>1</sup> and lobular carcinoma *in situ*<sup>2,3</sup> are often multicentric and represent an increase in the subsequent risk of breast cancer which may occur anywhere in either breast. This would suggest that atypical ductal hyperplasia (ADH) and lobular carcinoma *in situ* (LCIS) are marking a field defect throughout the breast tissue.

On the other hand, untreated ductal carcinoma *in situ* (DCIS) predicts for a subsequent invasive cancer in about 30 percent of women over ten years.<sup>4,5</sup> This risk is always in the same area of the breast as the original lesion.<sup>5</sup> Although many studies have reported that DCIS is multicentric, they are all based on the supposition that the breast tissue is in quadrants.<sup>6</sup> All of the studies took breasts that had been removed for DCIS and cut them into four quadrants. If DCIS was found in more than one quadrant it was deemed to be multicentric. The breast ducts are not oriented in quadrants. Rolland Holland<sup>7</sup> performed elegant dissections of mastectomy specimens and documented that, although a high percentage were in more than one quadrant, in 80 of 81 cases the disease was contiguous. This would argue for a focal or local defect, perhaps in one ductal system. It also suggests that there are changes in one ductal system which are not seen in the others. It suggests that a shift takes place from ADH to DCIS and that there are factors in the local environment of the duct which are responsible for this change. This would make blind fine needle aspirations<sup>8</sup> or pooled nipple discharge<sup>9</sup> unreliable in identifying the molecular genetic changes necessary to go from ADH to DCIS and on to invasive cancer. A better approach would be to actually biopsy the lining of the duct through an intraductal technique.

Makito<sup>10</sup> described the use of a ductoscope to examine women with nipple discharge. They used a rigid 1.2 mm scope to identify intraductal papillomas. A better approach would be to actually biopsy the lining of the duct through an intraductal technique. Makito (from Japan) described the use of a ductoscope to examine women with nipple discharge. They used a rigid 1.25 mm scope to identify intraductal papillomas. On the basis of his work we did a pilot study in 1991<sup>11</sup> to determine if this technique could be applied to the nondischarging duct. Women who were to undergo a mastectomy were approached and asked if they would allow us to try the ductoscope for 20 minutes after general anesthesia had been obtained and prior to their surgery. All the women approached agreed. In nine of the ten women we were able to cannulate a duct and visualize the duct lining. After the procedure the duct we had visualized was examined microscopically. We noted that the ductal lining had been eroded in the majority of cases probably due to the rigid scope and its size. Other problems included difficulty in dealing with ductal secretions. Although the pilot demonstrated to us that it was indeed possible to cannulate non-discharging ducts it was also obvious that the rigid scope was not ideal. In addition we had only tried to cannulate the most obvious duct rather than any one particular one. A second Japanese group<sup>12</sup> described the use of a 0.4 mm flexible scope for the investigation of nipple discharge. This scope allowed cannulation of the ducts with less trauma.

One difficulty in this project was that no one had actually mapped the breast ducts. Although many text books state that there are 15-20 breast ducts per breast that figure is actually based on the number of openings in the nipple. In fact, recent studies by Sartorius<sup>13</sup> have demonstrated that there are probably five to nine different ductal systems in a fairly regular pattern. The other openings in the nipple are blind sebaceous glands which coat the nipple. We needed to devise a technique for reliably identifying the duct openings in women who did not have nipple discharge.

We proposed trying to use the smaller flexible scope to see whether nondischarging ducts could be cannulated reliably and nontraumatically. We are reporting on the first year of the study exploiting the flexible ductoscope coupled with the use of contrast dyes and detailed pathological/cytological analysis to investigate the ductal system in seven cases of DCIS and/or invasive breast cancer in order to improve our understanding of pre-cancerous diseases of the breast.

Our original proposal had two phases. The first phase was to repeat the pilot study with the flexible scope gaining facility with its use both for visualizing the duct and obtaining tissue or cells from it. We planned to expand the pilot, as well, to women who had nipple discharge ( a group in which it has been successfully used in Japan). Once we had gained facility in the use of the scope and could reliably cannulate a duct at will and obtain tissue or cells (estimated 20 cases minimum) we planned to go on to phase two. Phase two would address the use of the scope in women who were likely to have DCIS. These women would be identified by having suspicious micro calcifications on their mammogram. The involved duct as demonstrated by ductogram would be identified and cannulated. Cells or tissues will be obtained from the duct lining as close as possible to the area of the duct involved with the pathology. These cells would be analyzed to determine their clonality.

This work was designed to serve two purposes. First we would devise a noninvasive reliable technique which could be used repeatedly to explore the breast ductal systems. Although it is unlikely that this will ever be used as a screening technique it will be an important research tool. Particularly in women at high risk for breast cancer, this would give us access to the crucial ductal lining tissue. The same area could be resampled at different times in order to identify changes in the cells as a result of progression of the disease or in response to treatment. This technique could also be an important tool in mapping out the breast ductal systems and determining the differences and similarities among them. It could even be a method for delivering a potential treatment for early changes. Our first application of this technique was to study the clonality of DCIS. This project would enable us to prove that this is indeed a reliable technique and that the cells obtained can be reliably used for further study.

### **Research Questions**

1. That a flexible ductoscope could be used to examine breast ducts and obtain cells and tissue from them.
2. That these cells could be analyzed to give information regarding the clonality of the early changes of breast cancer.

## Methods of Approach

### Original Procedure

The initial year of study has involved only the first phase of the proposed research, therefore only that aspect will be described in detail. All women who were scheduled to have a mastectomy under general anesthesia were approached to participate. Women scheduled for mastectomy were to be first put to sleep with general anesthesia. The breast was prepped and an attempt made to identify the breast duct orifices. A duct was cannulated with a catheter. After washing the duct with saline and obtaining cytology an attempt was made to pass the flexible scope into the duct. If this was successful we tried to biopsy the lining of the duct with brushings or washings. A marking dye was instilled into the duct and the nipple sutured closed. This procedure took approximately twenty minutes. Once the twenty minutes were up the endoscopy stopped and the patient would have the mastectomy as planned. An attempt would be made to examine the duct which had been cannulated histologically in the mastectomy specimen.

### Amended Approach

After it was determined by the UCLA Human Subject Protection Committee (HSPC) that this research posed a potential risk to patients, we were required to obtain an IDE from the FDA. We were initially approved by the FDA (IDE # G94002) to use the Japanese scope in five women who were about to undergo mastectomy. Although we were able to visualize the ducts in several of the patients, it was obvious that we needed some revisions in the protocol. We had found that marking the duct which had been scoped with methylene blue prior to the mastectomy was inadequate. The methylene blue did not persist fixation with formaldehyde and was not visible on the subsequent slides. We tried two other inert commonly used biological substances; gastrograffin and barium. Both proved to be better markers. We subsequently asked the FDA and the HSPC (Amendment B) for permission to use gastrograffin and/or barium as a marker in breasts to be removed by mastectomy.

We then requested and received permission from the FDA to attempt breast duct endoscopy in two additional patients using either the Japanese scope or a Baxter angioscope. This was obtained and the cases performed. The Baxter angioscope using saline dilatation of the duct proved to have superior optics as compared to the Japanese scope. Barium was used in these cases to mark the duct.

During much of this time we were waiting for various approvals to proceed with the endoscope. It occurred to us that we could use this time to practice finding the ducts and cannulating them to obtain washings without actually using the endoscopes. We asked the HSPC for Amendment A. This allowed us to approach every woman who was going to have a breast operation under anesthesia and ask her if we could spend ten additional minutes trying to identify her ductal orifices in the nipple. If one was identified we would cannulate it and instill saline (0.2cc) in an attempt to obtain washings. We have used a galactography kit which is commercially available to dilate and cannulate the ducts (Manan Taber-Rothschild dialators 000000 thru 0). This aspect of the study has proceeded and we have enrolled 12 women having breast sparing operations and five who were undergoing mastectomies.

As a result of this initial work we have asked for several revisions to our original protocol Amendment C (see Appendix).

## MATERIALS AND METHODS

### Use of the Breast Endoscope and Ancillary Pathological/Cytological Studies

This study of breast duct endoscopy was initially approved for five patients by both the UCLA Human Subjects Protection Committee as well as the U.S. Food and Drug Administration (IDE# G940002). Ultimately, seven patients with DCIS/invasive breast cancer diagnosed by previous core biopsy were prepared for mastectomy under general anesthesia. Patients consenting to the study were prepared for breast endoscopy using the technique of Okazaki.<sup>12</sup> The breast was prepped and draped and an attempt was made to identify the breast duct orifices with magnifying loupes. Once the ducts were identified, one or several were cannulated first with a rigid metal duct probe (0.35 mm in outer diameter) dilated to 0.45-0.5 mm. A right angled cannulation (0.4 mm in outer diameter) was then inserted into the duct orifice and 0.20-0.50 ml of physiologic saline solution was then instilled to wash the duct lumen. The washings were spun down and analyzed cytologically. In the first five cases, the duct lumen was then dried by injecting 0.20-0.50 ml of air. At the end of the final insufflation, the orifice was held shut by pinching the end of the nipple. The endoscope (FVS-3000) which is 0.4mm in outer diameter, was then threaded into the duct orifice while maintaining the dilation of the duct with air. Once the endoscope was 5-10 mm deep, its position was confirmed on the monitor screen. The cannulation was continued as far distally as possible. Once the cannula was removed, we instilled contrast dye which included methylene blue, gastrograffin or barium sulfate into the duct and sutured it closed. The additional two cases were then approved and the technique altered so that the duct was dilated with saline in a closed system using a burst adapter with a side arm. This allowed better optics. The final case was performed using a Baxter Angioscope (0.7 mm). Mastectomy was then performed followed by detailed cytological and pathological analysis of all specimens. On average 1 - 2 duct orifices were identified and were explored down to 2 or 3 bifurcations. (See Table 1) .

### Verification of the Identity of the Cannulated Ducts and the Cells So Obtained

Cells retrieved through the ductoscope (as washings) were initially processed according to standard cytological methods established for bronchial brushing, washings and biopsy. The identity of the cells were achieved in two ways: 1) directly by a study of the cells themselves and 2) indirectly by a histopathological analysis of the duct from which the cells were obtained.

The direct study of the cells was achieved using two different approaches. Cells were first identified as being epithelial in origin as opposed to macrophage or other cell types by immunocytochemistry studies utilizing a murine monoclonal anti-low molecular weight (39, 43, 50 kD) cytokeratin.<sup>14</sup> Strong cytokeratin immunoreactivity was present in ductal epithelial cells but completely absent in macrophages and other inflammatory cells. This immunocytochemical approach was not by itself able to distinguish normal ductal cells from hyperplasia of the usual type, atypical ductal hyperplasia or DCIS, etc., which are all cytokeratin positive. A second approach was to perform additional immunocytochemical studies utilizing anti-*neu* antibodies. Approximately 60-70% of cases of comedo DCIS are thought to show membrane staining with anti-*neu*<sup>15</sup> and another 20-30% are positive for mutant p53. Therefore, if comedo DCIS were obtained through the ductoscope, their anti-*neu* membrane and p53 staining confirmed their identity.

Indirect confirmation of the identity of the cells was achieved by a histopathological analysis of the duct from which the cells were obtained confirmed by the presence of contrast dye.

### **Immunocytochemical Reagents and Assay Protocols**

Antibodies and other immunohistochemical reagents were purchased from the following sources: c-neu Ab3 (OP15, Oncogene Science); biotinylated goat anti mouse (Zymed 62-6540); horseradish peroxidase conjugated streptavidin (Vector # SA-5004); aminoethyl carbazole-AEC (Zymed 00-2007); hematoxylin 9Sigma GHS-3-800; Nargase (Sigma P-4789).

Assay Protocol: Slides were dewaxed by five washes in hemo De and rehydrated by five washes 2 min each in 100% ethanol, 95% ethanol, and PBSTX (phosphate buffered saline, 0.1% triton x-100, thimersol). For Her2/neu, and p 53 assays slides were processed by antigen retrieval by boiling in 10 mM citric acid solution for 30 min.<sup>15</sup> Slides were washed five times in PBSTX between each step below. Endogenous peroxidase activity was blocked with 1% peroxidase solution for 15 minutes at room temperature. Sections were then incubated with primary antibody 1/300 Her/2neu, 1/100 p53 overnight in a hydration chamber at room temperature. Sections were incubated with 1/200 biotinylated goat anti mouse IgG for 30 minutes at 37 degrees followed by 1/200 horseradish peroxidase-streptavidin for 15 minutes. Antigen binding sites are then revealed by incubating with the peroxidase substrate AEC which was hydrolyzed to an insoluble brilliant red precipitate. Tissue was lightly counter stained with 105 Harris hematoxylin for 1 minute at room temperature. Sections were covered with Crystal/mount and dried at 90 degrees C for 15 minutes.

Nuclei of cells containing antigens for p53 stain red. Tissues with greater than 10% of the nuclei staining were considered positive for these antigens.<sup>16,17,18,19</sup>

Surface membrane of cells containing the Her2/neu antigens stain red. Tissues with greater than 10% staining (weak to strong staining intensity) were considered positive for these antigens, Cytoplasmic granular staining was considered nonspecific.

## **RESULTS**

### **Ductoscope Analysis**

The major difficulty that we encountered in this pilot work was in the identification of duct orifices. We attempted breast duct endoscopy in nine patients and were able to cannulate seven. (See Table 1.) One of the two who we were unable to cannulate had extensive surgery below her nipple areolar complex previously and her ducts were completely scarred shut. The other woman had no actual ducts identified. The one orifice which was identified was thought to be a sebaceous duct.

For this initial study we cannulated only those ducts whose orifices were readily apparent. This meant that sometimes we entered the duct with DCIS (Figure 1A) and other times we entered entirely normal ducts. In this pilot work we averaged two duct cannulations per breast studied. Our current work has shown that, with practice, the identification of the duct orifices becomes easier in some but not all women (Figure 1B). We are currently working on techniques to facilitate this aspect of the work.

We have also shown that the duct is distensible but can rupture. In our initial five cases we used air to distend the duct and employed a 0.45mm endoscope from Japan (FVS 3000). The difficulties in this approach included the fact that the tip of the endoscope easily became blurred through contact with the side of the duct. Recalling that the breast ducts are quite distensible during breast feeding we elected to try distending the duct with saline and using a larger scope. The last two cases involved using a closed system with saline to distend the duct and a 0.7mm Baxter angioscope. The visualization of the duct lining was excellent and much better than in the initial cases. When we examined the breast pathologically, however, we noted that we had ruptured the duct in both cases. This was demonstrated by the presence of extravasated dye. In both of these cases we had cannulated the ductal system involved in cancer. It may be that a cancerous ductal system is less distensible. In subsequent cases, we will study pressure gradients in the ductal system.

The final technical problem is in obtaining washings. The duct is so small (capacity 0.2-0.3cc) that it is difficult to aspirate back from a cannulate to obtain material. When doing washings we remove the catheter and collect the fluid externally in a capillary tube. This is adequate but not optimal. We are trying to develop a double lumen tube to overcome this difficulty.

In five of the nine cases we obtained epithelial cells in the washings. In one the cells were consistent with proliferative disease, in three there was atypical epithelium, and in one there were frank ductal carcinoma. There were no complications or untoward events in these first nine patients.

### **Pathological Analysis**

The pathological approach to the seven ductoscoped mastectomy specimens is depicted in Schematic I. Pathological analysis demonstrated a number of important observations with respect to both the normal ductal system as well as the ductal system in DCIS. The ductal epithelial cells were extremely sensitive to endoscopy and readily exfoliated with instrumentation (Figure 2A). A pronounced host inflammatory reaction composed of both polymorphonuclear leukocytes and eosinophil was seen, not only in the duct being instrumented, but also in the adjacent lobule illustrating a unique ductal-lobular inflammatory reflex (Figure 2B). In the studies where contrast dye was injected the ductal system appeared to be a non-anastomosing three dimensional network composed of ducts and acini which are difficult to correctly assign to their ductal system of origin in routine two dimensional histological sections (Figure 2C). This finding bears directly on the accuracy of both positive and negative margins in DCIS. DCIS lesions which were successfully visualized through endoscopy gave rise to exfoliated DCIS cells which could be successfully retrieved through washings (Figure 3A). The cells were confirmed as DCIS cells by either positive membrane neu immunoreactivity, positive nuclear p 53immunoreactivity, or aneuploidy (Figure 3B). In studies where several different dyes were injected in different ductal systems, DCIS appeared confined to a single ductal system despite its illusion of being present within a number of different ducts in routine sections (Figure 1).

## Conclusions

These initial findings from duct endoscopy should foster subsequent studies designed to investigate intermediate markers in breast cancer progression which may be present only within one ductal system. These initial endoscopy findings should lead to other studies which more accurately define the scope and extent of DCIS and establish more reliable cytological criteria. Finally, these early endoscopy observations should ultimately lead to future studies designed to exploit endoscopy to target the ductal system of the breast for promising DCIS drug or gene therapy.

The first question in this endeavor is whether any part of the breast is representative of the whole or whether there are anatomical subdivisions which are critical in the development of breast cancer. So far, it is not clear whether the steps toward malignant transformation are a field with a multicentric representation or a focal problem. Clinically, lobular carcinoma in situ<sup>2,3</sup> and atypical ductal carcinoma are found through both breasts. The future cancer risk in these situations is about 30%<sup>1</sup> and is bilateral. That is, the subsequent cancer can appear anywhere in either breast. This would imply a field defect throughout the breast tissue. Ductal carcinoma in situ (DCIS) was initially thought to be multicentric as well. This was based, however, on a false premise. Breasts removed for cancer were cut into four quadrants and, if disease was identified in more than one quadrant, it was said to be multicentric.<sup>6</sup> There is no anatomic correlation to quadrants in the breast. The ductal systems, when they have been mapped out, have no relation to the quadrants of the breast. A very careful study by Rolland Holland<sup>7</sup> in Nijmegen demonstrated that DCIS is almost always contiguous. Other investigators have also shown the focal nature of the disease.<sup>20</sup> This correlates well with the clinical observation that recurrences after limited treatment for DCIS are always in the same area in the same breast area as the original lesion and that bilateral DCIS is uncommon.<sup>5</sup> This leads to the hypothesis that DCIS is a focal defect which is found in the distribution of a single ductal system. This implies that perhaps only a single ductal system is at risk (limited field theory). Preliminary data from microdissection has supported this theory<sup>21</sup> as well as data provided in the present endoscopy study. It would follow that examining different ductal systems within one breast will help to determine whether the intermediate steps of progression are global throughout the breast or focal within one ductal system.

Nicholas Petrakis and his group in San Francisco have analyzed a series of 2,701 nipple duct fluid aspirates collected from 1973-1980. The fluid was obtained from volunteers using the technique of Sartorius. This technique involves a small plastic cup attached to a short plastic tube being placed over the nipple. While the woman gently massaged her breast with both hands, the syringe was retracted to the 5-6 ml mark. If fluid did not appear within 5 seconds, the plunger was withdrawn to the full 10 ml mark and held for an additional 10-15 seconds. If no fluid appeared within this time, the subject was designated as a nonyielder. The fluid appearing on the nipple surfaces was pooled and collected in capillary tubes and processed for cytology. Cytology was read as normal, hyperplasia and atypical hyperplasia. Nipple aspirate fluid satisfactory for cytologic diagnosis was obtained from 80% of women who were age 25-54 and 50% of women over 54. A recent analysis of the cohort after an average of 12.7 years and follow-up found 104 of the women in the cohort had developed breast cancer. The overall breast cancer incidence was 4.4% (104/2,343) and rose with fluid cytology findings, with the highest risk in the women who

had atypical hyperplasia identified in their nipple duct fluid aspirate (10.3%). Compared to women with no fluid, the relative risk of subsequent breast cancer in women with atypical hyperplasia in their nipple duct fluid was 4.9. The findings were strongest for women between 25-54. They concluded that hyperplasia and atypical hyperplasia diagnosed in nipple aspirates of breast fluid are associated with an increased risk of breast cancer.<sup>9</sup>

This work suggested that cytology of ductal fluid can be an intermediate marker for subsequent breast cancer risk. It is limited in that not all women are able to yield fluid with this technique. In addition, the fluid collected is presumably pooled from all of the ducts and from both breasts. It is possible that only the duct which is premalignant yields fluid and that normal ducts are less likely to shed cells and/or yield fluid on stimulation of the nipple. This concept is supported by the fact that the nonyielders had a low subsequent risk of breast cancer. This provocative study suggested that studying fluid from individual ducts has the potential of yielding information regarding intermediate markers for breast cancer. Although Sartorius' technique for obtaining nipple duct fluid is technically easier to perform than intraductal cannulation, it does not address the question of whether this is a focal or multicentric defect.<sup>13</sup>

A second technique which has been reported for identifying intermediate markers is the analysis of multiple fine needle aspirates in high risk women. Fabian's group from Kansas<sup>8</sup> performed eight aspirations per breast and repeated the procedure six months apart to obtain sufficient cells for all tests. A high risk woman was defined as a woman between 30 and 60 with a first degree relative with breast cancer, prior node negative breast cancer, or precancerous histology (DCIS or ADH). Cytology, ploidy, ER, p53, EGFR, and Her 2-neu were evaluated. In the high risk group, the prevalence of aneuploidy was 32%, ER over expression 10%, EGFR over expression 32%, p53 over expression 29%, and Her 2-neu over expression 12%. The differences between high risk women and low risk women were significantly different for cytology, ploidy, p53, and EGFR. Fifty-five percent of the high risk women had epithelial hyperplasia or atypical epithelia hyperplasia compared to 12% of low risk women. The prevalence of all biomarkers were greater in women with hyperplastic cytology. Although these data indicate that there may well be biomarkers identifiable in the breast tissue of high risk women, these markers may not be specific intermediate markers since their study pooled cells from all areas and both breasts. If intermediate markers are limited to one ductal system, the chance of finding them with this technique is small. Analysis of fluid or analysis of ductal cells from one hyperplastic or DCIS ductal system should have a higher likelihood of yielding information on intermediate markers. Hence the present work with breast duct endoscopy is especially promising.

Breast duct endoscopy also shows promise in enabling us to make a number of important observations with respect to both the normal ductal system as well as the ductal system in DCIS. The anatomy of the ductal systems has not been well delineated. Although the textbooks all list 15-20 ductal systems per breast, work by Sartorius demonstrated only 5-9.<sup>13</sup> He demonstrated by cannulation that the other orifices seen at the nipple are blind sebaceous glands. In both his and our experience the ductal systems do not anastomose with each other. The individual ductal systems do, however, intertwine with each other like branches of a tree. This means that ducts which appear adjacent to each other on a two dimensional tissue section do not necessarily belong to the same ductal system. The present work has convincingly demonstrated this. A recent study by Ohtake et al<sup>23</sup> suggested that there were 4-6 ductal systems per quadrant and that some

anastomoses between ductal systems do, in fact, exist. They based this statement on two false assumptions. First of all, as pointed out, the pattern of the ductal systems in no way correlates to quadrants. Therefore, they probably have one main ductal system and a portion of one from another quadrant. In addition, they started their dissection and analysis from stumps of ducts at the most central part of their dissection. From cannulating ducts and marking them with barium we have found that the stumps of several disparate ductal systems are found adjacent to each other under the nipple. We feel that cannulation of the duct is a more accurate method for depicting the anatomy.

The findings in this study concerning the confinement of DCIS to a single ductal system have direct implications for an understanding of the biology of DCIS as well as the need for focusing on the single involved duct for the discovery of intermediate markers. In addition, the demonstration that contrast dye can be injected into the ductal system involved by DCIS and that DCIS cells can be retrieved from this system in washings should allow us in subsequent studies to more precisely define the scope and extent of DCIS and establish cytological criteria by quantitative techniques such as digital image analysis. The evaluation of margins for DCIS, a perennial problem for both surgeons and pathologists, often subjectively evaluated, should be rendered more precise by the use of ductoscopy.

Finally, successful use of breast duct endoscopy should help us direct our thinking about breast cancer and pre-cancer within the framework of the ductal system. In thinking about therapy we might consider this ductal system as a target for new drug or gene therapies. For example, retroviral technology now exists to deliver antisense oncogenes (Ha-ras or Ki-ras) and/or normal wild type suppressor genes (p53) to lung cancer in the hopes of neutralizing or reversing some of the genetic alterations which play key roles in the pathogenesis of that cancer. Analogous alterations could be neutralized or reversed in DCIS if suitable vectors can deliver via endoscopy the appropriate neutralizing genes to their breast ductal targets.

### **Future Work**

In this pilot work we have shown that breast duct endoscopy has the potential to give us access to the milk ducts. The current limiting factor is the ability to identify and cannulate all of the duct orifices at will. We are addressing this problem in current studies attempting to develop a local technique to facilitate ductal identification. We will be exploring the use of local anaesthetic/vasodilator such as EMLA, papaverine and suction to help delineate the ductal orifices. We are reluctant to try systemic agents which may have hormonal effects on the breast such as oxytocin or prolactin until we have exhausted all local avenues.

As an ancillary study we are planning to study women who are lactating to develop a map of the milk duct orifices which will aid in identifying them in nonlactating women. Another ancillary study is analyzing 500 ductograms to better delineate the anatomy of the ductal system. We also plan anatomic studies in cadavers to help demonstrate ductal anatomy.

Duct cannulation is currently being explored in another ancillary study in women who are scheduled for breast surgery. All are approached before surgery, requesting 15 minutes to be spent trying to locate the ductal orifices and cannulate them. We are working with several companies to develop small catheters, glide wires, and balloon dilators to aid in this work.

Finally we are exploring a variety of ductoscopes. We are currently approved by the FDA to study 20 additional women who are about to undergo mastectomy with either the Baxter angioscope (0.7mm) or a new scope being developed by Stortz.

We have submitted a grant to the Department of Defense to support these further studies.

We have obtained permission from the FDA to study an additional 20 patients with either the Japanese scope, the Baxter angioscope or, most recently, a new flexible scope from Stortz. They have approved all of the requests from HSPC Amendment C. It should be noted that all of the research to date has been part of Phase IA. Because of technical difficulties and numerous procedural delays we have not been able to proceed beyond this phase. In the revised protocol I have taken the liberty to name the washings study Phase IC and will continue to call the nipple discharge study (delayed until the FDA approves us to proceed to women with nipple discharge) Phase I B.

**Planned Approach (amendment C 8/95).** An hour prior to surgery, in the holding area, EMLA cream will be applied to the nipple of women who are scheduled for mastectomy. An occlusive dressing will then be applied. Anesthesia will be induced and the breast will be prepped. Mild suction will be applied to the nipple to try and elicit discharge. A dissecting microscope or loupes will be used to magnify the nipple. A map will be made of the orifices which have been identified. Starting with the most promising orifice (i.e., most amount of discharge, largest), we will attempt to cannulate it using either a standard set of metal dilators (galactography set by Manan), a very small glide wire (type used in angiography), a small balloon dilator (used in angiography). Only one of these techniques will be tried in any one orifice until we are able to determine which is the best technique. Once the duct has been cannulated and dilated to approximately 0.7-1.0 cm, an angiocatheter topped with a two way stop cock and burst adapter will be threaded into the duct. This will establish a closed system. Saline will be instilled through the two way stop cock at 0.1cc aliquots up to a total of 1.0cc. This will gradually dilate the ductal system itself. A ductoscope (either the Baxter 0.7mm angioscope or the Stortz 0.5mm scope) will then be threaded through the burst adapter into the duct. The duct will be visualized and its appearance will be documented by still pictures and video. Once the scope has been removed, the saline in the system will be aspirated to obtain washings. (Once this technique has been well established we will try to devise a technique for biopsy or brushings). Barium, gastrograffin or lymphazurin will be instilled into the duct which has been studied and the nipple will be sutured closed. This will serve as a marker for future histologic studies. This procedure will take approximately 15 minutes. If we are unable to complete the procedure within the 15 minute limit we will stop prematurely. Once the 15 minutes are up, the patient will proceed to have the mastectomy as planned. We will study the duct that has been cannulated as part of the mastectomy specimen.

## LIST OF REFERENCES

1. Dupont WD, Page DL. Risk factors for breast cancer in women with proliferative disease. *NEJM* 312:146, 1985.
2. Haagensen CD, Lane N, Lattes R, et al. Lobular neoplasia (so called lobular carcinoma in situ) of the breast. *Cancer* 42:737-769, 1978.
3. Rosen PP, Lieberman PH, Braun DW. Lobular carcinoma of the breast. *Am J Surg Path* 2:225-251, 1987.
4. Betsill WL, Rosen PP, Lieberman PH, et al. Intraductal carcinoma long term follow up after treatment by biopsy alone. *JAMA* 239:1863-1867, 1978.
5. Page DL, Dupont WD. Intraductal carcinoma of the breast. *Cancer* 49:751-758, 1982.
6. Simpson T, Thirlby RC, Dail DH. Surgical treatment of ductal carcinoma in situ of the breast. 10-20 year follow-up. *Arch of Surg* 127(4):468-472, 1992.
7. Holland R, Hendriks JH, Vebeek AL, Mravunac M, Schvurmans Steekhoven JH. Extent, distribution and mammographic/histological correlations of breast ductal carcinoma in situ. *Lancet* 335(8688): 519-522, 1990.
8. Fabian C, Kamel S, McKittrick R, Zalles C, Chin T, Kimler B. Prevalence of abnormal biomarkers in fine needle breast aspirates in a high risk population: Potential for use in risk prediction (meeting abstract). *Proc Ann Meet Am Assn Cancer Res* 34:A1556, 1993.
9. Wrensch MR, Petrakis NL, King EB, et al. Breast cancer incidence in women with abnormal cytology in nipple aspirates of breast fluid. *Am J Epidemiol* 1991;135:130-141.
10. Makita M, Sakamoto G, Akiyama F, Namba K, Sugano H, Kasumi F, Nishi M, Ikenga M. Duct endoscopy and endoscopic biopsy in the evaluation of nipple discharge. *Breast Cancer Res Treat* 1991;Aug: 179-187.
11. Love, S.M., Troyan, S., Mills, D., Webb, M.S., Sadowski, N., Harris, J.: Partial Mastectomy with Immediate Reconstruction and Radiation for Extensive Breast Cancers: A Pilot Study. Faulkner Breast Centre and the Joint Center for Radiation Therapy. Presented at 15th Annual San Antonio Breast Cancer Symposium, December 9-10, 1992.
12. Okazaki A, Okazaki M, Asaishi K, Satoh H, Wantanbe Y, Mikami T, Toda K, Okazaki Y, Nabeta K, Hirata K, Narimatsu E. Fiberoptic ductoscopy of the breast: A new diagnostic procedure for nipple discharge. *Jpn J Clin Oncol* 1991;21(3):188-193.

13. Sartorius OW, Morris PL, Benedict DL, Smith HS. Contrast ductography for recognition and localization of benign and malignant breast lesions: An improved technique. In Logan WW, ed. *Breast Carcinoma: The Radiologist's Expanded Role*. New York: Wiley, 1977, pp. 281-300.
14. Moll R, Franke WW, Schiller DL, Geiger B, Krepler R. The catalog of human cytokeratins: Patterns of expression in normal epithelia, tumors, and cultured cells. *Cell* 30:11-19, 1982.
15. Van de Vijver MJ, Peterse JL, Mooi WJ, Wisman P, Lomans J, Dalcsio O, Nusse R. Neu-protein overexpression in breast cancer. *New Engl J Med* 1988;319:1239-1245.
16. Shi, S-R, Key ME, Kalra KL. Antigen retrieval in formalin-fixed, paraffin-embedded tissues: An enhancement method for immunohistochemical staining based on microwave oven heating of tissue sections. *J Histochem Cytochem* 1991;39: 741-748.
17. Slamon DJ, et al. Human breast cancer: Correlation of relapse and survival with amplification. *Science* 1987;235:177-182.
18. Weinberg, R. Tumor suppressor genes. *Science* 1991;254:1143.
19. Cossman J, Schlegel R. p53 in the diagnosis of human neoplasia. *J Natl Cancer Inst* 1991; 18: 980-981.
20. Visakorpi T, Kallioniemi OP, Koivula T, Harvey J, Isola J. Expression of epidermal growth factor receptor and ERBB2 (Her-2/neu) oncoprotein in prostatic carcinomas. *Modern Pathology* 1992;5:643-648.
21. Lennington WJ, Jensen RA, Dalton LW, Page DL. Ductal carcinoma in situ of the breast: Heterogeneity of individual lesion. *Cancer* 1994;73:118-124.
22. Noguchi S, Motomura K, Inaji, H, Imaoka S, Koyama H. Clinal analysis of predominately intraductal carcinoma and precancerous lesions of the breast by means of polymerase chain reaction. *Cancer Res* 1994;54:1849-1853.
23. Ohtake T, Abe R, Kimijima I, Fukushima T, Tsuchiya A, Hoshi K, Wakasa H. Intraductal extension of primary invasive breast carcinoma treated by breast conservative surgery. *Cancer* 1995;76:32-45.

## List of Appendices

Table 1

Schematic I

Figures

1A: Breast duct with DCIS

1B: Cannulas in duct orifices

2A: Exfoliating ductal epithelial cells

2B: Ductal-lobular inflammatory reflex

2C: Several ductal systems intertwined

3A: Exfoliated DCIS cells

3B: DNA ploidy histogram

FDA IDE

UCLA Human Subjects

Table 1  
BREAST DUCTOSCOPY

Patient #	# Ducts identified	# Ducts cannulated	# Ducts washed	Cytology	# Ducts scoped
0001 CW	1 middle	1	1		2 bifurcations
0002 AP	1 inferior 1 superior-lateral	2	inf: no return sup: good return	atypical ductal cells	superior-lateral
0003 LY	1	1	1	ductal ca	1 bifurcation
0004 LP	no ducts; ? sebaceous gland	1	1 cc no return	rare benign ductal epithelium	0
0005 EM	1 sup-med 1 inf-lateral	0	0	0	0
0006 JG	1 lateral-sup	1	1	atypical ductal cells	1
0007 NC	1 lateral 1 sup-lateral 1 medial	2 medial was not cannulated	2 medial was not washed		lateral duct scoped
0008 CT	2	2	1	scant cellularity	under saline not well visualized
0009 BA	1 lateral	1	1	atypical ductal cells	Baxter scope good visualization


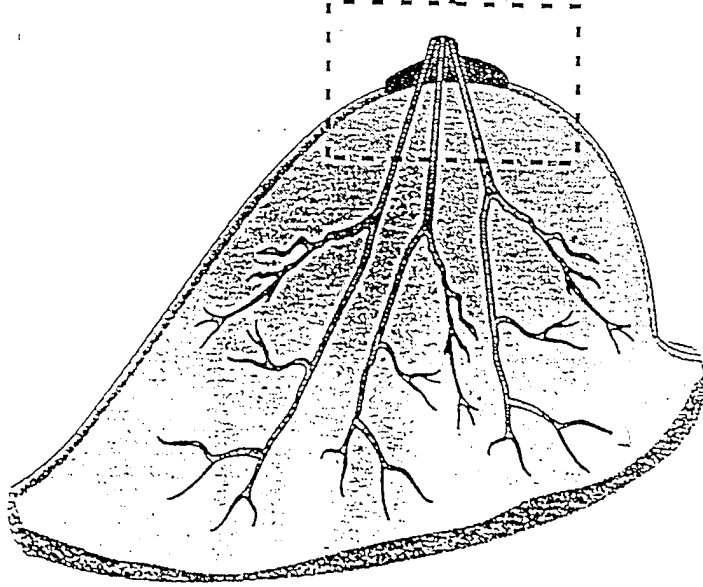
# Ductoscoped Mastectomies: Pathological Analysis

Administer Dye

to Ducts

or

Serially Section



Duct



Duct Cannulated  
w/Ductoscope



DCIS

ADDENDA (Illustrations)

Figure 1A.  
Duct with DCIS  
marked by barium,  
adjacent normal  
ducts

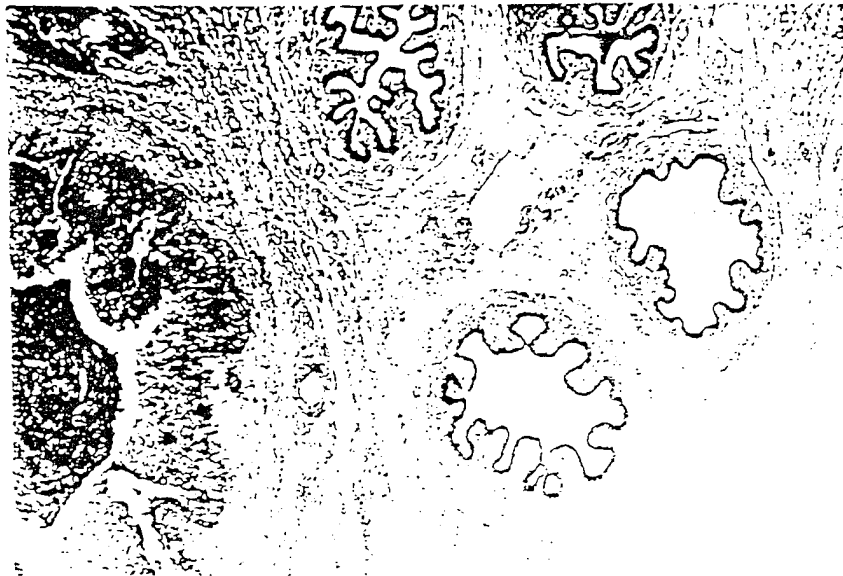


Figure 1B.  
Cannulas in  
duct orifices




Figure 2A.  
Exfoliating ductal  
epithelial cells



Figure 2B.  
Ductal-lobular  
inflammatory reflex

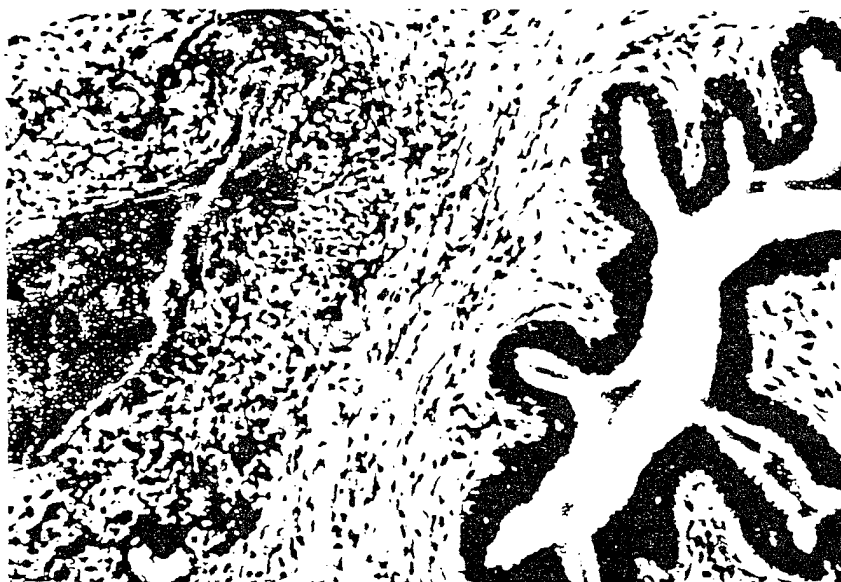

Figure 2C.  
Several ductal  
systems intertwined

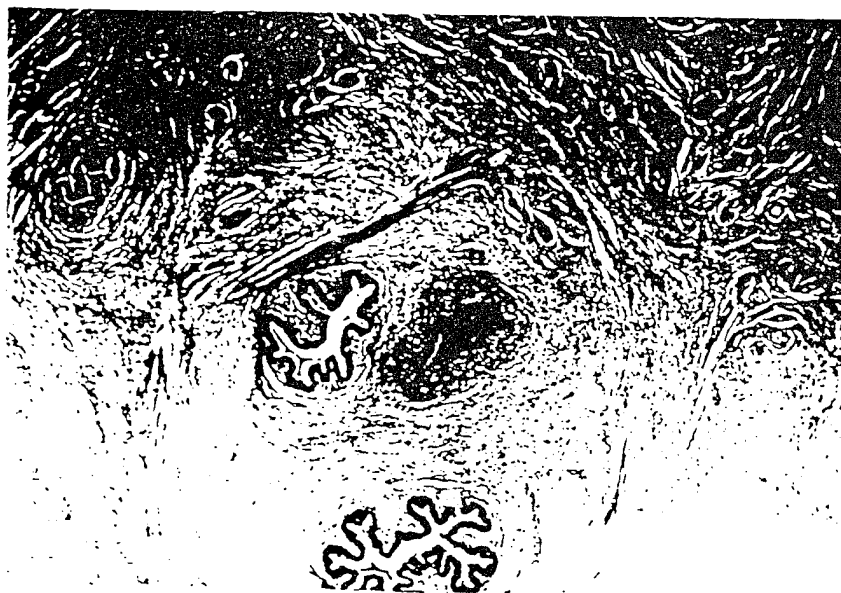


Figure 3A.,  
Exfoliated  
DCIS cells

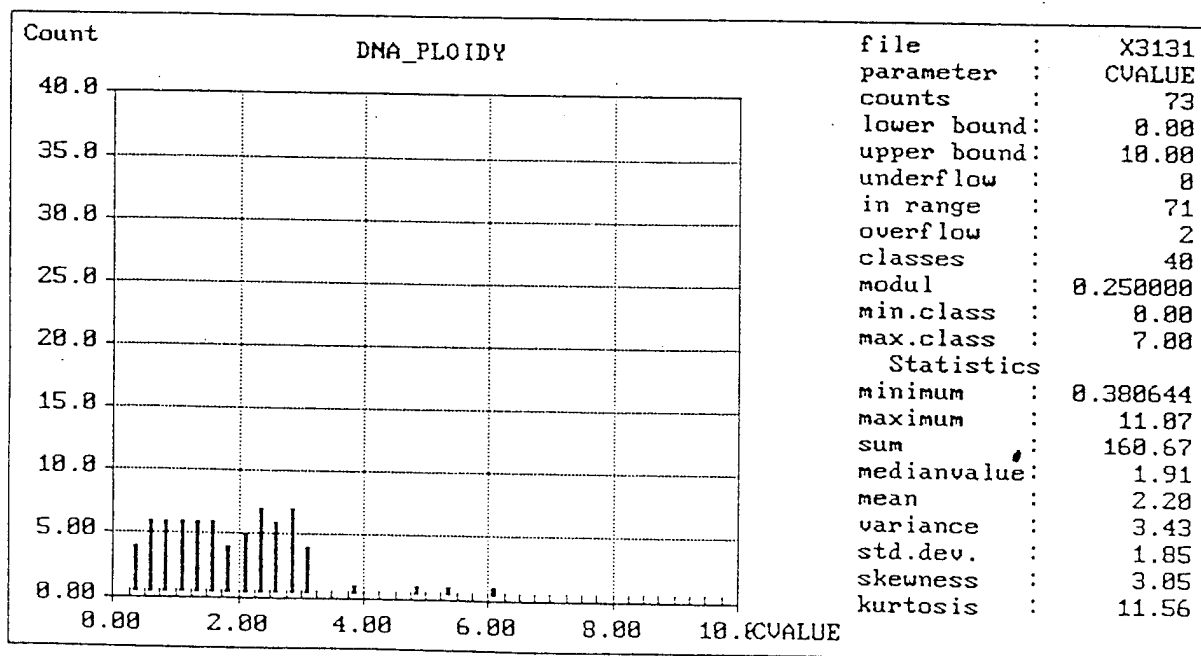


Figure 3B. DNA Ploidy Histogram



DEPARTMENT OF HEALTH & HUMAN SERVICES

Public Health Service

Food and Drug Administration  
1390 Piccard Drive  
Rockville MD 20850

JUN 10

JUN 15 1994

Susan M. Love, M.D.  
Director  
UCLA Breast Center  
Suite 510  
200 UCLA Medical Plaza  
Los Angeles, California 90024-7028

Re: G9400002/A1  
Breast Duct Endoscope  
Dated: March 21, 1994  
Received: March 31, 1994

Dear Dr. Love:

The Food and Drug Administration (FDA) has received your certification of final institutional review board (IRB) approval. You may begin your feasibility study at UCLA Medical Center, Los Angeles, California. Your investigation is limited to 1 institution and 5 subjects who will undergo an immediate post-procedure mastectomy. However, your application remains conditionally approved because your supplement does not address the deficiencies cited in our April 29, 1994, letter.

This approval is being granted on the condition that, within 45 days from the date of this letter, you submit information correcting the deficiencies cited in our April 29, 1994, letter. This information should be identified as an IDE supplement referencing the IDE number above, and must be submitted in triplicate to:

IDE Document Mail Center (HFZ-401)  
Center for Devices and Radiological Health  
Food and Drug Administration  
1390 Piccard Drive  
Rockville, Maryland 20850

If you do not provide this information within 45 days from the date of this letter, we may take steps to propose withdrawal of approval of your IDE application.

If you have any questions, please contact Mr. Colin M. Pollard at (301) 594-1180.

Sincerely yours,

Lillian Yin, Ph.D.  
Director, Division of Reproductive,  
Abdominal, Ear, Nose and Throat,  
and Radiological Devices  
Office of Device Evaluation  
Center for Devices and  
Radiological Health



DEPARTMENT OF HEALTH & HUMAN SERVICES

Public Health Service

AUG 8 1995

Food and Drug Administration  
9200 Corporate Boulevard  
Rockville MD 20850

AUG 15 1995

Susan M. Love, M.D.  
Director  
UCLA Breast Center  
Suite 510  
200 UCLA Medical Plaza  
Los Angeles, California 90095-7028

Re: G940002/S11  
Breast Ductoscope  
Dated: July 24, 1995  
Received: August 2, 1995

Dear Dr. Love:

The Food and Drug Administration (FDA) has reviewed the supplement to your investigational device exemptions (IDE) application proposing to begin using the Karl Storz Miniscope (Model 11552A) in your breast duct endoscopy study. Your supplement is approved, and you may implement that change at the institution enrolled in your investigation. Your investigation is limited to 1 institution and 29 subjects who will undergo an immediate post-procedure mastectomy.

We would like to point out that FDA approval of your supplement does not imply that this investigation will develop sufficient safety and effectiveness data to assure a determination of substantial equivalence of a premarket notification (510(k)) submission or sufficient safety or effectiveness data to assure FDA approval of a premarket approval (PMA) application for this device. You may obtain the guideline for the preparation of a PMA application, entitled "Premarket Approval (PMA) Manual," from the Division of Small Manufacturers Assistance at their toll free number (800) 638-2041 or (301) 443-6597.

If you have any questions, please contact Donna-Bea Tillman, Ph.D at (301) 594-1180.

Sincerely yours,

Lillian Yin, Ph.D.  
Director, Division of Reproductive,  
Abdominal, Ear, Nose and Throat,  
and Radiological Devices  
Office of Device Evaluation  
Center for Devices and  
Radiological Health

jc

UNIVERSITY OF CALIFORNIA, LOS ANGELES

HUMAN SUBJECT PROTECTION COMMITTEE

REVISED Approval Notice

HSPC #93-09-351-2

Committee # 1

PRINCIPAL INVESTIGATOR OF MAIN GRANT Susan M. Love, M.D.

TITLE OF MAIN GRANT same as project

DEPARTMENT Surgery DIVISION General Surgery

PRINCIPAL INVESTIGATOR OF PROJECT Susan M. Love, M.D.

TITLE OF PROJECT Breast Duct Endoscopy Study as a Means of Obtaining & Studying Pre-cancerous Ductal Epithelial Cells

DEPARTMENT Surgery DIVISION General Surgery

FUNDING AGENCY US Army CONTRACT/GRANT #AIBS #942

DATES FOR WHICH REVIEWED: FROM December 28, 1994 TO December 27, 1995

DATE FOR RE-SUBMISSION October 27, 1995 DATE APPROVED December 28, 1994

DATE REVISED: May 19, 1995

The Human Subject Protection Committee has reviewed the proposed use of human subjects in the project identified above and has determined that:

The rights and welfare of the subjects are adequately protected; the risks are outweighed by potential benefits; the informed consent of subjects will be obtained by methods that are adequate and appropriate. (WRITTEN X; ORAL       ; WAIVED       .)


Research involves use of: Minors        Fetuses        Pregnant Women       

Elderly X Mentally Retarded        Mentally Disabled       

The Committee has recommended and/or determined that significant changes have been made in the approved project over that submitted to the granting agency: yes no. If "yes", it is the principal investigator's responsibility to forward the revised material to the granting agency through the Office of Contract and Grant Administration.

CODICIL:

SIGNATURE:

  
Chairman, Human Subject Protection Committee

X Full Committee Review  
       Expedited Review

Original to: Principal Investigator


cc to: Director, Office of Contract and Grant Administration

See reverse

Revlon/UCLA BREAST CENTER  
200 Medical Plaza  
Suite 510 702824  
x49523

August 24, 1995

TO: Donald Tierney, M.D.  
Chair, Human Subject Protection Committee  
1355 PVUB 169407

FROM: Susan M. Love, M.D.   
Director, Revlon/UCLA Breast Center

RE: HSPC #93-09-351-2C, "Breast Duct Endoscopy Study as a Means of Obtaining and Studying Precancerous Ductal Epithelial Cells"

---

Thank you for your recent correspondence regarding this project. Since the submission we have received approval from the FDA to proceed with 20 more cases using the approach outlined in Amendment C (copy of letter attached).

A.

1. The HSPC number has been included on the consent forms
2. The modifications have been included.
3. The first several paragraphs have been changed to define the words outlined. It should be pointed out that these women have already signed an informed consent for a mastectomy and general anesthesia and are very aware of what is involved in these procedures. I have dropped the paragraph regarding nitric oxide as we have decided to use only saline for now.
4. We have eliminated the sentence regarding the risks of general anesthesia.
5. This sentence has been added to paragraph one.

B.

1. A new protocol is included. There are no outstanding amendments. The correspondence that you are referring to regards the use of barium and/or gastrograffin in the original seven patients.
2. We have decided not to try nitric oxide at this time.
3. We have decided not to try nitric oxide at this time.
4. This question is not clear. We have examined the mastectomy specimens following this procedure in the first seven cases and found some inflammatory reaction around the duct which has been cannulated. In two cases there was a minor disruption of the duct identified. We are

using women who are about to have a mastectomy so that we will be able to investigate the effect of the procedure on the surrounding tissues in detail. Since this is a local procedure we do not anticipate there will be any systemic effects.

5. In the original protocol we assured the committee that patient/subjects would not be responsible for the costs of the operating room, anesthesia/anesthesiology for the 15 minutes involved in the research. A letter confirming this was included at that time.

6. It is our intent to use 15 minutes after the induction of anesthesia for this procedure. If the procedure cannot be performed in that time it is aborted. We do not feel we can justify adding more than 15 minutes to a patient's 90 minute operation.

7. The EMLA cream and Lymphazurin will be paid for from a DOD grant supporting this research.

## BREAST DUCT ENDOSCOPY PROTOCOL

(Breast Duct Endoscopy Study as a Means of Obtaining and Studying Precancerous Ductal Epithelial Cells)

HSPC #93-09-351-2B

### **HISTORY OF RESEARCH PROJECT SINCE ITS ORIGINAL APPROVAL IN 1993**

After it was determined by the UCLA HSPC that this research posed a potential risk to patients we were required to obtain an IDE from the FDA. We were initially approved by the FDA (IDE # G94002/S2) to use the Japanese scope in five women who were about to undergo mastectomy. Although we were able to visualize the ducts in several of the patients, it was obvious that we needed some revisions in the protocol. We had found that marking the duct which had been scoped with methylene blue prior to the mastectomy was inadequate. The methylene blue did not persist fixation with formaldehyde and was not visible on the subsequent slides. We tried two other inert commonly used biological substances: gastrograffin and barium. Both proved to be better markers. We subsequently asked the FDA and the HSPC (**HSPC Amendment B**) for permission to use gastrograffin and/or barium as a marker in breasts to be removed by mastectomy. This request is again included in **HSPC Amendment C**.

We then requested and received permission from the FDA to attempt breast duct endoscopy in two additional patients using either the Japanese scope or a Baxter angioscope. This was obtained and the cases performed. The Baxter angioscope using saline dilatation of the duct proved to have superior optics as compared to the Japanese scope. Barium was used in these cases to mark the duct.

During much of this time we were waiting for various approvals to proceed with the endoscope. It occurred to us that we could use this time to practice finding the ducts and cannulating them to obtain washings without actually using the endoscopes. We asked for **Amendment A**. This allowed us to approach every woman who was going to have a breast operation under anesthesia and ask her if we could spend ten additional minutes trying to identify her ductal orifices in the nipple. If one was identified we would cannulate it and instill saline (0.2cc) in an attempt to obtain washings. We have used a galactography kit which is commercially available to dilate and cannulate the ducts (Manan Taber-Rothschild dilators 000000 thru 0). This aspect of the study has proceeded and we have enrolled 12 women having breast sparing operations and 5 who were undergoing mastectomies.

As a result of this initial work we have asked for several revisions to our original protocol **Amendment C**. We have obtained permission from the FDA to study an additional 20 patients with either the Japanese scope, the Baxter angioscope or most recently a new flexible scope from Storz. They have approved all of the requests from Amendment C. It should be noted that all of the research to date has been part of Phase IA. Because of technical difficulties and numerous procedural delays we have not been able to proceed beyond this phase. In the revised protocol I have taken the liberty to name the washings study Phase IC and will continue to call the nipple discharge study (delayed until the FDA approves us to proceed to women with nipple discharge) Phase I B.

**BREAST DUCT ENDOSCOPY PROTOCOL****HSPC #93-09-351-2B****Revised August 1995 with amendments A-C**

**Title:** "Breast Duct Endoscopy Study as a Means of Obtaining and Studying Precancerous Ductal Epithelial Cells

**IDE #:** G94002

**Principal Investigator:**

Susan M Love MD

200 Medical Plaza, Suite 510

Los Angeles, CA 90095-7028

phone: 310-794-9523

FAX 310-794-9461

**Medical Monitor:**

Frederick Eilber MD

UCLA Medical Center

10833 LeConte Ave

54-104 CHS

Los Angeles, Ca 90024

phone: 310-825-7086

FAX; 310-825-7575

August 1995

HSPC# 93-09-351-2

## RESEARCH QUESTIONS

1. Whether a technique can be developed to identify nipple duct orifices and cannulate breast ducts.
2. Whether breast duct endoscopy can be used to explore breast ducts and obtain tissue from them.
3. Whether breast duct washings can be analyzed for intermediate markers.

## INTRODUCTION

Most breast cancers are thought to arise in the ductal lobular unit of the breast. Initial hyperplastic lesions progress to intraductal carcinoma in situ and then go on to invasive ductal cancer. As new molecular genetic markers are being identified, there is an increasing need to have access to early intraductal changes in order to identify the intermediate markers for disease. Currently, most researchers are exploring a variety of techniques such as repetitive open biosies, repetitive fine needle aspirates, and/or nipple aspirates to look for early changes. These techniques assume that the malignant changes of breast cancer are a field defect, an assumption that has not actually been proven. A better approach would be to actually biopsy the lining of the duct through an intraductal technique.

Makito (and his Japanese colleagues) described the use of a ductoscope to examine women with nipple discharge. They used a rigid 1.25 mm scope to identify intraductal papillomas. On the basis of his work, we did a pilot study in Boston, to determine if this technique could be applied to the non-discharging duct. Women who were scheduled to undergo a mastectomy were approached and asked if they would allow us to try the ductoscope for 20 minutes after general anesthesia had been obtained and prior to their surgery. All the women approached agreed. In nine of the ten women, we were able to cannulate a duct and visualize the duct lining. After the procedure, the duct we had visualized was examined microscopically. We noted that the ductal lining had been eroded in the majority of cases, probably due to the rigid scope and its large diameter. Other problems included difficulty in dealing with ductal secretions. Although the pilot demonstrated to us that it was indeed possible to cannulate non-discharging ducts, it was also obvious that the rigid scope was not ideal. A second Japanese group then described the use of a 0.4 mm flexible scope for nipple discharge. The smaller flexible scope should allow cannulation of the ducts with less trauma.

The original proposal had two phases. The first phase was to repeat the pilot study with flexible 0.5mm and 0.7mm scopes, gaining facility with their use both for visulaizing the duct and obtaining tissue or cells from it. We had then planned to expand the pilot, as well, to women who have nipple discharge (a group with which it has been successfully used in Japan). Once we had gained facility in the use of the scope and could reliably cannulate a duct at will and obtain tissue or cells (estimated 20 cases minimum), we would go on to phase two. Phase two will address the use of the scope in women who are likely to have DCIS.

## POPULATION

### **PHASE I-A: DUCTOSCOPY STUDY**

#### **INCLUSION CRITERIA**

- Women  $\geq 18$  years of age, who are scheduled to have a mastectomy under general anesthesia, and who do not have exclusions as listed below

#### **EXCLUSION CRITERIA**

- Women  $< 18$  years of age
- Women with a history of or who currently have silicone implants
- Women with a diagnosis of breast cancer for whom breast sparing surgery will be performed
- Women, who for medical reasons, cannot tolerate an additional 15 minutes of general anesthesia

### **PHASE I-B: NIPPLE DISCHARGE STUDY**

#### **INCLUSION CRITERIA**

- Women with nipple discharge who do not have exclusions listed below

#### **EXCLUSION CRITERIA**

- Women  $< 18$  years of age
- Women who have no evidence of nipple discharge
- Women with a history of or who currently have silicone implants

### **PHASE I-C: WASHINGS STUDY**

#### **INCLUSION CRITERIA**

- Women who are  $\geq 18$  years of age
- Women who are having breast surgery under anesthesia

#### **EXCLUSION CRITERIA**

- Women  $< 18$  years of age
- Women with a history of or who currently have silicone implants
- Women, who for medical reasons, cannot tolerate an additional 15 minutes of anesthesia

### **PHASE II: DCIS STUDY**

#### **INCLUSION CRITERIA**

- Women  $\geq 18$  years of age, with microcalcifications seen on mammogram who have been recommended for but who have not yet undergone biopsy are eligible to participate provided they do not have exclusions as listed below

#### **EXCLUSION CRITERIA**

- Women  $< 18$  years of age
- Women who have already undergone biopsy for mammographic evidence of microcalcifications
- Women with a history of or who currently have silicone implants.

August 1995

HSPC# 93-09-351-2

## PROCEDURE

### **PHASE I-A: DUCTOSCOPY STUDY**

An hour prior to surgery, in the holding area, EMLA cream will be applied to the nipple of women who are scheduled for mastectomy. An occlusive dressing will then be applied. Anesthesia will be induced and the breast will be prepped. Mild suction will be applied to the nipple to try and elicit discharge. A dissecting microscope or loupes will be used to magnify the nipple. A map will be made of the orifices which have been identified. Starting with the most promising orifice (i.e., most amount of discharge, largest) we will attempt to cannulate it using either a standard set of metal dilators (galactography set by Mahan), a very small glide wire (type used in angiography), a small balloon dilator (used in angiography). Only one of these techniques will be tried in any one orifice until we are able to determine the best technique. Once the duct has been cannulated and dilated to approximately 0.7-1.0 cm, an angiocatheter topped with a two way stop cock and burst adapter will be threaded into the duct. This will establish a closed system. Saline will be instilled through the two way stop cock at 0.1cc aliquots up to a total of 1.0cc. This will gradually dilate the ductal system itself. A ductoscope (either the Baxter 0.7mm angioscope or the Stortz 0.5mm scope) will then be threaded through the burst adapter into the duct. The duct will be visualized and its appearance documented by still pictures and video. Once the scope has been removed, the saline in the system will be aspirated to obtain washings. (Once this technique has been well established, we will try to devise a technique for biopsy or brushings). Barium, gastrograffin or lymphazurin will be instilled into the duct which has been studied and the nipple will be sutured closed. This will serve as a marker for future histologic studies. This procedure will take approximately 15 minutes. If we are unable to complete the procedure within the 15 minute limit, we will stop prematurely. Once the 15 minutes are up, the patient will proceed to have the mastectomy as planned. We will study the duct that has been cannulated as part of the mastectomy specimen.

### **PHASE I-B: NIPPLE DISCHARGE**

This portion of the phase I study will not be started until we have permission from the FDA to move beyond women who are undergoing mastectomy to women with nipple discharge. (We anticipate that this will be after the next 20 patients). In this instance we will study women with spontaneous nipple discharge. We will apply EMLA cream to their nipple one hour prior to starting the procedure. An occlusive dressing will be applied. This will numb the nipple without distorting it. Mild suction will be applied to the nipple to try and elicit discharge. A dissecting microscope or loupes will be used to magnify the nipple. A map will be made of the orifices which have been identified. Once we have identified the discharging orifice we will attempt to cannulate it using the best technique which has been determined in phase I A. Once the duct has been cannulated and dilated to approximately 0.7-1.0 cm, an angiocatheter topped with a two way stop cock and burst adapter will be threaded into the duct. This will establish a closed system. Saline will be instilled through the two way stop cock at 0.1cc aliquots up to a total of 1.0cc. This will gradually dilate the ductal system itself. A ductoscope (either the Baxter 0.7mm angioscope or the Stortz 0.5mm scope) will then be threaded through the burst adapter into the duct. The duct will be visualized and its appearance will be documented by still pictures and video. Once the scope has been removed the

August 1995

HSPC# 93-09-351-2

saline in the system will be aspirated to obtain washings. (Once this technique has been well established we will try to devise a technique for biopsy or brushings). If at any time the patient complains of undue pain, the procedure will be aborted. An attempt will be made to identify the source of the discharge and obtain tissue from it, thus reproducing the Japanese work.

### **PHASE I-C: WASHINGS**

This portion of phase I will be done simultaneously with phase I-A. All women who are scheduled to have breast surgery who agree to participate will be approached in the holding area one hour prior to surgery and have EMLA applied to their breast with an occlusive dressing applied. (An alternative will be to give the patient some EMLA to apply at home prior to coming in for surgery). Once they have been induced with the appropriate anesthetic their nipple will be prepped. Mild suction will be applied to the nipple to try and elicit discharge. A dissecting microscope or loupes will be used to magnify the nipple. A map will be made of the orifices which have been identified. Starting with the most promising (i.e., most amount of discharge, largest orifice) orifice we will attempt to cannulate it using either a standard set of metal dilators (galactography set by Mahan), a very small glide wire (type used in angiography), a small balloon dilator (used in angiography). Only one of these techniques will be tried in any one orifice until we are able to determine the best technique. A single lumen catheter or a double lumen one when it becomes available will be threaded into the duct and up to 1.0 cc of saline will be instilled into the duct in 0.2cc aliquots. In the single lumen system the catheter will be removed from the duct and the saline gently squeezed from the breast and sucked up with a capillary tube. We hope, however, to devise a double lumen closed system which will allow us to instill saline distally in the duct and suck it out more proximally. This will eliminate the contamination which occurs once the saline spills out onto the nipple. Once the washings have been obtained, we will remove the catheter. We will take 15 minutes to do this procedure. If there is enough time we will attempt to cannulate a second and third duct. Once the 15 minutes are over we will stop the procedure and proceed with the planned surgery. All washings will be analyzed for cytology and intermediate markers. Correlation will be attempted with the pathology found in the breast. In those women who are undergoing mastectomy we will instill barium, gastrograffin or lymphazurin into the duct which has been studied and the nipple will be sutured closed. This will serve as a marker for future histologic studies.

### **PHASE II: MICROCALCIFICATIONS**

The phase II study will involve women with microcalcifications seen on mammogram. Prior to biopsy while in the radiology suite, an attempt will be made to cannulate the duct which contains the calcifications. This will be done using the procedure we have developed in phase I; for example using EMLA, suction, glide wires etc. Washings will be done. A ductogram will be done to demonstrate that the duct is actually the one with the calcifications. The duct will then be washed out and the ductoscope will be threaded into the duct to attempt to visualize the pathology and obtain biopsies. At the end of the procedure, or at another time, the calcifications will be localized and removed. The cytology, biopsy material, and excision will be correlated and analyzed for intermediate markers.

August 1995

HSPC# 93-09-351-2

## **POTENTIAL RISKS AND POTENTIAL BENEFITS**

### **PHASE I-A DUCTOSCOPY**

There is no risk to the patient other than the fact that she will undergo 15 additional minutes of general anesthesia. Since the breast which is to be studied is to be removed, any potential damage done to the ductal system will be irrelevant. The use of contrast as duct markers poses no risk as the participants will undergo immediate mastectomy. In addition, the contrast materials used have been commonly used in patients in intact and perforated organs without consequence. Benefit for the patient is that she will advance our knowledge of breast cancer and hopefully allow less invasive procedures in the future.

### **PHASE I-B NIPPLE DISCHARGE**

In this group of women with nipple discharge, the risk is that the patient may experience some discomfort. The EMLA applied to the nipple has had no major side effects other than a slight irritation to the skin to which it has been applied. The benefit is that we may be able to diagnose a breast lesion without surgery. The patient will receive no information from this study.

### **PHASE I-C WASHINGS**

In this group of women there is minimal risk to the patient. The EMLA applied to the nipple has had no major side effects other than a slight irritation to the skin to which it has been applied. If a duct were perforated, it would cause no immediate consequence. It is remotely possible that a perforated duct would scar and limit breast feeding from that ductal system. Since there are six to nine ductal systems per breast this would not decrease the patient's ability to breast feed in general. Benefit for the patient is that she will advance our knowledge of breast cancer and perhaps allow us to develop a means to prevent this disease. The patients will get no information from this study.

### **PHASE II MICROCALCIFICATIONS**

In this group of women, the risk is that the patient may experience some discomfort. The EMLA applied to the nipple has had no major side effects other than a slight irritation to the skin to which it has been applied. The benefit is to help develop a technique which will replace surgery in the treatment of premalignant disease. The patients will receive no information from this study.

## **CONFIDENTIALITY**

This is considered a pilot study. Any information obtained on a patient and any tissue or cells which are obtained will remain confidential.