

DTIC
ELECTE
S F D
APR 08 1994

CASE REPORT AD-A277 948



94-10593

Superior Mesenteric Artery Syndrome in a Burn Patient*

ELIZABETH A. MILNER, RD; WILLIAM G. CIOFFI, MD; WILLIAM F. McMANUS, MD; AND BASIL A. PRUITT, JR, MD

The US Army Institute of Surgical Research, Ft Sam Houston, Texas

Spj

ABSTRACT: Weight loss resulting from the hypermetabolic response to burn injury is not unusual and is often unavoidable. The loss of retroperitoneal fat has been postulated as a major factor in the cause of the uncommon complication of superior mesenteric artery syndrome. This syndrome is frequently treated nonoperatively with aggressive nutrition support. Nasojejunal feeding past the point of obstruction should be considered as the primary method of nutrition support. Alternatively, total parenteral nutrition or a combination of enteral and parenteral feeding may be necessary to meet nutritional needs until the duodenal obstruction resolves. This case study describes the nutrition management of a burn patient who developed superior mesenteric artery syndrome.

his estimated caloric and protein requirements by PBD 5. His initial estimated caloric needs were determined to be approximately 2800 kcal on the basis of this institute's equation for predicting energy requirements of spontaneously breathing, nonintubated, thermally injured patients.¹ Estimated protein requirements were determined to be approximately 120 g of protein on the basis of 2 g/kg with a nonprotein calorie to nitrogen ratio of 120:1.

Results from indirect calorimetry studies with use of a canopy system (Deltatrac, SensorMedics, Anaheim, CA) are summarized in Table 1. Peak requirements occurred on PBD 19. The table depicts resting energy expenditure, and we commonly use a 25% activity factor to estimate total caloric requirements.

A 35-year-old Hispanic man sustained a 49% total body surface area, 37% full-thickness thermal burn. He did not have an inhalation injury and his past medical history was unremarkable. He had a slender build, with a preburn weight of 61 kg and height of 170 cm (body surface area = 1.72 m²).

Because we have shown that visceral protein levels do not accurately predict nitrogen balance, we do not routinely monitor serum proteins in our patient population.² We perform nitrogen balance studies to assess the adequacy of nutrition support. Nitrogen balance studies in this patient are summarized in Table 2. This illustrates the nitrogen balance results on the basis of both urinary urea nitrogen (UUN) excretion and total urinary nitrogen excretion. The balance calculated from UUN was estimated by multiplying the UUN by 1.25 to account for the nonurea losses.³ Overall, there was a general trend of decreasing negative balance with time and a zero or slightly positive balance by the 36th postinjury day.

After an uncomplicated fluid resuscitation, a feeding tube was placed transnasally past the ligament of Treitz into the proximal jejunum. Enteral feedings were initiated with an isotonic polymeric formula (Osmolite HN, Ross Laboratories, Columbus, OH) on postburn day (PBD) 3, and the patient was receiving

A graphic summary of the actual caloric intake of this patient versus his measured needs is depicted in Figure 1. We were successful in meeting his measured needs. Although the patient consistently met at least 100% of his estimated caloric needs, his weight reached a nadir of 49 kg on PBD 45, which was approximately 20% below his preburn weight. A summary of his weight course is shown in Figure 2.

Correspondence: Elizabeth A. Milner, RD, US Army War College, Army Physical Fitness Research Institute, PO Box 355, Carlisle Barracks, PA 17013.

Reprints: Jan Mason, U.S. Army Institute of Surgical Research, Ft. Sam Houston, TX 78234

*The opinions or assertions contained herein are the private views of the authors and are not to be construed as official or reflecting the view of the Department of the Army or the Department of Defense.

0884-5336/93/0806-0264\$03.00/0

NUTRITION IN CLINICAL PRACTICE 8:264-266, December 1993

Copyright © 1993 American Society for Parenteral and Enteral Nutrition

On PBD 33, the patient began episodic vomiting shortly after oral intake. He received nothing by mouth while his enteral feedings continued. On PBD 39, a barium swallow demonstrated a duodenal obstruction

This document has been approved for public release and sale; its distribution is unlimited.

Table 1. Indirect calorimetry studies

PBD	REE
8	2444
19	2790
26	2690
36	2490
46	2390

PBD, postburn day; REE, resting energy expenditure.

Table 2. Nitrogen balance

PBD	UUN (g/d)	TUN (g/d)	NBAL (UUN)	NBAL (TUN)
20	13.9	17.4	-5.4	-5.4
23	12.3	14.9	-3.4	-2.9
36	13.0	15.0	0	1

PBD, postburn day; UUN, urinary urea nitrogen; TUN, total urea nitrogen; NBAL, nitrogen balance.

characteristic of the superior mesenteric artery syndrome (Fig 3). By this time, the patient had undergone three excision and grafting procedures and his burn wounds were closed.

This complication was treated conservatively by giving the patient nothing by mouth and continuing enteral feedings by nasojejunal tube. Another barium swallow obtained on PBD 52 indicated that the duodenal obstruction had resolved. At this time, oral liquids were slowly reinitiated. Positioning the patient on his left side after meals and offering small, frequent feedings increased his tolerance of oral feedings. The patient was gradually switched from enteral feedings to an oral diet, and the feeding tube was eventually removed. At the time of discharge, his weight of 53 kg was 15% below his preburn weight. His measured resting energy expenditure at discharge was 1930 kcal, which was approximately 28% above his estimated basal energy expenditure.

DISCUSSION OF SYNDROME

Characteristic symptoms of the superior mesenteric artery syndrome include postprandial epigastric pain, feelings of fullness, and voluminous vomiting shortly after the ingestion of food. The symptoms may first appear intermittently and gradually increase in frequency and severity. Symptoms are often relieved in the knee-chest or left lateral decubitus position. Radiologic studies are necessary to confirm the diagnosis.⁴ Figure 3 shows a barium study that is diagnostic of superior mesenteric artery syndrome. A dilated proximal duodenum is present with a sharp cutoff at the junction of the third and fourth portion of the duodenum. On fluoroscopy, an apparently antiperistaltic flow of barium proximal to the obstruction producing back and forth movements is often seen. In many cases,

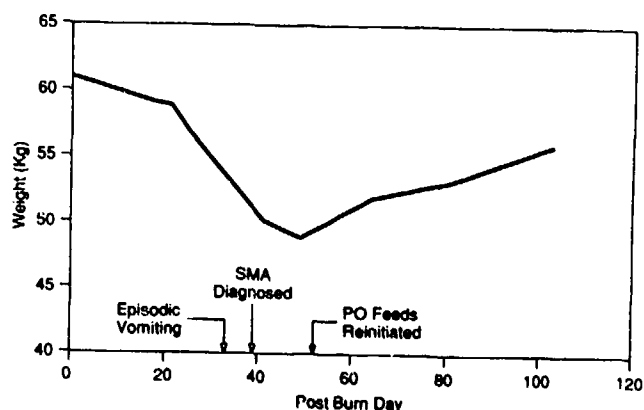


Figure 1. Actual caloric intake of the patient vs his measured needs. SMA, superior mesenteric artery syndrome; PO, oral.

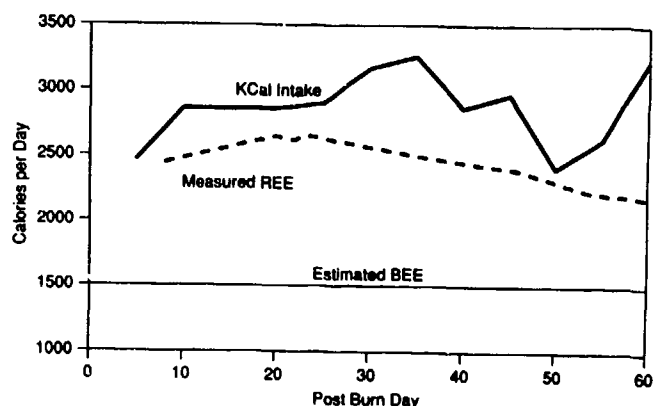


Figure 2. Summary of the patient's weight course. REE, resting energy expenditure; BEE, basal energy expenditure.

during fluoroscopic examination the patient can be positioned, usually on the left lateral side, so that some barium can pass beyond this "point of obstruction."⁵

An anatomical view of the normal duodenum and the superior mesenteric artery located anteriorly is depicted in Figure 4. The superior mesenteric artery syndrome is caused by compression of the duodenum between the superior mesenteric artery anteriorly and the aorta and vertebrae posteriorly. The angle formed by the aorta and superior mesenteric artery becomes more acute with the patient in a supine or upright position. Narrowing of this angle has been attributed to acute weight loss with loss of mesenteric and retroperitoneal fat, weak abdominal musculature, and prolonged bed rest in a supine position.⁶⁻⁹

Structural abnormalities including lordosis, tight-fitting abdominal appliances, retroperitoneal surgery, and/or weight loss with a decrease in adipose tissue can contribute to the superior mesenteric artery syndrome.⁵



Figure 3. Barium study showing the duodenal dilatation and cutoff at the third portion of the duodenum (arrow), indicative of the superior mesenteric artery syndrome.

In some cases, total parenteral nutrition is used as an adjunct to supplement or as the sole source of nutrition to promote weight gain if the patient cannot be fed past the point of obstruction. If surgical intervention is required, a duodenojejunostomy is the preferred procedure, but in certain cases a gastrojejunostomy may be necessary.⁶

In the burn population, severe weight loss and prolonged bed rest appear to be the main factors that contribute to superior mesenteric artery syndrome. It is not a common complication, occurring in less than 1% of severely burned patients.⁶ In the patient presented, excessive weight loss seemed to be the primary cause, even though the patient's measured needs plus 25% were consistently met by aggressive nutrition support. It is uncertain whether inefficient nutrient use, underestimation of the patient's activity factor, or

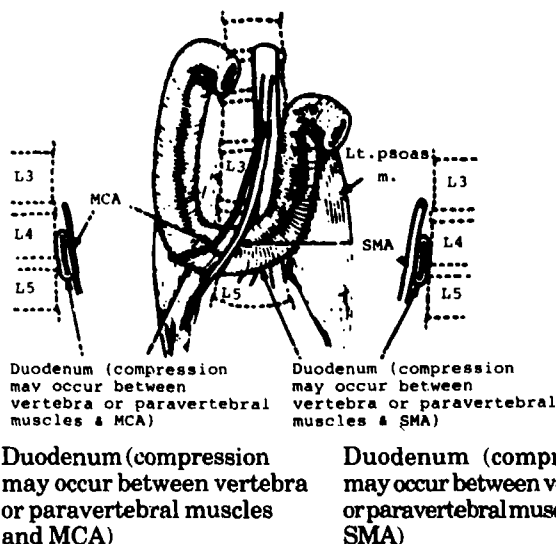


Figure 4. The anatomical relationships between the duodenum, the mesenteric vessels, and the spine are illustrated, emphasizing the potential for duodenal obstruction at the level of L-4. MCA, middle colic artery; SMA, superior mesenteric artery.

both, were responsible for the unexpected weight loss. This syndrome is best treated nonoperatively with aggressive nutrition support, preferably via the enteral route. Only after failure of conservative therapy should surgery be undertaken.

REFERENCES

- Carlson DE, Cioffi WG, Mason AD, et al. Resting energy expenditure in thermally injured patients. *Surg Gynecol Obstet* 1992;174:270-6.
- Carlson DE, Cioffi WG, Mason AD, et al. Evaluation of serum visceral protein levels as indicators of nitrogen balance in thermally injured patients. *JPEN* 1991;15:440-4.
- Milner EA, Cioffi WG, Mason AD, et al. Accuracy of urinary urea nitrogen for predicting total urinary nitrogen in thermally injured patients. *JPEN* 1993;17:414-6.
- Gustafsson L, Falk A, Lukes PJ. Diagnosis and treatment of superior mesenteric artery syndrome. *Br J Surg* 1984; 71:499-501.
- Hanes JR, Gore RM, Ballantyne GH. Superior mesenteric artery syndrome: diagnostic criteria and therapeutic approaches. *Am J Surg* 1984;148:630-2.
- Spiro HM. *Clinical gastroenterology*. 3rd ed. New York: MacMillan Publishing Company, 1983:484.
- Roth EJ, Fenton LL, Gaebler-Spira DJ, et al. Superior mesenteric artery syndrome in acute traumatic quadriplegia: case reports and literature review. *Arch Phys Med Rehab* 1991;72:417-20.
- Reckler JM, Bruck HM, Munster AM, et al. Superior mesenteric artery syndrome as a consequence of burn injury. *J Trauma* 1972;12:979-85.
- Cohen LB, Field SP, Sachar DB. The superior mesenteric artery syndrome. The disease that isn't, or is it? *J Clin Gastroenterol* 1985;7:113-6.

<input checked="" type="checkbox"/>	
<input type="checkbox"/>	
<input type="checkbox"/>	
<input type="checkbox"/>	
<input type="checkbox"/>	
<input type="checkbox"/>	
<input type="checkbox"/>	
<input type="checkbox"/>	
<input type="checkbox"/>	
<input type="checkbox"/>	
<input type="checkbox"/>	
<input type="checkbox"/>	

Dist	Special
A-1	20