



AD _____

MIPR NO: 90MM0533

TITLE: COMPARISON OF CRANIAL & ILIAC AUTOLOGOUS BONE GRAFTS AND THEIR EFFECT ON THE SUCCESS RATES OF SUBSEQUENT OSSEOINTEGRATED INTRA/EXTRAORAL IMPLANT APPLICATION IN THE MINIATURE SWINE

SUBTITLE: Autologous Calvarial and Iliac Onlay Bone Grafts in Miniature Swine

PRINCIPAL INVESTIGATOR: Nathan C. Dickerson, DDS
AUTHORS: Michael G. Donovan, DDS; John W. Hellstein, DDS; Kevin C. O'Hair, DVM

CONTRACTING ORGANIZATION: William Beaumont Army Medical Center
Oral & Maxillofacial Surgery
Oral Pathology and Bio Research
El Paso, Texas 79920-5001

REPORT DATE: October 31, 1992

DTIC
ELECTE
MAR 03 1993
S E D

TYPE OF REPORT: Final Report

PREPARED FOR: U.S. ARMY MEDICAL RESEARCH AND DEVELOPMENT COMMAND
Fort Detrick, Frederick, Maryland 21702-5012

DISTRIBUTION STATEMENT: Approved for public release;
distribution unlimited

The findings in this report are not to be construed as an official Department of the Army position unless so designated by other authorized documents.

98

93-04435



33

REPORT DOCUMENTATION PAGE

Form Approved
OMB No 0704-0188

Public reporting burden for this collection of information is estimated to average 1 hour per response, including the time for reviewing instructions, searching existing data sources, gathering and maintaining the data needed, and completing and reviewing the collection of information. Send comments regarding this burden estimate or any other aspect of this collection of information, including suggestions for reducing this burden, to Washington Headquarters Services, Directorate for Information Operations and Reports, 1215 Jefferson Davis Highway, Suite 1204, Arlington, VA 22202-4302, and to the Office of Management and Budget, Paperwork Reduction Project (0704-0188), Washington, DC 20503.

1. AGENCY USE ONLY (Leave blank)	2. REPORT DATE 31 October 1992	3. REPORT TYPE AND DATES COVERED Final Report (1/2/90 - 9/30/92)
---	--	--

4. TITLE AND SUBTITLE Comparison of Cranial & Iliac Autologous Bone Grafts and Their Effect on the Success Rates of Subsequent Osseointegrated Intra-Extraoral Implant Application in the Miniature Swine	5. FUNDING NUMBERS MIPR No 90MM0533
--	--

6. AUTHOR(S) Nathan C. Dickerson, DDS; Michael G. Donovan, DDS John W. Hellstein, DDS; Kevin C. O'Hair, DVM	61102A 3M161102B874.ED.298 WUDA330783
--	---

7. PERFORMING ORGANIZATION NAME(S) AND ADDRESS(ES) William Beaumont Army Medical Center Oral & Maxillofacial Surgery Oral Pathology and Bio Research El Paso, Texas 79920-5001	8. PERFORMING ORGANIZATION REPORT NUMBER
---	---

9. SPONSORING / MONITORING AGENCY NAME(S) AND ADDRESS(ES) U.S. Army Medical Research & Development Command Fort Detrick Frederick, Maryland 21702-5012	10. SPONSORING / MONITORING AGENCY REPORT NUMBER
--	---

11. SUPPLEMENTARY NOTES
Subtitle: Autologous Calvarial and Iliac Onlay Bone Grafts in Miniature Swine
To be published in the Journal of Oral and Maxillofacial Surgery.

12a. DISTRIBUTION AVAILABILITY STATEMENT Approved for public release; distribution unlimited	12b. DISTRIBUTION CODE
--	-------------------------------

13. ABSTRACT (Maximum 200 words)

Calvarial bone has been reported to be superior to iliac bone for onlay bone grafting due to decreased resorption. This study evaluated the physical, histologic and radiographic characteristics of calvarial and cortico-cancellous iliac onlay bone grafts in nine Pitman-Moore miniature swine at two weeks, one-, two-, four-, six-, eight-, ten- and twelve-month intervals. Compared to iliac grafts, the calvarial onlay grafts had more than a two-fold greater radiographic density. Statistical analysis of the mature grafts using the Standard of Estimated Means of the bone graft volumes revealed 85% retention of the calvarial grafts compared with 34% retention of the grafted iliac bone. There was no subjective difference in the rate or degree of revascularization between the two grafted materials.

14. SUBJECT TERMS Grafts; RA II; Swine; Implants; Bone Replacement; Lab Animals;	15. NUMBER OF PAGES
	16. PRICE CODE

17. SECURITY CLASSIFICATION OF REPORT Unclassified	18. SECURITY CLASSIFICATION OF THIS PAGE Unclassified	19. SECURITY CLASSIFICATION OF ABSTRACT Unclassified	20. LIMITATION OF ABSTRACT Unlimited
--	---	--	--

FOREWORD

Opinions, interpretations, conclusions, and recommendations are those of the author and are not necessarily endorsed by the U.S. Army.

N/A ✓ Where copyrighted material is quoted, permission has been obtained to use such material.

N/A ✓ Where material from documents designated for limited distribution is quoted, permission has been obtained to use the material.

✓ Citations of commercial organizations and trade names in this report do not constitute an official Department of the Army endorsement or approval of the products or services of these organizations.


✓ In conducting research using animals, the investigator(s) adhered to the "Guide for the Care and Use of Laboratory Animals," prepared by the Committee on Care and Use of Laboratory Animals of the Institute of Laboratory Animal Resources, National Research Council (NIH Publication No. 36-23, Revised 1985).

N/A ✓ For the protection of human subjects, the investigator(s) have adhered to policies of applicable Federal Law 45 CFR 46.

N/A ✓ In conducting research utilizing recombinant DNA technology, the investigator(s) adhered to current guidelines promulgated by the National Institutes of Health.

N/A ✓ In the conduct of research utilizing recombinant DNA, the investigator(s) adhered to the NIH Guidelines for Research Involving Recombinant DNA Molecules.

N/A ✓ In the conduct of research involving hazardous organisms, the investigator(s) adhered to the CDC-NIH Guide for Biosafety in Microbiological and Biomedical Laboratories.


Principal Investigator's Signature 12/20/72
Date

AUTOLOGOUS CALVARIAL AND ILIAC ONLY

BONE GRAFTS IN MINIATURE SWINE

MICHAEL G. DONOVAN, DDS¹
NATHAN C. DICKERSON, DDS¹
JOHN W. HELLSTEIN, DDS, MS²
KEVIN C. O'HAIR, DVM³

¹Oral and Maxillofacial Surgery

²Oral Pathology

³Bio Research, William Beaumont Army Medical Center

El Paso, Texas

Accession For	
NTIS CRA&I	<input checked="" type="checkbox"/>
DTIC TAB	<input type="checkbox"/>
Unannounced	<input type="checkbox"/>
Justification	
By _____	
Distribution /	
Availability Codes	
Dist	Avail and/or Special
A-1	

The opinions or assertions contained herein are the private views of the authors and are not to be construed as official or as reflecting the views of the Department of the Army or the Department of Defense.

Address for correspondence and reprints:

Oral and Maxillofacial Surgery Service, ATTN: Dr. Donovan

William Beaumont Army Medical Center

El Paso, TX 79920-5001

ABSTRACT

Calvarial bone has been reported to be superior to iliac bone for onlay bone grafting due to decreased resorption. This study evaluated the physical, histologic and radiographic characteristics of calvarial and cortico-cancellous iliac onlay bone grafts in nine Pitman-Moore miniature swine at two weeks, one-, two-, four-, six-, seven-, eight-, ten- and twelve-month intervals. Compared to iliac grafts, the calvarial onlay grafts had more than a two-fold greater radiographic density. Statistical analysis of the mature grafts using the Standard of Estimated Means of the bone graft volumes revealed 85% retention of the calvarial grafts compared with 34% retention of the grafted iliac bone. There was no subjective difference in the rate or degree of revascularization between the two grafted materials.

INTRODUCTION

Autologous onlay bone grafting utilizing the traditional iliac and rib grafts to repair facial bone defects has been less than ideal due to the rapid and almost complete resorption of these grafts.^{1,3} Calvarial bone grafts have been reported as superior to other bone grafts for maxillofacial onlay grafting due to decreased resorption.^{4,7} The literature describing previous clinical observations and animal studies contains ambiguous and conflicting hypotheses concerning the reasons for the increased viability and retention of autologous calvarial onlay bone grafts.^{4,6,7} This study was designed to examine the histological, physical, and radiographic differences in the retention of autologous calvarial and iliac onlay bone grafts in miniature swine at timed intervals. In an effort to make this animal study as valid as possible, current human surgical techniques were duplicated.⁸

MATERIALS AND METHODS

The miniature porcine was selected as the surgical model for evaluation of calvarial and iliac autografts.^{9,10} This animal has large frontal and parietal bones of adequate thickness to harvest the outer table of the cranial bone through the diploic space. The thickness of this cortical bone closely duplicates the 2-4 mm thickness of the outer table of human cranial bone. The autologous iliac grafts were cortico-cancellous and also duplicated the approximate size of typical grafts harvested from

the human ilium. Both types of bone grafts were stabilized with a lag screw technique using standard 2 mm rigid fixation screws. The onlay bone grafts were a minimum of 5 mm in height to allow the future placement of a 7.0 mm implant fixture (the shortest fixture recommended for placement).^{11,12}

Nine Pitman-Moore miniature swine weighing between 20 and 30 kilograms were used in this study. Every attempt was made to duplicate human surgical techniques for graft harvest and stabilization with rigid internal fixation.⁸ The outer table of the frontal and parietal bones and a cortico-cancellous section of the ilium were used. The cranial bone grafts were stacked two and three layers high to obtain the height necessary for placement of implants and to duplicate the heights of the iliac bone grafts. Each animal had four cranial onlay grafts and four iliac onlay grafts (Figure 1). The bone grafts were placed subperiosteally and secured on the nasal and maxillary bones through a midline full thickness skin flap using 2.0 mm self-tapping vitallium Luhr miniplate screws. The closure was done in layers. Each swine received 1.2 million units of Bicillin at the time of surgery. The study intervals were two weeks, one month, two months, four months, six months, seven months, eight months, ten months, and twelve months.

At the time of placement, each animal's grafts were measured for height (thickness), width, and length at three points. These volumes were compared with the physical measurements obtained at necropsy. Hematoxylin and eosin stains were utilized to assess

bone morphology, osteoblastic and osteoclastic activity, inflammation, bone remodelling (reversal lines), bony interface (osseointegration) with the host bone, and the vascularity of the bone grafts.

A barium sulfate solution was infused at the time of necropsy to evaluate the revascularization of the bone grafts. Under general anesthesia the femoral and carotid arteries were cannulated bilaterally, heparinized, and perfused with heparin and barium sulfate in a saline solution. Infusion pressures were between 110 and 150 mm Hg by gauge on the pressure bags. Once the barium sulfate solution flowed freely from the femoral arteries, the perfusion medium was changed to barium sulfate in a 10% buffered formalin solution. The large vessels in the neck were ligated, and the specimens were immersed in 10% formalin.¹³

The densities of the bone grafts were studied radiographically at the timed intervals. A Hewlett Packard Faxitron was used with exposures made using 50 KVP radiation and Kodak Technical Pan film 2415. The specimens studied were 4 mm thick.

The radiographic densities of the calvarial and iliac onlay grafts were compared to the density of stepped aluminum wedges varying from 0.55 mm to 3.81 mm in thickness (Figures 2, 3 and 4). The radiographic densities of the bone grafts were correlated with the observations of the hematoxylin and eosin stained sections.

RESULTS

None of the animals were lost during this study, and there were no wound infections. Thirty-five calvarial and thirty-five iliac onlay bone grafts were studied. One calvarial bone graft and one iliac bone graft were lost on the four month animal due to a technical error at the time of necropsy.

Comparison of the retained volumes measured at time of necropsy revealed an increased resorptive pattern of the iliac onlay grafts starting at the two-month interval. The calvarial onlay grafts were observed to have greater retention of their original volumes (Figure 5). Over the twelve-month period the mean average volume of iliac bone retention was 52.5%, compared to 91.2% of the calvarial bone (Figure 6). The mean average volume of the mature bone grafts in the six- to twelve-month time frame demonstrated retention of 35.6% for the iliac onlay grafts. There was 84.5% retention for the calvarial onlay grafts (Figure 7). Measurements and comparisons were based upon the Standard of Estimated Means for all volumes.

The histologic examination of each bone graft was accomplished using multiple criteria: marrow spaces, osteoblastic activity, osteoclastic activity, inflammation, reversal lines, host/graft interface, and vascularity.

A ranking method was used for grading the criteria. Marrow spaces were judged as fine, small, medium, or large. Osteoblastic activity and osteoclastic activity was both ranked as low, medium, or high. Cellular activity for each interval was

evaluated as diffuse or localized. The level of inflammation was graded as absent, extra low, low, medium, high, or extra high. Bone activity was judged by the presence and number of reversal lines. Reversal lines were evaluated as low, medium, high, or extra high. The host/graft interface was judged to be either fibrous, mixed fibrous-bony, or full bony. Vascularity was assessed by the presence of barium sulfate-filled arterioles and arteries within the lacunae and marrow spaces and was ranked as low, medium, or high. The intra-arterial injection of the barium sulfate solution observed in the histological sections may not accurately reflect the total number of viable vessels in the bone grafts, but it seems justifiable to consider the number of injected vessels as an index of vascularity. The barium sulfate was easily detected within the arterioles and arteries.

Findings and observations of the histological specimens revealed the marrow spaces of the iliac onlay grafts to be large when compared with the calvarial grafts, which had small to medium- small marrow spaces. This difference reflects the nature of the cortico-cancellous graft available from the ilium compared with the overall cortical nature of the calvarial bone graft. These morphological findings remained constant throughout the twelve-month study and correlated with the radiographic differences of the graft densities (Figures 8, 9, 10 and 11).

The iliac onlay grafts had more osteoclastic activity and less osteoblastic activity than the calvarial onlay grafts (Figures 12 and 13). The inflammatory response was markedly high

during the two-week, one-month, two-month, and four-month intervals in the iliac onlay grafts and correlated with the loss of graft volumes after two months. Inflammation was present in the iliac grafts throughout the twelve-month study (Figures 14 and 15). After six months, no inflammation was noted in the calvarial onlay grafts (Figure 16).

Remodelling of the bone grafts was evaluated by the number of reversal lines observed. The iliac onlay grafts displayed a low to medium number of reversal lines compared with a medium to high number of reversal lines in the onlay calvarial grafts (Figures 17 and 18).

Defining osseointegration as a description of a full bony interface between the grafted bone and the host bone,¹¹ the degree of osseointegration was significantly different for the two types of grafts. A fibrous interface was noted with the iliac onlay grafts up through two months and never progressed beyond a partial fibrous-bony interface. The calvarial onlay grafts progressed from a fibrous interface between the one- and two-month time frame to a full bony interface beginning at six months (Figures 8, 9 and 19).

Histologically, revascularization was accomplished by new vessel ingrowth.^{14,15} A relatively equal amount of barium-perfused vessels was found in both the calvarial and iliac onlay grafts at all intervals. Vascularity scores were low up to four months and then were medium until the termination of this study at twelve

months. No significant differences were noted in the vascularity of the onlay grafts at any time interval (Figure 20).

When compared radiographically, the densities of the onlay grafts were significantly different. Compared to the cortico-cancellous iliac grafts, the cortical calvarial grafts had a greater than two-fold higher density (Figure 11).

DISCUSSION

There is ample evidence that rib, tibial, and iliac grafts better retain their calcified matrix when subject to forces of active function such as stress and strain. When used as onlay grafts, these same sources of bone graft material can be expected to lose a considerable amount of their calcified matrix.¹⁶ Reports of increased retention of calvarial bone when used as onlay bone grafts have been attributed to such factors as its embryologic origin, early revascularization and delayed revascularization.^{4,6,7,17}

Fonseca's study of revascularization and healing of particulate autologous bone grafts in primates revealed that the smaller cortico-cancellous chips of grafted iliac bone were quicker to revascularize, displayed a greater inflammatory response, and retained less of the grafted material. The large particle graft retained more bone than the small particle graft.¹⁸

Smith and Abramson reported that bicortical iliac onlay grafts in rabbits had viable surface bone but that the cancellous bone was resorbed at three months. During this one-year study,

the cortical surfaces of the iliac grafts were noted to be thinner and the grafts smaller than the onlay grafted calvarial bone, which increased in thickness during the same time interval. The iliac grafts showed a rapid decrease in volume by three months and continued to decrease over time, with only 25% of the original graft bulk remaining at one year, whereas the calvarial onlay bone grafts showed an increase in volume over the one-year study.⁶

Both of these previous studies report that revascularization is dependent upon the architecture of grafts and that the size of the bone particle in the graft relates to the inflammatory response and the retention of the bone graft. Fonseca noted less osteoclastic activity and inflammation with the larger size grafts. Smith and Abramson theorized that the early ingrowth of vessels made for more rapid resorption due to the collapse of the cancellous portion of the iliac bone graft. They postulated that the greater volume of mineralized matrix of the calvarial bone delayed resorption and thus allowed for slow remodelling and retention of these grafts.^{6,18}

This study paralleled these previous studies by demonstrating increased inflammation and greater osteoclastic activity in the iliac grafts, which have less mineralized matrix. In this study the histological quantitative analysis of the number of viable vessels within the onlay bone grafts did not show any appreciable difference in the number of barium sulfate-filled vessels within the grafts. There was no subjective

difference in the rate of revascularization for the calvarial or iliac grafts.

At the twelve-month interval this study had similar results to Smith and Abramson. There was 30% volume retention for the iliac grafts and 83% for the calvarial onlay grafts. In the mature bone grafts of the six- to twelve-month time intervals, 35.6% of the iliac onlay grafts were retained, compared with 84.5% of the calvarial onlay grafts.

Overall, the cortico-cancellous iliac grafts displayed a consistently greater degree of osteoclastic activity when compared with the calvarial bone grafts. Inflammation was consistently higher in the iliac grafts. Of particular note was the increased inflammatory response found in the first three- to four-month intervals of the iliac bone grafts. This correlated with the marked initial resorption and volume of loss for the iliac grafts during the same time frame. At approximately the three-month interval, the degree of inflammation noted in the iliac onlay grafts decreased, yet there was a continued amount of diffuse inflammation throughout the twelve-months. This correlated with a decreased rate of volume loss for the iliac bone grafts over this time frame. The overall inflammatory response with the calvarial onlay bone grafts was markedly less than with the iliac onlay bone grafts. Inflammation was virtually nonexistent in the calvarial onlay bone grafts in the six- to twelve-month time intervals.

The increased inflammatory response and osteoclastic activity seen with the iliac onlay grafts appears to have a direct correlation to the resorptive pattern in the first three to four months. The relative lack of osteoclastic activity and inflammatory response seen with the calvarial bone grafts appears to have a direct effect on the retention of these volumes.

Correlation of the results of this study with those of previous studies would indicate that the amount of cancellous bone grafted with onlay bone grafts has a direct inverse effect on graft retention. The increased retention of calvarial bone when used as onlay bone grafts may be due to its architecture of predominantly cortical bone. The radiographic densities measured also correlate to the amount of cortical and cortico-cancellous bone in these grafts. The greater than two-fold density of the calvarial bone grafts is consistent with the volume of cortical bone present and directly effects the retention of the grafts. The iliac bone graft remaining at the ten- and twelve-month intervals appeared to be the residual cortical bone of the original grafts, consistent with previous observations.⁶ The amount of cortical bone grafted to a site may be more important than the source of bone for onlay bone grafting.

CONCLUSIONS

In this study, as in earlier studies, both the calvarial and iliac bone grafts demonstrated early revascularization. However, this study showed no difference in the rate or amount of

revascularization between the two grafts. We conclude that it is the bone density and architecture, not the rate of revascularization, which allows for the greater retention of the calvarial bone when used as an onlay graft. Early revascularization and delayed resorption of calvarial bone allows the deposition of new bone in an orderly fashion without the loss of significant volume. If similar volumes of cortical bone could be obtained from the ilium, perhaps there would be less difference in retention of the two types of grafts.

Our clinical observations in humans with autologous calvarial and iliac onlay grafts parallel the findings of this animal study. We therefore conclude that autologous calvarial bone is superior to autologous cortico-cancellous iliac bone when onlay grafting is indicated for reconstructive maxillofacial surgery.

REFERENCES

1. Fonseca RJ, Davis WH: Reconstructive Preprosthetic Oral and Maxillofacial Surgery. Philadelphia, PA, Saunders, 1986, pp 118-154
2. Fazilli M, Van Overvest-Eerdman GR, Vernoooy AM, Visser WJ, Van Waas AJ: Follow-up investigation of reconstruction of the alveolar process in atrophic mandible. Int J Oral Surg 7: 400, 1978
3. Davis WH, Delo RI, Ward WB, Terry B, Patakas B: Long term ridge augmentation with rib graft. J Maxillofac Surg 3: 105, 1975
4. Petroff MA, Burgess LPA, Lau P, Anonsen CK, Goode RL: Cranial bone grafts for post-traumatic facial defects. Laryngoscope 97: 1249, 1987
5. Powell NB, Riley RW: Cranial bone grafting in facial aesthetic and reconstructive contouring. Arch Otolaryngol Head Neck Surg 113: 713, 1987
6. Smith JD, Abramson M: Membranous vs endochondral bone autografts. Arch Otolaryngol 99: 203, 1974
7. Zins JE, Whitaker LA: Membranous versus Endochondral bone: Implications for craniofacial reconstruction. Plast Reconstr Surg 72: 778, 1983
8. Markowitz NR, Allan PG: Cranial bone graft harvesting: A modified technique. J Oral Maxillofac Surg 47: 1113, 1989
9. Tumbleson ME: Swine in Biomedical Research (Vol 3). New York, NY, Plenum Press, 1986

10. Getty R: The Anatomy of the Domestic Animals: Porcine Osteology (ed 5). Philadelphia, PA, Saunders, 1975, p 1231
11. Branemark P, Zarb GA, Albrektsson T: Tissue - Integrated Prosthesis, Osseointegration in Clinical Dentistry. Chicago, IL, Quintessence, 1985
12. Jensen J, Simonsen EK, Sindet-Pedersen S: Reconstruction of the severely resorbed maxilla with bone grafting and osseointegrated implants: A preliminary report. J Oral Maxillofac Surg 48: 27, 1990
13. Bell WH, Fonseca RJ, Kenneky, JW, et al: Bone healing and revascularization after total maxillary osteotomy. J Oral Surg 33: 253, 1975
14. Zeiss IM, Nisbet NW, Heslop BF, et al: Studies of transference of bone. Vascularization of autologous and homologous implants of cortical bone in rats. Br J Exp Pathol 41: 345, 1960
15. Lozano AJ, Cestero HJ Jr., Salyer RE: The early vascularization of onlay bone grafts. Plast Reconstr Surg 58: 302, 1976
16. Peer L: Transplantation of Tissues (Vol 1). Baltimore, MD, Williams & Wilkins, 1955, p 181
17. Kuziak JF, Zins JE, Ring E, Whitaker LA: The early revascularization of membranous bone grafts. Surg Forum 32: 567, 1980

18. Fonseca RJ, Clark PJ, Burkes EJ, et al: Revascularization and healing of onlay particulate autologous bone grafts in primates. J Oral Surg 38: 572, 1980

LEGEND

Figure 1: Position of the four calvarial and four iliac onlay bone grafts on the maxillae and nasal bones.

Figure 2: Radiographic densities of the onlay bone grafts compared to the densities of stepped aluminum wedges. On the left are the iliac grafts. On the right are the calvarial grafts. Two-week interval shown on top. One-month interval shown on bottom.

Figure 3: Radiographs of the onlay bone grafts. On the left are the iliac grafts. On the right are the calvarial grafts. Six-month interval shown on the top. Seven-month interval shown on bottom.

Figure 4: Radiographs of the onlay bone grafts. On the left are the iliac grafts. On the right are the calvarial grafts. Ten-month interval shown on top. Twelve-month interval shown on bottom.

Figure 5: Graph showing the comparison of percent retention of original volume cranial vs. iliac bone.

Figure 6: Graph showing the percent retention all months averaged together (± 1 sem).

Figure 7: Graph showing the percent retention months 6-12 averaged together (± 1 sem).

Figure 8: Iliac onlay graft at four months demonstrating large marrow spaces and the fibrous interface with the host bone. Original magnification 100x. Hematoxylin and eosin stain.

Figure 9: Calvarial onlay graft at six-months. Note full bony interface, small marrow spaces, high number of reversal lines, and osteoblastic activity. Original magnification 200x. Hematoxylin and eosin stain.

Figure 10: Graph showing marrow spaces.

Figure 11: Graph showing radiographic densities.

Figure 12: Graph showing osteoblastic activity.

Figure 13: Graph showing osteoclastic activity.

Figure 14: Iliac onlay graft at two-weeks. Note inflammation. Original magnification 400x. Hematoxylin and eosin stain.

Figure 15: Iliac onlay graft at ten-months. Note continued inflammation and osteoblastic and osteoclastic activity. Original magnification 400x. Hematoxylin and eosin stain.

Figure 16: Graph showing inflammation.

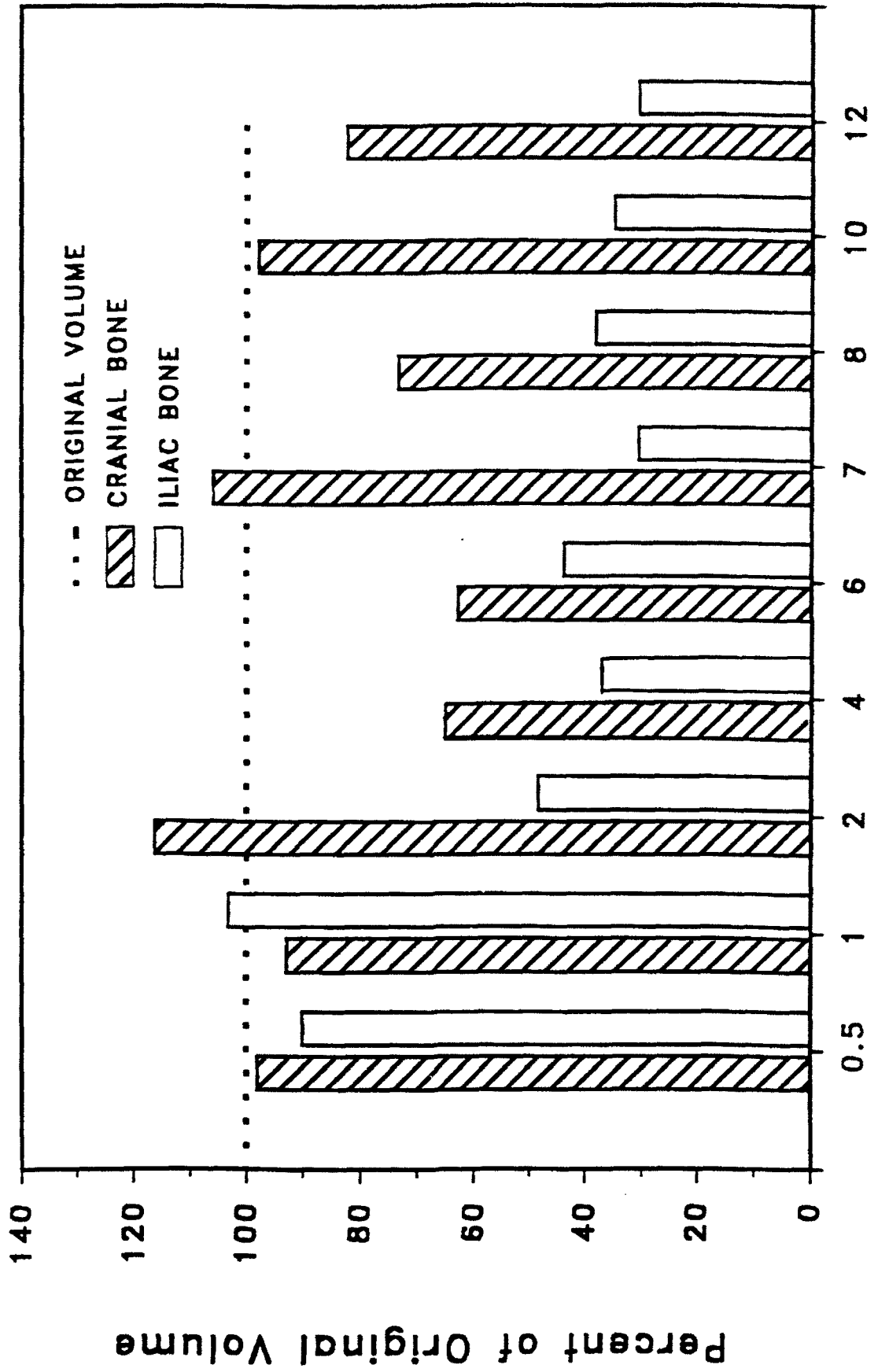
Figure 17: Calvarial onlay graft at seven-months. Note reversal lines and osteoblastic activity. Original magnification 400x. Hematoxylin and eosin stain.

Figure 18: Graph showing reversal lines.

Figure 19: Graph showing bone interface.

Figure 20: Graph showing vascularity.

COMPARISON OF PERCENT RETENTION OF ORIGINAL VOLUME CRANIAL VS. ILIAC BONE



Months
FIGURE 5

PERCENT RETENTION ALL MONTHS AVERAGED TOGETHER (± 1 SEM)

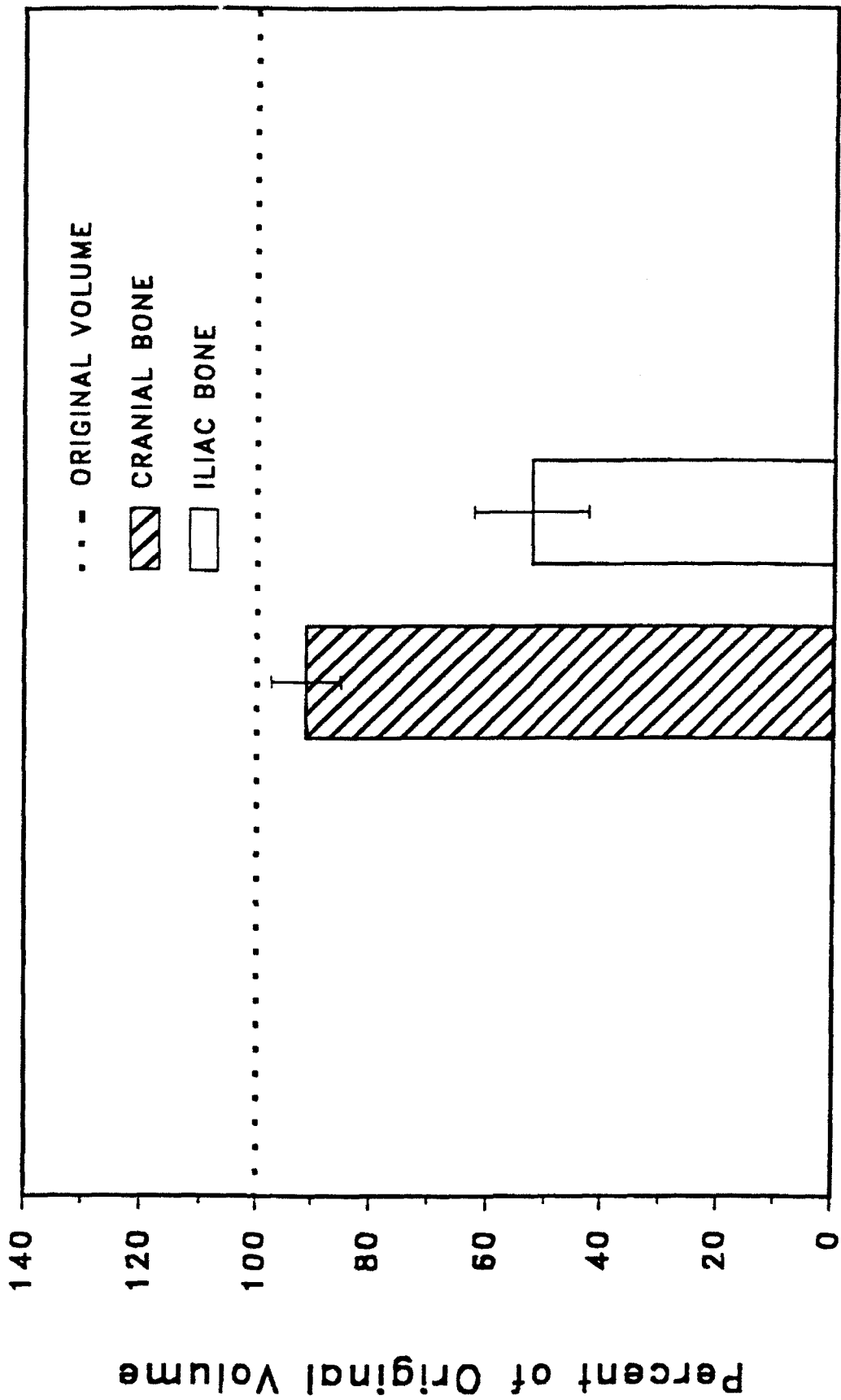


FIGURE 6

PERCENT RETENTION
MONTHS 6-12 AVERAGED TOGETHER
(± 1 SEM)

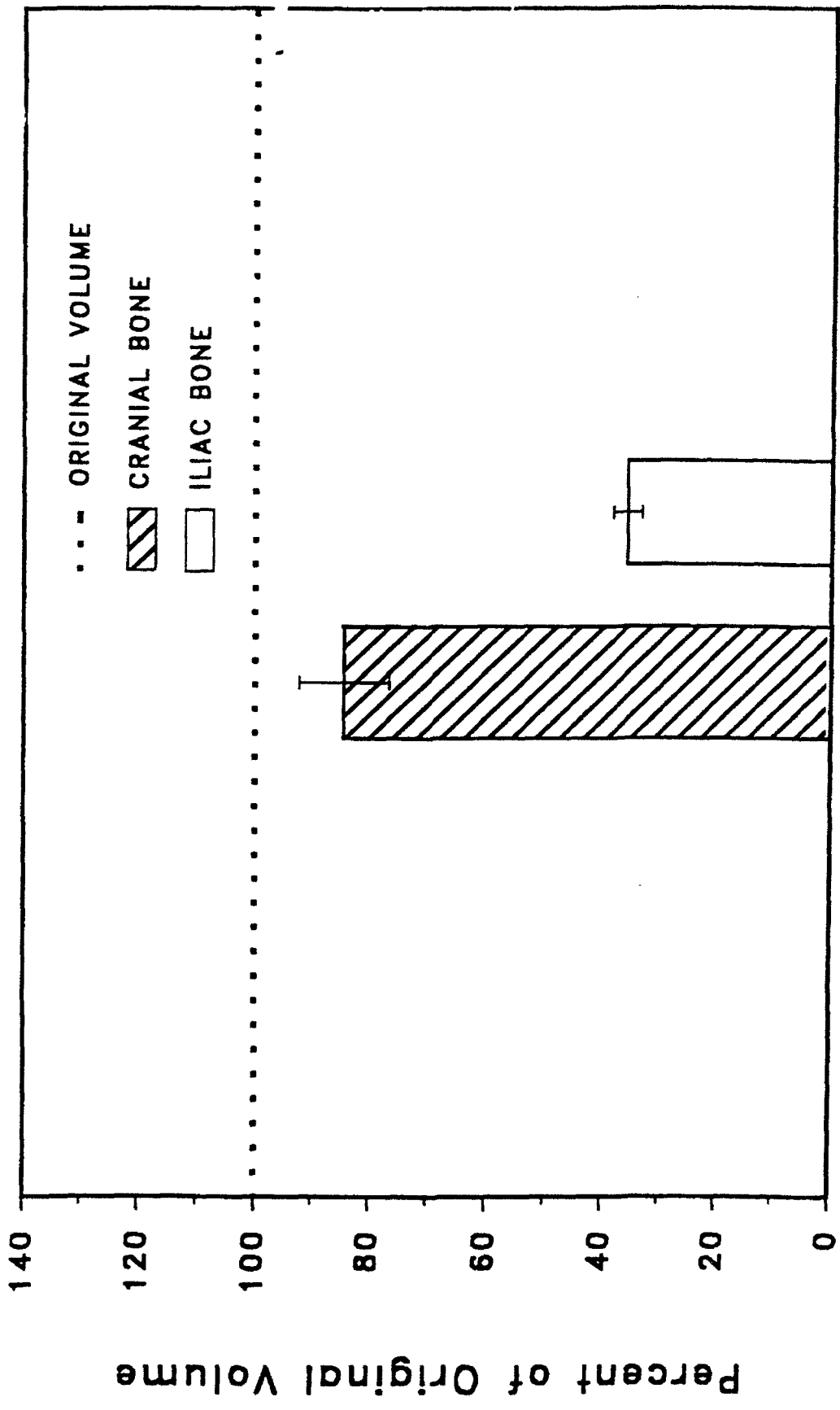


FIGURE 7

Marrow Spaces

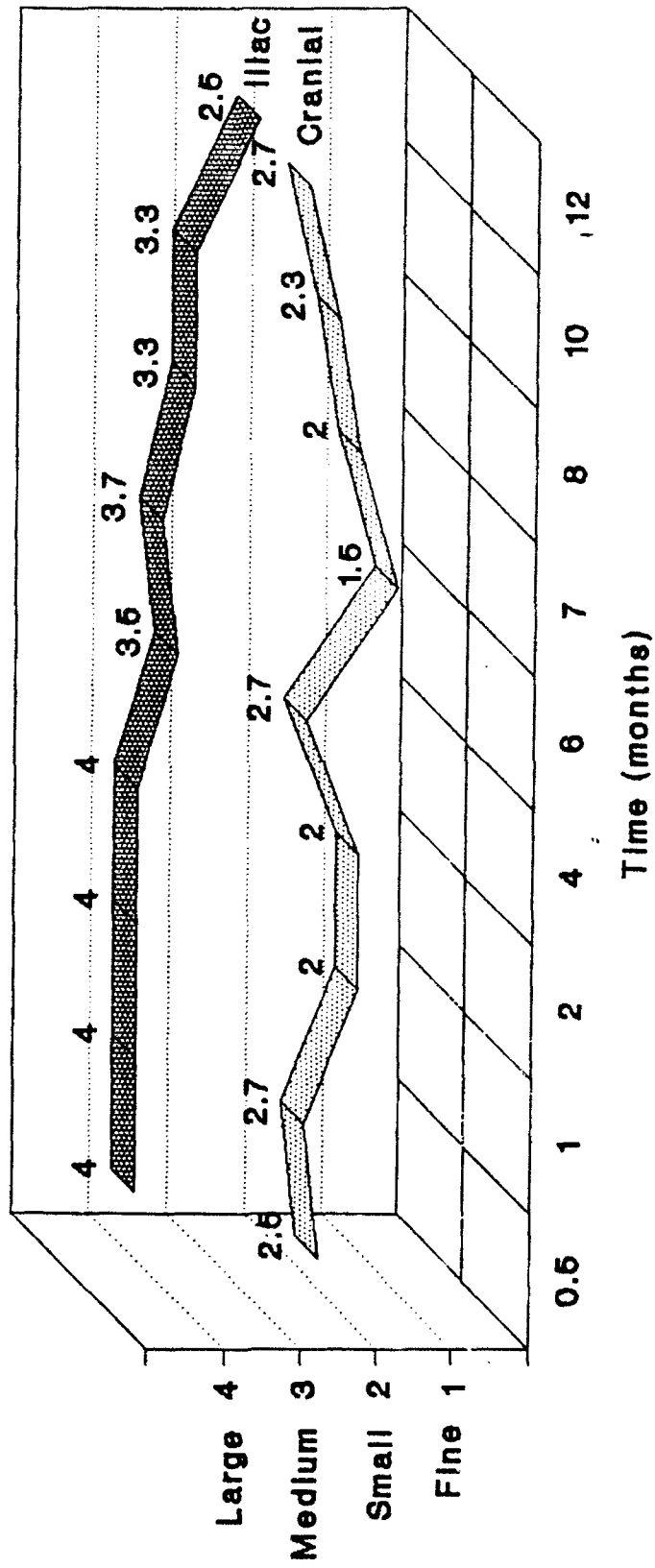


FIGURE 10

Radiographic Densities

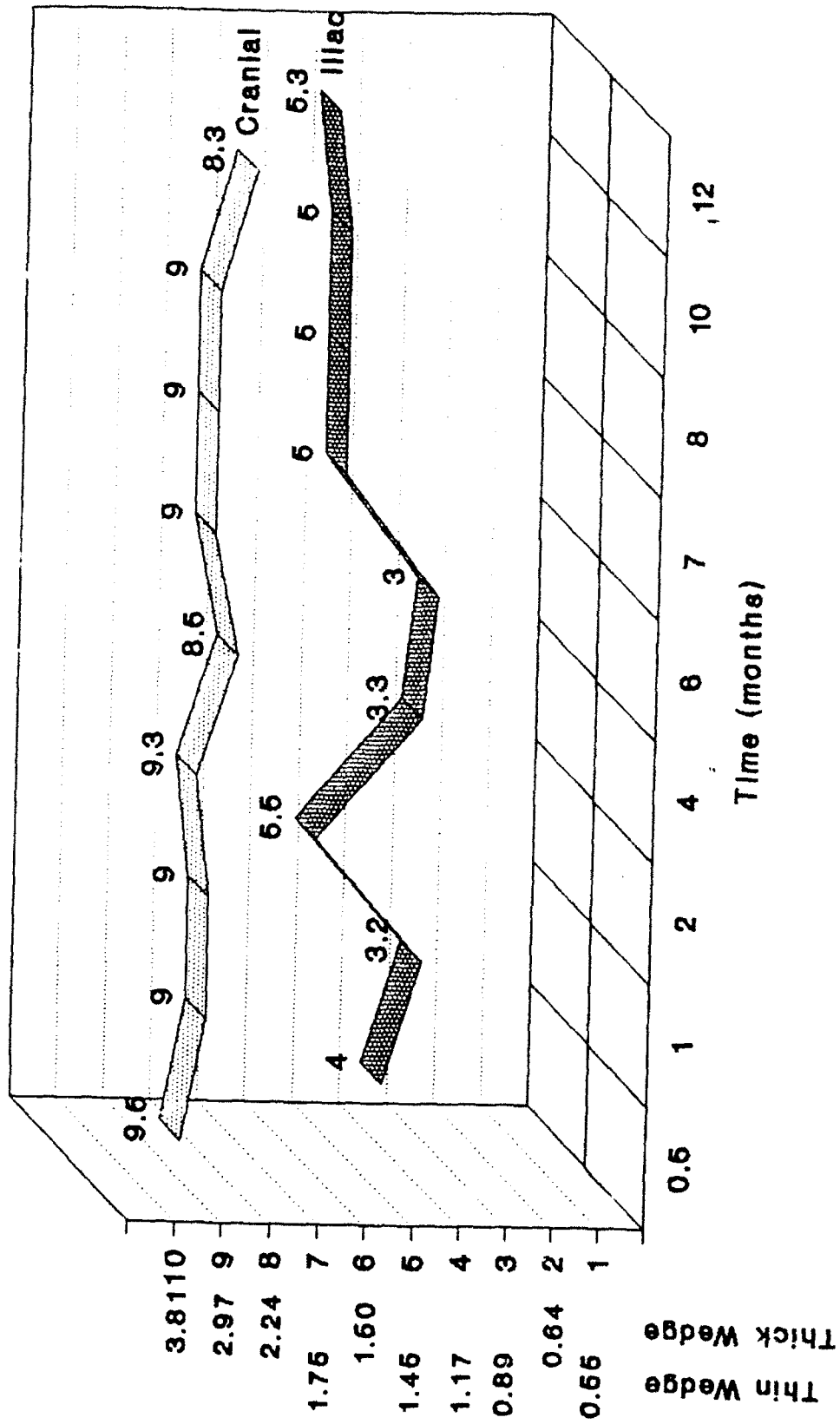


FIGURE 11

Osteoblastic Activity

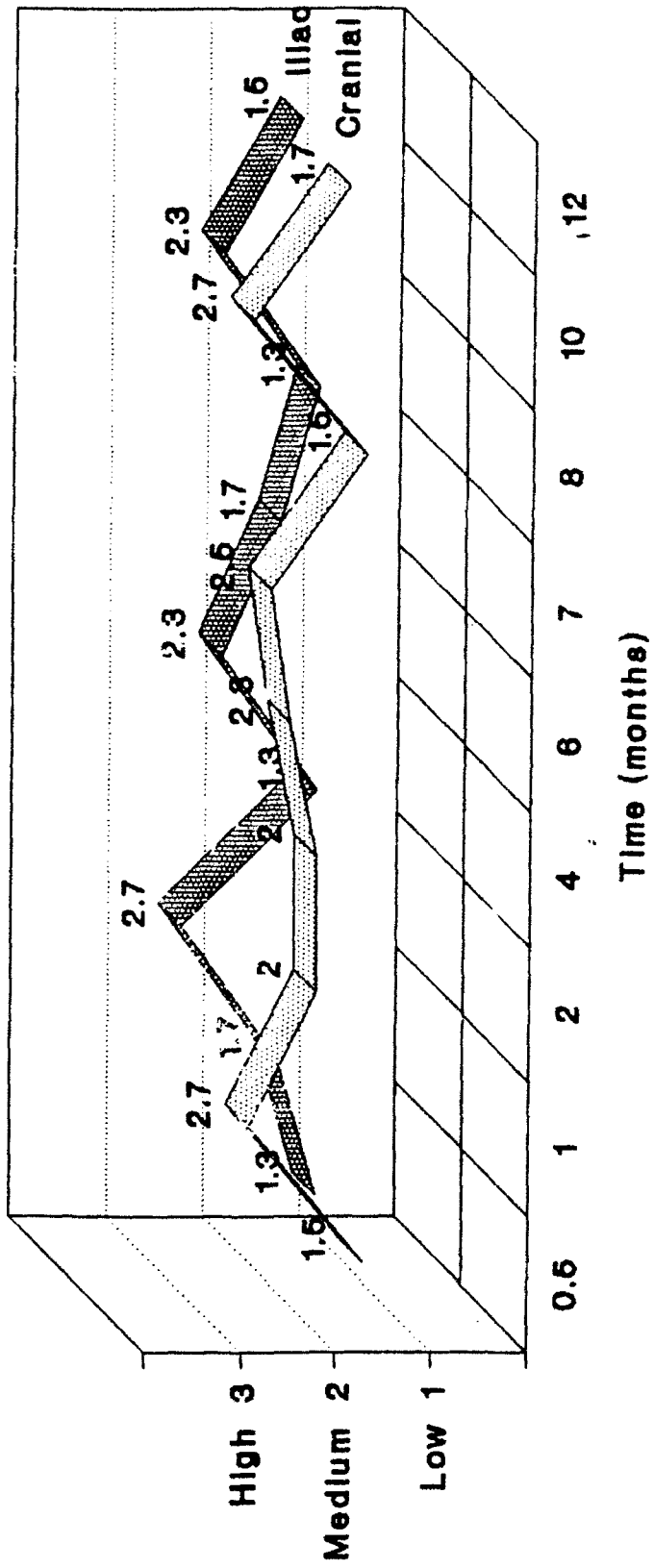


FIGURE 12

Osteoclastic Activity

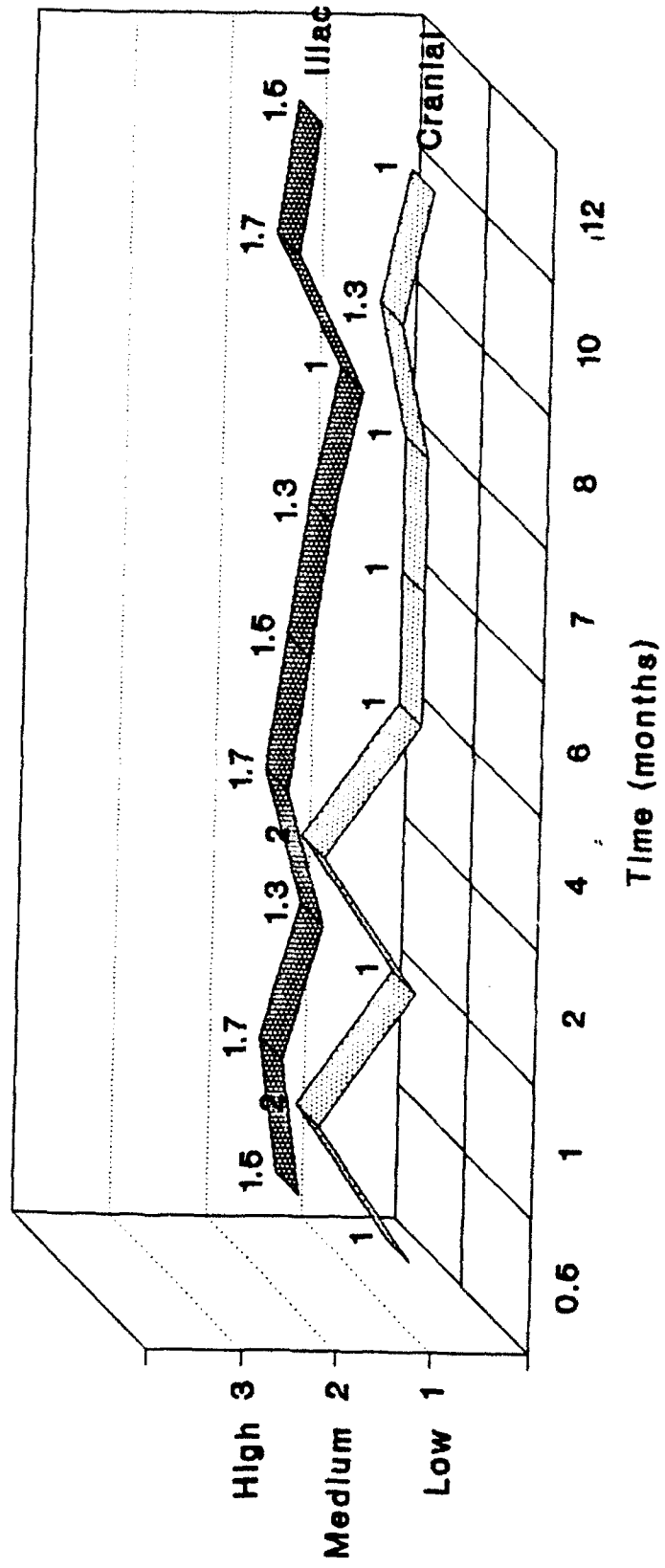


FIGURE 13

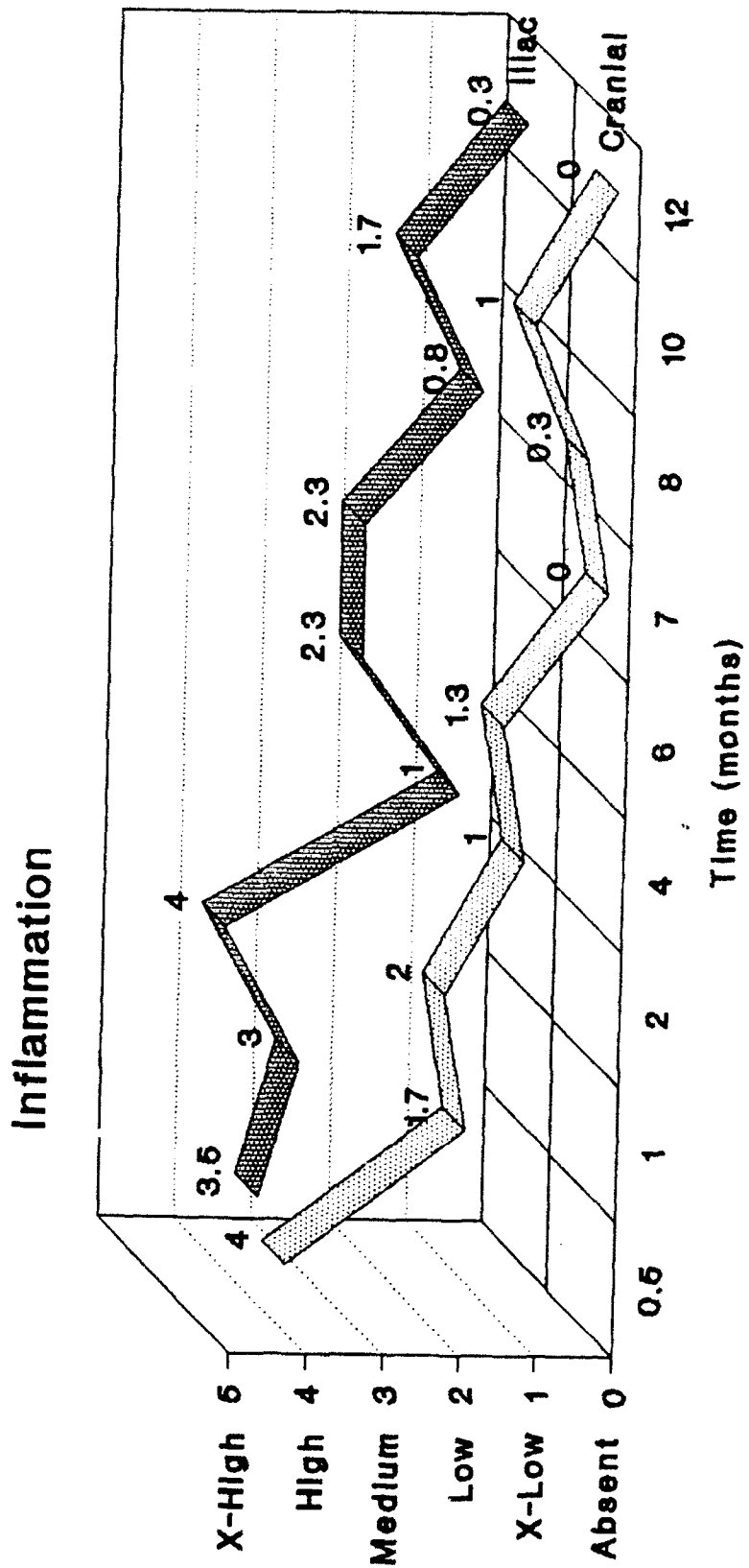


FIGURE 16

Reversal Lines

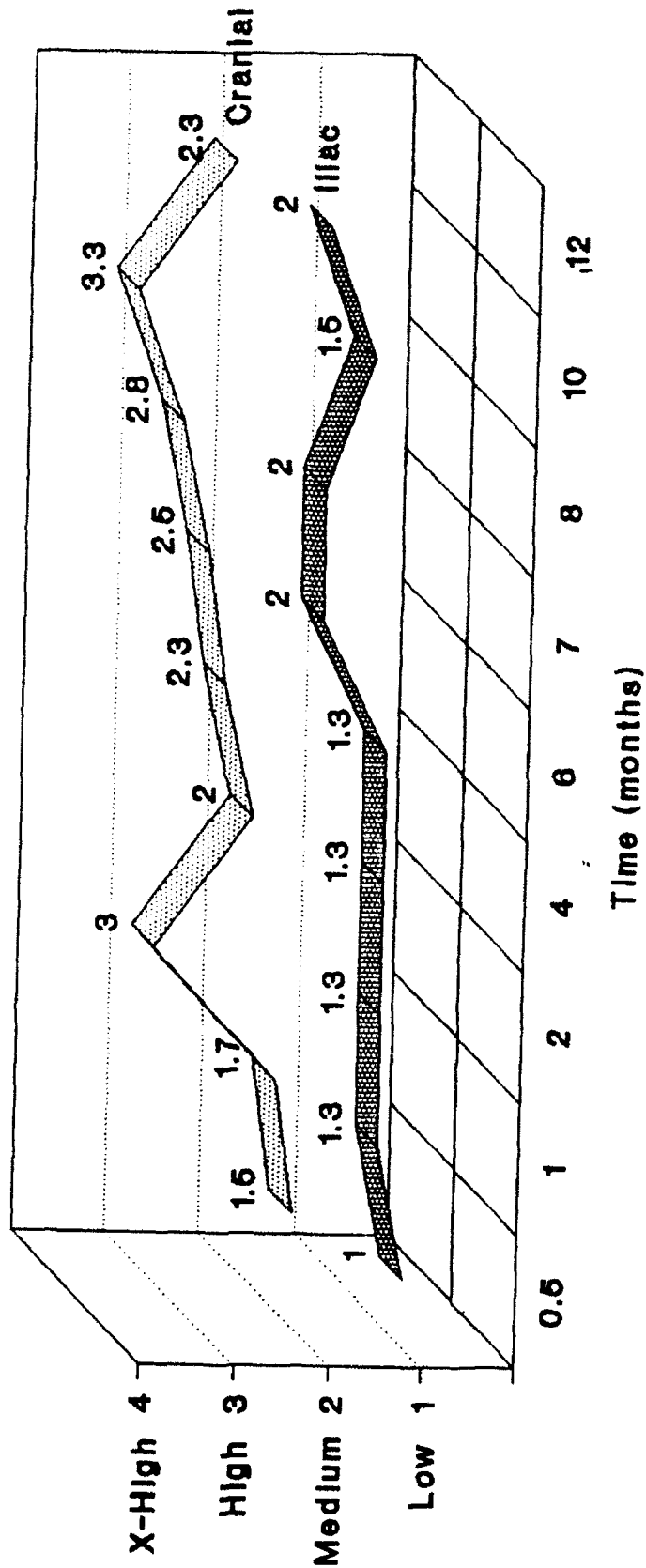


FIGURE 18

Bone Interface

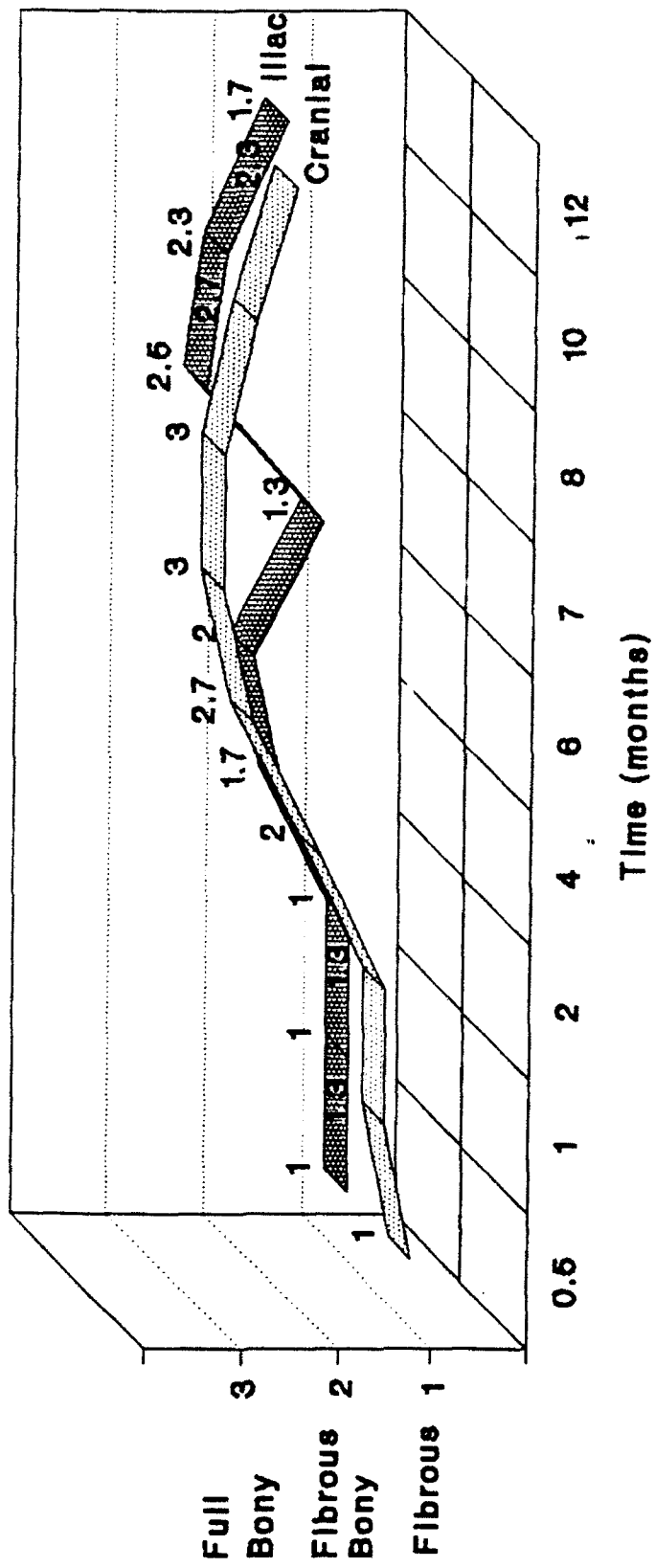


FIGURE 19

Vascularity

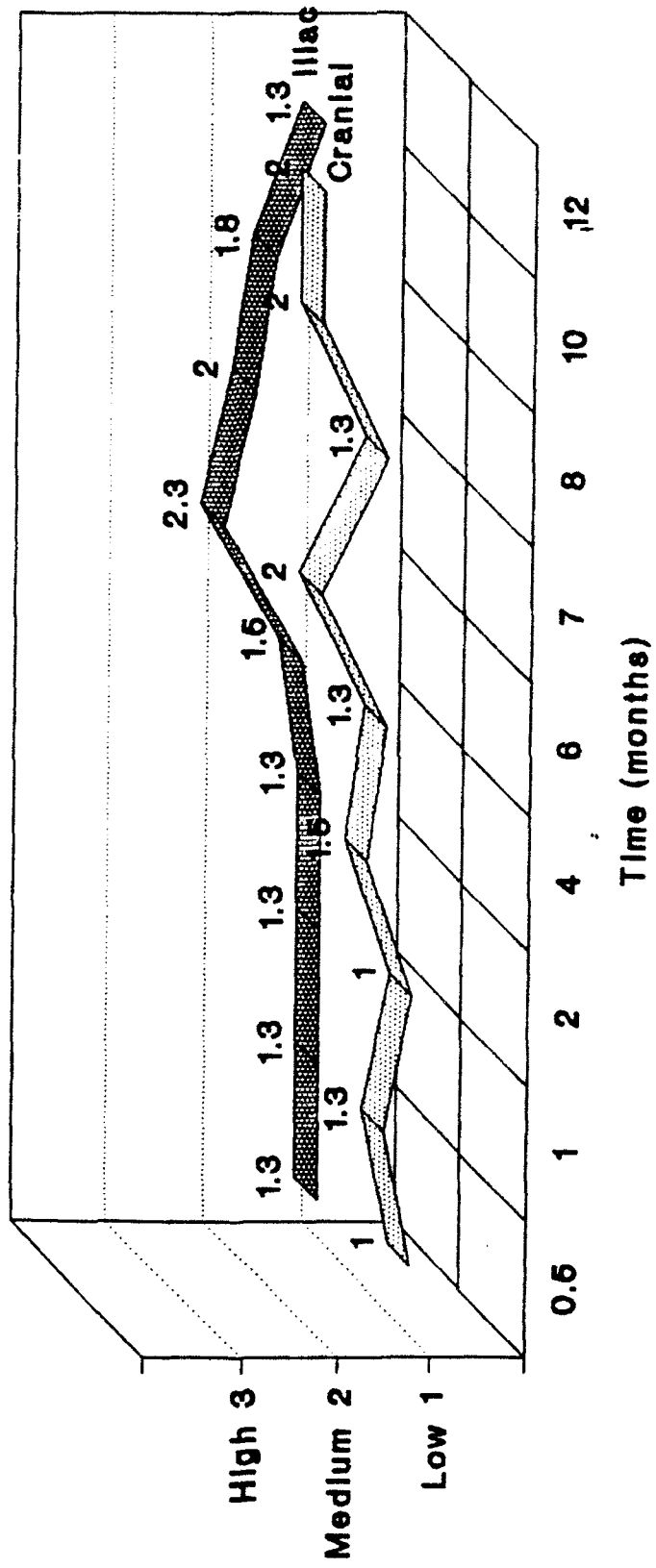


FIGURE 20