


AD-A244 866



✓

①

**WEAK DIRECT CURRENT
ACCELERATES SPLIT-THICKNESS
GRAFT HEALING ON TANGENTIALLY
EXCISED SECOND-DEGREE BURNS**

**CHI-SING CHU, MD,
ALBERT T. MCMANUS, PhD,
CARLIN V. OKERBERG, DVM,
ARTHUR D. MASON, JR., MD,
and**

**BASIL A. PRUITT, JR., MD,
Fort Sam Houston, Texas**

From the United States Army Institute of Surgical Research,
Fort Sam Houston.

Reprinted from
JOURNAL OF BURN CARE & REHABILITATION
St. Louis

Vol. 12, No. 4, pp. 285-293, July, 1991
(Copyright © 1991, by Burn Sciences Publishers, Inc.)
(Printed in the U.S.A.)

**DTIC
ELECTE
S D D
JAN 22 1992
D**

This document has been approved
for public release and sale; its
distribution is unlimited.

92-01502



92 1 16 096

Weak Direct Current Accelerates Split-Thickness Graft Healing on Tangentially Excised Second-Degree Burns

Chi-Sing Chu, MD, Albert T. McManus, PhD, Carlin V. Okerberg, DVM,
Arthur D. Mason, Jr., MD, and Basil A. Pruitt, Jr., MD
Fort Sam Houston, Texas

We have examined the effects of direct current (DC) conducted through silver-nylon dressings on the healing time and morphologic maturation of split-thickness grafts placed on tangentially excised deep partial-thickness burn wounds. Male guinea pigs ($n = 120$) were used as the experimental hosts. The DC-treated animals required 2 days for complete revascularization of their grafts; control animals required 7 days ($p < 0.01$). The DC-treated animals had increased epithelial proliferation at the graft-wound interface as compared with controls ($p < 0.01$). Grafts from DC-treated animals were firmly adherent within 4 days, whereas graft adherence in controls was weak before 7 days after grafting. At 3 months after grafting, control animal grafts had mild contraction with moderate hair loss and thick subepidermal fibrosis; the grafts in DC-treated animals expanded with the growth of the animals and had abundant hair growth and significantly reduced dermal fibrosis ($p < 0.01$). (J BURN CARE REHABIL 1991;12:285-93)

The practice of excision and autografting of full-thickness burn wounds to effect wound closure is a major advance in burn care. Excision of deep partial-thickness burns to the level of intact microcirculation (tangential excision) followed by partial-thickness autografting is also commonly believed to result in improved outcome through preservation of viable dermal and nervous tissue and shortened wound closure time. A major complication of both procedures is graft loss as a result of physical damage or infection during the time required to establish the grafts.

We have previously shown that DC anodal silver-nylon dressings are effective as topical antimicrobial

therapy and shorten healing time with an improved quality of healing for partial-thickness donor sites taken from areas of healed partial-thickness burns.^{1,2} In this study we have examined the effect of DC anodal silver-nylon dressings on the take and growth of split-thickness autografts that were placed on tangentially excised deep partial-thickness burn wounds.

MATERIAL AND METHODS

Standard Guinea Pig Burn. One hundred and twenty male Hartley guinea pigs, which weighed an average of 400 ± 25 gm, were used. The animals were anesthetized by intraperitoneal injection of 36 mg/kg pentobarbital sodium. The hair on the dorsal trunks was clipped, and a depilatory cream (Nair, Carte-Wallace, Inc., New York, N.Y.) was applied for 15 minutes. The residual hair roots were then gently washed out with warm tap water. Deep partial-thickness scalds were inflicted by means of a 10-second exposure to water at a temperature of 78° C. A Walker-Mason burn template with a 4.5×5.5 cm² window was used to restrict the wound to the cephalad portion of each animal's back.³ The resulting scald wounds covered 8% to 9% of the total body surface area of each guinea pig.

From the United States Army Institute of Surgical Research, Fort Sam Houston.

Reprint requests: Albert T. McManus, PHD, C/O Library Branch, United States Army Institute of Surgical Research, Fort Sam Houston, TX 78234-5012.

The opinions or assertions contained herein are the private views of the authors and are not to be construed as official or as reflecting the views of the Department of The Army or The Department of Defense.

In conducting the research described in this report, the investigators adhered to the Animal Welfare Act and other Federal statutes and regulations that relate to animals and experiments that involve animals and with the Guide for the Care and Use of Laboratory Animals, National Institutes of Health Publication 86-23.

30/1/28796

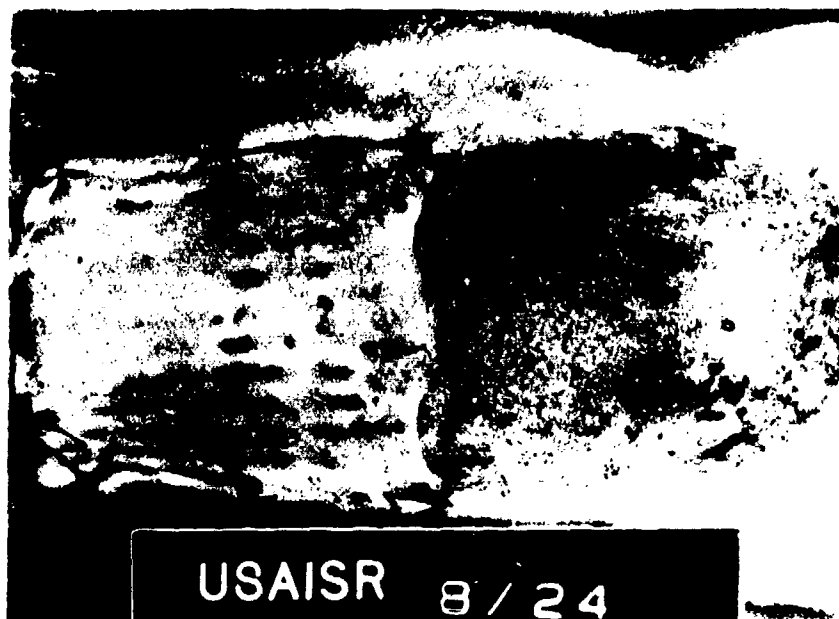


Figure 1. A cephalad autografted wound (9% total body surface area) and a caudad donor site (9% total body surface area) soon after tangential excision, harvesting, and grafting.

Table 1. Experimental groups

Group	Description	Duration of treatment (days)
Control ($n = 60$)	Graft + donor site + SN	
Treatment ($n = 60$)	Graft + donor site + SN	
Direct current	40 μ A	2
	20 μ A	3

SN, Silver-nylon.

Table 2. Frequency of India ink carbon in grafts (revascularization) at selected times after grafting

Group	Days after grafting				
	1	2	4	5	7
Control	—†	1/4	2/4	6/8	9/9
DC-treated	0/1	7/8*	11/11*	6/6	—‡

* $p < 0.01$.

†Grafts were not adherent.

‡Grafts were not perfused.

Tangential Excision and Autografting. One hour after scalding, a 5 cm transverse incision was made at 1 cm cephalad and parallel to the burn wound edge. A 25 × 5 cm smooth, surgical steel

plate was inserted 12 cm into the subpannicular space under the scald wound. To make the skin tense, four towel clips were applied to the skin at the corners of the metal plate. A 0.022-inch thick skin graft



<input checked="" type="checkbox"/>
<input type="checkbox"/>
<input type="checkbox"/>
Codes

Figure 2. Control animals at 7 days after grafting. Example of the complete reestablishment of graft microcirculation that shows ink particles (*arrow*) in subepidermal capillaries (hematoxylin-cosin, $\times 8$).

A-1 20

Table 3. Epithelial proliferation from hair follicles at the graft-wound interface at various times after grafting

Group	Days after grafting						
	2	3	4	5	7	14	90
Control	0/6†	0/3	1/8	2/8	0/9	4/10	0/9
DC-treated	3/8	3/3	6/10	4/5	3/5*	0/9	0/10

*Increased frequency of subgraft epithelial proliferation with DC treatment for days 2 to 7 ($p < 0.01$).
 †Number of animals that had epithelial proliferation over number of animals that were examined.

Table 4. Morphometric comparison of dermis profile in skin at 3 months after grafting

Group	Thickness	
	Subepidermal fibrosis (mm)	Lower dermis (mm)
Control ($n = 9$)	0.619 \pm 0.016	1.736 \pm 0.024
DC-treated ($n = 10$)	0.435 \pm 0.007*	1.518 \pm 0.015*

Values are expressed as mean \pm SEM.
 * $p < 0.01$.

(4.5 \times 11 cm) was harvested from both the scalded wound and the normal depilated area caudad to the burn wound with a Brown electrodermatome (Zimmer Mfg. Co., Warsaw, Ind.). This excision depth

resulted in a minimally bleeding wound bed. After the scalded portion of excised tissue was discarded a partial-thickness graft was prepared and fitted to the excised scald wound. As shown in Figure 1, each



Figure 3. Two days after grafting and the start of DC treatment. **A**, Carbon from infused Pelikan ink is evident in the whole layer of graft tissue; **B** proliferation of epithelium (*arrows*) is beginning in hair follicles (hematoxylin-eosin, $\times 8$ and $\times 50$).

animal had a cephalad autografted excised scald wound and a caudad ungrafted donor site.

Experimental Groups. As shown in Table 1, the animals were divided into control and DC treatment groups. The wounds were covered with silver-nylon dressings (Swift Textile Metalizing Corporation, Hartford, Conn.) and sutured in place.⁴ The silver-nylon dressings were covered with a layer of sponge and three layers of gauze and fixed in place with

flexible tubular bandages. The silver-nylon dressings in the DC-treated animals were connected as an anode in a DC circuit, as previously described.² A constant current of $40 \mu\text{A}$ was applied for 2 days, followed by a current of $20 \mu\text{A}$ for 3 days with the use of a constant direct current generator.⁵ The dressings of the DC-treated animals and controls were moistened once or twice daily with 2 to 3 ml saline solution, which was administered through irrigation

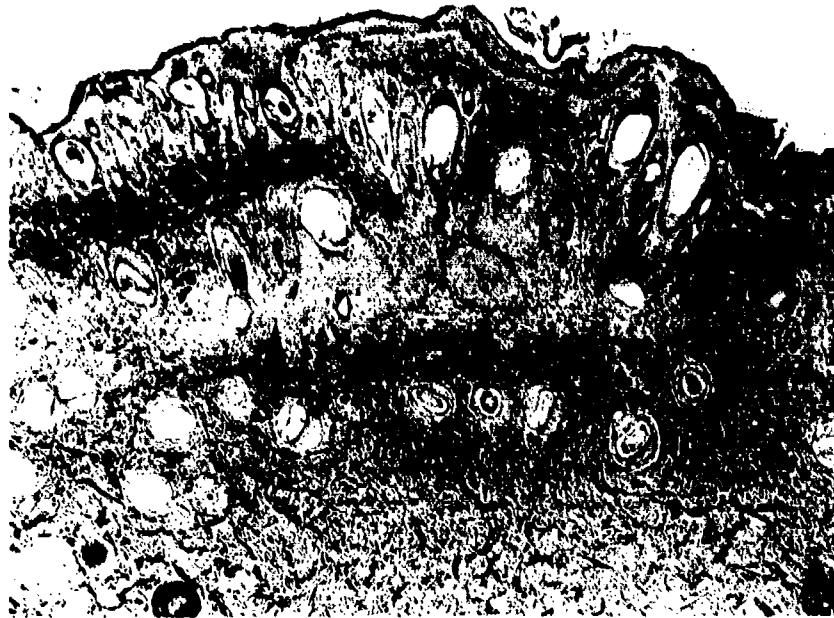


Figure 4. A portion of the graft from a DC-treated animal at 4 days after grafting. An incomplete epithelial layer is present at the graft-wound interface (*arrows*) (hematoxylin-eosin, $\times 8$).

Table 5. Contraction and expansion of grafted wounds treated with and without direct current

	14 Days after grafting		3 Months after grafting	
	Treatment (<i>n</i> = 10)	Control (<i>n</i> = 7)	Treatment (<i>n</i> = 10)	Control (<i>n</i> = 10)
Wound size (cm ²)				
Mean	16.00	15.58	29.07*	14.61
SEM	0.731	1.245	2.306	1.212

**p* < 0.0001.

rubes. All dressings were removed on the seventh day after grafting, or as indicated below.

Evaluation of Graft Healing. Grafted wounds were examined daily for 3 weeks and then weekly for 3 months after grafting. Graft adherence, hair growth, percentage of graft take, and wound contraction were recorded and photographed at selected times. Necropsy samples of the grafted wounds were collected for microscopic examination on selected days. Two animals from each group were killed and examined at days 1, 3, 5, 30 and 60 after grafting, and 10 from each group were killed and examined at 2, 4, 7, 14 and 90 days after grafting. All specimens were obtained from the central areas of the grafted wounds.

Estimation of circulatory integrity in the grafts was

made by microscopic examination for the presence of carbon particles in the capillaries after perfusion with 40 ml Pelikan ink (Pelikan, AG D3000, Hannover 1, Germany). After the animals were anesthetized with pentobarbital sodium, the ink was perfused via a small polyethylene cannulas that were placed in the superior mesenteric arteries. The perfusion speed (38.2 ml/min) was regulated with an infusion-withdrawal pump (Harvard Apparatus Inc., Natick, Mass.). Immediately after infusion, the animals were killed, and sections of grafts were prepared for microscopic examination. Photomicrographs were taken with a low-power objective lens (X8). Morphometric measurements of fixed tissue were made with a digital image analyzer (Vidas, Carl Zeiss Inc., Thornwood, N.Y.).

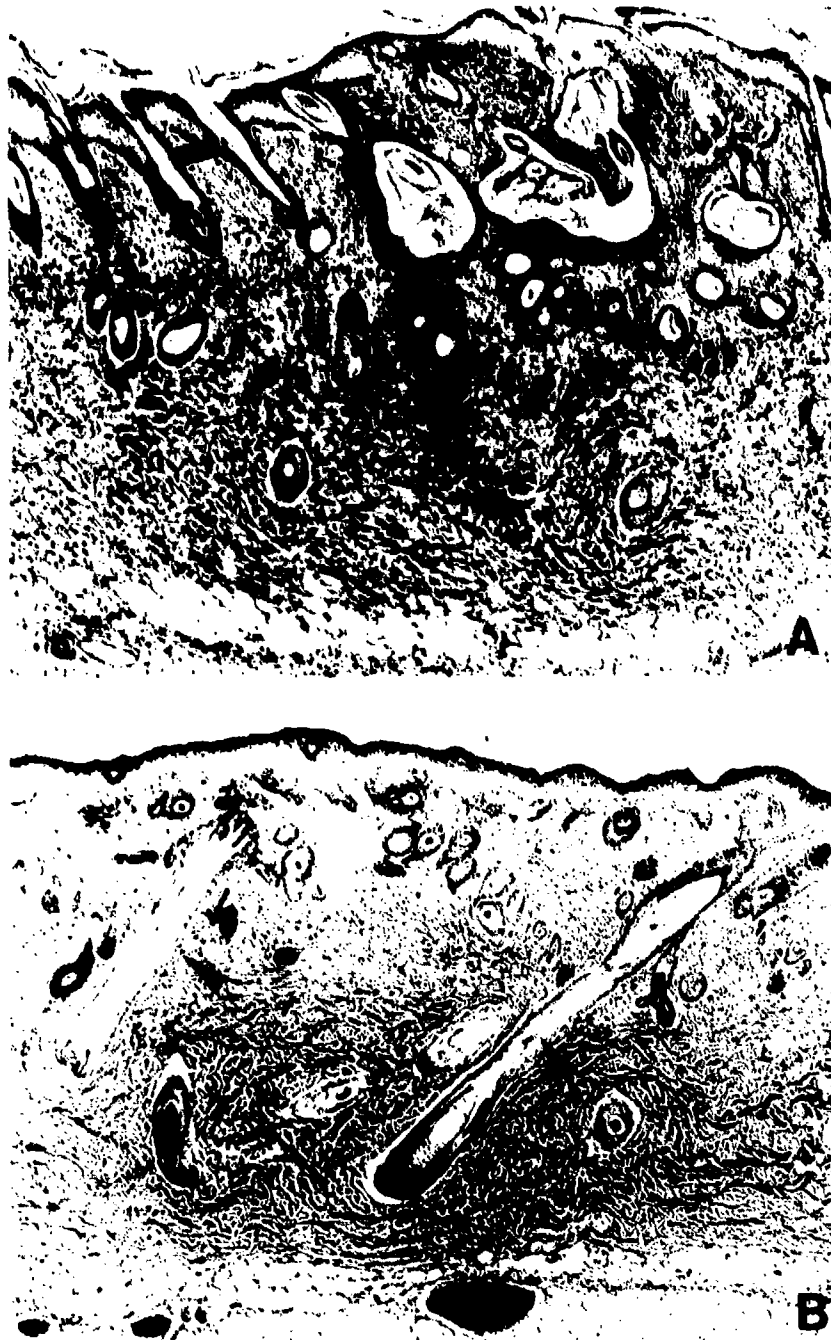

Figure 5. Example of a DC-treated wound 7 days after grafting. **A**, The incomplete epithelial layer at the graft-wound interface is much less prominent than at 4 days after grafting (see Figure 4). Hair follicles are dilated and contain debris and hair shafts. **B**, Hair shafts in the dermis and graft have been connected (*arrows*) (hematoxylin-eosin, $\times 8$).

RESULTS

Control animal grafts were not adherent to the wound bed at 1, 2, or 4 days and after grafting were commonly separated from the wound bed when the dressings were removed. Partial adherence was noted by day 7 after grafting, and grafts were firmly ad-

herent at 14 days. Grafts on DC-treated animals were partially adherent on day 1 after grafting, adherent on day 2, and firmly adherent by day 4 after grafting. Data that compare the effect of DC treatment on the reestablishment of graft microcirculation, as evidenced by histologic demonstration of carbon black in graft vessels, are presented in Table 2. Intact mi-




Figure 6. Comparison of control and DC-treated animals at 14 days after grafting. **A**, Photograph of the healed graft (*arrows*) of a control animal. There is mild contraction and no hair growth. **B**, Layer of fibrosis in the upper dermis of a control graft (*arrow heads*) (hematoxylin-cosin $\times 8$). **C**, photograph shows smoothly adherent graft (*arrows*) with short hair growth of a treated animal; **D** photomicrograph of a DC-treated graft shows a thin layer of fibrosis in the upper dermis (*arrow heads*) (hematoxylin-cosin, $\times 8$).

Microcirculation was observed in only one of four control animals on day 2 after grafting and in all control animals on day 7 after grafting (Figure 2). On day 1 after grafting, grafts on control animals separated from the underlying tissue during fixation and could not be examined. DC treatment enhanced the reestablishment of graft-host microcirculation; by day 2 after grafting, carbon black was present in graft vessels in seven of eight treated animals (Figure 3, A).

Graft epithelization and the development of fibrosis were markedly altered by DC treatment. Epithelial growth was distinctly stimulated by DC. Hair follicle epithelium in DC-treated animals proliferated actively as early as 2 days after grafting (Figure 3, B).

A comparison of epithelial proliferation at the graft-wound interfaces of control and treated animals is presented in Table 3. DC treatment resulted in earlier, more extensive epithelial growth. In treated animals, by day 4 after grafting, an epithelial layer had formed between the hair follicles at the graft-wound interface, and there was further evidence of expanding microcirculation (Figure 4). The hyperplastic epithelial layer was not seen in control animals and resolved in treated animals between 7 and 14 days after grafting, as dermal and graft follicles joined (Figure 5). A comparison of control and treated animals at 14 days after grafting is presented in Figure 6. On gross examination, control animals appeared to have mild contraction (Figure 6, A) compared

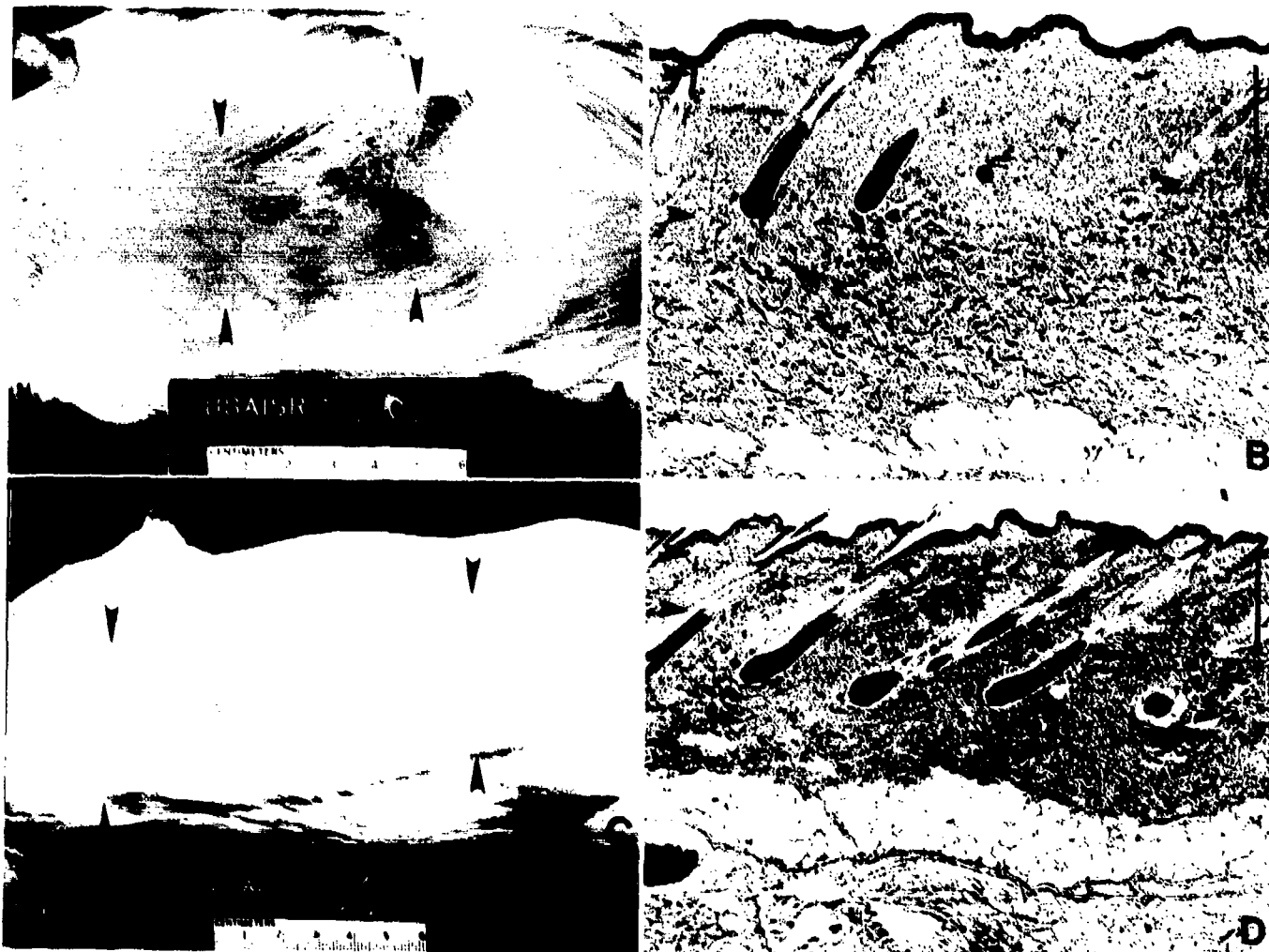


Figure 7. Comparison of DC-treated and control animals 3 months after grafting. **A,** Gross appearance of grafted wound (*arrows*) from a control animal, which healed with mild-to-moderate contraction and moderate hair growth. **B,** Microscopic section of control graft shows a subepidermal layer of fibrosis (*arrow heads*). The right portion of the section has fewer hair follicles (hematoxylin-eosin, $\times 8$, *bar* = 500 μm). **C,** Photograph that shows gross appearance of a DC-treated graft (*arrows*) shows no contraction and abundant hair growth. **D,** Photomicrograph from the grafted wound of a DC-treated animal shows nearly normal skin except for a slight decrease in the number of hair follicles and thin subepidermal fibrosis (*arrow heads*) (hematoxylin-eosin, $\times 8$, *bar* = 500 μm).

with treated animals (Figure 6, *C*). Control animals had a significant amount of fibrosis in the upper dermis (Figure 6, *B*). In treated animals, a mature stratum corneum was observed in hair follicle canals, and minimal subepithelial fibrosis was present (Figure 6, *D*).

The appearances of control and treated grafts at 90 days after grafting are presented in Figure 7. On gross examination, the grafts of treated animals had more hair and, unlike the grafts of control animals (Figure 7, *A*), which appeared to have grown with the animals (Figure 7, *C*). Histologic examination at 90 days after grafting showed treated animals to have

nearly normal skin structure, with the exception of mild subepidermal fibrosis and a minimal decrease in hair-follicle density (Figure 7, *D*). Control animals showed a markedly wider zone of fibrosis and loss of many hair follicles (Figure 7, *B*). Morphometric comparisons of the thickness of subepithelial fibrosis, dermal thickness measured from the deepest subepithelial fibrosis to the panniculus, and the dimensions of the residual grafts were made at 90 days after grafting. Data are presented in Tables 4 and 5, respectively. DC treatment resulted in a significant decrease in healed graft thickness and a significant increase in graft expansion.

DISCUSSION

The final depth of circulatory impairment after thermal injury defines the extent of tissue destruction and, therefore, the possibility of wound healing. This depth of tissue destruction is not always immediately obvious, and wounds that appear to be deep partial-thickness burns may, during subsequent days, undergo further ischemia or become infected with resulting loss of initially viable deep epidermal elements and are thus said to have converted to full-thickness injuries.⁶⁻⁸ These complications are, in part, the basis for the practice of early tangential excision and autografting of deep partial-thickness burns. Such procedures remove the infection-prone nonviable tissue and, with successful grafting, preserve the underlying microcirculation and reduce the inflammation and subsequent scarring that is associated with tissue slough.

The survival of an autograft depends on early establishment of the circulation for nutrient supply and disposal of metabolic waste products. Delayed healing, severe wound contraction, and failure of graft adherence are serious complications in deep partial-thickness burn wounds after tangential excision and split-thickness autografting. In 1972, Shepard⁹ suggested that such complications are due to the time required for adherence between the graft and the wound bed and reestablishment of the graft's circulation. He studied the viability of split-thickness autografts on donor sites and stated that normal, nonneoplastic epithelium will not migrate through viable tissue. This inability of epithelium to migrate down through a viable split-thickness graft was believed to reduce adherence of the graft to the wound bed for up to 10 days after grafting.⁹

In this study, we found that the transient epithelial cell proliferation that occurred between viable host tissue and a graft (at the graft-wound interface) was exaggerated by DC treatment. This hyperplastic epithelium was present by day 2 after grafting and appeared to be derived from dermal hair follicles in the wound bed. The hyperplasia was maximal at 1 week and resolved by 14 days, by what appeared to be extension of the epithelial cells into connections that were made with adjacent viable hair canals in the graft. This phenomenon may be an example of the previously reported effects of DC on epithelial growth.¹⁰⁻¹³

Although the mechanisms that underly the overall improvement in healing in DC-treated animals in this study are not clear, the results do suggest a possible mechanistic explanation. Return of graft blood supply was more rapid in the DC-treated group than in

the control group. In most DC-treated animals, graft microcirculation was reestablished by the second day after grafting, whereas grafts in control animals required 7 days to achieve this extent of circulatory restoration. This rapid reestablishment of the graft's microcirculation is compatible with reduced circulatory stasis in the wound bed.^{2,6,7} Any reduction in severity or duration of graft and wound-bed ischemia would be expected to result in a reduced inflammatory response and, in turn, less fibroblast replacement and wound contraction. Early reestablishment of graft circulation in the DC-treated animals appears to have provided the nutrients that are needed for more rapid take of the grafts and either prevented the accumulation of toxic metabolic products or accelerated elimination of them to reduce the inflammatory response and to improve the quality of healing of both the wound and the graft.

We thank Ms. Paulette Langlinais, MS, for her expert technical assistance in preparation of the photographs.

REFERENCES

1. Chu CS, McManus AT, Pruitt BA Jr, Mason AD Jr. Therapeutic effects of silver nylon dressings with weak direct current on *Pseudomonas aeruginosa*-infected burn wounds. *J Trauma* 1988;28:1488-92.
2. Chu CS, McManus AT, Mason AD Jr, et al. Multiple graft harvesting from deep partial thickness scald wounds healed under the influence of weak direct current. *J Trauma* 1990;30:1044-50.
3. Walker HL, Mason AD Jr. A standard animal burn. *J Trauma* 1968;8:1049-51.
4. Deitch EA, Marino AA, Gillespie TE, Albright JA. Silver-nylon: a new antimicrobial agent. *Antimicrob Agents Chemother* 1983;23:356-9.
5. Schmalzel JL, Chu CS, McManus AT. Constant-current and constant-voltage stimulators for wound healing studies. In: Proceedings of the Eighth Annual Conference of the IEEE/Engineering in Medicine and Biology Society, November 7-10, 1986, Fort Worth, Texas. Piscataway, N.J.: IEEE, 1986:1482-4.
6. deCamara DL, Raine TJ, London MD, Robson MC, Heggors JP. Progression of thermal injury: a morphologic study. *Plast Reconstr Surg* 1982;69:491-9.
7. Ehrlich HP, Trelstad RL, Fallon JT. Dermal vascular patterns in response to burn or freeze injury in rats. *Exp Mol Pathol* 1981;34:281-9.
8. Saranto JR, Rubayi S, Zawacki BE. Blisters, cooling, anti-thromboxanes and healing in experimental zone-of-stasis burns. *J Trauma* 1983;23:927-33.
9. Shepard GH. The storage of split-skin grafts on their donor sites. Clinical and experimental study. *Plast Reconstr Surg* 1972;49:115-22.
10. Alvarez OM, Mertz PM, Smerbeck RV, Eaglstein WH. The healing of superficial skin wounds is stimulated by external electric current. *J Invest Dermatol* 1983;81:144-8.
11. Becker RO, Spadaro JA. Treatment of orthopaedic infections with electrically generated silver ions. A preliminary report. *J Bone Joint Surg* 1978;60:871-81.
12. Robinson KR. The responses of cells to electrical fields: a review. *J Cell Biol* 1985;101:2023-7.
13. Webster DA, Spadaro JA, Becker RO, Kramer S. Silver anode treatment of chronic osteomyelitis. *Clin Orthop* 1981;161:105-14.