

AD-A237 662



AD \_\_\_\_\_

ARMY PROJECT ORDER NO: 89PP9945

TITLE: COMBAT TRAUMA SURGERY USING A PORTABLE CONTACT ND-(YAG)  
LASER IN THE PORCINE AND OVINE MODELS (HSC) (CIC3)

PRINCIPAL INVESTIGATOR: Anthony J. Canfield

CONTRACTING ORGANIZATION: William Beaumont Army Medical Center  
El Paso, Texas 79920

REPORT DATE: January 28, 1991

TYPE OF REPORT: Final Report

PREPARED FOR: U.S. ARMY MEDICAL RESEARCH AND DEVELOPMENT COMMAND  
Fort Detrick, Frederick, Maryland 21702-5012

DISTRIBUTION STATEMENT: Approved for Public Release;  
Distribution Unlimited

The findings in this report are not to be construed as an  
official Department of the Army position unless so designated by  
other authorized documents.

91-04037



28 January 1991

Final Report (5/1/89 - 1/31/91)

COMBAT TRAUMA SURGERY USING A PORTABLE CONTACT ND-(YAG)  
LASER IN THE PORCINE AND OVINE MODELS (HSC) (CIC3)

Project Order No.  
89PP9945

Anthony J. Canfield

61102A ✓  
3M161102BS12.ZZ  
WUDA318366

William Beaumont Army Medical Center  
El Paso, Texas 79920

U.S. Army Medical Research and Development Command  
Fort Detrick  
Frederick, Maryland 21702-5012

Approved for public release; distribution unlimited

The laser proved to be effective in the repair of liver and spleen trauma. It provided quicker hemostasis with less blood loss than conventional methods. The technique of laser coagulation of bleeding surfaces through a glass plate was very effective, providing local tamponade during coagulation. Field use of laser surgery is possible and may be beneficial, but further research is needed to explore other applications and refine techniques. Intestinal anastomosis using lasers in another technique that may be of great use in combat trauma.

Smaller and lighter lasers can be built that would be more suitable for field use. This would allow for use with highly mobile surgical units. Laser surgery is still evolving and may have a place in treating battlefield casualties. Further research and development of this field is warranted.

Laser; Trauma; Sheep, Swine; Animals; RAI

Unclassified

Unclassified

Unclassified

Unlimited

## FOREWORD

In conducting research using animals, the investigator(s) adhered to the "Guide for the Care and Use of Laboratory Animals," prepared by the Committee on Care and Use of Laboratory Animals of the Institute of Laboratory Animal Resources, National Research Council (NIH Publication No. 86-23, Revised 1985).

Citations of commercial organizations and trade names in this report do not constitute an official Department of the Army endorsement or approval of the products or services of these organizations.



A-1

## INTRODUCTION:

Blunt and penetrating abdominal trauma often cause injury to the liver. The liver is the most commonly injured organ following penetrating trauma to the abdomen, and the second most commonly injured organ in blunt abdominal trauma. (1) Lacerations and stellate fractures can cause massive intra-abdominal hemorrhage, which must be promptly controlled to prevent exsanguination. It is often difficult to isolate and ligate the bleeding sites in a liver parenchymal injury. The laser permits rapid coagulation of bleeding parenchymal surfaces, and thus allows the surgeon to decrease blood loss and to proceed quickly to repair other injuries. The laser provides another tool to reduce bleeding and operative time in trauma, and has a potential to be used the battlefield surgical setting. This study compares the Nd(YAG) laser to conventional surgical techniques, and tests a portable laser in a battlefield setting.

Since the 1960's various studies have demonstrated the efficacy of lasers in the debridement of burns, resection of intra-abdominal metastasis, excision of decubitus ulcers and in portal hepatectomies.(2)(3)(4)(5)(6) These studies utilized primarily the CO2 laser. The neodymium (Nd)YAG laser, unlike the CO2 laser, has a flexible quartz fiber optic delivery system that allows endoscopic use. 7) It is used for a variety of bleeding and obstructive gastrointestinal conditions, and is safe and effective. (8)

A synthetic sapphire probe for the Nd(YAG) laser makes possible it's use as a contact surgical scalpel.(7) The contact scalpel technique has been compared to the non contact laser technique in liver resections and had less tissue necrosis. Contact Nd(YAG) lasers produce excellent hemostasis, cause less tissue damage, and provide accurate rapid surgical control in hepatic resections.(10)(11)(12) This instrument has many potential uses; among them it has a potential to be extremely effective in controlling bleeding in patients with extensive liver trauma.(4)(5)(6)(10) Studies have shown that liver resections can be performed quicker and with less blood loss by using the Nd(YAG) laser. (15)

The use of the Nd(YAG) laser in pancreatic resection better hemostasis and duodenal preservation. In dog studies, pancreatic resections were performed safely with the Nd(YAG) laser with a significant decrease in operating time.(13) It is presently not known if the use of the laser in pancreatic resection will decrease the incidence of fistula formation occurring post-operatively.

Advantages of laser surgery are as follows: 1. A dry surgical field allowing better visualization. 2. Precise removal of tumors with maximal preservation of normal tissue. 3. Minimal tissue trauma and postoperative edema. 4. Sealing of lymph vessels (diminished lymphatic spread of cancer

cells during surgery). 5. Capacity to sterilize the surgical field of bacteria, tumor cells, and viruses. 6. Ability to use through endoscopes via fiberoptics. 7. Improved hemostasis and decreased blood loss.(14)

Although studies compare the Nd(YAG) laser to conventional methods of surgery, there are no articles that look objectively at it's use for trauma surgery.

Older Nd(YAG) laser systems require 220 volt 40 amp electrical hookups, external continuous flow water and CO2 gas attachments, weigh 500lbs or more, and are large and bulky. It is obvious that these older models would be too cumbersome and difficult to transport in the field. Recent advances in contact Nd(YAG) laser technology have produced a smaller portable laser that runs on regular 110 volt current, 15 amps, 60Hz, has a self contained cooling system and internal CO2 cylinder. Further developments could produce a very small and portable laser that would be effective in battlefield surgical units.

The laser model we used weighs 242 lbs and is 40 inches high, 25.5 inches wide and 16.5 inches deep. It is mounted on wheels and is transported in a shock-absorbing case. The only requirements for transport is that it cannot be placed on it's side or inverted. This laser was transported with other surgical equipment in a 2 1/2 ton truck to our field site in the desert at Fort Bliss. The laser we used is the Eagle Laser System, which was built by Living Technology, a corporate collaboration of BOC 's Ohmeda and Pilkington Medical. Unfortunately this laser is no longer in production, but other portable lasers are now on the market.

In the battlefield setting a portable laser could have a great impact. Reducing the amount of time required per surgery, and reducing the amount of blood products needed to resuscitate injured soldiers, would greatly increase the capacity of our medical system to handle greater numbers of casualties with a limited amount of resources. Also new techniques for bowel anastomosis using absorbable stints and laser welding appear to provide a method for rapid repair of intestinal injuries. The use of new advances in laser surgical techniques in the forward surgical units has the potential to save lives and decrease operating time.

#### **Experimental design:**

This study was divided into 2 phases to ensure objectivity while adequately evaluating the Nd(YAG) laser in both the laboratory and field settings. Phase I of the study involved the evaluation of the laser in controlling bleeding of liver and spleen injuries in the animal research laboratory. The porcine model was selected for this phase because of its anatomical and physiological similarities to humans and due to the fact that

the domestic swine is the current model utilized here for conventional surgical training.

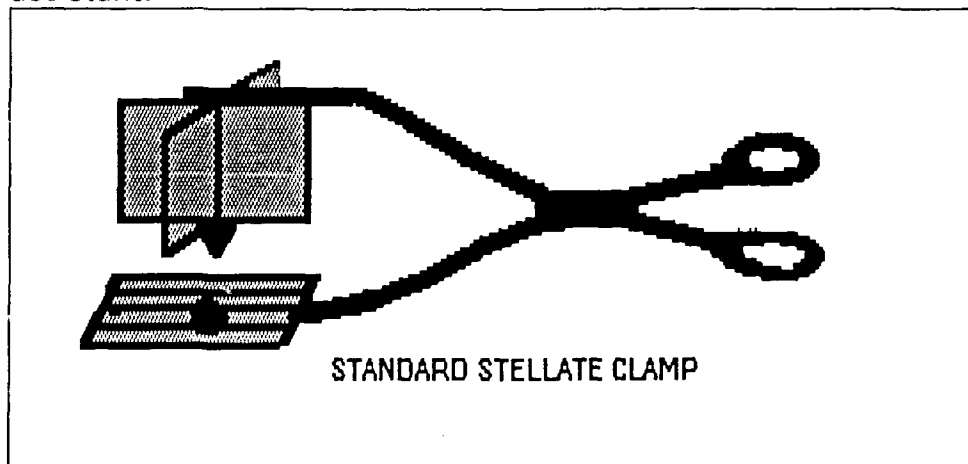
#### **Phase I:**

The animals' food was withheld for a period of 24 hours prior to surgery. Surgeries were conducted in the operating room Bldg.7776 and recovered in the recovery room for 24 hours prior to returning to the routine housing. A semi-liquid diet was fed to all pigs after surgery for 48 hours.

All surgical procedures were conducted with the administration of general anesthesia. Anesthesia was administered and monitored by veterinary staff assigned to the Biological Research Service. Preanesthetics were given 30-45 minutes prior to induction as follows: acetylpromazine 0.1 mg/kg i.m.; atropine sulfate 0.05 mg/kg s.c. and ketamine HCL 5 mg/kg i.m. Anesthesia was induced with Pentathol Sodium 8-16 mg/kg I.V. to effect. An aural indwelling i.v.catheter was placed along with a left femoral venous line and a left femoral arterial line. The anesthesia was monitored with a "Protocol Physiologic Monitor". Which is a very small portable battery operated unit. The swine were intubated and anesthesia maintained during surgery with 1-2% halothane and 100% oxygen via an endotracheal tube. Lactated Ringers was administered intravenously at the rate of 5 cc/kg/hr, along with fluid boluses of 10-20 cc/kg for any blood pressure decrease of 20 mmhg below baseline.

#### **Operative technique:**

The animals were randomized into the laser and conventional groups. The procedures were then alternated between laser and conventional repair so that the learning curve for the techniques would be the same. All of the surgeries were performed by the principle investigator with a surgical assistant.



(figure 1)

After anesthesia was administered, a left subcostal incision was made and a brief exploration of the abdomen performed. After heparinizing with 50 units/kg of heparin sulfate, the left lobe of the liver and the distal

1/3 of the spleen were injured using a standardized stellate clamp. (see figure 1) This produced a combination of blunt and sharp trauma deep into the parenchyma of the tissue. The left subcostal incision was then closed and 15 minutes elapsed from the time of liver and spleen injury until the midline incision was made. The abdomen was then packed with laparotomy sponges to control hemorrhage. The injuries were then inspected and then repaired. Using either the laser or conventional techniques described below.

In the laser group coagulation of the bleeding surfaces of the stellate lacerations were performed with the laser set on 60-80 watts and the bare fiber 1-2 cm from the liver surface. Large vessels were ligated with 3-0 dextron suture. Three pigs had wedge resections performed for ischemic areas of liver distal to the injury. On three of the last pigs we used an exciting new technique of coagulation of the bleeding liver surface through a glass plate. This technique allows for tamponade of the bleeding and very effective coagulation of the surface bleeding. We found this to be the most effective method of coagulation. The spleen laceration was repaired in a similar manner, with five pigs requiring distal splenectomies for ischemia in the distal segment of spleen. The raw surfaces in both of these organs were coagulated with the laser.

In the conventional group the repair was started with holding pressure on the liver and spleen lacerations. The larger vessels were then ligated with 3-0 dextron and liver sutures with 0 chromic on a liver needle were placed to control the hemorrhage. One pig required wedge resection of an ischemic area of liver, and 5 pigs underwent distal splenectomy. This decision was based on the viability of the distal hepatic and splenic segments.

In both groups the total time from midline incision to hemostasis was recorded. Hemostasis was determined when no further coagulation, pressure or suture was required. Fluids given, net sponge weight, irrigation fluid, suction fluid and hematocrits (1 day before and 1 day after) were recorded. The following equations were used:

Estimated blood loss  $EBL = \text{net sponge weight} + \text{suction fluid} - \text{irrigation fluid}$ .

Total blood volume  $TBV = \text{weight in kg} \times 74.5 \text{ cc/kg}$ .

Percent blood volume loss  $PBVL = EBL / (TBV + IV \text{ fluids})$

Hematocrit drop  $HD = HCT (\text{day}-1) - HCT (\text{day} + 1)$

Statistical analysis was performed using the student's t test. After hemostasis was achieved the abdomen was irrigated and the midline closed with a running 2-0 prolene and skin staples.

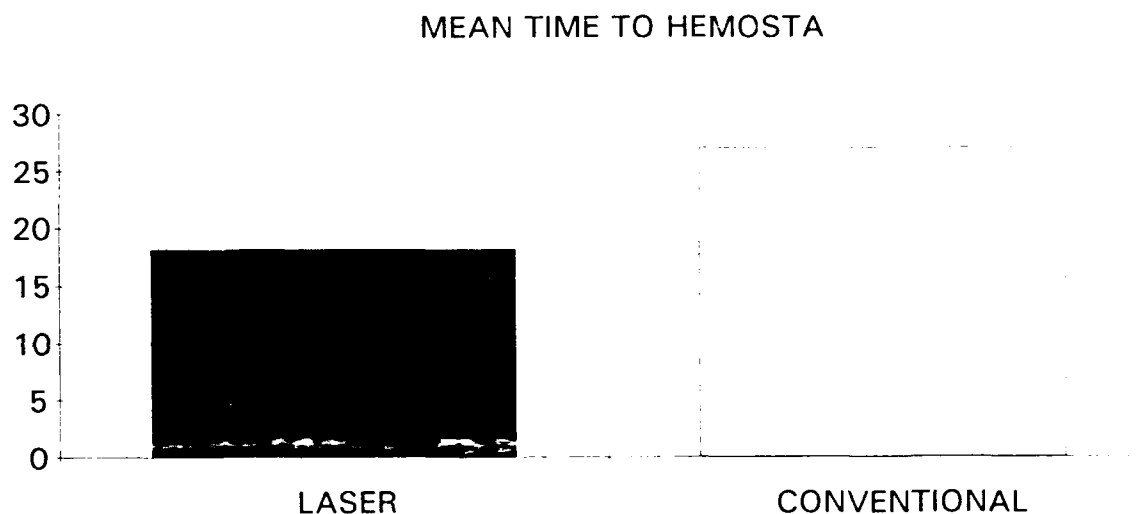
After closure of the abdomen the pigs were recovered from general anesthesia. Following the initial surgical procedure, the swine received

butorphanol tartrate 0.2 mg/kg Q8H for 24 hour as needed for analgesia. All the animals used in this study recieved adequate analgesia. Each animal was observed for 1 week from the surgery and then euthanatized with pentobarbital sodium (60 mg/kg i.v.). A necropsy was performed to assess the extent of liver necrosis and adequacy of repair.

#### Results of Phase I:

The time from the midline incision to hemostasis was significantly shorter in the laser group as compared to the conventional group. Both groups showed a trend toward quicker hemostasis which probably was due to improved efficiency of the surgeon.

Even with this trend, the laser group had significantly shorter times from midline incision to hemostasis.

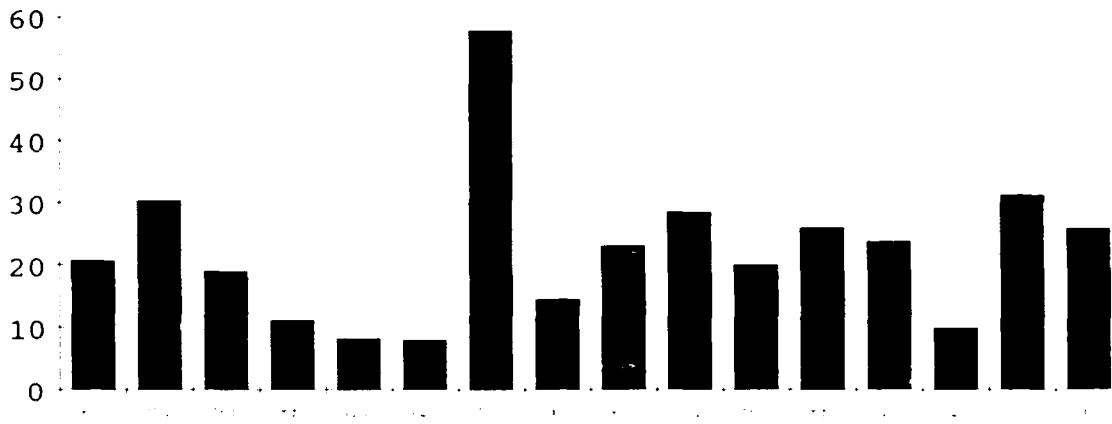


(figure 2)

This time was 18.19 minutes vs 27 minutes for the laser group and conventional group respectively. ( $p < 0.01$ , t-test). (see figure 2 above).




# PERCENT BLOOD VOLUME LOSS



(figure 3)

The laser group showed less blood loss than the conventional group with percent blood volume loss (PBVL) = 21% and 24% respectively. However this was not statistically significant. ( $0.05 > p < 0.10$ ). (see figure 3) This method of measuring blood loss did not take into account IV fluids given or changes in weight. For this reason the hematocrit the day before surgery and 1 day after operation was measured. This allowed for equilibration of blood volume loss with the extracellular volume, and for excess fluid removal by the kidneys. Also this would account for any post operative oozing during the first day postoperatively. Also of note was that in animal L7 above a large hepatic vein was transected with the stellate clamp, and this animal bled profusely during the 15 minute interval between injury and midline incision. This animal required a vigorous fluid resuscitation after it's blood pressure was too low to measure on the physiologic monitor during this interval. Once the midline incision was made and the bleeding vein ligated, the blood pressure returned to normal.

#### MEAN HCT DROP



(figure 4)

When the hematocrit drop from the day before surgery to the day after surgery was compared, there was a difference in the means of the laser and the conventional group. These were 8.38 and 13.75, respectively, showing a significant difference ( $p < 0.01$ ). (see figure 4 above) This is probably a more accurate way of accessing true blood loss than the measurements taken during the procedure.

#### AVERAGE AREA OF NECROSIS



(figure 5)

The amount of tissue necrosis in the liver was measured at the necropsy performed 1 week after the surgery. The specimens were examined by the pathology department at WBAMC. The averages of the depth of tissue necrosis was 8.5 and 8.38 mm for the laser and conventional groups respectively.

## Phase II:

The ovine was the surgical model selected for the field exercise (FTX-TRAUMA). This model was chosen instead of the pig since it is more docile, easier to restrain, and parenteral anesthesia can be maintained more simply and effectively. Anatomically, the majority of the solid viscera and also the small bowel are similar to that of humans. Small ruminants, such as sheep and goats, are also commonly used as models for advanced trauma life support and combat casualty care courses.

The sheep were housed in the Biological Research Service's animal facility. Animals utilized in the field were transported each morning to the FTX site. The animals' food will be withheld for a period of 30 hours prior to the surgical training. The field exercise was conducted on December 9th and 10th, 1989 in the desert at Fort Bliss Texas. Participants in the exercise were volunteers from the Departments of Surgery, Nursing, Clinical Investigations, and the medical company from the 3rd ACR. A field surgical unit was set up in a bunker, with areas for laser surgery and conventional surgery. Power requirements were provided by standard 10 Kilowatt army generators.

The animals were located a short distance away from the surgical area, and anesthesia was administered and monitored by veterinary staff assigned to the Biological Research Service. The animals were sedated with ketamine hydrochloride (22 mg/kg i.m.) and butorphanol tartrate (0.2mg/kg) 30 minutes prior to surgical preparation. An 18 ga. catheter was placed into the cephalic vein for anesthesia and fluids administration, and an internal carotid pressure line was inserted. The sheep were anesthetized with a combination of Ketamine HCl (5 mg/kg) and Diazepam (0.25 mg/kg) intravenously and maintained on a surgical plane of anesthesia during the injuries. The sheep were intubated with a 7mm endotracheal tube to enable ventilatory assist as needed. Lactated ringers was administered intravenously at the rate of 10 mg/kg/hr or greater as required throughout the procedure.

After anesthesia was reached, an incision was made in the left subcostal area and a combination of injuries were made. A combination of 3 injuries out of 4 possible penetrating injuries were made to the liver, spleen, kidney and intestines. The surgical teams were unaware of the exact injuries made to each animal.

The sheep were taken in groups by ground ambulance to the field surgical team area, and triaged to the surgical teams. Each surgical team consisted of a senior surgical resident, supervising staff and several junior residents. The teams resuscitated the injured sheep and performed a laparotomy. One of the teams was equipped with a Nd(YAG) laser along with an electrocautery unit. The conventional team had an electrocautery

unit. Because of the many variables in the field environment and different surgical teams, the field exercise was aimed at testing the laser's ability to perform in field conditions. The laser team operated on 6 sheep, and the conventional team operated on 5 sheep. After the closure of the abdomen, the hemodynamic stability of each animal was assessed and the animal was euthanatized with pentobarbital sodium (60 mg/kg i.v.).

#### **Phase II Results:**

The laser functioned well in the field environment. A single 10 Kilowatt generator provided all the power requirements for both surgical areas with lights, scrub sinks, electrosurgical units and the Nd(YAG) laser. The laser was used to coagulate the bleeding areas of liver and spleen. Several of the spleens were so extensively damaged that a splenectomy was performed. This occurred in both the laser and conventional groups. Overall, the laser performed very well in field conditions.

The disadvantages of this particular laser were as follows. It was bulky and required 4 soldiers to load and unload it from the back of a 2 1/2 ton truck. The laser goggles that we used were dark green and caused some color distortion of the operative field. Newer goggles do not have this problem due to the new clear-gray lenses. This specific laser would be difficult to move if the surgical unit was very mobile. The field exercise seemed to provide a very realistic model of combat trauma and was felt to be realistic by the majority of participants. A videotape of the exercise was previously sent with the quarterly report. Please review the tape with this report. If an additional copy of that videotape is needed, it will be sent on request.

#### **Conclusions:**

The laser proved to be effective in the repair of liver and spleen trauma. It provided quicker hemostasis with less blood loss than conventional methods. The technique of laser coagulation of bleeding surfaces through a glass plate was very effective, providing local tamponade during coagulation. Field use of laser surgery is possible, and may be beneficial, but further research is needed to explore other applications and refine techniques. Intestinal anastomosis using lasers in another technique that may be of great use in combat trauma.

Smaller and lighter lasers can be built that would be more suitable for field use. This would allow for use with highly mobile surgical units. Laser surgery is still evolving, and may have a place in treating battlefield casualties. Further research and development of this field is warranted.

## BIBLIOGRAPHY

1. Sabiston, David C., ed., "Textbook of Surgery". Philadelphia: W.B.Saunders Co., 1986.
2. Schwartz, Seymour I., ed., "Principle of Surgery". New York: McGraw-HillBook Co., 1989.
3. Minton, J. P., et. al., The Laser in Surgery: A 23 Year Perspective, "The American Journal of Surgery", 1986, June, 151:725-729
4. Joffe, S. N. et al. Resection of the Liver with the Nd:YAG Laser. "Surgery, Gynecology and Obstetrics", 1986, Nov. 163:437-442.
5. Orda, R. et. al., Partial Hepatectomies with a Hand<sup>®</sup>held Laser Knife:an Experimental study. "British Journal of Surgery", 1977, 64:857-861.
6. Fidler, James P. et. al., Laser Surgery in Exsanguinating Liver Injury. "Annals of Surgery", 1975, January, 74-80.
7. Daikuzono, N. Joffe, S. N., Artificial Sapphire Probe for Contact Photocoagulation and Tissue Vaporization with the Nd:YAG Laser. "Medical Instrumentation", July-Aug, vol 19, no. 4, 173-178.
8. Joffe, S. N., Contact Neodymium:YAG Laser surgery in Gastroenterology:A Preliminary Report, "Lasers in Surgery and Medicine", 1986, 6:155-157.
10. Meyer, H. J. and Haverkamp, K. Experimental Study of Partial Liver Resection with a Combined CO2 and Nd:YAG Laser. "Lasers in Surgery and Medicine", 1982, 2:149-154.
11. Matthewson, K. et. al., Biological Effects of Intrahepatic Neodymium:Yttrium-Aluminum-Garnet Laser Photocoagulation in Rats. "Gastroenterology", 1987, 93:550-557
12. Schroder, T., et. al., An Experimental Study of the Effects of Electrocautery and Various Lasers on Gastrointestinal tissue, "Surgery", June, 1987, pp. 691-697.
13. Beriatzky, Y. et al., Use of Nd:YAG Laser in Pancreatic Resections with Duodenal Preservation in the Dog. "Lasers in Surgery and Medicine", 1985, 5:507-514.

14. Jako, G. J., Presidential Keynote Address: The Road Toward 21st Century Surgery: New Strategies and Initiatives in Cancer Treatment, "Lasers in Sugery and Medicine", 1987, 7:217-218.
15. Tranberg,K.G. et al., Liver Resection. A Comparison Using the Nd-YAG Laser, an Ultrasonic Surgical Aspirator, or Blunt Dissection. "The American Journal of Surgery". 1986 Mar. 151(3). pp 368-373
16. Tumbleson, M. E. "Swine in Biomedical Research." 3 vol. New York: Plenum Press, 1986.