

AD-A196 766

sent to CORR early June 87

1

DTIC FILE COPY

A PRELIMINARY STUDY OF THE OSTEOGENIC POTENTIAL OF A  
BIODEGRADABLE ALLOPLASTIC-OSTEOINDUCTIVE ALLOIMPLANT

BY

John P. Schmitz D.D.S., M.S.

and

Jeffrey O. Hollinger D.D.S., Ph.D.

DTIC  
ELECTE  
JUN 02 1988  
S D

\*U.S. Army Institute of Dental Research  
Walter Reed Army Medical Center  
Washington D.C. 20307-5300

\* Address for reprints

Running title: Alloplastic-Alloimplant

Key words: Bone Repair, Polymers, Osteoinduction

DISTRIBUTION STATEMENT  
Approved for public release  
Distribution Unlimited

88 6 2 030

**ABSTRACT**

A biodegradable copolymer of polylactide:polyglycolide (PLA:PGA) was combined with allogeneic decalcified freeze-dried bone (DFDB) and implanted into 15 mm diameter defects in the calvaria of 26 New Zealand White rabbits. Similar defects were created in the calvaria of another 26 rabbits. These animals served as controls and did not receive copolymer implants. Upon sacrifice, both the implants and the controls were evaluated clinically, radiographically, and histomorphometrically using a Zeiss Image Analysis System (Videoplan™ version 4.1). Both controls and implants were evaluated in groups at 4, 8, 12, 16, 20, and 24 weeks. When compared with the control defects, the copolymer:DFDB implants displayed a significantly greater volume of trabecular bone ( $p < 0.05$ ). Three of the 15 mm diameter defects displayed evidence of complete osseous bridging at 8 weeks. No adverse host tissue responses were observed histologically in any of the implant specimens.

*bone regeneration*  
*implants*



Accession For	
NTIS CRA&I	<input checked="" type="checkbox"/>
DTIC TAB	<input type="checkbox"/>
Unannounced	<input type="checkbox"/>
Justification	
By	
Distribution	
Availability Codes	
Dist	Availability Codes
A-1	

## INTRODUCTION

Avulsive maxillofacial wounds present challenging problems in reconstructive surgical management. These wounds commonly present as irregularly-shaped discontinuity defects that require some form of bone graft to restore continuity. Defects in the maxillofacial region often occur on broad, flat regions of the skull and face where soft tissue support and facial esthetics are important requirements. A desirable bone repair material should be osteogenic, easily adaptable at the time of surgery, and rigid enough to support the muscles and soft tissues of the face.

For the repair of craniomaxillofacial fibrous union defects, bone obtained from the iliac crest, with its high cancellous-to-cortical ratio, is considered the grafting material of choice.<sup>21</sup> However, bone grafts present special problems including the need for a separate harvesting procedure with its attendant morbidity, the potential limitation of available donor bone, and a failure rate of 9-19% for grafts to the maxillofacial region.<sup>1,17,23</sup> The advantages and disadvantages of autogenous grafts versus alloplastic materials have been reviewed by Wolfe.<sup>39</sup>

The alpha-hydroxy polyesters, polylactide (PLA) and polyglycolide (PGA), have been investigated for use as implant materials in the repair of a variety of soft tissue and osseous wounds. Implanted homopolymers and copolymers of PLA and PGA have been used in a supportive role as suture material, orbital floor replacements, dressings to facilitate healing in tooth

extraction sites, and as biodegradable bone plates and screws.<sup>3,4,5,6,9</sup>

In the early 1960's, Urist discovered that consistent osteoinduction by demineralized bone matrix could be achieved by the control of time, temperature, and molar concentration of HCl.<sup>3,5</sup> Allogeneic decalcified bone implants subsequently, have been used clinically for the correction of craniomaxillofacial deformities and in the treatment of jaw defects.<sup>10,13,24</sup> It was the purpose of this study to examine the osteogenic potential of a biodegradable copolymer (PLA:PGA) combined with allogeneic decalcified freeze-dried bone for craniotomy wound repair.

## **MATERIALS AND METHODS**

### Implant Preparation

A composite alloimplant was prepared by combining 50:50 poly(DL-lactide-co-glycolide) (PLA:PGA) with an inherent viscosity of 0.92 with allogeneic decalcified freeze-dried bone (DFDB). Diaphyseal segments of long bones were removed from donor animals (New Zealand White rabbits) and pulverized in the cold (8°C) to a particle size of 150-590 micrometers. The particles were defatted in 100% ethanol for four hours, decalcified for 24 hrs in 0.6 N HCl at 4°C, rinsed in 0.1M PBS and distilled water, and lyophilized. PLA:PGA copolymer (1 gm.) was solubilized in chloroform, precipitated with methanol and combined with DFDB (500 mg.). The doughy composite was forced into Teflon<sup>®</sup> molds and heat cured for 24 hrs. at 45-48°C. After sterilization with ethylene oxide at room

temperature, the implants were lyophilized for 84 hours at 50 millitorr to remove ethylene oxide residuals.<sup>25</sup> Scanning electron micrographs of the lyophilized implants revealed a polymer lattice interspersed with bone matrix particles (Fig. 1).

### Surgery

Fifty-two, adult, male New Zealand white rabbits were randomly selected and conditioned for two weeks prior to the start of the experiment. Adult status was documented by radiographic confirmation of epiphyseal plate closure. The animals were anesthetized using a xylazine/ketamine technique supplemented with 1.8 ml of 2% lidocaine hydrochloride with 1:100,000 epinephrine. The scalp hair was removed with a depilating agent and the area over the calvaria was scrubbed with ethyl alcohol and povidone iodine for five minutes. Before surgery, 150,000 Units of Flocillin<sup>R</sup> were administered intramuscularly in the left hind leg. Following attainment of a suitable level of anesthesia, an incision was made in the midline from the area of the superior sagittal crest to the middle of the nasal bone. The soft tissues were gently reflected laterally and a 15 mm diameter craniotomy was created using a trephine in a slow-speed dental handpiece (Fig. 2a, 2b). Copious irrigation with normal saline was used throughout the procedure. Care was taken during the entire process to avoid perforating the dura or the superior sagittal sinus. The craniotomy was then irrigated with normal saline. Twenty-six of the animals served as controls while the other twenty-six

animals received circular implant discs (Fig. 3). The periosteum was closed over all the defects and implants and the tissues were closed in layers with 3-0 polyglycolic acid suture. At 4, 8, 12, 16, 20, and 24 weeks animals were euthanatized with an overdose of sodium pentothal, USP. The defects and implants were retrieved along with surrounding host bone and immediately fixed in 70% ethanol. Specimens were removed from the fixative, placed dura-side down on Kodak Ultraspeed Dental X-ray film and radiographed at 90 kVp, 10 Ma, 0.4 seconds using a long-cone technique. Each radiograph was developed in an automatic x-ray processor and printed using a standard enlargement magnification. Specimens were subsequently embedded in polymethylmethacrylate, sectioned at 6 micrometers and stained with a modified Masson-Goldner trichrome stain. Slides were analyzed using a Zeiss Universal microscope (X15.6 magnification) which was interfaced with a Zeiss Image Analysis System (Videoplan™ version 4.1). Six contiguous fields which extended symmetrically across the center of the defect were measured. The trabecular area per specimen was assessed by quantitating total trabecular bony volume (inclusive of calcified trabeculae and osteoid).

## RESULTS

### Gross Examination

#### Control sites

The control defects attempted to heal in a centripetal fashion. Although none of the 15 mm diameter defects healed in 24 weeks, healing was characterized by varying amounts of

fibrous tissue repair (Fig. 4).

#### Implant sites

4 weeks: Extensive fibrous encapsulation of the implants was noted without significant degradation of the polymer (Fig. 5). The implants appeared to have swollen to the point of protruding out of the defect. The wound margins could still be identified.

8 to 16 weeks: Varying amounts of osteosclerotic rimming were present at the wound margins with a reddish-brown soft tissue present within the center of the defect (Fig. 6). In many specimens the central area of the defect still contained areas of residual polymer.

20 to 24 weeks: Organized soft tissue elements and residual polymer were apparent. In implant sites which did not heal, dark red soft tissue was present in the center of the wound.

The implants were well tolerated by all the experimental animals. No adverse soft tissue reactions developed in any of the surgical sites. At necropsy, two of the implant-treated wounds healed completely at eight weeks. The copolymer implants were not completely degraded in all instances at 24 weeks, however, this did not appear to interfere with bone formation.

#### Radiographic Examination

##### Control sites

Control wounds demonstrated a centripetal pattern of bony repair characterized by finger-like extensions and occasional

islands of osseous repair. None of the control wounds displayed radiographic evidence of osseous bridging at 24 weeks (Fig. 7).

#### Implant sites

The implants also demonstrated a centripetal pattern of bony repair. Three of the implants showed trabecular patterns indicative of complete repair at 8 weeks (Fig. 8). Coalescing bony elements were present as irregular fingers and isolated areas of speckled radiopacities.

#### Histologic Examination

##### Control sites

4 weeks: Isolated islands of trabecular bone were present within the defect surrounded by fibrous connective tissue. Wound margins were not eburnated at this time.

8 to 12 weeks: Isolated areas of reparative elements were still present with apparent eburnation of the bony margins. The osseous islands appeared to increase in size with time. Many of these islands contained hematopoietic elements.

16 to 24 weeks: Islands of reparative elements became more numerous and incomplete attempts at osseous bridging were observed (Fig. 9).

##### Implant sites

4 weeks: Isolated islands of bony trabeculae were present throughout the defects. In the healing defects, widespread tessellation and rimming of osteoblasts was present (Fig. 10a, 10b). A minimal inflammatory cell infiltrate was present in areas between the demineralized bone particles.



8 to 12 weeks: Residual polymer was still present in the experimental defects. In three specimens, complete osseous bridging was observed (Fig. 11).

16 to 24 weeks: In areas devoid of healing, bone particles were occasionally present and appeared to be enveloped by fibrous connective tissue. Large islands of coalescing trabeculae were observed with areas of residual demineralized bone surrounded by a prominent round cell infiltrate. Residual copolymer was present in many implant-treated wounds at 24 weeks.

#### Histomorphometric Analysis

The mean pooled trabecular bony volume from the experimental and control data was analyzed using an unpaired Student's t-test (Table I). There was a significant difference in the pooled mean trabecular bony volume between the implant and the control sites ( $p < 0.05$ ). When the control and implant groups were assessed over time, there was no significant difference using a one-way analysis of variance ( $p > 0.05$ ). The rather large standard deviations reflected the inconsistent pattern of trabecular formation which characterized the center of the defects.

#### **DISCUSSION**

Traumatic avulsive wounds and ablative surgical defects commonly result in fibrous union or nonunion discontinuity defects. In testing novel bone repair materials (BRM's), an appropriate animal model which consistently reproduces these defects is essential to predicting success in clinical trials.

The use of critical size defects (CSD's) insures a nonunion wound which will not repair spontaneously with bone.<sup>13</sup> A CSD may be defined as the smallest size intraosseous wound in a particular bone and species of animal which will not heal spontaneously with bone during the lifetime of the animal.<sup>14</sup> Since many bones of the skull and face are of intramembranous origin, it is imperative to test novel bone repair materials in an intramembranous site such as the calvaria, rather than in an endochondral site such as a long bone. The use of a rabbit calvarial CSD model using 15 mm diameter defects satisfies both of these prerequisites and also obviates the need for rigid fixation appliances.<sup>5</sup>

Biodegradable polymers previously have been investigated for use in soft and hard tissue repair, in the internal fixation of fractures, and as intraosseous bone repair materials. A promising use for these polymers has been as carriers for osteogenic agents.

Nelson et al. were the first to assess the osteogenic potential of PLA/PGA copolymer implants in the repair of bony wounds.<sup>26</sup> The copolymer implants resulted in gradual healing of the bony wounds from the peripheries which progressed centrally. The implants were extremely tissue tolerant with little inflammatory or foreign body reaction. Olson et al. compared the tissue response of PLA with that of Gelfoam<sup>®</sup> and Surgicel<sup>®</sup> in healing extraction sites.<sup>27</sup> PLA was observed in the wounds after three months although its retention did not appear to interfere with new bone formation. PLA demonstrated

less inflammatory reaction than either Gelfoam<sup>®</sup> or Surgicel<sup>®</sup>. Brekke et al. investigated the influence of PLA mesh on the incidence of localized alveolar osteitis.<sup>3</sup> They concluded that the use of PLA mesh substantially reduced the incidence of mandibular third molar "wound failure" and that the PLA demonstrated a hemostatic effect. Hollinger evaluated the osteogenic potential of PLA:PGA copolymer implants in osseous wounds.<sup>13</sup> He showed that although the implant material was still present at 42 days, it displayed an accelerated rate of healing as compared to control bony wounds. Hollinger was the first to use PLA:PGA as a carrier for a calcification initiator, diposphoinositide-lysozyme (DPI-L).<sup>14</sup> When DPI-L was combined with a PLA-PGA copolymer for the repair of endochondral wounds in rats and in the repair of mandibular discontinuity defects in dogs, the implants displayed an accelerated rate of repair as compared to the control wounds.<sup>14,16</sup> Higashi et al. used PLA-hydroxyapatite (PLA-HA) composites to repair endochondral wounds in rats.<sup>12</sup> The PLA was observed to be rapidly resorbed and replaced by new bone which formed in direct contact with the HA.

#### Biocompatibility

There are no reports in the literature describing adverse systemic responses to polyester sutures or bone repair materials. Furthermore, the high degree of biocompatibility of PLA:PGA copolymers as bone implants has been described.<sup>2,13,22</sup> This was further supported by the high degree of tissue tolerance seen with the demineralized bone/copolymer composite.

A PLA-HA composite was shown to become drastically acidic in vitro, reaching a pH of 3.4 in one week and remaining at that level for five weeks.<sup>12</sup> This localized pH drop may account for the lack of consistent healing pattern observed in many of the copolymer-DFDB composite implants.

#### Degradation

The process by which the alpha-hydroxy polyesters biodegrade is principally by non-specific hydrolytic scission.<sup>22</sup> Lactic acid, which is generated when PLA degrades, becomes incorporated into the tricarboxylic acid cycle, and is excreted by the lungs as carbon dioxide and water.<sup>2</sup> PGA, on the other hand, is broken down hydrolytically as well as by nonspecific esterases and carboxypeptidases.<sup>36</sup> The resultant glycolic acid monomers are either excreted in the urine or enter the tricarboxylic acid cycle.

The rate at which the PLA:PGA implants degrade is dependent on five factors:

1. Molar ratio of the constituents.
2. Porosity of the implants.
3. Vascularity of the recipient site.
4. Degree of crystallinity of the constituents.
5. Average molecular weight.

In general, PLA:PGA copolymers with a greater molar ratio of PLA tend to degrade more slowly than those with a greater amount of PGA.<sup>7</sup> A 50:50 PLA:PGA molar ratio was chosen for this composite because its half-life appeared to be commensurate with normal fracture repair (four to six weeks).<sup>22</sup>

The total surface area of the polymer available for interface reactions with the host also appears to influence the rate of degradation. Porous implants will degrade more rapidly than dense glassy implants. During fabrication of the implants used in this study, the control of porosity was possible only to a limited extent. An overriding concern was the fabrication of a rigid implant which could be carved and contoured at the time of surgery.

The degradation rate is also governed by the vascularity of the recipient site. Implants placed in the mandible appear to degrade more rapidly than implants placed in the calvaria.<sup>16</sup>

The degree of polymer crystallinity significantly effects the rate of water sorption. Consequently, the L(-) form degrades more slowly than the D,L form.<sup>19,20</sup> Additionally, the alpha-hydroxy copolymers are less crystalline than their constituent homopolymers and will degrade more slowly.<sup>22</sup> A 50:50 poly(D,L-lactide-co-glycolide) implant was chosen because of its previous history of predictable degradation in endochondral wounds.<sup>13</sup>

An important factor governing degradation is the concept of a polymer's average molecular weight which is often described in terms of a polymer's inherent viscosity. Polymers that are highly viscous (high average molecular weight) will undergo slower biodegradation than those with a lower molecular weight and lower viscosity.<sup>15</sup> The presence of residual polymer at 24 weeks may be attributed to its viscosity in a relatively avascular site (e.g. calvaria). Previous studies with this

same copolymer in the repair of mandibular discontinuity defects showed complete biodegradation by 8-12 weeks.<sup>15</sup>

#### Mechanism of Action

Allogeneic decalcified freeze-dried bone is postulated to provide a substratum for the differentiation of perivascular mesenchymal cells into chondrocytes and ultimately into osteoblasts. This process is known as osteoinduction. Urist has proposed that the inducer was a protein, specifically, bone morphogenetic protein (BMP).<sup>36</sup> Reddi and coworkers, on the other hand, have proposed surface charge and geometry as well as inducer proteins as the putative factors in the osteoinduction process.<sup>29,30,31,32</sup>

Following the heterotopic implantation of decalcified bone matrix, a sequential development of endochondral bone is initiated.<sup>31</sup> Initially, the implant forms a plaque consisting of a conglomerate of decalcified matrix, fibrin, and neutrophils. Limited proteolysis is thought to cause the release of chemotactic factors and other matrix proteins into the surrounding milieu. The arrival of perivascular mesenchymal cells by chemotaxis is followed by their attachment to the bone matrix. The linear array of a random copolymer such as 50:50 PLA:PGA, which remotely resembles the linear array of the collagen molecule, may play a crucial role in the anchorage dependency of cells.<sup>34</sup> This anchorage dependency is essential in the early phase of the osteoinduction cascade. Cell attachment to bone matrix, thought to be promoted by fibronectin and related cell adhesive proteins, helps to bring

the putative inductor in contact with focal cell surface receptors. The subsequent release of mitogenic factors from the matrix (hSGF) helps to promote growth and proliferation of cells.<sup>37</sup> These cells differentiate into chondrocytes and ultimately osteoblasts. Osteoblasts are subsequently seen to be anchored to the periphery of the decalcified bone particles and to elaborate osteoid in a vectorial fashion.

Particulate cancellous marrow bone grafts presently are considered the material of choice for maxillofacial bone grafts. These grafts are primarily used to stabilize mobile skeletal segments, and to augment and construct new skeletal contour. However, the resorption of these grafts for certain utilities has been estimated to be in the range of 30-70% of graft bulk.<sup>24</sup> Demineralized bone powders, on the other hand, have not been reported to undergo resorption during bone induction and have complication rates no greater than those of conventional bone grafts. While impressive results have been documented clinically<sup>10,11,18,24,25</sup>, Mulliken et al.<sup>24</sup> noted that "Bone powder fails to provide immediate stability and structure needed in many types of skeletal reconstruction and construction". In this regard, PLA:PGA copolymers may be an acceptable carrier vehicle which also provides for immediate stability and structure conducive to repair of the craniofacial skeleton.

TABLE I. Trabecular Bony Volume of Implants Versus Controls

WEEKS	ANIMALS	CONTROLS	IMPLANTS
4	8	0.125+/-0.034	0.345+/-0.201
8	10	0.082+/-0.038	0.328+/-0.152
12	10	0.143+/-0.060	0.301+/-0.121
16	8	0.110+/-0.046	0.250+/-0.034
20	8	0.194+/-0.097	0.257+/-0.221
24	8	0.272+/-0.133	0.196+/-0.065
Mean +/- SEM			
Mean +/- SD		0.151+/-0.151	0.282+/-0.280

p Value <0.05

\*Statistical data generated using an unpaired Student's t-test



## LEGENDS

Figure 1. Scanning electron micrograph of the PLA:PGA/DFDB composite. Particles of demineralized bone ( ) can be seen to be invested within the copolymer matrix surrounded by open voids up to 200 micrometers wide (original magnification, X100.)

Figure 2a. Dried skull showing approximate size of the defect in relation to the overall calvaria.

Figure 2b. Surgical site following removal of the calvarial disc. Note the integrity of the dura and an intact superior sagittal sinus (arrow).

Figure 3. Polymer composite implant at the time of insertion demonstrating excellent adaptation to the bony wound margins.

Figure 4. 8 week control defect at retrieval. Fibrous repair tissue is present as a thin membrane over the defect. The wound margins are clearly demarcated (arrows).

Figure 5. 4 week implant at retrieval. Implant is found to have swollen within the defect with a fibrous tissue capsule present over the implant.

Figure 6. 8 week implant showing areas of osteosclerotic rimming (arrows).

Figure 7. Radiograph of a 24 week control defect with isolated bony islands present (arrows).

Figure 8. Radiograph of an 8 week implant showing trabecular patterns present throughout the defect.

Figure 9. Macrophotograph of a 24 week control defect. Note fibrous connective bridge.

Figure 10a. Tessellation and rimming of osteoblasts in a 4 week

specimen. Areas of amalgamated bone particles are present (arrows)(modified Masson-Goldner trichrome stain; original magnification,X64.)

Figure 10B. Anchorage of pre-osteoblasts to demineralized bone matrix in a 4 week implant. An active osteoblast may be seen anchored to the same particle (modified Masson-Goldner trichrome stain; original magnification,X100.)

Figure 11. Macrophotograph of a 20 week implant showing bony trabeculae continuous across the defect.

## REFERENCES

1. Boyne, P. J., and Zarem, H.: Osseous reconstruction of the resected mandible. *Am. J. Surg.* 132:49, 1976.
2. Brady, J. M., Cutright, D. E., Miller, R. A., Battistone, G. C., and Hunsuck, E. E.: Resorption rate, route of elimination, and ultrastructure of the implant site of polylactic acid in the abdominal wall of the rat. *Oral Surg.* 7:155, 1973.
3. Brekke, J. H., Olson, R. A. J., Scully, J. R., and Osbon, D. B.: Influence of polylactic acid mesh on the incidence of localized osteitis. *Oral Surg.* 56:240, 1983.
4. Christel, P., Chabot, F., Leray, J. L., Morin, C., and Mort, M.: Biodegradable composites for internal fixation. In G. D. Winter, D. F. Giobbones, and H. Plena (eds.): *Biomaterials*. New York. John Wiley and Sons, 1982, p.271.
5. Cutright, E. E., and Beasley, J. D.: Fracture reduction using a biodegradable material, polylactic acid. *J. Oral Surg.* 29:393, 1971.
6. Cutright, D. E., and Hunsuck, E. E.: The repair of fractures of the orbital floor using biodegradable polylactic acid. *Oral Surg.* 33:28, 1972.
7. Cutright, D. E., Perez, B., Beasley, J. D., Larson, W. L., and Posey, W. R.: Degradation rates of polymers and copolymers of polylactic and polyglycolic acids. *Oral Surg.* 37:142, 1974.
8. Frame, J. W.: A convenient animal model for testing bone substitute materials. *J. Oral Surg.* 38:176, 1980.
9. Getter, L., Cutright, D. E., Bhaskar, S. N., and Augsberg, J. K.: A biodegradable intraosseous appliance in the treatment of mandibular fractures. *J. Oral Surg.* 30:344, 1972.
10. Glowacki, J., Kaban, L. B., Murray, J. E., Folkman, J., and Mulliken, J. B.: Application of the biological principle of induced osteogenesis for craniofacial defects. *Lancet* 1:959, 1981.
11. Glowacki, J., and Mulliken, J. B.: Demineralized bone implants. *Clin. Plast. Surg.* 12:233, 1985.
12. Higashi, S., Yamamuro, T., Nakamura, T., Ikada, Y., Hyon, S. H., and Jamshidi, K.: Polymer-hydroxyapatite composites for biodegradable bone fillers. *Biomaterials* 7:183, 1986.

13. Hollinger, J. O.: Preliminary report on the osteogenic potential of a biodegradable copolymer of polylactide (PLA) and polyglycolide (PGA). *J. Biomed. Mater. Res.* 17:71, 1983.
14. Hollinger, J. O.: Facilitation of osseous healing by a proteolipid copolymer material. Ph.D. Dissertation, Baltimore, University of Maryland, 1983.
15. Hollinger, J. O., and Battistone, G. C.: Biodegradable bone repair materials. *Synthetic polymers and ceramics. Clin. Orthop.* 207:290, 1986.
16. Hollinger, J. O., and Schmitz, J. P.: Restoration of bone discontinuity defects in dogs using a biodegradable implant. *J. Oral Maxillofac. Surg.* 45:000, 1987.
17. James, J. D., Geist, E. T., and Gross, B. D.: Adynamic ileus as a complication of iliac bone removal: Report of two cases. *J. Oral Surg.* 39:289, 1981.
18. Kaban, L. B., Mulliken, J. B., and Glowacki, J.: Treatment of jaw defects with demineralized bone implants. *J. Oral Maxillofac. Surg.* 40:623, 1982.
19. Kulkarni, R. K., Pani, K. C., Neuman, C., and Leonard, F.: Polylactic acid for surgical implants. *Arch. Surg.* 93:839, 1966.
20. Kulkarni, R. K., Moore, E. G., Hegyeli, A. F., and Leonard, F.: Biodegradable poly(lactic acid) polymers. *J. Biomed. Mater. Res.* 5:169, 1971.
21. Marx, R. E., and Kline, S. N.: Principles and methods of osseous reconstruction. *Internat. Adv. Surg. Oncol.* 6:167, 1983.
22. Miller, R. A., Brady, J. M., and Cutright, D. E.: Degradation rates of oral resorbable implants (polylactates and polyglycolates): rate modification with changes in PLA/PGA copolymer ratios. *J. Biomed. Mater. Res.* 11:711, 1977.
23. Mrazik, J., Amato, C., Leban, S., and Mashberg, A.: The ileum as a source of autogenous bone for grafting: Clinical considerations. *J. Oral Surg.* 38:29, 1980.
24. Mulliken, J. B., Glowacki, J., Kaban, L. B., and Murray, J. E.: Use of demineralized allogeneic bone implants for the correction of maxillocraniofacial deformities. *Ann. Surg.* 194:366, 1981.
25. Mulliken, J. B., Kaban, L. B., and Glowacki, J.: Induced osteogenesis--the biological principle and clinical applications. *J. Sur. Res.* 37:487, 1984.

26. Nelson, J. F., Stanford, H. G., and Cutright, D. E.: Evaluation and comparisons of biodegradable substances as osteogenic agents. *Oral Surg.* 43:836, 1977.
27. Olson, R. A. J., Roberts, D. L., and Osbon, D. B.: A comparative study of polylactic acid, gelfoam, and surgical in healing extraction sites. *Oral Surg.* 53:441, 1982.
28. Prolo, D. J., Pedrotti, P. W., and White, D. H.: Ethylene oxide sterilization of bone, dura mater, and fascia lata for human transplantation. *Neurosurgery* 6:529, 1980.
29. Reddi, A. H., and Huggins, C. B.: Influence of geometry of transplanted tooth and bone on transformation of fibroblasts. *Proc. Soc. Exp. Biol. Med.* 143:643, 1973.
30. Reddi, A. H., and Huggins, C. B.: Cyclic electrochemical inactivation and restoration of competence of bone matrix to transform fibroblasts. *Proc. Natl. Acad. Sci. U.S.A.* 71:1648, 1974.
31. Reddi, A. H.: Implant-stimulated interface reactions during collagenous bone matrix-induced bone formation. *J. Biomed. Mater. Res.* 19:233, 1985.
32. Sampath, T. K., and Reddi, A. H.: Dissociative extraction and reconstitution of extracellular matrix components involved in local bone differentiation. *Proc. Natl. Acad. Sci. U.S.A.* 78:7599, 1981.
33. Schmitz, J. P., and Hollinger, J. O.: The critical size defect as an experimental model for craniomandibulofacial nonunions. *Clin. Orthop.* 205:299, 1986.
34. Stoker, M., O'Neill, C., Berryman, S., and Waxman, V.: Anchorage and growth regulation in normal and virus transformed cells. *Int. J. Cancer.* 3:683, 1968.
35. Urist, M. R.: Bone: Formation by autoinduction. *Science.* 150:893, 1965.
36. Urist, M. R., Mikulski, A., and Lietze, A.: Solubilized and insolubilized bone morphogenetic protein. *Proc. Natl. Acad. Sci. U.S.A.* 76:1828, 1979.
37. Urist, M. R., DeLange, R. J., and Finerman, G. A. M.: Bone cell differentiation and growth factors. *Science* 220:680, 1983.
38. Williams, D. F., and Mort, E.: Enzyme-accelerated hydrolysis of polyglycolic acid. *J. Bioengin.* 1:23, 1977.
- ✓ 39. Wolfe, A. A.: Autogenous bone grafts versus alloplastic materials in maxillofacial surgery. *Clin. Plast. Surg.* 9:539, 1982.

In conducting the research described in this report, the investigators adhered to the "Guide for the Care and Use of Laboratory Animals" as promulgated by the Committee on the Revision of the Guide for Laboratory Animal Facilities and Care of the Institute of Laboratory Animal Resources, National Research Council.

Commercial materials and equipment are identified in this report to specify the investigative procedure. Such identification does not imply recommendation or endorsement, or that the materials and equipment are necessarily the best available for the purpose. Furthermore, the opinions expressed herein are those of the authors and are not to be construed as those of the U.S. Army Medical Department.



Figure 1



Figure 2a





Figure 2b




Figure 3



Figure 4

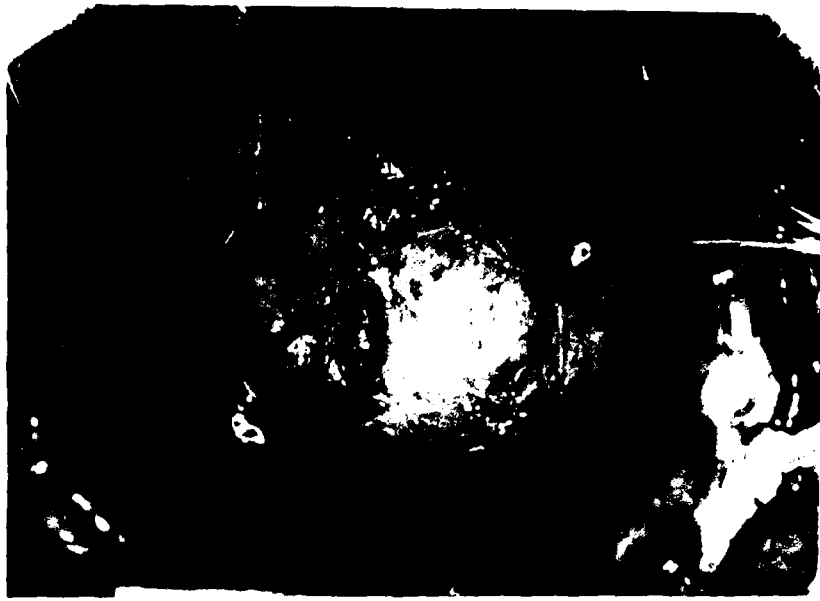

Figure 5




Figure 6




Figure 7

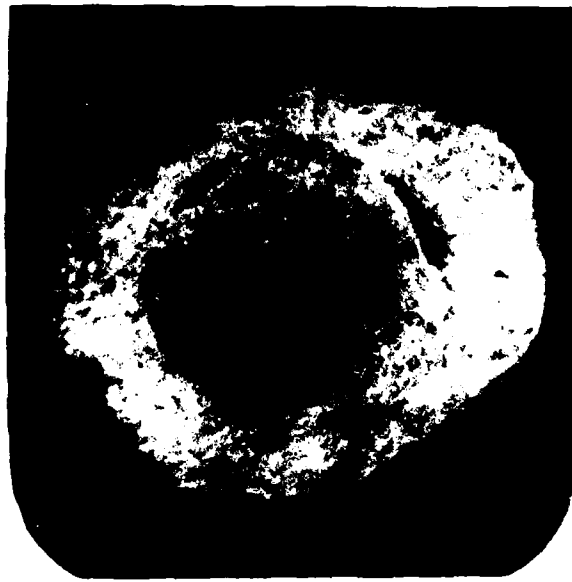

Figure 8



Figure 9



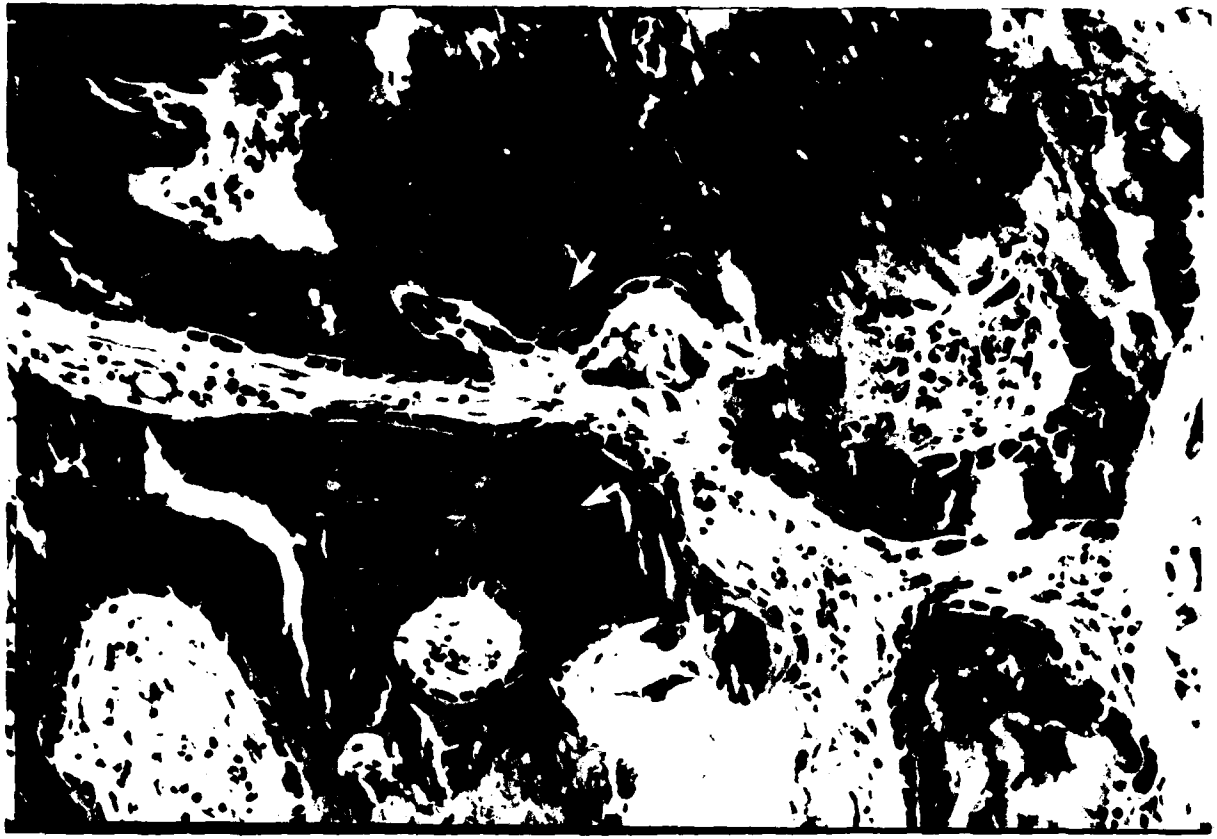

Figure 10a




Figure 10b



Figure 11

TABLE I. Trabecular Bony Area ( $\text{mm}^2/\text{mm}^2$ ) of Implants Versus Controls\*

WEEKS	ANIMALS**	CONTROLS	IMPLANTS
4	8	0.125 $\pm$ 0.034	0.345 $\pm$ 0.201
8	10	0.082 $\pm$ 0.038	0.328 $\pm$ 0.152
12	10	0.143 $\pm$ 0.060	0.301 $\pm$ 0.121
16	8	0.110 $\pm$ 0.046	0.250 $\pm$ 0.034
20	8	0.194 $\pm$ 0.097	0.257 $\pm$ 0.221
24	8	0.272 $\pm$ 0.133	0.196 $\pm$ 0.065
<b>Mean <math>\pm</math> SEM</b>			
<b>Mean <math>\pm</math> SD</b>		0.151 $\pm$ 0.151	0.282 $\pm$ 0.280

p Value <0.05

\*Statistical data generated using an unpaired Student's t-test

\*\*Half of each group of animals are controls and implants.

## LEGENDS

Figure 1. Scanning electron micrograph of the PLA:PGA/DFDB composite. Particles of demineralized bone (\*) can be seen to be invested within the copolymer matrix surrounded by open voids up to 200 micrometers wide (original magnification, X100.)

Figure 2a. Dried skull showing approximate size of the defect in relation to the overall calvaria.

Figure 2b. Surgical site following removal of the calvarial disc. Note the integrity of the dura and an intact superior sagittal sinus (arrow).

Figure 3. Polymer composite implant at the time of insertion demonstrating excellent adaptation to the bony wound margins.

Figure 4. 8 week control defect at retrieval. Fibrous repair tissue is present as a thin membrane over the defect. The wound margins are clearly demarcated (arrows).

Figure 5. 4 week implant at retrieval. Implant is found to have swollen within the defect with a fibrous tissue capsule present over the implant.

Figure 6. 8 week implant showing areas of osteosclerotic rimming (arrows).

Figure 7. Radiograph of a 24 week control defect with isolated bony islands present (arrows).

Figure 8. Radiograph of an 8 week implant showing trabecular patterns present throughout the defect.

Figure 9. Macrophotograph of a 24 week control defect. Note fibrous connective bridge.

Figure 10a. Tessellation and rimming of osteoblasts in a 4 week specimen. Areas of amalgamated bone particles are present surrounded by areas of new bone (arrows)(modified Masson-Goldner trichrome stain; original magnification,X64.)

Figure 10b. Anchorage of pre-osteoblasts to demineralized bone matrix in a 4 week implant. An active osteoblast may be seen anchored to the same particle (modified Masson-Goldner trichrome stain; original magnification,X100.)

Figure 11. Macrophotograph of a 20 week implant showing islands of bony trabeculae extending across the defect.

## REFERENCES

1. Boyne, P. J.: *Int. J. Maxillofac. Surg.* Osseous reconstruction of the resorbed mandible. *Am. J. Surg.* 132:49, 1976.
2. Brady, J. M., Cutright, D. E., Miller, R. A., Battistone, G. C., and Hunsuck, E. E.: Resorption rate, route of elimination, and ultrastructure of the implant site of polylactic acid in the abdominal wall of the rat. *Oral Surg.* 7:155, 1973.
3. Brekke, J. H., Olson, R. A. J., Scully, J. R., and Osbon, D. B.: Influence of polylactic acid mesh on the incidence of localized osteitis. *Oral Surg.* 56:240, 1983.
4. Christel, P., Chabot, F., Leray, J. L., Morin, C., and Mort, M.: Biodegradable composites for internal fixation. *In* G. D. Winter, G. F. Giobbone, and H. Plena (eds.): *Biomaterials*. New York. John Wiley and Sons, 1982, p.271.
5. Cutright, E. E. and Beasley, J. D.: Fracture reduction using a biodegradable material, polylactic acid. *J. Oral Surg.* 29:393, 1971.
6. Cutright, D. E. and Hunsuck, E. E.: The repair of fractures of the orbital floor using biodegradable polylactic acid. *Oral Surg.* 33:28, 1972.
7. Cutright, D. E., Perez, B., Beasley, J. D., Larson, W. L., and Posey, W. R.: Degradation rates of polymers and copolymers of polylactic and polyglycolic acids. *Oral Surg.* 37:142, 1974.
8. Frame, J. W.: A convenient animal model for testing bone substitute materials. *J. Oral Surg.* 38:176, 1980.
9. Getter, L., Cutright, D. E., Bhaskar, S. N., and Augsberg, J. K.: A biodegradable intraosseous appliance in the treatment of mandibular fractures. *J. Oral Surg.* 30:344, 1972.
10. Glowacki, J., Kaban, L. B., Murray, J. E., Folkman, J., and Mulliken, J. B.: Application of the biological principle of induced osteogenesis for craniofacial defects. *Lancet* 1:959, 1981.
11. Glowacki, J. and Mulliken, J. B.: Demineralized bone implants. *Clin. Plast. Surg.* 12:233, 1985.
12. Higashi, S., Yamamuro, T., Nakamura, T., Ikada, Y., Hyon, S. H., and Jamshidi, K.: Polymer-hydroxyapatite composites for biodegradable bone fillers. *Biomaterials* 7:183, 1986.

13. Hollinger, F. D.: Preliminary report on the osteogenic potential of a biodegradable copolymer of polylactide (PLA) and polyglycolide (PGA). *J. Biomed. Mater. Res.* 17:711, 1983.
14. Hollinger, F. D.: Facilitation of osseous healing by a proteolipid copolymer material. Ph.D. Dissertation, Baltimore, University of Maryland, 1983.
15. Hollinger, F. D. and Battistone, G. C.: Biodegradable bone repair materials. *Synthetic polymers and ceramics. Clin. Orthop.* 207:290, 1986.
16. Hollinger, F. D. and Schmitz, J. P.: Restoration of bone discontinuity defects in dogs using a biodegradable implant. *J. Oral Maxillofac. Surg.* 45:000, 1987.
17. James, J. D., Geist, F. T., and Gross, B. D.: A dynamic ileus as a complication of iliac bone removal: Report of two cases. *J. Oral Surg.* 39:289, 1981.
18. Kaban, L. B., Mulliken, J. B., and Glowacki, J.: Treatment of jaw defects with demineralized bone implants. *J. Oral Maxillofac. Surg.* 40:623, 1982.
19. Kulkarni, R. K., Pani, K. C., Neuman, C., and Leonard, F.: Polylactic acid for surgical implants. *Arch. Surg.* 93:839, 1966.
20. Kulkarni, R. K., Moore, E. G., Hegyeli, A. F., and Leonard, F.: Biodegradable poly(lactic acid) polymers. *J. Biomed. Mater. Res.* 5:169, 1971.
21. Marx, R. E. and Kline, S. N.: Principles and methods of osseous reconstruction. *Internat. Adv. Surg. Oncol.* 6:167, 1983.
22. Miller, R. A., Brady, J. M., and Cutright, D. E.: Degradation rates of oral resorbable implants (polylactates and polyglycolates): rate modification with changes in PLA/PGA copolymer ratios. *J. Biomed. Mater. Res.* 11:711, 1977.
23. Mrazik, J., Amato, C., Leban, S., and Mashberg, A.: The ileum as a source of autogenous bone for grafting: Clinical considerations. *J. Oral Surg.* 38:29, 1980.
24. Mulliken, J. B., Glowacki, J., Kaban, L. B., and Murray, J. E.: Use of demineralized allogeneic bone implants for the correction of maxillocraniofacial deformities. *Ann. Surg.* 194:366, 1981.



25. Mulliken, J. B., Haban, M. E., and Glowacki, J.: Induced osteogenesis--the biological principle and clinical applications. *J. Biomed. Mater. Res.* 17:487, 1984.
26. Nelson, J. B., Cantieri, E. J., and Cutright, D. E.: Evaluation and comparisons of biodegradable substances as osteogenic agents. *Oral Surg.* 43:836, 1977.
27. Olson, R. A., Roberts, D. L., and Osbon, D. B.: A comparative study of polylactic acid, gelfoam, and surgical in healing extraction sites. *Oral Surg.* 53:441, 1982.
28. Prolo, D. J., Pedrotti, P. W., and White, D. H.: Ethylene oxide sterilization of bone, dura mater, and fascia lata for human transplantation. *Neurosurgery* 6:529, 1980.
29. Reddi, A. H. and Huggins, C. B.: Influence of geometry of transplanted tooth and bone on transformation of fibroblasts. *Proc. Soc. Exp. Biol. Med.* 143:643, 1973.
30. Reddi, A. H. and Huggins, C. B.: Cyclic electrochemical inactivation and restoration of competence of bone matrix to transform fibroblasts. *Proc. Natl. Acad. Sci. U.S.A.* 71:1648, 1974.
31. Reddi, A. H.: Implant-stimulated interface reactions during collagenous bone matrix-induced bone formation. *J. Biomed. Mater. Res.* 19:233, 1985.
32. Sampath, T. K. and Reddi, A. H.: Dissociative extraction and reconstitution of extracellular matrix components involved in local bone differentiation. *Proc. Natl. Acad. Sci. U.S.A.* 78:7599, 1981.
33. Schmitz, J. P. and Hollinger, J. O.: The critical size defect as an experimental model for craniomandibulofacial nonunions. *Clin. Orthop.* 205:299, 1986.
34. Stoker, M., O'Neill, C., Berryman, S., and Waxman, V.: Anchorage and growth regulation in normal and virus transformed cells. *Int. J. Cancer.* 3:683, 1968.
35. Urist, M. R.: Bone: Formation by autoinduction. *Science.* 150:893, 1965.
36. Urist, M. R., Mikulski, A., and Lietze, A.: Solubilized and insolubilized bone morphogenetic protein. *Proc. Natl. Acad. Sci. U.S.A.* 76:1828, 1979.
37. Urist, M. R., DeLange, R. J., and Finerman, G. A. M.: Bone cell differentiation and growth factors. *Science* 220:680, 1983.

18. Williams, D. S. and Mort, E.: Enzyme-accelerated hydrolysis of polyglycol. *Artif. Organs*. 1:23, 1977.
19. Wolfe, A. V.: Autogenous bone grafts versus alloplastic materials in maxillofacial surgery. *Clin. Plast. Surg.* 9:539, 1982.