

MICROCOPY RESOLUTION TEST CHART
NATIONAL BUREAU OF STANDARDS 1963 A

12

AD _____

SURGICAL TOOTH IMPLANTS, COMBAT AND FIELD

DTIC FILE

AD-A183 742

ANNUAL REPORT

CRAIG R. HASSLER

November 15, 1985

DTIC
ELECTE
AUG 24 1987
S D
C/D

Supported by

U.S. ARMY MEDICAL RESEARCH AND DEVELOPMENT COMMAND
Fort Detrick, Frederick, Maryland 21701-5012

Contract No. DAMD17-82-C-2020

BATTELLE
Columbus Division
505 King Avenue
Columbus, Ohio 43201-2693

DOD DISTRIBUTION STATEMENT

Approved for public release; distribution unlimited

The findings in this report are not to be construed
as an official Department of the Army position
unless so designated by other authorized documents.

87 8 17 055

REPORT DOCUMENTATION PAGE

Form Approved
OMB No 0704-0188
Exp Date Jun 30, 1986

1a REPORT SECURITY CLASSIFICATION Unclassified		1b RESTRICTIVE MARKINGS	
2a. SECURITY CLASSIFICATION AUTHORITY		3 DISTRIBUTION / AVAILABILITY OF REPORT Approved for public release; distribution unlimited	
2b. DECLASSIFICATION / DOWNGRADING SCHEDULE		4 PERFORMING ORGANIZATION REPORT NUMBER(S)	
4 PERFORMING ORGANIZATION REPORT NUMBER(S)		5. MONITORING ORGANIZATION REPORT NUMBER(S)	
6a. NAME OF PERFORMING ORGANIZATION BATTELLE Columbus Laboratories	6b. OFFICE SYMBOL (If applicable)	7a. NAME OF MONITORING ORGANIZATION	
6c. ADDRESS (City, State, and ZIP Code) 505 King Avenue Columbus, Ohio 43201		7b. ADDRESS (City, State, and ZIP Code)	
8a. NAME OF FUNDING / SPONSORING ORGANIZATION U.S. Army Medical Research & Development Command	8b. OFFICE SYMBOL (If applicable)	9. PROCUREMENT INSTRUMENT IDENTIFICATION NUMBER DAMD17-82-C-2020	
8c. ADDRESS (City, State, and ZIP Code) Fort Detrick, Frederick, Maryland 21701-5012		10. SOURCE OF FUNDING NUMBERS	
		PROGRAM ELEMENT NO. 62775A	PROJECT NO 3S162. 775A825
		TASK NO AA	WORK UNIT ACCESSION NO 055
11. TITLE (Include Security Classification) (U) Surgical Tooth Implants, Combat and Field			
12. PERSONAL AUTHOR(S) Craig R. Hassler, Ph.D.			
13a. TYPE OF REPORT Annual Report	13b. TIME COVERED FROM 7/15/84 TO 8/15/85	14. DATE OF REPORT (Year, Month, Day) 15 November 1985	15 PAGE COUNT 77
16. SUPPLEMENTARY NOTATION			
17. COSATI CODES		18. SUBJECT TERMS (Continue on reverse if necessary and identify by block number)	
FIELD	GROUP	SUB-GROUP	
06	02		
06	05		
19. ABSTRACT (Continue on reverse if necessary and identify by block number) <p>→ This Annual Report summarizes progress to date on a long-term implant study of a serrated ceramic dental implant designed for fresh extraction sites. The baboon study was successfully completed last year. Clinical studies are presently continuing. The implants are single tooth rectangular design with serrations arranged for maximal stress distribution of occlusal loads. A three-piece design is used to minimize stresses upon the root portion during the bone ingrowth phase. The serrated root portion is produced from high purity dense aluminum oxide (Al₂O₃). The upper two parts of the implant, post, and core and crown, are conventional metal materials. A series of graded dental implants have been produced to provide an interference fit in any fresh extraction site. The long-term implant studies in baboons were terminated last year after an average residence time of implantation of 5.25 years in 5 baboons. The longest implant time in this baboon series was 7.71 years. In summary, 88 percent of the implants in baboons survived the initial ingrowth phase. The ingrowth failures were early implant attempts, suggesting</p>			
20 DISTRIBUTION / AVAILABILITY OF ABSTRACT <input type="checkbox"/> UNCLASSIFIED/UNLIMITED <input checked="" type="checkbox"/> SAME AS RPT <input type="checkbox"/> DTIC USERS		21 ABSTRACT SECURITY CLASSIFICATION	
22a. NAME OF RESPONSIBLE INDIVIDUAL Mrs. Judy Pawlus		22b TELEPHONE (Include Area Code) 301-663-7325	22c OFFICE SYMBOL SGRD-RMI-S

19. Abstract (Cont'd.)

→ technique or operative experience may be a contributing factor. Thirty-eight implants were rigidly retained by bone ingrowth. Of these implants, 63 percent or 24 implants were complete functional units at time of necropsy. Implants not completed at experimental termination included implant fractures, lost crowns, and implants that were never restored. Only 1 of the 38 implants became loose after initial ingrowth. Consequently, 37 or 38 (or 97 percent) of the implants which became rigidly fixed in bone could have successfully functioned if extenuating circumstances had not prevented or prematurely shortened the restoration of these implants. Histologic analyses of the bone implant interface has been performed at various time intervals. An increase in bone density appears to be associated with the early functional stage of implant life. Later, well-organized bone mixed with some connective tissue is typically observed totally filling the serrations. Numerous areas of apposition between bone and ceramic are observed. Alveolar bone height appears to be well maintained in all implants throughout the experimental period. Periodic radiographic analyses of dental implants verify this observation. Gross and microscopic pathologic analyses were performed on selected organs of all animals in the study. No implant-related lesions were observed. The pathologic changes recorded were interpreted as representing spontaneous, clinically insignificant disease from the effect of old age in the majority of cases. The pathologist's evaluation was that there was no definitive evidence of any adverse effects related to the chronic implantation of ceramic teeth in the baboon.

Samples were collected from 15 organ or tissue sites and assayed for aluminum concentration via atomic absorption spectrophotometry. Increases in aluminum concentration were noted in the lungs, regional lymph nodes, gingiva, tongue, and masseter muscle. When compared to a similar study where titanium alloy orthopaedic implants containing aluminum (Ti-6AL-4VA) were studied, similar increases in the lung and lymph node concentrations were observed. Increases in muscle, tongue, and gingiva aluminum ion concentrations can be explained by the close proximity between the implant and the tissue sample. In the dental implant animals, there was no noted increase in aluminum concentration in the brain. Adequate animal data were not available from this study to ascertain the release rate of aluminum oxide from the dental implant sites.

Human studies to date have been divided into three different experimental groups:

- Group I - freestanding implants placed slightly above the alveolar ridge at the time of surgery
- Group II - implants stabilized by splinting to adjacent teeth
- Group III - implants placed below or flush with the alveolar crest.

In Group I of the human studies, 25 patients were implanted with mandibular, premolar, or molar site implants. Eight implants or 32 percent remain. The average group implant time is 5.12 years. The average time to failure for restored implants was 2.06 years. However, only three of these patients have been available for recent followup. Therefore, these numbers should be viewed cautiously. The Group II tooth implants were splinted. Six patients received implants in the posterior mandibular area. Sixty-seven percent of these implants remain intact. The average implant time is 3.73 years. The average time for failure was 1 year. The average implant time for restored implants is 1.75 years. Group III implants were placed flush with or below the alveolar crest. Twenty-nine patients

19. Abstract (Cont'd.)

of human implants

were implanted with posterior mandibular or anterior maxillary area implants. Eighteen or 62 percent remain intact. The average implant time is 1.79 years. The average failure time of restored implants was 0.89 years.

The data indicated some advantage of the alternative techniques of splinting and/or deeper initial placement since a higher long-term success rate was evident. We suggest that the additional isolation from mechanical stresses provided by the Group II and Group III techniques appear to have made a significant difference in the maintenance of stability. However, the experiment time of Group II and especially Group III implants is relatively short compared to Group I. It is premature to prejudge the results. Two important observations should be made with this implant system. First, the system is based upon a series of rectangular implants specifically designed to be placed in fresh extraction sites. This particular design restriction is in keeping with the military desire to utilize basically the fresh extraction scenario for immediately replacing traumatically injured dentition. However, the negative effects of this design constraint are that a rectangular socket must be fashioned to accept the implant. Fashioning of a tapered rectangular socket is, under the best of conditions, a more difficult task than preparing a hole of circular cross-section. Also, immediate intimate bone contact cannot be obtained as is possible with a circular device. It is our contention that much higher success of this implant technology can be obtained in circular cross-section roots for edentulous cases. However, the present rectangular system appears successful for its intended fresh extraction site application.

Accession For		
NTIS	CRA&I	<input checked="" type="checkbox"/>
ETIC	TAB	<input type="checkbox"/>
Unannounced		<input type="checkbox"/>
Justification		
By		
Date		
Project/Contract		
Author		
Title		
A-1		

FOREWORD

This study was conducted at Battelle's Columbus Laboratories using the staff and resources of the Department of Toxicology and the Ceramics Section. The clinical portion of the study was conducted at The Ohio State University College of Dentistry. The Principal Investigator for this research was Dr. Craig R. Hassler. Ceramics research was directed by Ms. Carol Markhoff and Mr. Larry McCoy. Mr. Lynn Clark was responsible for technical aspects of the baboon study including preparation of the hard tissue histologic preparations.

Most recently, the human studies have been under the direction of Dr. Mark Brose in the clinical facilities of The Ohio State University College of Dentistry. The clinical research was conducted under a protocol approved by The Ohio State University Human Subjects Committee. Further, the study was performed in accordance with an investigational device exemption obtained from the FDA.

Citations of commercial organizations and trade names in this report do not constitute an official Department of the Army endorsement or approval of the products or services of these organizations.

In conducting the research described in this report, the investigator(s) adhered to the "Guide for the Care and Use of Laboratory Animals," prepared by the Committee on Care and Use of Laboratory Animals of the Institute of Laboratory Animal Resources, National Research Council (DHEW Publication No. (NIH) 78-23, Revised 1978).

For the protection of human subjects, the investigator(s) have adhered to policies of applicable Federal Law 45CFR46.

The Principal Investigator is indebted to his many colleagues whose assistance was invaluable to the conduct of this project. Dr. William Wallace, Dean of the OSU Dental School, was instrumental in arranging the cooperation between The Ohio State University and Battelle. Dr. Nancy Arlin and Dr. Orville Russell were invaluable for their unique, individual expertise during the project. Above all, the Principal Investigator in this project is indebted to Dr. Robert Downs who was the key clinical participant in this study until his death.

TABLE OF CONTENTS

	<u>Page</u>
SUMMARY	i
FOREWORD	iv
BACKGROUND	1
METHODS	6
Fabrication of Tooth Roots	6
Baboon Implant Procedures	7
Additional Animal Techniques	7
Human Implant Procedures	7
RESULTS	10
Parametric Analysis	10
Mechanical Evaluation of Root/Crown Interface	14
Animal Studies	17
Summary Analysis of Baboon Implant Data	17
Clinical Examples of Baboon Dental Implants	20
Histologic Analysis of the Bone-Implant Interface	27
Clinical Chemistry and Hematology Results in Baboons	34
Histopathology Report	34
Aluminum Analyses	35
Clinical Studies	37
Examples of Clinical Case	47
Clinical Implant Radiographic Analysis	47
Periodontal Study	50
CONCLUSIONS	55
Recommendations	57
REFERENCES	58

LIST OF TABLES

	<u>Page</u>
Table 1. Node Point Stresses in Three Dimensional Axisymmetric Model	13
Table 2. Fracture Characteristics of Laterally Loaded Post Design	16
Table 3. Tissue Aluminum Concentration in Baboons (ng/mL) Dry Weight	36
Table 4. Results of Group I Implant Patients Non-Stabilized Restored	38
Table 5. Results of Group II Implant Patients	40
Table 6. Results of Group III Implant Patients Buried Root Restored	42
Table 7. Peridental Analysis	54

LIST OF FIGURES

Figure 1. Serrated Aluminum Oxide Dental Implant	4
Figure 2. Grid Representation of Three Dimensional Axisymmetric Model of 4 X 4 mm Implant	12
Figure 3. Grid Representation of Shortened 4 X 4 mm Implant	15
Figure 4. Clinical Photograph of A29 and A30 in Baboon 469 at Necropsy	21
Figure 5. Post Necropsy Radiograph of A29 and A30 in Baboon 469 ..	22
Figure 6. Clinical Photograph of A19 and A20 in Baboon 469 at Necropsy	23
Figure 7. Post Necropsy Radiographic of A18, A19, A200 in Baboon 469	24
Figure 8. Post Necropsy Radiographs of Implants in A29 and A30 of Baboon 712	25
Figure 9. Post Necropsy Radiograph of Non Functional Implants in A29 and A39 of Baboon 715	26

LIST OF FIGURES
(Continued)

	<u>Page</u>
Figure 10. Cross Section of Alumina Root in Function for 15 Months	28
Figure 11. Microscopic View of Serration Bone Interface at Tip of Serration	29
Figure 12. Photomicrograph of Serration Detail A29 Baboon 469	30
Figure 13. Photomicrograph of Implant A29 Baboon 469	31
Figure 14. Photomicrograph of Implant A19 Baboon B	32
Figure 15. Photomicrograph of Implant A7 Baboon 713	33
Figure 16. Group I Implant (Integral Core) Restoration	44
Figure 17. Group II Implant - Integral Core - Stabilized - Restoration	45
Figure 18. Group III Implant (Buried Root) Post/Core - Restoration	46
Figure 19. Clinical Photograph of Posterior Mandibular Human Implant (78R6)	48
Figure 20. Radiograph of Posterior Mandibular Implant (78R6)	49
Figure 21. Least Squares Curve of Bone Height for Group I Implants	51
Figure 22. Least Squares Curve of Bone Height for Group II Implants	52
Figure 23. Least Squares Curve of Bone Height for Group III Implants	53

SURGICAL TOOTH IMPLANTS, COMBAT AND FIELD

by

Craig R. Hassler

SUMMARY

This Report summarizes progress on a long term implant study of a serrated ceramic dental implant designed for fresh extraction sites. The baboon study was successfully completed in 1983. Clinical studies are presently continuing. The implants are single tooth rectangular design with serrations arranged for maximal stress distribution of occlusal loads. A three-piece design is used to minimize stresses upon the root portion during the bone ingrowth phase. The serrated root portion was produced from high purity dense aluminum oxide (Al_2O_3). The upper two parts of the implant, post and core and crown, are conventional metal materials. A series of graded dental implants have been produced to provide an interference fit in any fresh extraction site. Baboons were terminated after an average implant residence time of 5.25 years. The longest implant time in this baboon series was 7.71 years. In summary, 88 percent of the implants in baboons survived the initial ingrowth phase. The ingrowth failures were early implant attempts suggesting technique or operative experience may be a contributing factor. Thirty-eight implants were rigidly retained by bone ingrowth. Of these implants 63 percent or 24 implants were complete functional units at time of necropsy. Implants not completed at experimental termination included implant fractures, lost crowns, and implants that were never restored. Only one of the 38 implants became loose after initial ingrowth. Consequently, 37 of 38 or 97 percent of the implants which became rigidly fixed in bone could have successfully functioned if extenuating circumstances had not prevented or prematurely shortened the restoration of these implants. Histologic analyses of the bone implant interface has been performed at various time intervals. An increase in bone density appears to be associated with the early functional stage of implant life. Later, well organized bone mixed with some connective

tissue is typically observed totally filling the serrations. Numerous areas of apposition between bone and ceramic were observed. Alveolar bone height was well maintained in all implants throughout the experimental period. Periodic radiographic analyses of dental implants verified this observation. Gross and microscopic pathologic analyses were performed on selected organs of all animals in the study. No implant related lesions were observed. The pathologic changes recorded were interpreted as representing spontaneous, clinically insignificant disease from the effect of old age in the majority of cases. The pathologist's evaluation was that there was no definitive evidence of any adverse effects related to the chronic implantation of ceramic teeth in the baboon.

Samples were collected from 15 organ or tissue sites and assayed for aluminum concentration via atomic absorption spectrophotometry. Increases in aluminum concentration were noted in the lungs, regional lymph nodes, gingiva, tongue and masseter muscle. When compared to a similar study where titanium alloy orthopaedic implants containing aluminum (Ti-6AL-4VA) were studied, similar increases in the lung and lymph node aluminum concentrations were observed. Increases in muscle, tongue, and gingiva aluminum ion concentrations can be explained by the close proximity between the implant and the tissue sample. In the dental implant animals, there was no noted increase in aluminum concentration in the brain. Adequate animal data were not available from this study to ascertain the release rate of aluminum oxide from the dental implant sites.

Human studies were divided into three different experimental groups:

- Group I - freestanding implants placed slightly above the alveolar ridge at the time of surgery
- Group II - implants stabilized by splinting to adjacent teeth
- Group III - implants placed below or flush with the alveolar crest.

In Group I of the human studies, 25 patients were implanted with mandibular, premolar, or molar site implants. Six implants remain. The average group implant time is 6.5 years. The average time to failure for restored implants was 2.24 years. However, only three of these patients have

been available for recent follow up. Therefore, these numbers should be viewed cautiously. The Group II tooth implants were splinted. Six patients received implants in the posterior mandibular area. Sixty-seven percent of these implants remain intact. The average implant time is 4.93 years. The average time for failure was 1 year. Group III implants were placed flush with or below the alveolar crest. Twenty-nine patients were implanted with posterior mandibular or anterior maxillary area implants. Sixteen or 55 percent remain intact. However, two patients have been unavailable for followup. The average implant time is 2.84 years. The average failure time of restored implants was 1.37 years.

The data indicated some advantage of the alternative techniques of splinting and/or deeper initial placement since a higher long term success rate was evident. We suggest that the additional isolation from mechanical stresses provided by the Group II and Group III techniques appeared to have made a significant improvement in the maintenance of stability. A radiographic analysis of alveolar bone indicated a continual loss of bone around all implants of all groups. There was a larger bone loss around failed implants, indicating a relationship between bone loss and implant failure. A periodontal study indicated a similarity to periodontally involved teeth, with some differences in the type of bacteria observed.

Two important observations should be made with this implant system. First, the system is based upon a series of rectangular implants specifically designed to be placed in fresh extraction sites. This particular design restriction is in keeping with the military desire to have a fresh extraction implant for immediately replacing traumatically injured dentition. However, the negative effects of this design constraint are that a rectangular socket must be fashioned to accept the implant. Fashioning of a tapered rectangular socket is, under the best of conditions, a more difficult task than preparing a hole of circular cross-section. Consequently, as intimate a bone contact cannot be obtained as is possible with a circular device. It is possible that much higher success of this implant technology could be obtained using circular cross-section roots for edentulous cases. The present rectangular system appears successful for its intended fresh extraction site application.

BACKGROUND

Dental implants may play an important role in the maxillofacial repair tasks which are of great interest to the U.S. Army Medical Research and Development Command. In the last several years a new generation of dental implants has evolved. These devices are designed to be rigidly affixed by bone ingrowth and provide minimization of stress usually being serrations^(1,4) or pores.^(5,6) Generally, these implants are designed as single freestanding prostheses. Several biocompatible materials have been utilized including plastics,⁽⁷⁾ metallics,⁽⁶⁾ and ceramics.^(1-3,8-18, 22-24,26-29) The aforementioned serrated tooth root design evolved on this project via a series of iterative stress beginning in 1969. At the inception of the study, tooth replicate technology and endosseous blades represented state of the art. The initial attempts on this project were to duplicate the technology of Hodosh, except using ceramics which were considerably stronger, and thought to be "more biocompatible" than the plastics. Numerous configurations of implants with: smooth surfaces, porous surfaces, and coatings were prepared and implanted into rhesus monkeys. The initial implant studies were performed at The State University of New York at Buffalo. The results were poor. Most of the implants were lost in short order. It should be recalled that at this time fibrous attachment or formation of a pseudo-periodontal ligament was considered the correct technique for attaching implants to alveolar bone.

Based upon these failures, it was determined that a better route of attack would be to design an implant that was solidly anchored via bony apposition and had a large surface to optimally distribute the load to the bone. The methods suggested for obtaining this goal was the use of grooved, corrugated or porous surfaces. A decision was made to adopt the serrated implant design. Slip casting procedures were used to produce a crude serrated implant. In vivo studies were performed in rhesus and cynomolgus monkeys. A significant breakthrough was obtained. Successful root stabilization was obtained in animals where implants were buried and wired to the mandibular arch for initial stabilization. However, when the same implants were splinted in fresh extraction sites, all implants were lost. In 1974 a higher quality serrated implant was manufactured. Additional animal studies indicated that

immediate placement of the total root and crown structure splinted to adjacent technique to adjacent teeth was not a successful technique. It appeared that even with splinting, the biomechanical forces placed upon the total device caused enough movement of the prosthesis to precipitate bone resorption and soft tissue invasion. But, when these serrated tooth roots were placed without crowns, not protruding stabilization was achieved in both edentulous and fresh extraction sites. This method was believed to be successful because the biomechanical forces upon the implant were minimized. Further experiments developed an implant that would accept via a recess a post and core and crown and allow easy reconstruction.

In 1975, the baboon was adopted as the experimental animal of choice having a dentition size closer to the human being than the monkey. A graded series of elliptical tooth implants plus of gages and burrs was developed for placement of tooth implants into both fresh and edentulous sites. A three piece implant system evolved which consisted of a gold post and core and crown plus the aluminum oxide root. The root could then be implanted out of function, and bone growth allowed to occur before reconstruction. A critical alteration that provided vastly increased success was burying the implants deep enough so that the stresses upon the implants were minimized. Major change was in the method of implant manufacture. Slip cast implants were by their nature relatively crude and not totally reproducible therefore a method of producing implants by contour grinding bisque fired aluminum oxide was developed. This method yielded a high quality reproducible dental implant that could be manufactured to any dimension⁽²⁰⁾. Adoption of the rectangular implant design to better fit the fresh extraction site was the last major modification. The methods of implant manufacture outlined in this report have remained relatively stable throughout the latter baboon and human implant studies. As ceramics technology improved higher quality ceramics were incorporated into the project.

In the past 15 years we have developed a combination of material, design, and technique components. It should be noted that all three components (design, material and technique) are of importance if an implant system is to be successful. Failure of any of the three components can be detrimental. A serrated ceramic implant system based upon these principles was tested in our laboratories.

The lower portion of the three-piece implants were produced from alumina (Al_2O_3) (Figure 1). This portion has large serrations into which bone ingrowth has been demonstrated.⁽⁴⁾ The implant illustrated in Figure 1 has smaller serrations at the crown end of the root to increase the strength of smaller sized roots in these critical areas. The upper two portions of the implant: post and core and crown, were cemented after ingrowth to allow function. The three-piece design allowed minimization of occlusal stresses and strains on the implant to facilitate bone ingrowth. An analogous situation is seen in the healing of long bone. It is assumed that, as in long bone, an orderly transition through a sequence of gradually stiffer bone materials proceeds (hematoma → connective tissue → woven bone → compact bone). The maximal strain which any of these tissues can withstand must not be exceeded if healing is to proceed to completion.⁽²¹⁾ Consequently, strain upon the implant-bone interface must be minimized early in the healing process if bone formation is to occur. Once the implant is stabilized by ingrowth, the large implant surface area at right angles to the principal load axis of the implant is intended to maintain bone stresses below a level which produces resorption of bone. Attempts to quantify these stresses have been made in this laboratory.⁽⁹⁾ This information is not specifically for alveolar bone; however, it serves as a guide in an area where no direct information is available. Finite element analyses performed on this design,⁽³⁰⁾ indicated that stresses in the bone were below design maximum for typical occlusal loads. The histologic data collected during this project⁽²⁾ show that bone can be maintained for extended periods, in intimate contact with a functional implant. This observation supports the hypothesis that the design has limited the stresses at the interface to acceptable levels.

The key parameters of this design are: serrations, three-piece construction, and multiple implants size. Size gradation allows optimal fit into the available site. Thus numerous sizes have been produced in clinical studies. In practice, several of the sizes are not used, but they are available when required. Baboon studies showed the rectangular shape provided a better initial fit in a fresh extraction site. Consequently, this design was used exclusively in human clinical trials. The shape and size flexibility of the rectangular design was especially crucial when placing implants in fresh extraction sites. A circular implant will rarely provide adequate initial

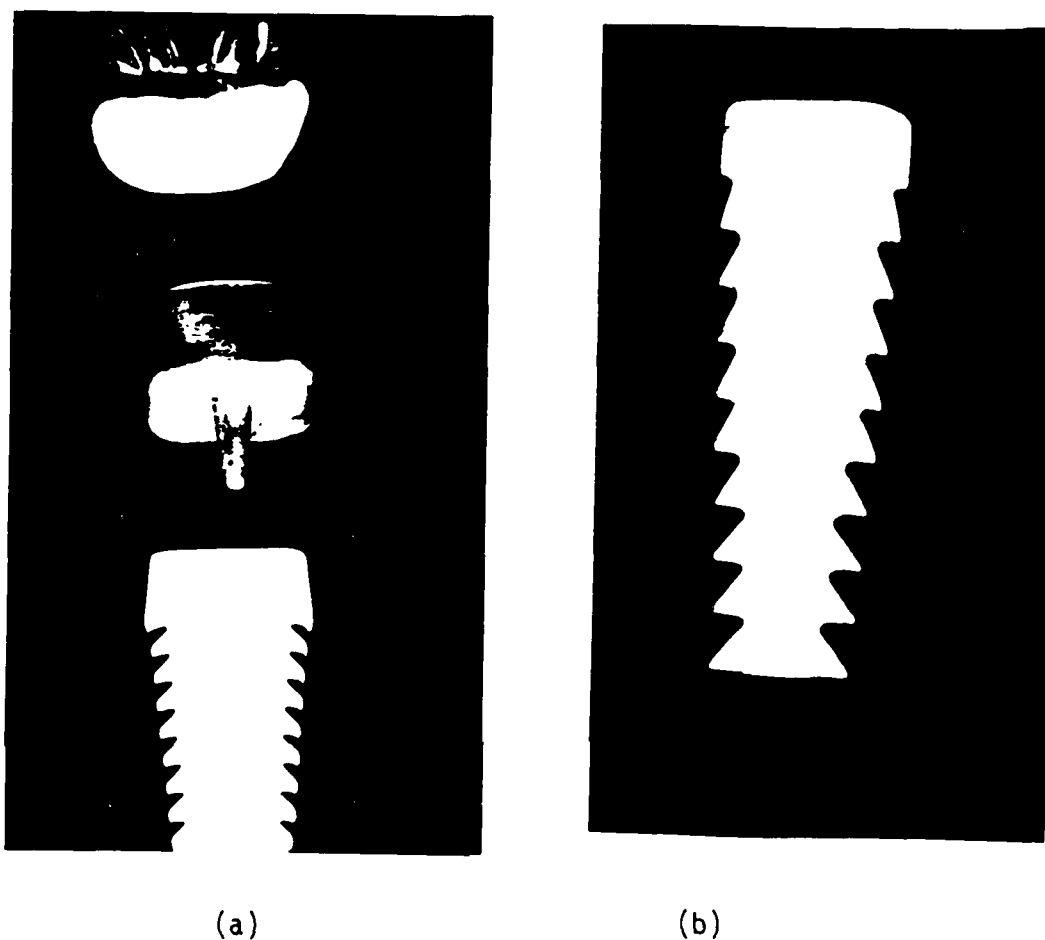


FIGURE 1. SERRATED RECTANGULAR ALUMINUM OXIDE DENTAL IMPLANT

Panel A shows a rectangular implant with post and core and crown. The crown is of overlapping design as used in Group I human implants and later baboon implants. It was prefabricated from gold and cemented into place after stabilization via bone apposition. Group II human implants (not shown) were similar to Group I except the alumina root was extended upwards to serve as an integral post and core.

Panel B shows the root portion of a Group III implant. Note that the upper serrations become progressively shallower to improve strength, stress distribution, and allow implants as small as 4 x 4 mm to be fabricated. Further, the upper most collar of the root was shortened to maximize the number of serrations in bone.

Implants were fabricated from Reynolds RC-HP-DBM alumina, bisque ground and sintered. The surface finish was also ground and sintered. Flexural strengths average 70 Kpsi.

stability in a fresh extraction site. Furthermore, with a circular design, implant size is limited by the buccal-lingual dimension. Disadvantages to the rectangular design are that more operator skill is required to initially place the implant than would be required with a circular implant. Also, the design prevents the immediate, intimate contact between bone and implant that can be obtained with a circular design that is "threaded" into bone.

The method of producing roots by contour grinding, on a computer controlled milling machine, has allowed for flexibility not only in size, but in other design changes. In a research protocol, this ease of flexibility has been an asset and will continue to be our method of root manufacture.

METHODSFabrication of Tooth Roots

The most satisfactory method for producing implants is summarized in this section. The powder used for fabrication of roots for the clinical studies was Reynolds Aluminum Company's RC-HP-DMB. This is a high purity, dry ball milled powder having a median particle size of approximately 0.5 microns. The methods for production of the tooth roots have been reported previously.(27,28) The processing procedure used is as follows:

- (1) Hydrostatic pressing granulated material at 50,000 psi to form preform rods nominally 125 mm long by 14 mm diameter
- (2) Bisque firing preform rods at 1120°C for 2 hours
- (3) Contour grinding tooth roots (roots were made in 1 millimeter sizes from 4 x 4 to 8 x 10)
- (4) Hand finishing tooth roots
- (5) Final sintering at 1540°C for 1 hour.

This unique combination of Bisque grinding following by final sintering provided for a very high flexural strength in all dimensions. The implant surface was left as ground and sintered.

A quality assurance program was utilized on all roots destined for clinical trials. The details of this program have been published in our previous reports.(27,28) This program consisted of:

- (1) A method of traceability which allowed each root to be identified as to raw material, size, and time of manufacture.
- (2) Manufacture of test bars, which were produced for each batch of roots. Flexural strengths averaging 70,000 psi were obtained.
- (3) Microscopic examinations of each root by both transmitted and reflected light.
- (4) Wet density measurements of representative implants from each group.

Baboon Implant Procedures

The procedures used in the baboon are briefly outlined below. Typically, following extraction, the tooth socket was shaped using a bone burr. The socket was formed by a continual fitting procedure. The root either elliptical or rectangular was firmly tapped into the alveolar bone until flush with the bone. The root was given no further attention, however, the animal received prophylactic antibiotics immediately post-surgery and a soft diet for two weeks. The root implant site was observed periodically for three months. Radiographic examination and manual palpation indicated if the root was adequately stable for reconstruction.

Restoration of the implants was facilitated by prefabrication of a gold post and core prior to implantation. Following adequate stabilization by bone ingrowth into the serrations (at approximately three months), the post and core was cemented into place and impressions were taken. A gold crown was fabricated and cemented into place. Care was taken to provide correct occlusion. The implants were periodically examined and documented by radiographs and photographs.

Additional Animal Techniques

Clinical chemistry, hematology and parasite analyses were performed periodically and at experiment termination. One half of the animal colony (animals 469, 709, and 712) were scaled, flossed and then brushed for three minutes with a two percent solution of chlorohexidine gluconate four times prior to necropsy. (The teeth were scaled only initially.) The treatments were at approximately weekly intervals.(32)

For histomorphometric analysis of bone growth rate, all animals were tetracycline double labeled in a 2-7-2-7 pattern prior to necropsy.(33)

Human Implant Procedures

Rectangular implants were placed in edentulous, or fresh extraction sites. Roots were placed where they would function as single, freestanding

implants when reconstructed. Under local anesthesia, implant sites were prepared using bone burrs placed in a low-speed contra-angle air turbine hand-piece with sterile saline cooling.

Over the period of clinical study, a series of specialized devices and surgical techniques were devised and evaluated until a system evolved which appeared to present the most acceptable result. The greatest challenge to this project was creating a rectangular socket in either a fresh or edentulous implant site. To that end, tapered diamond burrs matching the taper of the dental implants were produced. The special burrs were fabricated in the Battelle machine shop from stainless steel and plated with abrasive diamond by an outside vendor. In addition, very small diameter diamond burrs were fabricated which matched the corners radius of the rectangular implant. A standard bone burr was used to create the center of the socket. The diamond burrs were used to create the general rectangular shape of the socket. For the final fitting of the implant into the socket, specially designed rectangular files matched the taper and size (slightly undersized) of the implant were used. This hand fitting minimized heating of the bone. Slightly undersized plug gauges fabricated from stainless steel were used as trial fit devices. When the socket size was deemed to be appropriate, the implant was tapped snugly into place using a rod and mallet.

Implants utilized for surgery were cleansed via ultrasonic bath with solvent and then with distilled water to remove any residue from the post and core prefabrication. Sterilization was by dry heat. In many cases, it was necessary to shorten the overall implant length. Serrations were cut off using a diamond disk under liberal water lubrication. The most common shortening of the implant was are removal three serrations, or 4.5 ml from the implant. Shortened implants were resterilized in the surgical theater utilizing a glass bead sterilizer. This sterilizer was used solely for aluminum oxide implants sterilization to eliminate contamination from metallic sources. A gold post and core was prefabricated for each implant. The patients were observed periodically until the implant was rigid or exhibited minimal motion. At that time, the post and core was cemented and a clinical crown fashioned.

All clinical studies were performed at The Ohio State University College of Dentistry, in compliance with a protocol approved by The Ohio State

University Human Subjects Committee and the FDA Bureau of Medical Devices. In accordance with FDA regulations, annual progress reports and semiannual investigator lists have been provided to the Medical Devices Division. Since there has been no adverse effects from the implants, no other reports have been filed with the FDA.

Patient followup consisted of numerous post implant checks including: clinical evaluation, radiographs, probing, photographs, and later periodontal examination. Examinations occur at increasing intervals until one year post implant when patients were followed on a semi-annual basis.

Three variations of implant technique have been employed: in the first group, implants were surgically placed so that the uppermost serration was just covered by the crest of the alveolar ridge. Consequently, about 3 mm of implant was left protruding above the ridge. The first 25 patients' implants were implanted in this fashion.

A second group of 6 patients' implants were prepared with integral post and cores. The implants were partially isolated from occlusal loads by orthodontic stay wires attached to adjacent dentition and a methacrylate resin cap over the top of the implant.

A third group of 29 patients was prepared in which the top of the root was placed flush with the alveolar crest. Whenever possible, a muco-periosteal flap was placed over the top of the implant. Both anterior maxillary and posterior mandibular sites were included in this third group.

RESULTS

Parametric Analysis

The use of a serrated device for distributing the occlusal load directly into the bone without an intervening soft tissue membrane was a unique concept which matured due in part to the research efforts of this program. No data existed qualifying the distribution of stresses from a serrated object to bone. Further, no quantitative data, other than that previously developed in this laboratory⁽²⁵⁾, was available to indicate what stresses bone would tolerate. Consequently, analyses of the stresses in the bone, implant, and interface of the serrated tooth root situation were performed.

Ceramic and bone are dramatically different materials. The bone has relatively low modulus and that of the aluminum oxide is extremely high. The weakest portion in the system is the small projection of bone which fits into the serrations of the implant. The models considered the static load, a situation quite different from the dynamic loading which would typically be applied to dentition. To expand our understanding of the mechanics between the dental implant and the bone, a mathematical analysis of the implant was performed. The method being used was finite-element analysis. This laboratory, as well as the biomechanics community in general, has widely used this mathematical technique on biological problems.⁽⁹⁾ Basically, this method breaks the object to be analyzed into many small elements. The finer the elements, the higher the potential accuracy since the smaller motion allows more accuracy with the assumptions of linearity which are used. Unfortunately, the cost goes up. Consequently, an affordable, yet sufficiently accurate, compromise is sought. Presented in this report is the second version of the model. This model differs from the first version in that it is a three dimensional finite element model. (The previous model was two dimensional.) The three dimensional model provided a more accurate representation of the real world. The two dimensional model represented the objects, looking at stresses only in one plane. In the three dimensional model the basically rectangular and triangular shaped elements were cuboidal shaped elements,

having depth. The implant and bone was mathematically represented as a true three dimensional object. The model used for this study calculated stresses at three points along the edge of each element as well as in the center (or centroid) for a total of 21 points per element. Since stresses were calculated along edges of elements, the interfacial stresses could be calculated.

The following elastic moduli were used in the three dimensional model: ceramic, 54.54×10^6 psi; gold, 11.92×10^6 psi; and bone, 1.98×10^6 psi. Also, rigid bonding was assumed at the interface. This assumption was considered reasonable, since the serrated shape closely modeled by the ingrown bone and ceramic surface roughness probably eliminated relative motion between bone and ceramic. Using these constraints, the data were computed for an axial (occlusal) static load of 25 pounds. Calculations were for the smallest implant (4 mm x 4 mm). This size implant would have the highest stresses under the serrations because it has the smallest surface area of serrations to distribute the load and consequently represented the worst case. Also, the wall thickness of ceramic was the thinnest and most critical in this size implant.

Figure 2 is a grid representation of the three dimensional mathematical model of a full size implant. For simplicity, only one-half of the implant is shown in cross-section. The relatively thin cortical plates of bone and the thin layer of bone below the implant are characteristics normally noted histologically. The outline of the implant indicates the area which is ceramic. The post area and the portion above the top of the implant is gold. The remaining area is bone. The stresses shown are those at the centroids or center of each three dimensional element.

The maximum stresses in the bone are almost within the self-imposed 400 psi bone compressive stress limit.⁽⁹⁾ The bone stresses are somewhat higher than those predicted by the simpler two dimensional model reported in the 12th report.⁽²⁹⁾ The highest compressive stress indicated may be due to the sharp angulation selected at that particular point.

Additionally, the node point stresses were calculated at the inner edge, center and tip of each serration. These are the bone stresses at the bone-ceramic interface. The bone node stresses were consistently, slightly lower than those calculated for the centroids. The stresses were also fairly

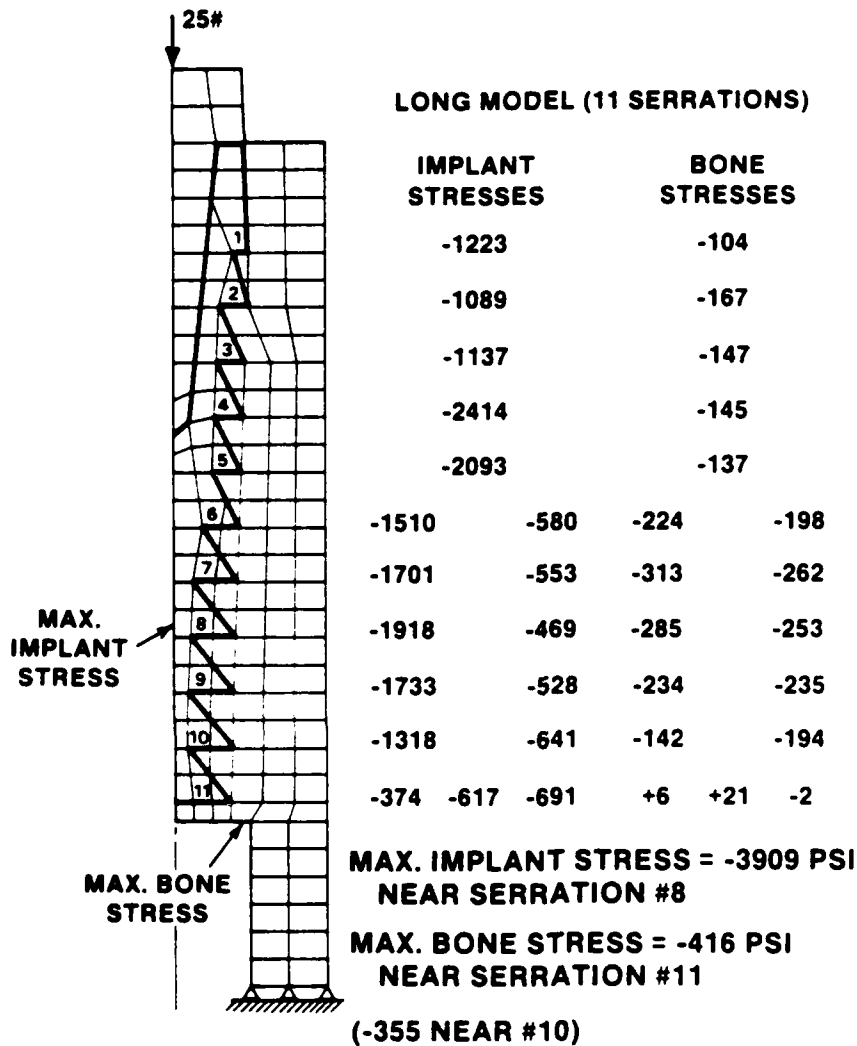


FIGURE 2. GRID REPRESENTATION OF THREE DIMENSIONAL AXISYMMETRIC MODEL OF 4 X 4 MM IMPLANT

In this figure, only one-half of the implant system is shown. The heavy line shows the outline of the ceramic implant. The stresses shown are those at the element centroids.

- is compression, + is tension

TABLE 1. NODE POINT STRESSES IN THREE DIMENSIONAL
AXISYMMETRIC MODEL

Along bottom edge of serration in ceramic

Serration Number	Inner Edge		Center		Tip	Serration Depth (mm)		
1	-2390		-990		-992	0.435		
2	-1114		-745		-383	0.763		
3	-1676		-935		-205	0.761		
4	-1625		-902		-193	0.759		
5	-1603		-895		-201	0.762		
6	-2769	-765	-500	-476	-359	0.979		
7	-2001	-574	-507	-527	-371	1.196		
8	-2973	-955	-487	-471	-293	1.196		
9	-2640	-803	-452	-458	-265	1.197		
10	-1688	-370	-378	-450	-241	1.196		
11	+247	+535	+339	+534	-22	-232	-120	2.956

NODE POINT STRESSES IN BONE ADJACENT TO
CERAMIC POINTS CALCULATED ABOVE

(These are compressive stresses in bone at the bone-ceramic interface.)

Serration Number	Inner Edge		Center		Tip		
1	-92		-93		-94		
2	-166		-161		-109		
3	-149		-131		-113		
4	-137		-125		-114		
5	-130		-121		-113		
6	-231	-189	-180	-168	-151		
7	-335	-264	-244	-222	-191		
8	-311	-241	-227	-214	-194		
9	-263	-197	-185	-198	-204		
10	-173	-114	-104	-169	-225		
11	-10	-36	-37	-45	-78	-114	-178

Note: All unit PSI
- is compression
+ is tension

uniform at the various positions along each serration. Also, the model indicated fairly uniform stresses at various serration levels despite the differences in serration depth. However, the nodes indicated slightly higher stresses in the ceramic than their respective centroid (Table 1). The stresses decreased progressively from the implant axis. The agreement between the two modeling approaches supports the use of centroid stresses as reasonable representations of the actual stress.

Figure 3 is an additional case that was calculated with the implant shortened by three serrations. This model shows stress alterations when an implant is shortened. In the case of Group III implants (which are placed deeper than with Groups I or II) frequently 3 serrations had to be sacrificed due to limited vertical bone height. The centroid axial stresses at the interface are shown. The model suggests minimal changes in implant stresses, except at the point of maximal stress near the implant apex. The maximum stress level is higher than the self-imposed design limit, but it is a stress level still below that which will inevitably produce bone resorption.⁽⁹⁾ Consequently, even the shortened implant should be adequate to distribute the imposed stresses.

Mechanical Evaluation of Root/Crown Interface

One of the areas of concern with the root structure design was the bond strength of the root/crown interface. The crown is fabricated as a two-part system. First, a gold alloy integral post and core was investment cast to fit each implant. After cementing the post in place in the mouth, impressions are taken and an all gold or porcelain veneer crown was fabricated to fit the post.

Two post and core designs are possible. In the first design and gold overlaps the outside of the root structure and extends downward into the gingival sulcus. The second design is formed flush with the exterior surface of the alumina. The prosthodontist prefers the use of the first design to maximize the strength of post/ceramic interface. The use of this design, however, necessitates setting the implant higher in the alveolar bone, which could impede the bone healing process. Also, the extended gold margin could

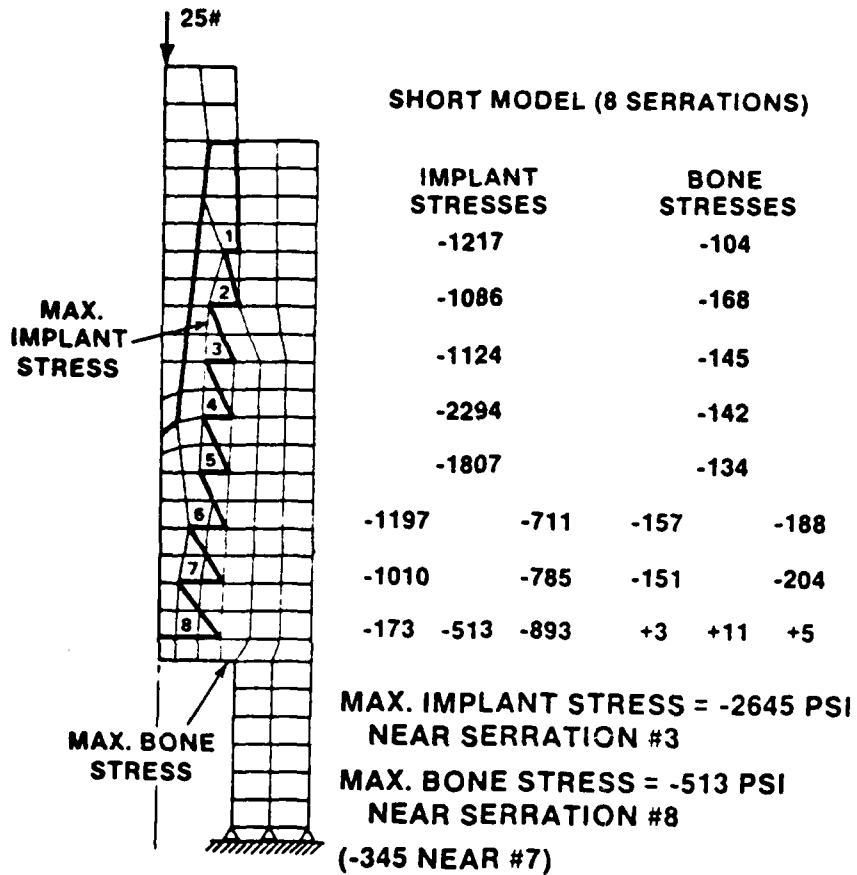


FIGURE 3. GRID REPRESENTATION OF SHORTENED 4 x 4 MM IMPLANT
 The stresses at the element centroids are shown.

irritate gingiva. Analysis of the two possible designs was required before proceeding to the Group III human implants.

To resolve the need for the gold overlap, comparative strength tests were conducted on the two designs. Implants of matching size were prepared with posts of each design. The ceramic root was then imbedded into a cylinder of epoxy up to the top of the first or second serration. After curing, the implant was clamped into a horizontal fixture (i.e., root axis horizontal) and a lateral load was placed on the gold post using an Instron® Universal Testing Machine. The load was increased at a fixed rate until failure of the bond, gold, or ceramic occurred. The results of the test are summarized in Table 2.

TABLE 2. FRACTURE CHARACTERISTICS OF LATERALLY LOADED POST DESIGN

Root Size mm	Post Design	Distance Load Point to Fracture mm	Loading Rate m/min	Breaking Load, lb	Location of Break
6 x 8	Flush	6 mm	0.002	69	Second Serration
6 x 8	Overlap	5.5 mm	0.002	71	First Serration
6 x 9	Flush	6 mm	0.01	95	Second Serration
6 x 9	Overlap	6 mm	0.01	93	Second Serration
7 x 10	Flush	--	0.1	86	Recess Wall
7 x 10	Overlap	6 mm	0.1	98	First Serration

With one exception, all of the fractures were initiated through the ceramic at the height of the epoxy mount (i.e., at the base of the first or second serration). In all of these cases the gold core bent and pulled out of the lower section of the implant because of the levering action; the upper fractured section of the implant remained intact and securely bonded to the gold. The loads at fracture were essentially the same for implants of the same size. Since interface debonding did not occur above the fracture line, the tests serve to prove that the lateral load strength of the two different post designs are the same up to the worst case lateral load levels required to initiate implant fracture (70 to 100 pounds depending on implant size). Thus

no immediate weakening of the implant would result from the removal of the gold overlap for the Group III clinical studies. Loads of this magnitude and direction are not expected under normal mastication. External impacts, however, could generate loads of sufficient nature to cause this type of failure. It would be interesting to compare the strength of natural teeth under the same mounting and loading conditions. However, the objective here was to verify the equivalency of restorative designs, thus, allowing deeper implantation of the root structure. The deeper initial implantation should facilitate initial bone ingrowth by minimizing stresses.

A secondary result of this study is the implied need for further design studies. The fact that the ceramic failed before the attachment suggests that the interface design could and possibly should be modified to allow joint failure before ceramic failure. It certainly would be less traumatic to replace a failed crown and post than to surgically remove and replace a fractured root structure. Breakaway designs could also reduce peripheral facial and bone damage in case of accident.

Animal Studies

Summary Analysis of Baboon Implant Data

For the purpose of this analysis, all implants have been classified according to their "final" status at time of death or necropsy. Some implants underwent a complicated course involving several different procedures. This analysis is intended as a "worst case" analysis where each implant is categorized according to its least favorable outcome. This analysis includes all implants placed in the 9 animals retained at Battelle for the long term dental implant study.

Forty-three attempts were made to place implants. Thirty-eight, or 88 percent of the implants survived the initial ingrowth phase. All ingrowth failures were early implant attempts (prior to 1977). Three of the five failures occurred in one animal. This animal was subsequently successfully implanted, suggesting that technique improvements or operator experience were failure contributing factors. Suspected failure modes include: fracture of

the buccal plate, and placing the implants too high relative to the alveolar crest.

Of the 38 implants which were retained, 24 or 63 percent were rigid, totally functional and complete implant units at necropsy or animal death. The 14 implants not complete at experiment termination were distributed in the following manner:

- 8 implants fractured while in service
- 1 implant lost its post and core and crown
- 1 implant was fractured during an attempted removal
- 4 were never restored.

These implants were analyzed in the following manner; all fractured roots were from the same processing batch. Consequently, poor material quality is suspected. These early implants were not put through a quality assurance program as was the practice with implants prepared for clinical study. The implants that did fail experienced an average of 3.27 years \pm 1.49 years before failure. Extreme crown wear seen on all baboon dental implants indicated that the animals severely stressed the devices. However, the actual contribution of severe treatment to implant fracture cannot be determined.

The post and core and crown loss was suspected to be due to faulty zinc oxyphosphate cement, and probably not related to a difficulty with the implant per se. Suspected cement failures were seen in other implants which were recemented and are classified elsewhere. For example, area 18 in animal 469 lost its crown after three years. The implant remained in function via the post and core until two months before necropsy when the implant fractured. This implant is counted as a fracture failure in this analysis. A similar example was seen in animal 713 area 20. A crown was lost due to cement failure after two years. The crown was recemented. However, the implant eventually fractured and was categorized as a fracture loss. A total of three implants exhibited cement failures, were reconstructed and went on to eventually fail due to fracture.

One implant in animal 712, area 19 presented an interesting case history. This implant never became stable. After 16 weeks removal was attempted, at which time the implant fractured. The remaining root, now below

alveolar crest, became rigidly fixed in the bone and remained so. This implant compounds the analysis since technically it is a loss, but still remained in the animal. Consequently, the implant was placed in a unique category. A similar incident was noted in animal B, area 29. The implant was placed in function earlier than usual. Normally at least 90 days was permitted to elapse, but in this case, only 68 days elapsed before reconstruction was undertaken. The implant loosened progressively. Twice, in the next 2.25 years, crown height was reduced to minimize function on the implant, but the implant remained mobile. Eventually, after four years, the implant fractured. The root segment of the implant, now totally removed from any function, became rigidly fixed in the bone and remained so. These two cases suggest that a mobile root can eventually stabilize, but only in the absence of external "stresses". Four implants, never restored, were placed late in the program to train new dentists for the clinical program. The residence time of these roots was too short (with one exception) to judge whether they would have been successful or not.

The 24 implants, termed totally successful, experienced an average implant residence time of 5.26 years \pm 1.49 years. It is significant in that, with one exception, all baboon implants which became rigidly implanted remained rigidly fixed. A very optimistic analysis could state a 33 out of 34, or 97 percent success rate for stabilized roots, if various mechanical failure modes such as implant fracture and cement failure are discounted. On the other hand a pessimistic analysis of the data could state that only 24 of the 43 roots (56 percent) were totally successful. The percentage could be even further reduced if crowns with extensive wear are considered failures. Obviously, the true success of the implant system is between the above stated percentages but probably closer to the optimistic analysis. The perception of success depends upon the analysis criteria employed. It is most important to indicate that the data strongly supports the hypothesis that a dental implant of this design can become rigidly fixed in bone and satisfactorily distribute the occlusal stresses on an extended basis.

Clinical Examples of Baboon Dental Implants

Photographic examples of long-term implants in the animal study are shown in Figure 4. These implants (Baboon 469, A29, and A30) were in place for 7.34 years and 7.71 years, respectively. The implants were rigid and in occlusion at necropsy. The gingival health was excellent, perhaps due in part to the chlorohexidine gluconate treatment. Extensive wear was seen on the crown surfaces. This wear is typical of long term Baboon implants. Aluminum staining on Baboon teeth indicated chewing on the cage bars. Presumably, the accelerated crown wear was due to this chewing activity.

Figure 5 is a post necropsy radiograph of the excised mandible of Baboon 469. This radiograph shows excellent hard tissue detail since interfering soft tissue has been removed. Most striking is the density of bone about the implant. All rigid implants demonstrate this increased radiodensity. This increase in density is interpreted as a response to the stresses induced in the bone by the functional implants.

Figure 6 is another clinical example of long-term function in a Baboon. These implants are also from animal 469. The total implant time of these roots was 7.34 years. As in the previous example, these implants exhibited good gingival health. There is a thickening of the gingiva, a cuff-like formation, about the buccal aspect of the implant. This cuff of gingiva was seen adjacent to several of the Baboon implants. It appears to be a response to poor gingival attachment.

Figure 7 is a post necropsy radiograph of A18, A19, and A20 in Baboon 469. This is the same area as shown in Figure 6. Dense bone, obscuring the serration detail can be observed about the implants. Vertical bone loss is evident about the implants. The bone loss is dramatic about the fractured implant in A18. The vertical loss about A19 and A20 implants appeared subsequent to the implantation in A18. Sequential radiographs in the 12th report⁽²⁹⁾ illustrate this point.

Figure 8 is a post necropsy radiograph of mandibular implants in A29 and A30 of Baboon 712. These implants were in place 4.93 years. In this example, alveolar crest was well maintained. As is typical with these implants, the bone appears denser near the alveolar crest. Figure 9 is a post

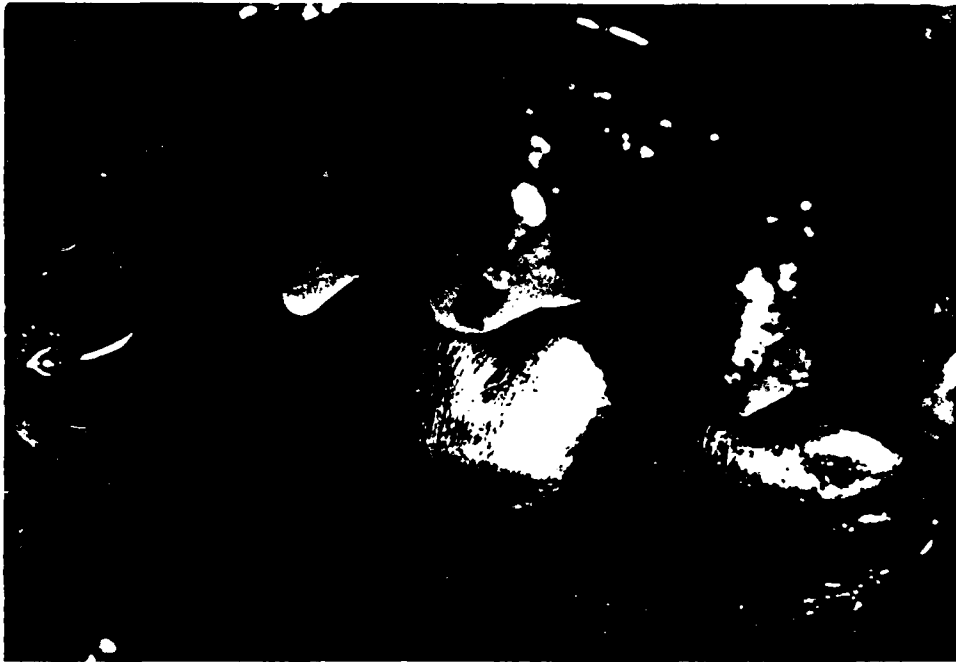

FIGURE 4. CLINICAL PHOTOGRAPH OF A29 AND A30 IN BABOON 469
AT NECROPSY

These particular implants had been implanted for 7.34 and 7.71
years prior to Necropsy. The crowns exhibit extensive wear.

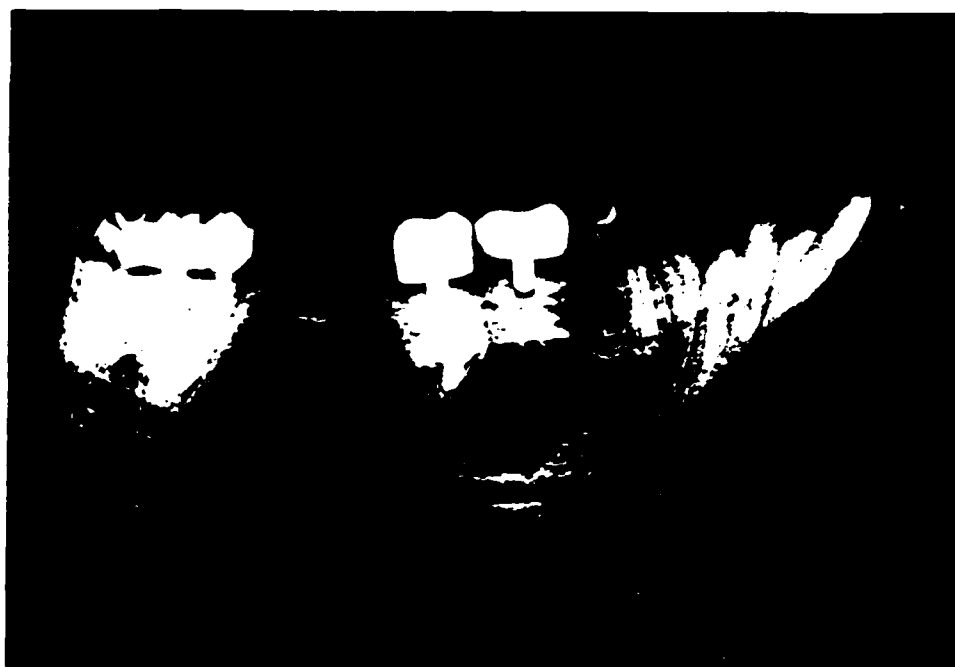

FIGURE 5. POST NECROPSY RADIOGRAPH OF A29 AND A30 IN BABOON 469

This radiograph illustrates the dense bone formation typically seen around the rigid long term implants. The serration detail is obscured by the bone formation. Bone appears denser at the alveolar crest. Crestal height was maintained through the life of these implants.

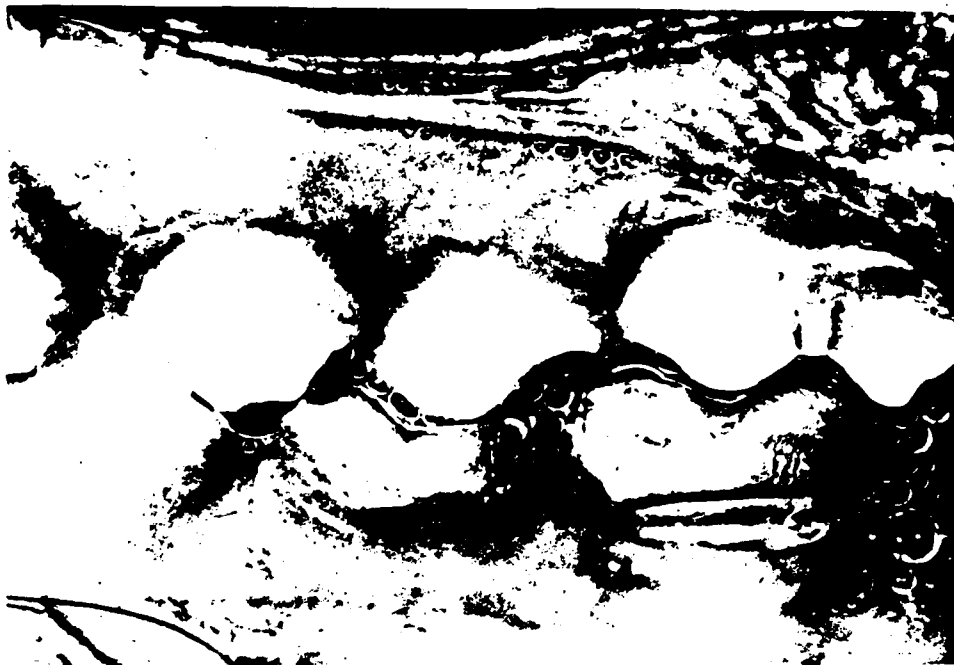

FIGURE 6. CLINICAL PHOTOGRAPH OF A19 AND A20 IN BABOON 469 AT NECROPSY

These two implants were in place for 7.71 years. The crowns exhibit wear and the gingival cuff often seen on multiple baboon implants is present. A distal implant in A18 fractured approximately 2 months before necrosy.




FIGURE 7. POST NECROPSY RADIOGRAPHIC OF A18, A19, AND A20
IN BABOON 469

This radiograph corresponds with implants shown in Figure 4.
Vertical alveolar bone loss is evident.



FIGURE 8. POST NECROPSY RADIOGRAPHS OF IMPLANTS IN A29 AND A30 OF BABOON 712

These implants have been in place for 4.93 years. Alveolar crest height was well maintained around the implants. The increase in bone density and the pattern of the density increase is typical.



FIGURE 9. POST NECROPSY RADIOGRAPH OF NON FUNCTIONAL IMPLANTS
IN A29 AND A39 OF BABOON 715

These two implants were in place for 39 days and 1.31 years respectively, but they were never in function. Note that the bone density has never increased around these implants as is typically observed in functional implants (see Figures 5 and 6).

necropsy radiograph of two implants placed 1.31 years (A31) and 39 days (A29) prior to necropsy. Neither of these implants were ever reconstructed. Note that the serrations of the implants are still plainly visible, especially when compared to the long-term function implants. The bone has never increased density about in these nonfunctional implants. Comparison of functional implant radiographs (Figures 7 and 8) to this nonfunction implant radiograph suggests that the increase observed in bone density is a response to the functional stresses.

Histologic Analysis of the Bone-Implant Interface

Analyses of the bone-implant interfaces was performed. Figure 10 shows a low magnification view of a tooth implant in function for 15 months. The close proximity of bone to the lower serrations is typical of these implants. The curling of soft tissue into the uppermost serration is also typical. The thin layering of bone beneath the implant is common. This cross section is typical of older style implants produced in 1975.

Figure 11 illustrates the very close apposition seen between bone and ceramic at the interface. This particular view is a cross section through the tip of a serration. This particular implant was in function for 21 months at the time of necropsy. Further examination of other sections reveal occasional small pockets of connective tissue in contact with the ceramic.

Figure 12 is a photomicrograph, showing serration detail from A29 of Baboon 469. This particular implant was in place for 7.71 years. This represents the longest implant duration of the study. Note that dense, well organized bone mixed with some connective tissue has totally filled the serration. There appears to have been close apposition between bone and implant. (The gap at the interface was caused by the slide grinding process).

Figure 13 shows serration tip detail around the same implant in Figure 11 (A29, Baboon 469). Well-formed bone totally surrounds the serrations with no apparent interveining connective tissue.

Figure 14 shows an example of dense bone ingrowth around implant serrations after 6.16 years (Baboon B-A19). As in the previous examples, a dense ingrowth of bone can be observed into the serrations. This basic fuchsin stained slide emphasizes the connective tissue.



FIGURE 10. CROSS SECTION OF ALUMINA ROOT IN
FUNCTION FOR 15 MONTHS




FIGURE 11. MICROSCOPIC VIEW OF SERRATION BONE
INTERFACE AT TIP OF SERRATION

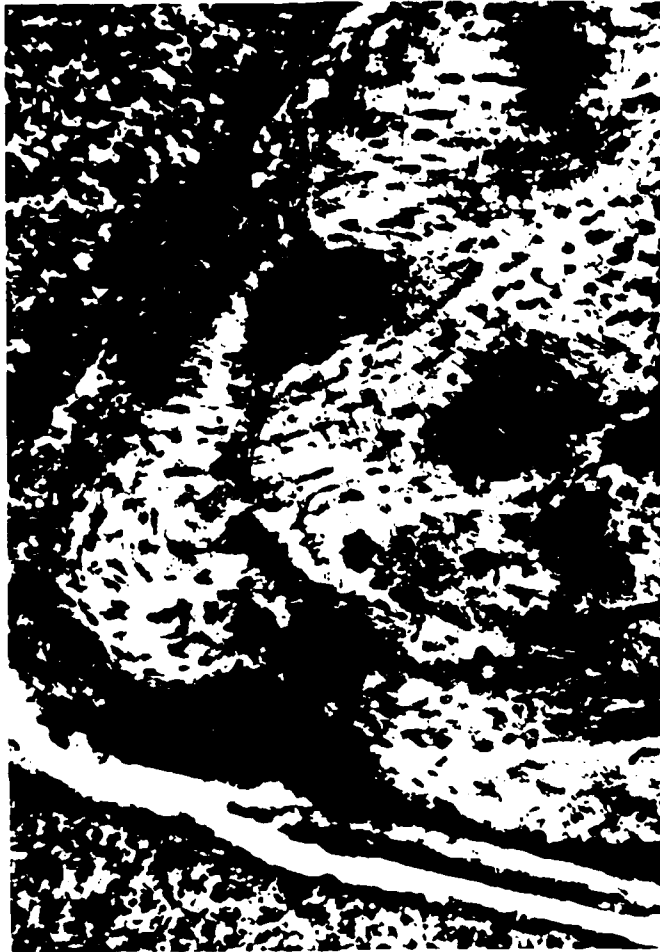

FIGURE 12. PHOTOMICROGRAPH OF SERRATION DETAIL A29 BABOON 469

This relatively high magnification view shows well developed bone, with lacunae and haversian systems. There are areas of connective tissue interspaced along the biomaterial interface. The implant has separated from the bone during preparation.

This is an implant representative of the longest implant duration observed in this study, 7.71 years.

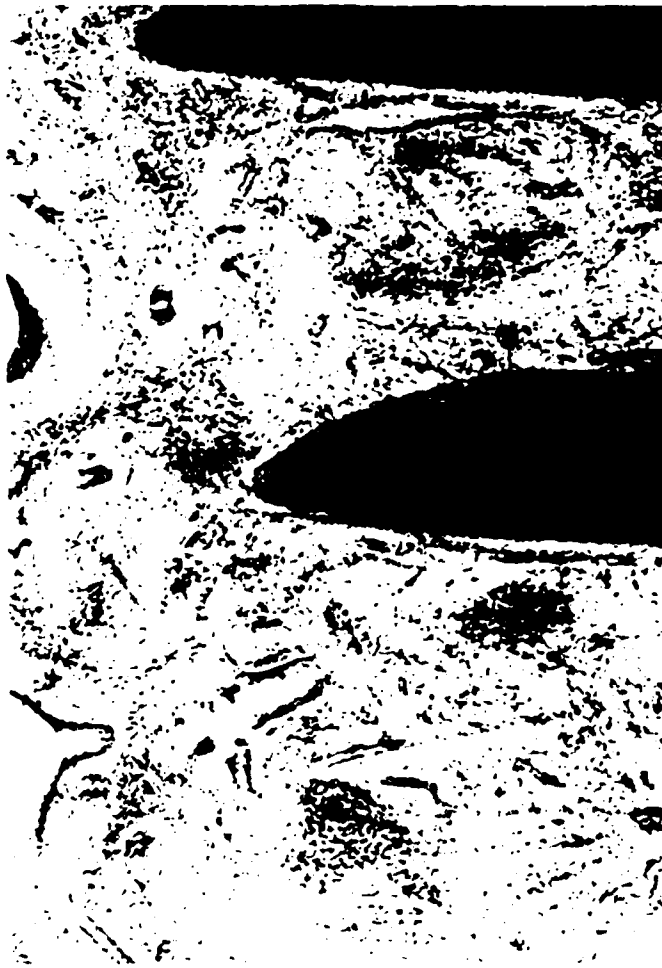

FIGURE 13. PHOTOMICROGRAPH OF IMPLANT A29 BABOON 469

This view demonstrates extremely dense bone totally surrounding a serration tip. The interface between bone and ceramic appears extremely tight, with no observable interface of connective tissue. This implant was in place for 7.71 years.

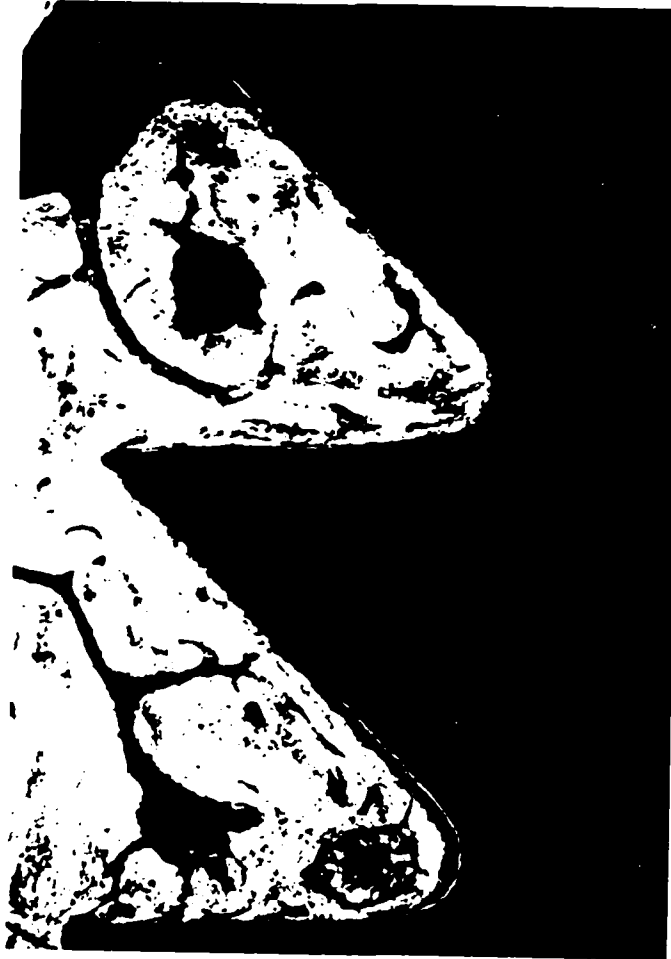

FIGURE 14. PHOTOMICROGRAPH OF IMPLANT A19 BABOON B

This preparation, like previous examples shows dense bone filling virtually all available space in two serrations. The staining process emphasizes connective tissue at the interface as well as in voids. Some slight separation, probably due to processing can be observed along portions of the interface.

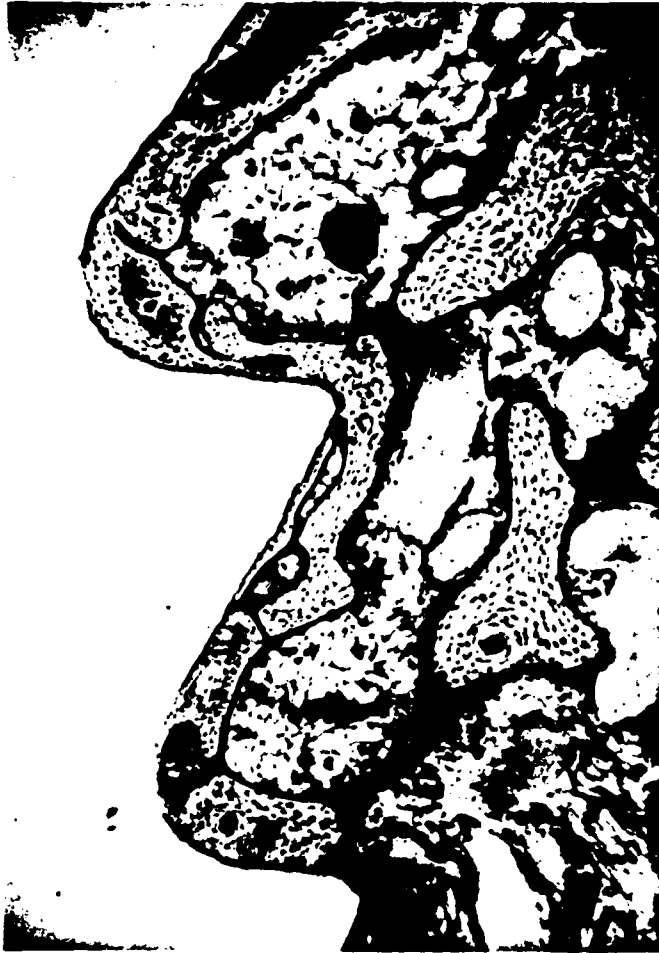

FIGURE 15. PHOTOMICROGRAPH OF IMPLANT A7 BABOON 713

This maxillary implant, in place for 2.12 years shows less dense bone architecture. The ceramic was removed during preparation. However, there appears to be a thin layer of connective tissue along most of the interface.

Figure 15 presents a somewhat different appearance, in that bone is not as dense. However, this is a maxillary implant in place for 2.12 years (Baboon 713, A7). There appears to be a thin layer of bone adherent to the ceramic, with large void spaces. This bone architecture is similar to that observed mesial and distal to some mandibular implants. Since our experience with maxillary implants is limited, it is premature to describe this result as typical of a maxillary site. Clinically this implant was rigid.

Clinical Chemistry and Hematology Results in Baboons

Throughout the project history hematology and clinical chemistry data were collected on all animals, at approximately 3-month intervals and prior to necropsy. No parameter indicated a significant alteration from baseline with the exception of values from animal 711, which periodically had low hematocrit. The parameters measured were: Glucose, BUN Chloride, Bilirubin, Alk. Phos., SGOT, SGPT, Creatinine, Na, Ca, Mg, K, Hemoglobin, Hematocrit, WBC, RBC, MCV, BANDS, SEGS, EOS, BASO, Lymph, Mono, Platelets, Retic, and Pro-time.

Histopathology Report

Analysis of tissue collected at gross necropsy was performed by the U.S. Army Pathology Laboratory under the direction of James B. Moe, D.V.M., Ph.D., Director of the Division of Pathology. Tissues were microscopically analyzed. Pathology narrative stated that a variety of pathologic lesions and tissue changes were observed in these baboons. Essentially all changes were interpreted as representing spontaneous clinically insignificant disease or effects of old age in the majority of cases. An interesting finding was the presence of nodular collections of hydroplastic acidophil cells in the anterior portion of the pituitary, a lesion which is not often observed in other species. The significance of this hydroplastic lesion is unknown. However, it is doubtful that this or any other lesion recorded reflected an adverse effect of chronic implantation of the ceramic teeth. The conclusion

was that there was no definitive evidence of an adverse systemic effect of chronic implantation of ceramic teeth in the baboons tissue. Complete histopathologic analysis was performed at Battelle on one animal which had died prematurely. A complete report of this early death is included in the 13th Report⁽³⁰⁾. The pathologist's analysis in this case was that the animal died of septicemia, the point of origin of infection not ascertained.

Aluminum Analyses

As with any implanted material there is always concern for the ultimate fate of that material in the body. To that end, tissue samples were collected from baboons at the time of scheduled necropsy. Elemental analyses for aluminum were performed. Table 3 indicates results for the 15 tissues that were analyzed for aluminum. Since no unimplanted control animals were included in our colony, two animals of approximately the same age and sex, housed under similar conditions were obtained from an unrelated experiment performed at The Ohio State University. The samples were analyzed by Dr. James L. Woodman at Rush Presbyterian St. Lukes Medical Center utilizing a Perken-Elmer model 4000 spectrophotometer with a HGA-400 graphite furnace. The techniques have been previously published.⁽³¹⁾

The aluminum oxide dental implant animals showed significant elevations of tissue aluminum concentration especially in the lungs, regional lymph nodes, gingiva, and tongue. Also included in Table 3 are comparative values reported by Woodman⁽³¹⁾ for a similar long term metallic ion analysis study in baboons. His study used Ti-6Al-4V samples. Thus, the source of aluminum ion in his study was the titanium alloy. The data cited from his study is for implant durations similar to those animals in this study. It is of interest to note similar aluminum ion concentrations in the two studies; the aluminum containing titanium long bone implants and the aluminum oxide dental implants. Control tissue concentrations are the same order of magnitude from both studies. In the dental implant study, the muscle harvested was the masseter, in the vicinity of the dental implant. In the case of the Woodman⁽³¹⁾ titanium study, muscle was harvested from skeletal muscle adjacent to the implant. There is almost a two-fold aluminum concentration in the muscle as

TABLE 3. TISSUE ALUMINUM CONCENTRATION IN BABOONS (ng/ml) DRY WEIGHT

Tissue	Al ₂ O ₃		Significance of Al ₂ O ₃ Vs. Control		Ti-6Al-4Va	
	Dental Implant	Control			Bone Implant ¹	Control
Lung	1576.27 +129.26	133.15 +1.3	P<.0001	*	1287.64 +31.76	281.23 +14.44
Lymph Node	682.62 +196.67	142.01 +4.09	P=.002	*	573.07 +26.91	74.13 +4.15
Muscle	239.19 +129.15	157.12 +5.50	P=.339	NS	345.16 +21.91	139.43 +10.47
Tongue	1470.16 +234.46	153.94 +2.70	P<.0001	*	--	--
Gingiva	417.16 +32.67	140.49 +7.77	P<.0001	*	--	--
Brain	118.15 +4.37	125.33 +2.47	P=.033	*	C>E	--
Kidney	119.92 +5.79	163.36 +9.84	P<.0001	*	C>E	101.97 +7.23
Spleen	122.48 +6.19	124.82 +2.46	P=.564	NS	179.31 +13.01	214.40 +19.09
Liver	125.26 +13.05	147.35 +3.89	P=.027	*	C>E	139.74 +12.96
Femur	875.31 +83.16	898.23 +2.03	P=.671	NS	--	--
Skin	131.50 +11.71	153.97 +15.35	P=.039	*	C>E	--
Heart	122.54 +4.90	164.29 +5.31	P<.0001	*	C>E	--
Stomach	130.78 +16.17	133.77 +11.72	P=.805	NS	--	--
Thyroid	129.86 +11.22	133.00 +3.85	P=.670	NS	--	--
Pancreas	123.00 +9.65	134.05 +10.59	P=.138	NS	--	--

¹Ti-6Al-4Va Data from Woodman et al.

6 Experimental Al₂O₃ Animals

2 Control Animals

*Statistically significant

compared to controls. Due to the dental implant study design, it was not possible to calculate a release rate. However, the Woodman study showed a zero order release rate for aluminum. This implies a continual release of aluminum not leveling off at any time. The consequence of this finding is unknown. However, up to the termination of our study, observable pathology attributable to the dental implants was indicated.

Clinical Studies

The clinical portion of this project has involved the implantation of rectangular ceramic roots in 60 patients. The clinical study commenced in August, 1978. The roots were implanted using three different techniques. In the first 25 patients, roots were implanted in mandibular areas with the first (or uppermost) serration flush with the alveolar crest. This implant height was dictated by the original post and core design, in which the gold overlapped the outside of the root structure and extended downward into the gingival sulcus. In the human, the implant was placed high enough to allow post and core seating without bone removal. The implant was placed higher than the preceding in baboon studies. Success in baboons, even when the implants were left to protrude slightly above the alveolar bone level, gave us confidence that in the "cooperative" human subject this procedure would be acceptable. In the first 25 patients, mandibular molar and premolar sites were used. Seventeen were healed sites and 8 were fresh extraction sites. All implants were periodically observed by clinical observation and x-ray. All implants were rigid at the time of surgery, by virtue of the interference fit produced by tapping the implant into place. All implants exhibited some degree of buccal-lingual mobility within the first 1 to 3 months post-implant. The degree of mobility and the cause of the increase in mobility was highly variable, but typically 1/2 mm or less mobility was observed within that time period. Sixteen of the 25 patients exhibited a subsequent decrease in mobility with time. Of the original patients, 6 are still in function with no buccal-lingual mobility. But three of the six have been unavailable for followup. Average implant time for the remaining implants in this group is 6.5 years (see Table 4).

TABLE 4. RESULTS OF GROUP I IMPLANT PATIENTS NON-STABILIZED RESTORED

Patient	Site	Surg.	Reconstruct.	Implant Time Yrs.	Function Time Yrs.	Mobility mm.	Status	Remarks
78R1	19F*	8-16-78	5-16-79	6.80	6.05	0.00	A	Pocketing 0-9 mm
78R2	30H	8-20-78	--	4.93	--		F	
78R3	30F	10-18-78	4-04-80	2.10	0.63		F	
78R4	31F	10-25-78	8-17-79	2.59	1.77		F	
78R5	31H	11-01-78	2-29-80	4.75	3.43		?	
78R6	30F	11-08-78	8-31-79	6.56	5.76	0.00	A	Pocketing 2-6 mm
78R7	29F	11-29-78	11-06-79	2.50	1.56		F	
78R8	19H	1-10-79	--	2.24	--		F	
78R9	19H	1-17-79	--	0.39	--		F	
78R10	19H	1-24-79	4-11-80	1.60	0.38		F	
78R11	30F	1-31-79	--	1.81	--		F	
78R12	29H	2-01-79	--	2.18	--		F	
78R13	19H	2-14-79	7-18-80	2.04	0.62		F	
78R14	19H	2-21-79	3-14-80	1.25	0.19		F	
78R15	30H	2-28-79	2-15-80	1.06	0.10		F	
78R16	19H	3-05-79	4-25-80	4.42	3.28		F	
78R17	30H	3-07-79	--	0.04	--		F	
78R18	19H	4-04-79	4-11-80	6.16	5.15	?	A	Pt reports "All is well" will be seen
78R19	19F	4-04-79	4-25-80	2.01	0.95		F	
78R20	18H	4-17-79	3-14-80	1.98	1.07		F	
78R21	19H	4-25-79	4-11-80	3.22	2.26		F	
78R22	19H	5-02-79	3-07-80	2.07	1.22		F	
78R23	19H	5-16-79	4-04-80	4.22	3.33		?	
78R24	30F	7-11-79	2-29-80	2.50	1.87		F	
78R25	30H	7-20-79	3-21-80	4.04	3.37		?	
Average of 3 active sites				6.50	5.65			

*F = Fresh extraction site
H = Healed site

The typical failure process observed was a slow increase in mobility over two years. When mobility reached 1 mm buccal-lingual, with rotation present, the implant was removed to prevent unnecessary bone loss. Two patients had infection noted at implant removal time. Seven patients near removal time indicated some degree of soreness when biting hard. Generally gingival health remained excellent in all patients regardless of the state of failure. Most patients utilized the implants as functional and aesthetic devices up until the time of removal. Several patients had to be convinced of impending implant failure, since they were satisfied with the devices. All patients with implants removed have gone on to heal uneventually.

In view of the difficulty of obtaining stability in the first group of patients, the next series of 6 patients (Group II) were performed using orthodontic devices to stabilize the implant to adjacent teeth. Orthodontic bands were fitted to adjacent teeth and connected by wires. An acrylic cap was fitted over the top of the implant to support and protect the implant.

The patients were implanted in the posterior mandibular areas, 5 in healed sites, and 1 fresh extraction site. The fresh extraction site implant never stabilized and was never restored. The implant was removed at 35 weeks post-surgery when rotation was observed.

Four of the healed site implants remain in function, but they exhibit about 0.5 mm buccal-lingual mobility. The average implant time in this group is 4.93 years, with a range of 5.05 years to 4.82 years. The one functional failure in this group occurred after being implanted for 1.75 years and functional for 1.27 years. The overall success rate is 67 percent. This group of implants continues to be of interest because there have been no additional losses despite the slight mobility (see Table 5).

A third group of patients (Group III) was intended to assess if a deeper placement of the root would offer additional protection from mechanical strain, and facilitate the long term rigid situation, commonly observed in baboon studies. The implant design as utilized in Group I studies prevented flush placement of the implant. For Group III, the gold overlap (or coping) was removed, thus creating a post and core flush with the exterior surface of the alumina. Mechanical testing indicated that this removal of coping did not reduce the mechanical strength of the root-post and core attachment. Additionally, the ceramic root portion was modified to facilitate flush placement.

TABLE 5. RESULTS OF GROUP II IMPLANT PATIENTS

Patient	Site	Surg.	Reconstruct	Implant Time	Function Time	Mobility in mm's	Status	Remarks
79RD1	19H	5-14-80	3-06-81	5.05	4.26	0.5	A	Pocketing 3-6 mm
RD2	29H	5-21-80	3-06-81	5.03	4.26	?	A	Living in Georgia
RD3	30H	7-23-80	1-16-81	1.75	1.27		F	
RD4	30H	8-01-80	1-16-81	4.84	4.38	0.5 mm	A	Pocketing 2-3 mm
RD5	19H	8-08-80	3-06-81	4.82	4.26	< 0.5 mm	A	Pockets 2-5 mm
RD6	19F	9-12-80	-	-	-		F	

Average of four active sites =

4.93 yrs

4.29 yrs

4 Healed sites

F = Fresh extraction sites

H = Healed sites

Twenty-nine patients were implanted in both fresh and healed sites using the flush implant technique (Group III). Fifteen implants were placed in posterior mandibular areas and 14 were placed in anterior maxillary areas. Sixteen of the 29 or 55 percent of the implants remain, however, one is not available for followup. The average implant time for the group is 2.84 years with a range of 4.17 to 1.57 years. Mean time to restored implant failure is 1.37 years (see Table 6).

Tricalcium phosphate in the granular form was used either as a salvage procedure or at the initial surgical implant to assess its value as a surgical in the surgical procedure. Three of the six cases where tricalcium phosphate was used at the time of surgery failed. Thus, no claim can be made as to whether this additional procedure facilitated or impeded surgical procedure. Only one of the three implants where tricalcium phosphate was used in attempt to salvage the root went on to success. Here again, it is impossible to judge whether the tricalcium phosphate was beneficial. The granular tricalcium phosphate packed around a loose implant appeared to have an immediate stabilizing effect. No deleterious effects were noted that could be uniquely attributed to the tricalcium phosphate presence in the surgical site.

Data for the three human implant groups are graphically displayed in Figures 16, 17, and 18. The bar graphs show the total implant history including duration of implant, relative time of restoration, and success or failure status. The dates indicate the last complete examination on each patient prior to the compilation of this data. Where possible, patients have been reexamined subsequent to this compilation.

The human studies have presented a relatively stable picture during the last project year. The losses have been minimal thus reinforcing the previous hypothesis that stated the initial stabilization of the dental implant is a critical step in long term success. The present data tend to substantiate that hypothesis. Group II and Group III implants appear to have potential success rates in the 50-65 percent region. The Group I implant success rate is very poor but there have been no additional losses thus indicating that those implants successfully stabilized have a high probability for long term success.

TABLE 6. RESULTS OF GROUP III IMPLANT PATIENTS BURIED ROOT RESTORED

Patient	Site	Surg.	Reconstruct.	Implant Time Yrs.	Function Time Yrs.	Mobility mm.	Status	Remarks
81R1	31F**	4-01-81	11-06-81	4.17	3.57	0.0	A	3-7 mm pockets
R2	20H	4-03-81	11-20-81	0.67	0.04	--	F	12-04-82
R3	10H	4-17-83	1-29-82	4.13	3.34	0.0	A	Pockets 2-3 mm
R4	5H	4-29-81	7-27-83	4.10	1.85	0.0	A	Pockets 2-5 mm
R5	8H	5-08-81	2-17-82	4.07	3.29	?	A	Telephoned" in place"
R6	30H	5-27-81	--	0.78	--	--	F	3-09-82
R7	19H	5-29-81	--	3.68	--	--	?	Pt. moved. Unable to follow.
R8	30H	6-05-81+	4-14-82	2.16	0.12	--	F	Gingival graft also tried.
R9	19H	7-15-81	3-10-82	1.00	0.23	--	F	7-16-82
R10	8H	7-17-81	2-24-82	3.03	2.42	--	F	7-30-84
R11	29H	2-03-82+	--	2.13	--	--	F	3-29-84
R12	12H	3-19-82	7-28-83	2.91	1.85	0.0	A	Pockets 4-8 mm
R13	19H	3-31-82	--	1.35	0.10	--	F	9-12-83
R14	19H	5-05-82+	--	3.08	0.97	0.0	A	Pockets 2-3 mm
R15	30H	5-19-82	7-18-83	3.14	1.88	0.0	A	Pockets 2-9 mm
R16	30F	5-26-82	--	0.06	--	--	F	6-17-82
R17	9F	6-04-82	--	0.72	--	--	F	2-21-83
R18	19H+	8-18-82	--	0.98	--	--	F	
R19	4H	8-27-82	7-18-83	2.76	1.77	0.0	A	
R20	30H	9-01-82*	7-20-83	0.27	0.04	--	F	9-22-83
R21	9H	11-10-82	--	2.56	1.77	0.5	A	Pockets 3-6 mm
R22	30F	11-10-82	7-26-83	2.56	1.86	?	A	Lives in Atlanta GA Says all "O.K."
R23	20H	1-19-83*	--	1.23	--	--	F	4-10-84
R24	10H	1-26-83*	8-30-83	2.35	0.76	1.0	A	Pockets 2-5 mm
R25	9H	8-03-83	12-21-84	1.86	0.45	0.0	A	Pockets 2-8 mm Pt has perio. dis.

**F = Fresh extraction site
H = Healed site

Failure dates noted in remarks column

TABLE 6. (Continued)

Patient	Site	Surg.	Reconstruct.	Implant Time Yrs.	Function Time Yrs.	Mobility mm.	Status	Remarks
R26	7F	8-05-83	6-14-84	1.82	1.03	0.5	A	Pockets 2-8 mm
R27	7H	10-12-83*	12-21-84	1.52	0.45	0.0	A	Pockets 2-8 mm
R28	12F	11-10-83*	5-29-84	1.57	1.01	0.0	A	Pt has perio dis.
R29	8F	12-8-83*	6-18-84	<u>0.53</u>	<u>0.12</u>	--	F	Pockets 2-6 mm 7-31-84
15 Active Sites Ave.				$\bar{X} = 2.84$	1.72	0.15		
				SD = .94	1.01	0.31		
				n = 15	15	13		

+T.C.P. used later to save.

*T.C.P. Used at surgery as "scaffolding"

Sites: Healed = 22

Fresh = 7

FIGURE 16.

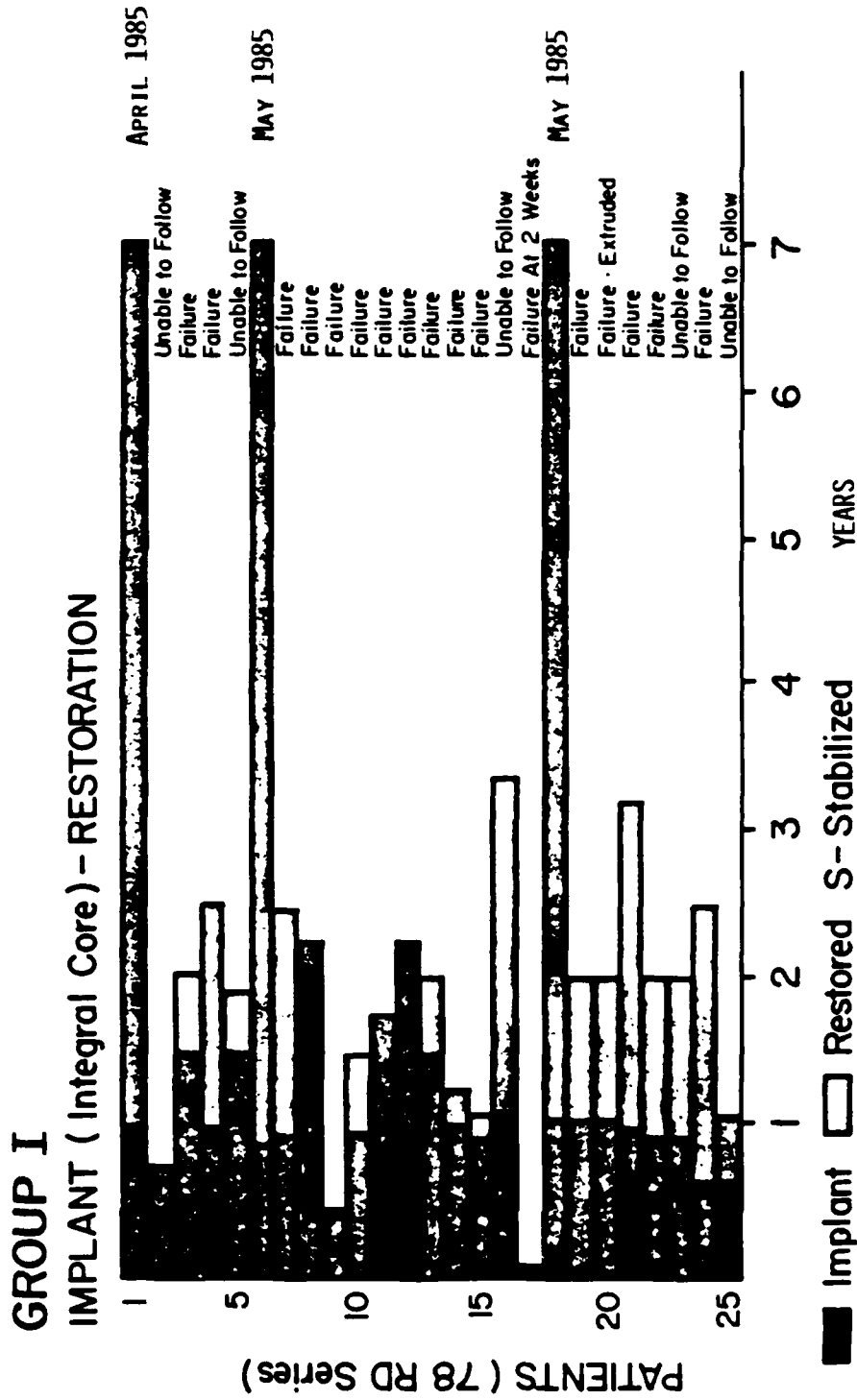


FIGURE 17.

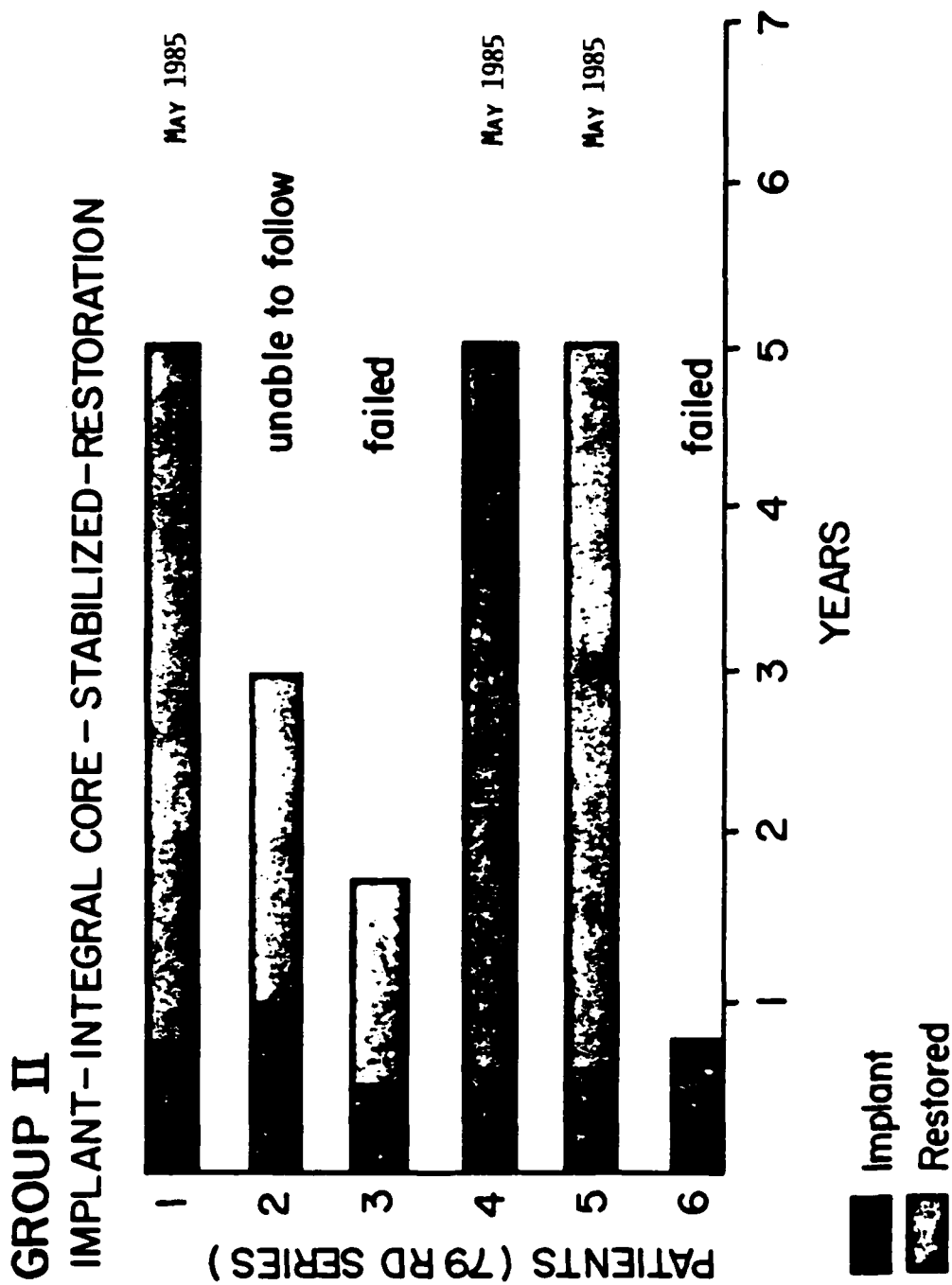
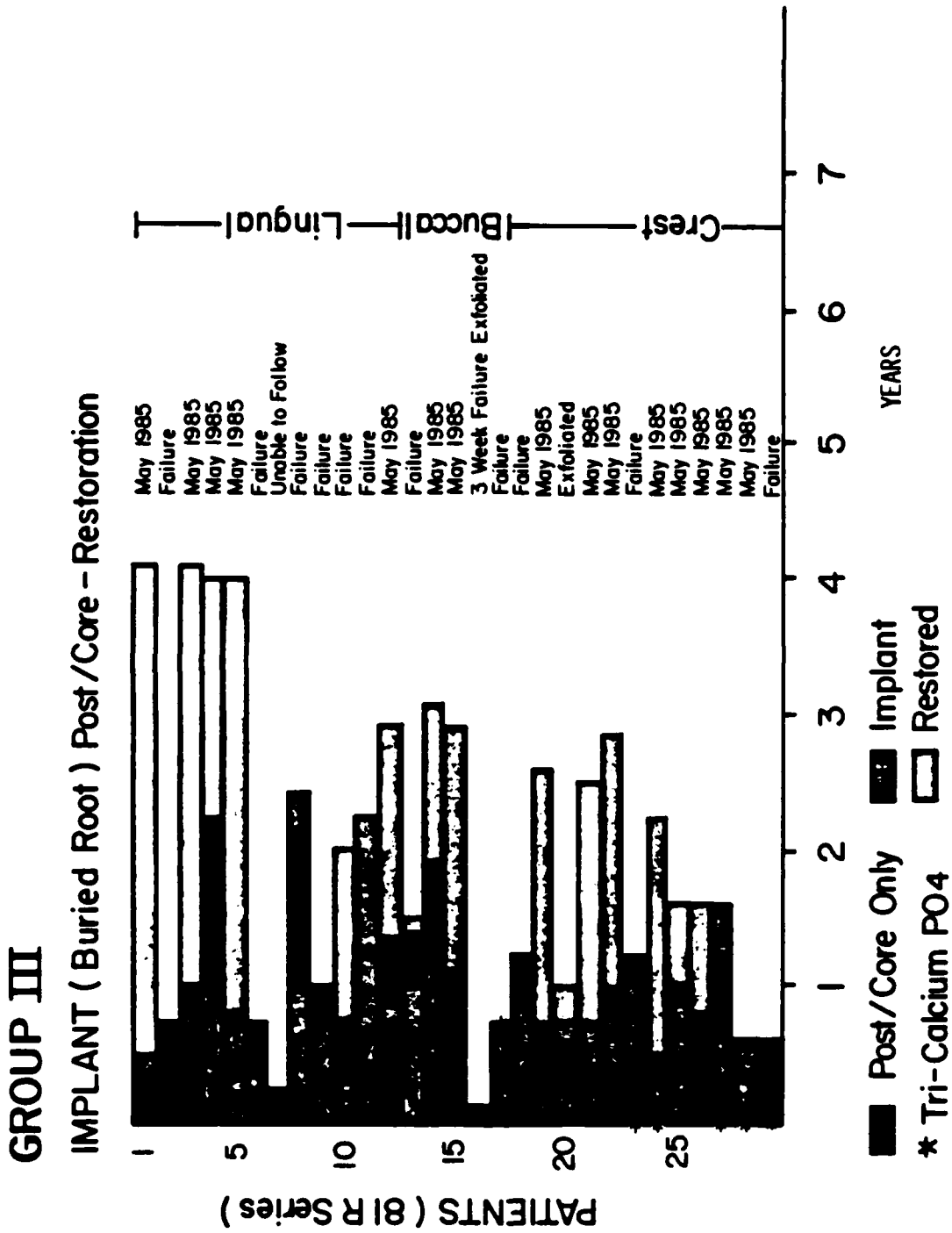


FIGURE 18.



Unfortunately, in all groups, the overall success rate is less than desired. However, this success and failure should be kept in context. The military objective of having an implant to fit a fresh extraction site dictated the use of the rectangular implant. This particular design constraint is thought to be a critical factor inhibiting initial ingrowth success and consequently limiting the long term successful outcome of the implants. Since a rectangular implant site is difficult to create in the bone, considerable bone growth is required before stabilization of the implant can be obtained as compared to a circular implant where a perfect hole to fit the implant can be created. Consequently, one would predict a higher long term success rate if a circular implant system were utilized. The screw type implant system of Branemark⁽³⁵⁾ has had reported success rates of about 80 percent. On the other hand, a circular implant system would be of little use in fresh extraction sites.

Examples of Clinical Case

Figures 19 and 20 show the clinical and radiographic appearance of a successful Group 1 implant. This particular implant indicates the success that can be obtained. This mandibular implant was placed in a fresh extraction site and has now been in place for 6.56 years with minimal alveolar bone loss. There is no mobility, and the implant appears clinically healthy in all aspects. The radiograph Figure 20 indicates dense bone formation of such magnitude that the implant serration detail is obscured. Alveolar bone height appears stable on all radiographs for the past 6 years. Unfortunately, this result was obtained in a minority of the clinical implants.

Clinical Implant Radiographic Analysis

Routine patient X-rays indicated in general a continual loss of bone height about the implants. Custom fixtures were fabricated for patients to assure consistent alignment of repeated periapical X-rays. From these X-rays, the percentage of bone height remaining as a function of implant height was calculated. Consequently the higher the percentage, the more bone adjacent to



FIGURE 19. CLINICAL PHOTOGRAPH OF POSTERIOR MANDIBULAR HUMAN IMPLANT (78R6)

This is an example of a success from the Group I patients, where the root was allowed to protrude slightly above the alveolar crest. This implant has been rigid and functional with minimal bone loss and excellent gingival health for 5-7 years.



FIGURE 20. RADIOGRAPH OF POSTERIOR MANDIBULAR IMPLANT (78R6)

This successful implant exhibits sufficient density of bone to obscure the serration detail. There has been minimal bone loss throughout the 6.5 year history of this implant. (This is the same case as Figure 19.)

the aluminum oxide portion of the implant. Figures 21, 22, and 23 demonstrate the percentage bone remaining for successful and failed implants for all three groups. The data displayed are the result of a least squares curve fit. In all three cases a constant time-related loss of alveolar bone around the implant can be observed for the failed implants. A similar but less dramatic bone height loss can be seen for successful implants. Thus, for all implants, either failed or successful, there is a continuous loss of alveolar bone height about the implant. Bone height loss appears to be correlated with implant loss. But, the high percentages for early failures indicate that bone height is not the sole determinant of early loss. Lack of bone apposition is probably of importance in early losses. Cross comparisons between groups must be made with caution since there is a different number of cases included within each category of implant group. The continuing bone loss, even in the successful implants, suggest the present successes may eventually fail due to loss of bone height. After 40 months, there is a slight suggestion of leveling off of bone loss, but only in Group I.

Periodontal Study

In light of the continuing implant bone height loss, a periodontal evaluation was performed to hopefully elucidate the pathogenic mechanisms leading to tooth implant failures. This study characterized the differences in bacterial flora between: Healthy sulci, periodontal pockets, and the gingival tissue envelope surrounding clinically asymptomatic alumina tooth root implants. Twelve subjects who had a clinically asymptomatic alumina implant for an average of 4.6 ± 1.8 years were selected for the study population. Each patient had: one clinically health sulcus, one periodontal pocket depth greater than or equal to 3 mm with bleeding on probing, and one implant. These teeth/implants were evaluated at six sites for: probe depth, pocket depth, bleeding on probing, mobility (free and functional) and presence of plaque. Plaque samples were then taken by sterile curette at one site on each tooth/implant and differential dark field morphology was evaluated by a blind evaluator. The plauque accumulation in diseased and implant sites was similar (50 and 61 percent, respectively) (see Table 7). Bleeding on probing

FIGURE 21.

LEAST SQUARES CURVE OF BONE HEIGHT FOR GROUP I IMPLANTS

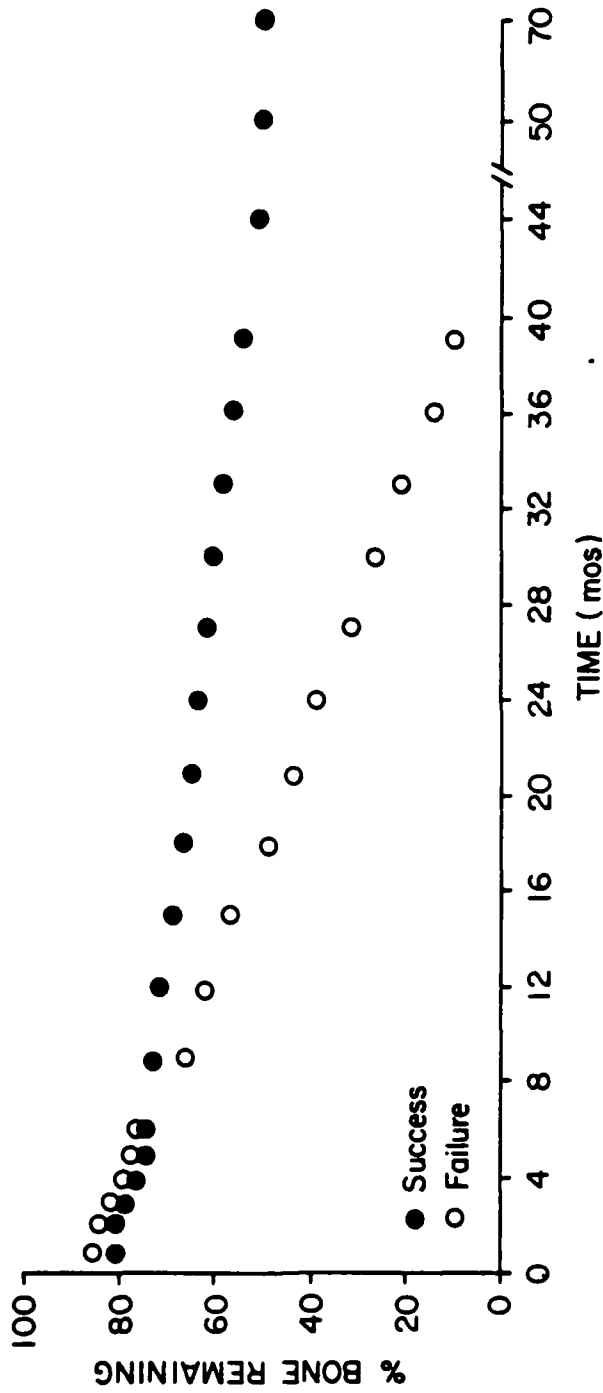


FIGURE 22.

LEAST SQUARES CURVE OF BONE HEIGHT FOR GROUP II IMPLANTS

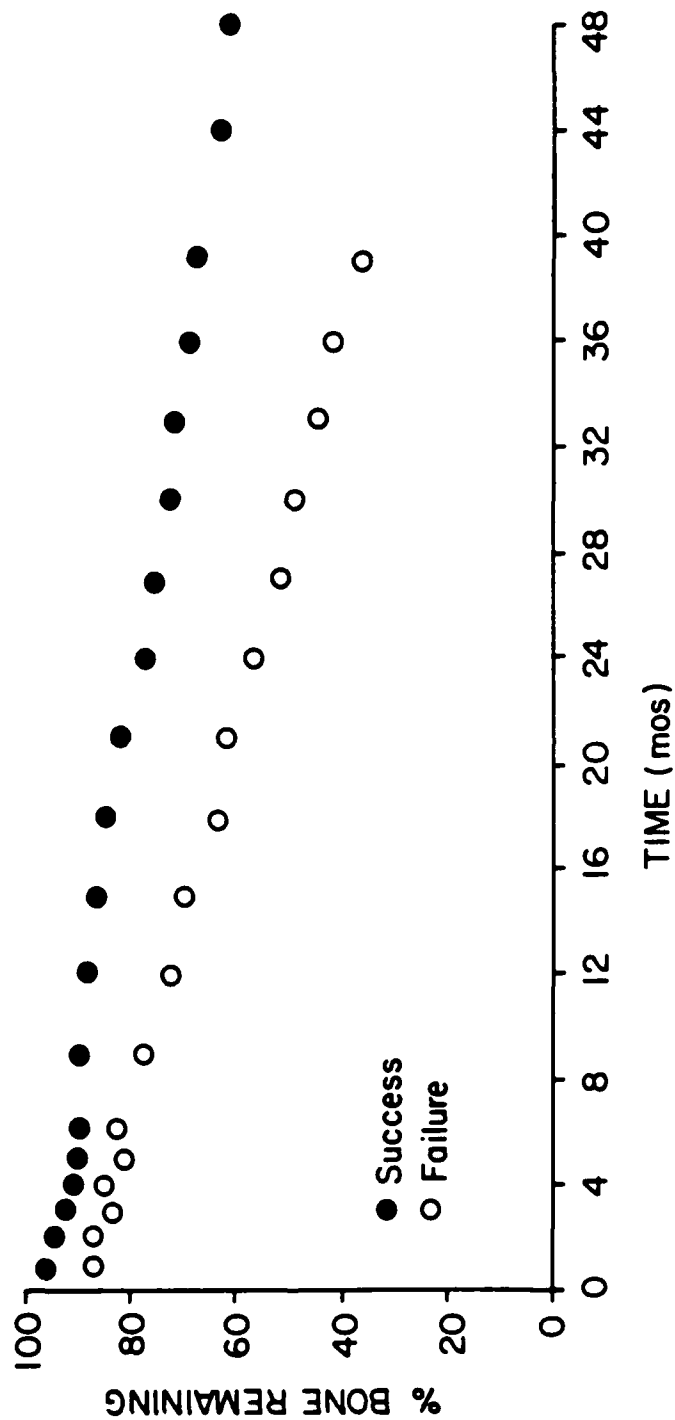


FIGURE 23.

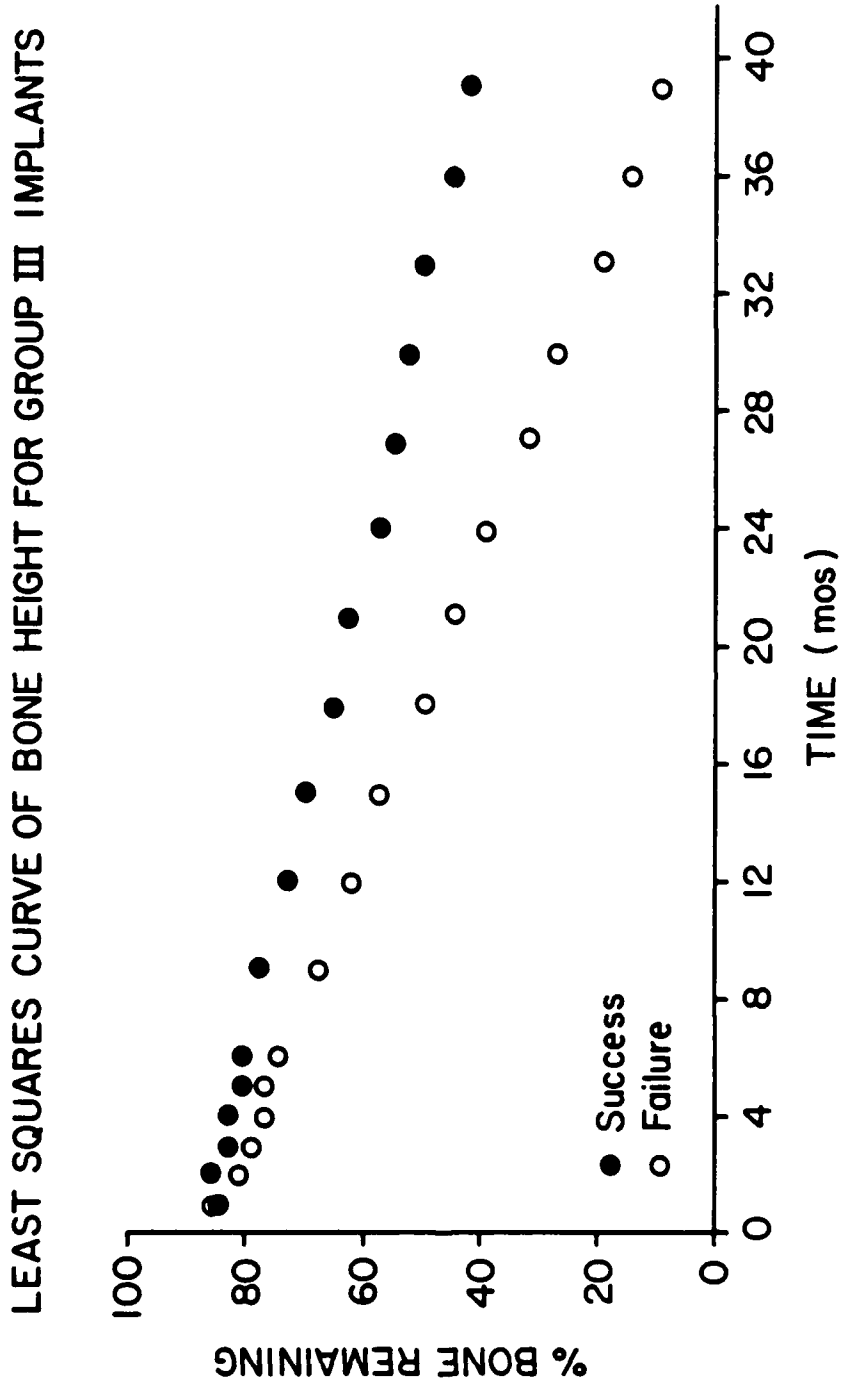


TABLE 7. PERIODONTAL ANALYSIS

Cross Sectional Study						
Sites	Bleeding on Probing*		Plaque		Pocket Depth in mm's Average of Measurements	
					S.D.	
Healthy	14.1%	(n=13)	38.3%	(n=11)	2.37 ± 0.26	(n=13)
Diseased	44.9%	(n=13)	61.0%	(n=11)	3.08 ± 0.62	(n=13)
Implant	69.0%	(n=14)	50.0%	(n=12)	4.51 ± 0.99	(n=14)

*The Bleeding on Probing data represent the presence/absence of periodontal disease, and is a non-parametric analysis.

The pocket depths of the healthy, diseased, and implant sites were compared and analyzed using a paired 't' (2-tailed) test. At a probability level (p=.05) there was no significant difference between: healthy and diseased sites ("t" = 3.84) healthy and implant sites ("t" = 7.62); and diseased and implant sites ("t" = 13.89). For this data the critical "t" values were 2.15 (p=.05) to 1.78 (p = .01).

Darkfield Microflora Analysis

Results are expressed as percent of total organisms

Sites	Coccoid		Filamentous		Fusiform	
Healthy	67.08 ± 5.48		0.0		7.79 ± 4.59	
Diseased	51.07 ± 19.19		1.39 ± 3.06		11.81 ± 5.20	
Implant	60.71 ± 11.92		0.74 ± 1.04		13.09 ± 7.13	
Sites	Non-Motile Rods		Motile Rods		Spirochetes	
	Small	Large	Small	Large	Small	Large
Healthy	21.34 ± 5.51	2.85 ± 3.03	0.27 ± 0.75	0.57 ± 1.37	0.0	0.0
Diseased	17.71 ± 5.77	5.70 ± 4.33	2.01 ± 3.81	3.76 ± 6.02	3.29 ± 4.92	3.75 ± 7.92
Implant	18.73 ± 5.30	3.88 ± 4.33	0.56 ± 1.81	1.68 ± 2.17	0.33 ± 0.81	0.25 ± 0.85

One Patient Longitudinal Study December 1984 - June 1985

It appears that the population time for the microflora to reach equilibrium in the one patient with two sites (#7, #9-implants 81 R 25 * 81 R 27) is approximately two months from the time of restoration.

was significantly greater ($p < .05$) greater in implant sites (69 percent) than diseased sites (45 percent). Implant sites also showed significantly fewer total spirochetes (0.6 percent) than diseased sites (7 percent) and fewer total motile rods (2.2 percent) than diseased sites (5.8 percent). This study indicated periodontal destruction is occurring around the serrated alumina implants but the destruction may be associated with different forms of microflora than that surrounding natural teeth. Consequently, conventional microscopic techniques for screening patients for periodontal destruction might be inadequate for implant patients.

CONCLUSIONS

The historical significance of this project in the development of dental implantology must not be overlooked. The early stages of this project clearly defined that rigid fixation of an implant device via bony ingrowth into serrations was a feasible technique and possibly superior to the historically favored notion that it was necessary to create a pseudoperiodontal ligament for implant success. More recently, several investigators have researched, reported upon, and manufactured devices which employ rigid fixation to bone. A critical difference between this project and others is that this project's implant was designed specifically for fresh extraction sites. Obtaining successful ingrowth appears more difficult in a fresh extraction site. But this type of implant is directly applicable to the envisioned military application. Typically devices designed for the civilian population are for use in edentulous sites. They are generally cylindrical in cross section. The advantage of the circular cross section is that the device can be easily put in close apposition with bone. Bone ingrowth time is minimized and the distance over which bone must heal is minimized. Consequently, circular devices should have a higher success rate than a rectangular implant. If the design presented in this report were manufactured in circular cross section, results similar to circular serrated type devices should be anticipated.

Despite the restrictions imposed upon the study by the rectangular design constraint, the baboon studies were astoundingly successful and a high success

rate was obtained. Long residence times and successful function was obtained from the baboons. They have provided valuable information about long-term effects of alumina implant devices. This study indicated via gross and histopathologic analyses that no untoward effect could be attributed to the presence of the aluminum oxide dental implants. Further, atomic absorption spectrophotometer studies indicated significant increases in aluminum in: lung, regional lymph nodes, tongue, and gingiva. The study indicated aluminum oxide is not totally inert, but produced no ill effects to within the study duration.

This study has taken advantage of advances in ceramics processing technology. From the early crude implants evolved the present high strength, accurately dimensioned, bisque contour ground dental implants. The slight roughness left by the grinding technique is thought to facilitate bone apposition. Flexural strength of the latest alumina produced approached 70,000 psi. The presently attainable ceramic strengths appears adequate for dental applications. This is not to say that stronger ceramics should not be developed. The general medical use of bioceramics would be tremendously advanced by further strength increase. Further, the unique biocompatibility observed with the aluminum oxide in this study place it in a special group of materials which appear to exist in close apposition to bone without an intervening connective tissue layer. This special property may prove useful in future medical applications.

This clinical study indicate that initial stabilization and bone ingrowth are critical to the long term success of the dental implant. Unfortunately, alveolar bone height loss indicates most patients continually loose bone around the implant. However, the ability of some patients and most baboons to resist loss of vertical bone height indicates that bone maintenance is possible. A satisfactory method to bond or seal the gingiva to the implant might be required. However, the ability of some patients to resist bone loss confounds this conclusion.

A fresh extraction site dental implant device was successfully demonstrated in baboons and to a lesser extent in the humans. However, in light of the study objectives to develop a fresh extraction site implant, the success rate is reasonable.

Recommendations

It is recommended that the human study be continued and the patients with implants presently in place be observed until each patient has been followed for a minimum of 5 years post-implant. This recommendation is in keeping with the American Dental Association consensus standards. In the majority of the patients, a history of the microbiological flora has been obtained. It is now appropriate to treat these patients to ascertain if the continual loss of alveolar bone height can be arrested or reversed by aggressive therapy. A further human trial should be undertaken with a circular implant of the same serration design to ascertain whether a higher success rate can be achieved in an edentulous site than was possible with the rectangular implant.

REFERENCES

1. Hassler, C. R., L. G. McCoy, R. H. Downes, and O. Russell. 1977. Ceramic tooth implants in baboons. Journ. Dent. Res., 56A: A117.
2. Hassler, C. R. and L. G. McCoy. 1977. Surgical tooth implants, combat and field. Report No. 8, Contract No. DADA17-69-C-9181.
3. Hassler, C. R., L. G. McCoy, R. H. Downes, L. C. Clark, and O. E. Russell. 1978. Ceramic tooth implants in baboons. Trans. Soc. of Biomaterials, 2: 114.
4. Hassler, C. R., and L. G. McCoy. 1976. Surgical tooth implants, combat and field. Report No. 7, Contract No. DADA17-69-C-9181.
5. Rasmussen, J. J., M. T. Karagianes, R. B. Westerman, and R. D. Marshall. 1973. Dental anchors of non-natural design implanted in miniature swine. J. Dent. Res., 52: 124.
6. Weiss, M. B., J. W. Rostoker, and E. Ronen. 1976. Six year study of an endosseous dental implant. J. Dent. Res., 55(b): 36.
7. Spector, M., N. M. Garden, J. T. Eldridge, and S. L. Harmon. 1977. Alveolar bone repair and porous endosseous dental implants. J. Dent. Res., 56A: 119.
8. Sandhaus, J. and I. Bar-Oz. 1977. Sixteen years experience of a bioceramic implant for oral rehabilitation. Trans. Soc. Biomaterials, 1: 45.
9. Hassler, C. R., E. F. Rybicki, K. D. Cummings, and L. C. Clark. 1977. Quantitation of compressive stress and its effects upon bone remodeling. Bulletin, Hosp. for Joint Diseases, 23: 90-93.
10. Driskell, T. D., M. J. O'Hara, and C. W. Greene, Jr., D.D.S. 1971. Surgical tooth implants, combat and field. Report No. 1, Contract No. DADA17-69-C-9181.
11. Driskell, T. D., M. J. O'Hara, and D. E. Niesz. 1973. Surgical tooth implant, combat and field. Report No. 2, Contract No. DADA17-69-C-9181.
12. Driskell, T. D., L. G. McCoy, V. J. Tennery, and D. E. Niesz. 1973. Surgical tooth implants, combat and field. Report No. 3, Contract No. DADA17-69-C-9181.
13. Hassler, C. R., T. D. Driskell, L. G. McCoy, and D. E. Niesz. 1974. Surgical tooth implants, combat and field. Report No. 4, Contract No. DADA17-69-C-9181.

14. Hassler, C. R. and L. G. McCoy. 1974. Surgical tooth implants, combat and field. Report No. 5, Contract No. DADA17-69-C-9181.
15. Hassler, C. R. and L. G. McCoy. 1975. Surgical tooth implants, combat and field. Report No. 6, Contract No. DADA17-69-C-9181.
16. Hassler, C. R., L. G. McCoy, R. H. Downes, L. G. Racey, and O. E. Russell. 1976. Ceramic tooth implants in primates. Jour. Dent. Res., 55B: 242.
17. Hassler, C. R., R. H. Downes, G. L. Messing, O. E. Russell. 1978. Surgical tooth implants, combat and field. Report No. 9, Contract No. DADA17-69-C-9181.
18. Hassler, C. R. 1978. Aluminum oxide implants in baboons. Alabama Implant Congress (May).
19. Hoagland, R. G., C. W. Marschall, and W. H. Duckworth. 1976. Reduction of errors in ceramic bend tests. J. Am. Ceram. Soc., 59(5-6): 189-192.
20. Messing, G. L., L. G. McCoy, and C. R. Hassler. 1979. The fabrication of Al_2O_3 tooth roots by diamond contour grinding, in the science of ceramic machining and surface finishing. II Dept. of Commerce (NBS), Hackey and Rice (eds.).
21. Perrin, S. M. and A. Baity. 1978. Cellular differentiation and bone biomechanics during the consolidation of a fracture. Anatomic Clinica, pp. 13-28.
22. Hassler, C. R., L. G. McCoy, R. H. Downes, and O. E. Russell. 1977. Ceramic tooth implants in baboons. Journ. Dent. Res., 56B.
23. Hassler, C. R., L. G. McCoy, R. H. Downes, L. C. Clark, and O. E. Russell. 1978. Ceramic tooth implants in baboons. Trans. 4th Ann. Biomaterials Society, April, p. 114.
24. Hassler, C. R., G. L. Messing, R. H. Downes, and O. E. Russell. 1979. Serrated tooth implants in animals and humans. Jour. Dent. Res., 58A: 298.
25. Hassler, C. R., E. F. Rybicki, K. D. Cummings, and L. C. Clark. 1980. Quantification of bone stresses during remodeling. J. Biomechanics, 13: 185-190.
26. Hassler, C. R., R. H. Downes, and G. L. Messing. 1980. Ceramic tooth implants of serrated design. Proc. 1st World Biomaterials Congress, Vienna, April, 1: 1.5.
27. Hassler, C. R., R. H. Downes, G. L. Messing, and O. E. Russell. 1979. Surgical tooth implants, combat and field. Report No. 10, Contract No. DADA17-69-C-9181.

28. Hassler, C. R., R. H. Downes, and L. G. McCoy. 1981. Surgical tooth implants, combat and field. Report No. 11, Contract No. DADA17-69-C-9181.
29. Hassler, C. R., R. H. Downes, and L. G. McCoy. 1982. Surgical tooth implants, combat and field. Report No. 12, Contract No. DAMD17-82-C-2020.
30. Hassler, C. R., L. G. McCoy, and N. E. Arlin. 1983. Surgical tooth implants, combat and field. Report No. 13, Contract No. DAMD-17-82-C-2020.
31. Woodman, J. L., J. J. Jacobs, J. O. Golante, and R. M. Unban. 1984. Metal ion release from titanium-based prosthetic segmented replacements of long bones in baboons: a long term study. J. Orthop. Res., 1(4): 421-430.
32. Caton, J. 1979. Establishing and maintaining clinically healthy gingival in Rhesus monkeys. J. Clin Periodontology, 6: 260-2163.
33. Frost, H. M. 1983. Bone histomorphometry: choice of marking agent and labeling schedule. In: Bone Histomorphometry: Techniques and Interpretation, edited by R. R. Reckler, C.R.C. Press, Boca Raton, Florida, pp. 34-52.
34. Hassler, C. R., 1984. Surgical Tooth Implants, Combat and Field Report No. 14, Contract No. DAMD-17-82-C-2020.
35. Leckholm, U., Osseointegration Interface. Present at American Academy of Implant Dentistry, First Annual Symposium, Boston, April 1985.

1 copy

Commander
U.S. Army Medical Research
and Development Command
ATTN: SGRD-RMI-S
Frederick, Maryland 21701-5012

12 copies

Administrator Defense Technical
Information Center
ATTN: DTIC-DDA
Cameron Station
Alexandria, Virginia 22304-6145

1 copy

Commandant
Academy of Health Sciences, U.S. Army
ATTN: AHS-CDM
Fort Sam Houston, Texas 78234-6100

1 copy

Dean
School of Medicine
Uniformed Services University
of the Health Sciences
4301 Jones Bridge Road
Bethesda, Maryland 20814-4799

END

9-87

DTIC