

AD-A139 727

QUANTITATIVE EVALUATION OF HEALING OF SOFT TISSUE  
WOUNDS TREATED EITHER B. (U) ARMY INST OF DENTAL  
RESEARCH WASHINGTON DC P S GROVER ET AL. 1984


1/1

UNCLASSIFIED

F/G 6/5

NL





MICROCOPY RESOLUTION TEST CHART  
NATIONAL BUREAU OF STANDARDS - 1963 - A

AD A139727

12

<b>READ INSTRUCTIONS BEFORE COMPLETING FORM</b>	
ACCESSION NO.	3. RECIPIENT'S CATALOG NUMBER
Quantitative Evaluation of Healing of Soft Tissue Wounds Treated Either by a Carbon Dioxide (CO <sub>2</sub> ) Laser or a Scalpel	5. TYPE OF REPORT & PERIOD COVERED Manuscript for Publication
	6. PERFORMING ORG. REPORT NUMBER
7. AUTHOR(s) Paul S. Grover, Jeffrey O. Hollinger, and Jay D. Shulman	8. CONTRACT OR GRANT NUMBER(s)
9. PERFORMING ORGANIZATION NAME AND ADDRESS U. S. Army Institute of Dental Research Walter Reed Army Medical Center Washington, DC 20012	10. PROGRAM ELEMENT, PROJECT, TASK AREA & WORK UNIT NUMBERS 61102A 3S16102BS10 04 09
11. CONTROLLING OFFICE NAME AND ADDRESS U. S. Army Medical Research & Development Command SGRD-RMS Fort Detrick, Maryland 21701	12. REPORT DATE
	13. NUMBER OF PAGES 12
14. MONITORING AGENCY NAME & ADDRESS (if different from Controlling Office)	15. SECURITY CLASS. (of this report) UNCLASSIFIED
	15a. DECLASSIFICATION/DOWNGRADING SCHEDULE
16. DISTRIBUTION STATEMENT (of this Report) This document has been approved for public release and sale; its distribution is unlimited.	
17. DISTRIBUTION STATEMENT (of the abstract entered in Block 20, if different from Report)	
18. SUPPLEMENTARY NOTES None	
19. KEY WORDS (Continue on reverse side if necessary and identify by block number)	
20. ABSTRACT (Continue on reverse side if necessary and identify by block number) The surgeon's scalpel is the instrument of choice for excisional, incisional, and debridement procedures. The CO <sub>2</sub> laser can be employed for similar purposes; however, additional applications include hemostasis, sterilization, endoscopy, preparation of recipient sites for flaps or grafts, and generation of granulation tissue. Two disadvantages that are associated with the use of the CO <sub>2</sub> laser are an increase in post treatment infection following some types of incisional surgery and a delay in the healing of tissue.	

NOTED  
APR 2 1984  
A

DTIC FILE COPY



## INTRODUCTION

The surgeon's scalpel is the instrument of choice for excisional, incisional, and debridement procedures. The CO<sub>2</sub> laser can be employed for similar purposes; however, additional applications include hemostasis, sterilization, endoscopy, preparation of recipient sites for flaps or grafts, and generation of granulation tissue. Two disadvantages that are associated with the use of the CO<sub>2</sub> laser are an increase in post treatment infection following some types of incisional surgery and a delay in the healing of tissue. The purpose of this study was to quantify some elements of the early phase of soft tissue wound repair. Surgical sites that were assessed had been treated with a CO<sub>2</sub> laser, a scalpel, or had been left untreated. The objective of the evaluation was to quantify inflammatory cells at the wound sites and to determine if there was any significant difference in the healing response.

## METHODS AND MATERIALS

Ketamine (3.5 mg/gm body weight) and Rumpkin (0.5 mg/gm body weight) were administered intramuscularly to 45 adult, random sex, Walter Reed rats. The lateral aspects of the right and left hindquarters were shaved and scrubbed for five minutes with Betadine™. A sterile number 15 scalpel blade was notched 5 mm inferior to the blade's tip to ensure a standard depth of incision. A sterile template guide was placed over the prepared hindquarters of the rat, and two parallel incisions, 5 mm apart and 2.5 cm in length were prepared. The soft tissue delineated by the parallel incisions was crushed

with a sterile, curved Kelly hemostat by using five pinching actions. Following the preparation of the wounds in the 45 animals, they were divided evenly into three treatment groups: laser, knife, and control. Each animal was returned to its individually marked cage and was given food and water *ad libitum*.

After 24 hours, anesthetic was administered to all animals and treatment was rendered according to the following format:

1. Control: Wounds were surgically closed with 000 monofilament sutures.
2. Scalpel: Wounds were debrided with a number 15 scalpel blade and closure was accomplished using 000 monofilament sutures.
3. Laser: Wounds were debrided with a CO<sub>2</sub> laser and closure was accomplished using 000 monofilament sutures.

Following treatment, animals were returned to their individually designated cages and they were given food and water *ad libitum*.

At time intervals of one, five, and fourteen days post-treatment, five animals from each group were euthanatized by administering an overdose of sodium pentathol intraperitoneally. A gross assessment of the wound sites was made at the time of necropsy. The same template that had been used to prepare the standard wounds was oriented over each experimental wound site. A soft tissue dermatome was placed in the center of the template and a standard volume of tissue was excised. Tissue specimens were immediately placed into properly labeled vials of neutral buffered formalin for fixation. This was followed by dehydration in graded alcohols,

parafin embedding, sectioning at six to eight micromillimeters, and hematoxylin and eosin staining. The sections of tissue were evaluated by conventional brightfield microscopy and histomorphometrically using an image analysis system.

The histomorphometric quantitation of the early phase of healing was accomplished by making linear area measurements of zones of primarily acute inflammatory cells (equivalent to irregularly defined polygons). A Zeiss Ph3 Planapo 63/1.4 oil objective and a checkerboard greticule in a 10X ocular were used to define the field to be measured (Fig.1). The field had to occupy at least 60 percent of the greticule if it was to be selected for quantitative measurement. A light emitting diode (LED) in a manual cursor combined with a digitizer tablet and drawing tube were used to outline areas of inflammatory cells that were within the greticule boundaries. The microscopic slides prepared from each rat enabled 100 fields to be evaluated for inflammatory cell areas (for each animal). A meandering pattern of measuring was followed to ensure for complete and accurate slide analysis. There were 4,500 histomorphometric measurements made and stored on a floppy disc. From these measurements, the mean area of inflammatory cells for each animal and then for each group at each temporal level was computed. A one-way, balanced analysis of variance model was used to explore the relationship between surgical technique (scalpel, laser, control) and soft tissue wound healing using the group mean value for each temporal level. Pairwise comparisons between the treatments were made for each of the sacrifice days (1, 5, 14).

The Bonferoni (1) procedure was used with an *a priori* testwise significance level of 0.017 (0.05/3). All data analysis was performed using the GLM procedure of the Statistical Analysis System (2).

## RESULTS

### Gross Evaluation

Control wounds at day one had a slightly more erythematous and puckered appearance than either scalpel or laser groups. At day five, scalpel treated wounds had the crispest looking wound margins. Erythema was more apparent at day five in the laser treated animals than it had been at day one. By the fourteenth day, scalpel-debrided crush wounds seemed to be healing in a normal fashion with margins tightly coapted and no erythema or exudate evident. The control group displayed erythematous zones associated with their wounds; wound margins were bunched up and puckered, and some necrotic tissue was apparent. The laser treated wounds displayed more acceptable juxtaposition of margins than controls; however, erythema and puckering were evident.

### Histologic Evaluation

All treatment groups displayed an abundance of polymorphonuclear leukocytes (PMNL's) at the first day (Fig.2). By day five the scalpel treated wounds displayed an increasing quantity of macrophages and far fewer PMNL's. Control wounds demonstrated ample numbers of PMNL's and some macrophages (Fig.3). There was an abundance of the acute inflammatory cells (PMNL's) still present in the CO<sub>2</sub> laser treated wound sites at five days (Fig.4). By day fourteen, there were macrophages still being observed in the scalpel group, with both fibroblasts and collagen in



greater abundance than at day five. Macrophages were more plentiful at day fourteen than at day five for the laser group; however, PMNL's continued to be numerous. Control wounds still displayed a high level of PMNL's; but more macrophages were observed than at day five.

Typical of all the histologic slides of the laser treated group was the presence of numerous carbon inclusions (Figs.5&6).

#### Histomorphometric Evaluation

Zones of acute inflammatory cells that were measured for all treatment groups were tabulated (Table I). The mean area of inflammatory cells that were derived from 500 measurements per treatment at day one displayed no significant statistical difference between treatment groups (Table II). By day five, the mean area of inflammatory cells for the scalpel group was statistically different from either the control or laser treated groups. Similarly, the laser treated group was statistically different from either the control or scalpel groups. In a quantitative sense, the mean total zones of acute inflammatory cells for the scalpel treated group was less than the control, which was less than the laser treated groups. By day fourteen, the mean total inflammatory zones of the scalpel and laser treated groups were statistically equivalent. However, they were statistically different from the control group. Quantitatively, the scalpel and the control groups were virtually equivalent in terms of the mean total area of inflammatory cells. Both the control and scalpel treated groups had a significant diminution in the mean total area of inflammatory cells. The laser treated group, in contrast, displayed a marked increase in the mean

total area of inflammatory cells from day five to day fourteen. Furthermore, the area of inflammatory cells for the laser treated group at fourteen days greatly exceeded the histomorphometrically derived values for the scalpel or control groups (Table I).

#### DISCUSSION

Hayes (1971) reviewed the healing of cutaneous wounds. He categorized cutaneous healing into six phases, acknowledging that from a clinical perspective, phases often overlapped. The phases are inflammation, epithelialization, vascularization, contraction, collagen synthesis, and late remodeling of scars. It was the purpose of our study to evaluate the effects of two modes of wound therapy by quantitating elements characteristic of the first phase of cutaneous wound repair.

Polymorphonuclear leukocytes predominate in the first few days following injury. Macrophages become abundant usually by the fifth day and predominate at the scene of injury while the reparative sequence is completed. Normal host defense mechanisms to infection from contaminating agents (i.e., bacteria, foreign bodies) are bimodal, and the cellular proliferation of phagocytic PMNL's is part of one of these modes.

Because these phagocytic cells are relatively short-lived (half-life in the circulation is six hours), their presence at a wound site is indicative of a persistent challenge. The PMNL's were most abundant in the laser treated tissue. It was this tissue that also was most retarded in its healing response to injury. This observation concurs with that of others. Hunt and Dunphy (1979) have mentioned that experimental wounds

produced from a laser are about ten times more susceptible to infection than those produced by electrosurgery. Furthermore, Hunt and Dunphy (1979) maintain that the infection potentiating effect of the laser militates against its application for incisional surgical procedures.

Quantitation of the elements of wound repair associated with Hayes' first phase provided unequivocal evidence implicating the laser as an instrument responsible for delaying cutaneous repair. Carbonization of soft tissue produced inflammation inducing inclusions that were additional impediments to normal cutaneous regeneration

A significant contribution provided by this study was the demonstration and use of a quantitative technique employing an Image Analysis System (IAS) to confirm histopathological observations. The benefits provided by such an objective assessment could provide a foundation for further quantitation of wound healing studies.

#### CONCLUSIONS

1. The use of CO<sub>2</sub> laser for debridement of cutaneous crush wounds significantly delays normal healing.
2. An IAS technique has been developed that provides a method for objectively quantitating tissue wound repair.

In conducting the research described in this report, the investigators adhered to the "Guide for the Care and Use of Laboratory Animals" as promulgated by the Committee on the Guide for Laboratory Animal Facilities and Care, of the Institute of Laboratory Animal Resources, National Academy of Sciences, National Research Council.

REQUESTS FOR REPRINTS TO:

LTC Jeffrey O. Hollinger, DC  
Division of Research Sciences  
U. S. Army Institute of Dental Research  
Walter Reed Army Medical Center  
Washington, DC 20307

TABLE I  
HISTOMORPHOMETRIC MEASUREMENTS

DAY	TREATMENT	ONES OF INFLAMMATORY CELLS (MEAN, in mm <sup>2</sup> )*	STANDARD DEVIATION
1	control	26,588	±1189
1	scalpel	27,530	±1231
1	laser	26,678	±1193
5	control	25,813	±1154
5	scalpel	23,305	±1042
5	laser	27,893	±1247
14	control	21,778	±974
14	scalpel	22,138	±990
14	laser	30,175	±1349

\*Mean was Derived from a Total of 500 Measurements (N)

TABLE II

PAIRWISE COMPARISON MATRIX\*

<u>DAY</u>	<u>TREATMENT</u>	<u>COMPARISON</u>		
		<u>Control</u>	<u>Scalpel</u>	<u>Laser</u>
1	Control	-	0.139	0.887
1	Scalpel		-	0.181
1	Laser			-
5	Control	-	0.0001	0.001
5	Scalpel		-	0.0001
5	Laser			-
14	Control	-	0.586	0.0001
14	Scalpel		-	0.0001
14	Laser		0.0001	-

\*Testing Hypothesis That Means Are Equal

## LEGENDS

Figure 1. Schematic of Image Analysis System and the Histologic Field.

Figure 2. Typical histological appearance of a wound at day one. Numerous PMNL's are present. (40X).

Figure 3. The histological appearance of the control wound site at day five still demonstrates numerous PMNL's and some macrophages (100X).

Figure 4. A CO<sub>2</sub> laser treated wound at day five had numerous PMNL's still present. (40X).

Figure 5. The histological sections of the CO<sub>2</sub> laser treated wound sites typically displayed both carbon inclusions and surface carbonization. (40X)

Figure 6. The histological sections of the CO<sub>2</sub> laser treated wound sites typically displayed both carbon inclusions and surface carbonization. (100X).

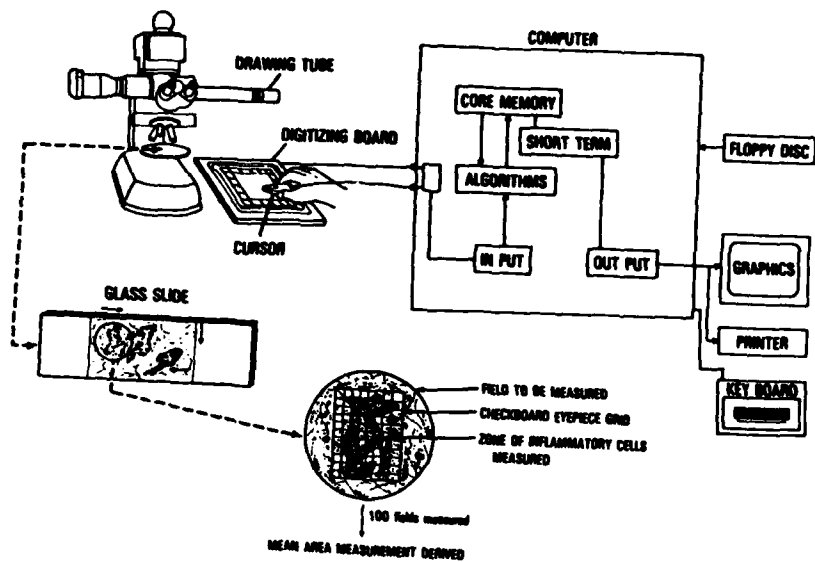


FIGURE 1.





FIGURE 2.

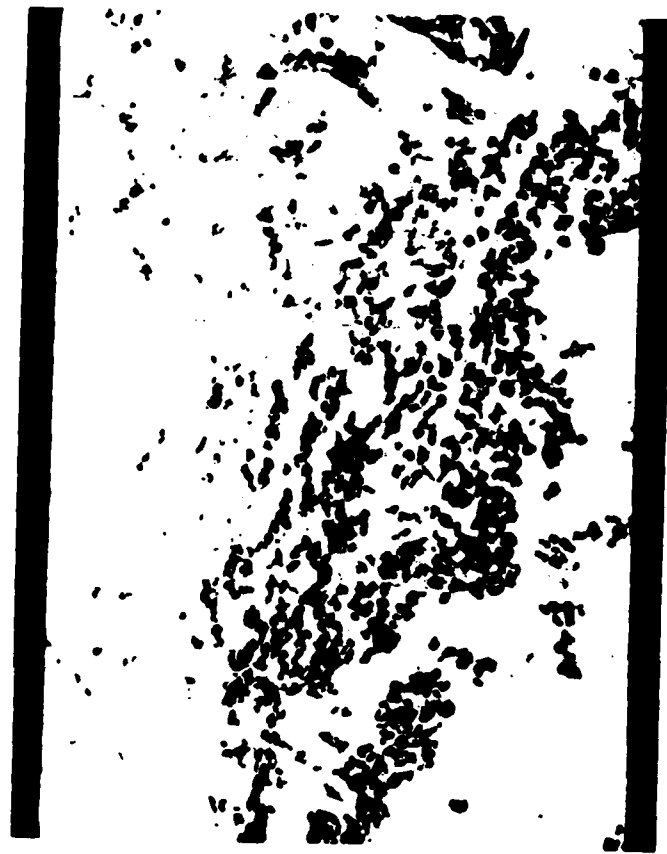

FIGURE 3.




FIGURE 4.



FIGURE 5.



FIGURE 6.

END

FILMED

5-84

DTIC