

AD A 129 457

DTIC  
ELECTE  
S JUN 16 1983 D  
A

Laboratory Animal Science  
Copyright © 1983  
by the American Association for Laboratory Animal Science

## Acute Clinical Malaria (*Plasmodium inui*) in a Cynomolgus Monkey (*Macaca fascicularis*)<sup>1,2,3</sup>

William S Stokes, John C Donovan, Richard D Montrey, William L Thompson, Robert W Wannemacher Jr, and Harry Rozmiarek

**Summary** | Acute clinical malaria caused by *Plasmodium inui* was diagnosed in an adult female cynomolgus monkey (*Macaca fascicularis*) 4 years after importation into the United States. Stress and immunosuppression associated with experimentation completed 2 weeks earlier may have contributed to the development of severe clinical disease. Clinical findings included severe regenerative anemia, hepatosplenomegaly, weakness, lethargy, weight loss, and anorexia. The infection was treated and successfully eliminated with chloroquine hydrochloride administered intramuscularly at a dose of 5 mg/kg base given at 0, 6, 24, 48, and 72 hours. Treatment also included a blood transfusion and intensive supportive care.

**Key Words** | Parasitic diseases — Malaria — *Plasmodium* — *Macaca*

Malaria in man and nonhuman primates is caused by protozoa of the genus *Plasmodium*. Infections result from the introduction of sporozoites into the primate host from the bite of infected mosquitoes. Nonhuman primates imported from endemic malarial regions frequently are found to be infected (1,2). These malarial infections are usually chronic and subclinical in nonhuman primate hosts, and rarely result in clinical disease (1,2) unless the animal is splenectomized, immunosuppressed, or otherwise stressed (3).

Wild-caught cynomolgus monkeys (*Macaca fascicularis*) are commonly infected with malaria, caused by *Plasmodium coatneyi*, *P cynomolgi*, *P fieldi*, *P inui*, or *P knowlesi* (4). The incidence of these natural infections has ranged from 2% to 25% in imported cynomolgus monkeys (5,6). Natural and experimental malarial infections in cynomolgus monkeys generally are subclinical (1,7). Severe malaria resulting from natural infection has been reported only once and was attributed to *P inui* (8). However, severe malaria in cynomolgus monkeys has infrequently resulted from experimentally induced infections with *P inui* (8), *P cynomolgi* (9), and *P knowlesi* (10,11). One experimental case occurred in a splenectomized monkey (11), but the remainder involved cynomolgus

monkeys with intact spleens and uncompromised immune defense mechanisms. The purpose of this report is to describe an additional case of acute clinical malaria in a cynomolgus monkey.

### Case Report

**Clinical history:** A wild-caught, 2.7-kg adult female cynomolgus monkey trapped near Kuala Lumpur, Malaysia, was obtained from a commercial source<sup>4</sup> in December 1976. After importation, the monkey was housed indoors in an individual cage for 4 years with no research utilization or observation of any clinical disease.

In December 1980, the monkey was placed on a 14-day experiment involving surgical implantation of catheters, experimental *Streptococcus pneumoniae* infection, and hyperalimentation treatment. A complete blood count performed prior to the experiment was within normal limits (Table 1). On day zero of the experiment, intravenous catheters were surgically implanted and a specially designed leather jacket fitted to the monkey to protect the catheters (12). On day 8, 5 x 10<sup>6</sup> pneumococcal organisms were administered intravenously, and the infection was untreated for 48 hours. On day 10, 40 ml of blood were drawn for lymphocyte transformation assays and other analytical tests; the volume was replaced with 40 ml of whole blood collected from a clinically normal cynomolgus monkey blood-donor. Also starting on day 10, 150,000 IU each of penicillin G procaine and penicillin G benzathine<sup>5</sup> were administered intramuscularly, and this treatment was given daily for the next 6 days. On day 14, the monkey was removed from the tethered jacket and the catheters surgically removed. The monkey appeared clinically normal at this time and a complete blood count from the previous day reflected only a slightly depressed

<sup>1</sup>From the Animal Resources Division, United States Army Medical Research Institute of Infectious Diseases, Fort Detrick, Frederick, MD 21701.

<sup>2</sup>The views of the authors do not purport to reflect the positions of the Department of the Army or the Department of Defense.

<sup>3</sup>The authors wish to thank William Collins of the Malaria Branch, Parasitic Diseases Division, Center for Disease Control, Atlanta, GA 30333 and CPT Chris Lambrose of the Division of Experimental Therapeutics, Walter Reed Army Institute of Research, Washington, DC 20012 for confirmation of the malaria species involved. The authors also acknowledge the excellent technical assistance provided by D Miller, P Rico, R Wright, and T Tyler.

<sup>4</sup>Charles River Primate Research Corporation, Port Washington, NY.  
<sup>5</sup>Wyeth Bicillin Fortified®, Wyeth Laboratories

83 06 16 027

DTIC FILE COPY

Table 1

Blood values before, during, and after acute clinical malaria in cynomolgus monkey

Parameter	Values by days								
	-18	13	Acute disease			Convalescence			
			29	30	31	32	41	57	73
Hematocrit (%)	38.4	32.0	15.1	12.0	9.7	29.4	30.4	34.2	42.1
Hemoglobin (g/dl)	13.4	9.8	4.4	ND <sup>a</sup>	3.2	8.3	9.1	10.6	11.8
Erythrocytes (x 10 <sup>6</sup> /mm <sup>3</sup> )	5.69	5.04	2.2	1.8	1.52	3.86	4.41	5.29	6.65
Leukocytes (x 10 <sup>3</sup> /mm <sup>3</sup> )	9.9	5.8	14.6	13.4	11.9	4.1	3.4	4.7	8.2
Band neutrophils (%)	-	-	4	8	3	-	-	-	-
Segmented neutrophils (%)	27	39	51	34	40	52	22	27	54
Lymphocytes (%)	69	61	41	53	46	46	61	56	36
Monocytes (%)	2	-	3	-	2	2	14	13	8
Eosinophils (%)	2	-	-	-	-	-	2	4	2
Basophils (%)	-	-	1	-	-	-	-	-	-
Nucleated erythrocyte/100 leukocytes	-	-	1	1	3	-	-	-	-
Reticulocytes (%)	ND	ND	ND	ND	10.0	ND	5.2	2.1	ND
Mean corpuscular volume (μ <sup>3</sup> )	66	64	67	65	64	75	69	64	62
Mean corpuscular hemoglobin conc'n (%)	34.9	30.6	29.1	ND	33.0	28.2	29.9	31.0	28.0
Mean corpuscular hemoglobin (pg)	23.5	19.4	20.0	ND	21.1	21.5	20.6	20.0	17.7
Serum total protein (mg/dl)	ND	7.6	6.8	6.4	5.0	6.9	7.4	7.8	ND
Chloroquine treatment			+	+	+				

<sup>a</sup>ND = Not done

hematocrit (Table 1). On day 22, mild anorexia was observed, which gradually progressed in severity during the next 7 days. On day 29, the monkey was lethargic and completely anorectic.

**Physical findings:** Examination on day 29 revealed pale mucous membranes, emaciated body condition, palpable hepatosplenomegaly, weakness, slight pyrexia of 39.2°C, and increased respiratory and heart rates. A grade III/VI holosystolic ejection murmur near the base of the right heart also was detected. Blood samples were drawn for a complete blood count and selected serum chemistries.

**Laboratory findings:** Hematologic results on day 29 revealed severe regenerative anemia with depressed hematocrit, hemoglobin, and erythrocyte count<sup>6</sup> (Table 1). Severe anisocytosis, marked polychromasia, nucleated erythrocytes, and neutrophilic leukocytosis were observed. Eight percent of the erythrocytes were infected with malarial parasites at a concentration of 1.8 x 10<sup>6</sup> parasites/dl blood. All stages of developing trophozoites and schizonts were present in the erythrocytes (Figure 1). Doubly and triply infected erythrocytes were observed, as well as monocytes containing malarial pigment. The malaria was identified as *P inui* based upon morphologic characteristics. Blood urea nitrogen, serum creatinine, and serum electrolytes were within normal limits. Serum total protein was low normal at 6.8 g/dl.

**Treatment:** Antimalarial therapy was begun immediately using chloroquine hydrochloride<sup>7</sup> at a dose of 5 mg/kg chloroquine base administered intramuscularly. This dose was repeated at 6, 24, 48, and 72 hours after the initial treatment for a total dose of 25 mg/kg. Antibiotic therapy to prevent secondary infections was instituted

using 150,000 IU each of penicillin G procaine and penicillin G benzathine intramuscularly and repeated daily for the next 10 days. Supportive therapy included the administration of parenteral B-vitamin complex,<sup>8</sup> *ad libitum* oral nutrient-electrolyte solution,<sup>9</sup> and subcutaneous electrolyte fluids.<sup>10</sup>

**Clinical course:** Twenty-four hours after treatment was started, the anemia worsened (Table 1). The animal was noticeably weaker, and the body temperature decreased to 37.2°C. Antimalarial and supportive therapies were continued with the addition of supplemental oral feedings of nutrient-electrolyte solution by nasogastric tube.

Forty-eight hours after treatment began, the monkey was weak, the body temperature decreased to 36.3°C, and the anemia worsened (Table 1). Serum chemistry values showed hypoalbuminemia (2.2 g/dl), hypoproteinemia (5.0 g/dl), and increased total bilirubin (0.6 mg/dl), serum aspartate aminotransferase (55 U/liter), serum alanine aminotransferase (84 U/liter), and serum alkaline phosphatase (573 U/liter). A blood transfusion was administered using 75 ml of whole blood collected in acid citrate dextrose solution<sup>11</sup> from a cynomolgus monkey. Improvement was evident the next day. By day 35, the monkey appeared clinically normal. The heart murmur decreased in intensity following the blood transfusion and was absent 1 week after originally detected. No malarial parasites were observed on thin blood smears after completion of the 3-day chloroquine therapy, and hematologic parameters gradually returned to normal over the next 6 weeks (Table 1).

**Follow-up:** Thick and thin blood smears were examined monthly over the next 5 months and were all found to be negative for malarial parasites. Six months after the clinical disease, the monkey was immunosuppressed to determine if a chronic latent malarial infection might still persist. The immunosuppressive regimen consisted of 4.4 mg/kg of prednisolone acetate<sup>12</sup> given daily for 3 weeks by intramuscular injection. No parasites were

<sup>6</sup>Coulter Counter<sup>®</sup> Model ZBI. Coulter Electronics, Hialeah, FL.

<sup>7</sup>Aralen<sup>®</sup> Hydrochloride. Winthrop Laboratories, New York, NY.

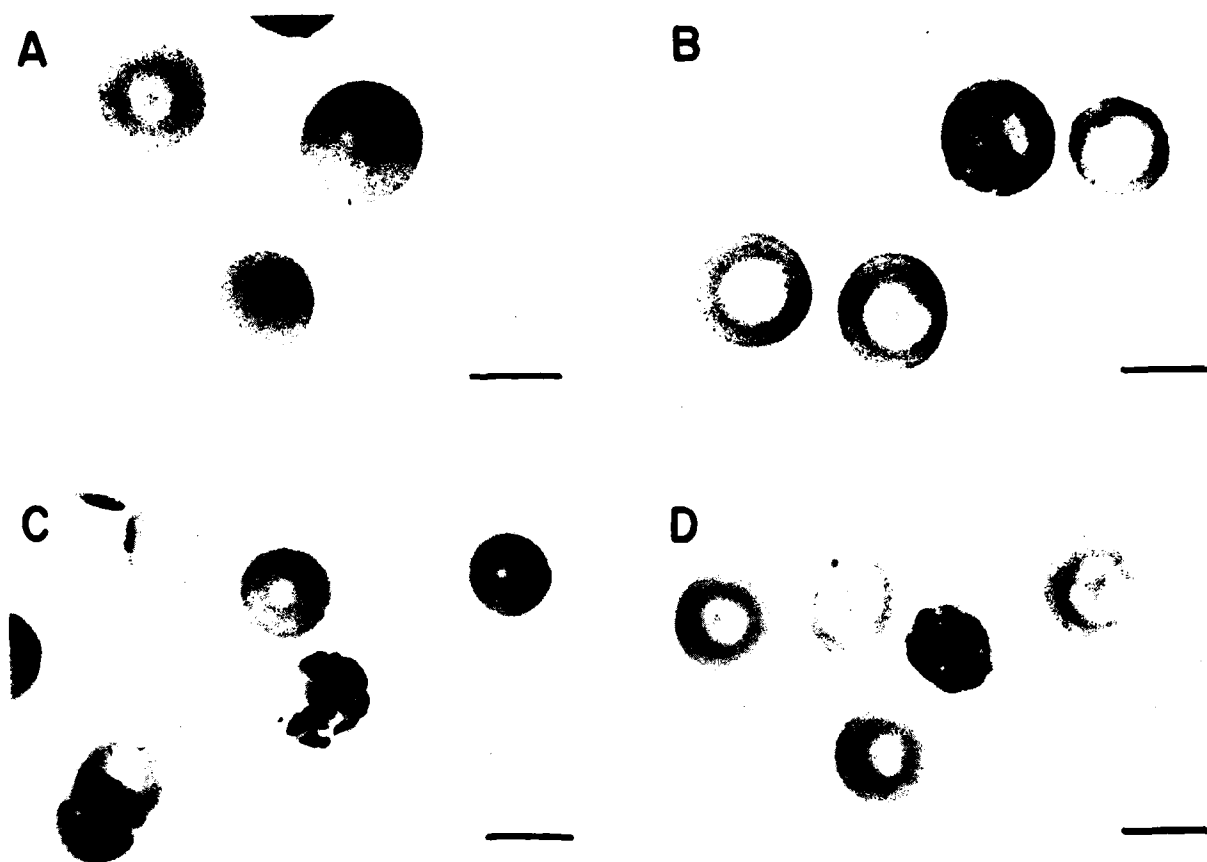
<sup>8</sup>Solu-B-Forte<sup>®</sup> (S-B-F<sup>®</sup>). The Upjohn Company, Kalamazoo, MI.

<sup>9</sup>Life-Guard<sup>®</sup>. Norden Laboratories, Lincoln, NE.

<sup>10</sup>Lactated Ringers Injection, USP. Cutter Laboratories, Berkeley, CA.

<sup>11</sup>ACD. A J Buck and Sons, Cockeysville, MD.

<sup>12</sup>Sterile Prednisolone Acetate USP D-M Pharmaceuticals, Rockville, MD.



**Figure 1**  
Various stages of *Plasmodium inui* in erythrocytes from case of acute malaria in cynomolgus monkey. A: Ring forms of early trophozoites; B: Trophozoite; C: Developing schizont; D: Mature schizont. Wright stain. Line = 6  $\mu$ m.

observed in thin or thick blood smears examined during this regimen or during a 6-month follow-up period.

A review was made of the lymphocyte transformation assay data performed on day 10 of the pneumococcal infection experiment. The responses of peripheral blood lymphocytes in whole blood cultures to mitogen stimulation with concanavalin A, phytohemagglutinin, and pokeweed mitogens were measured by standard micro-culture technique (13). Stimulation indexes for each of these mitogens were used to assess cell-mediated immune functions (13). Values for the monkey described in this case report as well as five other similarly treated monkeys were compared to those for six noninfected control monkeys (Table 2). The six monkeys with the acute pneumococcal infection were shown to have much lower lymphocyte stimulation indexes than the six noninfected control monkeys (Table 2).

The two cynomolgus monkeys used as blood donors, one during the pneumococcal experiment and a second during the acute malaria, were re-examined for malaria 3 months later. No malarial parasites had been detected on several complete blood count examinations on

**Table 2**

Effect of experimental *Streptococcus pneumoniae* infection in cynomolgus monkeys during hyperalimentation studies: Lymphocyte transformation mitogen stimulation indexes<sup>a,b</sup> from whole blood cultures

Mitogen	Mean stimulation index	
	Controls (n = 6 monkeys)	Infected (% of controls) (n = 6 monkeys)
Pokeweed mitogen (PWM)	30.74	4.28 (13.9)
Phytohemagglutinin (PHA)	15.34	5.62 (36.5)
Concanavalin A (ConA)	5.06	1.95 (38.5)

<sup>a</sup>Stimulation index =  $\frac{\text{dpm in mitogen-stimulated lymphocytes}}{\text{dpm in nonstimulated lymphocytes}}$

<sup>b</sup>Cultured with 4  $\mu$ g/ml PWM, 4  $\mu$ g/ml PHA, or 10  $\mu$ g/ml ConA

either monkey during the previous 2 years. The first donor, a wild-caught male imported from Malaysia, was found on thick blood smears to have low-level parasitemia of 600 malarial parasites/dl. The monkey used as the blood donor for the second transfusion was negative for hemoparasites on both thin and thick smear examination.

It was later found that a matched control monkey from the pneumococcal experiment also had

received a 40-ml blood transfusion from the first (infected) donor monkey. This control monkey was subjected on the same dates to the same experiment as the case described here, except that it was not infected with *S pneumoniae*. This control monkey did not develop any clinical signs or abnormal complete blood count parameters during or after the experiment, and no malarial parasites were observed on several complete blood count examinations during the 6 months following the experiment.

### Discussion

Most *Plasmodium* sp infections in cynomolgus monkeys have been described as chronic and asymptomatic (1,2), with acute clinical malaria only rarely reported. The reasons for development of acute clinical malaria in the few cases previously reported have not been clearly explained. Two reports suggest that some degree of stress or other immunosuppression contributed to the development of clinical disease (8,11). One description (8) of fatal disease attributed to a naturally acquired infection of *P inui* was observed shortly after shipment, and the stress associated with shipment may have been a contributing factor to development of symptomatic infection. The second report (11) described a case of acute fatal malaria that resulted from an induced infection following splenectomy. The lack of a spleen and its associated protective functions (14) undoubtedly contributed to the severe disease that developed.

Stress and immunosuppression associated with experimentation appeared to contribute to the clinical malaria described in this case report. The stress may have resulted from the experiment that involved two surgical procedures, 2 weeks in a tethered jacketing system, and an experimentally induced acute pneumococcal infection. Immunosuppression during the acute pneumococcal infection was demonstrated for the monkey described here as well as five other similarly treated monkeys when compared to six noninfected controls. The depressed immune functions may have allowed a rapid expansion of a low-level parasitemia, with the subsequent development of clinical malaria.

The source of the malaria infection causing the clinical disease in our case may have been from either a chronic pre-existing infection or from the blood transfusion received during the experiment. Since the monkey in this case was wild-caught, a chronic infection could have persisted that was originally acquired in the Malaysian jungle prior to importation 4 years previously. Chronic asymptomatic persistence for 4 years would not be considered unusual, as naturally occurring quartan malarial infections such as *P inui* persist as low-level parasitemias for long periods (4). Cynomolgus monkeys housed in our colony for over 7 years have been found with chronic *P inui* infections; furthermore, induced *P inui* infections have been reported to persist in rhesus monkeys for up to 14 years (15). *Plasmodium inui*, the species identified in this case, is the most widely distributed and most common malaria species found in cynomolgus monkeys and has been isolated from all areas of their natural habitat (11).

The infection in this case also may have originated from or been enhanced by the blood transfusion received on day 10 of the experiment. The donor monkey was later found to have a chronic malarial infection. However, the matched control monkey that also received an identical blood transfusion from the donor monkey on the same day did not develop clinical disease or abnormal blood parameters. Several possibilities exist to explain the absence of disease or detectable parasitemia in the control monkey. First, certain immune defense mechanisms of the control monkey were not suppressed as was shown for the pneumococcal-infected monkey. Therefore, any parasites introduced into the control monkey subsequently may have been eliminated because of a non-compromised immune system. Secondly, the control monkey may have had a protective level of antimalarial antibodies from a previous infection which allowed for rapid clearance of any new parasites. Lastly, the control monkey may have had an undetectable pre-existing malarial infection which allowed for effective protection by premunition.

Intraspecies variation in susceptibility to malaria may have been a factor in the development of clinical disease in this case. Susceptibility differences to malaria have been reported in cynomolgus monkeys depending on their geographic origin (10). Experimental *P knowlesi* infections caused uniformly fatal disease in cynomolgus monkeys of Malayan origin, but only mild chronic infections in cynomolgus monkeys of Phillipine origin. However, this variation in intraspecies susceptibility does not account for the fact that Malayan monkeys often harbor asymptomatic *P knowlesi* infections. It is not known if such an intraspecies variation in susceptibility to *P inui* exists.

The clinical signs observed in this case were similar to those observed in other nonhuman primates with acute severe malaria resulting from natural or experimental *Plasmodium* infections (1,10,16). The severe anemia accounted for most of the clinical signs including the transient heart murmur. The hepatosplenomegaly observed is a common feature of acute and chronic malaria.

Chloroquine hydrochloride was used as the antimalarial drug because of its wide acceptance as a standard blood schizonticidal drug for treatment of acute and chronic human malaria. No previous reports of treatment of acute malaria in cynomolgus monkeys exists; therefore, a dosage was extrapolated from the manufacturer's human pediatric recommendations (17). The total dose of 25 mg/kg chloroquine base divided into five doses over 3 days was successful in completely eliminating the infection, as determined by repeated negative blood smears. No adverse effects attributable to the drug were observed. The efficacy of this therapeutic regimen was further supported by negative thick blood smears following the immunosuppressive corticosteroid regimen administered after full recovery. Such immunosuppression has been shown to cause reactivation of latent malarial infections not detectable on thick blood smear examination (11).

Treatment of any malaria should consist of a blood schizonticidal drug such as chloroquine hydrochloride to eliminate the parasitemia. In the case of *P cynomolgi* and *P fieldi* infections, this treatment should also include a tissue schizonticidal drug such as primaquine to eliminate the persistent tissue schizonts. To insure elimination of all malarial species in a potentially infected animal, treatment should include both blood and tissue schizonticidal drugs. Follow-up examinations should then be performed on all animals to insure that parasitemias have been cleared.

**References**

1. Ruch TC. *Diseases of Laboratory Primates*. Philadelphia: WB Saunders, 1959; 312-51.
2. Voller A. Plasmodium and hepatocystis. In: T-W. Fiennes RN, ed. *Pathology of Simian Primates*, Part II. Basel: S Karger, 1972; 57-73.
3. Loeb WF, Bannerman RM, Rininger BF, et al. Hematologic disorders. In: Benirschke K, Garner FM, Jones TC, eds. *Pathology of Laboratory Animals*, Vol I. New York: Springer-Verlag, 1978; 890-1050.
4. Coatney GR, Collins WE, Warren MW, et al. *The Primate Malariae*. Washington: US Government Printing Office, 1971.
5. Otsuru M, Sekikawa H. Surveys of simian malaria in Japan. *Zbl Bakt Hyg, Orig A* 1979; 244:245-50.
6. Schmidt LH, Cramer DV, Rossan RN, et al. The characteristics of *Plasmodium cynomolgi* infections in various Old World primates. *Am J Trop Med Hyg* 1977; 26:356-72.

7. Flynn RJ. *Parasites of Laboratory Animals*. Ames: Iowa State University Press, 1973; 67-113.
8. Leger M, Bouilliez M. Recherches expérimentales sur "Plasmodium inui" Halberstädter et Prowazek d'un "Macacus cynomolgus." *Ann Inst Pasteur* 1913; 27:955-85.
9. Blanchard R, Langeron M. Le paludisme des macaques (*Plasmodium cynomolgi*, Mayer 1907). *Arch Parasitol (Paris)* 1913; 15:529-42.
10. Schmidt LH, Fradkin R, Harrison J, et al. Differences in the virulence of *Plasmodium knowlesi* for *Macaca irus (fascicularis)* of Phillipine and Malayan origins. *Am J Trop Med Hyg* 1977; 26:612-22.
11. Garnham PCC. *Malaria Parasites and other Haemosporidia*. Oxford: Blackwell Scientific Publications, 1966.
12. Bryant JM. Vest and tethering system to accommodate catheters and a temperature monitor for nonhuman primates. *Lab Anim Sci* 1980; 30:706-08.
13. Oppenheim JJ, Schechter B. Lymphocyte transformation. In: Friedman H, Rose NR, eds. *Manual of Clinical Immunology*. Washington: American Society for Microbiology, 1976; 81-94.
14. Wyler DJ, Miller LH, Schmidt LH. Spleen function in quartan malaria (due to *Plasmodium inui*): Evidence for both protective and suppressive roles in host defense. *J Infect Dis* 1977; 135:86-93.
15. Schmidt LH, Fradkin R, Harrison J, et al. The course of untreated *Plasmodium inui* infections in the rhesus monkey (*Macaca mulatta*). *Am J Trop Med Hyg* 1980; 29:158-69.
16. Ayala SC. Clinical malaria in a pet capuchin monkey. *Vet Med Sm Anim Clin* 1978; 73:217-18.
17. Winthrop Laboratories. ARALEN® Hydrochloride. In: *Physicians Desk Reference*, 34th ed. Oradell, NJ: Medical Economics Co, 1980; 1834.

Accession For

GRA&I  
 TAB  
 Unannounced  
 Classification \_\_\_\_\_  
 Distribution \_\_\_\_\_  
 Availability Group \_\_\_\_\_  
 Avail. and/or Special \_\_\_\_\_

A 21

