

AD-A114 974


ALABAMA UNIV IN BIRMINGHAM
RESPONSE OF COMBINED ELECTRICAL STIMULATION AND APPLIED LABORAT--ETC(1)
MAR 81 J E LEMONS

F/G 6/5

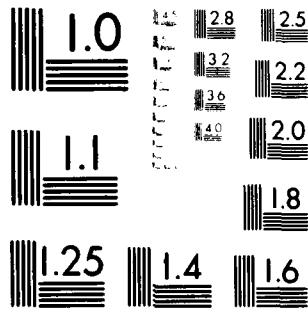
DAMD17-75-C-5044

NL

UNCLASSIFIED



END
DATE
FILMED
6 82
DTIC



MICROCOPY RESOLUTION TEST CHART
NATIONAL BUREAU OF STANDARDS-1963-A

12

Report Number 5

RESPONSE OF COMBINED ELECTRICAL STIMULATION AND APPLIED LABORATORY
AND CLINICAL STUDIES ON BIODEGRADABLE CERAMIC

Annual Report

J. E. Lemons

March, 1981

Supported by
U. S. ARMY MEDICAL RESEARCH AND DEVELOPMENT COMMAND

Contracts
DAMD17-75-C-5044 and DAMD17-79-C-9173

University of Alabama in Birmingham
Birmingham, Alabama 35294

Approved for public release: distribution unlimited.

The findings in this report are not to be construed
as an official Department of the Army position unless
so designated by other authorized documents.

DTIC
ELECTE
S MAY 26 1982
A

AD A114974

DTIC FILE COPY

82 05 0 0 0

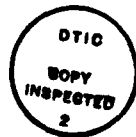REPORT DOCUMENTATION PAGE		READ INSTRUCTIONS BEFORE COMPLETING FORM
1. REPORT NUMBER	2. GOVT ACCESSION NO. AD-A114974	3. RECIPIENT'S CATALOG NUMBER
4. TITLE (and Subtitle) Response of Combined Electrical Stimulation and Applied Laboratory and Clinical Studies on Biodegradable Ceramic		5. TYPE OF REPORT & PERIOD COVERED Annual Report July, 1979 to November, 1980
		6. PERFORMING ORG. REPORT NUMBER
7. AUTHOR(s) Jack E. Lemons, Ph.D.		8. CONTRACT OR GRANT NUMBER(s) DAMD17-75-C-5044 DAMD17-79-C-9173
9. PERFORMING ORGANIZATION NAME AND ADDRESS University of Alabama in Birmingham University Station Birmingham, Alabama 35294		10. PROGRAM ELEMENT, PROJECT, TASK AREA & WORK UNIT NUMBERS 62775A 3S162775A825.00.048
11. CONTROLLING OFFICE NAME AND ADDRESS US Army Medical Research and Development Command Fort Detrick, Frederick, Maryland 21707		12. REPORT DATE March, 1981
		13. NUMBER OF PAGES 20
14. MONITORING AGENCY NAME & ADDRESS (if different from Controlling Office)		15. SECURITY CLASS. (of this report) Unclassified
		15a. DECLASSIFICATION/DOWNGRADING SCHEDULE
16. DISTRIBUTION STATEMENT (of this Report) Approved for public release; distribution unlimited.		
17. DISTRIBUTION STATEMENT (of the abstract entered in Block 20, if different from Report)		
18. SUPPLEMENTARY NOTES		
19. KEY WORDS (Continue on reverse side if necessary and identify by block number) Tricalcium phosphate Biodegradable ceramic Chronic implants Animal model Biomaterials Granular Tricalcium Phosphate Surgical implants		
20. ABSTRACT (Continue on reverse side if necessary and identify by block number) Investigations on granular (1, 2 or 3 mm average size) and rod (1 cm diameter x 1 cm length) form porous tricalcium phosphate ceramic has shown good biocompatibility in rabbit and dog animal models. The granular form was mixed with equal weights of autogeneous bone and 8 mm tibial lesions in rabbits evaluated at 3, 6 and 9 months post surgery. Twenty three of twenty five comparable sites healed and showed no specific correlation with ceramic particulate size. Rod form ceramic implants in the mid		

Form DD 1473 continued:

Block 20 continued:

position of dog radii showed continued biodegradation at healed and nonunion sites. Initial human clinical investigations for the granular form ceramic with autogeneous bone should initiate in 1981.

Accession For	
NTIS GRA&I	<input checked="" type="checkbox"/>
DTIC TAB	<input type="checkbox"/>
Unannounced	<input type="checkbox"/>
Justification	
By _____	
Distribution/	
Availability Codes	
Avail and/or	
Dist	Special
A	



Report Number 5

RESPONSE OF COMBINED ELECTRICAL STIMULATION AND APPLIED LABORATORY
AND CLINICAL STUDIES ON BIODEGRADABLE CERAMIC

Annual Report

J. E. Lemons

March, 1981

Supported by
U. S. ARMY MEDICAL RESEARCH AND DEVELOPMENT COMMAND

Contracts
DAMD17-75-C-5044 and DAMD17-79-C-9173

University of Alabama in Birmingham
Birmingham, Alabama 35294

Approved for public release: distribution unlimited.

The findings in this report are not to be construed
as an official Department of the Army position unless
so designated by other authorized documents.

SUMMARY

This report summarizes the past years investigations on granular (1, 2 or 3 mm average dimension) and rod (1 cm diameter by 1 cm length) form porous tricalcium phosphate ceramic implants in rabbits and dogs.

The granular form was mixed with equal weights of autogeneous bone and implanted in 8 mm length surgically created defects in rabbit tibiae. The sites were evaluated at 3, 6 and 9 months and showed good biocompatibility for the ceramic and clinical unions for 23 of 25 intercomparable lesion sites.

The clinical status for the dog radii implants shows continued biodegradation of the rod form ceramic for two dogs at 3.5 years and for three dogs at 2 years. Three dogs with nonunions showed biodegradation of the rod form implants and now have replacement implants with autogeneous bone at the same lesion sites.

Initial protocols for human clinical studies on the granular form porous tricalcium phosphate ceramic have been submitted and the investigations should start in 1981.

FOREWORD

In conducting the research described in this report, the investigator adhered to the "Guide for Laboratory Animal Facilities and Care", as promulgated by the Committee on the Guide for Laboratory Animal Resources, National Academy of Sciences - National Research Council.

TABLE OF CONTENTS

	<u>Page</u>
<u>Summary</u>	2
<u>Foreward</u>	3
<u>Introduction</u>	6
<u>Materials and Methods</u>	6
Materials and Implant Fabrication	
Animal Models - Surgical Techniques	
Animal Models - Follow Up	
Necropsy and Specimen Evaluations	
<u>Results and Discussion</u>	7
Materials and Implant Fabrication	
Surgical Techniques	
Necropsy and Specimen Evaluations	
Human Clinical Trial Protocols	
<u>Conculusions</u>	19
<u>References</u>	20

TABLES

	Page
Table I. Summary of One, Two and Three Millimeter Tricalcium Phosphate Ceramic and Autogeneous Bone Rabbit Tibial Implant Series.....	12
Table II. Rod Form Dog Radius Porous Tricalcium Phosphate Implant Summary Information.....	16

FIGURES

Figure 1. Schematic Drawing of Segmental Lesion in a Rabbit Tibia Showing the Relative Placement Positions of the Stabilization Pins.....	8
Figure 2. Schematic Drawing of the Segmental Bone Replacement and Bone Stabilization Plate for the Dog Studies	9
Figure 3. One, Two, Three Millimeter Average Diameter and Rod Form Porous Tricalcium Phosphate Ceramic Implants	11
Figure 4. Radiographs of Rabbit R401 Showing One Millimeter Granular Ceramic When Bridged (Upper) and at Euthanization (Lower)	13
Figure 5. Radiographs of Rabbit 398 Showing Two Millimeter Granular Ceramic Post Surgical (Upper) and at Euthanization (Lower).....	14
Figure 6. Radiographs of Rabbit 405 Showing Three Millimeter Granular Ceramic Post Surgical (Upper) and at Euthanization (Lower)	15
Figure 7. Radiographs of Dog 229 Showing Rod Form Implant (Upper) and the Long Term Follow Up (Lower).....	17
Figure 8. Radiographs of Dog 2730 Showing Delayed Union (Upper) and Replacement Rod Form Ceramic (Lower).....	18

INTRODUCTION

This report summarizes the results from the 1979-1980 programs titled "Response of Combined Electrical Stimulation and Biodegradable Ceramics", contract number DAMD17-75-C-5044 and "Applied Laboratory and Clinical Studies on Biodegradable Ceramic", contract number DAMD17-79-C-9173. The contract DAMD17-75-C-5044 is currently the long term investigations on the rod form porous tricalcium phosphate implants in dogs while contract DAMD17-79-C-9173 includes the rabbit implant series and the initial protocol for the human clinical studies. These programs have been combined in this report.

A significant amount of interest continues in the apatite and modified apatite - like ceramic biomaterials for applications in surgical repairs of bone¹⁻¹⁴. The biodegradable ceramic substances are being considered for a number of clinical applications, as evidenced by recent publications.

Although new procedures and various types of replacement biomaterials continue to expand for major lesions of bone the basic methods of treatment continue to require reduction, mechanical stabilization, and autogeneous bone graft. To obtain a bone graft in many cases requires a second surgical procedure with the added possibilities of complications. The overall objective of the current program is to fully investigate one synthetic bone substitute material in an attempt to significantly improve the conditions for surgical correction of bone lesions. The military applications are extensive when considering the possibility of major reductions in maxillofacial and orthopaedic surgical time, deformities and morbidity.

The technical objectives of the programs summarized in this report were as follows:

1. To compare granular forms of porous tricalcium phosphate ceramic, with average particulate dimensions of 1, 2 and 3 millimeters, for use as a mixture with 50 weight percent autogeneous bone in the rabbit animal model;
2. To continue the long term evaluations of mid-radius rod form porous tricalcium phosphate ceramic implants in the dog animal model; and
3. To develop clinical study protocols for limited human patient applications of the granular form porous tricalcium phosphate ceramic with autogeneous bone in Maxillofacial and Orthopaedic Surgery.

MATERIALS AND METHODS

Materials and Implant Fabrication

The porous tricalcium phosphate ceramic was the material received previously from Battelle Memorial Institute Columbus Laboratories. The material specifications were given in the previous annual report*. The same starting material has been used

* Contract No. DAMD17-75-C-5044, (1979)

throughout this program. The last group of ceramic pieces have been reduced to make the granular and rod form implants. A diamond sectioning disc and simple hand reduction was used to make the various implant sizes. The 1, 2 and 3 mm particles were size - fractioned with standard ASTM mesh sieves. The surfaces of the rod form implants were removed to provide an open porosity at all locations. The various forms were dry heat sterilized by placing the specimens in Pyrex glass tubes and exposing at 300 to 350 C for 0.5 to 2 hours in a muffle furnace.

Animal Models - Surgical Techniques

The segmental surgically created lesion and the stabilization pin arrangement for the rabbit tibia implant series are shown schematically in Figure 1. This procedure has been described in detail in previous reports. The mixtures of the 1, 2 or 3 mm porous tricalcium phosphate ceramic and the autogeneous bone from the iliac crest were placed within the 8 mm length defect. The periosteum was retained for all of these lesions. The relative quantity of ceramic and bone was determined on the surgery table using a stainless steel beam balance. The weight ratios included 0.5 gm bone and 0.5 gm ceramic.

The surgical procedures for the dog implants only included the follow up required where the lesion had not healed and the location where the implant was originally implanted was corrected. The detailed surgical techniques for the dogs have been previously described. For replacement procedures the central radius lesion region was resectioned for histology and a new 1 cm length by 1 cm diameter rod form implant inserted with iliac crest autogeneous bone. The original bone plate stabilization system was retained. The dog radius implant site and bone plate location are shown schematically in Figure 2.

Animal Models - Follow Up

The rabbit and dog clinical follow up methods were similar to those employed during the preceding studies. This includes general observation, routine radiographs, local implant site examinations, and selective corrective medications or procedures where indicated.

Necropsy and Specimen Evaluations

The schedule of rabbit experiments included nine to twelve for each size fraction of ceramic with the rabbits euthanized by standard methods at 3, 6 and 9 months post surgery. After euthanization by drug overdose, the rabbit tibiae were dissected free of soft tissues and the central lesion site removed for standard histological and nondecalcified thin section analyses.

The tissue specimens removed from the dog radii were submitted to standard histological examinations.

RESULTS AND DISCUSSION

Materials and Implant Fabrication

No problems were encountered in handling the porous tricalcium phosphate synthetic biomaterial. The implant forms were easily produced using standard

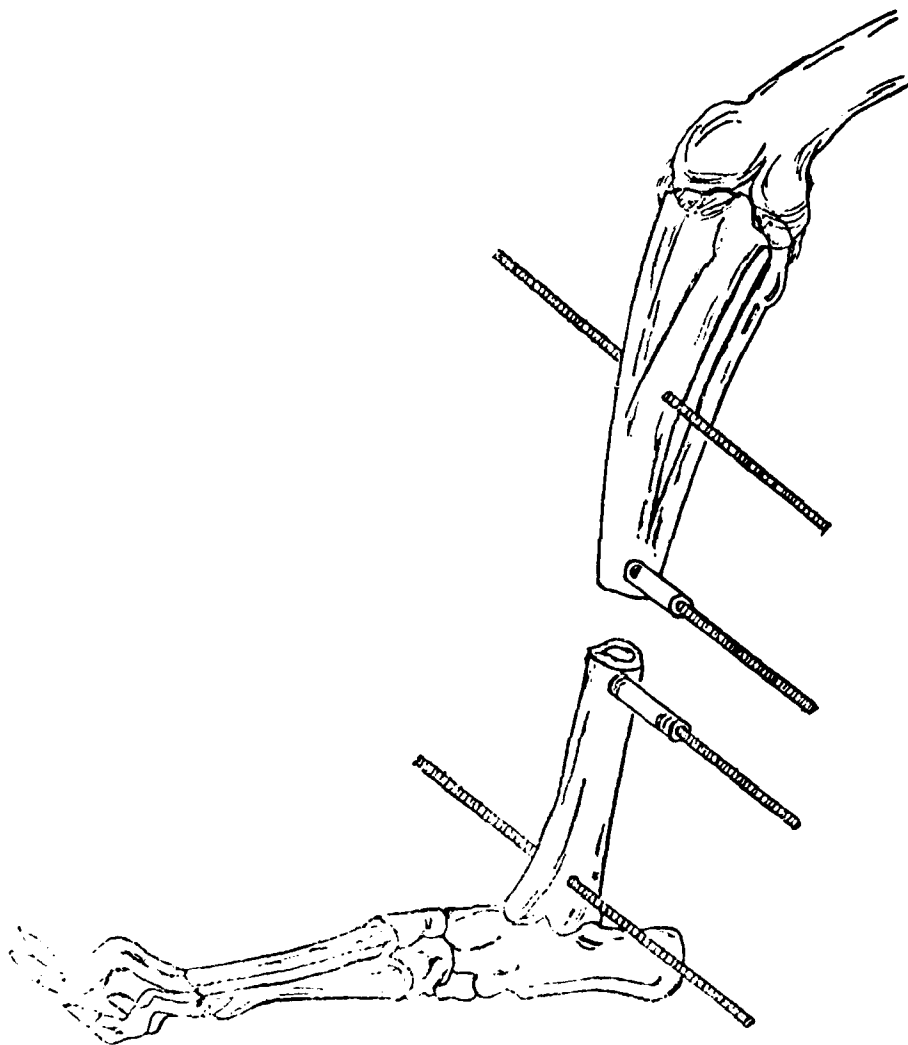


Figure 1. Schematic Drawing of Segmental Lesion in a Rabbit Tibia Showing the Relative Placement Positions of the Stabilization Pins

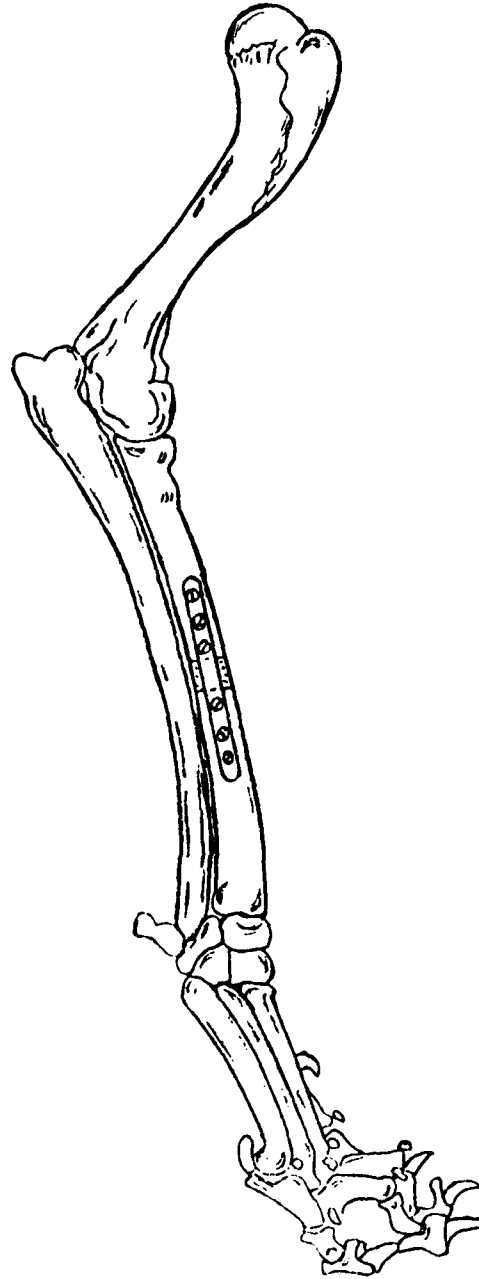


Figure 2. Schematic Drawing of the Segmental Bone Replacement and Bone Stabilization Plate for the Dog Studies

laboratory instruments. The various forms of the ceramic implants are shown in Figure 3.

Surgical Techniques

The surgical procedures were relatively uneventful with no special problems. The surgical team included either an Oral and Maxillofacial or Orthopaedic Surgeon, a Veterinarian, and one or two surgical assistants as required.

Necropsy and Specimen Evaluations

The rabbit number, experimental group, time of implantation, and clinical observations for the 1, 2 or 3 mm ceramic and autogeneous bone implant series are summarized in Table 1. The continuing problem with caged rabbits and surgical studies is evident in the number of animals lost during the experimental series. However, most of the rabbits healed the lesion site and no specific or unusual problems were encountered.

Radiographic and gross dissection examinations of the 6 and 9 months lesions showed no evidence or retained porous tricalcium phosphate ceramic granules for a number of rabbits. The lesion sites were quite normal and no problems with the biocompatibility of the granular ceramic was found. Considering the thirty rabbits those that showed complete healing of the lesion included in this series at each time period were as follows: four of nine at 3 months, nine of the nine at 6 months and ten of twelve at 9 months. Five of the thirty animals were lost to the study because of early death from unknown causes or complications related to pin - tract infections. Twenty three of the remaining twenty five healed the lesion although three died prior to the scheduled euthanization period.

Examples of radiographs from 1, 2 and 3 mm granular ceramic lesion for rabbits in the 9 month group are shown in Figures 4, 5 and 6 respectively. The sites show examples of acceptable bridging of the lesions.

The identification number, time of original implantation of the rod form ceramic, and the clinical status of the eight dogs with radius implants are summarized in Table 2. Two of the dogs now have implantation times of 3.5 years. The remaining dogs are approaching two years. Three of the two year animals did not require additional surgical procedures, while the other three developed nonunions. These three nonunions were allowed to continue until the fate of the porous ceramic rod implant was determined. With biodegradation of the original rod form ceramic implant, additional surgical procedures were initiated. The nonunion site was removed by sharp dissection, a new 1 cm long by 1 cm diameter rod form porous tricalcium phosphate ceramic inserted and the site was packed with iliac crest autogeneous bone before surgical closure.

Examples of a radiograph from a long term (3 year) radius site and a nonunion and replacement site are shown in Figures 7 and 8 respectively.

In general, the dog study is progressing without major complications and the question about the eventual fate of long term rod form porous tricalcium phosphate implants should be answered in this program. It now appears that the rod form porous ceramic implants will eventually biodegrade, even when completely surrounded by bone.




Figure 3. One, Two, Three Millimeter Average Diameter and Rod Form Porous Tricalcium Phosphate Ceramic Implants

TABLE 1. SUMMARY OF 1, 2 AND 3 MM TRICALCIUM PHOSPHATE CERAMIC AND AUTOGENEOUS BONE RABBIT TIBIAL IMPLANT SERIES

<u>Rabbit</u>	<u>Ceramic Size (mm)</u>	<u>Group (months)</u>	<u>Comments</u>
419	1	3	lost at 4 wks, infection
420	1	3	not healed, infection, ceramic retained
422	1	3	healed, no problems
410	1	6	healed, no apparent ceramic
413	1	6	lost at 15 wks, infection
417	1	6	died at 15 wks, healed
397	1	9	died at 3 wks
401	1	9	healed, no problems
402	1	9	healed, no problems
407	1	9	healed but chronic infection
423	2	3	not healed
424	2	3	healed, no problems
429	2	3	died at 3 wks
411	2	6	healed, continued to 52 wks
414	2	6	healed, ceramic retained
421	2	6	healed, ceramic retained but soft
398	2	9	healed, no problems
403	2	9	healed, no problems
404	2	9	healed, no problems
408	2	9	healed, ceramic retained
416	3	3	lost at 5 wks, bridging lesion
425	3	3	healed, no problems
428	3	3	healed, no problems
409	3	6	healed, no problems
412	3	6	lost at 8 wks, infection
415	3	6	healed, no problems
399	3	9	lost at 6 wks
400	3	9	healed, euthanized at 29 wks, inner ear infection
405	3	9	healed, no problems
406	3	9	healed, died at 21 wks




Figure 4. Radiographs of Rabbit R401 Showing 1 Millimeter Granular Ceramic When Bridged (Upper) and at Euthanization (Lower)




Figure 5. Radiographs of Rabbit 398 Showing 2 Millimeter Granular Ceramic Post Surgical (Upper) and at Euthanization (Lower)




Figure 6. Radiographs of Rabbit 405 Showing 3 Millimeter Granular Ceramic Post Surgical (Upper) and at Euthanization (Lower)

TABLE 2. ROD FORM DOG RADIUS POROUS TRICALCIUM PHOSPHATE IMPLANT SUMMARY INFORMATION

<u>Animal</u>	<u>Date - Original Surgery</u>	<u>Comments</u>
229	8/77	Bone plate removed 1/78, good health, implant biodegrading
363	8/77	Bone plate removed 12/77, good health, implant biodegrading
2629	4/79	Bone plate removed 7/80, good health, implant slowly biodegrading
2634	4/79	Bone plate removed 10/79, chronic external ear infections, skin ulcer on limb with implant
2730	4/79	Nonunion, skin problems on limb with implant
2915	6/79	Bone plate removed 6/80, good health
3020	6/79	Nonunion site resected on 1/81, new implant and autogeneous bone placed
2930	6/79	Nonunion site resected on 1/81, new implant and autogeneous bone placed



Figure 7. Radiographs of Dog 229 Showing Rod Form Implant (Upper) and the Long Term Follow Up (Lower)




Figure 8. Radiographs of Dog 2730 Showing Delayed Union (Upper) and Replacement Rod Form Ceramic (Lower)

Human Clinical Trial Protocols

The protocol for the initial human clinical trial investigation on granular form porous tricalcium phosphate ceramic for use with autogeneous bone was written and submitted to the USAMRC and the clinical Investigational Review Committee of the university. Approval has been granted and FDA applications for an investigational number is now in submission. The current proposal is to start the limited human clinical investigations in early 1981.

CONCLUSIONS

The conclusions for the investigations conducted during the last year are summarized as follows.

1. The granular form porous tricalcium phosphate ceramic with average dimensions of 1, 2 or 3 mm when mixed with equal weights of iliac crest autogeneous bone showed healing of a 8 mm rabbit tibial lesion for 23 or 25 intercomparable implants. No correlation with ceramic particulate size could be determined.
2. The rod form porous tricalcium phosphate ceramic implants in the mid-radius site of dogs shows continued biodegradation of the ceramic for the healed and nonunion conditions. Five dogs are healed while the new rod form ceramic implants were placed in the remaining three dogs approximately two years after initial implantation.
3. Gross observation, nondecalcified thin sectioning, standard histological sectioning and general evaluations continues to show good biocompatibility for this porous tricalcium phosphate ceramic.
4. Initial human clinical trial protocols are complete and the various local and national review processes are in progress. Initial human clinical trials for the granular form porous tricalcium phosphate ceramic for use with autogeneous bone should initiate during 1981.

REFERENCES

1. Coriello, J. and Brilliant, J. D., A Preliminary Clinical Study on the Use of Tricalcium Phosphate as an Apical Barrier, *J. Endod.*, 5 (1), 6, 1979.
2. Nery, E. B., Pflughoeft, F. A., Lunch, K. L., and Rodney, G. E. Functional loading of Bioceramic Augmented Alveolar Ridge - a Pilot Study, *J. Prosthet. Dent.*, 43 (3), 338, 1980.
3. Stub, J. R. Gaberthuel, T. W., and Firestone, A. R., Comparison of Tricalcium Phosphate and Frozen Allogenic Bone Implants in Man, *J. Periodontol*, 50 (12), 624, 1979.
4. Shima, T., Keller, J. T., Alvira, M. M., Mayfield, F. H. and Dunsker, S. B., Anterior Cervical Discectomy and Interbody Fusion, An Experimental Study using a Synthetic Tricalcium Phosphate, *J. Neurosurg*, 51 (4), 533, 1979.
5. Signs, S. A., Bajpai, P. K., Pantano, C. G., and Driskell, T. D., In Vitro Dissolution of Synthos Ceramics in a Acellular Physiological Environment, *Biomater., Med. Dev., Artif. Organs*, 7, 183, 1979.
6. Kato, K., Adki, H. Tabata, T. and Ogiso, M., Biocompatibility of Apatite Ceramics in Mandibles, *Biomater., Med. Dev., Artif. Organs*, 7, 291, 1979.
7. McDavid, P. T., Boone, M. E., Kafrawy, A. H. and Mitchell, D. F., Effect of Autogeneous Marrow and Calcitonin on Reactions to a Ceramic, *J. Dent. Res.*, 58, 1478, 1979.
8. Boone, M. E. and Kafrawy, A. H., Pulp Reaction to a Tricalcium Phosphate Ceramic Capping Agent, *Oral Surg.*, 47, 369, 1979.
9. Swart, J. G., Feenstra, L., Ponssen, H. and Degroot, K., Preliminary Clinical Experience with Sintered Tricalcium Phosphate as a Bone Substitute, *Ned Tijdschr Geneeskd*, 123, 1421, 1979 (Dutch Paper).
10. Lemons, J. E., Edentulous Ridge Augmentation, Biocompatibility of Dental Materials, CRC Press, Williams and Smith Editors, Chapter 37, 1979.
11. Kaiser, G., Wagner, W., Tetsch, P., and Kaster, K., Regeneration in Bony Defects after Implantation of Resorbable Calcium Phosphate Ceramics, A Comparative Clinical Study, *Dtsch Zahnarztl*, 35, 108, 1980 (German Paper).
12. Lemons, J. E., Ballard, J. B., Culpepper, M. I., and Niemann, K. M. W. Porous Tricalcium Phosphate Ceramic for Segmental Bone Lesions, *Soc. for Biomat. Abst.*, 1980.
13. Ducheyne, P., Hench, L. L., Kagan, A., Martens, M., Bursens, A. and Mulier, J. C., Effect of Hydroxyapatite Impregnation on Skeletal Bonding of Porous Coated Implants, *J. Biomed. Mater. Res.*, 14, 225, 1980.
14. Klein, C. P. A. T., deGroot, K., Vermeiden, J. P. W., and vankamp, G., Interaction of Some Serum Proteins with Hydroxylapatite and Other Materials, *J. Biomed. Mater. Res.*, 14, 705, 1980.

DISTRIBUTION LIST

4 copies	HQDA (SGRD-SI) Fort Detrick Frederick, MD. 21701
12 copies	Defense Technical Information Center (DTIC) ATTN: DTIC-DDA Cameron Station Alexandria, Virginia 22314
1 copy	Dean School of Medicine Uniformed Services University of the Health Sciences 4301 Jones Bridge Road Bethesda, Maryland 20014
1 copy	Superintendent Academy of Health Sciences, US Army ATTN: AHS-COM Fort Sam Houston, Texas 78234

DATE
ILME
— 88