

AD-A114 509

ARMY MEDICAL RESEARCH INST OF INFECTIOUS DISEASES FO--ETC F/8 6/5
AN INCARCERATED INGUINAL HERNIA INVOLVING THE URINARY BLADDER I--ETC(U)
JAN 82 6 P JAAX, 6 A MCNAMEE, J C DONOVAN

UNCLASSIFIED

NL

1 1/2
1 1/2
1 1/2



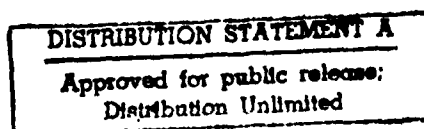
END
DATE
JAN 82
6-82
DTIC

AD A114509

An Incarcerated Inguinal Hernia Involving the Urinary Bladder
in a Cynomolgus Monkey (Macaca fascicularis)^{1,2,3,4}

Gerald P Jaax, George A McNamee Jr, John C Donovan, William S Stokes
Richard D Montrey, and Harry Rozmiarek

DTIC FILE COPY



DTIC
ELECTE
MAY 18 1982
H

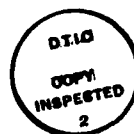Running title: Inguinal Hernia in a Cynomolgus Monkey

¹From the US Army Medical Research Institute of Infectious Diseases, Frederick, MD 21701.

²Address requests for reprints to: Dr. Gerald P. Jaax, US Army Medical Research Institute of Infectious Diseases, Frederick, MD 21701.

³In conducting the research described in this report, the investigators adhered to the "Guide for the Care and Use of Laboratory Animals," as promulgated by the Committee on Care and Use of Laboratory Animals of the Institute of Laboratory Animal Resources, National Research Council. The facilities are fully accredited by the American Association for Accreditation of Laboratory Animal Care.

⁴The views of the authors do not purport to reflect the positions of the Department of the Army or the Department of Defense.



Accession For	
NTIS GRA&I	<input checked="checked" type="checkbox"/>
DTIC TAB	<input type="checkbox"/>
Unannounced	<input type="checkbox"/>
Justification	
By	
Distribution/	
Availability Codes	
Dist	Avail and/or Special
A	

Summary | An inguinal hernia involving the omentum and urinary bladder was detected in a cynomolgus monkey. Surgical repair was performed; recovery was uneventful.

Key Words | Inguinal hernia, Indirect — Urinary bladder —
Cynomolgus monkey

Abdominal hernias in nonhuman primates have been frequently reported in the literature (1-9). They are often associated with a history of traumatic incident, such as long-term chair-restraint, strenuous handling, or escape from a cage (1, 4, 6). Umbilical hernias have been reported in baboons (Papio sp) and a gibbon (Hylobates sp) (7, 8), while para-median abdominal hernias have been reported in the pigtail macaque (Macaca nemestrina) and rhesus (Macaca mulatta) monkeys (1, 5). Indirect inguinal hernias have been reported in the rhesus monkey, baboons, and a pigtailed macaque (1, 4-6, 9), and there is a reported case of a direct inguinal hernia in the cynomolgus monkey (Macaca fascicularis) (10). However, the involvement of an incarcerated urinary bladder in an inguinal hernia has not been reported previously in nonhuman primates.

Case Report

During regular daily rounds by the attending veterinarian, an experimentally naive, adult, 4-7 kg, male cynomolgus monkey (M. fascicularis) was observed to have vomited. Appetite, bowel movements, and urination had been normal and no abnormal clinical signs were evident. The monkey was observed closely; on the third day, a large soft tissue swelling was detected in the left inguinal/scrotal area (Figure 1). Physical examination revealed a clinically healthy, afebrile, unstressed animal, with a 10.5 x 3 cm swelling extending from the scrotum to the inguinal ring. The skin covering and adjacent to the swelling appeared normal and no indication of trauma was evident. Palpation revealed the swelling to be firm with a normal sized left testicle in the caudal portion. The testicle could not be separated from the mass by digital manipulation, nor could the mass be manually

returned to the abdomen. The content or nature of the swelling cranial to the testicle could not be accurately determined by palpation. A tentative diagnosis of inguinal hernia was made and the patient was prepared for surgery.

Surgical Procedure

The monkey was preanesthetized with 0.2 mg/kg acetyl promazine,⁵ and 0.02 mg/kg atropine sulfate,⁶ before intramuscular administration of 10 mg/kg ketamine hydrochloride⁷ anesthesia. The scrotal and inguinal areas were shaved and prepared for surgery. Surgical exploration revealed a hernial sac adherent to the scrotum, requiring digital dissection to free. The sac was excised revealing a 12-cm length of omentum and a portion of the urinary bladder protruding through the inguinal ring. The bladder appeared dark red and was distended with urine. The bladder and omentum could not be replaced until approximately 5 ml of urine were removed by cystocentesis with a 20-gauge needle and syringe. The omentum was ligated at its most proximal point and transected. The deflated bladder was then manually returned through the inguinal ring into the abdominal cavity. The left spermatic cord and testicle were congested and a unilateral orchidectomy was performed. Repair of the inguinal defect and closure of the skin were performed; recovery was uncomplicated.

Discussion

Inguinal hernias in nonhuman primates are a potentially serious problem. Detection can be difficult, especially in a large primate colony or in facilities using gang cages. The various postural attitudes that monkeys assume when confronted by humans can effectively

⁵ Acepromazine^R. Ayerst Laboratories, New York, NY.

⁶ Atropine Sulfate. Eli Lilly and Co., Indianapolis, IN.

⁷ Ketaset^R. Bristol Laboratories, Bristol-Myers Co., Division
Syracuse, NY.

conceal an inguinal defect until significant complications arise. Furthermore, the initial lack of abnormal clinical signs may delay or even prevent detection.

Warren and Piccoli have reported the potential of hernial bladder involvement (4) while Carpenter and Riddle have reported the bladder's presence in a direct inguinal hernia (10). In that case, however, the hernial sac was not adherent, nor was the bladder's blood supply compromised. An undetected hernia involving an incarcerated bladder could have serious consequences including ischemic necrosis, sepsis, and eventually death in an untreated animal. In this instance, it is probable that prompt detection and surgical intervention were responsible for the routine resolution of the case.

References

1. Fox JG: Abdominal hernias in the rhesus monkey (Macaca mulatta). Lab Anim Sci 1971; 21:746-7.
2. Starzynki W: Surgery for abdominal hernia in a pigtailed macaque. Internat'l Zool Yearbook 1965; 5:184.
3. Valerio DA, Miller RL, Innes JRM, et al: Management of a Laboratory Breeding Colony (Macaca mulatta). New York: Academic Press 1969:116-7.
4. Warren RG, Piccolie A: Bilateral inguinal hernia in a pigtailed monkey (Macaca nemestrina). Lab Anim Sci 1979; 29:400-1.
5. Rawlings CA, Kirk JH, Harwell JF Jr et al: Indirect inguinal hernia in two rhesus monkeys. J Am Vet Med Assoc 1971; 159: 621-2.
6. Chaffee V, Shehan T: Indirect inguinal hernia in two baboons. J Am Vet Med Assoc 1975; 163:638.
7. Schultz AH: Notes on diseases and healed fractures of wild apes and their bearing on the antiquity of pathological conditions in man. Bull Hist Med 1939; 7:571-82.
8. Kalter SS, Kunz RE, Myers BJ, et al: The collection of biomedical specimens from baboons (Papio sp.), Kenya 1966. Primates 1968; 9:123-9.
9. Ratcliffe HL: Left inguinal hernia in a pigtailed macaque (Macacus nemestrina). Report of the Laboratory of Comparative Pathology. Philadelphia 1930:51-2.
10. Carpenter RH, Riddle KE: Direct inguinal hernia in the cynomolgus monkey (Macaca fascicularis). J Med Primatol 1980; 9:194-9.

FIGURE LEGEND

Figure 1

Inguinal hernia in a cynomolgus monkey.

UNCLASSIFIED

SECURITY CLASSIFICATION OF THIS PAGE (When Data Entered)

REPORT DOCUMENTATION PAGE		READ INSTRUCTIONS BEFORE COMPLETING FORM
1. REPORT NUMBER	2. GOVT ACCESSION NO.	3. RECIPIENT'S CATALOG NUMBER
	AD-A114 589	
4. TITLE (and Subtitle) AN INCARCERATED INGUINAL HERNIA INVOLVING THE URINARY BLADDER IN A CYNOMOLGUS MONKEY (MACACA FASCICULARIS)		5. TYPE OF REPORT & PERIOD COVERED
		6. PERFORMING ORG. REPORT NUMBER
7. AUTHOR(s) Gerald P. Jaax, George A. McNamee, Jr., John C. Donovan, William S. Stokes, Richard D. Montrey, and Harry Rozmiarek		8. CONTRACT OR GRANT NUMBER(s)
9. PERFORMING ORGANIZATION NAME AND ADDRESS Animal Resources Division USAMRIID Ft Detrick, Frederick, MD 21701		10. PROGRAM ELEMENT, PROJECT, TASK AREA & WORK UNIT NUMBERS MK-24
11. CONTROLLING OFFICE NAME AND ADDRESS U.S. Army Medical Research and Development Command, Office of the Surgeon General Department of the Army, Washington, D.C. 20314		12. REPORT DATE 19 Jan 82
		13. NUMBER OF PAGES 11
14. MONITORING AGENCY NAME & ADDRESS (if different from Controlling Office)		15. SECURITY CLASS. (of this report) Unclassified
		15a. DECLASSIFICATION/DOWNGRADING SCHEDULE
16. DISTRIBUTION STATEMENT (of this Report) Approved for public release; distribution unlimited		
17. DISTRIBUTION STATEMENT (of the abstract entered in Block 20, if different from Report)		
18. SUPPLEMENTARY NOTES Reprints bearing assigned AD number will be forwarded upon receipt. To be submitted for publication in Journal of Laboratory Animal Science.		
19. KEY WORDS (Continue on reverse side if necessary and identify by block number) Inguinal Hernia Indirect Urinary Bladder Cynomolgus Monkey		
20. ABSTRACT (Continue on reverse side if necessary and identify by block number) An inguinal hernia involving the urinary bladder and omentum was detected in a Cynomolgus monkey. Surgical repair was performed. Recovery was routine.		

DD FORM 1473

EDITION OF 1 NOV 65 IS OBSOLETE

UNCLASSIFIED

SECURITY CLASSIFICATION OF THIS PAGE (When Data Entered)

820517063

END

DATE
FILMED

6-82

DTIC