

AD-A110 399

ARMY INST OF DENTAL RESEARCH WASHINGTON DC  
A PRELIMINARY REPORT ON THE OSTEOGENIC POTENTIAL OF A BIODEGRAD--ETC(U)  
DEC 81 J O HOLLINGER

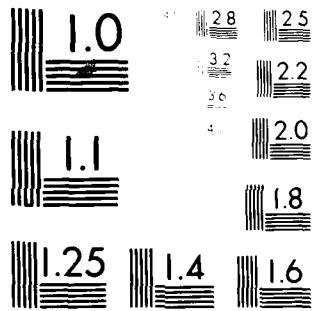
F/6 6/5

UNCLASSIFIED

NL

1 of 1  
AD A  
1 01 399

END  
DATE  
FILMED  
02 82  
DTIC



MICROCOPY RESOLUTION TEST CHART  
NATIONAL BUREAU OF STANDARDS-1963-A

LEVEL II

12

SECURITY CLASSIFICATION OF THIS PAGE (When Data Entered)

REPORT DOCUMENTATION PAGE		READ INSTRUCTIONS BEFORE COMPLETING FORM
1. REPORT NUMBER	2. GOVT ACCESSION NO.	3. RECIPIENT'S CATALOG NUMBER
	AD A110399	
4. TITLE (and Subtitle) A Preliminary Report on the Osteogenic Potential of a Biodegradable Copolymer of Polylactide: Polyglycolide (PLA:PGA)		5. TYPE OF REPORT & PERIOD COVERED Manuscript for Publication July - December 1981
7. AUTHOR(s) Jeffrey O. Hollinger		6. PERFORMING ORG. REPORT NUMBER
9. PERFORMING ORGANIZATION NAME AND ADDRESS U. S. Army Institute of Dental Research Walter Reed Army Medical Center Washington, DC 20012		8. CONTRACT OR GRANT NUMBER(s)
11. CONTROLLING OFFICE NAME AND ADDRESS U. S. Army Medical Research & Development Command SGRD-RMS Fort Detrick, Maryland 21701		10. PROGRAM ELEMENT, PROJECT, TASK AREA & WORK UNIT NUMBERS OB 6037, 3S16102BS10, 04, 09
14. MONITORING AGENCY NAME & ADDRESS (if different from Controlling Office)		12. REPORT DATE 3 December 1981
		13. NUMBER OF PAGES 12
		15. SECURITY CLASS. (of this report) UNCLASSIFIED
		15a. DECLASSIFICATION/DOWNGRADING SCHEDULE

16. DISTRIBUTION STATEMENT (of this Report)  
This document has been approved for public release and sale; its distribution is unlimited.

17. DISTRIBUTION STATEMENT (of the abstract entered in Block 20, if different from Report)

DTIC  
ELECTE  
FEB 3 1982  
S D  
D

18. SUPPLEMENTARY NOTES

None

19. KEY WORDS (Continue on reverse side if necessary and identify by block number)

Biodegradable Copolymer; Polylactic and Polyglycolic Acids;  
Osteogenic; Osseous Wound Repair; Accelerated Bony Healing.

82 02 02 065

20. ABSTRACT (Continue on reverse side if necessary and identify by block number)

A biodegradable copolymer of 50:50 polylactide:polyglycolide was prepared for implantation into experimentally created osseous defects in the tibias of 25 rats. Similarly prepared defects were made in the humeri and these did not receive copolymer implants. At 7, 14, 21, 28, and 42 days five animals were sacrificed and the implant and untreated sites were evaluated by gross visual inspection and by histologic examination using a Zeiss Videoplan Image Analysis System with Osteoplan™ for the quantitation of bone morphometrics. When compared with bony defects that were not treated with the biodegradable copolymer implant

AD A110399

DTIC FILE COPY

UNCLASSIFIED

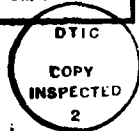
SECURITY CLASSIFICATION OF THIS PAGE(When Data Entered)

BLOCK 20. (continued)

the implant sites displayed a slightly accelerated healing response rate at 7 days ( $p < 0.01$ ), a slightly accelerated response rate at 14 and 21 days ( $p < 0.005$ ), and a similar healing response rate at 28 and 42 days ( $p < 0.01$ ). The copolymer was highly tissue tolerant throughout the period of the investigation.

SECURITY CLASSIFICATION OF THIS PAGE(When Data Entered)

Accession For	
NTIS GRA&I	<input checked="" type="checkbox"/>
DTIC TAB	<input type="checkbox"/>
Unannounced	<input type="checkbox"/>
Justification	
By _____	
Distribution/	
Availability Codes	
Dist	Avail and/or Special
A	



A PRELIMINARY REPORT ON THE OSTEOGENIC POTENTIAL OF A BIODEGRADABLE  
COPOLYMER OF POLYLACTIDE:POLYGLYCOLIDE (PLA:PGA)

JEFFREY O. HOLLINGER, D.D.S.

Division of Basic Sciences  
U. S. Army Institute of Dental Research  
Walter Reed Army Medical Center  
Washington, D. C. 20012

**DISTRIBUTION STATEMENT A**  
Approved for public release;  
Distribution Unlimited

A PRELIMINARY REPORT ON THE OSTEOGENIC POTENTIAL OF A BIODEGRADABLE  
COPOLYMER OF POLYLACTIDE:POLYGLYCOLIDE (PLA:PGA)

SYNOPSIS

A biodegradable copolymer of 50:50 polylactide:polyglycolide was prepared for implantation into experimentally created osseous defects in the tibiae of 25 rats. Similarly prepared defects were made in the humeri and these did not receive copolymer implants. At 7, 14, 21, 28, and 42 days five animals were sacrificed and the implant and untreated sites were evaluated by gross visual inspection and by histologic examination using a Zeiss Videoplan Image Analysis System with Osteoplan<sup>™</sup> for the quantitation of bone morphometrics. When compared with bony defects that were not treated with the biodegradable copolymer implant, the implant sites displayed a slightly accelerated healing response rate at 7 days ( $p < 0.01$ ), a slightly accelerated response rate at 14 and 21 days ( $p < 0.005$ ), and a similar healing response rate at 28 and 42 days ( $p < 0.01$ ). The copolymer was highly tissue tolerant throughout the period of the investigation.

KEYWORDS: Biodegradable Copolymer; Polylactic and Polyglycolic Acids; Osteogenic; Osseous Wound Repair; Accelerated Bony Healing.

## INTRODUCTION

The alpha-polyesters, polylactide and polyglycolide, have been investigated for use as suture and implant materials for the repair of a variety of soft tissue and osseous wounds.<sup>1-5</sup> Implanted polymers and copolymers of polylactide and polyglycolide were expected to function in a supportive role, to undergo hydrolytic scission to form nontoxic, excretable metabolites, and to be ultimately replaced by the host's contiguous tissue. Indeed, it was found by Getter<sup>4</sup> that a homopolymer of lactic acid, when used in dogs for mandibular fracture repair, had partially degraded after six weeks and was completely resorbed after thirty-two weeks. Getter described the fracture sites at thirty-two weeks as being indistinguishable from the adjacent bone areas. Cutright<sup>5</sup> employed a similar homopolymer implant for the repair of blowout fractures of the orbital floor in monkeys. After thirty-eight weeks, it was found that the implants were being tolerated well but had not been completely resorbed, although phagocytosis of polymer fragments was occurring. At this time there is no information in the literature about the osteogenic potential of a 50:50 copolymer of polylactide:polyglycol to induce bony wound healing. It was the purpose of this study, therefore, to evaluate the healing capacity of prepared osseous wounds treated with the biodegradable copolymer of 50:50 PLA:PGA compared with nontreated control bony wounds.

## METHODS AND MATERIALS

A commercially synthesized copolymer of 50:50 PLA:PGA (50:50 poly (L (-) lactide co-glycolide), having an inherent viscosity of 0.92 dl/g

as measured in hexafluoroisopropanol at 30C, corresponding to a weight-average-molecular weight of approximately 80,000 Daltons, was solubilized in methylene chloride at a 1:12.5 weight:volume ratio. Anhydrous methanol (1:1) was added to this liquid suspension to precipitate a milky-white gelatinous mass which was then placed into prepared wells (2.0 mm X 1.25 mm) in a Teflon mold. The viscous, milky-white copolymer mass was gently forced into the prepared wells using a supple Teflon spatula and this was placed in a lyophilizer chamber at a pressure of 0.1 mm of mercury for 48 hours. After 48 hours each copolymer preparation was designated as an implant plug (Figure 0A and 0B) and all plugs were sterilized in ethylene chloride and stored in a dessicator.

Using sodium pentobarbital, USP (Pentobarbital Sodium), 25 adult Walter Reed strain of rats (random male and female) were anesthetized by IP injection at a dose of 3 to 5 mg/100 mg of body weight. Each tibia was prepared for a copolymer implant and each humerus was prepared as a control. The tibias and the humeri were clipped and scrubbed with povidone iodine, NF (Betadine®) for three to five minutes. An incision 1 cm in length was made on the anteriolateral surface of each tibia and humerus and soft tissue was reflected down to bone to expose the broadest area of the diaphysis. A hole was made completely through the cortical plate and into the medullary cavity using a bone trephine (OD = 1.95 mm) and sterile water coolant. An implant was placed in each tibia and the humeri holes were left



void to serve as controls. All surgical sites were appropriately sutured and the animals were returned to their individually marked cages. At 7, 14, 21, 28, and 42 days five animals were sacrificed by administration of an overdose of sodium pentobarbital. Gross examination was made of the implant and control areas after surgical removal of the overlying soft tissues. A bone saw was then used to remove the implant and control sites from the contiguous bone and at least 5 mm of host bone remained to encompass these zones. The retrieved specimens were fixed in 10% formalin. After decalcification for 18 hours in Bankuthy's medium the specimens were prepared for hematoxylin and eosin staining. Quantitative morphometric analysis was undertaken using a Zeiss Videoplan Image Analysis System with Osteoplan™.

## RESULTS

### Gross Examination

#### Control Sites

1. 7 to 14 days: Inspection revealed circular wounds that appeared to be filled with a reddish-brown, soft tissue.
2. 21 days: Wounds were similar in configuration to the 7 and 14 day levels, with the exception that tissue in the wound bed appeared to be speckled with osteoid or osseous components.
3. 28 and 42 days: By 28 days it had become increasingly difficult to discern wound sites from contiguous bone. By

42 days all control wounds demonstrated complete osseous union.

#### Implant Sites

1. 7 days: Rather than the crisply shaped circular implant plug, an irregularly contoured implant was evident in the experimental site. The implant appeared to be firmly fixed in all the experimental sites. Reddish-brown soft tissue was apparent among the implant interstices.
2. 14 through 28 days: It became obvious as the experiment progressed that the copolymer implant was gradually hydrolyzing (breaking down) and that a whitish (osteoid?) tissue fill was filling the prepared wound zones. The implant remained firmly entrenched within the wound bed at all times.
3. 42 days: There appeared to be no gross evidence of the copolymer implant. Bony union appeared to have been achieved.

#### Histologic Examination

##### Control Sites

Histologic observation of the healing control sites revealed an unremarkable progression of normal endochondral bone formation. A typical callus developed and osteogenic cell proliferation resulted in a distinct collar of uniting tissue around the defect border. The more rapidly growing areas of the callus displayed chondrocytic differentiation at the early stages (7 through 21 days). As a capillary network developed and became steadily more advanced, vascular penetration into the cartilaginous sanctum occurred and osteoblastic

cell populations became predominant. By 28 to 42 days numerous zones of osteoid and bony spicules had been replaced by rapidly coalescing trabeculae (Figure 1). By 42 days a complete bony union had been achieved, albeit areas of immature bone were evident. Osteons were not present, indicating that at 42 days substantial union was still lacking.

#### Implant Sites

1. 7 days: The implant appeared as a wavy, heterogenous, and amorphous structure with infrequent lymphocytic infiltrate and a few polymorphonuclear cells (Figure 2A). Host-cell activity was evident at the implant periphery; centrally, a minimal number of lymphocytes were observed. Juxtaposed to the copolymer implant-host bone boundary were zones of osteoid with frequent robust osteoblasts (Figure 2B).
2. 14 and 21 days: The implants became increasingly more tenuous as the experiment continued. Observed at 14 days, and more dramatically apparent at 21 days, was the gradual dissolution of the implant into multiple islands and peninsulas of material with osteoid-immature bone-copolymer intercalations (Figure 3). Trabeculae with both entrapped and rimming osteoblasts became more predominant at 21 days than at 14 days (Figure 4). Birefringence of the polyglycolide from hydrolytic scission of the implant was typical of the 21 day histologic picture. A robust periosteal callus was routinely seen by 21 days. Some specimens (Figure 5) displayed remarkable fervor in their bony healing response.
3. 28 and 42 days: Implant copolymer was present at 42 days in the form of isolated, irregularly shaped small zones

of birefringence. Osteoid and trabecular coalescence were evident at 28 and 42 days, despite remaining implant that had not been fully degraded. Capillary penetration and phagocytic cells were often closely associated with residual copolymer islands. Satisfactory callus formation resulted in complete obliteration of the wound defect by 42 days, and in several specimens this result was achieved at the 28 day level (Figure 6.). There was no indication of an inflammatory response in any of the implant specimens. Tissue tolerance of the implant copolymer was extremely favorable.

#### DISCUSSION

In different experiments Getter *et al.*<sup>4</sup> and Cutright *et al.*<sup>5</sup> determined that a homopolymer of lactic acid (PLA) could be used for selected types of osseous wound repair. These investigators also noted that PLA was observed histologically up to 38 weeks after implantation.<sup>4</sup> Several studies have shown histological evidence of homopolymers of glycolic acid (PGA) being present in soft tissue, varying from 50 to 120 days after implantation.<sup>2,3</sup> In a histologic study to plot copolymer and homopolymer degradation of PGA and PLA, Cutright *et al.*<sup>6</sup> determined that by varying the proportions of PLA to PGA, degradation rates could be varied from between 100 days to greater than 220 days. It was found that the homopolymers, PLA and PGA, persisted for the greatest time span, while the 25% PLA degraded most rapidly, followed in succession by 50% and 75% PLA.

Kulkarni *et al.*<sup>7</sup> investigated polylactide degradation *in vivo*

using  $^{14}\text{C}$ -labeled homopolymer. These workers compared the kinetics of degradation of the D,L- and L(-)-polymers and they established that the D,L form degraded more rapidly. This property may be attributed to the high order of crystallinity of this form of polymer. The mechanical properties of homopolymers and copolymers of glycolide and lactide also vary directly with composition. The composition varies, according to Sinclair and Gynn,<sup>8</sup> in relation to the degree of crystallinity. The different optical activities (crystallinity) of the homopolymer/copolymer implants could logically explain the variable rates of degradation that have been reported. The degradation rate of a homopolymer/copolymer must be defined in terms of the polymer's optical activity. In the investigation undertaken in this laboratory, a 50:50 poly (L (-) lactide co-glycolide) implant was employed. Breakdown was noted histologically by seven days. This observation could contrast markedly with a copolymer of a different optical activity or crystallinity. It is perhaps this factor that has led to some amount of disparity between studies, in terms of degradation rates of copolymers and homopolymers of lactides and glycolides. Also, different preparation techniques for fabrication of the copolymer implant could produce a variety of different physical properties. In this laboratory, a nondeformable, spongy morphology was achieved (Figures 7 and 8). In contrast, a glassy, dense structure could have been produced, if such an attribute was desired. A hard, spongy architecture allows for rigid, stable bone fixation and permits host access to a vast molecular domain for hydrolytic scission and subsequent hard tissue ingress.

In the study performed in this laboratory, the glycolide/lactide copolymer implant was still present in the wound bed after 42 days, although to a lesser degree than the 28 or 21 day levels. The presence of the copolymer implant did not adversely affect bone induction. Indeed, there was strong evidence ( $p < 0.005$ ) that the copolymer did effectively promote osteogenesis at a rate greater than would be anticipated in a similarly contrived wound. This point is an important consideration for bony wound repair. It is the primary incentive for the pursuit of the study of the 50:50 PLA:PGA implant copolymer by this laboratory. Bony wound fixation (i.e., mandibular arch fractures) requires reduction and fixation for four to eight weeks. A copolymer employed for fixation that could degrade in harmony with normal osseous healing would be ideal. If that same copolymer could also orchestrate an accelerated bone healing process, then this would be superb.

It would be germane at this time to mention briefly the manner by which the 50:50 PLA:PGA copolymer implant is degraded. Nonspecific hydrolytic scission of the copolymer chain results in the generation of lactic acid and glycolic acid residues. The lactic acid becomes incorporated into the tricarboxylic acid cycle and is consequently excreted by the lungs as  $\text{CO}_2$ . The glycolic acid molecules are acted upon by glycolate oxidase and are transformed into glyoxylate, which reacts with glycine transaminase and results in the formation of glycine. The glycine can be used for protein synthesis or for the

synthesis of serine, which may be employed in the tricarboxylic acid cycle after transformation into pyruvate.

#### CONCLUSION

When compared with the untreated, control wounds, the wounds where copolymer implants were inserted did display an early acceleration in bone healing (7 days:  $p < 0.01$ , and 14 and 21 days:  $p < 0.005$ ); however, a similar healing rate was displayed at 28 and 42 days ( $p < 0.01$ ). Bone healing rate was assessed in terms of 36 morphometric parameters that were quantitated using a Zeiss Image Analysis System with Osteoplan™. Important considerations to be highlighted are that the implant was well tolerated by the host tissue and it did not impede bony repair. By hastening early osseous repair, the likelihood of the occurrence of fragment migration is minimized. Stability in bony wound healing is a critical parameter for successful union.

\* \* \* \*

Commercial materials and equipment are identified in this report to specify the investigative procedures. Such identification does not imply recommendation or endorsement or that the materials and equipment are necessarily the best available for the purpose. Furthermore, the opinions expressed herein are those of the authors and are not to be construed as those of the U. S. Army Medical Department.

ANIMAL CARE STATEMENT

In conducting research described in this report, the investigator adhered to the "Guide for the Care and Use of Laboratory Animals" as promulgated by the Committee on the Revision of the Guide for Laboratory Animal Facilities and Care of the Institute of Laboratory Animal Resources, National Research Council.



#### REFERENCES

1. D.E. Cutright, E.E. Hunsuck, and J.D. Beasley, III: "Fracture Reducing Using a Biodegradable Material, Polylactic Acid." *J Oral Surg* 29:393-397, (1971).
2. D.E. Cutright, J.D. Beasley, III, and B. Perez: "Histologic Comparison of Polylactic and Polyglycolic Acid Sutures." *Oral Surg* 32:165-173, (1971).
3. E.J. Frazza and E.E. Schmitt: "A New Absorbable Suture." *J Biomed Mater Res Symposium* 1:43-58 (1971).
4. L. Getter and D.E. Cutright: "Fracture Fixation Using Biodegradable Material." *J Oral Surg* 30:344:348 (1972).
5. D.E. Cutright and E.E. Hunsuck: "The Repair of Fractures of the Orbital Floor." *Oral Surg* 33:28-34 (1972).
6. D.E. Cutright, B. Perez, J.D. Beasley, III, W.J. Larson, and W.R. Posey: "Degradation Rates of Polymers and Copolymers of Polylactic and Polyglycolic Acids." *Oral Surg* 37:142-152 (1974).
7. R.K. Kulkarni, E.G. Moore, A.F. Hegyeli, and F. Leonard: "Biodegradable Poly(lactic acid) Polymers." *J Biomed Mater Res* 5: 169-181 (1971).
8. R.G. Sinclair and G.M. Gynn: *Preparation and Evaluation of Glycolic and Lactic Acid-Based Polymers for Implant Devices Used in Management of Maxillofacial Trauma, Part I. Final Scientific Report under Contract #DADA17-72-C-1053 by Battelle Columbus Laboratories, Columbus, Ohio supported by U. S. Army Medical Research and Development Command, Washington, D.C. 20314.*

### LEGENDS

FIGURE 1. Osseous wound healing in a control site of the tibia of a rat at 28 days.

FIGURE 2A. At 7 days the copolymer implant plug (\*) appeared wavy, heterogenous, and amorphous with infrequent lymphocytes and polymorphonuclear cells (arrows).

FIGURE 2B. At 7 days zones of osteoid with robust osteoblasts could be seen.

FIGURE 3. By 14 days within the experimental wound bed, the copolymer had broken down into numerous islands (\*). Bony trabeculae were evident throughout the dissolving implant (arrows). A bony bridge had also formed (arrowheads). An inflammatory response was not evident.

FIGURE 4. By 21 days numerous bony trabeculae were developed at the implant site and there was scarce evidence of the implant.

FIGURE 5. At 21 days all wound sites treated with an implant had a well developed bony bridge (arrowheads).

FIGURE 6. By 42 days complete obliteration of the osseous defect was achieved (between arrowheads). In several specimens, wound closure was demonstrated at 28 days. No inflammatory infiltrate was present.


FIGURE 7. An end-view of the copolymer implant plug magnified 50X in a scanning electron microscope.

FIGURE 8. The same implant as Figure 7, but magnified 100X. The irregular, spongy morphology of the copolymer may be easily observed.

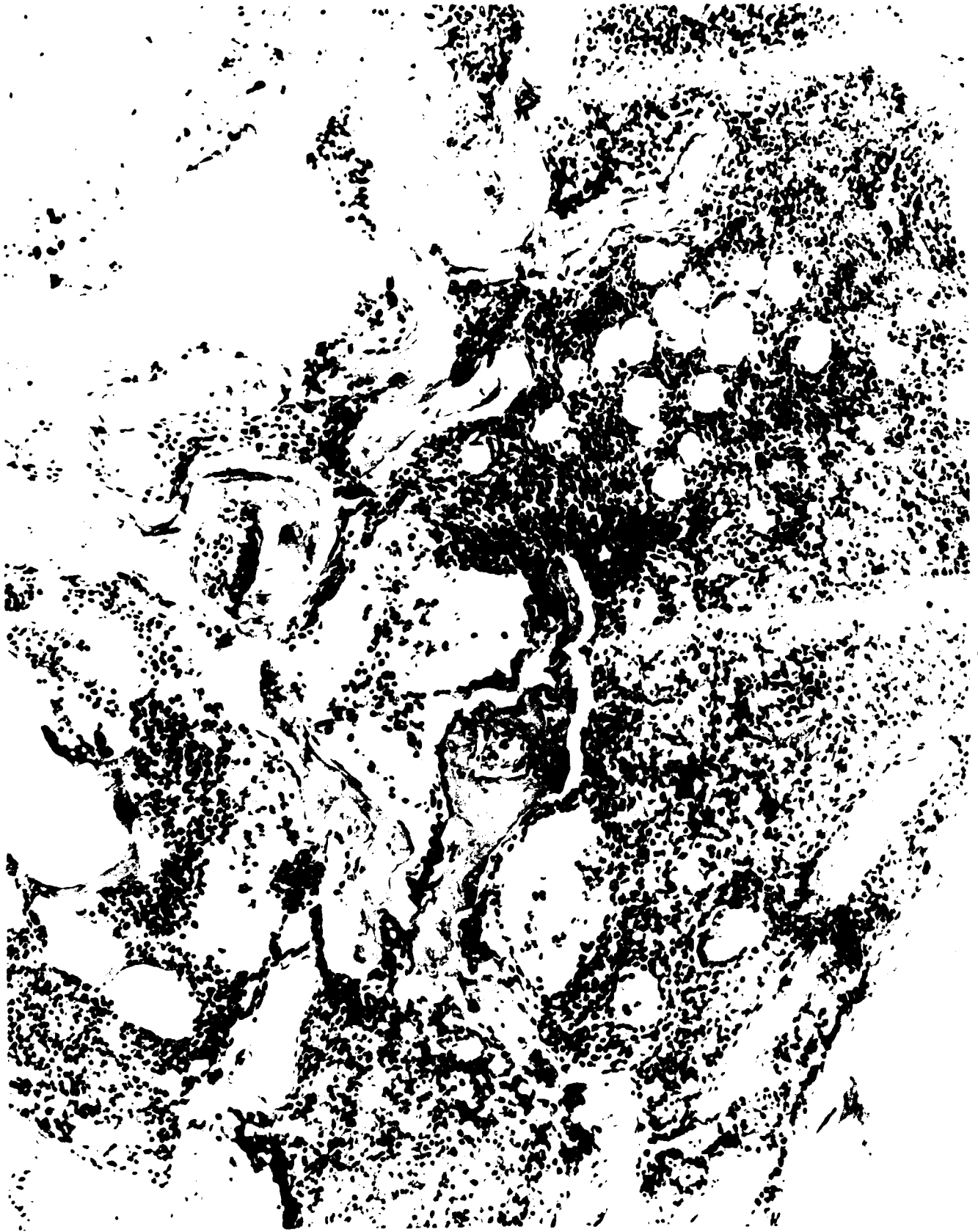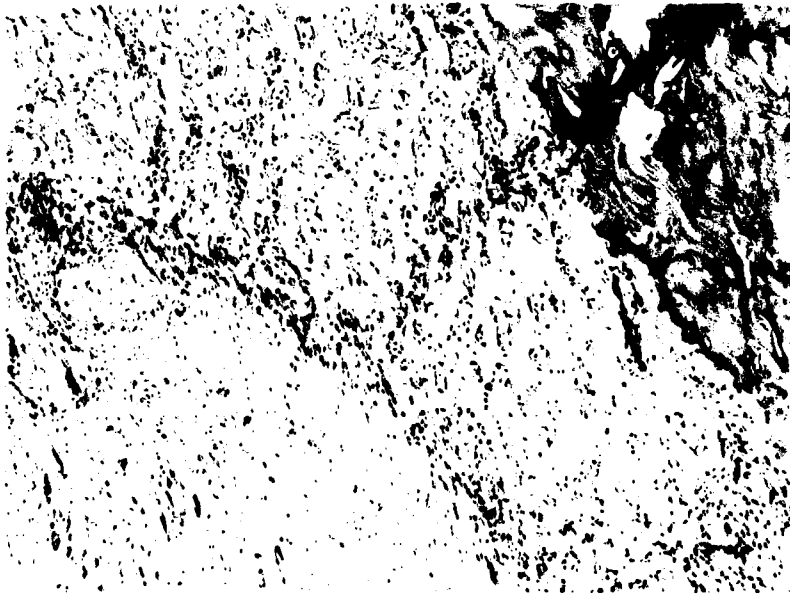


Fig. 1

2A



2B



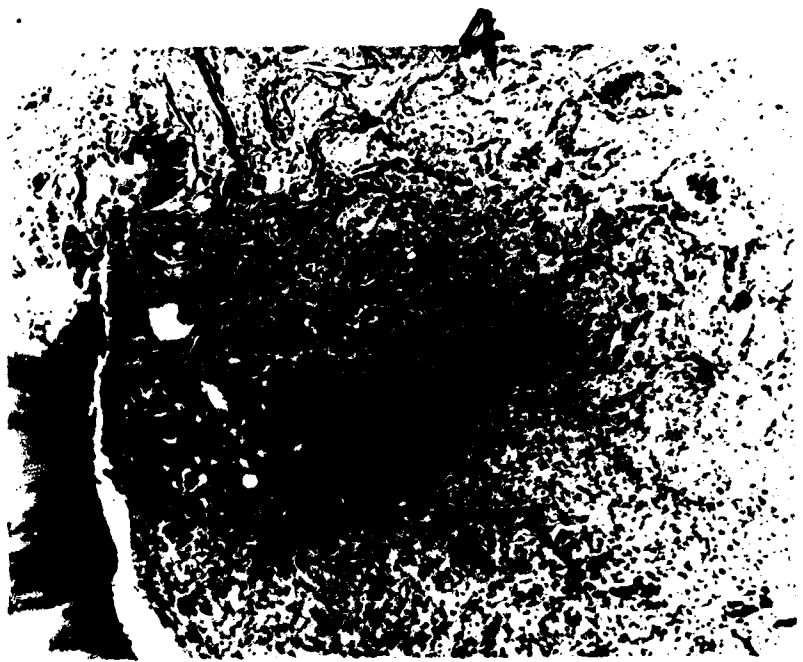
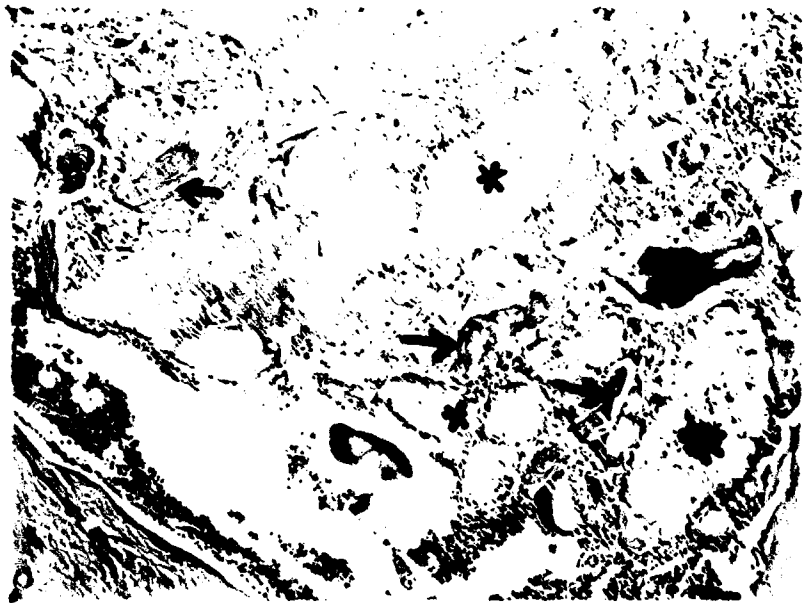




Fig. 5





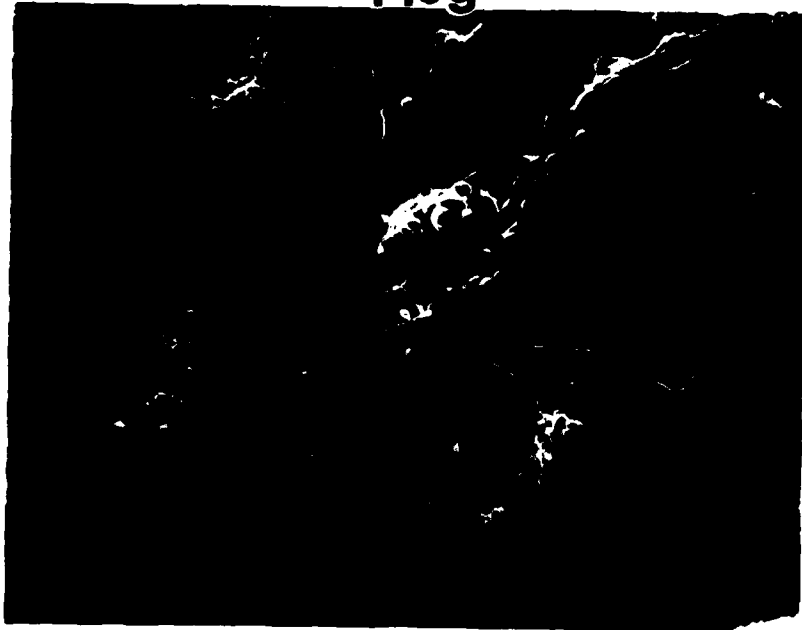6

plug



7

plug



8



**DATE  
FILMED**

**2-8**