

AD-A064 646

ARMY INST OF DENTAL RESEARCH WASHINGTON D C  
RETAINED TOOTH VITALITY AFTER FIFTEEN YEARS DISPLACEMENT INTO F--ETC(U)  
DEC 78 E A RUSSELL, B M KOUDDELKA

F/G 6/5

UNCLASSIFIED

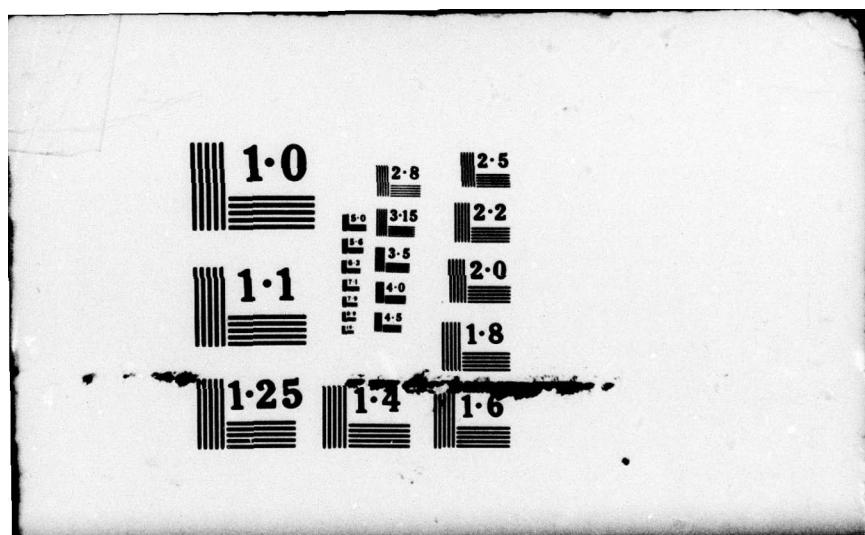
NL

1 OF 1  
ADA  
064646



END  
DATE  
FILMED

4-79  
DDC



LEVEL II

①  
14

SECURITY CLASSIFICATION OF THIS PAGE (When Data Entered)

ADA 064646

DDC FILE COPY

REPORT DOCUMENTATION PAGE		READ INSTRUCTIONS BEFORE COMPLETING FORM
1. REPORT NUMBER	2. GOVT ACCESSION NO.	3. RECIPIENT'S CATALOG NUMBER n/a
4. TITLE (and Subtitle) ⑥ Retained Tooth Vitality After Fifteen Years Displacement Into Floor of Mouth: A Case Report		5. TYPE OF REPORT & PERIOD COVERED n/a
7. AUTHOR(s) ⑩ Emery A./Russell, Jr., Brent M. Koudelka Mark E./Ballinger		6. PERFORMING ORG. REPORT NUMBER n/a
9. PERFORMING ORGANIZATION NAME AND ADDRESS US Army Institute of Dental Research Walter Reed Army Medical Center Washington, D.C. 20012		8. CONTRACT OR GRANT NUMBER(s) n/a
11. CONTROLLING OFFICE NAME AND ADDRESS US Army Medical Research & Development Command SGRD-RP Washington, D.C. 20314		10. PROGRAM ELEMENT, PROJECT, TASK AREA & WORK UNIT NUMBERS ⑪ n/a
14. MONITORING AGENCY NAME & ADDRESS (if different from Controlling Office) ⑫ 11p.		12. REPORT DATE 8 December 1978
		13. NUMBER OF PAGES 10 pages
		15. SECURITY CLASS. (of this report) UNCLASSIFIED
		15a. DECLASSIFICATION/DOWNGRADING SCHEDULE
16. DISTRIBUTION STATEMENT (of this Report)  This document has been approved for public release and sale; its distribution is unlimited.		
17. DISTRIBUTION STATEMENT (of the abstract entered in Block 20, if different from Report)  DDC DISTRIBUTION 13 FEB 1979 RECEIVED E		
18. SUPPLEMENTARY NOTES		
19. KEY WORDS (Continue on reverse side if necessary and identify by block number)  Tooth vitality, Displaced tooth, Retained root, Wound debridement		
20. ABSTRACT (Continue on reverse side if necessary and identify by block number)  A case of a tooth traumatically displaced into the floor of the mouth which retained its vitality for fifteen years is reported. Although the presence of the tooth and soft tissue cuff which appeared to represent the original attached gingiva presented a source for complications, no sig- nificant pathological changes were noted. The requirement for a thorough radiographic examination before definitive treatment of maxillofacial injuries is emphasized.		

DD FORM 1 JAN 73 1473

EDITION OF 1 NOV 65 IS OBSOLETE

SECURITY CLASSIFICATION OF THIS PAGE (When Data Entered)

038670

Cameron ✓

LB

79 01 16 07 1



RETAINED TOOTH VITALITY AFTER FIFTEEN YEARS  
DISPLACEMENT INTO FLOOR OF MOUTH:  
A CASE REPORT

Traumatic avulsion of teeth is a common occurrence especially in young children where root development is incomplete. These teeth are often successfully replanted into the tooth sockets. However, maintenance of tooth vitality is not always assured and, among other factors, appears to be highly dependent upon the length of time the tooth has been outside the mouth. Although avulsed teeth are not normally replanted when associated with the line of jaw fracture, a thorough radiographic survey should be made to assure complete debridement of the wound. Intraoral occlusal radiographs are recommended before definitive treatment of mandibular fractures. This case report illustrates the importance of the occlusal roentgenogram when the dentition is involved in jaw fractures.

Case Report:

A 22 year old caucasian male presented for routine dental examination at a Fort Meade outpatient dental clinic. Oral findings revealed a mandibular incisor tooth to be missing. A past medical history further revealed he had been treated for a mandibular fracture at the age of seven, fifteen years prior to this examination. An occlusal roentgenogram showed a tooth to be located in the floor of the mouth in close approximation to the lingual cortex of the mandible (Fig. 1). Bimanual palpation further localized the position of the tooth in the periapical region of the left mandibular bicuspid teeth.

The patient was not aware of the presence of the displaced tooth nor any complications associated with it since the time of his injury. Although the patient was asymptomatic the decision was made to remove the tooth. Surgical exploration by way of a lingual mucoperiosteal flap extending from the midline

of the mandible to the left second molar revealed the tooth to be subperiosteal in location. The root appeared to be ankylosed to the lingual cortex of the mandible but this presented no difficulty in removal of the tooth. The patient's postoperative course was unremarkable.

Clinical examination of the tooth after removal showed the root to be incompletely developed. A soft tissue cuff surrounded the tooth in the region of the cemento-enamel junction (Fig. 2). The tooth and attached soft tissue were submitted for histopathological examination.

#### Histopathology:

The specimen (Fig. 3) is that of a decalcified vital tooth showing a patent pulp canal. Within the pulp chamber, demonstrating vitality of the tooth, are seen a loose arrangement of fibroblasts, vascular tissue and scattered chronic inflammatory cells (Fig. 4). Small foci of odontoblasts were seen only in the apical region of the pulp canal. A band of dense fibrous connective tissue surrounds the central portion of the tooth (Fig. 5). Several small fragments of epithelium are evident and may represent remnants of the original epithelial attachment.

#### Discussion:

The root portion of the tooth is composed of four functionally and morphologically different calcified tissues. As would be expected, the bulk of the tooth structure consists of uniform, well organized rows of dentinal tubules of the primary dentin. An abrupt change to irregular, poorly organized rows of tubules is noted immediately adjacent to the primary dentin and nearly occludes the pulp canal. In the normal tooth this layer would represent secondary dentin. However, in this specimen the tissues most likely represent a combination of both secondary and reparative dentin. Significantly, the ratio of primary to



secondary dentin is lowest at the apex of the tooth producing morphologically a funnel shaped or "blunderbuss" effect. This is consistent with the clinical history of displacement at an early age before complete formation of the apical foramen. Coronal, in the region of the pulp chamber, there is evidence of active internal resorption of the dentin with concomitant apposition of tissue resembling bone. This has been described by Shafer as osteodentin<sup>3</sup> and most likely represents a chronic inflammatory process characterized by alternating periods of resorption and repair. In time, continued deposition of osteodentin could have caused complete obliteration of the pulp chamber. This would suggest that the displaced tooth was being treated as a foreign body. Interestingly, no significant histological change in the epithelial remnants was noted; however, the potential for proliferation with possible resultant pathology did exist.

Summary:

A case of a mandibular incisor traumatically displaced into the subperiosteal, periapical area of the bicuspid which retained its vitality for 15 years is reported. Although no significant pathology developed, the potential for pathological change did exist as demonstrated by the presence of the tooth with its associated mesenchymal and epithelial components. The findings in this case serve to emphasize the requirement of an adequate radiographic survey to assure complete wound debridement before definitive treatment of maxillo-facial injuries.

## REFERENCES

1. Grossman, L.I.: Endodontic practice, ed. 8, Phila., 1974, Lea and Febiger, pp. 389-393.
2. Archer, H.W.: Oral Surgery: A Step-By-Step Atlas of Operative Techniques, ed. 4, Phila., 1966, W.B. Saunders Co., p. 772.
3. Shafer, W.G., Hine, M.K., and Levy, B.M.: A textbook of Oral Pathology, ed. 3, Phila., 1974, W.B. Saunders Co., pp. 291, 300-301.



## LEGEND OF ILLUSTRATIONS

- Figure 1. Occlusal radiograph showing displaced tooth in floor of mouth.
- Figure 2. Displaced tooth with incomplete root development and associated connective tissue cuff resembling the original attached gingiva.
- Figure 3. Low-power photomicrograph of decalcified tooth showing (A) organized rows of dentinal tubules of the primary dentin and (B) poorly organized rows of dentinal tubules of the secondary or reparative dentin (Hematoxylin and Eosin x10).
- Figure 4. High-power photomicrograph showing (A) vital tissue in the pulp chamber with (B) resorption of dentin by multinucleated cells located in lacunae; (C) blastic cells laying down osteoid (Hematoxylin and Eosin x130).
- Figure 5. High-power photomicrographs showing (E) fragments of epithelium; (CT) a portion of the connective tissue band and (T) surface of the tooth (Hematoxylin and Eosin x150).

## ABSTRACT

A case of a tooth traumatically displaced into the floor of the mouth which retained its vitality for fifteen years is reported. Although the presence of the tooth and soft tissue cuff which appeared to represent the original attached gingiva presented a source for complications, no significant pathological changes were noted. The requirement for a thorough radiographic examination before definitive treatment of maxillofacial injuries is emphasized.



The opinions expressed herein are those of the authors and are not to be construed as those of the Army Medical Department.

Request for reprints may be submitted to:

Colonel Emery A. Russell, Jr., DC  
Chief, Department of Oral Surgery  
US Army Institute of Dental Research  
Walter Reed Army Medical Center  
Washington, DC 20012



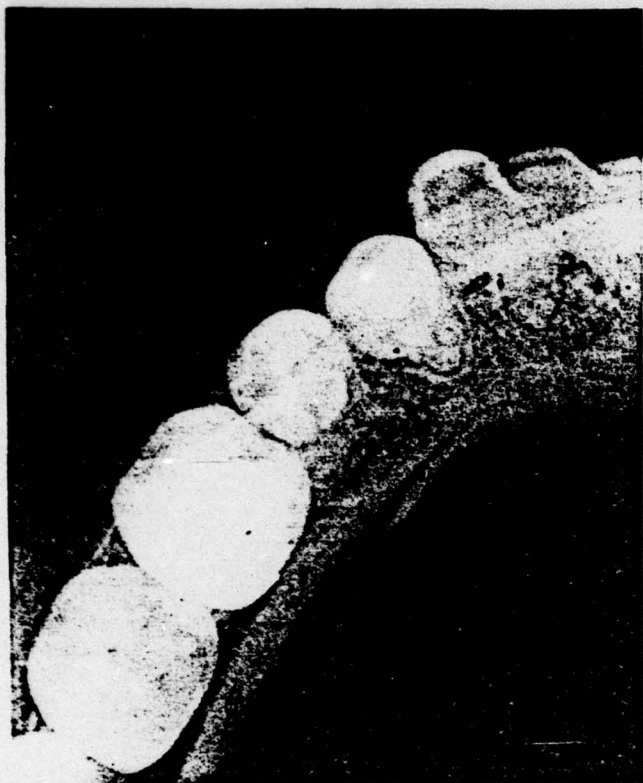


FIGURE 1

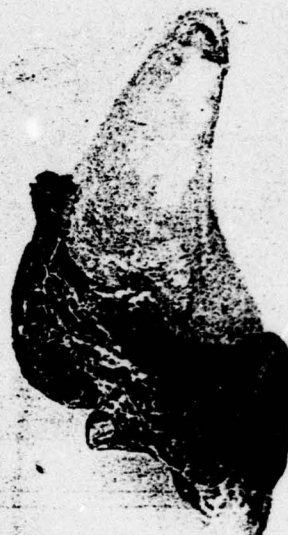

FIGURE 2




FIGURE 3



FIGURE 4

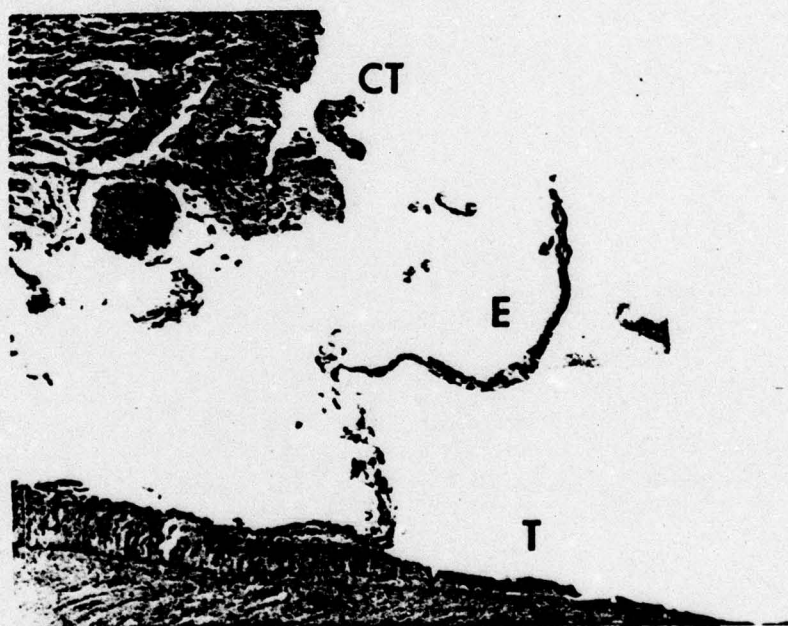


FIGURE 5