

ADA 064426

Special Report 78-6

LEVEL II

12

SELECTION AND PAIRING OF "NORMAL" RHESUS MONKEYS (*Macaca mulatta*) FOR RESEARCH


Matthew J. Kessler, James L. Kupper, James D. Grissett, and Richard J. Brown

DDC FILE COPY

DDC
RECEIVED
OCT 12 1978
C



November 1978



Approved for public release; distribution unlimited.

79 02 06 008

Approved for public release; distribution unlimited.

12

SELECTION AND PAIRING OF "NORMAL" RHESUS MONKEYS
(Macaca mulatta) FOR RESEARCH

Matthew J. Kessler, James L. Kupper, James D. Grissett, and Richard J. Brown

Naval Medical Research and Development Command

Approved by

Ashton Graybiel, M.D.
Assistant for Scientific Programs

Released by

Captain R. E. Mitchel, MC USN
Commanding Officer

8 November 1978

NAVAL AEROSPACE MEDICAL RESEARCH LABORATORY
NAVAL AIR STATION
PENSACOLA, FLORIDA 32508

(See 1472)

79 02 06 008

INTRODUCTION

The selection of a homogeneous population of experimental animals for research projects is a major responsibility of veterinarians supporting biomedical activities. Control and experimental subjects must be paired as closely as possible if minor effects of experimental protocols are to be successfully evaluated. A general outline is presented for the complete physical examination of rhesus monkeys preparatory to their selection for projects where uniform populations and pairs of animals are required. The same examination procedures can be modified as necessary to provide the laboratory animal veterinarian with a routine physical and laboratory examination procedure for use in the monkey colony.

PROCEDURE

A group of 120 rhesus monkeys (*Macaca mulatta*), initially purchased as a single shipment from another research facility, consisted of 61 female and 59 male monkeys of mixed ages and weights. Upon arrival at our laboratory, the animals were immediately placed into a quarantine holding area for 6 weeks. During that period, the monkeys were tested for tuberculosis by using 0.1cc Koch's Old Tuberculin* injected intrapalpebrally. The entire group was released from quarantine status after three negative intrapalpebral tuberculin tests over the 6-week period had been obtained. All monkeys were maintained on a diet of monkey chow** that was supplemented regularly with fresh oranges and apples.

The initial screening procedure involved an analysis of the hemogram, serum biochemistry values, and serum electrolyte values. Venipuncture was performed after completion of the quarantine. All monkeys were fasted for 17 hours and then given a restraint dosage of a neuroleptic-narcotic combination drug, fentanyl-droperidol***, at a dosage of 1 cc per 18.2 kg body weight intramuscularly (9). Blood samples were obtained from the femoral vein, placed in serum and heparinized test tubes, and then subjected to a battery of tests. Normal values for the hemogram, serum biochemistry, and serum electrolytes, determined in another study (6), are presented in Tables I, II, and III, respectively. Each monkey's values were compared with the range of "normal" values (mean \pm 2 standard deviations), and any monkey whose blood values were beyond the limits established as "normal" was eliminated from further consideration for the research project.

*Jen-Salsbery Laboratories, Kansas City, Missouri, 64141

**Purina Monkey Chow, Ralston Purina Co., St. Louis, Missouri.

***Innovar, McNeil Laboratories, For Washington, Pennsylvania.

Table I
Hematological Values for the NAMRL Rhesus Monkey Colony

	Males		Females	
	Mean	S.D.	Mean	S.D.
erythrocytes x 10 ⁶ /mm ³	5.25	0.46	5.00	0.39
hemoglobin gm%	15.10	1.10	14.60	1.00
hematocrit %	42.90	4.40	41.80	4.00
MCV microns ³	79.60	5.60	80.40	5.70
MCH picograms	29.40	1.10	26.70	1.40
MCHC %	38.30	2.40	32.80	1.80
leukocytes x 10 ³ /mm ³	7.60	5.20	8.30	5.70
lymphocytes/100 WBC	43.80	9.60	57.30	9.50
neutrophils/100 WBC	32.00	8.40	35.20	8.60
band cells/100 WBC	1.80	1.40	1.90	1.00
monocytes/100 WBC	0.56	0.79	0.59	0.87
eosinophils/100 WBC	2.30	2.20	2.20	1.80
basophils/100 WBC	0.49	0.73	0.39	0.71

Table II
Biochemical Values for the NAMRL Rhesus Monkey Colony

	Males		Females	
	Mean	S.D.	Mean	S.D.
total protein gm%	7.4	0.58	7.6	0.71
albumin gm%	4.2	0.38	4.0	0.40
cholesterol mg%	146.9	28.50	140.9	25.00
BUN mg%	23.5	4.4	22.8	4.70
glucose mg%	102.4	20.1	89.8	18.30
triglyceride mg%	57.7	18.8	56.2	12.10
SGOT I.U./liter	28.4	9.0	28.1	8.10
SGPT I.U./liter	25.9	8.0	24.4	9.70
LDH I.U./liter	348.1	214.7	364.0	177.30
CPK I.U./liter	159.8	133.3	164.7	95.00
albumin % total protein	61.5	4.7	60.5	6.20
globulins % total protein				
alpha	8.8	2.0	9.2	2.60
beta	17.9	3.3	17.0	3.70
gamma	11.0	4.4	13.3	5.20
lipoproteins % total lipoproteins				
alpha	64.1	3.0	64.3	1.00
pre-beta	10.6	6.9	10.1	7.70
beta	26.4	7.5	26.6	7.40

Table III
Serum Electrolyte Values for the NAMRL Rhesus Monkey Colony

mEq/L	Males		Females	
	Mean	S.D.	Mean	S.D.
calcium meq/liter	5.4	0.21	5.3	0.22
sodium meq/liter	147.2	3.80	147.5	5.10
potassium meq/liter	3.6	0.34	3.3	0.25

After venipuncture, the monkeys' ages were determined by dentition (3). They were also weighed at this time. Anthropometric determinations were made according to the procedure outlined in detail in a previous report from this laboratory (2), with slight modifications and abbreviations. Whole-body radiographs were taken while the monkeys were sedated, with the animals positioned for an anterior-posterior exposure. For most monkeys, diagnostic quality radiographs were obtained with 87 kvp, 300 ma, and 1/30 second exposure settings at a focal-film distance of 40 inches (101.6 cm). A bucky tray, rapid process x-ray film*, and high-speed cassettes** were used for all radiographs. The films were processed on an automatic processor***.

While the monkeys were still under the influence of the neuroleptic-analgesic drug, they were placed in acrylic restraint chairs and electrodes were attached for recording an electrocardiogram. Using an electrocardiograph****, each monkey's electrocardiogram was recorded for Leads I, II, III, aVR, aVL, and aVF at a paper speed of 25 mm per second. The specific techniques for obtaining the electrocardiograms and calculation of the various electrocardiographic parameters are reported elsewhere (5).

*DuPont Cronex-4, E.I. DuPont de Nemours & Co., Inc., Wilmington, Delaware.

**High Speed Radelin TF-2 cassettes, E.I. DuPont de Nemours & Co., Inc., Wilmington, Delaware

***Kodak M15 automatic processor, Eastman Kodak Co., Rochester, N. Y.

****Hewlett Packard electrocardiograph Model 1514A, Hewlett Packard, Kenner, Louisiana 70062.

A complete physical examination during which the monkeys remained in the acrylic restraint chairs followed their recovery from sedation. The examination consisted of the items listed in Table IV. The ophthalmological examination was done with a standard direct ophthalmoscope and 1% tropicamide solution*. The drops were instilled into each eye 10 to 15 minutes prior to ophthalmoscopic viewing of the ocular fundus in order to permit dilation of the pupils. The fecal samples were taken from each monkey for direct smears and fecal floatations for intestinal parasite ova. Fecal culture samples were obtained by rotating a sterile cotton swab in the rectum and directly smearing a MacConkey agar plate, and then placing the remainder of the sample in selenite broth for incubation.

RESULTS

Nineteen monkeys were disqualified from further consideration for a planned research project due to abnormal hematological, serum biochemical, or serum electrolyte values.

On the basis of electrocardiographic findings, 10 animals were deleted due to axis degree determinations exceeding the normal range. Eight of these monkeys had axis deviations suggestive of left ventricular hypertrophy, one of right ventricular hypertrophy, and one of biventricular hypertrophy. Normal values for the male and female groups (5) are presented in Table V. Medical or anatomical problems on physical examination resulted in the elimination of seven monkeys from further consideration. One animal had anisocoria, and one an abnormal-appearing optic disc on ophthalmoscopic examination. No other ocular abnormalities were noted. Problems considered severe enough to result in rejections included: severe gingivitis, severe traumatic injury and scarring of the tongue, surgical amputation of the arm, extensive ulceration of the cheek pouch and gingiva, chipped/broken teeth, abnormal optic disc, impacted teeth, testicular atrophy, and chronic diarrhea.

The fecal ova and parasite tests indicated that the overwhelming majority of monkeys were free of intestinal parasites. Each monkey had been treated at the previous research laboratory with a two-dose regimen of thiabendazole 300 mg per os. A few monkeys had been parasitized by *Trichuris*, *Oesophagostomum*, and *Strongyloides* species and were treated with 100 mg thiabendazole** per kg body weight per os twice at 2-week intervals. Fecal bacteriological cultures did not detect any *Salmonella* or *Shigella* carriers in the population.

The male monkeys ranged in age, as determined by dentition, from 24 to 54 months, with a mean age of 42.2 months (standard deviation \pm 5.8 months). The female monkeys ranged in age from 24 to 80 months, and their mean age was 50.1 months (standard deviation \pm 8.8 months).

*Alcon Laboratories, Inc., Fort Worth, TX 76134

**Equisole, Merck, and Co., Rahway, N. J. (280 mg Equisole - 100 mg thiabendazole)

Table IV
Routine Physical Exam

Tattoo Number _____ Date _____

Sex _____

Weight _____

Species _____

- _____ ECG
- _____ Blood Pressure
- _____ Ocular Motility
- _____ Pupillary Reflexes (Direct and Indirect)
- _____ Fascial Muscle Tone
- _____ Apply Mydriatic Agents to Dilate Eyes
- _____ Head, Face, Scalp, Neck
- _____ Mouth, Teeth, Throat
- _____ Nose, Nostrils
- _____ Ears, Ooscopic Exam
- _____ Upper Extremities/Hands
- _____ Palpate Abdomen (Liver, Spleen, Kidneys)
- _____ Lower Extremities/Feet
- _____ Auscultate Heart
- _____ Auscultate Lungs
- _____ Palpate Cervical, Axillary, Femoral Lymph Nodes, Femoral Pulse
- _____ Spine
- _____ Skin, Haircoat, Skin Hydration
- _____ Palmar Reflex
- _____ Patellar Tendon Reflex
- _____ Babinski Reflex (Plantar)
- _____ Superficial Abdominal Reflex
- _____ Auditory-Palpebral Reflex
- _____ Direct Ophthalmoscopy
- _____ Remove from Chair and Check for Hernia
- _____ Perineal Region (Anus, Genitals)
- _____ Locomotor Activity/Proprioception
- _____ Disposition/Character
- _____ Other (State) _____
- _____ Temperature _____
- _____ Fecal _____

Table V

Summary of Electrocardiographic Data for Maccaca mulatta*

	Heart Rate beats/min	P wave sec	P wave mV	P-R Interval sec	QRS Duration sec	R Wave mV	Q-T Interval sec	QRS Axis degree
Males (Mean 2 S. D.)	210 ± 50	.041 ± .012	2.15 ± 1.12	.078 ± .016	.039 ± .014	9.10 ± 10.80	.185 ± .050	65 ± 84
Females (Mean 2 S. D.)	216 ± 54	.044 ± .022	2.40 ± 1.42	.079 ± .022	.045 ± .028	9.93 ± 8.62	.189 ± .052	62 ± 61

*Data obtained under sedation with fentanyl-droperidol, 1 cc per 18.2 kg body weight given intramuscularly.

The males ranged in weight from 3.38 to 8.45 kg. The mean male weight was 5.01 kg (standard deviation \pm 1.2 kg). The female weights ranged from 3.13 kg to 6.99 kg. The mean female weight was 4.67 kg (standard deviation = 0.74 kg).

The whole-body radiographs revealed two medical problems and resulted in the rejection of eight monkeys. One monkey had a fractured clavicle and was eliminated due to concern for additional injury since the research selectees would be subjected to frequent handling and manipulation. The radiographs of seven other monkeys contained evidence of abdominal opacities. Lateral radiographs and additional anterior-posterior radiographs located the stationary opacities in the area of the gall bladder or the right kidney. To investigate this problem, the classical human cholecystographic technique and the intravenous pyelographic techniques were modified for use in rhesus monkeys. A review of the literature indicated that spontaneous cholelithiasis is rare in rhesus monkeys. Only one report was located (7).

To perform cholecystography, iopanoic acid* per os was used as the opacifying contrast media. The monkeys were fasted for 24 hours prior to the radiography. They were then administered ketamine** HCl intramuscularly at the dosage of 20 mg per kg, and atropine sulfate at the dosage of 0.02 mg per kg given subcutaneously to facilitate handling, placement of the nasogastric tube, and radiography. These seven monkeys ranged in weight from 4.20 kg to 5.18 kg, with a mean of 4.51 kg and a standard deviation of 0.36 kg. Since they all weighed approximately the same, an empirical dosage of 1 gram iopanoic acid was used for each animal. A plain radiograph was made of each monkey just prior to injection of the contrast media into the stomach. A french 8-gauge nasogastric tube was placed through one nare and into the stomach. One gram of iopanoic acid was crushed and mixed with 30 cc warm tap water in a 50-cc disposable syringe to obtain a suspension. The suspension was then slowly injected into the nasogastric tube while continuously swirling the liquid to keep the particles of the relatively insoluble iopanoic acid suspended. Anterior, posterior, and right lateral recumbent radiographs were obtained at times zero hours, 2 hours, 6 hours, 10 hours, and 20 hours post-iopanoic acid administration, using the same radiographic procedure previously described for the whole-body screening radiographs. In an attempt to visualize the biliary duct system, 15 cc of a cholecystokinetic emulsion*** were administered per os by syringe at approximately 16 hours post-iopanoic acid, and 20 minutes before radiographs were taken to visualize the ducts. This procedure was tried on one monkey and was only partially successful in causing contraction of the gall bladder and visualization of the duct system. Figures 1 and 2 show anterior-posterior radiographs of one monkey with a right abdominal opacity of unknown origin. The first radiograph (Figure 1) was taken before administration of iopanoic acid. The second radiograph (Figure 2) was obtained at 20 hours post-iopanoic acid ingestion. Figure 2 clearly shows the contrast media within the gall bladder and that the opacity of unknown origin is not within the gall bladder. Right lateral radiography showed that the opacity was located in the area of the right kidney; therefore, a technique of intravenous pyelography was developed to investigate our suspicions that these opacities were uroliths.

*Telepaque 500 mg tablets, Winthrop Laboratories, New York, N.Y. 10016.

**Ketalar, 10 mg/cc, Parke, Davis and Co., Detroit, Michigan 48232.

***G.B. - Prep emulsion, Gray Pharmaceuticals Co., Yonkers, N. Y. 10701



Figure 1. Anterior-posterior radiograph of rhesus monkey showing right abdominal opacity (arrow).



Figure 2. Anterior-posterior radiograph of rhesus monkey 20 hours post-iopanoic acid per os. Black arrows outline gall bladder. White arrow indicates position of right abdominal opacity.

The absence of reports or mention of spontaneous urolithiasis in the literature indicates that this entity is rare in rhesus monkeys. A case report of urolithiasis in one Macaca cyclopis monkey and a literature review were published in 1969 (8). To perform intravenous pyelography, we modified the human technique and dosage by trial and error, starting with a dosage regimen of contrast media solution extrapolated from the human pediatric dosage. Ketamine HCl and atropine sulfate were again used to facilitate handling, injection of the contrast agent, and radiographic techniques. Meglumine diatrizoate* injection U.S.P. was used as the contrast media. Seven and one-half cc of this solution were injected into the saphenous vein. The frequent adverse reaction, emesis, reported in humans also occurred in our monkeys. Anterior-posterior and right lateral recumbent radiographs were taken at times zero minutes, 30 seconds, 1 minute, 2 minutes, 4 minutes, and 6 minutes post-injection of the contrast solution. Figure 3 shows an anterior-posterior radiograph of a suspected urolith in the right kidney of one of the monkeys examined, taken at 6 minutes post-injection of the meglumine diatrizoate solution. Although these seven monkeys were otherwise normal, they were deleted from the general population of monkeys available for a research project to enable us to monitor their condition. After cholecystography and intravenous pyelography, cholelithiasis and urolithiasis were deleted as possible causes of the opacities. It is possible that these dense objects represented fragments from gun pellets. Adrenal mineralization also occurs in animals, including man, and this is another possible explanation for radioopacities in the supra renal area (1).

Four monkeys died of spontaneous ailments between the time of arrival and the start of the study. Monkey 603B was losing weight and in poor general condition on arrival. She was found dead in her cage one morning. Necropsy revealed typical signs of malnutrition, including absence of adipose tissue. The specific cause of death remains unknown because of the nonavailability of an assigned pathologist from 1973 until 1976. A second monkey was also found dead in its cage. Necropsy showed hydro-metra, pneumonia, and an almost complete gastric obstruction from the ingestion of pine wood fibers (4). The third fatality resulted from pulmonary emphysema, cause unknown. The fourth monkey that died had a generalized lymphadenopathy.

After the selection process outlined above was completed, 47 monkeys had been rejected for various single or multiple reasons, and 73 remained physically qualified for selection for a proposed research project. The monkeys then had to be paired by sex, weight, and age to become control or experimental group subjects. Whenever possible, temperament and general body conformity were used to further refine the final selection process. We sometimes found that animals which were approximately the same age by dentition were often extremely different in size and conformity; for example, the two females shown in Figure 4. Monkey 3Z7 weighed 11.1 kg and had just reached an age of 90 months while monkey 775B weighed 3.2 kg and was between the ages of 80 and 90 months. Another interesting point was that we would occasionally find a young monkey that was far larger and heavier than an older monkey. Figure 5 shows a male rhesus that weighed 9.7 kg and was 48 months of age compared with a male monkey that weighed 6.4 kg and was 90 months or older.

*Reno-M-60, E.R. Squibb & Sons, Inc., New York, N. Y. 10022.

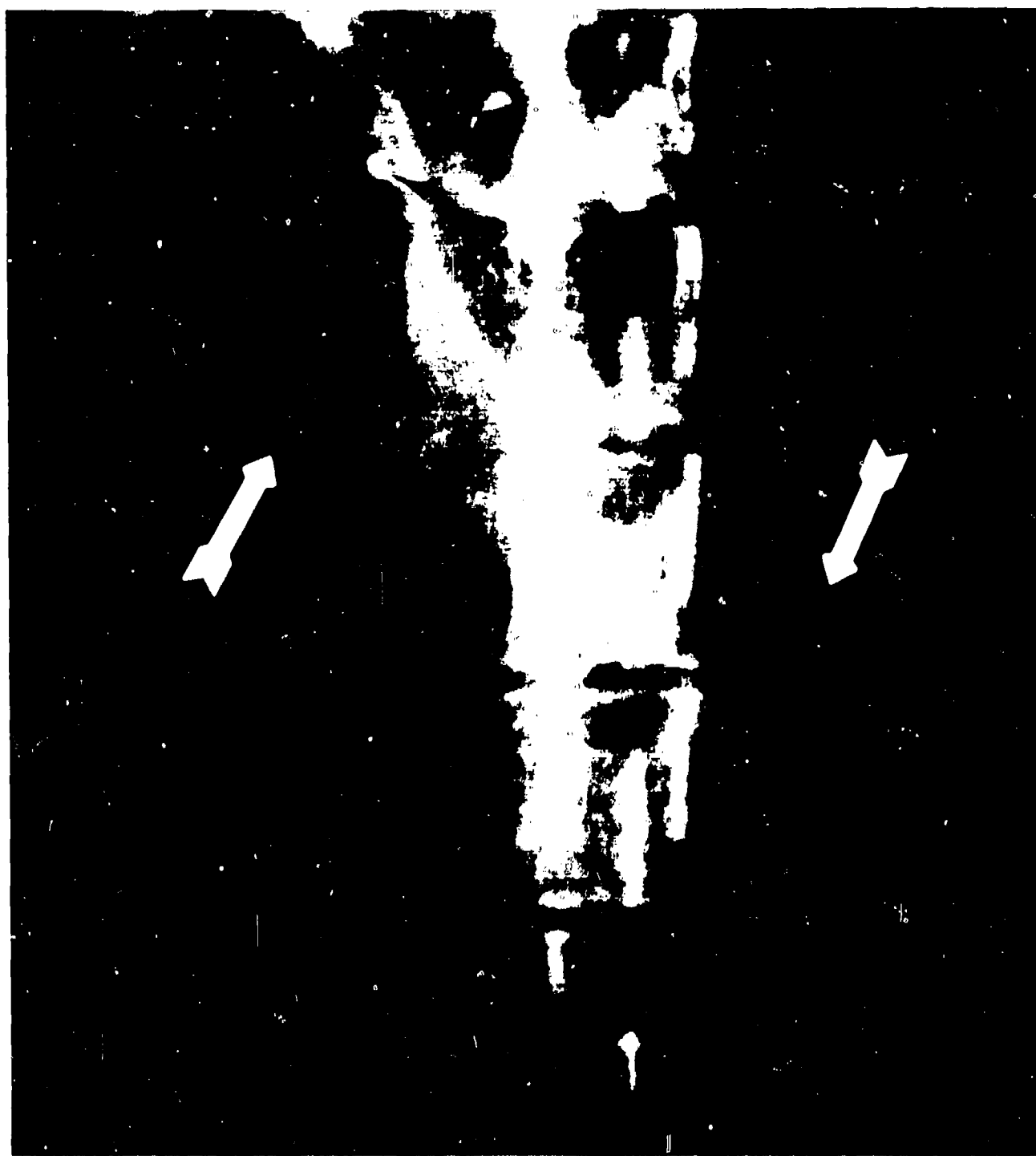


Figure 3. Anterior-posterior radiograph of rhesus monkey taken 6 minutes after intravenous injection of contrast media. White arrows indicate position of renal pelvis. Black arrow indicates right abdominal opacity.

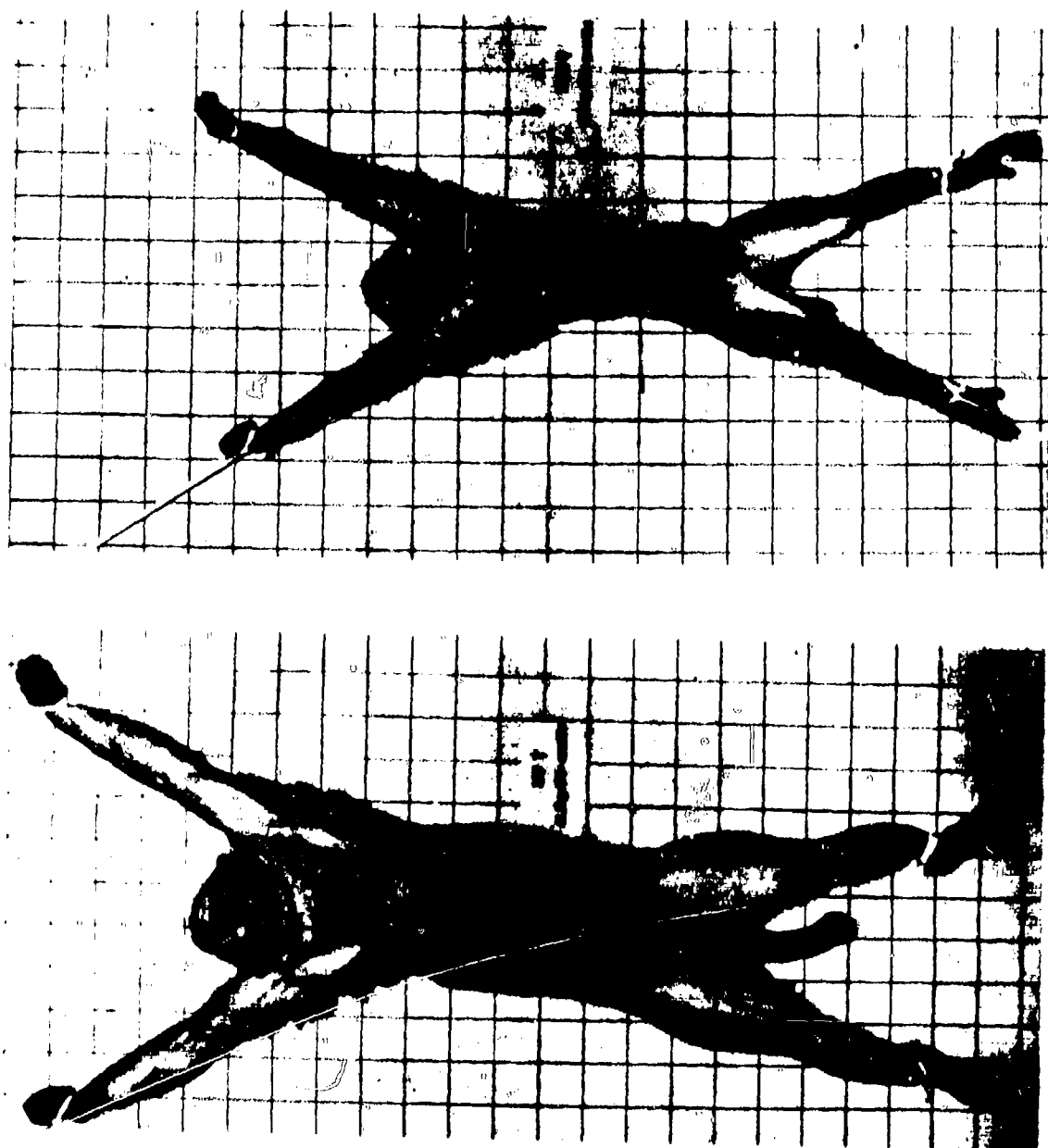


Figure 4. Two female monkeys of approximately the same age, but extremely different in size and conformity.

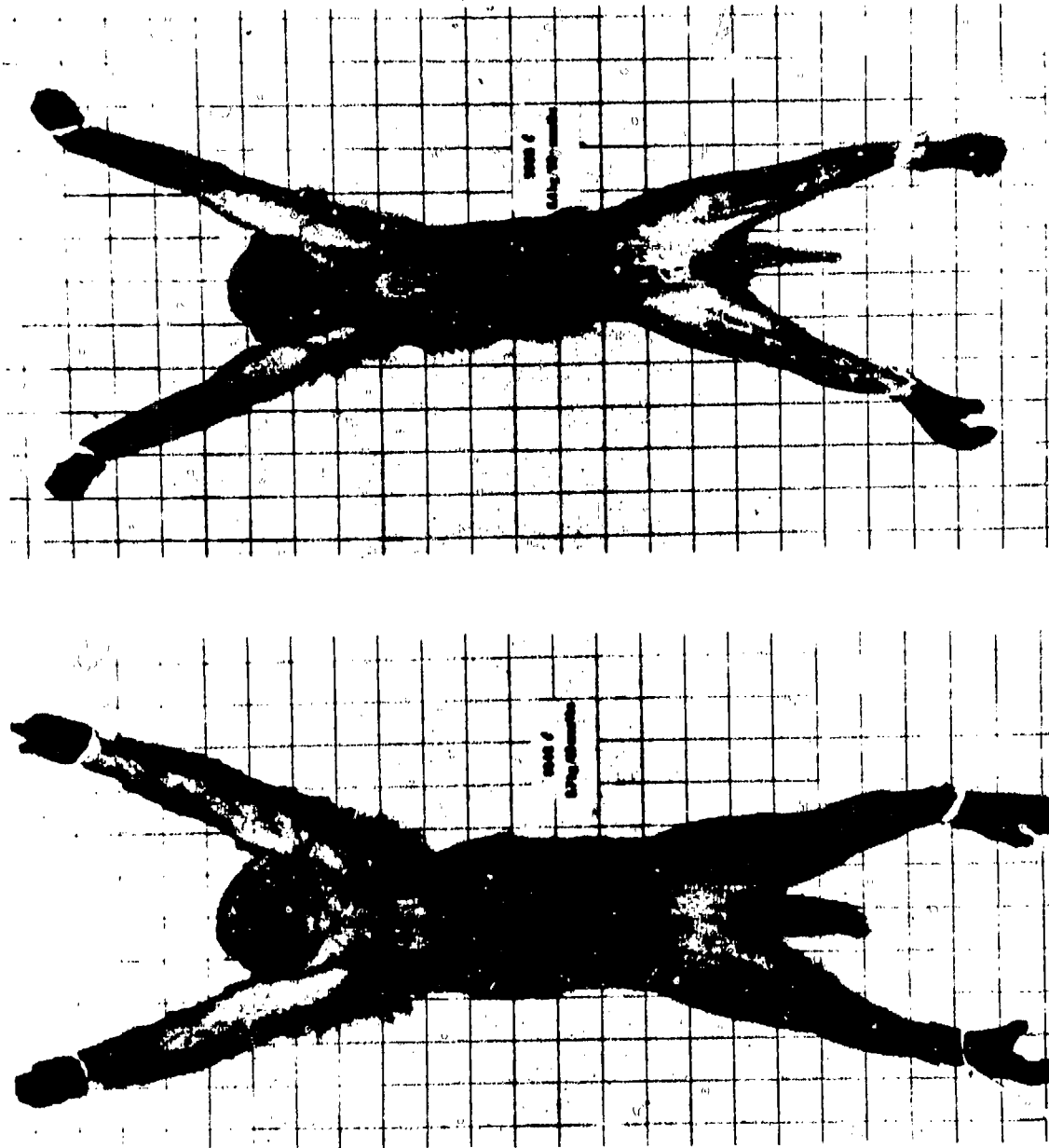


Figure 5. Male rhesus monkey weighing 9.7 kg and 48 months of age compared with a male rhesus monkey weighing 6.4 kg and was 90 months or older.

Of the 73 physically qualified monkeys, 32 pairs of animals were selected for a proposed project. The other monkeys could not be paired because of incompatibilities. Some monkeys were the same age, but not the same weight. Others were the same weight, but not the same age. Sometimes they were the same age and weight, but not of the same sex.

DISCUSSION

Of the original group of 120 rhesus monkeys, 47 (39.2%) were eliminated from consideration for a research project. Seven of the rejected monkeys had more than one abnormality. The 64 selected monkeys represented only 53.3% of the original group of animals, which was considerably below our expectations at the outset of the screening process. With the ever-increasing costs of purchasing and maintaining rhesus monkeys, and the recent complete embargo by the government of India, it will not be surprising if some minor compromises occur in selecting animals for future studies.

Selecting pairs of monkeys by sex, weight, and age fairly well defined the physical characteristics of our rhesus monkeys. Since some parameters measured in research experiments are age-dependent, such as hormone levels and reproductive capabilities, it is well advised to determine age by dentition when accurate birth records are not available. The method is fairly simple and uncomplicated, and accurate up to 80 to 90 months of age.

It has been shown that many possible selectees for a project are eliminated by careful analysis of the hemogram, serum chemistry, physical examination, electrocardiography, and total-body screening radiography.

We were very satisfied with the safe, predictable, short action of Ketamine HCl. It was more predictable than the fentanyl-droperidol combinations. Another advantage of the drug is that the monkeys retained the swallowing reflex. This was especially important when emesis occurred during intravenous pyelography using meglumine diatrizoate. It also enabled us to place a nasogastric tube easily into the monkeys without much fear of it going into the trachea.

REFERENCES

1. Brown, R. J., and Robinson, F. R., Osseous metaplasia in the adrenal cortex of a two-toed sloth. J. Wildlife Dis., 7:46-48, 1971.
2. Clark, K. A., and New, A. E., Anthropometric determinations of American born Macaca mulatta. NAMI-1078. Pensacola, FL: Naval Aerospace Medical Institute, 1969.
3. Hartman, C. G., and Straus, W. L., Jr., (Eds), The Anatomy of the Rhesus Monkey (Macaca mulatta). New York: Hafner Publishing Co., 1933. Pp 21 and 23.
4. Kessler, M. J., and Kupper, J. L., Obstructive gastric foreign body in a rhesus monkey (Macaca mulatta). Lab. Anim. Sc., 26:619-621, 1976.
5. Kupper, J. L., Kessler, M. J., and Clayton, J. D., Establishment of normal electro-cardiographic values for rhesus monkeys (Macaca mulatta) under sedated and unsedated conditions. NAMRL-1226. Pensacola, FL: Naval Aerospace Medical Research Laboratory, 1976.
6. Kupper, J. L., Kessler, M. J., and Cook, L. L., Establishment of normal hematological, biochemical, and serum electrolyte values for a colony of rhesus monkeys (Macaca mulatta). NAMRL 1230. Pensacola, FL: Naval Aerospace Medical Research Laboratory, 1976.
7. Martin, D. E., Wolf, R. C., and Houser, W. D., Naturally occurring cholelithiasis in a rhesus monkey and its effects on plasma and biliary lipid concentrations. Am. J. Vet. Res., 34:971-974, 1973.
8. Pryor, W. H., Jr., Chang, C. P., and Raulston, G. L., Urolithiasis in a Taiwan monkey (Macaca cyclopis). A literature review and case report. Lab. Anim. Care, 19:862-865, 1969.
9. Stunkard, J. A., and Miller, J. C., An outline guide to general anesthesia in exotic species. Vet. Med./Sm. Anim. Clin., September 1974, Pp 1181-1186.

Unclassified

SECURITY CLASSIFICATION OF THIS PAGE (When Data Entered)

REPORT DOCUMENTATION PAGE		READ INSTRUCTIONS BEFORE COMPLETING FORM
1. REPORT NUMBER Special Report 78-6	2. GOVT ACCESSION NO.	3. RECIPIENT'S CATALOG NUMBER (14) NAMRL-SR-78-6
4. TITLE (and Subtitle) Selection and pairing of normal rhesus monkeys (Macaca mulatta) for research,		5. TYPE OF REPORT & PERIOD COVERED (9) Special rept.
7. AUTHOR(s) (10) Matthew J. Kessler, James L. Kupper, LTCOL, USAF, James D. Grissett, Richard J. Brown, LTCOL, USAF, VC		6. PERFORMING ORG. REPORT NUMBER
9. PERFORMING ORGANIZATION NAME AND ADDRESS Naval Aerospace Medical Research Laboratory Naval Air Station Pensacola, Florida 32508		8. CONTRACT OR GRANT NUMBER(s)
11. CONTROLLING OFFICE NAME AND ADDRESS Naval Medical Research and Development Command National Naval Medical Center Bethesda, Maryland 20014		10. PROGRAM ELEMENT, PROJECT, TASK AREA & WORK UNIT NUMBERS
14. MONITORING AGENCY NAME & ADDRESS (if different from Controlling Office)		12. REPORT DATE (11) 8 Nov 1978
		13. NUMBER OF PAGES 12 21p.
		15. SECURITY CLASS. (of this report)
		15a. DECLASSIFICATION/DOWNGRADING SCHEDULE
16. DISTRIBUTION STATEMENT (of this Report) Approved for public release; distribution unlimited.		
17. DISTRIBUTION STATEMENT (of the abstract entered in Block 20, if different from Report)		
18. SUPPLEMENTARY NOTES Macaca mulatta		
19. KEY WORDS (Continue on reverse side if necessary and identify by block number) Macaca mulatta Rhesus monkey Veterinary pathology Laboratory animals		
20. ABSTRACT (Continue on reverse side if necessary and identify by block number) To select a homogeneous population of experimental nonhuman primates for research projects a selection process has been developed by the authors to insure investigators that animal subjects used in their experiments will accurately reflect biological changes associated with the project design. The procedure involved the following: complete physical examination; complete hemogram, serum electrolytes, serum biochemistry, body weight, and anthropometric determinations; aging by dentition; electrocardiography; total-body radiography; fecal culture; fecal ova, and parasite examinations; and examination of		

DD FORM 1473 1 JAN 73

EDITION OF 1 NOV 68 IS OBSOLETE
5/N 0102-014-6601

Unclassified

SECURITY CLASSIFICATION OF THIS PAGE (When Data Entered)

406061

[Handwritten signature]

Unclassified

SECURITY CLASSIFICATION OF THIS PAGE(When Data Entered)

other conditions. Arithmetic means and standard deviations were calculated and used to eliminate monkeys whose values varied from the mean by more than two standard deviations. On the basis of the selection criteria, 47 of the original 120 monkeys in the group were deleted due to abnormalities, severe illness, disability, or death. Also described are: the methods and techniques used to select paired rhesus monkeys on the basis of normal values established for the population from which they were derived, the reasons for rejecting subjects, and some observations and experiences of the authors. Specific techniques for cholecystography and intravenous pyelography in rhesus monkeys using radio-opaque contrast media have been detailed.

Unclassified

SECURITY CLASSIFICATION OF THIS PAGE(When Data Entered)