

U.S. DEPARTMENT OF COMMERCE
National Technical Information Service

AD-A036 168

RADIATION-INDUCED CENTRAL NERVOUS SYSTEM
DEATH - A STUDY OF THE PATHOLOGIC FINDINGS
IN MONKEYS IRRADIATED WITH MASSIVE DOSES
OF COBALT-60 (GAMMA) RADIATION

SCHOOL OF AVIATION MEDICINE
RANDOLPH AIR FORCE BASE, TEXAS

APRIL 1959

ADA 036 168

0

ADVANCED TECHNOLOGICAL SERVICES
SYSTEMS

Advanced Technological Services, Inc.
1000 North 17th Street, Suite 100
Ft. Worth, Texas 76102

REPRODUCED BY
NATIONAL TECHNICAL
INFORMATION SERVICE
DEPARTMENT OF COMMERCE

DDC
REF ID: A61111
FEB 23 1977
REUTERS

DISTRIBUTION STATEMENT A
Approved for public release
Distribution unlimited

RADIATION-INDUCED CENTRAL NERVOUS SYSTEM DEATH

**A Study of the Pathologic Findings in Monkeys Irradiated with
Massive Doses of Cobalt-60 (Gamma) Radiation**

STEPHEN G. WILSON, Jr., Captain, USAF (MC)

Department of Radiobiology

59-58

**Air University
SCHOOL OF AVIATION MEDICINE, USAF
Randolph AFB, Texas
April 1959**

RADIATION-INDUCED CENTRAL NERVOUS SYSTEM DEATH

A Study of the Pathologic Findings in Monkeys Irradiated with Massive Doses of Cobalt-60 (Gamma) Radiation

The pathologic alterations produced in the central nervous system of *Macaca mulatta* monkeys by doses of ionizing radiation exceeding 10,000 r have been described in detail in the literature. This study reveals the pathologic changes occurring in the remaining viscera of such animals; until now, such a description has not appeared in the open literature.

Whereas other authors have emphasized the changes found in the brain and pituitary, this report presents circumstantial evidence indicating that gastrointestinal damage is also an important part of the syndrome of "radiation-induced central nervous system death." Also, the observed central nervous system changes are compared to those described by other authors. The concept of "leukocyte devitalization" is introduced.

Prior to 1945 there existed in the literature scattered descriptions of three distinct modes of radiation death which become apparent at rather specific dose levels. It remained for Quastler (1) in 1945 to demonstrate the continuity of the pathologic panorama and to point out the series of steplike plateaus in any dose versus survival time curve that covered an adequate dose range. Subsequently, this phenomenon has been repeatedly confirmed by experiments utilizing many species of animals. Many investigations, both biochemical and histologic, have been made in an effort to elucidate the mechanism of death represented by each of the plateaus. The modes of death have often been designated as central nervous system, gastrointestinal, and hematopoietic (2).

There is often considerable species variation in reaction to radiation at a given level. Hence, the innumerable varieties of experimental subjects employed by the multitude of individual investigators have often led to widespread confusion concerning the implications of the various descriptive terms applied to the three classical modes of radiation death. This paper represents a portion of the effort being made at this laboratory to define these various pathologic conditions as they occur in the monkey.

Received for publication on 18 December 1958.

This work was accomplished at the Radiobiological Laboratory of the University of Texas and the United States Air Force, Austin, Tex.

While radiation-induced central nervous system death has been variously defined in the literature, at this laboratory the concept has generally been accepted that it constitutes those instances in which symptoms of central nervous system damage are produced by ionizing radiation and persist until death (3). Other observers have emphasized the changes occurring in the brain and pituitary and have presented only brief statements regarding the general pathologic features found in such animals (4, 5). In this presentation, more attention is focused on the lesions occurring simultaneously in the remaining viscera, particularly the gastrointestinal tract. Descriptions of the histopathology of the central nervous system lesions are kept brief, but their incidence and temporal pattern are compared with similar material reported by others (4, 5). Data yielded by this comparison suggest that with massive doses of radiation circulating leukocytes may be "devitalized." The physical and clinical data are presented in more complete form in a separate publication (3).

MATERIAL AND METHODS

Ninety-nine immature monkeys (*Macaca mulatta*) weighing from 5 to 8 pounds each had been obtained from India eighteen months prior to the experimental procedure. They had been maintained under close veterinary supervision and were regarded as being free from disease (6).

Thirty-two cobalt-60 sources rated at 237 curies each were distributed evenly over a spherical wire frame (fig. 1). Radiation measurements were made primarily with the Air Force one-phase chemical dosimeter (7). The actual technics of the dosimetry are reported in more detail in a separate publication (3). In brief, by actual measurement, the source was found to deliver 803 r per minute at the center of the sphere with less than 5 percent variation throughout the cylindrical plastic exposure chamber (8 by 15 in.).

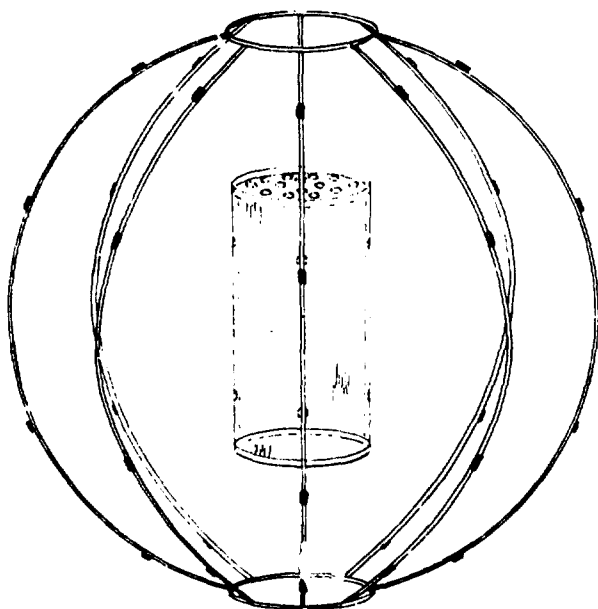


FIGURE 1

Thirty-two Co⁶⁰ sources were distributed evenly over the spherical wire frame which was 36 inches in diameter. The dose rate at the center of the sphere was 803 r per minute. There was less than 5 percent variation throughout the plastic cylindrical exposure chamber.

The monkeys were divided into groups of 5 to 8 animals each and irradiated with whole-body gamma radiation ranging from 400 to 40,000 r. Each monkey was irradiated separately and observed continuously during exposure. Following irradiation the monkeys were placed in individual cages and kept under constant

surveillance. Autopsy was performed immediately after death.

The necropsy procedure was designed so that a postmortem examination could be completed within 20 to 25 minutes. All water required in the autopsy was made isotonic with sodium chloride. The brain was removed first. It was cut into multiple slices and immediately placed in 10 percent formalin. Small wedges of each organ were fixed in Bouin's solutions for 18 to 24 hours and thereafter transferred to 70 percent ethyl alcohol. The remaining portions of the viscera were cut into slices (4 to 8 mm. thick) and preserved in neutral, phosphate-buffered 10 percent formalin.

The microscopic material was first evaluated without exact knowledge of the total dose of radiation administered to the animal or the number of hours the animal survived. In addition, a second set of blocks was taken from the cerebrum and cerebellum. These were given code numbers known only to the technician. The various lesions were then graded 1 to 4 with regard to severity. The grading in each animal was accomplished in the following manner: Identical sets of slides from every animal were examined. These consisted of samples of the frontal lobes, the occipital lobes, a coronal section through the entire brain at the level of the postcentral gyrus, and a longitudinal section through the center of the pons to include the full thickness of the cerebellum. The following criteria were used to determine the numerical category into which each animal fell: (1) the percentage of vessels involved by the inflammatory infiltrate in all of the sections; (2) the density of the inflammatory reaction in each of the involved vessels; and (3) the degree of meningeal inflammation in the meninges as a whole. After an initial survey of the material, the most severe case of meningitis and vasculitis was selected and empirically designated grade 4. Similarly, the mildest case was assigned grade 1. Two cases of intermediate severity were then categorized as grades 2 and 3, the numerical values denoting their relative severity with regard to grades 1 and 4, respectively. The conclusions drawn from the coded slides did not differ significantly from those yielded by the "known slides."

RESULTS

The dose versus survival time curve (fig. 2) strikingly resembles that demonstrated by Quastler's studies on roentgen death in mice. Attention here is focused on the 20 animals dying during the first 54 hours postirradiation as they were the only ones fulfilling the stated criteria of central nervous system death.

CLINICAL OBSERVATIONS

The clinical picture was extremely uniform. By the time the animal had received 3,000 r, there was a brief, transient period of hyperirritability and scratching movements. Subsequently there was progressive, severe debilitation. Several animals became comatose. One-third of them had excessive salivation, vomiting, or diarrhea during irradiation. After being removed from the confines of the plastic cylinder, the animals exhibited marked opisthotonos, ataxia, and convulsions. Severe watery diarrhea was frequent. These various signs persisted and progressed until death. Terminally there was often a prolonged period of complete prostration with gasping respiration extending over a period of 1 or 2 hours.

GROSS AUTOPSY FINDINGS

Since death was so rapid, it might be expected that gross pathologic changes would be infrequent and minor. Indeed, at the time of autopsy, this appeared to be the case. As the changes were viewed in retrospect, however, their significance became more obvious.

Pulmonary edema and serous pleural effusions were frequent (table I). These two pathologic features were closely associated with the microscopic finding of adventitial edema of the pulmonary vessels. Not infrequently, adipose tissue and other connective tissue in the body cavities had a semitranslucent appearance caused by accumulation of excess interstitial fluid.

In 3 animals there were focal areas of mucosal congestion in the stomach, small intestine, and colon. The most remarkable find-

ing in the gastrointestinal tract, however, was the almost complete absence of solid material from the bowel lumen. Instead, the stomach, colon, and segments of the small intestine were moderately distended by clear, watery fluid.

Cerebral edema was difficult to appreciate, and there were no pressure cones. In every animal, however, there were varying degrees of meningeal congestion, and rare meningeal petechiae were seen. Commonly, there was widespread extravasation of erythrocytes into the perivascular spaces.

MICROSCOPIC OBSERVATIONS

Changes in the brain and other viscera occurred regularly. Haymaker et al. (4) and Vogel et al. (5) have given excellent histopathologic descriptions of the central nervous system changes observed in similar experiments. Five basic lesions observed were: pyknosis of granule cells of the cerebellum; pyknosis of pituitary basophils; cerebral vasculitis, focal meningitis, and choroid plexitis. These descriptive diagnostic terms are used in the same context in the current report as employed by Haymaker and Vogel.

Pyknosis of cerebellar granule cells

Often the nuclei were shrunken to one-half their normal size. In most cases it appeared that one-third to one-half of the granule cells were affected. Damage was most pronounced in the inner half of the granular cell layer and in the immediate region of the fourth ventricle (fig. 3). In severe cases, however, 80 to 90 percent of all the granule cells in all portions of the cerebellum were pyknotic. Frank nuclear fragmentation was rare. Usually the nuclear membranes of affected cells had smooth contours. As nuclear pyknosis progressed, there appeared to be a decrease in cellularity in the granular layer. However, this "apparent" decreased cellularity was most likely due to a decreased nuclear size as contrasted to a "true" decreased cellularity resulting from nuclear destruction. This is in accord with the accepted view that radiation damage to granular cells, in the doses employed, is transitory in nature (4, 5, 8).

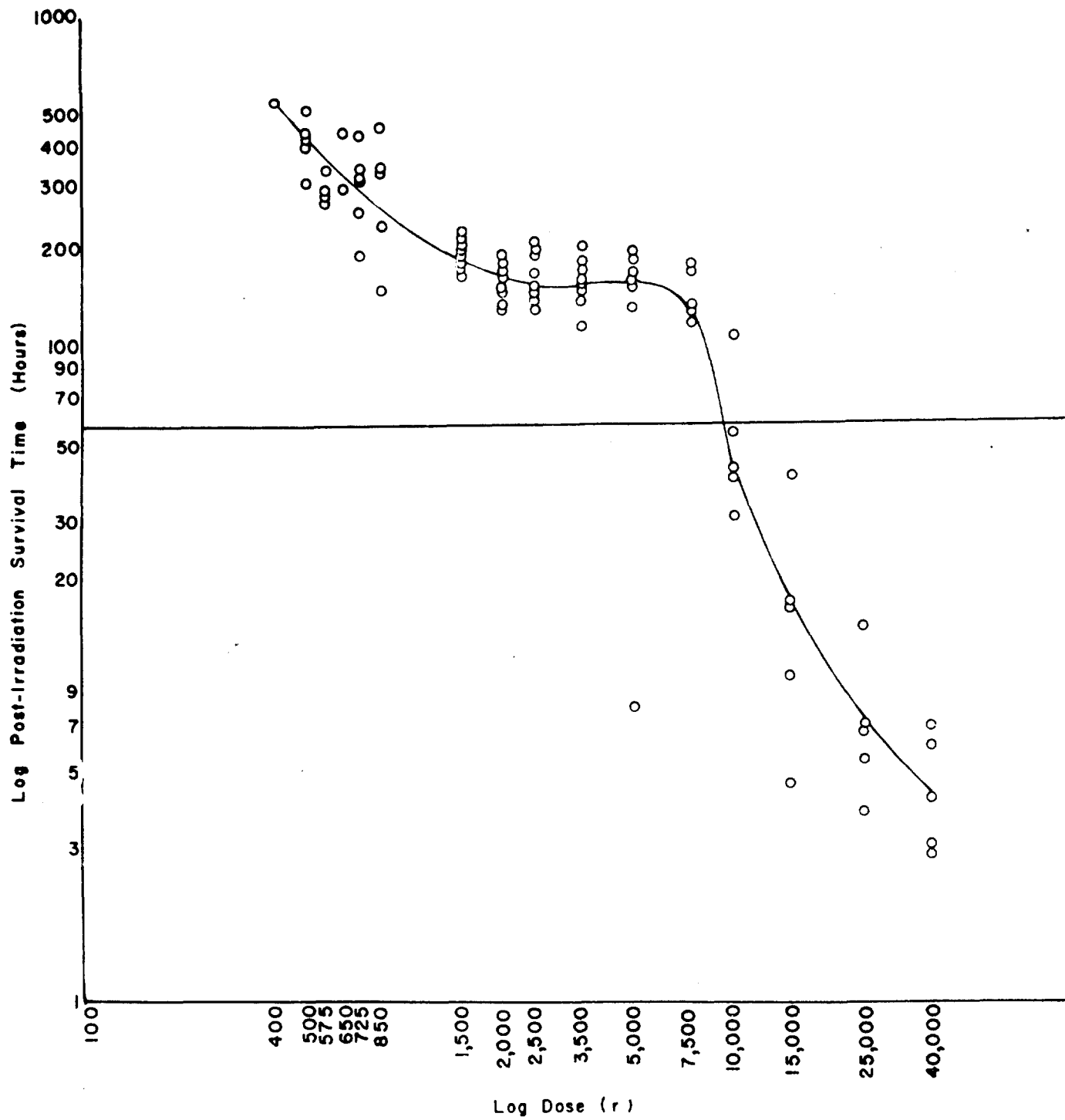


FIGURE 2

The dose versus survival time curve is quite similar to those seen in other species of animals. The animals discussed in the current paper are those below the horizontal line placed at the 54-hour mark.

TABLE I

Relative severity of pulmonary lesions

	Animal No.																			
	2	4	6	1	10	8	5	9	13	7	3	12	11	14	15	16	18	17	19	20
Adventitial vascular edema			4		4	4		4	1	2	4	1	4	2	1		2		3	
Pleural effusions			4		3					2		3	1	2					2	
Pulmonary edema			4		3	3				3				4	1	2				

The lesions occurring in the lungs are graded 1 to 4 depending on their relative severity. The distribution of the lesions suggests that these three findings are closely related as far as pathogenesis is concerned. The edema of the vascular adventitia is thought to be due to direct vascular damage and is regarded as the initiating factor in the other two lesions.

Pyknosis of pituitary basophils

When there were morphologic changes in the cerebellar granule cells, there was also nuclear pyknosis of the pituitary basophils. The latter did not occur in the absence of the former, and the two types of changes were parallel with regard to severity. The individual basophil nuclei exhibited more severe pyknosis than the cerebellar granule cells. Their outlines were often distorted (fig. 4). It was difficult to determine whether basophils permanently disappeared. However, the work of other investigators suggests that this phenomenon is also transitory (4, 5).

Cerebral vasculitis

Inflammation of the intracranial vessels appeared in two forms. In the earliest animals to die, the larger veins in the superficial portions of the sulci were the most severely affected (fig. 5). Segmented neutrophils were present in all portions of the vessel walls. At times they were observed infiltrating the adventitia of adjacent arteries in such a fashion as to indicate that their primary origin was from the neighboring veins. At this stage, there was practically no involvement of the small vessels permeating the grey and white matter.

On the second and third day, the pattern almost completely reversed itself. There was extensive infiltration of Virchow-Robbins spaces by segmented neutrophils (fig. 6). In addition, the small vessels of the grey matter and white matter, particularly paraventricularly, were often severely involved. However, the

larger vessels of the leptomeninges were never completely spared. At this stage the vessels deep in the sulci were more frequently affected than those in the superficial meninges.




FIGURE 3

A typical case of granule cell pyknosis. The cells along the inner aspect of the cerebellar folia are most severely affected. There is no nuclear fragmentation. From animal dying 65 hours after irradiation with 25,000 r of gamma. X100.

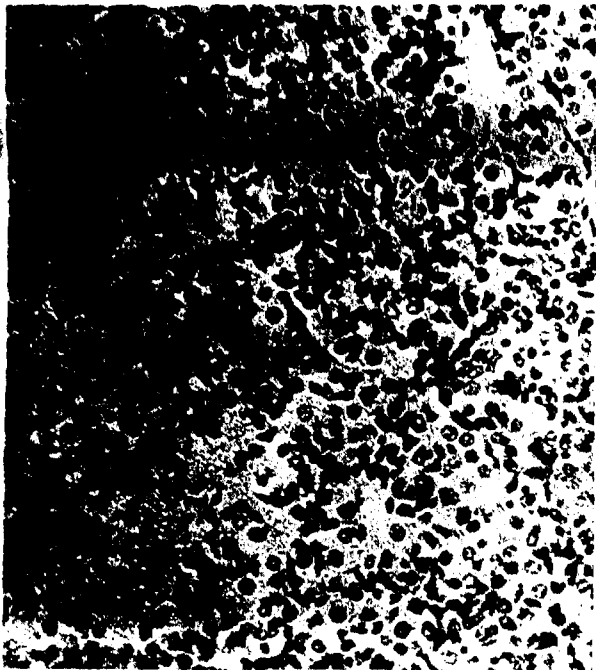

FIGURE 4

Nuclear pyknosis of pituitary basophils. From animal dying 5.5 hours after irradiation with 40,000 r. X320.

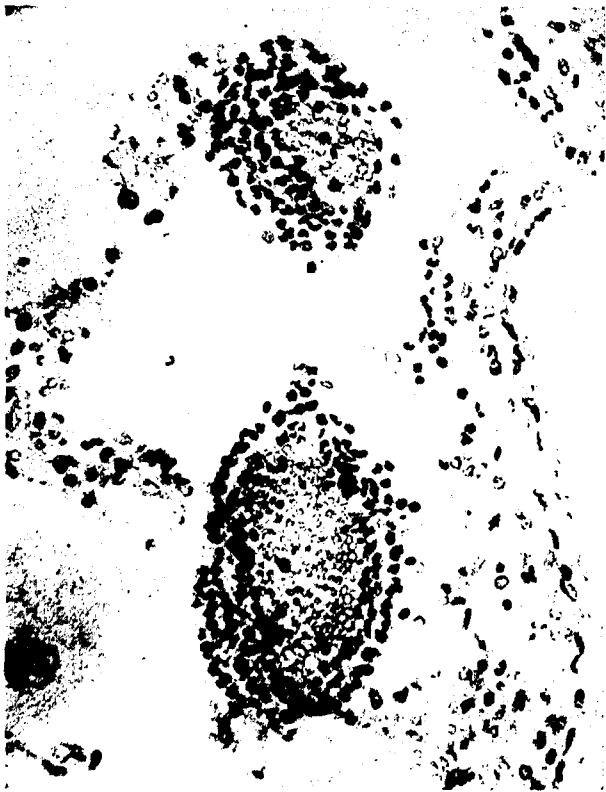

FIGURE 5

Heavy neutrophil infiltration of superficial meningeal vessels. A pattern that was frequent during the first 24 hours postirradiation. This animal expired 15 hours after receiving 15,000 r. X100.

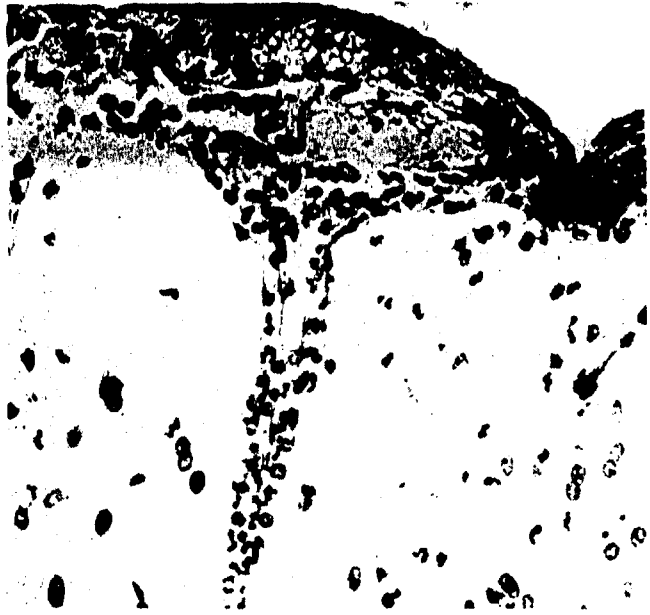

FIGURE 6

There is extensive neutrophilic infiltration of the meninges with extension into Virchow-Robbins spaces; a pattern of inflammation common on the second and third day postirradiation. Note that there are scattered neutrophils in the grey matter. X200.

Meningitis

Focal collections of segmented neutrophils were scattered throughout the leptomeninges. In every instance but one, when acute focal meningitis was present, there was also demonstrable inflammation of the meningeal vessels. It is interesting to note that meningitis became more severe as involvement of the small vessels of the white matter progressed.

Choroid plexitis

Inflammation of the choroid plexus was also present in those animals exhibiting meningitis and vasculitis. It was characterized by neutrophils infiltrating the edematous stroma supporting the choroid epithelium. In only a rare case was there frank erosion of the epithelial cells, and it was always associated with severe neutrophil infiltration (fig. 7).

There were striking microscopic abnormalities in practically every portion of the gastrointestinal tract. Although the severity of the damage varied from one segment of the gut to another, it was basically the same in every portion of the system.

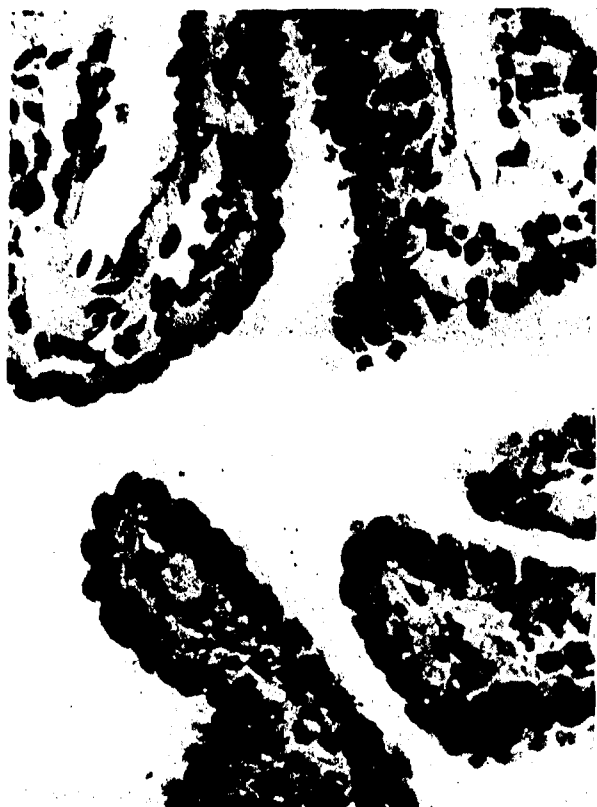

FIGURE 7

Choroid plexus of animal dying 58 hours after irradiation with 10,000 r of gamma. The edematous stroma is heavily infiltrated by neutrophils. $\times 320$.

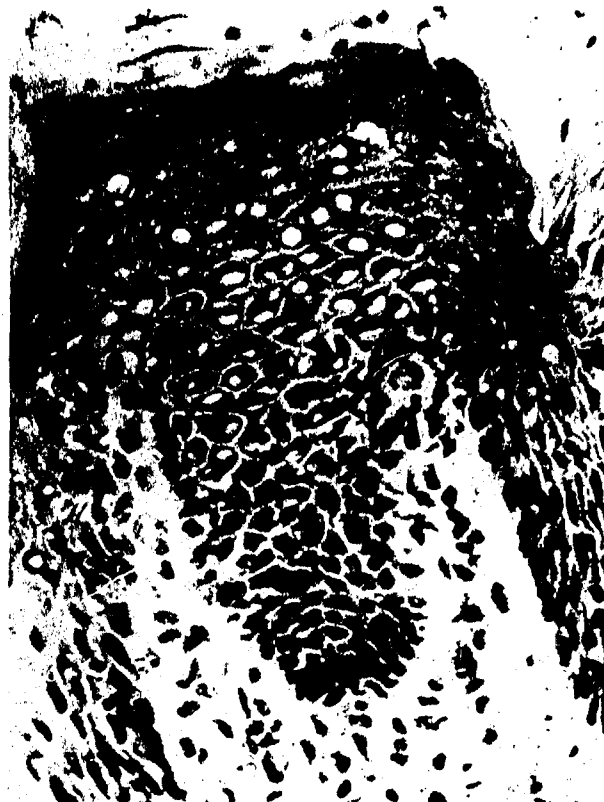

FIGURE 8

A segment of the nuclear vacuolization observed in the epithelium of the tongue. There are scattered degenerating cells in the basal layers, and there are a few monocytes in the subjacent stroma. From animals receiving 5,000 r and dying 6.7 hours postirradiation. $\times 320$.

Tongue

Three definite abnormalities occurring with regularity in the mucosa were: (1) intranuclear vacuolization; (2) necrobiosis of basal cells with accumulation of chromatin dust in the stratum germinativum; and (3) mononuclear infiltration of the connective tissue and squamous epithelium. In the typical case there was mild to moderate hydropic degeneration of epithelial nuclei. Usually only short segments of epithelial cells were involved, but the involved segments were spread over a wide area. Nuclear dropsy was generally accompanied by mononuclear infiltration of the squamous epithelium. In 75 percent of the animals dying on the first and second day, there were increased amounts of chromatin dust in the basal layers of the epithelium. Scattered nuclei were undergoing karyorrhexis (fig. 8).

Esophagus

Changes were less pronounced and less varied in the esophagus as compared to the tongue. The only consistent finding was increased chromatin dust and basal cell necrobiosis similar to that described in the mucosa of the tongue. These abnormalities were observed in the first 16 animals only. Generally they were accompanied by mild nuclear enlargement of the epithelial cells and mild increase in nucleolar size.

Stomach

By far the most conspicuous change in the stomach was parietal cell degeneration. It was extremely prevalent, occurring in 15 of 20 monkeys, and was most pronounced in the upper halves of the gastric glands. Typically

there was severe nuclear pyknosis and extreme cytoplasmic eosinophilia. Desquamated parietal cells often filled the glandular lumina. Accompanying the cellular degeneration was mild to moderate dilation of the affected portion of the gland. In most instances the basilar halves of the gastric glands were spared (fig. 9).



FIGURE 9

Section of gastric mucosa from stomach of animal dying 2.8 hours postirradiation with 40,000 r of gamma. The nuclei of the parietal cells are markedly pyknotic. Cytoplasmic eosinophilia was pronounced. $\times 300$.

Chief cell degeneration has been described as a prominent feature of radiation damage in other species (9). In only 4 of 20 monkeys, however, were there morphologic changes. In 2 animals there was widespread necrobiosis of chief cells. In one of these the parietal cells were histologically intact. In 2 other animals the cytoplasm of the chief cells was decreased in amount and had lost its reticulated appearance. The mucous cells lining the stomach and the predominantly mucous glands of the fundic and prepyloric regions were devoid of any morphologic alterations.

Small intestine

The four most consistent alterations in the small intestine were: (1) absence of mitotic figures; (2) mild nuclear atypism; (3) necrobiosis of epithelial cells; and (4) increased amounts of chromatin dust in the basilar portions of the intestinal glands. In the majority of cases the duodenum, jejunum, and ileum appeared to be equally affected. Rarely one portion would be more severely damaged than the others. This was most often true of the ileum. The degree of difference was slight, however, and in several instances the duodenum and jejunum appeared more susceptible than the ileum. Nuclear changes consisted of slight nuclear enlargement and increased prominence of nucleoli. Chromatin was clumped along the nuclear membrane. The cells in the basilar portions of the glands were most severely affected, but the Paneth cells appeared to be spared (fig. 10).




FIGURE 10

Crypt of small intestinal gland of animal dying 14 hours postirradiation with 25,000 r. Note the severe nuclear fragmentation. $\times 900$.

In one animal there was a striking difference in the degree of damage to different segments of the small intestine. In the nineteenth animal dying 41 hours postirradiation there was much more severe atypism in the ileum than in the jejunum.

Probably the most consistent abnormality in the small intestine was increased chromatin dust in the basilar portions of the glands. As a general rule it was quite meager, but in several instances was extremely heavy. Where there was a marked increase in chromatin dust, karyorrhexis of individual nuclei was conspicuous. Brunner's glands appeared normal in most cases except for mild dilatation of the glandular lumina.

Six of the last 7 animals to die exhibited return of mitotic activity in the intestinal epithelium. There were mitoses in one other animal that died at the 7-hour mark, but this was the one animal that received 5,000 r. In animals 1 and 5 the tips of scattered villi were devoid of epithelial cells (fig. 11). The same was true of animals 8, 9, 10, 12, and 16. In the remaining animals the villi were completely covered by epithelial cells (fig. 12).

Large intestine

The changes in the colon largely paralleled those in the ileum, but were generally slightly more severe. Necrobiosis of epithelial cells was definitely more frequent. In one instance practically every cell in the basilar portions of the cecal and sigmoid glands was affected. There was a striking decrease in mucus production in the last 5 animals to die.

When mitotic figures were present in the small bowel, they were also seen in the colon. However, mitotic activity was always greater in the small intestine than in the colon.

Pancreas

The changes in the islets of Langerhans were extremely interesting in view of the blood sugar changes reported in some species. Every animal that received at least 15,000 r exhibited varying degrees of necrobiosis of alpha and beta cells. There was no dose severity inter-

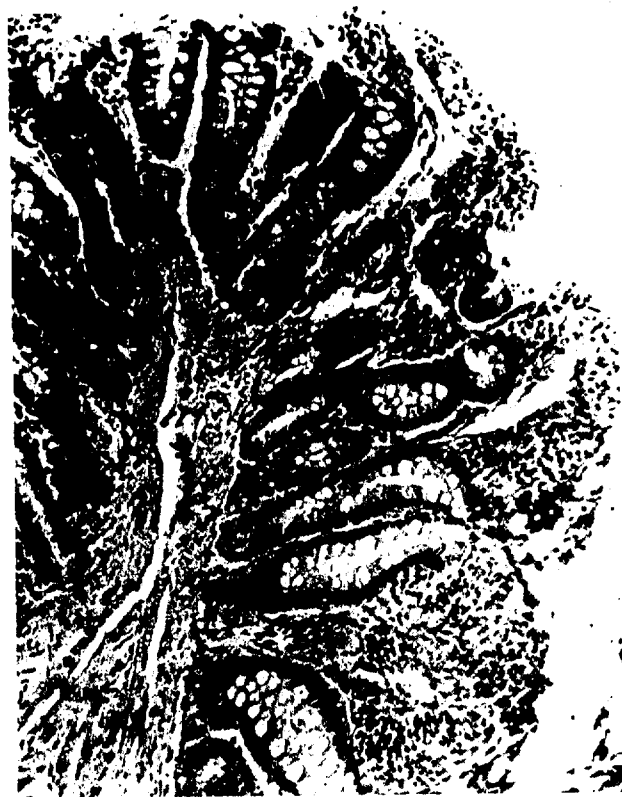

FIGURE 11

The tips of the intestinal villi are devoid of epithelial cells. However, this was an infrequent finding and most probably represents an iatrogenic artifact. $\times 130$.

dependence, the changes in the 15,000 r animals being as severe as those observed in the 40,000 r animals. Most commonly one-third to one-half of the cells of a given islet were affected. The earliest change was nuclear pyknosis. Subsequently there was dissolution of the cytoplasm, and finally complete destruction of the cell. In some instances almost every islet was affected. In the majority of cases, however, intact islets were scattered among degenerating islets (fig. 13). There were only 5 animals in which no changes could be detected in the islets. Four of these received 10,000 r and 1 received 5,000 r.

In 2 animals there were severe alterations in the exocrine parenchyma. The secretory cells had lost their granules and occupying the cytoplasm were single or multiple large vacuoles (fig. 14). In 6 other animals there was mild vacuolization of the exocrine cells, but none of these approached the severity noted in the 2 animals described above.



FIGURE 12

More typical appearance of intestine. The villi are covered by intact columnar epithelium. However, throughout the crypts there are moderate amounts of nuclear dust. $\times 200$.

Salivary glands

The parotid and submaxillary glands appeared essentially unaffected by the ionizing radiation.

Lungs

In 13 monkeys there was severe edema of the vascular adventitia and perivascular connective tissue. The larger pulmonary arteries and veins were particularly susceptible. The collagenous fibers were widely separated by accumulations of protein-rich fluid. The intima and muscularis exhibited no histologic alterations (fig. 15). In some instances, smaller vessels were edematous, but this was not typical. In the first 2 animals to die, fluid-filled alveoli contained moderate numbers of segmented neutrophils. There were no secondary

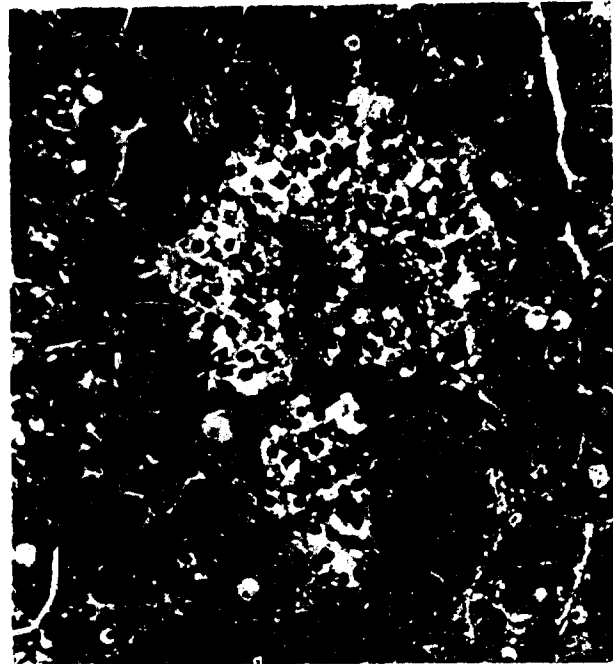

FIGURE 13

Every cell in this islet of Langerhans is degenerating. Quite often, however, there were intact cells intermingled among cells exhibiting extreme nuclear pyknosis. From animal dying 13.8 hours after irradiation with 25,000 r. $\times 400$.

pulmonary infections of note. Lung mites (*Pneumonyssus foxi*) were extremely rare.

Larynx, trachea, and bronchi

No radiation-induced histologic alterations were demonstrable in these structures.

Bone marrow

Representative portions of the sternum, thoracic vertebra, and distal end of the femur were removed for fixation and examination. The samples of marrow were examined by means of sections alone, no smears being made. The sternal and vertebral marrow were similar. The femur was consistently the least cellular of the three samples. It was sometimes difficult to differentiate physiologic hypocellularity from radiation effect. The exact age at which the femur marrow of the monkey undergoes physiologic atrophy is not well established. However, definite evidence of nuclear degeneration as early as 3½ hours




FIGURE 14

In the last 3 animals to die, there was vacuolization of the exocrine parenchyma of the pancreas. There was also proliferation of stromal cells and ducts. $\times 130$.

postirradiation suggested that the femur marrow was the most susceptible to the effects of ionizing radiation. This was particularly true of the para-epiphyseal marrow.

Fourteen hours postirradiation all portions of the bone marrow began to exhibit moderate decreased cellularity. On the second and third day moderate to severe generalized atrophy of all the hematopoietic elements became a constant finding (fig. 16).

Lymphoid tissue

Destruction of lymphoid tissue followed the same general pattern observed in the hematopoietic tissue. In the first 4 animals to die, there were no visible changes. Thereafter there was increasingly severe degeneration of lymphocytes. In the earliest stages there was mild, decreased cellularity of germinal centers. Occasionally pyknotic nuclei were scattered throughout the Malpighian bodies and red pulp

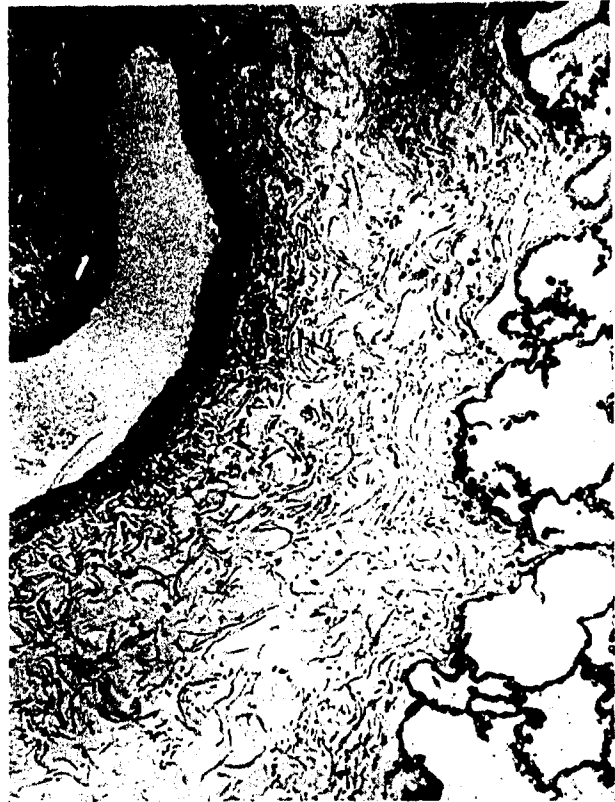

FIGURE 15

An extremely common finding was severe edema of the adventitia and perivascular connective tissue of the larger pulmonary arteries. From an animal dying 6.5 hours postirradiation with 25,000 r. $\times 130$.

of the spleen. Within hours nuclear pyknosis became generalized and severe. Chromatin dust was prominent throughout the region of the Malpighian bodies and germinal centers (fig. 17). On the second and third day practically no lymphocytes remained in the spleen or lymph nodes. In both tissues the germinal centers were composed of large, epithelial-like cells with voluminous, pale eosinophilic cytoplasm (fig. 18).

Degeneration of thymocytes lagged 4 to 6 hours behind degeneration of the other lymphoid elements. Hassall's corpuscles were the last structures to disappear. Interlobular edema was prominent in most of the animals (fig. 19), which resulted in the thymus being 8 to 10 times its normal size.

Adrenals

The most consistent feature was infiltration of the cortex by segmented neutrophils. The intensity of the leukocytic infiltration

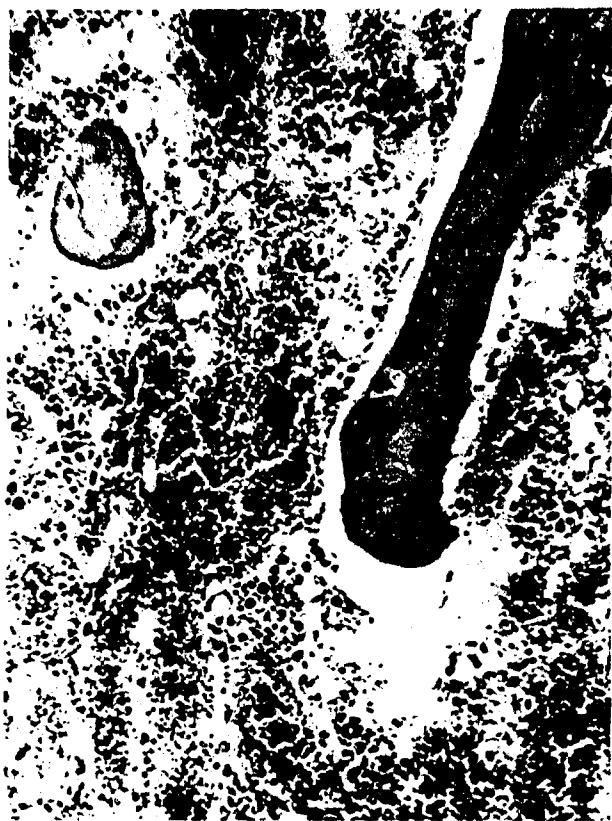

FIGURE 16

Marrow atrophy was almost complete in this animal dying 15 hours postirradiation with 15,000 r. $\times 130$.

varied slightly without regard to dose or survival time (fig. 20). In animal 8 there was intense congestion of the medulla, zona reticularies, and the inner third of the zona fasciculata. In the most intensely congested areas there were scattered degenerating cortical cells. Their cytoplasm was intensely eosinophilic, and nuclear pyknosis was present.

Skin, muscle, and bone

The massive doses of ionizing radiation had induced no visible changes in these structures.

Heart and great vessels

Pathologic changes of any nature were rare in these organs, and none were attributable to the effects of ionizing radiation. There was one instance of mild fibrous thickening of the epicardium. In one animal there was a small focus of chronic myocarditis characterized by mild interstitial fibrosis and monocytic infiltration.

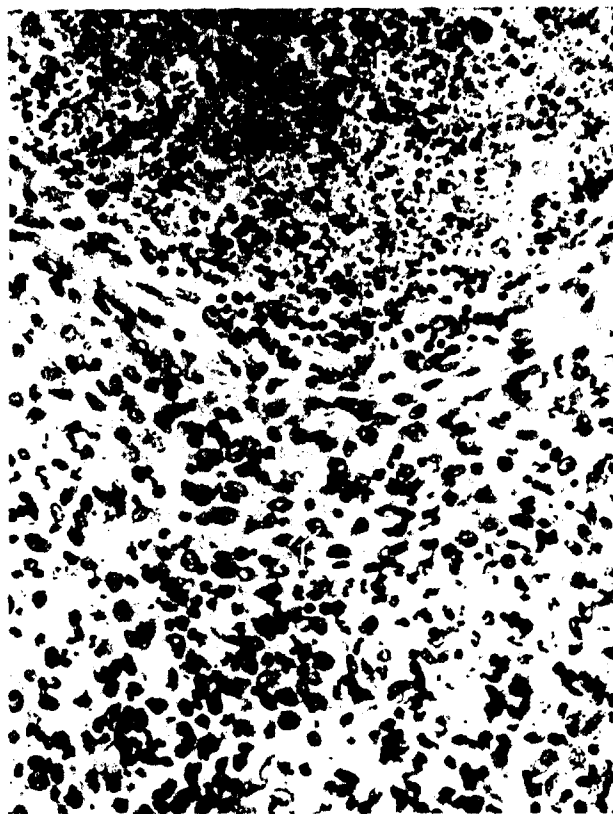


FIGURE 17

Extensive lymphocyte fragmentation in lymph node of animal dying 39 hours after receiving 15,000 r. $\times 320$.

Liver and biliary tree

There were no gross or microscopic abnormalities of note in any of these structures.

Kidneys, ureters, and urinary bladder

Gross and histologic examination revealed no significant anatomic alterations.

Genitalia

All of the monkeys were prepubertal; therefore, no irradiation effects were demonstrable in the testicles or prostates. In the females there was early degeneration of scattered oocytes.

DISCUSSION

Ionizing radiation produces at least three distinct modes of acute death, depending upon the radiation dose employed. In the *Macaca mulatta* hematopoietic death is manifested by



FIGURE 18

Complete lymphoid atrophy observed in the last animal to die. Note that only reticulum cells remain. X180.

animals irradiated with 400 to 800 r of gamma. Beyond 1,000 r and to the level of 7,500 r the intestinal death syndrome predominates. Above 9,000 r the central nervous system phase of radiation death occurs (3). At doses intermediate between these three groupings, there is likely to be an intermixing of the modes of death (3, 10). Hence, in order to depict a typical pathologic syndrome, it is best to choose a radiation dose near the midpoint of the dose range capable of producing the syndrome in question (1, 2, 3, 10). When this optimum dose is used, the pathologic syndrome usually follows a generally consistent pattern. Typically, after a time lapse which is dependent upon the radiation dose, there is a sudden onset in the pathologic reaction. It rapidly increases in severity, reaches a peak, and begins to subside more gradually than it began (1-5, 10). In referring to "increased" and "decreased" severity of the pathologic reaction in this context, however, the mortality of the animals is not being used as an index. In each instance the altera-

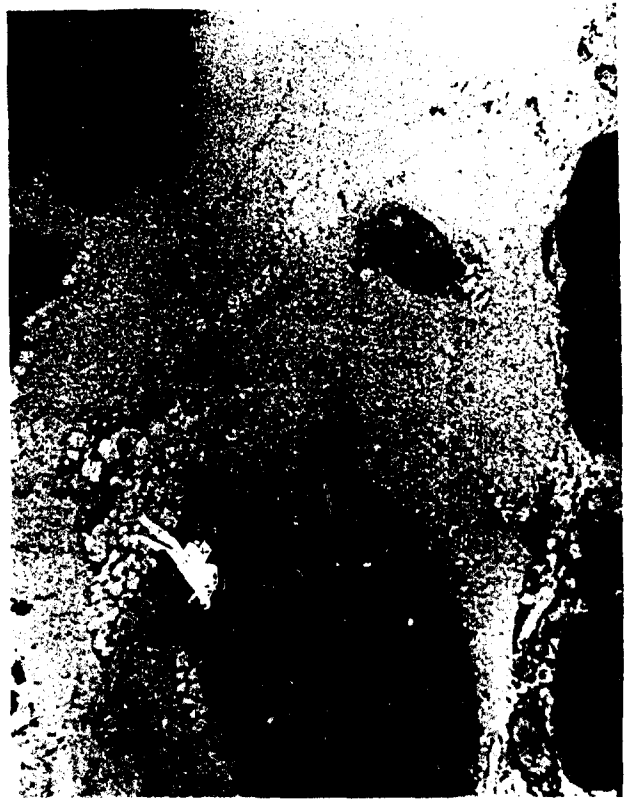

FIGURE 19

Marked interlobular edema of the thymus in an animal dying 3.5 hours postirradiation with 25,000 r. X50.

tions produced were severe enough to kill the animal. Instead, the relative severity of the reaction is determined by two other factors: (1) how many of the given criteria for the syndrome in question are fulfilled; and (2) how severe each of the manifested lesions is when compared to similar lesions produced in other animals in the same experiment.

Haymaker et al. determined that doses of 2.5 kr to 30 kr of gamma were capable of producing cerebral vasculitis and meningitis in the monkey. Lesions were found as early as 1 hour postirradiation (4). Subsequently, Vogel et al. established in a serial sacrifice experiment that monkeys irradiated with 10 kr exhibited an onset of meningitis within 2 hours postirradiation. The reaction reached a point of maximum intensity within 8 to 24 hours and thereafter subsided or disappeared.

In the current experiment two groups of 4 animals each were exposed to 10 and 15 kr, respectively; all died within the period of declining inflammatory reaction established by




FIGURE 20

Severe neutrophilic infiltration observed in the adrenals of the last animal to die. $\times 100$.

Vogel. Yet all of these animals exhibited more severe inflammatory reactions than the 25 kr and 40 kr animals that died during the time when the inflammatory reaction should have been reaching its peak (table II). It is observed at this point that it does not matter whether the grade 4 lesions in the current study correspond in severity to the 4+ reactions observed by Haymaker and Vogel. In any case, the general trend of the relative severity of the inflammatory reactions should have been the same since in each case the animals were judged with respect to one another. Yet the pattern of the pathologic reaction with regard to time was quite different (fig. 21). In the current study, the over-all severity of the meningitis and cerebral vasculitis gradually increased until maximum intensity was reached about 24 hours postirradiation. For the subsequent 24 hours a plateau effect was encountered. At 54 hours the inflammatory reaction abruptly disappeared and was not seen in the animals irradiated with 5

kr and 7.5 kr and dying during the fourth and fifth day (3).

There are at least three possible explanations for the failure of the two curves in figure 21 to coincide. Since all three experiments were performed at different times and at different locations, the variations could be artifacts. To a certain extent, however, each of the experiments was under the guidance of the same individual. All of the experimental animals came from the same source and were handled under similar conditions. Equivalent energies of radiation were used in the three experiments, and the dose rate was approximately the same. In particular, the critical conditions of the current experiment were adjusted to correlate as closely as possible with the conditions of the Haymaker experiment (4). In addition, the relative severity of the two lesions not dependent upon leukocytic infiltration, nuclear pyknosis in the pituitary and cerebellum, correlated closely with those observed by both Haymaker and Vogel.

Since one group of monkeys received a higher radiation dose (40 kr) than any of the animals in the Haymaker experiment (30 kr), it is possible that the early deaths described in this report may represent a heretofore unrecognized mode of radiation death. However, all of the animals exhibited the typical clinical and pathologic syndrome of central nervous system death and died within the time limits described by Haymaker.

The third possibility is that one of the factors responsible for promoting the leukocytic infiltration may have been compromised by the doses of radiation above the level of 15 kr. From this point of view there are at least three factors to be considered. First of all, if damage to the white or grey matter yields a chemotactic principle which attracts the leukocytes to the central nervous system, it would appear probable that 40 kr would be at least as efficient as 10 kr since only the factor of tissue damage is involved. Secondly, if leukocytic infiltration is dependent upon increased vascular permeability, again 40 kr should be at least as efficient as 10 kr since only the factor of damage is involved. On the other hand, migra-

TABLE II

Relative severity of central nervous system lesions

Animal No.	→	2	4	6	1	10	8	5	9	13	7	3	12	11	14	15	16	18	17	19	20
Dose (kr.)	→	40	40	25	40	15	25	40	25	5	25	40	15	25	15	15	10	10	15	10	10
Survival (hr.)	→	2.7	2.8	3.5	4.0	4.5	5.3	5.5	6.5	6.6	6.7	6.8	9.8	14	15	16	30	38	39	42	54
CNS vasculitis							1			4				1	2	1	3	1	1	2	2
Meningitis*					1		2	1	1	4	1	2	3	1	3	2	3	2	2	2	3
Nuclear pyknosis†			1	2	1	2	2	3	4		4	2	2	3	4	4	±	±	±	±	±

The lesions occurring in the central nervous system are graded 1 to 4 depending on their severity. Note the striking absence of meningitis and vasculitis in the 40 kr. animals. The ± sign indicates that there were rare pyknotic nuclei, but their significance was doubtful.

*Includes the meningeal vessels. Choroid plexitis followed essentially the same pattern.

†Refers to both cerebellar granule cells and pituitary basophils.

tion of leukocytes into a damaged area is dependent upon the preservation of the biologic integrity of the leukocytes, and it is possible, if sufficiently high doses of radiation were used, that this function could be compromised or completely destroyed. In other words, the evidence presented in table II and figure 21 suggests that, above the level of 20 to 25 kr, there is a certain degree of impairment of the migratory capacity of the leukocytes and at levels of 35 to 40 kr the circulating leukocytes may be "devitalized."

The pattern of granule cell pyknosis supports the view that it is not merely a manifestation of vascular damage and that at the 10,000 r level the changes are transitory. Haymaker qualified the latter conclusion since he had only animals receiving 5,000 r or less to observe after 24 hours. However, in the current study there were 4 animals receiving 10,000 r that survived between 30 and 54 hours (table II). In each of them only occasional pyknotic granule cells were seen and this is indicated by the ± sign. The same was true of a 15,000 r animal that expired during this time span. Table II also shows that the granule cell pyknosis was severe during 2.7 to 16 hours postirradiation. Pyknosis of pituitary basophils followed the same pattern of involvement as the cerebellar granule cells.

Changes in the central nervous system were impressive, but no more so than those in other parts of the body. As in the brain, there ap-

peared to be two definite categories of injury. The first was production of individual cell death in various organs; the second, compromised vascular integrity.

Evidence of the ability of such doses of radiation to bring about rapid cell death without disruption of basic tissue structure was manifest by necrobiosis of gastric parietal cells and secretory cells of the islets of Langerhans. In each instance 15,000 r or more was needed to induce the cell death. It was interesting that, at least by morphologic evidence, the parietal cells were selectively damaged in the stomach. In only two instances were the chief cells markedly affected and the mucous cells never appeared abnormal.

Damage to epithelial cells in the small intestine and colon was manifest by necrobiosis of crypt cells, moderate amounts of nuclear dust scattered throughout the basilar portions of the glands, mild nuclear atypism, and cessation of mitotic activity. In mice, 10 kr of whole-body radiation are sufficient to produce denudation of the small intestinal villi. Three and one-half days are required for complete denudation. However, epithelial depletion and cell atrophy are noticeable as early as one day postirradiation (10). In monkeys dying 38 to 54 hours postirradiation there was no noticeable alteration in cell population or villus size as compared to nonirradiated animals. In the animals receiving 15,000 to 40,000 r there were occasional villi partially devoid of epithelial

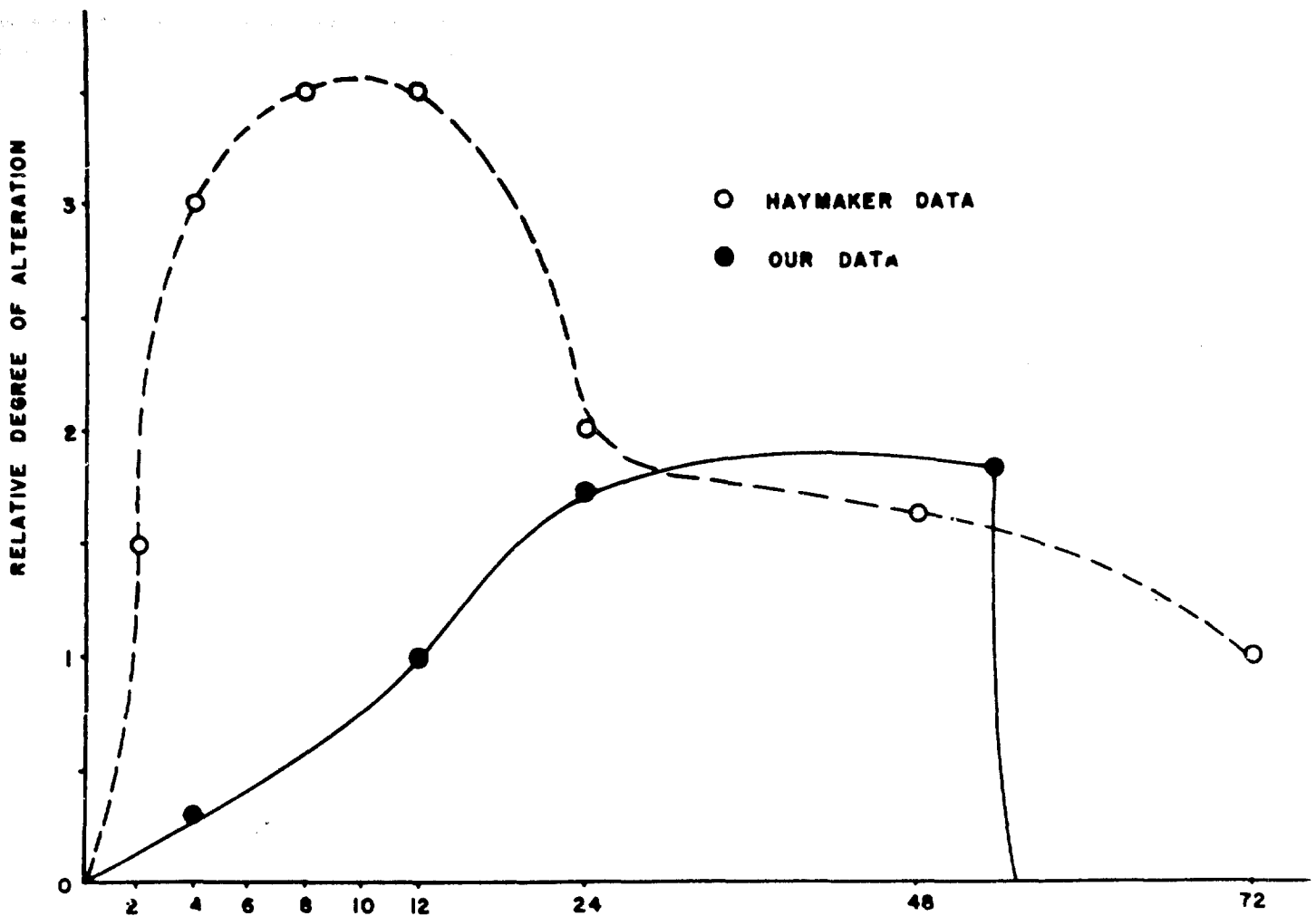


FIGURE 21

The broken line is a composite graph depicting the general pattern of cerebral vasculitis and meningitis reported by Vogel and Haymaker. The solid line is a composite representation of the over-all pattern of the inflammatory reaction in the brain and cerebral vessels of the animals utilized in this experiment (see table II). The striking difference in the shape of the two curves is the important feature.

cells. The fact that the bowel was rinsed in saline prior to being placed in fixative may have resulted in loss of some cells. However, the possibility of primary radiation death of these cells cannot be dogmatically excluded since the dosages employed were sufficient to induce widespread cell death in other tissues.

The effect that radiation has on gastrointestinal motility is well documented in the literature (11). From the clinical observations it was evident that there was marked hyperirritability of this system. In addition, at autopsy the lumen of the bowel was not only devoid of particulate matter, it also contained considerable quantities of clear, watery fluid.

No doubt, severe dehydration and electrolyte imbalance were present. The lethality of these phenomena in their severe form is well known. Hence, it is postulated that loss of the epithelial lining does not represent the major factor in the breakdown of the intestinal barrier. Also, the nature and quantity of the fluid accumulated in such a short time suggest that it did not have origin in the biliary tree.

The severe adventitial and perivascular edema of the large pulmonary vessels is regarded as evidence of primary vascular damage. The question might be raised as to whether or not this is simply a manifestation of pulmonary congestion. If such were the case, the veins

and lymphatics of the periphery of the lung parenchyma and vascular tree should exhibit the most severe changes; such was not the case. The role that the bronchial arteries played in this pathologic process can only be theorized upon at this time. Pulmonary edema was seen occasionally, and pleural effusions were frequent. Their distribution (table I) raises the question as to whether or not the primary vascular damage might have been the precipitating factor.

On the basis of these findings it is concluded that damage to the abdominal and thoracic viscera and damage to the central nervous system are basically the same; that is, substantial vascular damage and injury are observed to occur in individual cells of selected tissues. The gravity of the changes in the gastrointestinal tract and lungs appeared as great as those occurring in the brain. Hence the qualifications stated in the introductory remarks must be adhered to if the diagnosis "radiation-induced central nervous system death" is to be utilized accurately. Even as a clinical diagnosis it is misleading since there are also severe signs of gastrointestinal injury. In the past these have been inadequately emphasized, probably because convulsions and nystagmus are more awe-inspiring than vomiting and diarrhea. However, the lethality of the latter in their severe form is well known.

SUMMARY

Ninety-nine monkeys were irradiated with acute doses of whole-body gamma radiation ranging from 400 to 40,000 r. Twenty of the animals receiving from 5,000 to 40,000 r exhibited severe signs of central nervous system damage which persisted until death. In this respect they differed from the remainder of the animals in the experiment. For this reason they were segregated into one group and designated "central nervous system deaths."

Damage to the central nervous system was extremely widespread in the autopsy material. The changes were morphologically the same as those described by other investigators. However, the temporal incidence was unique and

suggests that at high dose levels the functional capacity of circulating neutrophils is severely compromised. It would also appear that this "leukocyte devitalization" is not an all or none proposition, but occurs to varying degrees over a wide dose range.

While this group of monkeys was segregated from the remaining animals on the basis of persistence of signs of central nervous system damage, it was apparent both clinically and pathologically that there were extensive lesions in the thoracic and abdominal viscera. Most evident were the severe diarrhea and the widespread epithelial necrobiosis throughout the gastrointestinal tract. However, the lungs also exhibited severe damage, and the combination of these visceral lesions appears to have contributed as much to the death of the animals as did the central nervous system damage.

REFERENCES

1. Quastler, H. Studies on roentgen death in mice. I. Survival time and dosage. *Am. J. Roent.* 54:449-456 (1945).
2. Gerstner, H. G. Military and civil defense aspects of the acute radiation syndrome in man. School of Aviation Medicine, USAF, Report No. 58-6, Nov. 1957.
3. Allen, R. G., Jr., F. A. Brown, L. C. Logie, D. R. Rovner, S. G. Wilson, Jr., and R. W. Zellmer. Acute effects of gamma radiation in primates. School of Aviation Medicine, USAF Report No. 59-41, Mar. 1959.
4. Haymaker, W., W. J. H. Nauta, J. C. Sloper, G. L. Laqueur, J. E. Pickering, and F. S. Vogel. The effects of barium¹⁴⁰ — lanthanum (gamma) radiation on the central nervous system and pituitary gland of macaque monkeys. *J. Neuropath. & Exper. Neurol.* 27:138-150 (1958).
5. Vogel, F. S., C. G. Hoak, J. C. Sloper, and W. Haymaker. The induction of acute morphologic changes in the central nervous system and pituitary body of macaque monkeys by cobalt⁶⁰ (gamma) radiation. *J. Neuropath. & Exper. Neurol.* 27:138-150 (1958).
6. Young, R. J., B. D. Fremming, R. E. Benson, and M. D. Harris. Care and management of a

- Macaca mulatta* monkey colony. School of Aviation Medicine, USAF, Report No. 57-49, Feb. 1957.
7. Sigoloff, S. C. Chemical systems for the measurement of penetrating radiations — Techniques and production. School of Aviation Medicine, USAF, Report No. 57-86, May 1957.
 8. Upners, T. Experimentelle untersuchugen ueber die lokale einwirknug des thiophens in zentralnervensystem. Ztschr. f. d. ges. Neurol. u. Psychiat. 166:623 (1939).
 9. Bloom, W. Histopathology of irradiation. National nuclear energy series, vol. 4, No. 221, p. 505 (1958).
 10. Quastler, H. The nature of intestinal radiation death. Radiation Res. 4:303-320 (1956).
 11. Conrad, R. A. Effects of x-irradiation on intestinal motility of the rat. Am. J. Physiol. 165:375-385 (1951).