

AD-A032 805

ARMY AEROMEDICAL RESEARCH LAB FORT RUCKER ALA
THE CONTRACTILE RESPONSE OF THE SPLEEN OF MINIATURE SWINE TO IN--ETC(U)
SEP 72 T L WACHTEL, G R MCCAHAN
USAARL-73-4

F/G 6/15

UNCLASSIFIED

NL

1 OF 1
ADA032805

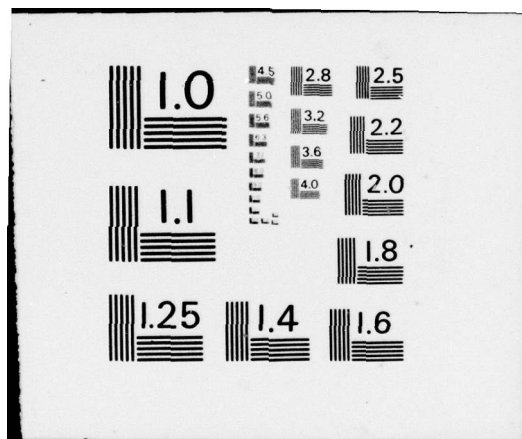


END

DATE

FILMED

- 77



ADA 032805

1473 AD (2)

USAARL REPORT NO. 73-4

THE CONTRACTILE RESPONSE OF THE SPLEEN OF MINIATURE SWINE
TO INTRA-ARTERIAL INFUSION OF EPINEPHRINE


BY

LCDR Thomas L. Wachtel, M.D.
CPT G. R. McCahan, Jr., DVM
Mr. William M. McPherson, B.S.

September 1972

U. S. ARMY AEROMEDICAL RESEARCH LABORATORY

Fort Rucker, Alabama 36360



DISTRIBUTION STATEMENT A
Approved for public release;
Distribution Unlimited

NOTICE

Qualified requesters may obtain copies from the Defense Documentation Center (DDC), Cameron Station, Alexandria, Virginia. Orders will be expedited if placed through the librarian or other person designated to request documents from DDC (formerly ASTIA).

Change of Address

Organizations receiving reports from the US Army Aeromedical Research Laboratory on automatic mailing lists should confirm correct address when corresponding about laboratory reports.

Disposition

This document has been approved for public release and sale; its distribution is unlimited.

Disclaimer

The findings in this report are not to be construed as an official Department of the Army position unless so designated by other authorized documents.

The products referred to in this report are not considered as an endorsement by the authors or the Department of the Army.

AD _____

USAARL REPORT NO. 73-4

THE CONTRACTILE RESPONSE OF THE SPLEEN OF MINIATURE SWINE
TO INTRA-ARTERIAL INFUSION OF EPINEPHRINE

BY

LCDR Thomas L. Wachtel, M.D.
CPT G. R. McCahan, Jr., DVM
Mr. William M. McPherson, B.S.

September 1972

U. S. ARMY AEROMEDICAL RESEARCH LABORATORY

Fort Rucker, Alabama 36360

U. S. Army Medical Research and Development Command

Distribution Statement: This document has been approved for public
release and sale; its distribution is unlimited.

SEARCHED	INDEXED	SERIALIZED	FILED

SEP 1972

U.S. ARMY MEDICAL RESEARCH AND DEVELOPMENT COMMAND

Fort Rucker, Alabama 36360

The Vivarium of the United States Army Aeromedical Research Laboratory is fully accredited by the American Association for Accreditation of Laboratory Animal Care.

In conducting this research, the investigators adhered to the "Guide for Laboratory Animals Facilities and Care" prepared by the committee on the Guide for Laboratory Animals Facilities and Care, National Academy of Sciences, National Research Council. Humane procedures were utilized throughout, and a graduate veterinarian was in constant attendance to perform all surgical procedures and to ensure that all animals were fully anesthetized and insensitive to pain.

ACKNOWLEDGMENTS

The authors are indebted to Janice Speigner, Diana Patrick, John Barbaccia, Tom Downs, Richard Chapman, David Bellemore, Rodney Polk, Malcolm Kirk, C. D. Williams, Patricia Wagner, and Frederick Nelson for their generous assistance, without which this project could not have been completed.

ABSTRACT

The spleen of miniature swine is a blood storage organ which contracts with intra-arterial injection of epinephrine (and presumably other stressful stimuli) and thus autotransfuses the animal. We recommend the removal of the spleen of miniature swine prior to the use of this animal for any shock studies.

APPROVED:



ROBERT W. BAILEY
Colonel, MSC
Commanding

TABLE OF CONTENTS

	<u>Page</u>
INTRODUCTION	1
METHODS AND MATERIALS	1
RESULTS	2
DISCUSSION	4
CONCLUSIONS	9
REFERENCES	11

LIST OF FIGURES

		<u>Page</u>
FIGURE 1	ECG (Lead I) before and immediately after stimulation with epinephrine	3
FIGURE 2	(A) Mean packed cell volumes (PCV); (B) White blood cell count (WBC); and (C) Platelet count for twelve (12) miniature swine before and after stimulation with epinephrine pre- and post-splenectomy	5
FIGURE 3	Illustration of the spleen of the miniature swine and its vascular supply	6
FIGURE 4	Photographs of the spleen of miniature swine before (A) and after (B) injection of epinephrine into the gastro-splenic artery	7

THE CONTRACTILE RESPONSE OF THE SPLEEN OF MINIATURE SWINE TO INTRA-ARTERIAL INFUSION OF EPINEPHRINE

INTRODUCTION

The spleen is the largest lymphoid organ in the animal body and an important reservoir of blood.¹ In the cat and dog, the spleen is a storage organ which autotransfuses the animal and responds to appropriate stimuli; in other animals the spleen is only a rudimentary structure.² Despite extensive observations of the pig's liver and spleen during extracorporeal perfusion studies,^{3 4 5} no data are available from which we might determine the response of the spleen of swine (specifically, miniature swine) to shock-like states.

We anticipate using the pig in a burn shock animal model. These experiments were undertaken to determine whether the contractile response of the spleen was significant when appropriately stimulated and hence whether splenectomies must be performed prior to use of these animals in porcine burn shock studies.

METHODS AND MATERIALS

Twelve (12) white adult male and female Minipigs* weighing an average of 54.7 kg (40.9 to 61.3 kg) were procured, quarantined, and verified to be healthy and free of internal parasites prior to use in this study. They were handled frequently by the vivarium personnel and investigators so that entrance into the pens for studies could be performed without noticeable excitement.

The animals were fasted overnight, premedicated with atropine (1-2 mg) and Innovar-Vet** (1 cc/20 lb), intubated, and anesthetized with Halothane, USP. Central venous and arterial (aortic) catheters were inserted using the method developed in this laboratory.⁶ Stainless-steel limb electrodes for electrocardiography were implanted. The animals were allowed to fully recover from the anesthetic and stabilize.

*Modified Pitman Moore Strain of Miniature Swine, Vita Vet Laboratories, Marion, IN 36952

**McNeil Laboratories, Ft. Washington, PA 19304

Each animal was stimulated with an intra-arterial (aortic) injection of epinephrine (3 cc of 1:10000) while the heart sounds were monitored by auscultation and the rhythm evaluated by ECG. Arterial (aortic) blood samples were taken just prior to the stimulation and four (4) minutes after injection of epinephrine. These samples were submitted to study for packed cell volume (PCV), white blood cell count (WBC), platelet count, and peripheral smear. The PCV was obtained by the microhematocrit method. The WBC and platelet counts were obtained using "B-D brand Unopettes"* for dilution, hemocytometer counting chambers, and binocular light microscopy. Blood smears were made and stained with Wright's stain. The stimulation procedure was repeated again before splenectomy. A mean and standard deviation were derived from these determinations.

The Minipigs were premedicated and anesthetized again as described above. The hair over and adjacent to the operative area was closely clipped with a #40 clipper head, washed with a surgical detergent, and prepared with an iodine solution prior to the splenectomy. For the operation, each pig was restrained on its right side. The operative field was draped with sterile towels and Steri-Drape**. Laporatomy was performed through a left subcostal incision. A Bovie Electro-Surgical Unit*** was used for hemostasis and transecting muscle and fat. The spleen was delivered through the incision. The vascular supply to the spleen and the gross anatomy of the spleen were studied. Epinephrine (0.25 to 0.75 cc of 1:0000) was injected into either the splenic or gastro-splenic artery and the response of the spleen was observed. A clean splenectomy and closure of the wound was completed after the method described by Seamer and Walker.⁷

When the animal had recovered completely the stimulation procedure described above was performed twice. The catheters were removed. Additional blood was obtained by serial superior vena cava sticks for follow-up platelet counts and peripheral smears. A mean and standard deviation were derived from these determinations.

The spleen was submitted for microscopic evaluation. At the completion of the study all animals underwent a complete necropsy.

RESULTS

*Becton-Dickinson, Rutherford, NJ 07070

**3M Company, St. Paul, MN 55101

***Model CVS, Liebel-Flarsheim Company, Cincinnati, OH 45215

Intra-arterial injection of epinephrine caused an immediate tachycardia (See Figure 1) and frequently premature ventricular contractions. Clinically, the animals were slightly more active and somewhat more irritable.

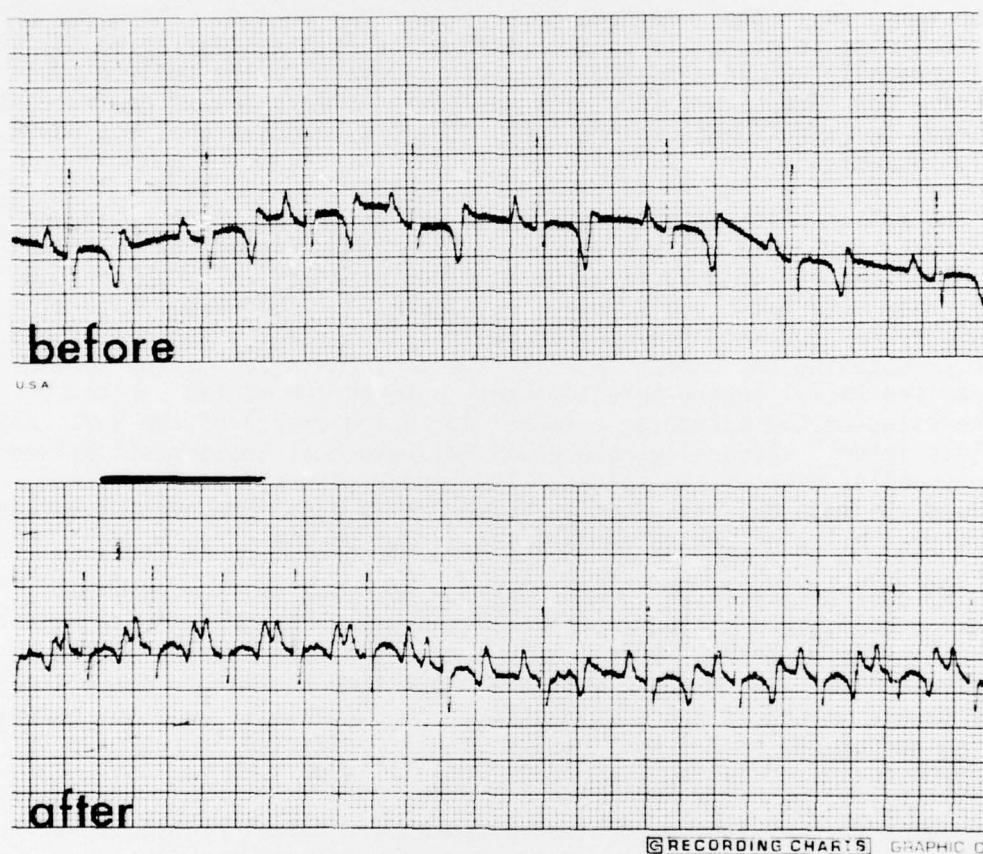


FIGURE 1. ECG (Lead I) before and immediately after stimulation with epinephrine.

The results of the blood studies are shown in Figure 2. The hematocrit increased an average of $5.43\% \pm \text{SD } 0.94$ (or an increase of 13.2% in PCV) with the intra-arterial injection of epinephrine prior to splenectomy and showed no significant increase ($0.31 \pm \text{SD } 0.15\%$) in PCV after splenectomy (See Figure 2a). The WBC remained unchanged following the intra-arterial injection of epinephrine prior to splenectomy and increased slightly (1828 WBC per ml or a 15% increase) after splenectomy. Platelets were unchanged after stimulation with intra-arterial epinephrine before splenectomy and in the immediate post splenectomy period. There was a transient rise in platelets on the sixth or seventh postoperative day which generally returned to pre-splenectomy levels by the twelfth post operative day (See Figure 2c). The peripheral smears showed no increase in target cells following splenectomy. There were occasional eosinopenia and lymphopenia.

The spleen of these miniature swine was an oblong, flat, J-shaped organ that measured $3 \pm 1 \times 6 \pm 2 \times 35 \pm 5$ cm and weighed 357 ± 84 gm with blood and $144 \text{ gm} \pm 33$ gm with the blood expelled. The spleen had a dual main arterial blood supply (See Figure 3). The larger lateral splenic artery egressed from the pancreatic tissue and often bifurcated prior to entering the curled lateral aspect of the hilus of the spleen. The smaller medial gastro-splenic artery entered the medial one-third of the hilus of the spleen as a large continuing branch of the left gastro-epiploic artery. Generally, there was no anatomical anastomosis between these supplies without the spleen. The venous return from the spleen followed the main arterial supply. Vasa brevia also were present between the lateral hilus of the spleen and the fundus of the stomach.

The dual arterial supply was used for studying the contractile response of the spleen to intra-arterial (splenic or gastro-splenic) injections of epinephrine. Small concentrations of epinephrine gave a positive contractile response within a short time and larger concentrations gave a marked splenic contraction (See Figure 4). Only the corresponding medial or lateral half of the spleen contracted in response to the epinephrine indicating a separate arterial supply.

Microscopic evaluation of the spleen showed normal architecture and structures. At necropsy there were a few adhesions to the operative scar in the animals, but no evidence of accessory spleens or splenosis.

DISCUSSION

The spleen is an important reservoir of blood which may be called

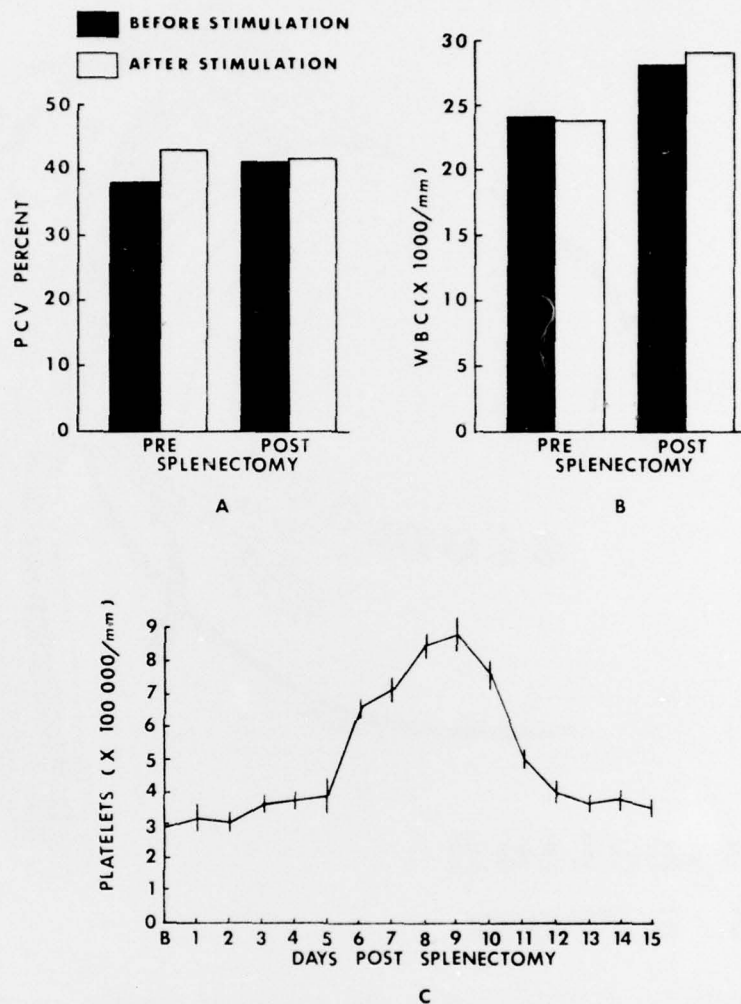
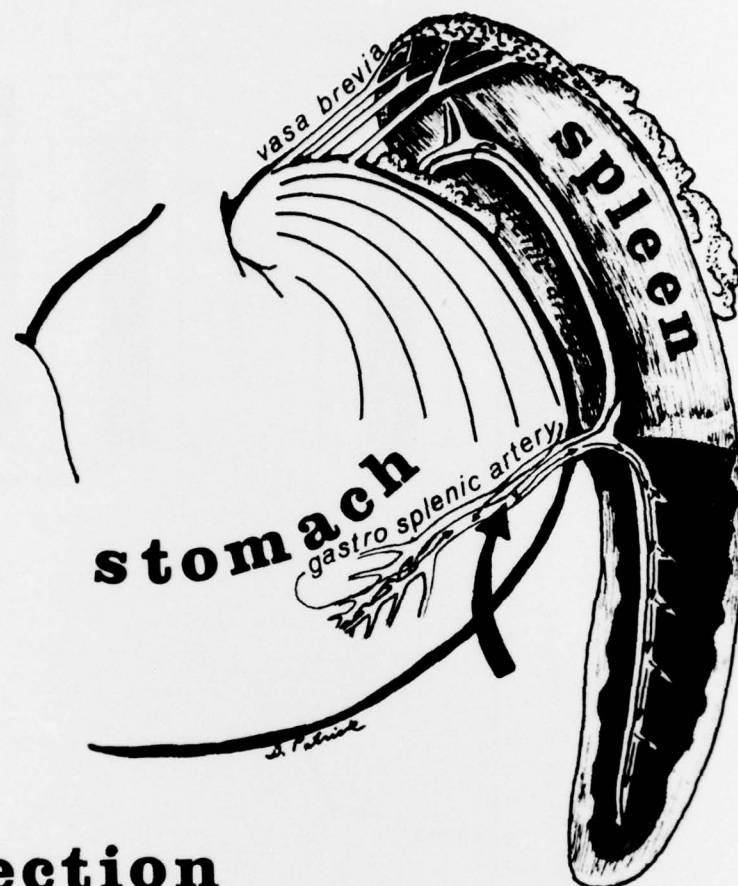


FIGURE 2. (A) Mean packed cell volumes (PCV); (B) White blood cell count (WBC); and (C) Platelet count for twelve (12) miniature swine before and after stimulation with epinephrine pre- and post-splenectomy.



injection at arrow

FIGURE 3. Illustration of the spleen of the miniature swine and its vascular supply. Shaded portion indicates contracted spleen from injection of epinephrine into the gastro-splenic artery.

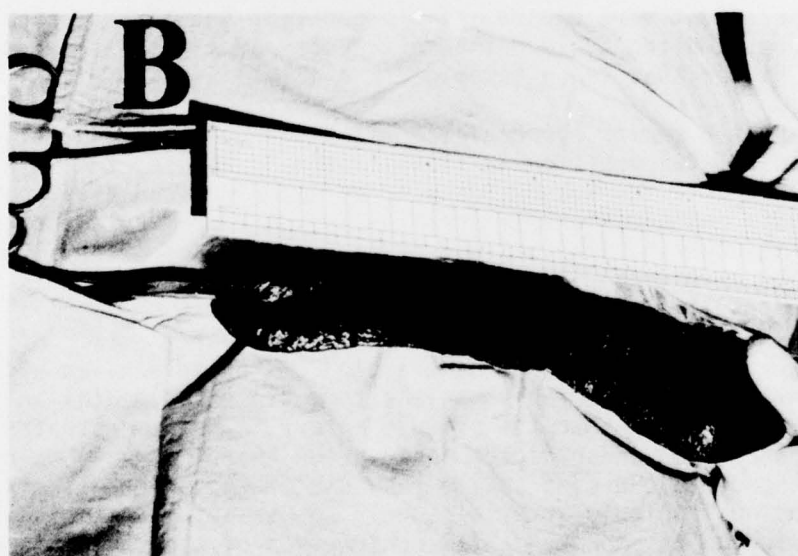
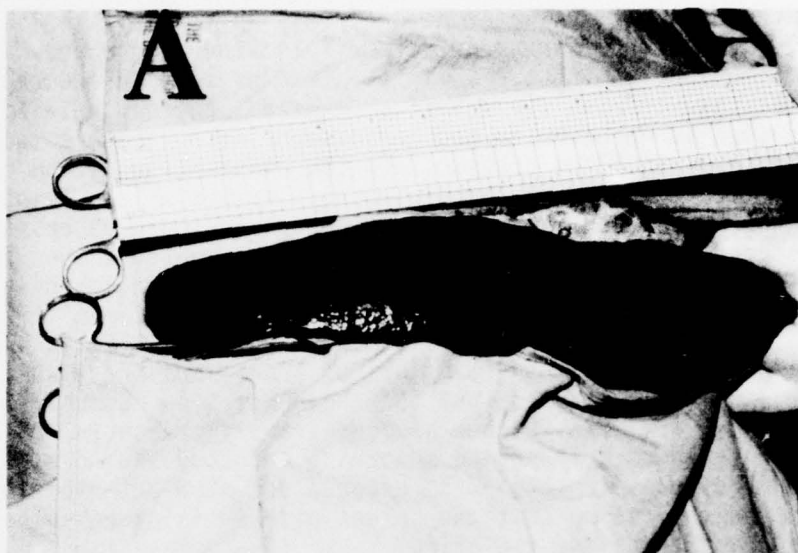


FIGURE 4. Photographs of the spleen of miniature swine before (A) and after (B) injection of epinephrine into the gastro-splenic artery.

upon when the body has a greater need for oxygen in the tissues.¹ This may occur postfeeding,⁸ during exercise, following hemorrhage, in carbon monoxide poisoning, during the administration of certain anesthetics, in emotional states, or when the animal is excited, thereby releasing catecholamines such as epinephrine and norepinephrine.¹ These catecholamines cause an increase in blood pressure and the contraction of the spleen, mobilizing erythrocytes into the circulatory system (i.e., autotransfusion).¹ Under these conditions, as well as when exogenous epinephrine is administered in effective doses, there are increased values for erythrocyte counts, packed cell volumes (PCV), and hemoglobin values which may be as high as 15% to 20% in some animals.¹ In an anesthetized dog the values for PCV may be increased from 40% to 45% after a release or injection of epinephrine.¹ Similar considerations presumably apply to the large domestic species, but they have not been demonstrated specifically.⁹ We were able to show a significant increase in PCV by intra-arterial injection of epinephrine before splenectomy and no significant change in PCV after splenectomy in response to intra-arterial infusion of epinephrine indicating that the spleen of the miniature swine does contract and autotransfuse the animal.

Pre-experiment handling of the animals and our catheterization technique permitted the studies to be done in unanesthetized, unrestrained, non-medicated, stable basal state animals. This minimized the extraneous factors that might have caused splenic contraction. Using only large vessel blood sampling avoided the controversy of large artery and venous PCV being higher than those taken peripherally.¹

Epinephrine causes myocardial irritability which produces tachycardia and can cause fatal ventricular fibrillation.⁹ We used twice the recommended therapeutic intravenous dose of epinephrine⁹ and always observed a tachycardia and occasionally arrhythmias. A four-minute post stimulation with epinephrine time was chosen for sampling of arterial blood because of the experience in dogs^{10 11} and because epinephrine is rapidly metabolized (15 to 30 minutes).⁹

Epinephrine causes prompt contraction of the spleen--an effect that is frequently utilized prior to splenectomy [in experimental animals] by injection of the drug into the splenic artery.⁹ We demonstrated marked splenic contraction under direct observation (See Figure 4) as our second method of studying the contractile response of the spleen of miniature swine. The dual splenic arterial supply was a useful anatomical finding which enabled us to show segmental contraction of the spleen (See Figures 3 and 4). This configuration is unlike the vascular supply in humans where there is an anastomosis of the left gastroepiploic to a branch of the bifurcated splenic artery prior to entering the spleen.¹² In repeated

examinations and injections of the two arteries, there always appeared to be a distinct anatomical division in the arterial supply.

Several other methods are available for studying splenic contraction. The F cells factor ($\frac{\text{PCV body}}{\text{PCV venous}}$) is influenced by the ability of the spleen

to contract as shown by the fact that it is stable in cats and dogs after splenectomy.¹ We did not use this method because of the inconsistencies in peripheral blood sampling and the inevitable excitability factor of doing so. Roentgenologic observations of the spleen were conducted by Hausner, et. al.¹³ He was able to effectively outline the spleen with small, perforated, disk-shaped pellets of lead which were sewed 2 to 3 cm apart along the periphery of the organ.¹³ This requires an additional operative technique and stabilization period as well as some restraining technique during roentgenologic studies. Celiac axis catheterization and direct splenoportography each would have considerable technical disadvantages¹³ in addition to restraining the animal during roentgenologic examination.

Splenectomy, without excessive blood loss, has no effect on the hematocrit of normal animals.¹⁴ The slight increase in our post-splenectomy PCV is probably the result of contracting one half of each spleen with epinephrine prior to splenectomy; thus autotransfusing the animal to some extent.

The rise in WBC post-splenectomy has been observed by others and its mechanism is poorly understood.^{14 15} Possible mechanisms of this rise in WBC include loss of an inhibiting humoral factor that allows more WBC's to be produced, or the loss of a mechanical filter which then allows the cells once produced to linger longer in the circulation.¹⁵ Likewise, the reason for the increase in WBC's after epinephrine stimulation post-splenectomy in our studies is not clear.

The platelet count data parallel that reported for the rat¹⁴ and approach the transient thrombocytosis seen in humans.² No unusual cells were consistently noted on our peripheral smear although Howell-Jolly bodies,^{2 14} Heinz bodies, siderocytes, and target cells are frequently reported.²

Gross and microscopic evaluation of the spleens revealed no unusual findings nor did necropsy show any accessory spleens or splenosis which might have confused the blood studies.

CONCLUSIONS

The spleen of the miniature swine has a dual arterial supply.

The spleen of miniature swine contracts with intra-arterial injection of epinephrine.

The spleen of the miniature swine is a storage organ which autotransfuses the animal in response to appropriate stimuli.

We recommend the removal of the spleen of miniature swine prior to the use of this animal for any shock studies.

REFERENCES

1. Swenson, M. J.: "Physiological Properties, Cellular and Chemical Constituents of Blood." In Duke's Physiology of Domestic Animals, 8th ed., Swenson, M. J., Ed., London, Cornell University Press, 1970, pp. 21-61.
2. Ballinger, W. F.: "Spleen." In Principles of Surgery, Schwartz, S. I., Ed., New York, McGraw-Hill Book Co., 1969, pp. 1139-1141.
3. Liem, D. S., Waltuch, T. L. and Eiseman, B.: "Function of the Ex-Vivo Pig Liver Perfused with Human Blood." Surg. Form, 15:90-91, 1964.
4. Eiseman, B.: Personal communication, 1971.
5. Griffin, W.: Personal communication, 1971.
6. Wachtel, T. L., McCahan, G. R., Jr. and Alford, L. A.: "Development of a Bio-Pac for Cardiac Evaluation of Porcine Research Animals." USAARL Report 73-3, US Army Aeromedical Research Laboratory, Fort Rucker, AL, August 1972.
7. Seamer, J. and Walker, R. G.: "Splenectomy and the Spleen Weight of Young Pigs." Research Vet. Sci., 1:125-128, 1960.
8. Reece, W. O. and Snodgrass, R. R.: "Effect of Splenectomy in Post-feeding Changes in Packed Cell Volume of Dogs." Am. J. Vet. Res., 33:635-637, 1972.
9. Stowe, C. M.: "Adrenergic Drugs." Veterinary Pharmacology and Therapeutics, 3rd ed., Jones, L. M., Ed., Ames, Iowa, The Iowa State University Press, 1965, pp. 277-294.
10. Benjamin, M. M.: "Blood Parasites--Heartworms." Outline of Veterinary Clinical Pathology, 2nd ed., Ames, Iowa, The Iowa State University Press, 1961, pp. 116-117.
11. Young, H. G.: "A Survey of the Problem of Heartworms Among Dogs in the United States." Gaines Vet. Symp., 5th ed., 1955, pp. 5-8.
12. Grant, J. C. B.: An Atlas of Anatomy, 5th ed., Figures 158 & 159, Baltimore, The Williams & Wilkins Co., 1962.

13. Hausner, E., Essex, H. E. and Marm, F. C.: "Roentgenologic Observations of the Spleen of the Dog Under Ether, Sodium Amytal, Pentobarbital Sodium and Pentothal Sodium Anesthesia." Am. J. Physiol., 121:387-391, 1938.
14. Widmann, W. D., Davidson, S. J., Laubscher, F. A., et. al.: "Effects of Splenectomy and Splenosis on the Blood and Platelet Count and Red Cell Morphology." Mil. Med., 136:15-19, 1971.
15. Palmer, J. G., Kemp, I., Cartwright, G. E., et. al.: "Studies on the Effect of Splenectomy on the Total Leukocyte Count in the Albino Rat." Blood, 6:3-15, 1951.

DISTRIBUTION LIST OF USAARL REPORTS

Project No. 3AO 6211 OA 819 Army Aviation Medicine

No. of
Copies

5	US Army Medical Research and Development Command Washington, D. C. 20314
12	Defense Documentation Center Alexandria, Virginia 22314
1	US Army Combat Developments Command Medical Department Agency, BAMC Fort Sam Houston, Texas 78234

Unclassified

Security Classification

DOCUMENT CONTROL DATA - R & D

(Security classification of title, body of abstract and indexing annotation must be entered when the overall report is classified)

1. ORIGINATING ACTIVITY (Corporate author)		2a. REPORT SECURITY CLASSIFICATION	
U. S. Army Aeromedical Research Laboratory Fort Rucker, Alabama		Unclassified	
		2b. GROUP	
3. REPORT TITLE			
The Contractile Response of the Spleen of Miniature Swine to Intra-Arterial Infusion of Epinephrine			
4. DESCRIPTIVE NOTES (Type of report and inclusive dates)			
Paper for publication			
5. AUTHOR(S) (First name, middle initial, last name)			
CDR Thomas L. Wachtel, M.D. G. R. McCahan, Jr. DVM William M. McPherson, D.S.			
6. REPORT DATE		7a. TOTAL NO. OF PAGES	7b. NO. OF REFS
September 1972		12	15
8a. CONTRACT OR GRANT NO.		9a. ORIGINATOR'S REPORT NUMBER(S)	
b. PROJECT NO. 3A0 6211 OA 819		73-4	
c. 3A06211OA819		9b. OTHER REPORT NO(S) (Any other numbers that may be assigned this report)	
10. DISTRIBUTION STATEMENT			
This document has been approved for public release and sale; its distribution is unlimited.			
11. SUPPLEMENTARY NOTES		12. SPONSORING MILITARY ACTIVITY	
		US Army Medical R&D Command Washington, D. C. 20314	
13. ABSTRACT			
The spleen of miniature swine is a blood storage organ which contracts with intra-arterial injection of epinephrine (and presumably other stressful stimuli) and thus autotransfuses the animal. We recommend the removal of the spleen of miniature swine prior to the use of this animal for any shock studies.			

14 USHARL-73-4

12 22p

DD FORM 1473

REPLACES DD FORM 1473, 1 JAN 66, WHICH IS OBSOLETE FOR ARMY USE.

Unclassified
Security Classification

404578

VB

Unclassified
Security Classification

14. KEY WORDS	LINK A		LINK B		LINK C	
	ROLE	WT	ROLE	WT	ROLE	WT
Miniature Swine Spleen Contraction Epinephrine Packed Cell Volumes (PCV)						

Unclassified
Security Classification

ARL 73-4

AD

U. S. Army Aeromedical Research Laboratory, Fort Rucker, Alabama. THE CONTRACTION RESPONSE OF THE SPLEEN OF MINIATURE SWINE TO INTRA-ARTERIAL INFUSION OF EPINEPHRINE by Thomas L. Wachtel, M.D., G. R. McCahan, Jr., DVM and William M. McPherson, B.S., 12 pp. DA Project 340 6211 OA 819, Aviation Medicine Research Division.

The spleen of miniature swine is a blood storage organ which contracts with intra-arterial injection of epinephrine (and presumably other stressful stimuli) and thus autotransfuses the animal. We recommend the removal of the spleen of miniature swine prior to the use of this animal for any shock studies.

AD

U. S. Army Aeromedical Research Laboratory, Fort Rucker, Alabama. THE CONTRACTION RESPONSE OF THE SPLEEN OF MINIATURE SWINE TO INTRA-ARTERIAL INFUSION OF EPINEPHRINE by Thomas L. Wachtel, M.D., G. R. McCahan, Jr., DVM and William M. McPherson, B.S., 12 pp. DA Project 340 6211 OA 819, Aviation Medicine Research Division.

The spleen of miniature swine is a blood storage organ which contracts with intra-arterial injection of epinephrine (and presumably other stressful stimuli) and thus autotransfuses the animal. We recommend the removal of the spleen of miniature swine prior to the use of this animal for any shock studies.

ARL 73-4

AD

U. S. Army Aeromedical Research Laboratory, Fort Rucker, Alabama. THE CONTRACTION RESPONSE OF THE SPLEEN OF MINIATURE SWINE TO INTRA-ARTERIAL INFUSION OF EPINEPHRINE by Thomas L. Wachtel, M.D., G. R. McCahan, Jr., DVM and William M. McPherson, B.S., 12 pp. DA Project 340 6211 OA 819, Aviation Medicine Research Division.

The spleen of miniature swine is a blood storage organ which contracts with intra-arterial injection of epinephrine (and presumably other stressful stimuli) and thus autotransfuses the animal. We recommend the removal of the spleen of miniature swine prior to the use of this animal for any shock studies.

AD

U. S. Army Aeromedical Research Laboratory, Fort Rucker, Alabama. THE CONTRACTION RESPONSE OF THE SPLEEN OF MINIATURE SWINE TO INTRA-ARTERIAL INFUSION OF EPINEPHRINE by Thomas L. Wachtel, M.D., G. R. McCahan, Jr., DVM and William M. McPherson, B.S., 12 pp. DA Project 340 6211 OA 819, Aviation Medicine Research Division.

The spleen of miniature swine is a blood storage organ which contracts with intra-arterial injection of epinephrine (and presumably other stressful stimuli) and thus autotransfuses the animal. We recommend the removal of the spleen of miniature swine prior to the use of this animal for any shock studies.