



A Comparison of Zone 3 Resuscitative Endovascular Balloon Occlusion of the Aorta to the Abdominal Aortic and Junctional Tourniquet AAJT in a Lethal Pelvic Injury Swine Model

Jason M. Rall, PhD
LTC Theodore Redman, MD
CDR Elliot Ross, MD
Jonathan Morrison, MD, PhD, FRCS
Maj Joseph K Maddry, MD
USAF En Route Care Research Center

FINAL REPORT

December 2017

59th Medical Wing
Office of the Chief Scientist
1100 Wilford Hall Loop, Bldg. 4554
JBSA Lackland AFB, TX 78236-7517

DISTRIBUTION A. Approved for public release; distribution is unlimited.

DECLARATION OF INTEREST

The views expressed in this article are those of the authors and do not necessarily reflect the official policy or position of the Department of the Air Force, Department of Defense, nor the U.S. Government. This work was funded by Project Code Number AC12EM01. Authors are military service members, employees, or contractors of the US Government. This work was prepared as part of their official duties. Title 17 USC §105 provides that 'copyright protection under this title is not available for any work of the US Government.' Title 17 USC §101 defines a US Government work as a work prepared by a military service member, employee, or contractor of the US Government as part of that person's official duties.

NOTICE AND SIGNATURE PAGE

The views expressed are those of the authors and do not reflect the official views of the Department of Defense or its Components. The experiments reported herein were conducted according to the principles set forth in the National Institute of Health Publication No. 80-23, Guide for the Care and Use of Laboratory Animals and the Animal Welfare Act of 1996, as amended.

Using Government drawings, specifications, or other data included in this document for any purpose other than Government procurement does not in any way obligate the U.S. Government. The fact that the Government formulated or supplied the drawings, specifications, or other data does not license the holder or any other person or corporation or convey any rights or permission to manufacture, use, or sell any patented invention that may relate to them.

Qualified requestors may obtain copies of this report from the Defense Technical Information Center (DTIC) (<http://www.dtic.mil>).

“A COMPARISON OF ZONE 3 REBOA TO THE AAJT IN A LETHAL PELVIC INJURY SWINE MODEL” HAS BEEN REVIEWED AND IS APPROVED FOR PUBLICATION IN ACCORDANCE WITH ASSIGNED DISTRIBUTION STATEMENT”.

MICHAEL W. TRADER, GS-12, DAF
Program Analyst, Medical Modernization

DR. AMBER MALLORY, GS-15, DAF
Director, Trauma and Clinical Care
59th Medical Wing

This report is published in the interest of scientific and technical information exchange, and its publication does not constitute the Government's approval or disapproval of its ideas or findings.

REPORT DOCUMENTATION PAGE				<i>Form Approved OMB No. 0704-0188</i>	
The public reporting burden for this collection of information is estimated to average 1 hour per response, including the time for reviewing instructions, searching existing data sources, gathering and maintaining the data needed, and completing and reviewing the collection of information. Send comments regarding this burden estimate or any other aspect of this collection of information, including suggestions for reducing the burden, to Department of Defense, Washington Headquarters Services, Directorate for Information Operations and Reports (0704-0188), 1215 Jefferson Davis Highway, Suite 1204, Arlington, VA 22202-4302. Respondents should be aware that notwithstanding any other provision of law, no person shall be subject to any penalty for failing to comply with a collection of information if it does not display a currently valid OMB control number. PLEASE DO NOT RETURN YOUR FORM TO THE ABOVE ADDRESS.					
1. REPORT DATE (DD-MM-YYYY) 11-12-2017		2. REPORT TYPE Closeout		3. DATES COVERED (From - To) Oct 2015 – July 2017	
4. TITLE AND SUBTITLE A Comparison of Zone 3 REBOA to the AAJT in a Lethal Pelvic Injury Swine Model				5a. CONTRACT NUMBER	
				5b. GRANT NUMBER	
				5c. PROGRAM ELEMENT NUMBER	
6. AUTHOR(S) Rall, Jason M. Redman, Theodore T. Ross, Elliot M. Morrison, Jonathan J. Maddy, Joseph K.				5d. PROJECT NUMBER Project Code Number AC12EM01	
				5e. TASK NUMBER	
				5f. WORK UNIT NUMBER	
7. PERFORMING ORGANIZATION NAME(S) AND ADDRESS(ES) 59 th MDW/ST 1100 Wilford Hall Loop, Bldg. 4554 / SA Lackland AFB, TX 78236				8. PERFORMING ORGANIZATION REPORT NUMBER	
9. SPONSORING/MONITORING AGENCY NAME(S) AND ADDRESS(ES) Air Force Medical Support Agency (AFMSA)				10. SPONSOR/MONITOR'S ACRONYM(S)	
				11. SPONSOR/MONITOR'S REPORT NUMBER(S)	
12. DISTRIBUTION/AVAILABILITY STATEMENT DISTRIBUTION A. Approved for public release; distribution is unlimited.					
13. SUPPLEMENTARY NOTES					
14. ABSTRACT Traumatic injuries to the pelvis and high junctional injuries are difficult to treat in the field; however, Resuscitative Endovascular Balloon Occlusion of the Aorta (REBOA) and the Abdominal Aortic and Junctional Tourniquet (AAJT) constitute two promising treatment modalities. The aim of this study is to use a large animal model of pelvic hemorrhage to compare the survival, hemostatic, hemodynamic, and metabolic profile of both techniques. Yorkshire swine (N=10, 70-90 kg) underwent uncontrolled hemorrhage of the femoral artery by arteriotomy. Animals were randomly allocated to either REBOA or AAJT. After one hour, the injured femoral artery was ligated to simulate definitive hemostasis followed by a second Hextend bolus and device removal. Animals were observed for two more hours. Physiological data was collected throughout the experiments and compared between groups. No differences were found between groups with regards to pretreatment blood loss or blood chemistries. Both techniques effectively controlled hemorrhage in all animals, with no difference in mortality. During the 60-minute treatment phase, the AAJT group had a higher lactate level and MAP compared to the REBOA group (repeated measures ANOVA; p<0.05). Despite mechanistic differences between REBOA and the AAJT, both techniques achieve a similar hemostatic, hemodynamic and metabolic profile.					
15. SUBJECT TERMS Hemorrhage, REBOA, AAJT, Swine, Resuscitative endovascular balloon occlusion of the aorta, abdominal aortic and junctional tourniquet					
16. SECURITY CLASSIFICATION OF:			17. LIMITATION OF ABSTRACT UU	18. NUMBER OF PAGES 22	19a. NAME OF RESPONSIBLE PERSON Jason Rall, Ph.D.
a. REPORT U	b. ABSTRACT U	c. THIS PAGE U			19b. TELEPHONE NUMBER (Include area code) 210-292-5593

Standard Form 298 (Rev. 8/98)

TABLE OF CONTENTS

1.0 EXECUTIVE SUMMARY	1
2.0 INTRODUCTION	1
3.0 METHODS	2
3.1 Animal Preparation	3
3.2 Injury and Intervention.....	3
3.3 End of Intervention and Observation	4
3.4 Outcomes.....	4
3.5 Data Analysis	4
4.0 MAJOR EVENTS/MILESTONES/SUCCESS	4
5.0 RISK ASSESSMENT	5
5.1 Risk Analysis	5
5.2 Technical Challenges	5
6.0 TRANSITION PLAN	5
6.1 Military Relevance	5
6.2 Transition Strategy	5
7.0 RESULTS	5
7.1 Baseline Characteristics	5
7.2 Injury and Intervention.....	6
7.3 Hemodynamic and Pulmonary Parameters	7
7.4 Lab values	7
8.0 DISCUSSION	111
9.0 DELIVERABLES	114
9.1 Publications	114
9.2 Presentations	15
10.0 COST	115
11.0 REFERENCES	16
12.0 APPENDIX	18
12.1 Tables	118
12.2 Figures.....	118
12.3 List of Acronyms.....	118

1.0 EXECUTIVE SUMMARY

Traumatic injuries to the pelvis and high junctional injuries are difficult to treat in the field; however, Resuscitative Endovascular Balloon Occlusion of the Aorta (REBOA) and the Abdominal Aortic and Junctional Tourniquet (AAJT) constitute two promising treatment modalities. The aim of this study was to use a large animal model of pelvic hemorrhage to compare the survival, hemostatic, hemodynamic, and metabolic profile of both techniques.

Yorkshire swine (N=10, 70-90 kg) underwent general anesthesia, instrumentation and surgical isolation of the femoral artery. Uncontrolled hemorrhage was initiated by an arteriotomy. Animals were randomly allocated to either REBOA or AAJT. Following completion of device application, both groups received a 500 ml Hextend bolus. After one hour, the injured femoral artery was ligated to simulate definitive hemostasis followed by a second Hextend bolus and device removal. Animals were observed for two more hours. Physiological data was collected throughout the experiments and compared between groups.

Both techniques achieved 100% hemostasis, and all animals survived the entire experiment except one in the REBOA group. During the hour treatment phase, the AAJT group had a higher mean arterial pressure (MAP) than the REBOA group (59.9 ± 16.1 vs 44.6 ± 9.8 mmHg, respectively; $p < 0.05$). The AAJT-treated group had higher lactate levels than the REBOA-treated group (4.5 ± 2.0 vs 3.2 ± 1.3 mg/dL, respectively; $p < 0.05$).

Despite their mechanistic differences, both techniques achieve a similar hemostatic, hemodynamic and metabolic profile. Some differences do exist including lactate levels and blood pressure.

2.0 INTRODUCTION

The ability to effectively and rapidly control pre-hospital pelvic and junctional hemorrhage remains a challenge in both civilian and military trauma care.¹⁻³ The source of hemorrhage can vary widely depending on the mechanism and injury pattern, but hemodynamic instability is associated with major venous and arterial injury. While management is multimodal, such as the use of pelvic binders and damage control resuscitation, control of pelvic and junctional arterial inflow is critical.⁴⁻⁷

Arterial control has traditionally been performed in-hospital by operative or endovascular means, but such an approach has neglected patients who exsanguinate in the pre-hospital setting. Several techniques have been developed that can be deployed in such an environment.⁸⁻¹¹ The AAJT is a method of extrinsic control which consists of a pneumatic bladder, which when inflated, compresses the aorta and pelvic vasculature.¹²⁻¹⁵ REBOA provides intrinsic aortic control via a balloon-catheter inserted in the femoral artery and is inflated in the infrarenal aorta (zone 3).¹⁶⁻¹⁸ Both adjuncts are shown in Figure 1.

Both techniques have demonstrated promise in experimental and clinical studies, but each suffer from limitations which pertain to physiological sequelae, provider training burden and the

integration with the in-hospital phase of care. While AAJT is simple to apply, the reperfusion injury has been associated with respiratory depression in spontaneously ventilating subjects.¹⁹ Conversely, REBOA requires a practitioner skilled in arterial access in order to insert the device, but once inserted, there is the option of zone 1 (thoracic aorta) placement, should abdominal hemorrhage be encountered.

The aim of the current study is to compare the hemostatic ability of the AAJT and REBOA using a large animal model of uncontrolled hemorrhage. The hemodynamic, metabolic and pathologic effects will also be examined in an effort to identify evidence of superiority between techniques.




Figure 1. Test Products

3.0 METHODS

This study was a randomized, prospective trial with allocation concealment. Male, Yorkshire-Landrace swine, weighing 70 to 90 kg were housed according to regulation at an Association for Assessment and Accreditation of Laboratory Animal Care (AAALAC) accredited facility and entered into the experimental protocol. The study was approved by United States Air Force 59th Medical Wing's Institutional Animal Care and Use Committee (IACUC). All subjects were treated according to The Guide for the Care and Use of Laboratory Animals.²⁰ Overview of the experimental procedures is shown in Figure 2.

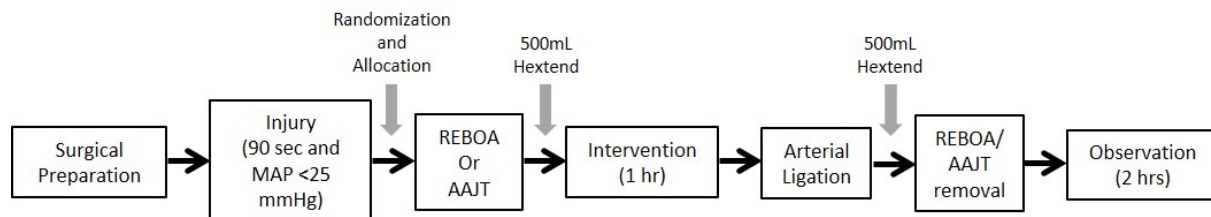


Figure 2. Experimental Schematic

3.1 Animal Preparation

Each animal was housed on-site for at least seven days to allow for acclimation and was fasted overnight with free access to water before surgery. Sedation was performed by intramuscular (IM) injection of 4.4 mg/kg tiletamine-zolazepam and 2.2 mg/kg ketamine. Buprenorphine was then given for alleviation of pain at 0.01 mg/kg IM. Anesthesia was induced via mask with 2-4% Isoflurane in an air/oxygen mixture of 40-60%. Following intubation, isoflurane was adjusted to maintain a minimum alveolar concentration of 1.2 or greater throughout the experiment. Ventilation was delivered using a volume controlled setting at 6 mL/kg.

Vascular access was obtained using the modified Seldinger technique. The left external vein was accessed for resuscitation fluid administration, while the right external jugular vein was utilized for insertion of a pulmonary artery catheter (Edwards Lifesciences, Irvine, CA, USA). The right carotid was used for blood collection and for invasive blood pressure. The left femoral artery was cannulated with an 8 Fr access sheath in preparation for REBOA deployment. The AAJT (Compression Works, Birmingham, AL) was placed in position under the animal, but not buckled.

3.2 Injury and Intervention

The right femoral artery was isolated by cut-down as previously described for arterial injury.²¹⁻²² A 10 cm-incision was made above the femoral artery. The underlying adductor muscle was excised to provide unrestricted access to the artery. Adventitia was removed and any small branches were either cauterized or ligated. Following a 10-minute incubation in 20 mL of 2% lidocaine to reduce vasospasm, a 6.0 mm-arteriotomy was performed while atraumatic bulldog clamps were placed proximally and distally of the injury site. The start of injury ($t=0$) was initiated by release of the bulldog clamps permitting uncontrolled hemorrhage for 90 seconds. Free bleeding was allowed to continue past the 90 seconds until the MAP reached below 25 mmHg.

Following 30 seconds of free bleeding, the intervention was revealed by the opening of a sealed envelope. If the AAJT was selected, the buckle was fastened and the strap tightened at the end of the injury phase. The windlass was then tightened followed by inflation of the AAJT until 300 mmHg was reached. Throughout the protocol, additional air was pumped into the AAJT if the pressure fell below this value.

If REBOA was selected, a 7 Fr ER-REBOA catheter (Prytime Medical, Boerne, TX) was inserted into the left femoral artery through the prepositioned catheter ~20 cm. Following inflation with saline, the balloon was gently pulled back until resistance was felt corresponding to the bifurcation of the aorta. During model development, this positioning was confirmed to be correctly placed in zone 3 by fluoroscopy. Following inflation of the REBOA balloon or AAJT bladder, a first bolus of 500 mL of Hextend was given.

3.3 End of Intervention and Observation

Fifty-five minutes after injury, a second bolus of 500 mL Hextend was administered. After the full bolus was delivered, all blood samples were taken and the femoral artery was ligated to simulate definitive hemostasis. Both interventions were then slowly removed over 1-2 minutes. The AAJT was slowly deflated using the pressure relief knob and once the AAJT's bladder was deflated, the windlass was released and the AAJT unbuckled. Saline was slowly removed until the REBOA balloon was completely deflated; the catheter was then slowly removed from the vessel. Animals were then observed for two more hours.

Hemostasis was defined as the cessation of bleeding from the femoral wound. Ongoing losses were quantified by suction collecting from outside the wound and weighed. Whole arterial blood samples were taken before surgical manipulation, immediately before initiation of injury, then 10, 30, 60, 90, 120, and 150 minutes after injury. Following euthanasia by IV Pentobarbital at 100 mg/kg, kidney, jejunum, lung, haired skin, and abdominal muscle were collected for routine hematoxylin and eosin staining and microscopic evaluation.

3.4 Outcomes

Primary outcome was survival and hemostasis. Secondary outcomes were hemodynamic and pulmonary parameters including MAP, Cardiac Output (CO), Mean Pulmonary Artery Pressure (MPAP), and other hemodynamic values. Blood gases, chemistries, and other lab values were also considered secondary outcomes including potassium, pH, lactate, hemoglobin, creatinine, creatine kinase (CK), cytokines, and myoglobin. Tissue damage was determined by gross and microscopic examination (H & E) of kidney, abdominal muscle, lung, haired skin, and jejunum.

3.5 Data Analysis

Data is presented as mean \pm standard deviation. Differences between groups was considered significant when $p < 0.05$. Hemodynamic data was automatically captured and used for analysis. Two-way repeated measures analysis of variance was used for continuous variables. T-tests were used for a single time point and continuous variables. Fisher exact test was used for categorical variables. This study was designed as a noninferiority experiment; and power analysis was determined using a noncentral t-distribution of resuscitation fluids of related previous experiments.¹⁸ Using a power of 0.8 and a detectible difference of one standard deviation, 10 animals in each were found to be necessary.

4.0 MAJOR EVENTS/MILESTONES/SUCCESS

- Obtained IACUC approval 8 March 2016
- Experimental procedures completed January 2017
- Abstract acceptance and presentation at 2017 Military Health System Research Symposium (MHSRS)
- Manuscript will be published in June 2018 in the Journal of Surgical Research.

5.0 RISK ASSESSMENT

5.1 Risk Analysis

The procedures involved in this project were common to our lab, and the risk of completion was minimal. However, animal experimentation involves unexpected variability. To address this issue, power analysis was performed prior to the onset of experimentation resulting in 10 animals per group. Midway through experiments, another power analysis was performed that confirmed that the experiment was properly powered. Multiple methods for analyzing the same endpoints (e.g. survival/ hemostasis/blood loss) were also used.

5.2 Technical Challenges

All experiments in this project went as planned. No deviations in protocol were necessary.

6.0 TRANSITION PLAN

6.1 Military Relevance

More than 90% of potentially survivable battlefield deaths are associated with hemorrhage.³ Effective and rapid methods to stop hemorrhage will lead to improved prehospital and en route care. The studies presented here aim to address the current treatment gap of these casualties, to learn how each product should be used on and off the battlefield and share that knowledge with the combat casualty care community.

Air Force Medical Service (AFMS) Capability Gap: 2015 CBA (Research to Knowledge/RTK) 13 Air Mobility Command (AMC) supported Advanced Point of Injury (POI) and En Route Care (ERC) Resuscitation: “Lack research on advanced point of injury and ERC resuscitation.”

6.2 Transition Strategy

Using the Commercial Off-The-Shelf (COTS) AAJT and REBOA to occlude blood flow in junctional regions and the descending aorta, this study investigated the efficacy of each product in an established swine model of iliac artery injury (to model lethal pelvic injury in warfighters). Knowledge Products generated by this study will inform feasibility and practicability of either REBOA or AAJT use on injured warfighters with pelvic hemorrhage, toward increasing the effectiveness of point of injury treatment in pre-hospital settings. Generated evidence regarding efficacy of REBOA and the AAJT with respect to improving patient outcomes will inform research on advanced Point of Injury (POI) and en route resuscitation.

7.0 RESULTS

7.1 Baseline Characteristics

Twenty-five animals were entered into the study with 10 animals per treatment group and 5 animals for model development. Baseline values were similar between groups with no significant differences except animal weight (Table 1). The animals selected for AAJT-treatment weighed

more than the REBOA-treated animals despite allocation concealment. Overall, the animals weighed 78.3 ± 6.6 kg, MAP was 64.4 ± 5.5 mmHg, and HR was 79 ± 14 bpm before injury. Table 1

Baseline Values

	AAJT	REBOA	p-value
<i>n</i>	10	10	
Weight	81.9 ± 7.1	74.7 ± 3.6	0.01*
MAP – carotid (mmHg)	65.3 ± 6.0	63.6 ± 5.4	0.517
MAP – femoral (mmHg)	63.8 ± 5.6	63.7 ± 6.5	0.967
Heart Rate (bpm)	79.6 ± 14.1	79.8 ± 15.6	0.975
EtCO ₂ (mmHg)	42.1 ± 1.8	43.7 ± 2.3	0.109
Lactate	1.72 ± 0.60	1.52 ± 0.23	0.34
Hemoglobin	9.64 ± 0.56	9.59 ± 0.77	0.870
EBV (mL)	5324 ± 461	4856 ± 235	0.01*
Pretreatment Blood Loss (g)	1628 ± 348	1551 ± 295	0.60
Pretreatment Blood Loss (%)	30.5 ± 5.6	31.8 ± 5.4	0.60
Hemorrhage time (s)	124 ± 47	115 ± 43	0.68
Uncontrolled hemorrhage time (s)	124 ± 47	115 ± 43	0.682
MAP at intervention (mmHg)	25.1 ± 4.1	22.1 ± 4.8	0.148

* p < 0.05

7.2 Injury and Intervention

At the end of the femoral artery injury, no significant differences were observed between groups (Table 2). The time of free bleed was not significantly different between groups (119 ± 44 s). The injury resulted in an overall loss of 1499 ± 299 mL of blood loss or $29.4 \pm 5.1\%$ estimated blood volume (EBV) which caused a carotid MAP at intervention of 23.6 ± 4.6 mmHg. Application time, as measured by time for treatment delivery after preplacement, was significantly different between groups with the insertion of REBOA being significantly faster than application of the AAJT ($p= 0.022$).

All animals survived the lethal injury after hemostatic intervention. Both groups had a slow hemorrhage from the wound that resulted in 386 ± 369 mL of blood loss or $7.5 \pm 7.1\%$ EBV following intervention that typically reached spontaneous hemostasis (no blood escaping from wound) at 31 ± 18 min with no significant differences between groups (Table 2). After 60 minutes of intervention, the femoral artery was ligated and the REBOA balloon or the AAJT air bladder was slowly deflated. One animal from the REBOA group died shortly after deflation, but all others survived until the end of the two-hour observation period.

Table 2

Post-treatment Values

	AAJT	REBOA	P-value
Uncontrolled hemorrhage time (s)	124 ± 47	115 ± 43	0.682
MAP at intervention	25.1 ± 4.1	22.1 ± 4.8	0.148
Post-treatment blood loss (g)	422 ± 433	397 ± 368	0.596
Post-treatment blood loss (%)	7.9 ± 8.1	8.1 ± 7.3	0.892
Application time (s)	96 ± 43	60 ± 13	0.022*
Time to reach hemostasis (min)	25.6 ± 17.6	37.0 ± 18.1	0.182

* p < 0.05

7.3 Hemodynamic and Pulmonary Parameters

No significant differences were observed between groups with respect to HR, MPAP, EtCO₂, CO, SpO₂, SVO₂, or CVP over the entire experimental procedures (Figure 3). As expected from a severe arterial injury, carotid MAP, femoral MAP, EtCO₂, MPAP, and SVR all rapidly decreased following injury in both groups. Cardiac output (CO) also decreased, but this effect was delayed compared to the other factors. During the intervention, MAP from both the carotid and the femoral artery were significantly higher in the AAJT group ($p = 0.025$ and $p = 0.009$ respectively). Peak Inspiratory Pressure (PIP) was significantly different between groups with the AAJT-treated animals displaying higher pressures than REBOA-treated animals during intervention ($p = 0.013$), but no significant differences were observed between groups with respect to FiO₂/PaO₂ ratio (Figure 4). While heart rate was not significantly different between groups, repeated measures ANOVA approached significance with the AAJT-treated animals having a faster heart rate than the REBOA-treated animals ($p = 0.054$). Likewise, MPAP was higher in the AAJT group ($p = 0.069$).

Following intervention removal, MAP and SVR initially fell in both groups but increased shortly thereafter (Figure 3). Interestingly, both groups saw a substantial drop in SpO₂ during this transient hypotension approximately five minutes after removal of the device with some animals going below 80% oxygenation (Figure 4). MPAP and CO were transiently elevated following the intervention removal, but no significant differences were observed between groups.

7.4 Lab Values

Arterial blood gas values were compared between groups (Figure 5). Potassium levels, pH, and base excess were not significantly different between groups. However, lactate levels were significantly higher with AAJT than REBOA starting at 30 minutes following injury ($p = 0.022$). Both groups appeared to clear lactate at the same rate, although the slope of clearance of the AAJT arm stayed elevated above the REBOA arm. Hemoglobin values were significantly different between groups with AAJT-treated animals having a higher concentration than the REBOA-treated animals ($p = 0.029$). Both groups saw a drop in pH and base excess shortly after

intervention removal, but both returned to near pre injury levels by the end of the observation period with no statistically significant differences between groups.

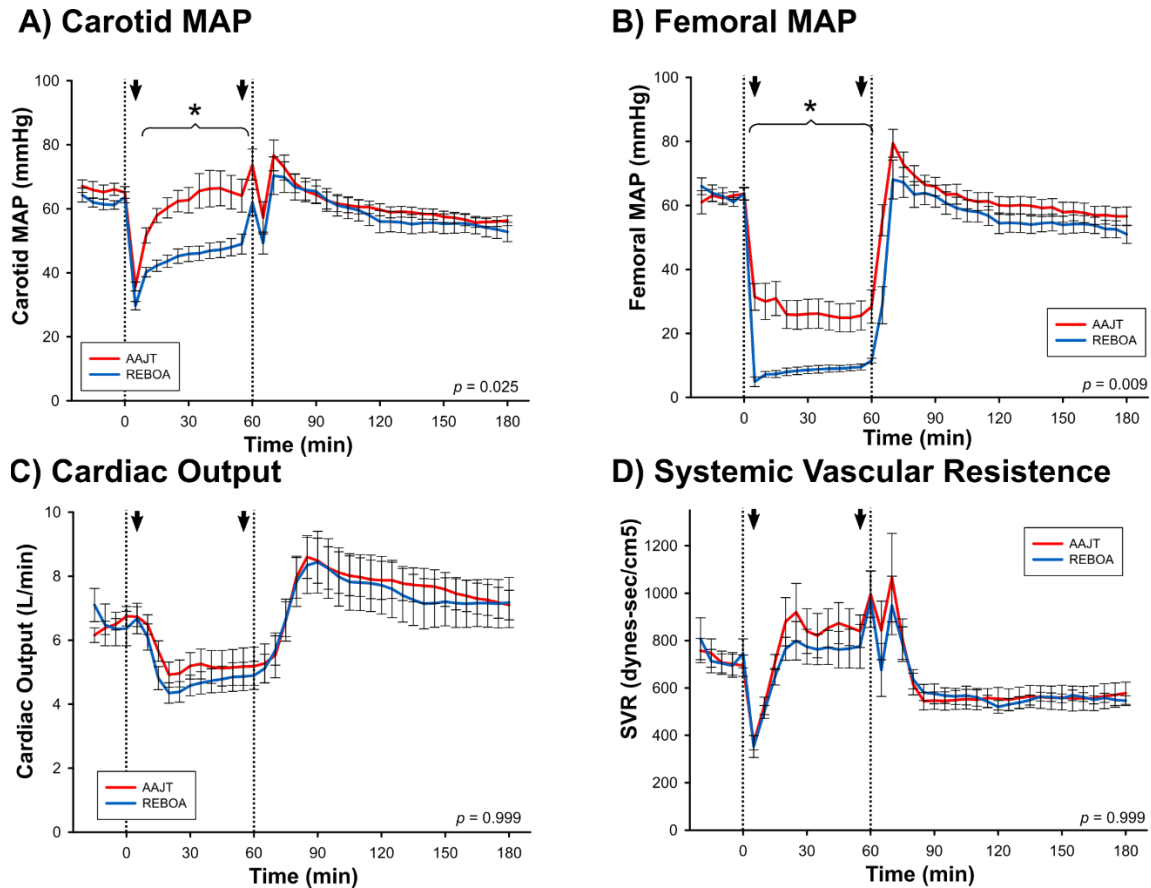


Figure 3. Multi-Panel Hemodynamics

*Figure (A) Carotid Mean Arterial Pressure, MAP (B) Femoral Artery MAP (C) Cardiac output, CO (D) Systemic Vascular Resistance, SVR. Dotted lines correspond to application or removal of intervention. Arrows correspond to Hextend bolus. All plotted values are mean and standard error of the mean. P-values are shown from repeated measures ANOVA. * post hoc of $p < 0.05$.*

Inflammatory cytokines are both a marker for trauma and ischemic-reperfusion injury. We examined levels of IL-6, IL-1b, IL-10, and TNF α prior to injury, at the end of intervention, and at the end of the two hour observation period (Table 3). No significant differences were observed between groups. Interestingly, no differences in cytokine levels were observed when comparing baseline values with either end of intervention or end of observation.

Markers of end organ dysfunction were also compared. No significant differences between groups at the end of the study were observed with blood urea nitrogen (BUN), alanine transaminase (ALT), aspartate aminotransferase (AST), creatinine, creatine kinase (CK). The level of AST at the end of intervention was significantly different between groups, but the

magnitude of difference was minimal (Table 3). There was no difference between groups in the microscopic evaluation of lung, kidney, jejunum, haired skin, or abdominal muscle.

Table 3

Lab Values

	AAJT	REBOA	p-value
Baseline (T0)			
IL-1B (ng/ml)	0.44 ± 0.93	0.22 ± 0.15	0.486
IL-6 (ng/ml)	0.23 ± 0.44	0.103 ± 0.049	0.442
IL-10 (ng/ml)	0.73 ± 1.8	0.27 ± 0.34	0.454
TNFα (ng/ml)	49 ± 33	53 ± 25	0.748
BUN (mEq/L)	9.3 ± 1.9	8.9 ± 1.8	0.907
Creatinine (mg/dL)	1.2 ± 0.2	1.1 ± 0.2	0.162
ALT (mg/dL)	36 ± 6.6	34 ± 7.1	0.558
AST (U/L)	20 ± 5.0	18 ± 2.6	0.193
Creatinine Kinase (U/L)	508 ± 144	461 ± 201	0.550
Myoglobin (ng/ml)	45 ± 20	33 ± 18	0.209
End of Intervention (T60)			
IL-1B (ng/ml)	0.48 ± 1.0	0.18 ± 0.09	0.397
IL-6 (ng/ml)	0.24 ± 0.50	0.097 ± 0.033	0.422
IL-10 (ng/ml)	0.81 ± 2.1	0.21 ± 0.24	0.401
TNFα (ng/ml)	48 ± 33	48 ± 32	0.982
BUN (mEq/L)	10 ± 2.2	10 ± 1.9	0.999
Creatinine (mg/dL)	1.3 ± 0.2	1.2 ± 0.3	0.596
ALT (mg/dL)	22 ± 4.1 [#]	20 ± 4.8 [#]	0.283
AST (U/L)	14 ± 3.1 [#]	12 ± 2.4 [#]	0.043 [*]
Creatinine Kinase (U/L)	317 ± 112	268 ± 128 [#]	0.378
Myoglobin (ng/ml)	50 ± 39	30 ± 16	0.180
End of Study (T180)			
IL-1B (ng/ml)	0.66 ± 1.4	0.12 ± 0.11	0.387
IL-6 (ng/ml)	0.30 ± 0.66	0.12 ± 0.11	0.420
IL-10 (ng/ml)	0.82 ± 2.1	0.23 ± 0.27	0.421
TNFα (ng/ml)	52 ± 33	40 ± 30	0.417
BUN (mEq/L)	12 ± 4.6	14 ± 2.8 [#]	0.379
Creatinine (mg/dL)	1.7 ± 0.4 [#]	1.5 ± 0.3 [#]	0.303
ALT (mg/dL)	25 ± 5.0	25 ± 4.8	0.778
AST (U/L)	28 ± 24	20 ± 6.5	0.321
Creatinine Kinase (U/L)	891 ± 1320	606 ± 337	0.538
Myoglobin (ng/ml)	226 ± 127 [#]	271 ± 195 [#]	0.555

* p < 0.05; #, p < 0.01 vs BL

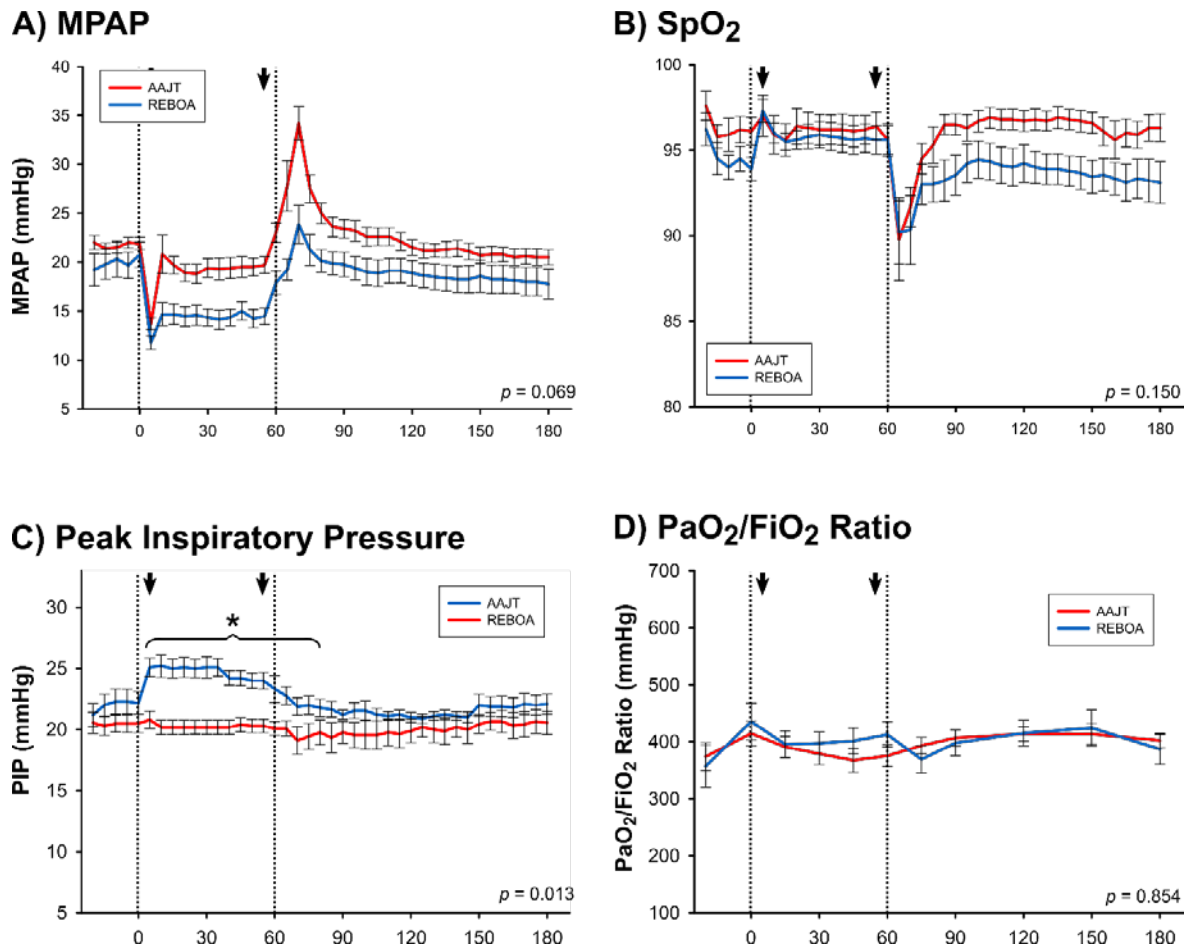


Figure 4. Multi-Panel Pulmonary Figure

*(A) Mean pulmonary artery pressure, MPAP (B) Capillary oxygen saturation, SpO₂ (C) Pulmonary Inspiratory Pressure (D) PaO₂:FiO₂ Ratio. Dotted lines correspond to application or removal of intervention. Arrows correspond to Hextend bolus. All plotted values are mean and standard error of the mean. P-values are shown from repeated measures ANOVA. * post hoc of $p < 0.05$.*

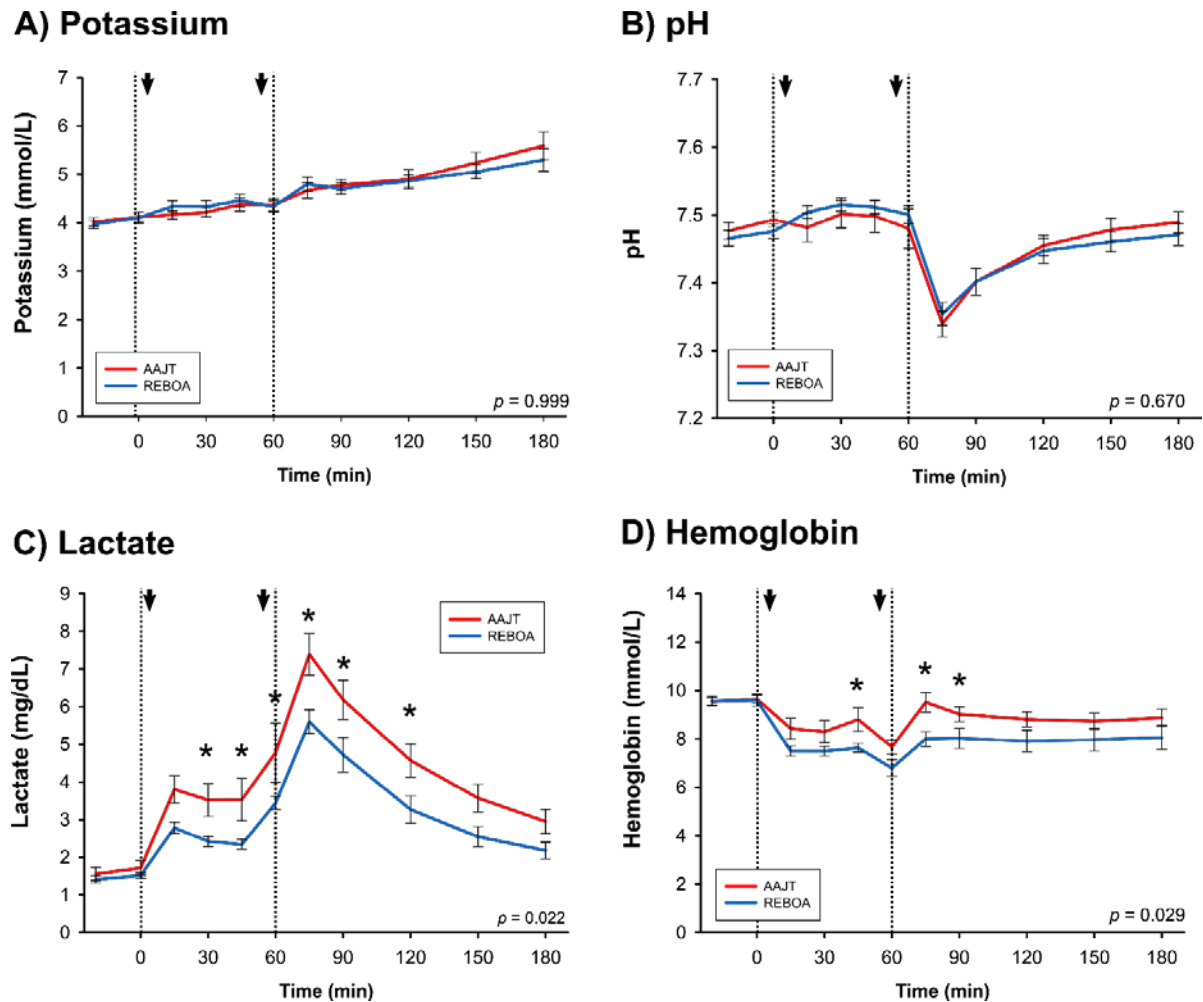


Figure 5. Multi-panel of Blood Properties (A) Potassium (B) pH (C) Lactate (D) Hemoglobin. Dotted lines correspond to application or removal of intervention. Arrows correspond to Hextend bolus. All plotted values are mean and standard error of the mean. P-values are shown from repeated measures ANOVA. * post hoc of $p < 0.05$.

8.0 DISCUSSION

The current study demonstrates that in a porcine model of uncontrolled hemorrhage, the AAJT and zone 3 REBOA deliver similar hemostatic efficacy. This is accompanied by a comparable hemodynamic and pulmonary profile, with the exception of an increased inspiratory pressure observed during AAJT use. This phenomenon does not have a significant effect on oxygenation or other pulmonary indices. Both techniques achieved improvements in proximal perfusion via an increase in systemic vascular resistance. Based on this study, the decision to use either technique will be largely based on factors that are independent of the technique such as injury pattern, provider training and clinical capability.

The current study confirms and extends the current evidence base for hemostatic interventions in traumatic hemorrhage. Rall et al. previously characterized the physiological effects of AAJT in a model of controlled hemorrhage.¹⁴ In a group of hypotensive and normotensive animals, the AAJT was applied to half of the subjects. This study demonstrated a reduction in flow in the femoral artery and an improvement in proximal blood pressure largely due to afterload support. Crucially, no adverse effects were noted from caval compression or direct pressure on organs such as the intestine. These findings have been confirmed by the current study, this time using a model of uncontrolled hemorrhage.

Other investigators have also examined the use of the AAJT using large animal models of controlled hemorrhage. Kheirabadi et al. performed a study where female pigs (45-55kg) were utilized to compare spontaneously breathing and ventilated animals after a 25% EBV hemorrhage.¹⁹ Their results showed the AAJT controlled the lethal junctional hemorrhage, but spontaneously breathing subjects require ventilator support after two-hour AAJT application. Tissue injury biomarkers were elevated after this extended application, but pulmonary indices were largely unaffected during AAJT use in this study.

Laboratory research into REBOA has similarly seen a proliferation in recent years. However, investigators have predominantly focused on zone 1 occlusion which is associated with greater physiological sequelae. One of the few zone 3 studies used a similar injury model, but located in the iliac artery. Morrison et al. compared the efficacy of combat gauze to zone 3 REBOA in groups with and without coagulopathy.¹⁸ These investigators demonstrated that the hemostasis achieved with REBOA was independent of coagulopathy, unlike combat gauze which was dependent on a normal coagulation profile.

Clinical evidence is also sparse for both adjuncts. The use of the AAJT is still confined to case reports, which while promising, are far from conclusive. The experience of REBOA is much larger and a recent systematic review by Morrison et al., identified 41 studies reporting on the use of aortic occlusion in torso hemorrhage.²³ The only consistent finding related to the elevation of central blood pressure following aortic occlusion. At the time of publication in 2016, there was no evidence of a reduction in mortality with REBOA. This has prompted the funding of the UK-REBOA trial which is a multicenter, prospective, randomized trial assessing the standard-of-care versus the standard-of-care plus REBOA. This trial is due to report in 2020.

Application time between the two modalities was found to be statistically significant in favor of REBOA ($p=0.022$). However, there was some artificiality in the lab environment. The AAJT was placed underneath the swine and a femoral percutaneous introducer sheath was placed in every animal, before the arteriotomy was performed. This decision was made as the animal's randomization was unmasked during the bleeding procedure and the authors did not know which procedure would be undertaken prior to the arteriotomy. In this study, The REBOA catheter simply had to be floated to Zone 3 and inflated, while the AAJT had to be buckled and then inflated. The inflation phase of the AAJT took the most time. Thus the time comparisons are only true when the patient has been prepared in the laboratory setting.

The AAJT has a relatively low training burden, with operators trained within hours on how to apply the device effectively. The device is specifically designed for pre-hospital practitioners and it does not require a physician. Conversely, REBOA has a far greater training burden, as well as a need to maintain skills. Currently, REBOA is a physician-only procedure, requiring attendance of a course such as the Basic Endovascular Skills for Trauma (BEST™) course.²⁴ This provider-need limits the pre-hospital use of REBOA, unless such systems incorporate a pre-hospital physician, which is common practice in the UK and Europe, but less so in the US.

Training proficiency is linked to safety and certainly the more invasive a procedure, the greater the risk of complications. The AAJT carries a relatively low risk profile, with no reported complications within the literature, although this is sparse. REBOA has a much greater published experience and the morbidity associated with the procedure is better quantified. The systematic review by Morrison et al. reported an overall morbidity rate of 3.7%, with an amputation rate of 0.8%. However, access related complications are likely to become less frequent as smaller caliber REBOA systems become available.²³ Teeter et al. reported on an institutional experience moving from a 12 Fr to a 7 Fr system, which saw no access related complications in the 7 Fr group.²⁵

The greatest issue relating to deployment of the AAJT or REBOA is appropriate patient selection, which is dependent upon injury pattern. While both techniques appear to have similar hemostatic effect, proximal blood pressure is also increased, which is likely beneficial unless there is also a source of hemorrhage proximal to device. As an example, in a patient with a pelvic fracture and splenic injury, the application of either the AAJT or zone 3 REBOA is likely to increase the bleeding from the spleen.

This represents a major issue, as in both civilian and military cohorts of hypotensive trauma patients, a substantial number of patients have a mixed injury pattern which includes a pelvic injury and an abdominal visceral or vascular component. An analysis of military casualties determined that one-in-five combat casualties had a hemorrhagic focus in their torso that might be amenable to REBOA.²⁶ The ratio of zone 1 (thoracic) to zone 3 (infrarenal) suitability in patients dying en-route to a medical facility was 3:2, suggesting that the majority of patients had an abdominal component to their torso hemorrhage. A similar analysis of a UK civilian population had a zone 1: zone 3 ratio of 2:1, again suggesting a significant burden of abdominal injury.²⁷

Harvin and co-workers recently analyzed 1,706 patients undergoing trauma laparotomy in 12 level 1 trauma centers.²⁷⁻²⁸ Those investigators demonstrated a mortality of 46% in hypotensive patients, where 80% of deaths occurred within the first hour and 65% were due to hemorrhage. Visceral trauma (liver, kidney, spleen) was noted in 60% of these patients, along with 27% with a major vascular injury. While this group represents the population where a pre-operating room hemorrhage control intervention might have helped achieve temporary hemostasis, the majority would have required a zone 1 REBOA.

Generally, the AAJT is considered a pre-hospital intervention while REBOA currently has limited pre-hospital employment. When considering pre-hospital hemorrhage control, it may be beneficial to consider the use of both techniques as a potential clinical pathway. Given the short time required to place the AAJT, it may be the ideal initial intervention for the hypotensive trauma patient meeting criteria for zone 3 REBOA. This would then be followed by vascular access and balloon deployment. Also, many pre-hospital physicians are not surgeons and while very comfortable with ultrasound guided percutaneous vascular access, they may have poor proficiency at femoral artery open cut down. Dubose et al., showed in their AORTA registry that nearly 50% of patients receiving REBOA required vascular cut down to place the vascular sheath.²⁹ The AAJT may be a reasonable intervention as a failure pathway for providers not successful with percutaneous access and not capable of open vascular access.

This study has a number of limitations to discuss. One such limitation is that the effect each product had on spontaneous breathing cannot be determined as ventilated animals were used throughout the entire study. Another limitation is in utilizing femoral ligation instead of vascular repair following treatment may have resulted in a different reperfusion injury profile. However, this study aimed to address each product's direct effect on physiologic outcomes and not be masked by ischemia-reperfusion injury. Finally, a true comparison of timing of each product was not performed. We chose to pre-apply each product to a level where the time of hemostasis, if any would occur, would be nearly equivalent allowing for the same level of hemorrhagic shock to more accurately compare the products.

In aggregate, the AAJT and zone 3 REBOA compared in this current study appear to perform well as a hemostatic and resuscitative maneuver. The AAJT has a much lower training requirement than REBOA and can be used by a greater number of providers, but its application is limited to isolated pelvic or junctional trauma; whereas REBOA can be escalated to zone 1, controlling abdominal hemorrhage. The challenge of pre-hospital use relates to correctly identifying these patients, which is largely reliant on understanding the mechanism of injury, how the patients physiology responds to intervention and using judgement to balance the risk of intervention.

Both the AAJT and zone 3 REBOA achieve effective hemostasis in a model of uncontrolled junctional hemorrhage. Further study is required in order to better define where these hemorrhage control and resuscitation adjuncts fit within the clinical paradigm.

9.0 DELIVERABLES

9.1 Publications

Rall JM, Redman TT, Ross EM, Morrison JJ, Maddry JK. Comparison of Zone 3 Resuscitative Endovascular Balloon Occlusion of the Aorta and the Abdominal Aortic and Junctional Tourniquet in a Model of Junctional Hemorrhage in Swine. *Journal of Surgical Research*, June 2018 (226) 31-39.

9.2 Presentations

Rall JM, Redman TT, Ross EM, Morrison JJ, Maddry JK (2017) Comparison of Zone 3 Resuscitative Balloon Occlusion of the Aorta (REBOA) and the Abdominal Aortic and Junctional Tourniquet (AAJT) in a Model of Non-Compressible Pelvic Hemorrhage in Swine. 2017 Military Health System Research Symposium

10.0 COST

This project shared funds with the Air Force Medical Support Agency (AFMSA) funded project “A Comparison of Mechanical Ventilation Methods in Transport of Critically Injured and Ill Patients by CCATT – Validation of Current CPG and Description of Current Ventilation Approaches” (Mechanical Vent). The REBOA v AAJT project received and executed \$57,000 of FY15 funds.

11.0 REFERENCES

1. Butler, F.K., Jr. and L.H. Blackburne, *Battlefield trauma care then and now: a decade of Tactical Combat Casualty Care*. J Trauma Acute Care Surg, 2012. 73(6 Suppl 5): p. S395-402.
2. Davis, J.S., et al., *An analysis of prehospital deaths: Who can we save?* J Trauma Acute Care Surg, 2014. 77(2): p. 213-8.
3. Eastridge, B.J., et al., *Death on the battlefield (2001-2011): implications for the future of combat casualty care*. J Trauma Acute Care Surg, 2012. 73(6 Suppl 5): p. S431-7.
4. Chang, R., B.J. Eastridge, and J.B. Holcomb, *Remote Damage Control Resuscitation in Austere Environments*. Wilderness Environ Med, 2017. 28(2S): p. S124-S134.
5. Rodrigues, R.R., M.J. Carmona, and J.O. Junior, *Bleeding and damage control surgery*. Curr Opin Anaesthesiol, 2016. 29(2): p. 229-33.
6. van Oostendorp, S.E., E.C. Tan, and L.M. Geeraedts, Jr., *Prehospital control of life-threatening truncal and junctional haemorrhage is the ultimate challenge in optimizing trauma care; a review of treatment options and their applicability in the civilian trauma setting*. Scand J Trauma Resusc Emerg Med, 2016. 24(1): p. 110.
7. White, C.E., J.R. Hsu, and J.B. Holcomb, *Haemodynamically unstable pelvic fractures*. Injury, 2009. 40(10): p. 1023-30.
8. Bennett, B.L. and L. Littlejohn, *Review of new topical hemostatic dressings for combat casualty care*. Mil Med, 2014. 179(5): p. 497-514.
9. Kragh, J.F., et al., *Performance of Junctional Tourniquets in Normal Human Volunteers*. Prehosp Emerg Care, 2015. 19(3): p. 391-8.
10. Mueller, G.R., et al., *A novel sponge-based wound stasis dressing to treat lethal noncompressible hemorrhage*. J Trauma Acute Care Surg, 2012. 73(2 Suppl 1): p. S134-9.
11. Peev, M.P., et al., *Self-expanding foam for prehospital treatment of severe intra-abdominal hemorrhage: dose finding study*. J Trauma Acute Care Surg, 2014. 76(3): p. 619-23; discussion 623-4.
12. Croushorn, J., G. Thomas, and S.R. McCord, *Abdominal aortic tourniquet controls junctional hemorrhage from a gunshot wound of the axilla*. J Spec Oper Med, 2013. 13(3): p. 1-4.
13. Lyon, M., et al., *Use of a novel abdominal aortic tourniquet to reduce or eliminate flow in the common femoral artery in human subjects*. J Trauma Acute Care Surg, 2012. 73(2 Suppl 1): p. S103-5.
14. Rall, J.M., et al., *Hemodynamic effects of the Abdominal Aortic and Junctional Tourniquet in a hemorrhagic swine model*. J Surg Res, 2017. 212: p. 159-166.
15. Taylor, D.M., M. Coleman, and P.J. Parker, *The evaluation of an abdominal aortic tourniquet for the control of pelvic and lower limb hemorrhage*. Mil Med, 2013. 178(11): p. 1196-201.
16. Gupta, B.K., et al., *The role of intra-aortic balloon occlusion in penetrating abdominal trauma*. J Trauma, 1989. 29(6): p. 861-5.
17. Irahara, T., et al., *Retrospective study of the effectiveness of Intra-Aortic Balloon Occlusion (IABO) for traumatic haemorrhagic shock*. World J Emerg Surg, 2015. 10(1): p. 1.

18. Morrison, J.J., et al., *Aortic balloon occlusion is effective in controlling pelvic hemorrhage*. J Surg Res, 2012. 177(2): p. 341-7.
19. Kheirabadi, B.S., et al., *Physiological Consequences of Abdominal Aortic and Junctional Tourniquet (AAJT) Application to Control Hemorrhage in a Swine Model*. Shock, 2016. 46(3 Suppl 1): p. 160-6.
20. National Research, C., *Guide for the Care and Use of Laboratory Animals: Eighth Edition*. 1996, Washington, DC: The National Academies Press. 246.
21. Kheirabadi, B.S., et al., *Development of a standard swine hemorrhage model for efficacy assessment of topical hemostatic agents*. J Trauma, 2011. 71(1 Suppl): p. S139-46.
22. Rall, J.M., et al., *Comparison of novel hemostatic dressings with QuikClot combat gauze in a standardized swine model of uncontrolled hemorrhage*. J Trauma Acute Care Surg, 2013. 75(2 Suppl 2): p. S150-6.
23. Morrison, J.J., et al., *A systematic review of the use of resuscitative endovascular balloon occlusion of the aorta in the management of hemorrhagic shock*. J Trauma Acute Care Surg, 2016. 80(2): p. 324-34.
24. Brenner, M., et al., *Basic endovascular skills for trauma course: bridging the gap between endovascular techniques and the acute care surgeon*. J Trauma Acute Care Surg, 2014. 77(2): p. 286-91.
25. Teeter, W.A., et al., *Smaller introducer sheaths for REBOA may be associated with fewer complications*. J Trauma Acute Care Surg, 2016. 81(6): p. 1039-1045.
26. Morrison, J.J., et al., *Resuscitative endovascular balloon occlusion of the aorta: a gap analysis of severely injured UK combat casualties*. Shock, 2014. 41(5): p. 388-93.
27. Barnard, E.B., et al., *Resuscitative endovascular balloon occlusion of the aorta (REBOA): a population based gap analysis of trauma patients in England and Wales*. Emerg Med J, 2015. 32(12): p. 926-32.
28. Harvin, J.A., et al., *Mortality after emergent trauma laparotomy: A multicenter, retrospective study*. J Trauma Acute Care Surg, 2017. 83(3): p. 464-468.
29. DuBose, J.J., et al., *The AAST prospective Aortic Occlusion for Resuscitation in Trauma and Acute Care Surgery (AORTA) registry: Data on contemporary utilization and outcomes of aortic occlusion and resuscitative balloon occlusion of the aorta (REBOA)*. J Trauma Acute Care Surg, 2016. 81(3): p. 409-19.

12.0 APPENDIX

12.1 Tables

- Table 1 Baseline Values
Table 2 Post-trauma Values
Table 3 Laboratory Values

12.2 Figures

- Figure 1 Test Products
Figure 2 Experimental Schematic
Figure 3 Multipanel Hemodynamics
Figure 4 Multipanel Pulmonary
Figure 5 Multipanel Blood Properties

12.3 List of Symbols, Abbreviations and Acronyms

AAALAC	Association for Assessment and Accreditation of Laboratory Animal Care
AAJT	Abdominal Aortic and Junctional Tourniquet
AFMS	Air Force Medical Service
AFMSA	Air Force Medical Support Agency
AMC	Air Mobility Command
ANOVA	Analysis of Variance
ALT	Alanine Transaminase
AST	Aspartate Aminotransferase
BEST	Basic Endovascular Skills for Trauma Course
BUN	Blood Urea Nitrogen
CBA	Capabilities Based Assessment
CK	Creatine Kinase
CO	Cardiac Output
COTS	Commercial Off-the-Shelf
CVP	Central Venous Pressure
DBP	Diastolic Blood Pressure
EBV	Estimated Blood Volume
ERC	En-Route Care
EtCO ₂	End Tidal Carbon Dioxide
FiO ₂	Fraction of inspired oxygen
H & E	Hematoxylin and Eosin stain
IACUC	Institutional Animal Care and Use Committee
IL-6	Interleukin 6
IL-1b	Interleukin 1-beta
IL-10	Interleukin 10
MAP	Mean Arterial Pressure
MHSRS	Military Health System Research Symposium
MPAP	Mean Pulmonary Artery Pressure

PaO ₂	Dissolved Oxygen in Arterial Blood
PIP	Peak Inspiratory Pressure
POI	Point of Injury
REBOA	Resuscitative Endovascular Balloon Occlusion of the Aorta
RTK	Research to Knowledge
SBP	Systolic Blood Pressure
SpO ₂	Arterial Oxygen Saturation
SVO ₂	mixed venous saturation of oxygen
SVR	Systemic Vascular Resistance
TCA	Traumatic Cardiac Arrest
TNF α	Tumor Necrosis Factor Alpha