

AWARD NUMBER: W81XWH-13-1-0501

TITLE: Novel Therapy for Bone Regeneration in Large Segmental Defects

PRINCIPAL INVESTIGATOR: Tien-Min Chu

CONTRACTING ORGANIZATION: Indiana University  
Indianapolis, IN 46202-5211

REPORT DATE: December 2017

TYPE OF REPORT: Final Report

PREPARED FOR: U.S. Army Medical Research and Materiel Command  
Fort Detrick, Maryland 21702-5012

DISTRIBUTION STATEMENT:

Approved for public release; distribution unlimited

The views, opinions and/or findings contained in this report are those of the author(s) and should not be construed as an official Department of the Army position, policy or decision unless so designated by other documentation.

REPORT DOCUMENTATION PAGE				Form Approved OMB No. 0704-0188	
Public reporting burden for this collection of information is estimated to average 1 hour per response, including the time for reviewing instructions, searching existing data sources, gathering and maintaining the data needed, and completing and reviewing this collection of information. Send comments regarding this burden estimate or any other aspect of this collection of information, including suggestions for reducing this burden to Department of Defense, Washington Headquarters Services, Directorate for Information Operations and Reports (0704-0188), 1215 Jefferson Davis Highway, Suite 1204, Arlington, VA 22202-4302. Respondents should be aware that notwithstanding any other provision of law, no person shall be subject to any penalty for failing to comply with a collection of information if it does not display a currently valid OMB control number. <b>PLEASE DO NOT RETURN YOUR FORM TO THE ABOVE ADDRESS.</b>					
1. REPORT DATE December 2017		2. REPORT TYPE Final Report		3. DATES COVERED 30Sept2013 - 29Sept2017	
4. TITLE AND SUBTITLE  Novel Therapy for Bone Regeneration in Large Segmental Defects				5a. CONTRACT NUMBER W81XWH-13-1-0501	
				5b. GRANT NUMBER OR120080P2	
				5c. PROGRAM ELEMENT NUMBER	
6. AUTHOR(S) Melissa Kacena, Todd McKinley, Tien-Min Chu  E-Mail: <a href="mailto:mkacena@iupui.edu">mkacena@iupui.edu</a> ; <a href="mailto:tgchu@iupui.edu">tgchu@iupui.edu</a> ; <a href="mailto:tmckinley@IUHealth.org">tmckinley@IUHealth.org</a>				5d. PROJECT NUMBER	
				5e. TASK NUMBER	
				5f. WORK UNIT NUMBER	
7. PERFORMING ORGANIZATION NAME(S) AND ADDRESS(ES)  Indiana University 980 Indiana Ave. RM 2232 Indianapolis, IN 46202-5130				8. PERFORMING ORGANIZATION REPORT NUMBER	
9. SPONSORING / MONITORING AGENCY NAME(S) AND ADDRESS(ES)  U.S. Army Medical Research and Materiel Command Fort Detrick, Maryland 21702-5012				10. SPONSOR/MONITOR'S ACRONYM(S)	
				11. SPONSOR/MONITOR'S REPORT NUMBER(S)	
12. DISTRIBUTION / AVAILABILITY STATEMENT  Approved for Public Release; Distribution Unlimited					
13. SUPPLEMENTARY NOTES					
14. ABSTRACT <b>The purpose</b> of this study is to test the efficacy of thrombopoietin (TPO) to heal a segmental bone defect (SBD) in a large animal model, the minipig. <b>The scope</b> of the research comprises the following specific aims (i) to determine the union rate of tibial midshaft defects in minipigs treated with BMP-2, TPO, or saline control; and (ii) to evaluate the safety and side effects of treating tibial midshaft defects in minipigs treated with BMP-2, TPO, or saline control. Over the course of our study we completed surgeries on 51 minipigs. Three minipigs were used to develop our model. Of the others, 24 had a 25mm defect and were fixed with an IM nail, 12 had a 25mm defect and were fixed with a compression plate, and 12 had a 40mm defect and were also fixed with a compression plate. Perhaps the two <b>most significant findings</b> are: 1) we discovered that fixation type (IM nail vs. compression plates) impacts the size requirement for a critical size defect, and 2) although the dose and timing may not yet be optimized, TPO can heal bone defects in pigs and is able to more rapidly allow for bone healing than observed in saline treated controls. Further, no toxic effects were observed, and although additional analyses remain to be completed, TPO and BMP-2 appear to work by different mechanisms to elicit bone healing.					
15. SUBJECT TERMS Bone healing, bone morphogenetic protein (BMP), thrombopoietin (TPO), therapy, fracture healing, bone regeneration, minipig, pig					
16. SECURITY CLASSIFICATION OF:			17. LIMITATION OF ABSTRACT  Unclassified	18. NUMBER OF PAGES  64	19a. NAME OF RESPONSIBLE PERSON USAMRMC
a. REPORT  Unclassified	b. ABSTRACT  Unclassified	c. THIS PAGE  Unclassified			19b. TELEPHONE NUMBER (include area code)

## Table of Contents

	<u>Page</u>
<b>1. Introduction.....</b>	<b>4</b>
<b>2. Keywords.....</b>	<b>4</b>
<b>3. Overall Project Summary.....</b>	<b>4-7</b>
<b>4. Key Research Accomplishments.....</b>	<b>7-18</b>
<b>5. Conclusion.....</b>	<b>19</b>
<b>6. Publications, Abstracts, and Presentations.....</b>	<b>20</b>
<b>7. Inventions, Patents and Licenses.....</b>	<b>20</b>
<b>8. Reportable Outcomes.....</b>	<b>10</b>
<b>9. Other Achievements.....</b>	<b>10</b>
<b>10. References.....</b>	<b>10</b>
<b>11. Appendices.....</b>	<b>22-64</b>

**1. INTRODUCTION:** The **subject** of this research is the need for improved treatment of segmental bone defects. The **purpose** of this study is to test the efficacy of thrombopoietin (TPO) to heal a segmental bone defect (SBD) in a large animal model, the minipig. The **scope** of the research comprises the following specific aims (i) to determine the union rate of tibial midshaft defects in minipigs treated with BMP-2, TPO, or saline control; and (ii) to evaluate the safety and side effects of treating tibial midshaft defects in minipigs treated with BMP-2, TPO, or saline control.

**2. KEYWORDS:** Bone healing, bone morphogenetic protein (BMP), thrombopoietin (TPO), therapy, fracture healing, bone regeneration, minipig, pig

### **3. OVERALL PROJECT SUMMARY:**

Project start date 30/09/2013

Project end date 29/09/2017 (with 1 year NCE)

**Task 1 and Milestone 1.** Obtain Regulatory Approvals – Completed by **Drs. Kacena, Chu, and McKinley** (led by **Dr. Kacena**).

<u>Initial projected timeline</u>	<u>Actual timeline</u>
1-3 months original SOW	1-3 months
35 months revised SOW	36-37 months

**Task 2.** Perform surgeries on minipigs and evaluate bone healing with x-ray.

**Task 2a.** Fabricate Scaffolds –completed by **Dr. Chu**.

**Task 2b.** Perform surgeries on minipigs. There were 3 rounds of surgeries in the end following our requests and approvals for changes based on ongoing experimental results

Surgery Round 1: 27 minipig surgeries completed – surgeries performed by **Drs. Anglen, Chu, and Cheng** (plus other approved trainees and vet technicians). **Drs. Chu and Anglen** optimized the surgical protocol on cadaver minipigs and live pilot minipigs first, tested hardware on tibia curvature etc. required to create and stabilize a 25 mm segmental defect in the tibias. **Drs. Kacena and Chu** ordered all required supplies/equipment/reagents/animals and confirmed schedule. **Dr. Kacena** has been responsible for management of personnel/trainees for post-operative animal care. The time, effort, and even drugs required (pain management) for post-operative management of minipigs has been substantially larger than was anticipated. The veterinarian was in charge of deciding our post-operative pain management protocol. These studies required significantly more time, effort, and budget than we anticipated. We obtained significant internal funding and cost shared significant effort to accomplish the surgeries and post-operative care to date (we enlisted in the assistance of 6 medical students, 2 additional orthopaedic surgeons (Drs. Todd McKinley and Karl Shively), a graduate student, and a postdoctoral fellow (the latter has been averaging 60-90 hours/week since the surgeries have begun) in addition to our original team of 4 (**Drs. Kacena, Chu, Anglen, and Cheng**) and everyone is well over their anticipated % effort). We have not increased the salary associated with the effort or added salary for any of the additional personnel at this time.

Surgery Round 2: We next completed surgeries on 12 minipigs – surgeries performed by **Drs. McKinley, Chu, and Zhao** (plus other approved trainees and vet technicians). This surgery used compression plates rather than the IM nail system as the IM nail system showed that it was not biomechanically stable over time. This was also a 25mm defect (same size in the original 27 minipigs).

Surgery Round 3: Finally we completed surgeries on 12 minipigs – surgeries performed by **Drs. McKinley, Chu, and Zhao** (plus other approved trainees and vet technicians). This surgery used compression plates and increased the size of the defect to 40 mm. All changes were approved and included amendments to IACUC and ACURO as required.

**Task 2c.** Perform radiographic assessments. X-rays have been obtained for the 27 minipigs with IM nails. Completed by **Drs. Anglen, Chu, and Cheng**. X-rays have been obtained for the 24 minipigs with compression plates. Completed by **Drs. McKinley, Chu, and Zhao**.  
**Milestone 2.** Completed for all pigs. Month 46.

<u>Task</u>	<u>Initial projected timeline</u>	<u>Actual timeline</u>
2a	1-15 months original SOW 35-36 months revised SOW	1-3 months 36-37 months
2b	11-17 months original SOW 36-39 months revised SOW	3-12 months 40 months
2c	11-29 months original SOW 36-45 months revised SOW	3-36 months 45 months

**Task 3.** Determine the bone union rate of the minipigs after implant retrieval.

**Task 3a.** Retrieve tibiae from minipigs – completed for 27 minipigs with IM nails by **Drs. Chu and Cheng (and Dr. Kacena’s medical students, postdoctoral fellows as well as pathologists)**.

Retrieve tibiae from minipigs – completed for 24 minipigs with IM nails by **Drs. Chu and Zhao (and Dr. Kacena’s medical students, postdoctoral fellows as well as pathologists)**.

**Task 3b.** Perform CT on retrieved tibia. This has not yet been completed due to common use IU equipment being transferred to Purdue unknown at the time by the PIs. We plan to finish this on our own time once the equipment is returned to IU. (**Dr. Chu**)

**Task 3c.** Process tibia for histological evaluation. Cannot be completed until after CT is completed. (**Dr. Chu and Kacena**)

**Task 3d.** Perform histological analysis. Cannot be completed until after CT is completed. (**Drs. Chu and Kacena**)

**Milestone 3.** Completed using xrays from Task 2. Month 46.

<u>Task</u>	<u>Initial projected timeline</u>	<u>Actual timeline</u>
3a	23-29 months original SOW 42-45 months revised SOW	36 months 45 months
3b	23-33 months original SOW 42-48 months revised SOW	Not yet completed – see above Not yet completed – see above
3c	25-34 months original SOW 42-48 months revised SOW	Not yet completed – see above Not yet completed – see above

**Task 4.** Determine the biomechanical properties of the newly formed callus.

**Task 4a.** Retrieve samples – completed for 27 minipigs with IM nails by **Drs. Chu and Cheng (and Dr. Kacena’s medical students, postdoctoral fellows as well as pathologists)**.

Retrieve samples – completed for 24 minipigs with compression plates by **Drs. Chu and Zhao (and Dr. Kacena’s medical students, postdoctoral fellows as well as pathologists).**

**Task 4b.** Perform torsion testing – completed for 27 minipigs with IM nails by **Dr. Chu.** Completed for 24 minipigs with compression plates by **Drs. Chu and Zhao.**

**Milestone 4.** Completed. Month 45.

<u>Task</u>	<u>Initial projected timeline</u>	<u>Actual timeline</u>
4a	23-30 months original SOW	36 months
	42-45 months revised SOW	45 months
4b	30-33 months original SOW	36 months
	42-45 months revised SOW	45 months

**Task 5.** Evaluate potential systemic side effects of TPO by studying the blood of the minipigs before and post-surgery.

**Task 5a.** Collect blood samples. We have completed the collection of the blood samples as per approved IACUC/ACURO protocols. Completed for 27 minipigs with IM nails by **Drs. Kacena and Cheng.** Completed for 24 minipigs with compression plates by **Drs. Kacena and Zhao.**

**Task 5b-d.** Evaluate platelet numbers. Complete blood counts were completed on all blood samples, data has been collected and analyzed by **Drs. Kacena and Zhao.** We have also completed a preliminary genomic analysis including TPO and Type I collagen analyses. Final analysis is ongoing by **Drs. Kacena and Zhao.**

**Milestone 5.** No side effects were observed of using TPO as determined by blood analyses and all other testing completed to date.

<u>Task</u>	<u>Initial projected timeline</u>	<u>Actual timeline</u>
5a	11-29 months original SOW	36 months
	36-45 months revised SOW	45 months
5b	11-29 months original SOW	37 months
	36-45 months revised SOW	46 months
5c&d	30-36 months original SOW	Not yet completed – see above
	45-48 months revised SOW	Not yet completed – see above

**The surgical method is detailed in our IACUC/ACURO protocols.** Briefly, Prior to surgery, x-rays of the right tibia were collected to confirm skeletal maturity (epiphyses were closed). Also prior to surgery, PPF/TCP scaffolds of 17 mm in the outer diameter, 10 mm in the inner diameter, and 25 or 40 mm in height were fabricated using the casting method described in our previous publication. (Chu et al 2007) As a carrier for saline, BMP-2, or TPO we have chosen to use an FDA approved type I bovine collagen sponge (Helistat, 7.5 cm x 10.0 cm x 5.0 mm, ½ of a sponge will be used for each pig or 7.5 cm X 5.0 cm X 5.0 mm). Collagen sponges were treated with BMP-2, TPO, or saline and allowed to sit for 15 minutes prior to implantation.

The animals will be induced and maintained under sodium thiopental and fentanyl dihydrogenate for the duration of the procedure. First, a subcutaneous implantable port system was inserted into each minipig to provide better access for later blood sampling and injections. The animals were properly draped and surgical site was prepared using sterile technique. The right hind-limb was prepared with betadine. A 10 cm incision was made in the proximal diaphysis of the tibia using an anteromedial approach. The exposures were carried down between the tibia and the TA muscle and the tibia was circumferentially exposed through muscle elevation. The tibia was marked for length and orientation to ensure rotational accuracy. Two parallel, transverse osteotomies were made 25 or 40 mm apart with a reciprocating saw (Stryker, Kalamazoo, MI). The resulting free segment of bone was removed, creating a critical-size defect.

### IM Nail Procedure:

The intramedullary (IM) nail was inserted through the proximal incision. The IM nail was inserted in an antegrade fashion from the proximal bone fragment, through the central canal of the scaffold, terminating in the distal bone fragment, ensuring tight apposition between the cut bone ends and the scaffold. The IM nail was then locked with 2 locking screws proximal and 2 locking screws distal to the segmental defect. The fascia and subcuticular layer was closed with Vicryl suture. The scaffold was placed into the segmental defect. The scaffold was circumferentially surrounded by a type I collagen sponge soaked with BMP-2, TPO, or saline control and the joined ends were secured with Vicryl suture. IM nail procedure was only carried out in tibias with 25 mm defects.

### For Compression Plate Procedure:

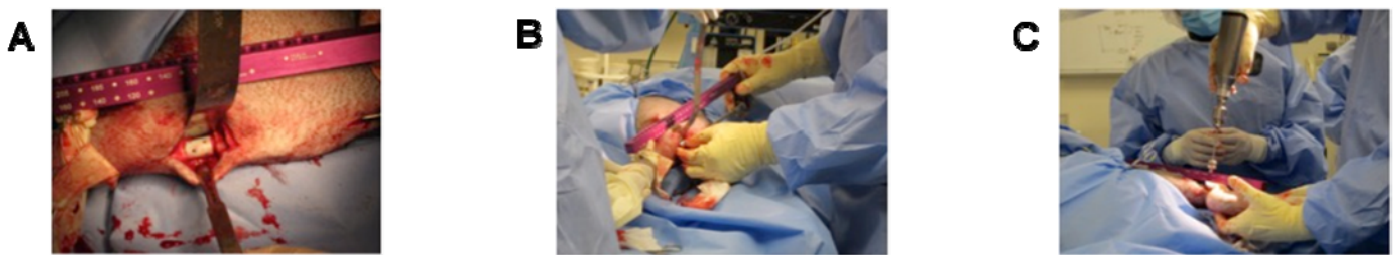Orthogonal double bone plate fixation technique was used. A standard narrow nine-hole 4.5 mm limited contact dynamic compression plate (Synthes; Paoli, PA) was placed on the anterolateral surface of the tibia. Any necessary contouring to optimize conformity of the plate with the bone surface was performed with a table-top bending device. The plate was secured with four 4.5 mm screws inserted proximal and four more 4.5 mm screws distal to the defect inserted with standard techniques through both cortices. A secondary plate was then placed and secured with two 4.5 mm screws proximally and two 4.5 mm screws distally to prevent rotation. Subsequently, the scaffold was circumferentially surrounded by a type I collagen sponge soaked with TPO, BMP-2, or saline and the joined ends were secured with an appropriately size absorbable suture.

The fascia and subcuticular layer was closed with an appropriately sized absorbable suture. An appropriately sized suture was used for skin closure. From our preliminary minipig study, we have not observed deformation of locking screws but have needed to tighten the screws. We did not have these problems with the compression plate.

Amoxicilline, benzylpenicillin and clavulanate was given 24 hrs prior to the surgery and daily for 3 days after the surgery as prophylactic antibiotics; the animals were monitored postoperatively and given analgesic drugs such as dexmedetomidine, buprenorphine, hydromorphone, and ketamine for three postoperative days at which time tramadol was given for up to 4 weeks based on veterinarian recommendations. Anteroposterior and lateral radiographs of both tibiae were taken during the acclimation period before implantation to serve as controls as a standard for normal tibia mineralization (Toshiba Infinix VC with Vitrea 2 work station) and to exclude animals with pre-existing bone pathology.

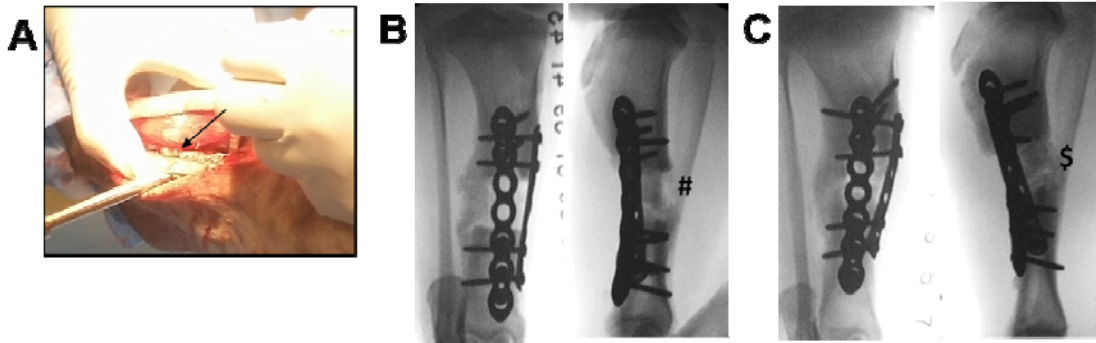
**4. KEY RESEARCH ACCOMPLISHMENTS:** We completed surgeries and blood/tissue collection from all 51 minipigs. **Group 1 Surgeries:** 25mm IM Nail: 8 = saline control, 8 = 1.5mg BMP-2, 8 = 1.5 mg TPO, 3= 7.5 mg TPO. As the sample size was low in the high dose TPO group and there were complications observed with a pig in that group below we focus on data from the 3 groups with the larger sample sizes. **Group 2 Surgeries:** 25mm Compression Plate: 4=saline control, 8= 1.5mg TPO. **Group 3 Surgeries:** 40mm Compression Plate: 4=saline control, 4=2.4mg BMP-2, 4= 2.4mg TPO.

**Figure 1** demonstrates the key surgical methods IM nail procedure (27 pig surgeries).



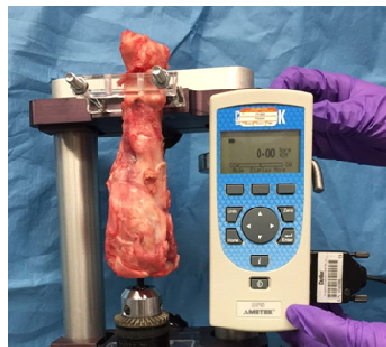
**Figure 1:** (A) Pig tibia with scaffold in place. (B) Manipulation of the surgical site to place collagen sponge loaded with treatment. (C) Fixation of the intramedullary nail. We created critical size defects in the tibiae of 24 Yucatan mini-pigs. Into these defects were placed synthetic scaffolds composed of polypropylene fumarate/tricalcium phosphate supported by an intramedullary nail that was further fixated with screws. Overlaying the scaffold was a collagen sponge impregnated with saline (control), BMP-2 (1.5 mg), or TPO (1.5 mg). After surgery, the animals were allowed to heal for 6 to 9 months during which they ambulated as tolerated. Healing progress was monitored with plain radiography at baseline and then monthly until euthanasia. Whole blood was collected at baseline, 1 and 2 weeks post-operatively, and then monthly until euthanasia. At euthanasia, experimental tibiae with the scaffold in place were collected and the specimens are being processed for micro-CT and histological examination.

**Figure 2** demonstrates the key surgical methods for the compression plate surgeries. Key accomplishments with compression plate fixation: We completed surgeries and tissue collection from all 24 minipigs with compression plates.

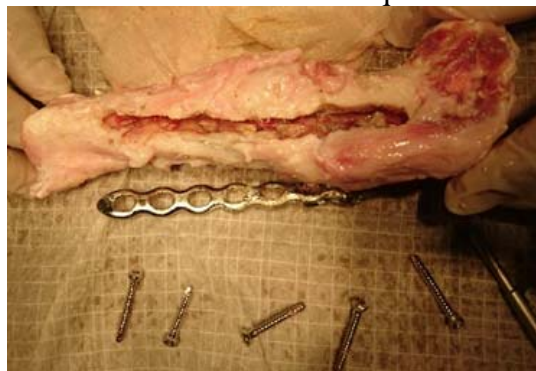

**Figure 2: Compression plate model (25mm defect size).** (A) Compression plate (arrow) is placed across defect and secured in place with locking screws. (B) Representative lateral and anteroposterior (AP) views of saline treated animal 4 weeks after surgery. Minimal healing (#) is visible across the defect. (C) Representative lateral and AP views of TPO treated animal 4 weeks after surgery. Partial healing (\$) is visible and is more robust than saline treated animal.

**Figures 3&4** show key methods for biomechanical testing.



**Figure 3:** Pig tibia with distal end stabilized on a testing stand. The proximal end of the tibia was connected to the torque sensor through a hex head screw inserted between the medial and lateral facets of the superior articular surfaces and secured to the Jacobs chuck on the torque sensor.

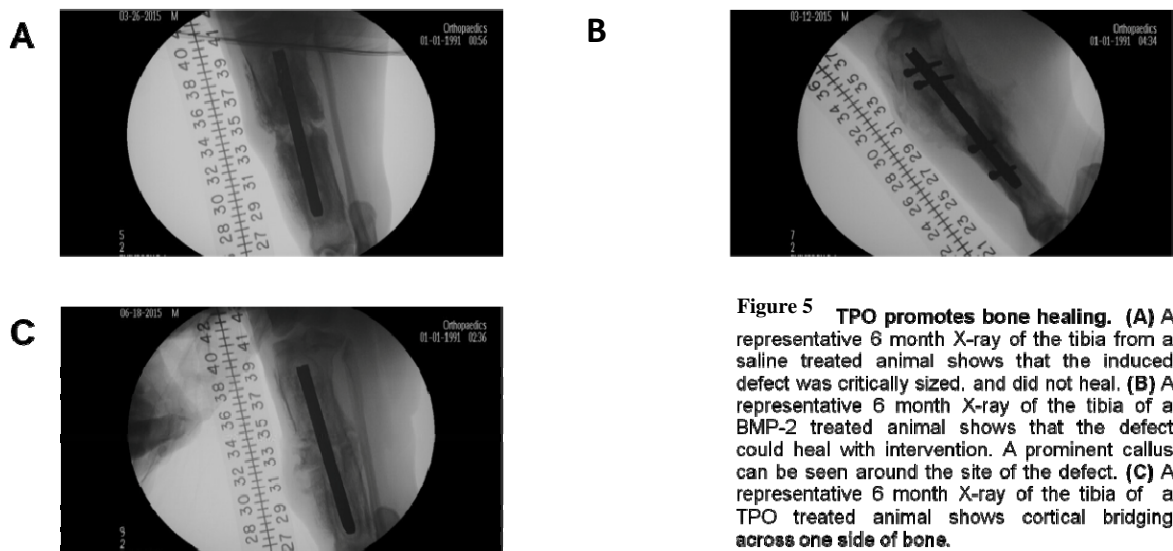


**Figure 4:** Bone plate removed from the tibia where bone plates were used to stabilize the tibia.



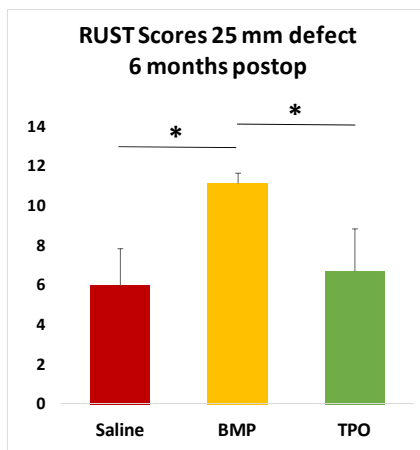
Figures 5-8 show some of the key data for 25 mm bone defects fixed with an IM nail.

Figure 5 shows the key IM nail x-ray findings.



**Figure 5 TPO promotes bone healing.** (A) A representative 6 month X-ray of the tibia from a saline treated animal shows that the induced defect was critically sized, and did not heal. (B) A representative 6 month X-ray of the tibia of a BMP-2 treated animal shows that the defect could heal with intervention. A prominent callus can be seen around the site of the defect. (C) A representative 6 month X-ray of the tibia of a TPO treated animal shows cortical bridging across one side of bone.

Figure 6 shows the IM nail RUST score or bone bridging score (additional details below).

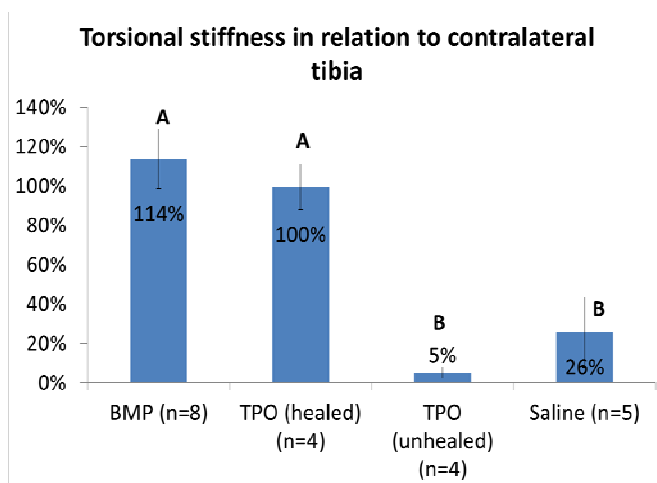


**Figure 6. RUST score.** 25 mm defect, IM nail fixation, 6 months postop (n=8/ group). \*Indicates significant difference between groups,  $p < 0.05$ .

RUST: Radiographic Union Score for Tibial Fractures.

RUST score: each cortex was given a score of 1 (no bridging), 2 (partial bridging), or 3 (complete bridging) and scores for all 4 cortices were added to provide a final score ranging from 4 (not healed) to 12 (maximally healed).

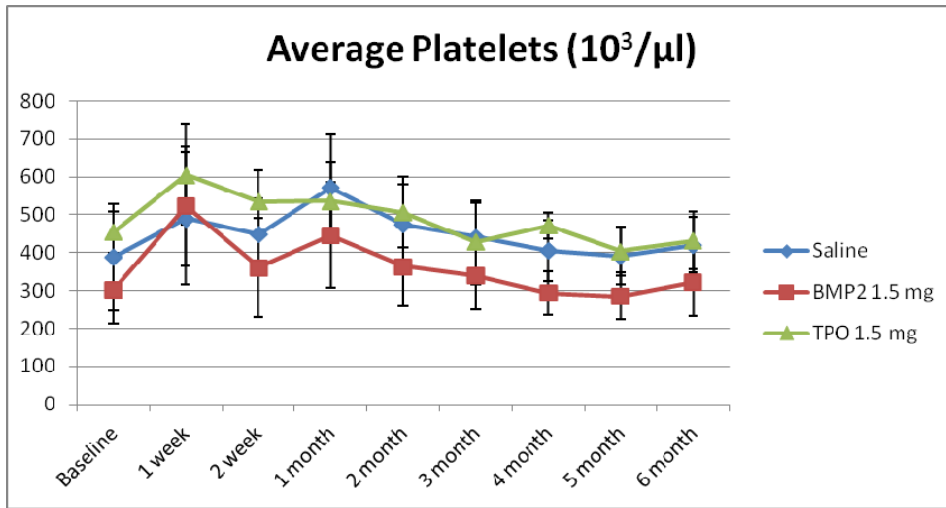
Figure 7 shows the IM nail biomechanical data.



**Figure 7.** Both operated tibia and contralateral un-operated tibia were retrieved at sacrifice and were subjected to non-destructive torsional test using a digital torque gauge. All operated tibia in the BMP group healed and demonstrated a torsional stiffness of  $114 \pm 15\%$  of the contralateral tibia. Four out of eight tibia in the 1.5 mg TPO group healed and showed a torsional stiffness of  $100 \pm 12\%$  of the contralateral tibia. Another four tibia in the 1.5 mg TPO group did not heal. None of the tibia in the saline group healed. There were no statistical significant differences between the BMP and the healed TPO group ( $p > 0.05$ ). These two groups are statistically significantly higher than the unhealed TPO and the saline groups. Due to retrieval issues and/or hardware/technical failures we unfortunately lost 3 of the saline specimens (experimental limb or contralateral limb), and thus only have n=5 rather than n=8 for the torsional stiffness data.

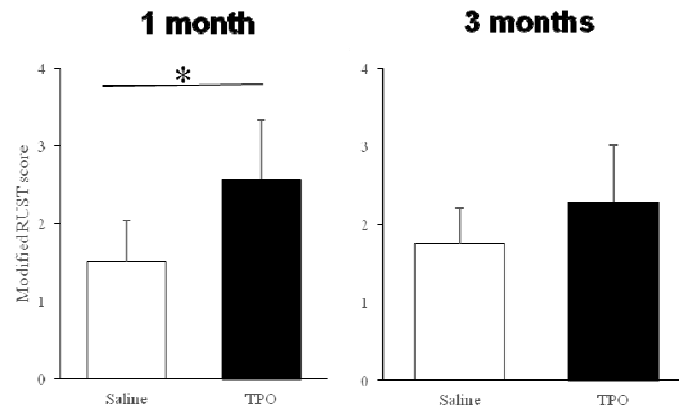
**\*\*Biomechanical testing is more important for assessment of bone healing outcome than RUST score, especially as radiographic artifacts (where hardware is located etc) can confuse radiographic interpretation.**

**Figure 8** shows the key IM nail platelet data.



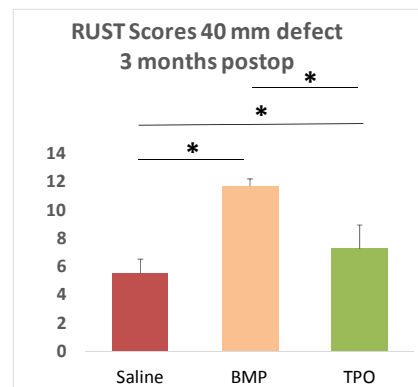
**Figure 8.** Blood was collected from the minipigs prior to surgery (baseline) as well as 1 week, 2 weeks, 1 month, 2 months, 3 months, 4 months, 5 months, and 6 months post-surgery. A complete blood count was completed on all blood samples. Platelet concentrations are reported as the mean  $\pm$  standard deviation. Platelet concentrations were significantly elevated in all minipigs 1 week after surgery (compared to respective baseline samples,  $p < 0.001$ ). No differences were observed in platelet concentrations between minipigs treated with saline or TPO. However, using a 2-way ANOVA we determined that platelet concentrations were significantly reduced in BMP-2 treated minipigs compared to that observed in saline treated controls ( $p < 0.001$ ).

**Figure 9** shows the key bone healing data for the 25mm bone defect surgeries with compression plate fixation. It should be noted that complete healing was observed upon euthanasia and therefore samples were not tested for biomechanical properties.



**Figure 9: Modified RUST score.** (A) 4 weeks after surgery, The TPO treated animals (n=8) scored significantly higher than saline controls (n=4). (B) At 3 months the difference between TPO and saline treated animals was not significant. Note modified RUST scores are different from RUST scores (the average of the cortices is provided as a single score rather than adding them together. 1 = no healing, 2 = partial healing, 3= complete healing.

**Figure 10** and **Table 1** Show the key bone healing and biomechanical testing data for 40mm bone defect surgeries with compression plate fixation.



**Figure 10: RUST score.** 40 mm defect, compression plate fixation, 3 months postop (n=3-4/ group).

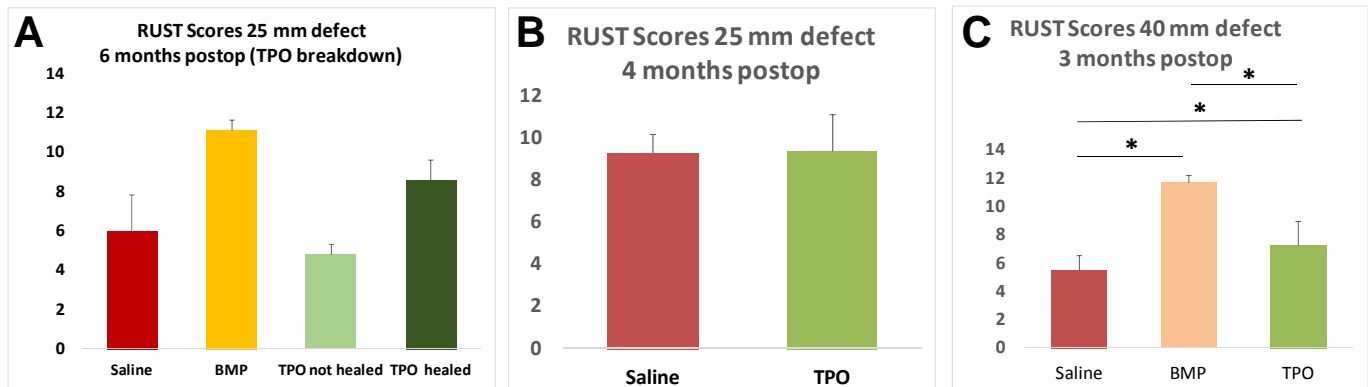
\*Indicates significant difference between groups,  $p < 0.05$ .

**Table 1. Biomechanical Testing Results from pigs with 40mm bone defect and compression plate fixation.**

<b>Pig ID</b>	<b>Tx group</b>	<b>Age at euthanasia (months)</b>	<b>Wt. at euthanasia</b>	<b>Implant duration (days)</b>	<b>% torque</b>
34-004	BMP	35.10	94.8	121	95%
34-111	BMP	34.27	106	121	92%
35-114	BMP	32.57	101.2	121	94%
31-120	SALINE	34.80	87.2	79	0%
31-123	SALINE	34.80	82.8	79	0%
32-001	SALINE	34.57	86.2	79	0%
32-032	SALINE	34.20	84.4	79	0%
35-123	TPO-L	34.63	112.6	176	48%
35-159	TPO-L	34.43	97	176	98%
36-075	TPO-L	33.77	94.8	176	3%
37-035	TPO-L	32.77	93.2	176	20%

It should be noted that once x-ray imaging confirmed failure of the scaffold (saline controls) pigs were humanely euthanized early as per veterinarian advice. Similarly pigs were humanely euthanized at an early time point when no differences in bone healing were observed during 2 consecutive series of X-rays as per our approved protocol, thus, BMP-2 treated pigs were euthanized earlier than TPO treated pigs. The % torque is compared to the contralateral tibia. Also, it should be noted that the hardware failed/surgery failed in one of the BMP-2 treated pigs, resulting in n=3 rather than n=4.

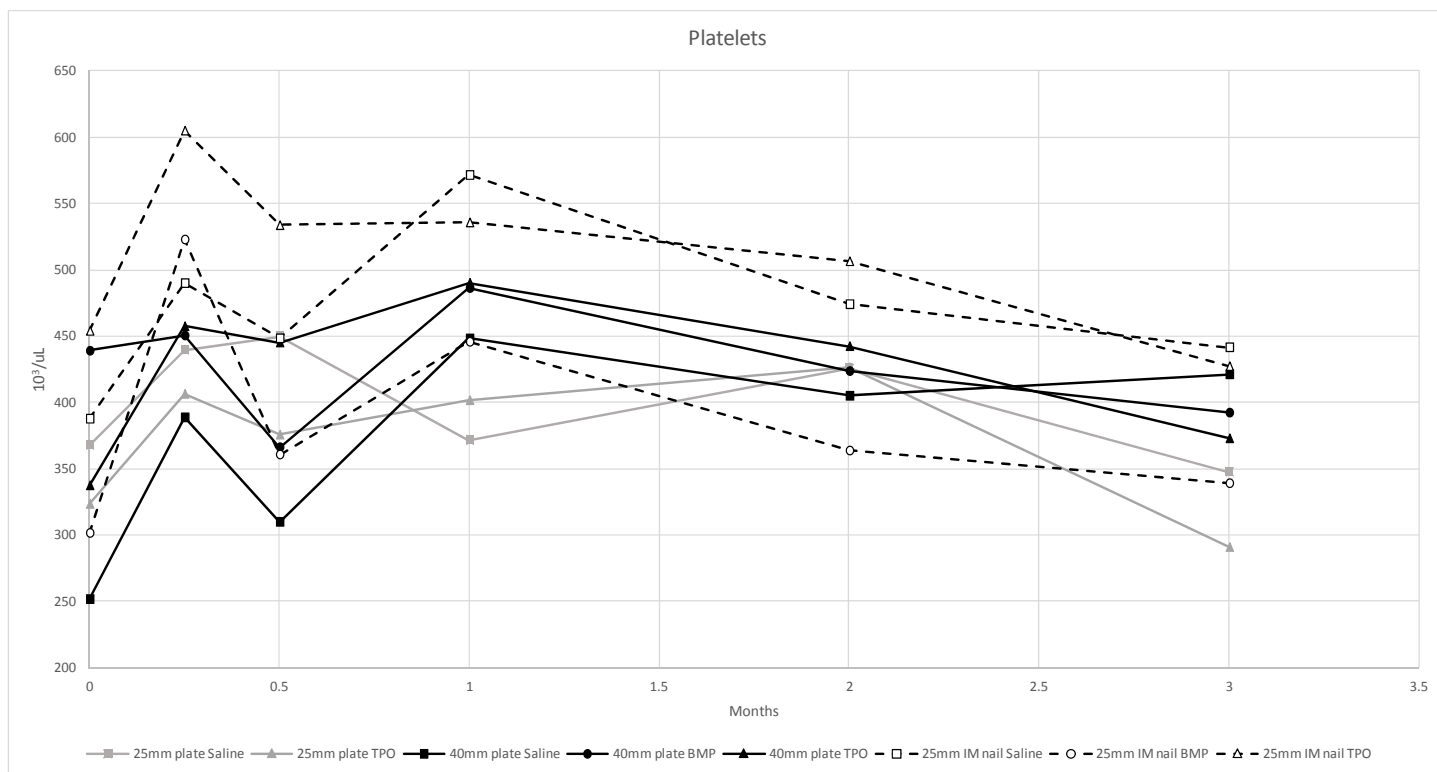
The next series of figures (11-14) look at all of the data from all of the different surgeries in aggregate.



**Figure 11: RUST score. (A)** 25 mm defect, IM Nail fixation, 6 months postop (n=8/group saline and BMP-2 and 4/group TPO healed and TPO not healed). **(B)** 25 mm defect, compression plate fixation, 4 months postop (n=8/ group TPO and n=4/group saline). **(C)** 40 mm defect, compression plate fixation, 3 months postop (n=3-4/group).

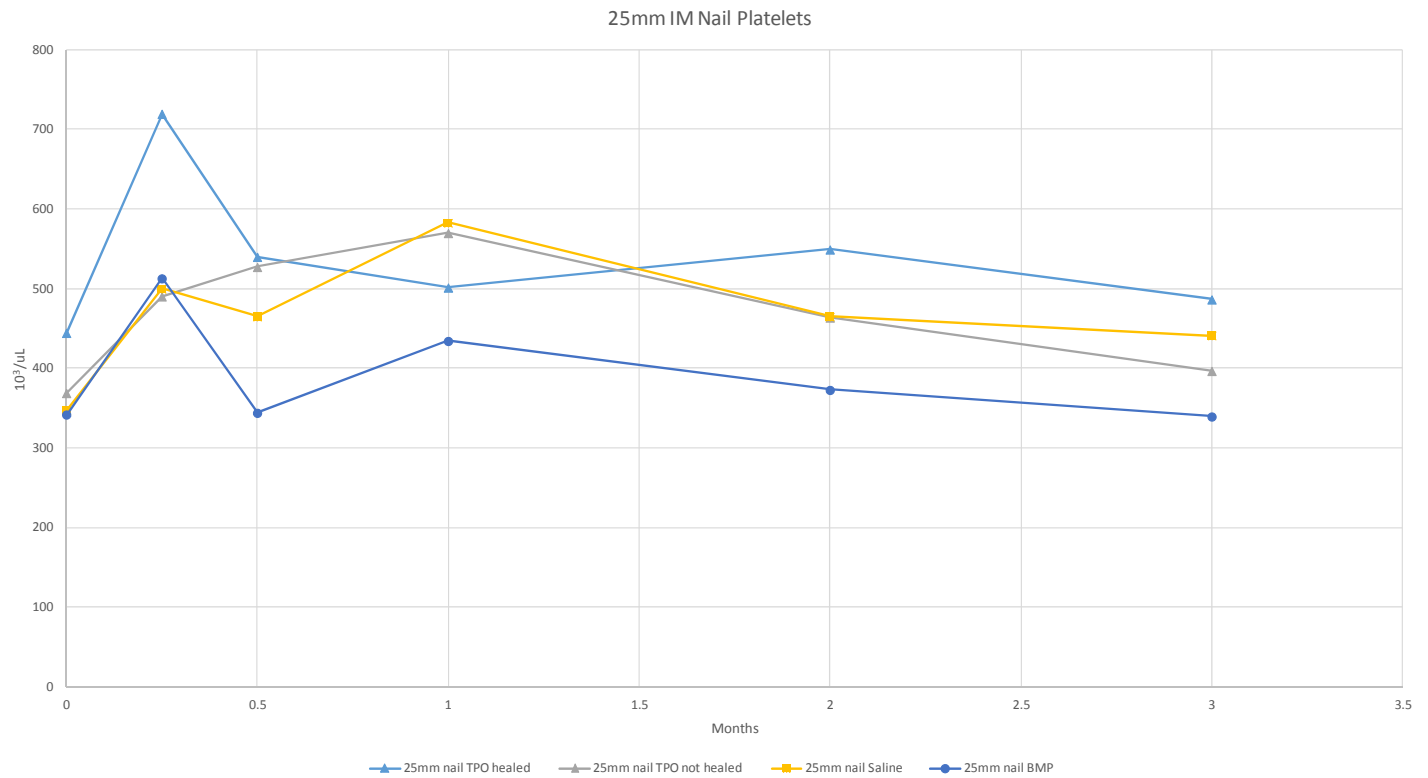
Preliminary blood including CBC analyses and pathology analyses have not raised any safety concerns.

As TPO is the main megakaryocyte growth factor, and as in rodent studies we observed a transient increase in systemic platelet levels we examined platelet levels in pigs over time.

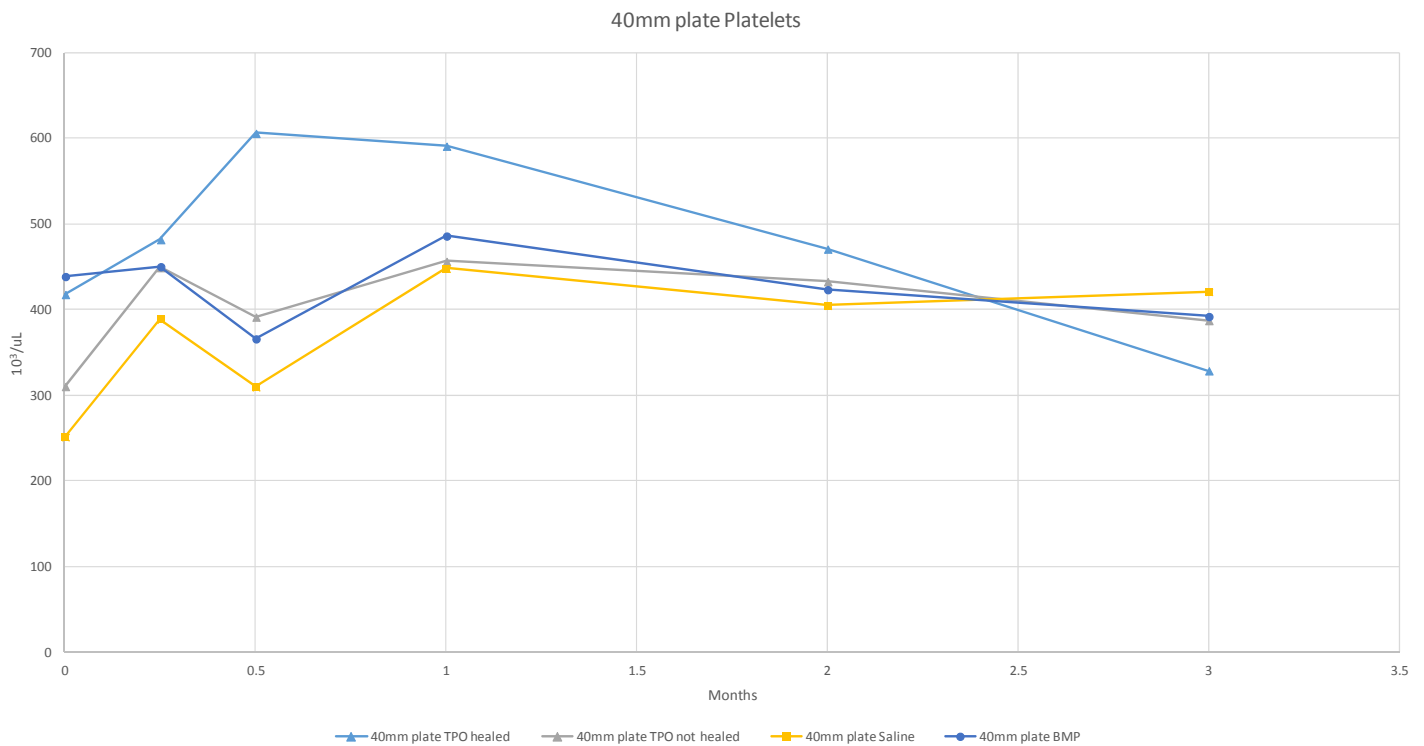


**Figure 12: Average platelet concentration over time all surgical groups.** Squares: Saline, Triangles: TPO, Circles: BMP-2. Solid gray symbols/line – 25mm bone defect with compression plate fixation. Solid black symbols/lines – 40mm bone defect with compression plate fixation. Open symbols/dashed line – 25mm bone defect with IM Nail fixation.

Since we observed in the 25mm IM Nail fixation and 40mm compression plate fixation groups that all saline treated pigs did not heal and all BMP-2 healed, but TPO healing was variable among pigs with about half healing in each group, we further divided the TPO-treated groups based on whether healing was observed or not.



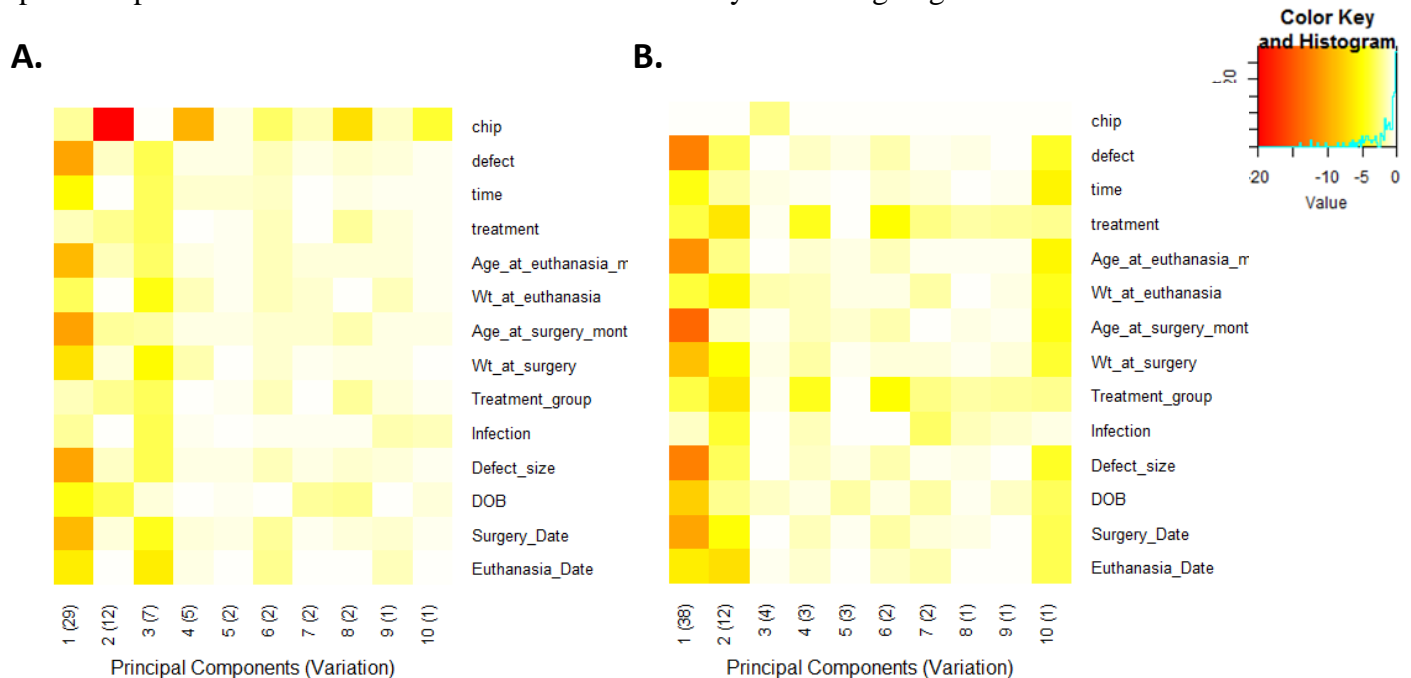
**Figure 13: Average platelet concentration over time 25mm bone defect with IM Nail fixation.** Blue triangle represent the healed TPO group where as gray triangle represent those pigs that did not heal when treated with TPO. There is a significant increase in platelet levels 1 week post-surgery in TPO-treated pigs that healed as compared to all other groups (including TPO-treated pigs that did not heal). As our previous data suggests that megakaryocytes (give rise to platelets) stimulate osteoblast proliferation and bone formation, it may be that if platelet levels are not sufficiently increased early after surgery/treatment that bone healing is not effective with TPO treatment.



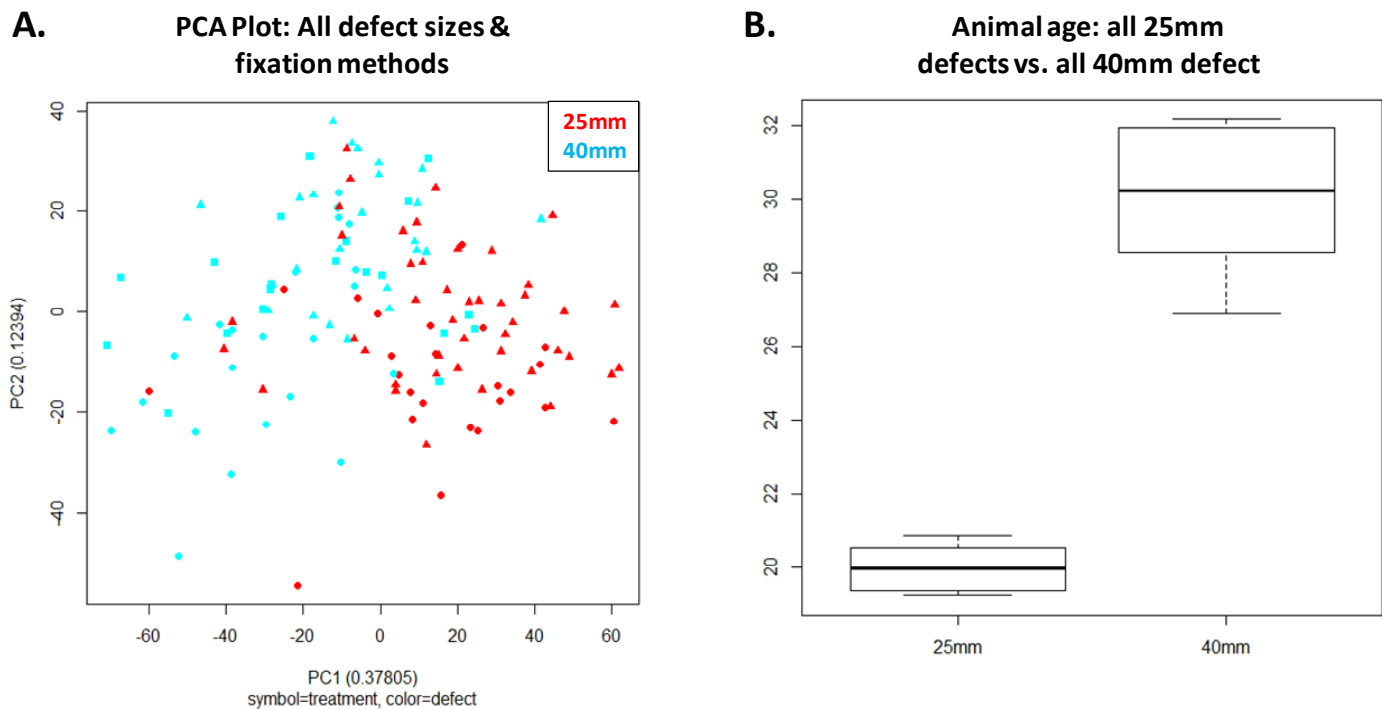
**Figure 14: Average platelet concentration over time 40mm bone defect with compression plate fixation.** Blue triangle represent the healed TPO group where as gray triangle represent those pigs that did not heal when treated with TPO. There is an increase in platelet levels in the pigs that healed when treated with TPO at 1 week (although not significantly different from the TPO-treated pigs that did not heal); however, there was a significant increase in platelet levels 2 weeks and 4 weeks post surgery in the TPO treated pigs that healed versus all other pigs. These data provide further evidence that the ability of the locally administered TPO to illicit a response in the endogenous cells (platelets can be used as a surrogate marker) is critical for TPO to enhance bone healing.



Additionally we have completed preliminary genomic analyses including QC steps which identified and removed significant chip batch effect. **Figure 15**, shows PCA analysis of these cleaned data revealed a clear distinction between animals with different defect sizes. Additionally, we found that animal age (**Figure 16**) at the time of surgery was a critically important confounding factor for understanding the relationship between expression profiles and the size of the defect. Further analyses are ongoing.



**Figure 15: Correction of non-biological experimental error in peripheral blood microarray analysis.** We used a statistical method tailored for small sample size microarray studies to remove technical artifacts (batch effects). **(A)** Principle Component Analysis (PCA) identified the non-biological variable of ‘chip’ as a major source of variation. **(B)** After ComBat (Combing Batches) correction biological variables such as animal age and defect size accounted for largest variation in gene expression.



**Figure 16. Separation of gene expression profiles confounded by age. (A)** PC1 vs. PC2 reveals separation of 25mm defect animals from 40mm animals. **(B)** Animal age for all 25mm and 40mm defect animals. Principal component analysis apparently separates animals based on defect size. However, animal age differed by 10 months between groups. Though a relatively small difference (compared to lifespan of pig and they were all adults with closed growth plates), age accounted for more variation than defect size in PC1 (data not shown). This suggests, that age is a dominant factor in bone healing. We are continuing to analyze within group differences based on treatments and will be analyzing data based on whether healing occurred or not (based on biomechanical data).

## 5. CONCLUSIONS:

### IM Nail Conclusions

- All eight of the saline control treated animals failed to demonstrate healing across the induced tibial defect.
- All eight of the BMP-2 treated animals showed healing across the induced tibial defect and had a torsional stiffness of  $114 \pm 15\%$  of the contralateral tibia.
- Four of the eight TPO treated animals showed healing across the tibial defect and had a torsional stiffness of  $100 \pm 12\%$  of the contralateral tibia.
  - No adverse effects from TPO treatment have been identified from blood measurements, organ pathology, or veterinary inspection.
  - Healed tibiae had torsional stiffness values which were not statistically different from their contralateral counterparts.
- While healing with TPO is better than that observed with saline, TPO did fail in 4 of 8 of our pigs. Based on our 4 healed tibia and our previous mouse/rat data, TPO morphologically appears to promote robust bone growth by direct bone healing, which takes longer to accomplish than BMP-2. Thus, if our fixation fails before our healing process is allowed to occur (which appears to have been the problem in the 4 tibiae that failed to heal), we cannot properly assess the value of TPO as a bone healing therapy. To better investigate this we have recommended completion of one more group of pigs with a different fixation strategy (more rigid fixation). As we secured internal funding to assist with defraying our expenses to date as well our revising our protocol to euthanize the pigs earlier than the original 1 year time point, we would have sufficient funds to complete this testing. Dr. Todd McKinley discussed this with Dr. Yadav in person at the August meeting in Florida.
- Platelet concentrations were significantly elevated in all minipigs 1 week after surgery (compared to respective baseline samples,  $p < 0.001$ ).
- Platelet concentrations were significantly reduced in BMP-2 treated minipigs compared to that observed in saline treated controls ( $p < 0.001$ ).
- TPO treatment did not result in a significant systemic increase in platelet concentration as significant differences were not observed in platelet concentrations between minipigs treated with saline or TPO in aggregate groups. However, when platelet levels were subdivided in the TPO-treated pigs based on whether the bone healed or not (based on biomechanical data), a significant increase in platelets was observed immediately post-surgery.

### Compression Plate Conclusions

- TPO treated minipigs had significantly improved healing at 1 and 2 months post-surgery (25 mm defect).
- All saline and TPO treated minipigs healed over time (25 mm defect).
- The 25 mm defect is not a critical sized defect when compression plating fixation is used whereas it is with IM nails.
- Thus, 25mm defect is what we are now terming a metacritical sized defect based on fixation strategy. Several investigators at other institutions have been impressed with this and are interested in working with this model. Indeed, one recently supported DOD funded project is about to start with inclusion of volumetric muscle loss along with our metacritical sized defect model. A second proposal using this model was recently submitted for DOD funding.
- 40 mm defect is a critical sized defect when compression plating fixation is used.
- With a 40 mm defect, all saline treated minipigs failed to heal, all BMP-2 treated minipigs healed over time, and like with the 25 mm IM nail (also a critical sized defect) TPO treatment improved healing compared to saline treated controls, but was not as robust or consistent at BMP-2 treatment.
- Future investigations with different dosing would be useful.
- With the 40mm defect group, TPO-treated pigs that healed had higher platelet levels post-surgery than did TPO-treated pigs that did not heal (biomechanical testing data).

Overall, our pig data continues to support the idea that TPO can enhance bone healing in large animals as well as in rodents. However, it appears that additional optimization of dosing or timing of drug treatment is required. Our data also suggests that like with other drugs, some animals are more responsive to the drug and that with treatment with TPO, high platelet levels early post-surgery may predict a positive bone healing outcome.

**Future plans:** Complete uCT and histological analysis of tibias. Complete blood analyses. Apply for expansion grants related to these studies. Related to the latter, identify all opportunities to fund safety studies so that once safety is confirmed we can obtain FDA approval to begin a first in human (for bone healing indications), phase I clinical trial.

## 6. PUBLICATIONS, ABSTRACTS, AND PRESENTATIONS:

### a. Manuscript publications submitted

1. Lay Press: N/A

### 2. Peer-Reviewed Scientific Journal:

- 1.) Davis KM, Griffin KS, **Chu T-MG**, Wenke JC, Corona BT, **McKinley TO**, **Kacena MA**. Muscle-bone interactions during fracture healing. *J Musculoskelet Neuronal Interact*, 15:1-9, 2015.

### 3. Invited Articles:

- 1.) Jewell E, Rytlewski J, **Anglen JO**, **McKinley TO**, Shively KD, **Chu T-MG**, **Kacena MA**. Surgical Fixation Hardware for Regeneration of Long Bone Segmental Defects: Translating Large Animal Model and Human Experiences. *Clinical Reviews in Bone and Mineral Metabolism*, 13:222-231, 2015.
- 2.) Griffin KS, Davis KM, **McKinley TO**, **Anglen JO**, **Chu T-MG**, Boerckel JD, **Kacena MA**. Evolution of bone grafting: Bone grafts and tissue engineering strategies for vascularized bone regeneration. *Clinical Reviews in Bone and Mineral Metabolism*, 13:232-244, 2015.

### 4. Abstracts:

- 1.) Rytlewski J, Childress P, Cheng Y, **Anglen JO**, Shively KD, **McKinley TO**, **Chu T-MG**, **Kacena MA**. Safety and efficacy of thrombopoietin as a novel bone healing agent in a large animal model. *SRPinAM Research Day*, 2015.
- 2.) Childress P, **Chu TMG**, **Anglen JO**, **McKinley TO**, **Kacena MA**. The Development of a Critical Sized Bone Defect Model in Yucatan Miniature Swine, *Military Health System Research Symposium*, 2016.
- 3.) Childress PJ, Rytlewski J, Zhao L, **Anglen JO**, Shively KD, **McKinley TO**, **Kacena MA**. TPO Augments Bone Regeneration in a Large Animal Critical Sized Defect Model, *Second Annual Symposium on Cell Therapy and Regenerative Medicine*, 2016
- 4.) Childress P, Rytlewski J, Zhao L, **Anglen JO**, Shively KD, **Chu T-MG**, **McKinley TO**, **Kacena MA**. TPO augments bone regeneration in a large animal critical sized defect model. *Orthopaedic Research Society*, 2017

### b. Presentations made:

- 1.) Rytlewski J, Childress P, Cheng Y, **Anglen JO**, Shively KD, **McKinley TO**, **Chu T-MG**, **Kacena MA**. Safety and efficacy of thrombopoietin as a novel bone healing agent in a large animal model. *SRPinAM Research Day*, 2015.
- 2.) Childress P, **Chu TMG**, **Anglen JO**, **McKinley TO**, **Kacena MA**. The Development of a Critical Sized Bone Defect Model in Yucatan Miniature Swine, *Military Health System Research Symposium*, 2016.
- 3.) Childress PJ, Rytlewski J, Zhao L, **Anglen JO**, Shively KD, **McKinley TO**, **Kacena MA**. TPO Augments Bone Regeneration in a Large Animal Critical Sized Defect Model, *Second Annual Symposium on Cell Therapy and Regenerative Medicine*, 2016
- 4.) Childress P, Rytlewski J, Zhao L, **Anglen JO**, Shively KD, **Chu T-MG**, **McKinley TO**, **Kacena MA**. TPO augments bone regeneration in a large animal critical sized defect model. *Orthopaedic Research Society*, 2017

## 7. INVENTIONS, PATENTS AND LICENSES: Nothing to report.

## 8. REPORTABLE OUTCOMES: Nothing to report.

## 9. OTHER ACHIEVEMENTS:

Based in part on work supported by this award we have applied for several grant opportunities. From the Center for the Advancement of Science in Space (CASIS) we obtained funding for spaceflight ground testing “NASA Ames Grounds Testing – Rodent Research-4” (\$91,370). To further explore the role of TPO in stimulating angiogenesis during the bone healing process we obtained a grant from the Indiana Clinical and Translational Institute “Delivery of Recombinant Human Thrombopoietin for Large Bone Defect Regeneration” (\$27,951). To expand this research into a high risk population, those persons with Type 2 Diabetes, we obtained pilot funding from the Indiana Clinical and Translational Institute “Impact of TPO treatment on bone healing and angiogenesis in type 2 diabetes” (\$24,315). The data obtained from this pilot study was then leveraged and we were awarded a VA Merit Award, 1101 BX003751 (\$1,047,196) for a grant also entitled, “Impact of TPO treatment on bone healing and angiogenesis in type 2 diabetes”. Finally, as noted above, we also obtained recent funding from the DOD PRORP-ARA “Repair of Traumatized Muscle Tissue for Improvement of Musculoskeletal Healing”, W81XWH-17-1-0626 (\$295,940) using the metacritical sized defect model we

developed during this award. We also recently submitted (as a subcontract) another application entitled, “Evaluation of a Novel Acute Care Biomaterial Strategy to Facilitate Improved Outcomes in the Treatment of Volumetric Muscle Loss Injuries”, W81XWH-17-PRORP-ARA (\$200,882).

#### **10. REFERENCES:**

- 1.) **Chu TM**, Warden SJ, Turner CH, Stewart RL. Segmental bone regeneration using a load-bearing biodegradable carrier of bone morphogenetic protein-2. *Biomaterials*. 2007;28(3):459-467.
- 2.) Davis KM, Griffin KS, **Chu T-MG**, Wenke JC, Corona BT, **McKinley TO**, **Kacena MA**. Muscle-bone interactions during fracture healing. *J Musculoskelet Neuronal Interact*, 15:1-9, 2015.
- 3.) Jewell E, Rytlewski J, **Anglen JO**, **McKinley TO**, Shively KD, **Chu T-MG**, **Kacena MA**. Surgical Fixation Hardware for Regeneration of Long Bone Segmental Defects: Translating Large Animal Model and Human Experiences. *Clinical Reviews in Bone and Mineral Metabolism*, 13:222-231, 2015.
- 4.) Griffin KS, Davis KM, **McKinley TO**, **Anglen JO**, **Chu T-MG**, Boerckel JD, **Kacena MA**. Evolution of bone grafting: Bone grafts and tissue engineering strategies for vascularized bone regeneration. *Clinical Reviews in Bone and Mineral Metabolism*, 13:232-244, 2015.

## **11. APPENDICES:**

Note, updated Quad chart is submitted as an attachment as directed in the instructions.

Full publications of numbers 1-4 above.

### **Additional Required Information Without Specific Location**

#### **Personnel receiving pay for research efforts:**

Melissa Kacena

Tien-Min Gabriel Chu

Jeffery Anglen

Todd McKinley

Yinghua Cheng

Liming Zhao

# Segmental bone regeneration using a load-bearing biodegradable carrier of bone morphogenetic protein-2

Tien-Min G. Chu<sup>a,b,\*</sup>, Stuart J. Warden<sup>c</sup>, Charles H. Turner<sup>a,b</sup>, Rena L. Stewart<sup>b</sup>

<sup>a</sup>*Department of Biomedical Engineering, Purdue School of Engineering and Technology, Indiana University-Purdue University Indianapolis, Indianapolis, IN 46202, USA*

<sup>b</sup>*Department of Orthopaedic Surgery, Indiana University School of Medicine, Indianapolis, IN 46202, USA*

<sup>c</sup>*Department of Physical Therapy, School of Health and Rehabilitation Sciences, Indiana University, Indianapolis, IN 46202, USA*

Received 12 July 2006; accepted 3 September 2006

Available online 25 September 2006

## Abstract

Segmental defect regeneration has been a clinical challenge. Current tissue-engineering approach using porous biodegradable scaffolds to delivery osteogenic cells and growth factors demonstrated success in facilitating bone regeneration in these cases. However, due to the lack of mechanical property, the porous scaffolds were evaluated in non-load bearing area or were stabilized with stress-shielding devices (bone plate or external fixation). In this paper, we tested a scaffold that does not require a bone plate because it has sufficient biomechanical strength. The tube-shaped scaffolds were manufactured from poly(propylene) fumarate/tricalcium phosphate (PPF/TCP) composites. Dicalcium phosphate dehydrate (DCPD) were used as bone morphogenetic protein-2 (BMP-2) carrier. Twenty-two scaffolds were implanted in 5 mm segmental defects in rat femurs stabilized with K-wire for 6 and 15 weeks with and without 10 µg of rhBMP-2. Bridging of the segmental defect was evaluated first radiographically and was confirmed by histology and micro-computer tomography (µCT) imaging. The scaffolds in the BMP group maintained the bone length throughout the duration of the study and allow for bridging. The scaffolds in the control group failed to induce bridging and collapsed at 15 weeks. Peripheral computed tomography (pQCT) showed that BMP-2 does not increase the bone mineral density in the callus. Finally, the scaffold in BMP group was found to restore the mechanical property of the rat femur after 15 weeks. Our results demonstrated that the load-bearing BMP-2 scaffold can maintain bone length and allow successfully regeneration in segmental defects.

© 2006 Elsevier Ltd. All rights reserved.

**Keywords:** Bone morphogenetic protein (BMP); Bone regeneration; Calcium phosphate cement; Bone tissue engineering; Free form fabrication

## 1. Introduction

Segmental bone defects resulting from trauma or pathology represent a common and significant clinical problem. Limb amputation was historically the principal treatment option for these defects as they typically do not heal spontaneously [1]. With advances in medicine and science, alternative treatment options have developed such as the use of bone-grafting techniques. Autologous bone grafts are preferred as they possess inherent osteoconductivity, osteo-

genicity and osteoinductivity. However, there is often limited supply of suitable bone for autologous grafting, and its collection is frequently associated with donor-site morbidity. An alternative is to use allogeneic bone grafts from donors or cadavers. These circumvent some of the limitations associated with harvesting autologous grafts, but allogeneic bone grafts lack osteogenicity, have limited osteoinductivity and present a risk of disease transmission. These limitations necessitate the pursuit of alternatives for the management of segmental bone defects, with the latest approach being to use tissue-engineering techniques.

Tissue engineering for bone typically involves coupling osteogenic cells and/or osteoinductive growth factors with osteoconductive scaffolds [2,3]. In terms of osteoinductive growth factors, most research has focused on the use of the bone morphogenic proteins (BMPs) and, in particular,

\*Corresponding author. Department of Biomedical Engineering, Purdue School of Engineering and Technology, Indiana University-Purdue University Indianapolis, Indianapolis, IN 46202, USA.

Tel./fax: +1 317 278 8716.

E-mail address: [tgchu@iupui.edu](mailto:tgchu@iupui.edu) (T.-M.G. Chu).

BMP-2 [1,4–8]. BMP-2 is a bone matrix protein that stimulates mesenchymal cell chemotaxis and proliferation, and promotes the differentiation of these cells into chondrocytes and osteoblasts [6,8]. These cellular effects bestow BMP-2 potent osteoinductive capabilities, which are primarily evident by the induction of new bone formation via a process of endochondral ossification when implanted at ectopic sites [9,10]. This osteoinductive action of BMP-2 is well established to be beneficial during the repair of fractures and segmental bone defects [1,5,7,8].

BMP-2 induces bone regeneration following injury and has been approved for limited clinical use in the form of recombinant human BMP-2 (rhBMP-2) [5]. However, rhBMP application has been limited by ongoing delivery issues. To facilitate retention of rhBMP-2 at the treatment site and reduce the effective dose, an appropriate carrier is required [9]. The preferred carrier consists of a scaffold that is both biocompatible and bioresorbable in order to limit tissue rejection and exposure to the scaffold material, respectively [11]. While numerous scaffolds have been manufactured that meet these requirements [12] many lack the ability to tolerate appreciable loads. This is of importance as segmental defects frequently occur in load-bearing bones. Scaffolds need to be able to tolerate loading so that patient morbidity is minimized during reparation and the structure of the engineered bone is optimized to the local mechanical environment. Few load-bearing scaffolds have been described in the literature, with many studies of tissue engineered bone regeneration with BMP-2 being conducted at non-load-bearing sites [13–16] or in defects stabilized with stress-shielding devices (bone plates or external fixation) [17–20].

In the current paper, we present a tissue-engineering strategy for bone regeneration using rhBMP-2 carried by a novel load-bearing biodegradable scaffold. Tube-shaped scaffolds were fabricated from a high strength biodegradable composite and calcium phosphate cement, and implanted into critical-sized defects in an established rodent model [21]. Defects and scaffolds were stabilized with a load-sharing device (intramedullary pin). The aim was to investigate the effect of our novel load-bearing scaffold carrying rhBMP-2 on segmental defect repair in the rat femur.

## 2. Materials and methods

### 2.1. Animals

Twenty-two adult male Long-Evans rats (weight = 450–550 g) were purchased from Charles River Laboratory (Wilmington, MA) and acclimatized for a minimum of 1 week prior to experimentation. Animals had ad libitum access to standard rat chow and water at all times, and all procedures were performed with prior approval of the Institutional Animal Care and Use Committee of Indiana University.

### 2.2. Scaffold manufacture

Polypropylene fumarate (PPF) with a molecular weight of 1750 g/mol and PI = 1.5 was obtained from Prof. Antonios Mikos (Rice University,

Houston, TX). A thermal-curable PPF/tricalcium phosphate (TCP) suspension was prepared by mixing PPF, *N*-vinyl pyrrolidinone (NVP), and TCP at a weight ratio of 1:0.75:0.66 [22]. Tube-shaped structures (outer diameter = 4 mm, inner diameter = 2 mm, height = 5 mm, with four side holes of 800 µm diameter) were created by the indirect casting technique developed by Chu et al. [23,24]. Briefly, a scaffold design was generated using commercial Computer-Aided-Design software and a negative model obtained by using Boolean computer operation. Wax casting-molds were fabricated on a 3-D Inkjet Printing Machine (T66, Solidscape Inc. NH) according to the model design. The PPF/TCP slurry was combined with 0.5% benzoyl peroxide (thermal initiator) and 10 µl of dimethyl *p*-toluidine (accelerator), and cast into the wax mold. Following polymerization, the wax mold was removed by acetone to reveal the scaffold. rhBMP-2 was aseptically added to half of the scaffolds prior to surgery by adding 10 µg of rhBMP-2 (Wyeth, Cambridge, MA) to porous dicalcium phosphate dihydrate (DCPD) cement previously packed into the side holes of the scaffold (BMP-2 group). In the remaining scaffolds, DCPD without rhBMP-2 was added to the side holes (control group).

### 2.3. Segmental defect induction and surgical implantation of the scaffolds

All animals underwent surgery to create a unilateral midshaft femur segmental defect into which either a rhBMP-containing scaffold (BMP group) or control scaffold (control group) was implanted. A non-scaffold control group was not used in this study since the non-healing nature of 5 mm segmental defects in the rat femur is well established [25,26]. Following a pre-operative subcutaneous dose of buprenorphine hydrochloride analgesia (0.05 mg/kg; Buprenex<sup>®</sup>—Reckitt Benckiser Pharmaceuticals Ltd., Inc., Richmond, VA), surgical anesthesia was achieved using a mixture of ketamine (60–80 mg/kg; Ketaset<sup>®</sup>—Fort Dodge Animal Health, Fort Dodge, IA) and xylazine (7.5 mg/kg; Sedazine<sup>®</sup>—Fort Dodge Animal Health, Fort Dodge, IA) introduced intraperitoneally. The fur was clipped and cleaned using alternating chlorhexidine and 70% ethanol scrubs. Using a sterile technique, a 30-mm longitudinal incision was made over the lateral thigh, beginning just distal to the lateral knee joint and extending proximally. The intermuscular septum between the vastus lateralis and hamstring muscles was divided using blunt dissection to localize the femur. The lateral structures stabilizing the patella were divided and the patella manually dislocated medially. A 5 mm segment of the midshaft femur was removed following two parallel osteotomies under irrigation using a Dremel drill (Robert Bosch Tool Corporation, Mount Prospect, IL) with attached diamond-embedded wafer blade (Super Flex Diamond Disc, Miltex Inc, York, PA). To stabilize the fracture, a 1.25 mm diameter stainless steel K-wire (Synthes Inc, West Chester, PA) was inserted retrograde into the distal intramedullary canal, beginning in the knee between the femoral condyles. The wire was advanced to the segment defect and a scaffold centered over the tip. The wire passed through the central canal of the scaffold and was further advanced in a retrograde fashion into the proximal intramedullary canal and through the greater trochanter (Fig. 1). The distal tip of the wire was cut flush with the femoral condyles. After thorough irrigation, the patella was relocated and stabilized with an absorbable suture, and the muscle and skin layers closed and sutured.

### 2.4. Radiographic analysis

In vivo X-rays were taken of eight rats ( $n = 4/\text{group}$ ) at 1, 3, 6, 12 and 15-weeks post-operatively using a portable X-ray machine (AMX-110, GE Corp, Waukesha, WI). The rats were anesthetized using isoflurane (Abbott Laboratories, North Chicago, IL) and placed prone on an X-ray film cassette 29 inches beneath the X-ray source. Exposure was at 60 kVp for 2.5 mAs. All films were evaluated in a blinded fashion by three independent evaluators using a three-point radiographic scoring system (0 = no callus formation; 1 = possible union across the gap; 2 = complete callus bridging across the gap).



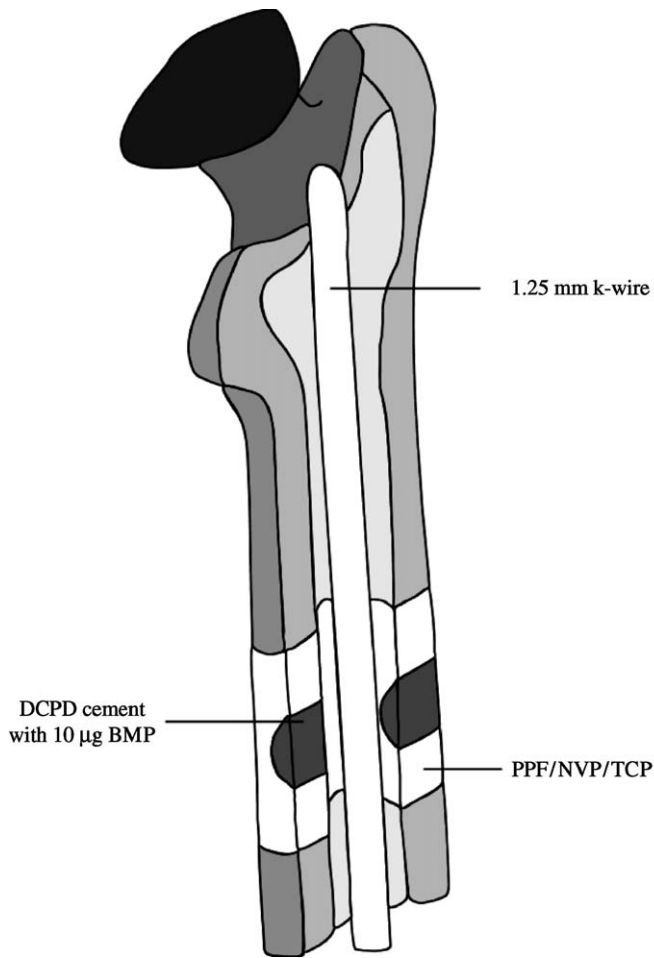


Fig. 1. Illustration of the BMP scaffold placed in rat femur segmental defect stabilized with intramedullary pin.

## 2.5. Assessment time points and specimen preparation

Animals were killed at 6 ( $n = 4/\text{group}$ ) and 15 ( $n = 7/\text{group}$ ) weeks post-operatively by inhalation of carbon dioxide followed by bilateral pneumothorax. In four rats per group, both femora were dissected free, and prepared for micro-computed tomography ( $\mu\text{CT}$ ), peripheral quantitative computed tomography (pQCT) and histological assessment by fixing in 10% neutral buffered formalin for 48 h and storing in 70% alcohol. In the remaining six rats in the 15-week group, hind limbs were prepared for mechanical testing by wrapping in gauze and storing in normal saline at  $-4^\circ\text{C}$ .

## 2.6. $\mu\text{CT}$

$\mu\text{CT}$  was performed on a randomly selected subgroup of segmental defects to visualize in three dimensions the stage of healing at 6- and 15-weeks post-operatively. The intramedullary K-wires were carefully removed before further assessment as metal causes beam-hardening artifacts during quantitative radiographic imaging. Each femur was centered in the gantry of a desktop  $\mu\text{CT}$  machine ( $\mu\text{CT}$ -20; Scanco Medical AG, Bassersdorf, Switzerland) and scanned at 50 kVp/32 keV (160  $\mu\text{A}$ ) with an isotropic voxel size of 8  $\mu\text{m}$ . The scanned slices were reconstructed to show in three dimensions the external and cut-away views of the reparative callus and scaffold.

## 2.7. pQCT

pQCT was used to assess callus and scaffold volumetric bone mineral density (vBMD;  $\text{mg}/\text{cm}^3$ ) at 6- and 15-weeks post-operatively. Each femur

was centered in the gantry of a pQCT machine (XCT Research SA+; Stratec Medizintechnik, Pforzheim, Germany) and scanned with a 70  $\mu\text{m}$  voxel size. Five 0.46 mm cross-sectional slices were scanned at 1 mm intervals, with the center slice coinciding with the center of the scaffold. Contouring mode 1 with a threshold of 240  $\text{mg}/\text{cm}^3$  was used to separate bone from soft tissue. Areas containing only the callus or scaffold were selected from the images using the region-of-interest (ROI) tool function, and the vBMD of the callus and scaffolds were determined, respectively.

## 2.8. Histological assessment

Femurs were processed for histomorphometry by washing, dehydrating in graded alcohols, and infiltrating and embedding undecalcified in methyl methacrylate (Aldrich Chemical Co., Inc., Milwaukee, WI). Thin (7  $\mu\text{m}$ ) sections were taken through the long axis of each femur in the sagittal plane using a rotating microtome (Reichert-Jung 2050; Reichert-Jung, Heidelberg, Germany). Alternating sections were stained with hematoxylin-and-eosin and McNeals tetrachrome. Sections were viewed on Nikon Optiphot fluorescence microscope (Nikon, Inc., Garden City, NJ).

## 2.9. Mechanical testing

For mechanical testing, femurs were brought to room temperature overnight in a saline bath, the gauze wrapping removed, soft-tissue dissected free and the intramedullary pin carefully removed. A custom-made four-point bending fixture with a span width of 22.0 mm between the lower contacts and 8.0 mm between the upper contacts was used. The femurs were positioned cranial side up across the lower contacts. A preload of 1.0 N and crosshead speed of 20.0 mm/min were used to break the femurs. Measurements made using force-versus-displacement curves included: ultimate force (N) or the height of the curve, stiffness (N/mm) or the maximum slope of the curve, and energy to ultimate force (mJ) or the area under the curve up to ultimate force.

## 2.10. Statistical analyses

Statistical analyses were performed with the Statistical Package for Social Sciences (SPSS 6.1.1; Norusis/SPSS Inc., Chicago, IL) software. All comparisons were two-tailed with a level of significance set at 0.05, unless otherwise indicated. Mann–Whitney  $U$ -tests were used to compare radiographic scores between scaffold groups (BMP vs. control) at each time point. vBMD was compared by two-way factorial analyses of variance (ANOVA), with scaffold group (BMP vs. control) and time since surgery (6 vs. 15 weeks) being the independent variables. Mechanical properties were compared by two-way, one-repeated measure ANOVA, with scaffold group (BMP vs. control) and surgical group (segmental defect vs. intact control) being the between- and within-animal independent variables, respectively. Paired or unpaired  $t$ -tests were performed in the event of a significant ANOVA interaction, with a Bonferroni correction to the level significance for the number of pair-wise comparisons. ANOVA main effects were explored in the event of a non-significant interaction. Surgical group effect sizes were assessed using mean percentage differences and their 95% confidence intervals (CIs) between femurs with segmental defects and contra-lateral intact control femurs, whereas time since surgery effect sizes were determined using mean differences and their 95% CI between 6 and 15 weeks.

# 3. Results

## 3.1. Radiographic analysis

Qualitative assessment of the X-rays films showed no bone formation in any specimen at 1 week after surgery. At 3 weeks, continuous callus had formed and bridged across the gap defect in two of the four rats in the BMP group.

In the control group, some cortical bone thickening and callus formation was noticed immediately adjacent to the scaffold; however, callus did not bridge the gap. At 6 weeks, the callus bridge in the BMP group showed signs of consolidation and further thickening of the cortex next to the scaffold. In the control group, isolated radiopaque spots were noticed (islands of bone formation), but callus bridging was not present. Further thickening and remodeling of the callus was seen at 12 and 15 weeks in the BMP groups. At 12 and 15 weeks the control group showed increased callus size in the area adjacent to the scaffold, but there was no X-ray evidence of bridging callus (Fig. 2). In the X-ray score, all rats in the BMP group showed a score of 0 at week 1. Three rats received scores of 1 and 2 at week 3. At 6 weeks, all rats received a score of 2. All rats in the control group received a score of 0 till 12 weeks. One rat received a score of 1 at 15 weeks (Table 1).

There were no significant differences on radiographic scoring between the BMP and control groups after 1 ( $p = 1.00$ ) or 3 ( $p = 0.11$ ) weeks. After 6, 12 and 15 weeks, defects in the BMP group had significantly greater radiographic scores than those in the control group (all  $p = 0.03$ ), indicating that the former had more advanced healing.

### 3.2. Histology

Histology sections at 6 weeks showed mineralized callus bridging the gap in the BMP group. Normal trabeculae were found between the periosteal callus and the scaffold (Fig. 3A). Residual DCPD can be seen in the side holes (Fig. 3B). Under H&E stain, normal fatty bone marrow was restored at 6 weeks (not shown). No inflammation reaction was seen in either BMP group or control group.

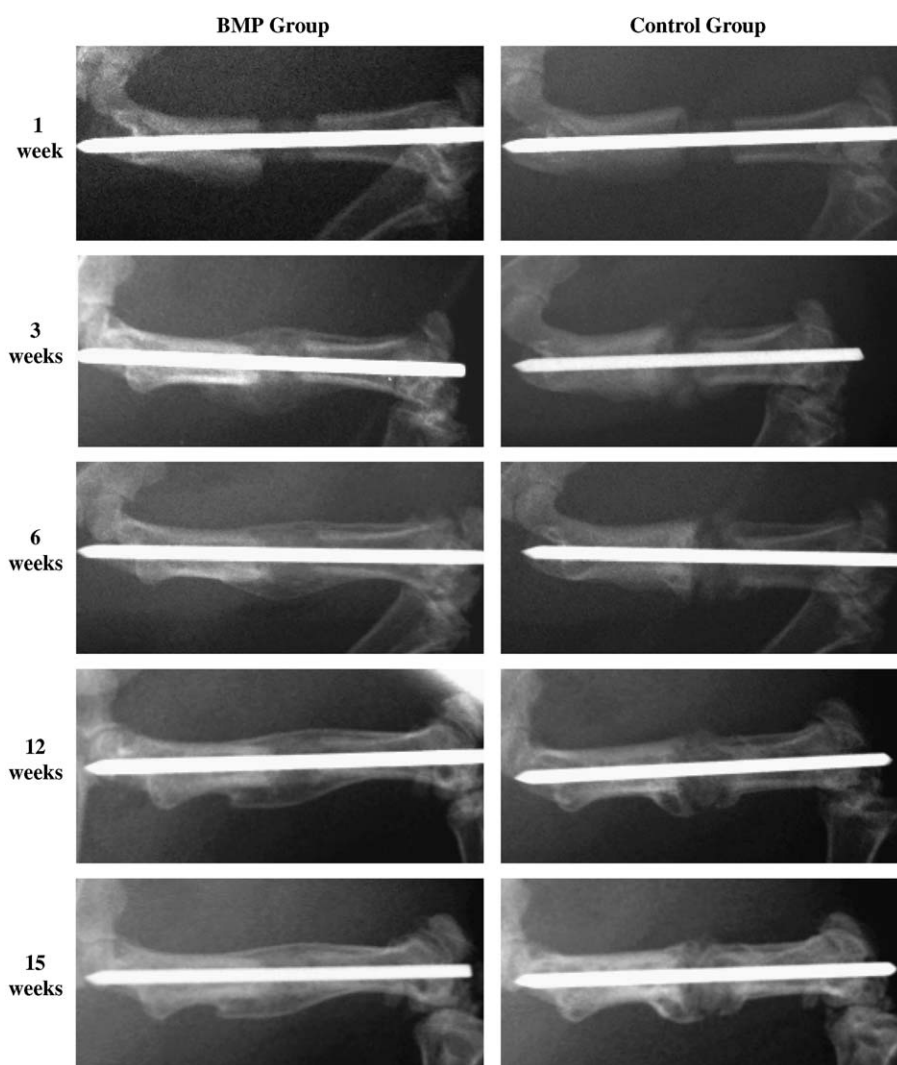


Fig. 2. Representative serial radiological images of segmental defects in the BMP and control groups at 1, 3, 6, 12 and 15 weeks post-operatively. At 3 weeks, callus had formed and bridged the segmental defect in the BMP group. In the control group, some cortical bone thickening and callus formation was evident immediately adjacent to the scaffold; however, there was no bridging callus. Between 6 and 15 weeks, the bridging callus in the BMP group showed signs of consolidation and remodeling. In contrast, in the control group only isolated regions of radio-opacity were evident within the defect region and no bridging callus was present.

In the control group, the histology showed characteristics of psuedoarthrosis with cartilage forming at the junction between the scaffold and the bone end. The periosteal callus did not bridge the gap (Fig. 3C). The histology of the BMP group at 15 weeks showed mature trabeculae between the scaffold and the periosteal callus (Fig. 3D). In the

control group, the gap was filled with fibrous tissue and the scaffolds started to crumble (not shown).

### 3.3. $\mu$ CT analysis

$\mu$ CT scans showed continuous callus formation around the scaffold in the BMP group at 6 weeks. Bone has also formed inside the marrow cavity next to the intramedullary pin (pin removed prior to scanning). Normal trabecular bone was found between the cortical layer of the callus and the BMP group scaffolds. In contrast, the control group at 6 weeks shows minimal bone formation outside the scaffold and the callus did not bridge the gap. At 15 weeks, the bridging callus and the trabeculae between the scaffold and the cortex of the callus is evident in the BMP group (Fig. 4).

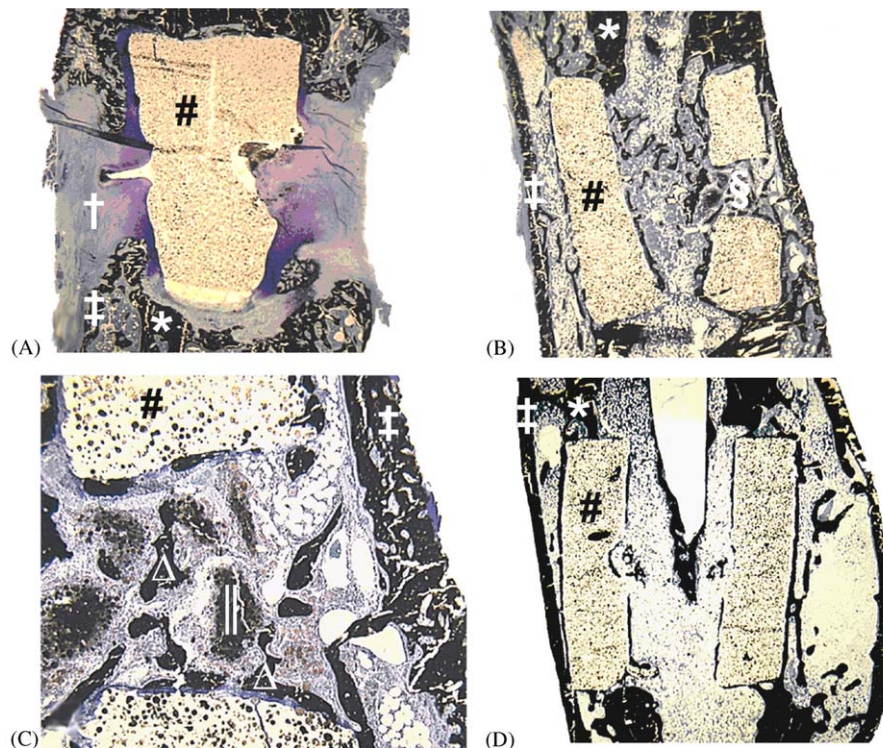
The histology and  $\mu$ CT results confirms the radiographic finding that defects in the BMP group to be bridged with mineralized callus that was integrated with the scaffold.

### 3.4. pQCT analysis

At 6 weeks, the measured vBMD of the callus for the BMP group and the control group was  $724.05 \pm 108.71$  and  $742.00 \pm 54.46 \text{ mg/cm}^3$ , respectively. At 15 weeks, the vBMD of the callus increased to  $959.06 \pm 81.47$  and

**Table 1**  
Table showing the scores on bridging based on x-ray films at 1, 3, 6, 12, and 15 after surgery. X-ray scores: 0 = no callus formation; 1 = possible union across the gap; 2 = complete callus bridging across the gap

	Week	X-ray score		
		0	1	2
Control group ( $N = 4$ )	1	4	0	0
	3	4	0	0
	6	4	0	0
	12	4	0	0
	15	3	1	0
BMP group ( $N = 4$ )	1	4	0	0
	3	1	1	2
	6	0	0	4
	12	0	0	4
	15	0	0	4



**Fig. 3.** Representative histological images of segmental defects in the (A) control and (B and C) rhBMP groups at 6-weeks post-operatively. Sections are stained with McNeal's tetrachrome, which stains bone black. (A) Segmental defects in the control group demonstrated cartilaginous union, whereas (B) defects in the BMP group were bridged by mineralized callus that (C) invaded the side hole and was on the surface of the scaffold, indicating scaffold osteoconductivity. Inflammatory cells were not present in either scaffold group. (D) By 16-weeks post-operatively in the BMP group, the osteoconductivity of the scaffold is evident by the formation of new bone on its surfaces. \* = original cortex of the femoral diaphysis, # = weight bearing biodegradable scaffold, † = cartilaginous tissue, § = mineralized callus, Δ = side hole within the scaffold, || = residual dicalcium phosphate dihydrate cement carrying rhBMP-2, Δ = mineralized callus within the side hole and on the surface of the scaffold.






Fig. 4. Representative external and cut-away images of segmental defects in the (A) control and (B) BMP groups, as assessed by microcomputed tomography at 6-weeks post-operatively. (A) Segmental defects in the control group had minimal bone surrounding the scaffold and the reparative callus did not bridge the defect. (B) In contrast, the BMP group had a continuous mineralized callus around the scaffold, and bridging trabeculae beneath the cortical layer of the callus were integrated with the scaffold, indicating scaffold osteoconductivity. (C) By 16-weeks post-operatively in the BMP-group, the bridging trabeculae had thickened and there is evidence of bone formation of bone on the surfaces of the scaffold, indicating scaffold osteoconductivity. \* = original cortex of the femoral diaphysis, # = weight bearing biodegradable scaffold, † = mineralized callus, ‡ = side hole within the scaffold.

$894.66 \pm 59.82 \text{ mg/cm}^3$  for BMP group and control group. The measured vBMD in the native femur was  $920.95 \pm 49.53 \text{ mg/cm}^3$ .

The mineral density of the scaffold was measured to evaluate the in vivo absorption of TCP in the scaffold. The mineral density of the scaffolds after 6 weeks of implantation in vivo was  $625.96 \pm 26.14 \text{ mg/cm}^3$  in the BMP group and  $613.59 \pm 16.35 \text{ mg/cm}^3$  in the control group. After 15 weeks of implantation in vivo, the mineral density of scaffold was  $579.42 \pm 13.99 \text{ mg/cm}^3$  in the BMP group and  $574.82 \pm 37.50 \text{ mg/cm}^3$  in the control group.

There were no significant interactions between group (BMP vs. control) and time since surgery (6 vs. 15 weeks) on either callus ( $p = 0.28$ ) or scaffold ( $p = 0.79$ ) vBMD (Fig. 4). Similarly, there were no group main effects on either callus ( $p = 0.36$ ) or scaffold ( $p = 0.62$ ) vBMD. In contrast, there were significant main effects for time since surgery on both callus ( $p < 0.001$ ) and scaffold ( $p < 0.01$ ) vBMD. Callus vBMD was 26% greater (mean difference =  $193.2 \text{ mg/cm}^3$ , 95% CI =  $118.2$  to  $268.2 \text{ mg/cm}^3$ ) and scaffold vBMD was 6.9% lower (mean difference =  $-42.4 \text{ mg/cm}^3$ , 95% CI =  $-65.7$  to  $-19.1 \text{ mg/cm}^3$ ) at 15-weeks post-surgery than at 6 weeks (Fig. 5).

### 3.5. Mechanical property results

Mechanical properties of the femurs were only measured at 15 weeks. There were significant interactions between scaffold group (BMP vs. control) and surgical group (segmental defect vs. intact control) on ultimate force ( $p = 0.01$ ) and stiffness ( $p < 0.05$ ), but not energy to ultimate force ( $p = 0.10$ ) (Fig. 6). Segmental defects in the BMP group had 290%, 286% and 234% greater ultimate force ( $p < 0.01$ ), stiffness ( $p = 0.04$ ) and energy to ultimate force ( $p = 0.02$ ) than segmental defects in the control group, respectively (Fig. 6). There were no side-to-side differences in ultimate force (%diff =  $-1.4\%$ , 95% CI =  $-35.7\%$  to  $32.8\%$ ), stiffness (%diff =  $-15.5\%$ , 95% CI =  $-68.5\%$  to  $37.6\%$ ) or energy to ultimate force (%diff =  $-11.7\%$ , 95% CI =  $-28.8\%$  to  $5.3\%$ ) in the BMP group between femurs with segmental defects and contra-lateral, intact control femurs (all  $p = 0.15$ – $0.64$ ). In contrast, femurs with segmental defects in the control group had lower ultimate force (%diff =  $-66.1\%$ , 95% CI =  $-105.8\%$  to  $-26.5\%$ ) and stiffness (%diff =  $-62.6\%$ , 95% CI =  $-96.6\%$  to  $-28.5\%$ ) than contra-lateral, intact control femurs (all  $p < 0.02$ ). Energy to ultimate force between femurs with segmental defects and

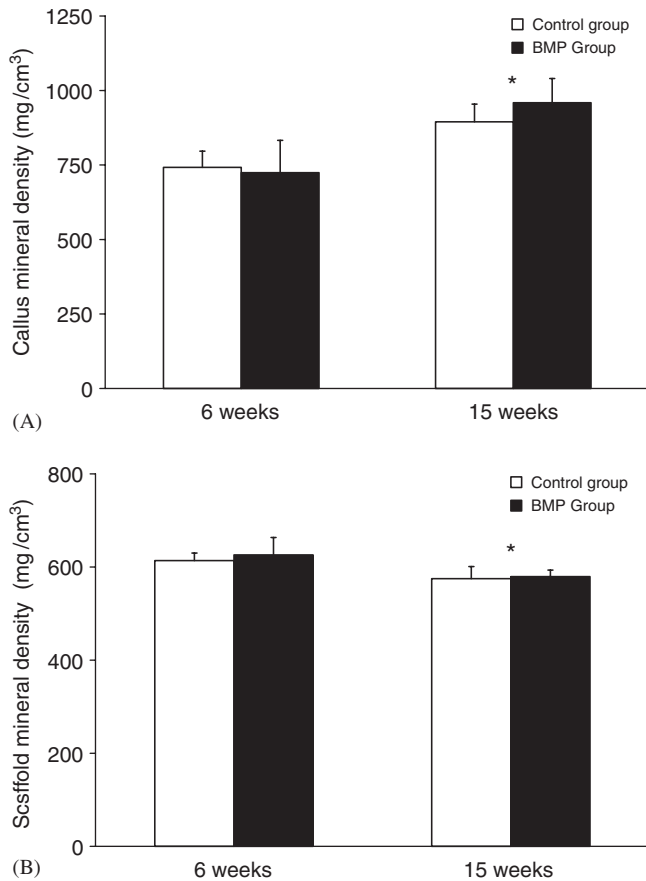


Fig. 5. Effect of scaffold group on volumetric bone mineral density (vBMD) of the: (A) callus and (B) scaffold, as assessed by peripheral quantitative computed tomography at 6- and 15-weeks post-operatively. \* indicates significant main effect for time since surgery (6 vs. 15 weeks) ( $p < 0.01$ ).

contra-lateral, intact control femurs did not differ in the control group (%diff = -61.4%, 95% CI = -126.4% to 3.6%) ( $p = 0.06$ ).

#### 4. Discussion

We have shown that scaffold made from high-strength biodegradable composite can be used as BMP-2 carrier to facilitate segmental defect regeneration in partial load-bearing condition, such as in the intramedullary pin fixation. This is clinically relevant since intramedullary pin fixation is commonly used for segmental defect fixation. In a retrospective study of ten patients treated for large bone defects, six of the 10 treatments involve the use of intramedullary pins [27]. In another retrospective study, six of the seven patients treated for acute segmental defects involve the use of intramedullary pins [28]. In research, Tiyyapatanaputi et al. [29] demonstrated the use of pin to stabilize autograft, isograft and allograft in rat femoral defect model and found that the fixation using K-wire as intramedullary pin provided reproducible results in stabilized structural allograft. However, studies using

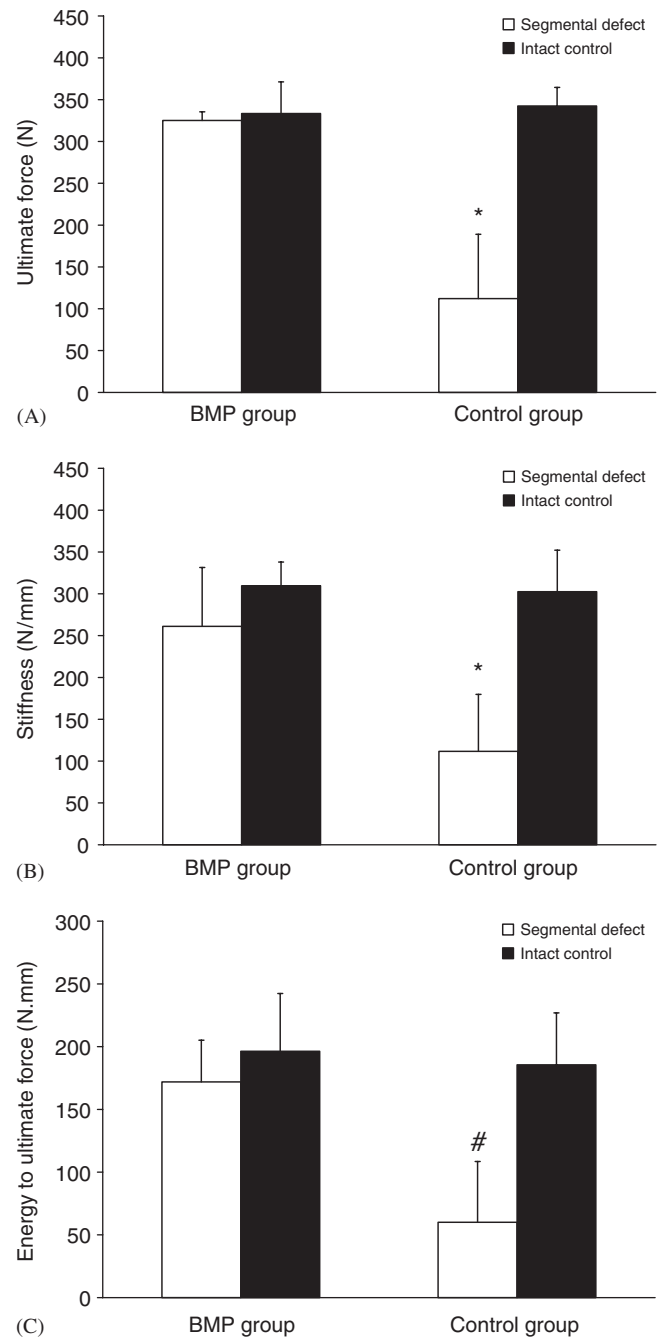


Fig. 6. Effect of scaffold group on femoral: (A) ultimate force, (B) stiffness and (C) energy to ultimate force, as assessed by mechanical testing at 15-weeks post-operatively. \* indicates significantly different from all other groups ( $p < 0.01$ ). # indicates significantly different from segmental defect in BMP group ( $p = 0.02$ ).

intramedullary pin for stabilization tissue-engineering scaffolds has been lacking.

In this paper, we stabilized the PPF/TCP tissue-engineering scaffold by a 1.25 mm K-wire as intramedullary pin. This is a load-sharing model since the loads are shared by the friction between the intramedullary pin and the contact areas in the medullary canal and by the scaffolds. All BMP groups show bridging callus, indicating

a stable biomechanical environment conducive to the formation of callus. Our previous experience showed that the scaffolds made from DCPD by itself (compressive strength = 0.5 MPa) collapsed 1 day after implantation, indicating that the rats bear load on the scaffolds (unpublished results). The PPF/TCP scaffold has an initial compressive strength of 23 MPa, but gradually reduces to 12 MPa after 12 weeks of incubation in phosphate buffered solution at 37 °C [30]. The fact that PPF/TCP scaffold did not collapse during implantation indicates that the initial strength of the scaffold is sufficient to sustain the femoral loading in the rat model. When callus bridging failed to occur, the PPF/TCP scaffolds eventually collapsed after 15 weeks demonstrating that the degraded compressive strength of PPF/TCP at 15 weeks is no longer sufficient to support rat locomotor loads. This result together with the fact that the scaffold in the BMP group is still intact at 15 weeks also indicates that the bridging callus in the BMP group has assumed loading sharing/bearing function in the defect.

DCPD is biodegradable and has been used as BMP-2 carrier [25]. In this study, a dose of 10 µg of BMP-2 was found to induce callus formation, similar to the results by Ohura et al. [25] and Yasko et al. [26]. PPF/TCP is biodegradable [31], though very slowly, as pQCT measurements demonstrated that the scaffold density was reduced by less than 10% in 15 weeks of implantation. The long effect of the degradation byproduct on tissue is critical and will need to be studied in the future. Nonetheless, this study established that a compressive strength of 23 MPa will provide sufficient strength to withstand the initial load placed on the scaffold when the scaffold is implanted in rat femoral gap stabilized with intramedullary pin.

In BMP group and control group, we found no difference in callus vBMD, in consistent with the findings by Hyun et al. [32] where bone density in BMP-2 induced new bone was the same as normal bone. From our results, we conclude that it is the quantity and the distribution of the callus, but not the bone mineral density, that makes the difference between the BMP group and the control group.

## 5. Conclusions

In this study, investigated a tissue-engineering strategy for bone regeneration using BMP-2 carried by a load-bearing biodegradable scaffold. We found that critical-sized segmental defects in the rodent femur have advanced radiological, histological and mechanical healing using our tissue engineering strategy of load-bearing scaffold stabilized with intramedullary pins. Radiographical and histological healing is enhanced with weight-bearing biodegradable scaffolds of rhBMP-2.

The weight-bearing biodegradable scaffold of BMP-2 do not influence the callus mineral density. Finally, the mechanical properties of the segmental defects are restored with weight-bearing biodegradable scaffolds of BMP-2.

## Acknowledgments

The authors would like to thank Prof. Antonio Mikos for providing the poly(propylene fumarate) used in this study. The authors would also like to thank Wyeth Co. for providing the rhBMP-2. The research was supported by NIH EB005426.

## References

- [1] Giannoudis PV, Pountos I. Tissue regeneration. The past, the present and the future. *Injury* 2005;36(Suppl. 4):S2–5.
- [2] Buma P, Schreurs W, Verdonchot N. Skeletal tissue engineering—from in vitro studies to large animal models. *Biomaterials* 2004;25(9):1487–95.
- [3] Mistry AS, Mikos AG. Tissue engineering strategies for bone regeneration. *Adv Biochem Eng Biotechnol* 2005;94:1–22.
- [4] Cowan CM, Soo C, Ting K, Wu B. Evolving concepts in bone tissue engineering. *Curr Top Dev Biol* 2005;66:239–85.
- [5] Mont MA, Ragland PS, Biggins B, Friedlaender G, Patel T, Cook S, et al. Use of bone morphogenetic proteins for musculoskeletal applications. An overview. *J Bone Joint Surg Am* 2004;86-A(Suppl. 2):41–55.
- [6] Reddi AH. Role of morphogenetic proteins in skeletal tissue engineering and regeneration. *Nat Biotechnol* 1998;16(3):247–52.
- [7] Termaat MF, Den Boer FC, Bakker FC, Patka P, Haarman HJ. Bone morphogenetic proteins. Development and clinical efficacy in the treatment of fractures and bone defects. *J Bone Joint Surg Am* 2005;87(6):1367–78.
- [8] Wozney JM, Rosen V. Bone morphogenetic protein and bone morphogenetic protein gene family in bone formation and repair. *Clin Orthop Relat Res* 1998(346):26–37.
- [9] Urist MR, Lietze A, Dawson E. Beta-tricalcium phosphate delivery system for bone morphogenetic protein. *Clin Orthop Relat Res* 1984(187):277–80.
- [10] Wang EA, Rosen V, D'Alessandro JS, Bauduy M, Cordes P, Harada T, et al. Recombinant human bone morphogenetic protein induces bone formation. *Proc Natl Acad Sci USA* 1990;87(6):2220–4.
- [11] Seeherman H, Wozney JM. Delivery of bone morphogenetic proteins for orthopedic tissue regeneration. *Cytokine Growth Factor Rev* 2005;16(3):329–45.
- [12] Perry CR. Bone repair techniques, bone graft, and bone graft substitutes. *Clin Orthop Relat Res* 1999(360):71–86.
- [13] Akamaru T, Suh D, Boden SD, Kim HS, Minamide A, Louis-Ugbo J. Simple carrier matrix modifications can enhance delivery of recombinant human bone morphogenetic protein-2 for posterolateral spine fusion. *Spine* 2003;28(5):429–34.
- [14] Arosarena OA, Collins WL. Bone regeneration in the rat mandible with bone morphogenetic protein-2: a comparison of two carriers. *Otolaryngol Head Neck Surg* 2005;132(4):592–7.
- [15] Hu Y, Zhang C, Zhang S, Xiong Z, Xu J. Development of a porous poly(L-lactic acid)/hydroxyapatite/collagen scaffold as a BMP delivery system and its use in healing canine segmental bone defect. *J Biomed Mater Res A* 2003;67(2):591–8.
- [16] Suzuki A, Terai H, Toyoda H, Namikawa T, Yokota Y, Tsunoda T, et al. A biodegradable delivery system for antibiotics and recombinant human bone morphogenetic protein-2: a potential treatment for infected bone defects. *J Orthop Res* 2006;24(3):327–32.
- [17] Baltzer AW, Lattermann C, Whalen JD, Wooley P, Weiss K, Grimm M, et al. Genetic enhancement of fracture repair: healing of an experimental segmental defect by adenoviral transfer of the BMP-2 gene. *Gene Ther* 2000;7(9):734–9.
- [18] Betz OB, Betz VM, Nazarian A, Pilapil CG, Vrahas MS, Bouxsein ML, et al. Direct percutaneous gene delivery to enhance healing of segmental bone defects. *J Bone Joint Surg Am* 2006;88(2):355–65.

- [19] Lieberman JR, Daluiski A, Stevenson S, Wu L, McAllister P, Lee YP, et al. The effect of regional gene therapy with bone morphogenetic protein-2-producing bone-marrow cells on the repair of segmental femoral defects in rats. *J Bone Joint Surg Am* 1999;81(7):905–17.
- [20] Xu XL, Tang T, Dai K, Zhu Z, Guo XE, Yu C, et al. Immune response and effect of adenovirus-mediated human BMP-2 gene transfer on the repair of segmental tibial bone defects in goats. *Acta Orthop* 2005;76(5):637–46.
- [21] Einhorn TA, Lane JM, Burstein AH, Kopman CR, Vigorita VJ. The healing of segmental bone defects induced by demineralized bone matrix. A radiographic and biomechanical study. *J Bone Joint Surg Am* 1984;66(2):274–9.
- [22] Chu TM, Flanagan CL, Hollister S, Feinberg SE, Fisher JP, Mikos AG. The mechanical and in vivo performance of 3-D poly(propylene fumarate)/tricalcium phosphate scaffolds. In: *Biomaterials SF*, editor. 29th annual meeting of Society for Biomaterials. Reno, NV: Society for Biomaterials; 2003. p. 660.
- [23] Chu TM, Halloran JW, Hollister S, Feinberg SE. Hydroxyapatite implants with designed internal architecture. *J Mater Sci: Mater Med* 2001;12:471–8.
- [24] Chu TM, Orton DG, Hollister SJ, Feinberg SE, Halloran JW. Mechanical and in vivo performance of hydroxyapatite implants with controlled architectures. *Biomaterials* 2002;23(5):1283–93.
- [25] Ohura K, Hamanishi C, Tanaka S, Matsuda N. Healing of segmental bone defects in rats induced by a beta-TCP-MCPM cement combined with rhBMP-2. *J Biomed Mater Res* 1999;44(2):168–75.
- [26] Yasko AW, Lane JM, Fellingner EJ, Rosen V, Wozney JM, Wang EA. The healing of segmental bone defects, induced by recombinant human bone morphogenetic protein (rhBMP-2). A radiographic, histological, and biomechanical study in rats. *J Bone Joint Surg Am* 1992;74(5):659–70.
- [27] Wilson Jr PD. A clinical study of the biomechanical behavior of massive bone transplants used to reconstruct large bone defects. *Clin Orthop* 1972;87:81–109.
- [28] Chmell MJ, McAndrew MP, Thomas R, Schwartz HS. Structural allografts for reconstruction of lower extremity open fractures with 10 centimeters or more of acute segmental defects. *J Orthop Trauma* 1995;9(3):222–6.
- [29] Tiyyapattanaputi P, Rubery PT, Carmouche J, Schwarz EM, O'Keefe RJ, Zhang X. A novel murine segmental femoral graft model. *J Orthop Res* 2004;22(6):1254–60.
- [30] Chu TG, Sargent PW, Warden SJ, Turner CH, Stewart RL. Preliminary evaluation of a load-bearing BMP-2 carrier for segmental defect regeneration. *Biomed Sci Instrum* 2006;42:42–6.
- [31] Peter SJ, Miller ST, Zhu G, Yasko AW, Mikos AG. In vivo degradation of a poly(propylene fumarate)/beta-tricalcium phosphate injectable composite scaffold. *J Biomed Mater Res* 1998; 41(1):1–7.
- [32] Hyun SJ, Han DK, Choi SH, Chai JK, Cho KS, Kim CK, et al. Effect of recombinant human bone morphogenetic protein-2, -4, and -7 on bone formation in rat calvarial defects. *J Periodontol* 2005;76(10):1667–74.

# Muscle-bone interactions during fracture healing

K.M. Davis<sup>1\*</sup>, K.S. Griffin<sup>1\*</sup>, T-M.G. Chu<sup>2</sup>, J.C. Wenke<sup>3</sup>, B.T. Corona<sup>3</sup>, T.O. McKinley<sup>1</sup>, M.A. Kacena<sup>1</sup>

<sup>1</sup>Department of Orthopaedic Surgery, Indiana University School of Medicine, Indianapolis, IN;

<sup>2</sup>Department of Restorative Dentistry, Indiana University School of Dentistry, Indianapolis, IN;

<sup>3</sup>Extremity Trauma & Regenerative Medicine Task Area, United States Army Institute of Surgical Research, San Antonio, TX

\*contributed equally to this work

---

## Abstract

Although it is generally accepted that the rate and strength of fracture healing is intimately linked to the integrity of surrounding soft tissues, the contribution of muscle has largely been viewed as a vascular supply for oxygen and nutrient exchange. However, more is becoming known about the cellular and paracrine contributions of muscle to the fracture healing process. Research has shown that muscle is capable of supplying osteoprogenitor cells in cases where the periosteum is insufficient, and the muscular osteoprogenitors possess similar osteogenic potential to those derived from the periosteum. Muscle's secretome includes proteins capable of inhibiting or enhancing osteogenesis and myogenesis following musculoskeletal injury and can be garnered for therapeutic use in patients with traumatic musculoskeletal injuries. In this review, we will highlight the current knowledge on muscle-bone interaction in the context of fracture healing as well as concisely present the current models to study such interactions.

**Keywords:** Muscle, Bone, Fracture, Mesenchymal Stem Cells, Paracrine

---

## Introduction

In the orthopaedic field, the muscle-bone relationship is of utmost importance as surgeons must often battle increased complications, morbidity, and delayed fracture healing in cases with extensive soft tissue damage resulting from high energy trauma. The Gustilo-Anderson open fracture classification scale, which has been commonly used for nearly 4 decades, classifies severity almost solely on soft tissue (primarily muscle) injury, and the complication rate is much higher in fractures with soft tissue damage<sup>1</sup>. Although it has long been accepted that intact surrounding soft tissues are important in the fracture healing process, the underlying mechanisms have not been fully elucidated. However, basic science and translational research have made advances in the understanding of how muscle injuries impede fracture healing.

To understand muscle's potential role in fracture repair, a comprehension of the repair process is necessary. In brief, fracture repair consists of three chronological and overlapping phases: a reactive phase, a reparative phase, and a remodeling phase. The reactive phase peaks within the first 24-48 hours and lasts less than 1 week. During this phase, endothelial damage to the vasculature causes a hematoma, drawing in inflammatory cells (lymphocytes, polymorphonuclear cells, monocytes) and fibroblasts to form granulation tissue<sup>2</sup>. The granulation tissue is important for vascular ingrowth as well as the recruitment of mesenchymal stem cells (MSCs). The inflammatory cells release cytokines such as TNF- $\alpha$ , IL-1, IL-6, IL-11, and IL-18 to induce osteogenic differentiation of MSCs as well as promote angiogenesis<sup>3</sup>. The reparative phase begins within a few days after fracture and lasts several weeks. Pluripotent mesenchymal cells, dependent on local strain and oxygen tension, differentiate into fibroblasts, chondroblasts, or osteoblasts. Healing can occur through intramembranous ossification alone (direct healing) or a combination of intramembranous and endochondral ossification (indirect healing), depending on the degree of mechanical stability<sup>4</sup>. In endochondral ossification, a fibrocartilage callus forms and is subsequently replaced by a bony callus with woven bone deposition. In intramembranous ossification, lamellar bone regeneration occurs without the need for remodeling, but it requires stable fixation<sup>2</sup>. Thus, the ossification process is dependent on

---

The authors have no conflict of interest.

Corresponding author: Melissa Kacena, Ph.D., August M. Watanabe Translational Scholar, Showalter Scholar, Associate Professor of Orthopaedic Surgery, Indiana University School of Medicine, 1120 South Drive FH 115, Indianapolis, IN 46202, United States  
E-mail: mkacena@iupui.edu

Edited by: M. Hamrick  
Accepted 8 December 2014



the stability of the fracture site. During the remodeling phase, the woven bone is replaced with lamellar bone, and the bone is gradually remodeled under mechanical stress to its original contour. This phase can last for several years<sup>2,5</sup>.

## Vascularization and fracture healing

The importance of vascularization in osteogenesis cannot be overemphasized, as a nearby vascular supply is required for both normal development and bone regeneration<sup>6-9</sup>. Indeed, an early step in the fracture healing process is the formation of granulation tissue consisting of connective tissue and small blood vessels<sup>10,11</sup>, reinforcing the importance of vascularization in healing. Surrounding soft tissues at the fracture site primarily have been considered an important vascular source<sup>12</sup> to deliver oxygen<sup>13</sup>, nutrients<sup>13</sup>, and potential osteoprogenitor cells to the injured area<sup>14,15</sup>. In the surrounding soft tissue are MSCs and pericytes, which are crucial for angiogenesis in the wounded tissue<sup>16,17</sup>. In the clinical arena, the rate of non-union is 4 times higher in cases with reduced vascular function<sup>18</sup>, and in animal fracture models that disrupt angiogenesis, bone formation is hindered through the suppression of osteoblast proliferation<sup>18-20</sup>. Muscle flap coverage has been shown to increase bone blood flow and the rate of osteotomy union compared to skin tissue coverage, supporting the vascular role of muscle in bone regeneration<sup>21-23</sup>.

Although vascularization has been shown to be critical for regeneration, there has been evidence of nearly equal vascularization in healed bone and non-unions in animal studies as well as in human patients<sup>20,24-26</sup>. In a murine open tibial fracture model, Harry et al. observed faster fracture healing in musculocutaneous compared to fasciocutaneous flaps, despite the musculocutaneous flaps having decreased vascularization<sup>27</sup>. These studies point to a more extensive role of muscle in the repair process than solely as a vascular supply.

## Osteoprogenitors derived from muscle

The relationship between muscle and bone has been observed for decades and continues to be elucidated. Urist first deduced muscle's ability to induce bone formation in 1965 when decalcified bone implanted into muscle resulted in new bone formation<sup>28,29</sup>. In fracture healing studies in multiple species, callus formation tends to be the largest and most dense at the interface between bone and muscle<sup>30</sup>, suggesting that muscle contributes to callus formation or provides a suitable environment for its occurrence.

Muscle is also a common site for ectopic bone formation following physical trauma<sup>31</sup>, orthopaedic surgery<sup>32</sup>, or due to disease like fibrodysplasia ossificans progressiva, which has been identified to be a result of a mutation in a gene encoding a bone morphogenetic protein (BMP) receptor<sup>33</sup>. BMPs, a group of growth factors involved in tissue architecture throughout the body, are of particular importance to bone formation as they induce osteoblast differentiation.

In the presence of BMPs, cells derived from muscle are ca-

pable of differentiating into cells expressing bone markers<sup>34-37</sup>. That muscle-derived cells capable of displaying osteogenic potential under proper conditions could partly explain the importance of muscle in fracture healing aside from their role in vascularization. In addition, muscle may be able to influence bone in a manner unlike any other tissue. When both muscle and fat are activated by exposure to a BMP-2 encoded adenovirus, the "gene-activated" muscle results in more consistent bone regeneration than the "gene-activated" fat<sup>38</sup>. Furthermore, when muscle-derived stem cells (MDSCs) are recruited and driven to osteogenic differentiation by BMPs, they display an osteogenic potential that is equivalent to those derived from bone marrow<sup>39</sup>. Lineage-traced MDSCs in a fracture healing model have been found to alter gene expression to give rise to chondrocytes, up-regulating chondrogenic markers Sox9 and Nkx3.2 and down-regulating the muscle marker Pax3<sup>36</sup>. These studies provide evidence that, in the appropriate environmental conditions, muscle can supply osteoprogenitor cells required for the fracture repair process.

It should be noted, however, that MDSCs are not the sole osteoprogenitor cells derived from muscle. C2C12 myoblasts infected with a retroviral vector have been found to overexpress osteoactivin (OA) and transdifferentiate into osteoblasts and express bone-specific markers<sup>40</sup>. Muscle-derived stromal cells, when administered TNF- $\alpha$  at low concentrations, are also capable of undergoing recruitment and osteogenic differentiation<sup>41</sup>. Muscle satellite cells were originally believed to be muscle stem cells restricted to the myogenic lineage<sup>42</sup>, but the osteogenic potential of these cells has been observed under several conditions. Satellite cell-derived myoblasts have been shown to differentiate into osteocytes following treatment with BMPs<sup>43</sup>, into osteoblasts *in vivo* and *in vitro* in the presence of platelet-rich plasma<sup>44</sup>, and the osteogenic potential of satellite cells can increase in response to cutaneous burn trauma<sup>45</sup>. Satellite cells have been observed to express both myoblastic (Pax7, MyoD) and osteoblastic (alkaline phosphatase, Runx2) markers and are capable of differentiating into osteoblasts spontaneously<sup>46</sup>.

The abundance of potential osteogenic cells derived from muscle could have applications in the future in tissue engineering techniques, particularly in cases where the bone marrow or periosteum is compromised. It has been commonly believed that in fractures in which the periosteum is intact, repair occurs largely through endochondral ossification driven by a periosteal supply of cells<sup>10,47-50</sup>. Indeed, in open fractures with a stripped periosteum, Liu et al. found that myogenic cells of the MyoD-lineage contributed to fracture repair, but MyoD-expressing cells were not incorporated into the callus in the case of a closed fracture with intact periosteum<sup>51</sup>. Such a study demonstrates that myogenic cells can be activated to serve as a secondary supply of cells when the periosteal supply becomes compromised<sup>52,53</sup>. These recent findings of muscle's ability to augment the periosteal supply of osteoprogenitor cells provide insight into the clinical observations of prolonged recovery time and increased morbidity that is especially seen associated with high energy fractures with substantial soft tissue damage.

## Muscle-bone paracrine interactions in bone repair

Only within the past two decades has the muscle secretome been identified and explored. With the recent advent of improved characterization instruments, the muscle secretome has rapidly expanded to over 200 proteins<sup>54</sup>. Muscle secreted proteins important in muscle-bone interactions include, but are not limited to: myostatin, BMPs, secreted protein acidic and rich in cysteine (SPARC or osteonectin), interleukin (IL)-1, IL-4, IL-6, tumor necrosis factor (TNF) $\alpha$ , and insulin-like growth factor (IGF)-1<sup>41,54-56</sup>. Many of the muscle derived factors have previously been described to play a role in muscle-bone interactions without addressing the interactions specifically during fracture repair. Importantly, the presence of inflammation differentiates fracture repair from bone formation during development. That is, fracture healing is initiated by an inflammatory cascade, which is mediated by a number of factors, including but not limited to: neutrophils, macrophages, lymphocytes, and various inflammatory cytokines (i.e., IL-1, IL-6, TNF $\alpha$ )<sup>2,57-59</sup>. Mounting and maintaining an appropriate inflammatory response in early fracture healing is critical for adequate repair and multiple studies have demonstrated that interference with the inflammatory process can either impair<sup>60,61</sup> or improve<sup>62</sup> fracture healing. This review focuses primarily on four factors known to be involved in muscular injury and fracture repair and are therefore likely to contribute to muscle-bone interactions in the presence of inflammation.

### *Insulin-like growth factor-1*

IGF-1 is recognized as a key myokine that may direct local fracture healing<sup>63</sup>. IGF-1 is expressed by maturing osteoblasts in culture<sup>64</sup> and expression has been localized using *in situ* hybridization to osteoblasts during phases of matrix formation and remodeling in fractured human bone<sup>65</sup>. Further signifying the importance of IGF-1 to fracture healing, delivery of IGF-1 to ovine bone defects promotes accelerated bone formation<sup>66,67</sup>. The association of low systemic levels of IGF-1 with osteoporosis<sup>68,69</sup> suggests that local production of IGF-1 by nearby skeletal muscle tissue may support bone healing. Given that skeletal muscle up-regulates expression of IGF-1 in response to injury<sup>70-72</sup>, the context of fractures involving muscle trauma specifically highlight this possibility. Overexpression of IGF-1 in skeletal muscle can result in increased systemic concentrations evidencing the capacity of skeletal muscle as a paracrine organ to support nearby bone healing<sup>73</sup>. IGF-1 plays a role in muscle fiber repair and regenerative processes via a number of mechanisms to include increasing protein synthesis via PI3-AKT-mTOR pathway and by activating and promoting proliferation of satellite cells<sup>74,75</sup>. Perhaps most interesting in the context of complex musculoskeletal injury is the anti-inflammatory (i.e., inhibition of NF- $\kappa$ B) role of IGF-1 in muscle<sup>76,77</sup> and bone<sup>67</sup>.

### *Myostatin*

Perhaps the most well-known muscle derived protein, myostatin, has been implicated to play a significant, albeit inhibitory, role in fracture repair. Myostatin is a member of the TGF- $\beta$  superfamily, negatively regulating muscle growth, development, and regeneration<sup>78,79</sup>. Its negative trophic influence has been supported in myostatin null mice that demonstrate increased bone strength and increased bone mineral density<sup>80-82</sup>. Furthermore, myostatin inhibition by decoy receptors increases musculoskeletal mass<sup>83</sup>. Interestingly however, expression of myostatin is elevated with significant musculoskeletal injury, specifically in the early part of bone repair<sup>84,85</sup>. Due to its negative role in musculoskeletal development, interventions were targeted toward inhibiting myostatin after skeletal injury. Small molecule inhibition of myostatin following orthopaedic trauma has been demonstrated to improve muscle regeneration and fracture healing<sup>79,85,86</sup>. These data suggest that inhibition of myostatin may be a plausible intervention to improve fracture healing outcomes in patients with significant musculoskeletal injuries. However, the conundrum of elevated myostatin after musculoskeletal injury remains poorly understood.

### *Bone morphogenetic proteins*

Generally speaking, BMPs are growth factors for various skeletal tissues and are required for skeletal development. Conditional knockout mice deficient in BMPs displayed a wide range of skeletal defects<sup>87,88</sup>. There are 7 members of the BMP family, of which BMPs 2-7 belong to the TGF $\beta$  superfamily<sup>89</sup>. Multiple BMPs have been demonstrated to promote osteoblastic differentiation of bone marrow stromal cells<sup>90,91</sup>. Specifically, BMP-2 and BMP-7 are FDA approved for use in clinical musculoskeletal therapeutics due to their role in osteoblast differentiation and musculoskeletal repair. Unfortunately, concerns have arisen regarding the multiple side effects and off-label usage of BMPs including a recent link to oncogenic side effects with use of BMP-2<sup>92,93</sup>. More novel approaches to utilization of BMP-2 in fracture healing includes modified muscle cells that secrete BMP-2. Critical size rat femoral defects underwent quicker bridging and restored mechanical strength when receiving activated muscle secreted BMP-2<sup>38</sup>. Though not a member of the TGF $\beta$  superfamily and not used in the clinical setting currently, BMP-1 is secreted by muscle and may play a role in fracture healing. BMP-1, specifically, is a protease secreted by muscle that cleaves procollagen<sup>94</sup>. In patients with traumatic blast injuries, both BMP-1 protein and mRNA levels were elevated<sup>95</sup>, suggesting a significant role for BMP-1 in musculoskeletal repair. Therefore, better understanding of the roles of muscle derived BMPs in skeletal tissue regeneration is warranted to improve musculoskeletal repair in patients who suffer extensive traumatic injuries.

### *SPARC or osteonectin*

Osteonectin is a phosphorylated glycoprotein present in developing bone in many animal species<sup>96</sup>. Osteonectin is suggested to serve multiple functions in the developing bone

matrix, including collagen organization, osteoblast growth and proliferation, and matrix mineralization<sup>97</sup>. Mice deficient in osteonectin display osteopenia and decreased bone mineral content<sup>98</sup>. Importantly, osteonectin is secreted by injured and regenerating myotubes and muscle fibers<sup>99</sup>. Osteonectin expression by these sources is dependent on injury severity, suggesting that more severe musculoskeletal injuries result in greater osteonectin expression<sup>99</sup>. Longitudinal studies of fracture healing show detectable osteonectin transcripts throughout the healing phase<sup>100,101</sup>, most notably from days 9 to 15<sup>102</sup>. These studies provide evidence for the significant role osteonectin plays in bone regeneration and suggest muscle may be a source of osteonectin during musculoskeletal repair.

## Mechanical muscle-bone interactions

It would be remiss to forego some discussion of the mechanical influences involved in muscle bone interactions. The cellular mechanisms by which mechanical strain affects bone are largely uncharacterized, but some data suggest it is due in part to gap junctions in bone formed by connexin43<sup>103,104</sup>. Though characterization of mechanically induced cellular mechanisms remains limited, multiple studies have pointed to the importance of muscle's mechanical interactions on bone health<sup>105</sup>. Disuse atrophy via denervation or immobilization has been shown to decrease bone integrity in animal models<sup>106-108</sup>. Furthermore, multiple studies have demonstrated that muscle paralysis induced by administration of botulinum toxin impairs bone quality and/or fracture healing<sup>109-113</sup>. Further research into the cellular mechanisms of the mechanical influence of muscle is warranted to better understand how bone can be further modified by muscle during the healing process.

## Muscle in fracture healing - current models

### *Murine*

Multiple murine studies have been conducted to examine the extent to which muscle enhances bone repair after significant musculoskeletal injury. Zacks and Sheff<sup>114</sup> conducted early sentinel research addressing the potential for muscle to contribute to bone regeneration in 1982. Zacks and Sheff utilized experimental groups where after limb muscle resection, isotopic or heterotopic minced muscle implants were placed immediately adjacent to the periosteum. Their control groups consisted of liver minced implant or no implant. They concluded that isotopic and heterotopic minced muscle preparations implanted adjacent to the periosteum could directly induce new bone formation *in situ* as demonstrated by the formation of exostoses and metaplastic nodules in the minced muscle implants<sup>114</sup>. The work of Zacks and Sheff confirmed the importance of studying the trophic influence of muscle on bone.

As previously mentioned, Harry et al. conducted a murine study addressing the importance of muscle in open tibial fracture repair<sup>27</sup>. The authors demonstrated that musculocutaneous flaps performed superior to the fasciocutaneous flaps, though the fasciocutaneous flaps provided more angiogenic capacity. There-

fore, the osteogenic capability of muscle is greater than that of cutaneous flaps and extends beyond simply angiogenesis.

### *Rattus*

Multiple studies have also been conducted utilizing rat models to assess bone healing in light of soft tissue injuries. A study by Hao et al.<sup>109</sup> evaluated the effect of muscle atrophy and paralysis on femoral fracture healing. Atrophy of the quadriceps muscle, induced by administration of botulinum A toxin, negatively impacted the healing capacity of femoral fractures in rats. Utvag et al. conducted three critical studies<sup>115-117</sup> assessing the role of periosteum or surrounding soft tissue in bone healing. In 1998 Utvag et al.<sup>115</sup> demonstrated that fracture healing was impaired when periosteal tissue was mechanically removed from interacting with surrounding muscle. Additionally, Utvag et al. showed that significant muscle injury and absence of muscle by resection, or by traumatic injury in the clinical setting, significantly compromised the regeneration potential of non-augmented healing bone<sup>116,117</sup>. The importance of muscle for bone healing was further confirmed by the work of Willett et al. that demonstrated that volumetric muscle loss (VML) also impairs the effectiveness of BMP-2 in the healing of a critical size bone defect<sup>118</sup>. Taken together, it is clear that frank loss of muscle tissue (VML) is a significant comorbidity to poor bone healing outcomes.

### *Humans*

Since the mid 1970s, open fractures have been graded clinically according to the Gustilo-Anderson classification scale<sup>1,119</sup>, which is largely based on the severity of soft tissue injury associated with open fractures. Gustilo and Anderson identified 3 types of fractures: Type I - open fracture with a wound <1 cm and clean; Type 2 - open fracture with a wound >1 cm without extensive soft tissue damage; and Type 3 - open fracture with extensive soft tissue damage<sup>119</sup>. Type 3 fractures were later subdivided into 3 subcategories<sup>1</sup>. The Gustilo Anderson classification makes it evident that soft tissue injury plays a significant role in the musculoskeletal repair process in the clinical setting. Specifically, open fractures (Type 3) with extensive soft tissue injury demonstrate greater complication rates than open fractures without soft tissue injury (Types 2 & 3)<sup>120,121</sup>.

Similar to the results observed from animal studies, substantial clinical data exist characterizing the importance of muscle integrity in bone repair. A multitude of studies have demonstrated soft tissue damage associated with fractures impairs the ability of bone to repair properly<sup>122,123</sup>, while the quality of the muscle bed is essential for appropriate bone formation and bone healing<sup>30,51</sup>.

Similar to the murine study conducted by Harry et al.<sup>27</sup>, Gopal et al.<sup>124</sup> specifically examined the treatment of open tibial fractures with fasciocutaneous flaps versus muscle flaps in humans. The results of their study were then later confirmed by Harry et al. in the mouse model, with both groups concluding that muscle flaps are superior in bone healing. Even in clinical



practice, the gold standard of treating critical size defects or extensive fractures includes soft tissue coverage, supporting the significance of muscle-bone interactions during bone healing.

A more recent meta-analysis by Reverte et al.<sup>125</sup> analyzed 16 studies addressing the union rate and time to fracture union in patients with tibial fractures and associated compartment syndromes. Reverte et al. demonstrated that tibial fractures with associated soft tissue injury significantly impaired fracture healing. The rate of delayed union or non-union in tibial fractures with associated compartment syndrome was 55% compared to only 18% in patients with tibial fracture without associated compartment syndrome<sup>125</sup>. This study points to the importance of soft tissue integrity in the quality of fracture healing.

## Conclusion

Taken together, these studies illustrate the importance of muscle-bone interactions in bone regeneration. Exact mechanisms by which muscle is responsible for bone formation in the healing process are not well elucidated. Most of the current literature is limited to qualitative findings of muscle's role in bone healing. Therefore, more rigorous models with aims directed toward identification and quantification of muscle-derived effectors of bone regeneration are required. Identifying and characterizing the muscle-derived factors responsible for bone healing may provide opportunities to develop therapies to augment normal physiologic mechanisms underlying bone regeneration.

Current strategies, such as the use of BMPs, in fracture healing have recently been thought of as having more limited benefit due to the more robust understanding of detrimental side effects. This review outlines some potential targets for therapeutic development, including stimulation of MDSCs, inhibition of myostatin, or administering or enhancing the targeted expression of osteonectin. Future studies addressing muscle factors associated with bone healing may provide insight into these mechanisms necessary to promote bone regeneration. Soft tissue integrity is crucial to appropriate bone regeneration, but our understanding of the mechanisms is limited at the present time. A better understanding of muscle's effect on fracture healing at the cellular and molecular levels will open translational opportunities to incorporate the findings into clinics and operating rooms abroad.

## Acknowledgements

*This work was supported by the Medical Student Affairs Summer Research Program in Academic Medicine, Indiana University School of Medicine funded in part by NIH grant HL110854 (KMD) and the Department of Orthopaedic Surgery, Indiana University School of Medicine (MAK, TOM). In addition, research reported in this publication was supported in part by the following grants: NIH NIAMS R01 AR060863 (MAK), USAMRMC OR120080 (MAK, T-MGC), an Indiana University Health Values Grant (MAK), an Indiana Clinical and Translational Sciences Institute Grant partially supported by NIH UL1TR001108 (MAK, T-MGC), and an Indiana University Collaborative Research Grant (MAK, T-MGC). The content of this manuscript is solely the responsibility of the authors and does not necessarily represent the official views of the NIH.*

*The opinions or assertions contained herein are the private views of the authors and are not to be construed as official or as reflecting the views of the Department of the Army or the Department of Defense.*

## References

1. Gustilo RB, Mendoza RM, Williams DN. Problems in the management of type III (severe) open fractures: a new classification of type III open fractures. *J Trauma* 1984;24:742-6.
2. Marsell R, Einhorn TA. The biology of fracture healing. *Injury* 2011;42:551-5.
3. Gerstenfeld LC, Cullinane DM, Barnes GL, Graves DT, Einhorn TA. Fracture healing as a post-natal developmental process: molecular, spatial, and temporal aspects of its regulation. *J Cell Biochem* 2003;88:873-84.
4. Gerstenfeld LC, Alkhiary YM, Krall EA, et al. Three-dimensional reconstruction of fracture callus morphogenesis. *J Histochem Cytochem* 2006;54:1215-28.
5. Claes L, Recknagel S, Ignatius A. Fracture healing under healthy and inflammatory conditions. *Nat Rev Rheumatol* 2012;8:133-43.
6. Schipani E, Maes C, Carmeliet G, Semenza GL. Regulation of osteogenesis-angiogenesis coupling by HIFs and VEGF. *J Bone Miner Res* 2009;24:1347-53.
7. Glowacki J. Angiogenesis in fracture repair. *Clin Orthop Relat Res* 1998:S82-9.
8. Zelzer E, Olsen BR. Multiple roles of vascular endothelial growth factor (VEGF) in skeletal development, growth, and repair. *Curr Top Dev Biol* 2005;65:169-87.
9. Kristensen HB, Andersen TL, Marcussen N, Rolighed L, Delaisse JM. Increased presence of capillaries next to remodeling sites in adult human cancellous bone. *J Bone Miner Res* 2013;28:574-85.
10. Colnot C, Zhang X, Knothe Tate ML. Current insights on the regenerative potential of the periosteum: molecular, cellular, and endogenous engineering approaches. *J Orthop Res* 2012;30:1869-78.
11. Zuscik MJ, Hilton MJ, Zhang X, Chen D, O'Keefe RJ. Regulation of chondrogenesis and chondrocyte differentiation by stress. *J Clin Invest* 2008;118:429-38.
12. Rhinelander FW. Tibial blood supply in relation to fracture healing. *Clin Orthop Relat Res* 1974;34-81.
13. Laroche M. Intraosseous circulation from physiology to disease. *Joint Bone Spine* 2002;69:262-9.
14. Brighton CT, Lorch DG, Kupcha R, Reilly TM, Jones AR, Woodbury RA, 2nd. The pericyte as a possible osteoblast progenitor cell. *Clin Orthop Relat Res* 1992:287-99.
15. Diaz-Flores L, Gutierrez R, Lopez-Alonso A, Gonzalez R, Varela H. Pericytes as a supplementary source of osteoblasts in periosteal osteogenesis. *Clin Orthop Relat Res* 1992;(275):280-6.
16. Mills SJ, Cowin AJ, Kaur P. Pericytes, mesenchymal stem cells and the wound healing process. *Cells* 2013;2:621-34.
17. Kumar A, Salimath BP, Stark GB, Finkenzeller G.

- Platelet-derived growth factor receptor signaling is not involved in osteogenic differentiation of human mesenchymal stem cells. *Tissue Eng Part A* 2010;16:983-93.
18. Lu C, Miclau T, Hu D, Marcucio RS. Ischemia leads to delayed union during fracture healing: a mouse model. *J Orthop Res* 2007;25:51-61.
19. Green N, French S, Rodriguez G, Hays M, Fingerhut A. Radiation-induced delayed union of fractures. *Radiology* 1969;93:635-41.
20. Liu R, Schindeler A, Little DG. The potential role of muscle in bone repair. *J Musculoskelet Neuronal Interact* 2010;10:71-6.
21. Richards RR, Schemitsch EH. Effect of muscle flap coverage on bone blood flow following devascularization of a segment of tibia: an experimental investigation in the dog. *J Orthop Res* 1989;7:550-8.
22. Richards RR, McKee MD, Paitich CB, Anderson GI, Bertoia JT. A comparison of the effects of skin coverage and muscle flap coverage on the early strength of union at the site of osteotomy after devascularization of a segment of canine tibia. *J Bone Joint Surg Am* 1991;73:1323-30.
23. Richards RR, Orsini EC, Mahoney JL, Verschuren R. The influence of muscle flap coverage on the repair of devascularized tibial cortex: an experimental investigation in the dog. *Plast Reconstr Surg* 1987;79:946-58.
24. Choi P, Ogilvie C, Thompson Z, Miclau T, Helms JA. Cellular and molecular characterization of a murine non-union model. *J Orthop Res* 2004;22:1100-7.
25. Brownlow HC, Reed A, Simpson AH. The vascularity of atrophic non-unions. *Injury* 2002;33:145-50.
26. Reed AA, Joyner CJ, Brownlow HC, Simpson AH. Human atrophic fracture non-unions are not avascular. *J Orthop Res* 2002;20:593-9.
27. Harry LE, Sandison A, Paleolog EM, Hansen U, Pearse MF, Nanchahal J. Comparison of the healing of open tibial fractures covered with either muscle or fasciocutaneous tissue in a murine model. *J Orthop Res* 2008;26:1238-44.
28. Urist MR. Bone: formation by autoinduction. *Science* 1965;150:893-9.
29. Chan JK, Harry L, Williams G, Nanchahal J. Soft-tissue reconstruction of open fractures of the lower limb: muscle versus fasciocutaneous flaps. *Plast Reconstr Surg* 2012;130:284e-95e.
30. Stein H, Perren SM, Cordey J, Kenwright J, Mosheiff R, Francis MJ. The muscle bed—a crucial factor for fracture healing: a physiological concept. *Orthopedics* 2002;25:1379-83.
31. Davis TA, Lazdun Y, Potter BK, Forsberg JA. Ectopic bone formation in severely combat-injured orthopedic patients - a hematopoietic niche. *Bone* 2013;56:119-26.
32. DeLee J, Ferrari A, Charnley J. Ectopic bone formation following low friction arthroplasty of the hip. *Clin Orthop Relat Res* 1976;(121):53-9.
33. Kaplan FS, Lounev VY, Wang H, Pignolo RJ, Shore EM. Fibrodysplasia ossificans progressiva: a blueprint for metamorphosis. *Ann N Y Acad Sci* 2011;1237:5-10.
34. Kato S, Sangadala S, Tomita K, Titus L, Boden SD. A synthetic compound that potentiates bone morphogenetic protein-2-induced transdifferentiation of myoblasts into the osteoblastic phenotype. *Mol Cell Biochem* 2011;349:97-106.
35. Wong E, Sangadala S, Boden SD, et al. A novel low-molecular-weight compound enhances ectopic bone formation and fracture repair. *J Bone Joint Surg Am* 2013;95:454-61.
36. Cairns DM, Liu R, Sen M, et al. Interplay of Nkx3.2, Sox9 and Pax3 regulates chondrogenic differentiation of muscle progenitor cells. *PLoS One* 2012;7:e39642.
37. Lee JY, Qu-Petersen Z, Cao B, et al. Clonal isolation of muscle-derived cells capable of enhancing muscle regeneration and bone healing. *J Cell Biol* 2000;150:1085-100.
38. Evans CH, Liu FJ, Glatt V, et al. Use of genetically modified muscle and fat grafts to repair defects in bone and cartilage. *Eur Cell Mater* 2009;18:96-111.
39. Gao X, Usas A, Tang Y, et al. A comparison of bone regeneration with human mesenchymal stem cells and muscle-derived stem cells and the critical role of BMP. *Biomaterials* 2014;35:6859-70.
40. Sondag GR, Salihoglu S, Lababidi SL, et al. Osteoactivin induces transdifferentiation of C2C12 myoblasts into osteoblasts. *J Cell Physiol* 2014;229:955-66.
41. Glass GE, Chan JK, Freidin A, Feldmann M, Horwood NJ, Nanchahal J. TNF-alpha promotes fracture repair by augmenting the recruitment and differentiation of muscle-derived stromal cells. *Proc Natl Acad Sci U S A* 2011;108:1585-90.
42. Jankowski RJ, Deasy BM, Huard J. Muscle-derived stem cells. *Gene Ther* 2002;9:642-7.
43. Asakura A, Komaki M, Rudnicki M. Muscle satellite cells are multipotential stem cells that exhibit myogenic, osteogenic, and adipogenic differentiation. *Differentiation* 2001;68:245-53.
44. Huang S, Jia S, Liu G, Fang D, Zhang D. Osteogenic differentiation of muscle satellite cells induced by platelet-rich plasma encapsulated in three-dimensional alginate scaffold. *Oral Surg Oral Med Oral Pathol Oral Radiol* 2012;114:S32-40.
45. Wu X, Rathbone CR. Satellite cell functional alterations following cutaneous burn in rats include an increase in their osteogenic potential. *J Surg Res* 2013;184:e9-16.
46. Hashimoto N, Kiyono T, Wada MR, et al. Osteogenic properties of human myogenic progenitor cells. *Mech Dev* 2008;125:257-69.
47. Malizos KN, Papatheodorou LK. The healing potential of the periosteum molecular aspects. *Injury* 2005;36 Suppl 3:S13-9.
48. Dwek JR. The periosteum: what is it, where is it, and what mimics it in its absence? *Skeletal Radiol* 2010;39:319-23.
49. Zhang X, Xie C, Lin AS, et al. Periosteal progenitor cell fate in segmental cortical bone graft transplantations: im-

- plications for functional tissue engineering. *J Bone Miner Res* 2005;20:2124-37.
50. Hutmacher DW, Sittertinger M. Periosteal cells in bone tissue engineering. *Tissue Eng* 2003;9 Suppl 1:S45-64.
  51. Liu R, Birke O, Morse A, et al. Myogenic progenitors contribute to open but not closed fracture repair. *BMC Musculoskelet Disord* 2011;12:288.
  52. Kaufman H, Reznick A, Stein H, Barak M, Maor G. The biological basis of the bone-muscle inter-relationship in the algorithm of fracture healing. *Orthopedics* 2008;31:751.
  53. Utvag SE, Grundnes O, Reikeras O. Early muscle-periosteal lesion inhibits fracture healing in rats. *Acta Orthop Scand* 1999;70:62-6.
  54. Bortoluzzi S, Scannapieco P, Cestaro A, Danieli GA, Schiaffino S. Computational reconstruction of the human skeletal muscle secretome. *Proteins* 2006;62:776-92.
  55. Norheim F, Raastad T, Thiede B, Rustan AC, Drevon CA, Haugen F. Proteomic identification of secreted proteins from human skeletal muscle cells and expression in response to strength training. *Am J Physiol Endocrinol Metab* 2011;301:E1013-21.
  56. Seale P, Bjork B, Yang W, et al. PRDM16 controls a brown fat/skeletal muscle switch. *Nature* 2008;454:961-7.
  57. Kon T, Cho TJ, Aizawa T, et al. Expression of osteoprotegerin, receptor activator of NF-kappaB ligand (osteoprotegerin ligand) and related proinflammatory cytokines during fracture healing. *J Bone Miner Res* 2001;16:1004-14.
  58. Ai-Aql ZS, Alagil AS, Graves DT, Gerstenfeld LC, Einhorn TA. Molecular mechanisms controlling bone formation during fracture healing and distraction osteogenesis. *J Dent Res* 2008;87:107-18.
  59. Mountziaris PM, Mikos AG. Modulation of the inflammatory response for enhanced bone tissue regeneration. *Tissue Eng Part B Rev* 2008;14:179-86.
  60. Park S, Silva M, Bahk W, McKellop H, Lieberman J. Effect of repeated irrigation and debridement on fracture healing in an animal model. *J Orthop Res* 2002;20:1197-204.
  61. Grundnes O, Reikeras O. The importance of the hematoma for fracture healing in rats. *Acta Orthop Scand* 1993;64:340-2.
  62. Glass GE, Chan JK, Freidin A, Feldmann M, Horwood NJ, Nanchahal J. TNF- $\alpha$  promotes fracture repair by augmenting the recruitment and differentiation of muscle-derived stromal cells. *Proceedings of the National Academy of Sciences* 2011;108:1585-90.
  63. Hamrick MW. A role for myokines in muscle-bone interactions. *Exerc Sport Sci Rev* 2011;39:43-7.
  64. Kalajic I, Staal A, Yang WP, et al. Expression profile of osteoblast lineage at defined stages of differentiation. *J Biol Chem* 2005;280:24618-26.
  65. Andrew JG, Hoyland J, Freemont AJ, Marsh D. Insulin-like growth factor gene expression in human fracture callus. *Calcif Tissue Int* 1993;53:97-102.
  66. Luginbuehl V, Zoidis E, Meinel L, von Rechenberg B, Gander B, Merkle HP. Impact of IGF-I release kinetics on bone healing: a preliminary study in sheep. *Eur J Pharm Biopharm* 2013;85:99-106.
  67. Meinel L, Zoidis E, Zapf J, et al. Localized insulin-like growth factor I delivery to enhance new bone formation. *Bone* 2003;33:660-72.
  68. Ljunghall S, Johansson AG, Burman P, Kampe O, Lindh E, Karlsson FA. Low plasma levels of insulin-like growth factor 1 (IGF-1) in male patients with idiopathic osteoporosis. *J Intern Med* 1992;232:59-64.
  69. Liu JM, Zhao HY, Ning G, et al. IGF-1 as an early marker for low bone mass or osteoporosis in premenopausal and postmenopausal women. *J Bone Miner Metab* 2008;26:159-64.
  70. Hill M, Goldspink G. Expression and splicing of the insulin-like growth factor gene in rodent muscle is associated with muscle satellite (stem) cell activation following local tissue damage. *J Physiol* 2003;549:409-18.
  71. Marsh DR, Criswell DS, Hamilton MT, Booth FW. Association of insulin-like growth factor mRNA expressions with muscle regeneration in young, adult, and old rats. *Am J Physiol* 1997;273:R353-8.
  72. Hammers DW, Merritt EK, Matheny RW, Jr., et al. Functional deficits and insulin-like growth factor-I gene expression following tourniquet-induced injury of skeletal muscle in young and old rats. *J Appl Physiol* (1985) 2008;105:1274-81.
  73. Shavlakadze T, Winn N, Rosenthal N, Grounds MD. Reconciling data from transgenic mice that overexpress IGF-I specifically in skeletal muscle. *Growth Horm IGF Res* 2005;15:4-18.
  74. Machida S, Booth FW. Insulin-like growth factor 1 and muscle growth: implication for satellite cell proliferation. *Proc Nutr Soc* 2004;63:337-40.
  75. Han B, Tong J, Zhu MJ, Ma C, Du M. Insulin-like growth factor-1 (IGF-1) and leucine activate pig myogenic satellite cells through mammalian target of rapamycin (mTOR) pathway. *Mol Reprod Dev* 2008;75:810-7.
  76. Mourkioti F, Rosenthal N. IGF-1, inflammation and stem cells: interactions during muscle regeneration. *Trends Immunol* 2005;26:535-42.
  77. Lee WJ. IGF-I Exerts an Anti-inflammatory Effect on Skeletal Muscle Cells through Down-regulation of TLR4 Signaling. *Immune Netw* 2011;11:223-6.
  78. Elkasrawy M, Fulzele S, Bowser M, Wenger K, Hamrick M. Myostatin (GDF-8) inhibits chondrogenesis and chondrocyte proliferation *in vitro* by suppressing Sox-9 expression. *Growth Factors* 2011;29:253-62.
  79. Hamrick MW, Arounleut P, Kellum E, Cain M, Immel D, Liang LF. Recombinant myostatin (GDF-8) propeptide enhances the repair and regeneration of both muscle and bone in a model of deep penetrant musculoskeletal injury. *J Trauma* 2010;69:579-83.
  80. Hamrick MW, McPherron AC, Lovejoy CO, Hudson J. Femoral morphology and cross-sectional geometry of adult myostatin-deficient mice. *Bone* 2000;27:343-9.
  81. Hamrick MW, McPherron AC, Lovejoy CO. Bone min-




- eral content and density in the humerus of adult myostatin-deficient mice. *Calcif Tissue Int* 2002;71:63-8.
82. Hamrick MW. Increased bone mineral density in the femora of GDF8 knockout mice. *Anat Rec A Discov Mol Cell Evol Biol* 2003;272:388-91.
83. Bialek P, Parkington J, Li X, et al. A myostatin and activin decoy receptor enhances bone formation in mice. *Bone* 2014;60:162-71.
84. Elkasrawy M, Immel D, Wen X, Liu X, Liang LF, Hamrick MW. Immunolocalization of myostatin (GDF-8) following musculoskeletal injury and the effects of exogenous myostatin on muscle and bone healing. *J Histochem Cytochem* 2012;60:22-30.
85. Elkasrawy MN, Hamrick MW. Myostatin (GDF-8) as a key factor linking muscle mass and bone structure. *J Musculoskelet Neuronal Interact* 2010;10:56-63.
86. Kellum E, Starr H, Arounleut P, et al. Myostatin (GDF-8) deficiency increases fracture callus size, Sox-5 expression, and callus bone volume. *Bone* 2009;44:17-23.
87. Gazzerro E, Canalis E. Bone morphogenetic proteins and their antagonists. *Rev Endocr Metab Disord* 2006;7:51-65.
88. Chen D, Zhao M, Mundy GR. Bone morphogenetic proteins. *Growth Factors* 2004;22:233-41.
89. Wozney JM. Bone Morphogenetic Proteins. *Progress in Growth Factor Research* 1989;1:267-80.
90. Yamaguchi A, Ishizuya T, Kintou N, et al. Effects of BMP-2, BMP-4, and BMP-6 on osteoblastic differentiation of bone marrow-derived stromal cell lines, ST2 and MC3T3-G2/PA6. *Biochem Biophys Res Commun* 1996;220:366-71.
91. Lavery K, Swain P, Falb D, Alaoui-Ismaili MH. BMP-2/4 and BMP-6/7 differentially utilize cell surface receptors to induce osteoblastic differentiation of human bone marrow-derived mesenchymal stem cells. *J Biol Chem* 2008;283:20948-58.
92. Carragee EJ, Hurwitz EL, Weiner BK. A critical review of recombinant human bone morphogenetic protein-2 trials in spinal surgery: emerging safety concerns and lessons learned. *Spine J* 2011;11:471-91.
93. Carragee EJ, Chu G, Rohatgi R, et al. Cancer Risk After Use of Recombinant Bone Morphogenetic Protein-2 for Spinal Arthrodesis. *J Bone Joint Surg Am* 2013;95:1537-45.
94. Kessler E, Takahara K, Biniaminov L, Brusel M, Greenspan DS. Bone morphogenetic protein-1: the type I procollagen C-proteinase. *Science* 1996;271:360-2.
95. Jackson WM, Aragon AB, Onodera J, et al. Cytokine expression in muscle following traumatic injury. *J Orthop Res* 2011;29:1613-20.
96. Villarreal XC, Mann KG, Long GL. Structure of human osteonectin based upon analysis of cDNA and genomic sequences. *Biochemistry* 1989;28:6483-91.
97. Brekken RA, Sage EH. SPARC, a matricellular protein: at the crossroads of cell-matrix communication. *Matrix Biol* 2001;19:816-27.
98. Delany AM, Amling M, Priemel M, Howe C, Baron R, Canalis E. Osteopenia and decreased bone formation in osteonectin-deficient mice. *J Clin Invest* 2000;105:1325.
99. Jorgensen LH, Petersson SJ, Sellathurai J, et al. Secreted protein acidic and rich in cysteine (SPARC) in human skeletal muscle. *J Histochem Cytochem* 2009;57:29-39.
100. Yamazaki M, Majeska R, Moriya J. Role of osteonectin during fracture healing. *Trans Orthop Res Soc* 1997;22:254.
101. Hiltunen A, Metsaranta M, Virolainen P, Aro HT, Vuorio E. Retarded chondrogenesis in transgenic mice with a type II collagen defect results in fracture healing abnormalities. *Dev Dyn* 1994;200:340-9.
102. Jingushi S, Joyce ME, Bolander ME. Genetic expression of extracellular matrix proteins correlates with histologic changes during fracture repair. *J Bone Miner Res* 1992;7:1045-55.
103. Grimston SK, Goldberg DB, Watkins M, Brodt MD, Silva MJ, Civitelli R. Connexin43 deficiency reduces the sensitivity of cortical bone to the effects of muscle paralysis. *J Bone Miner Res* 2011;26:2151-60.
104. Grimston SK, Brodt MD, Silva MJ, Civitelli R. Attenuated response to *in vivo* mechanical loading in mice with conditional osteoblast ablation of the connexin43 gene (*Gja1*). *J Bone Miner Res* 2008;23:879-86.
105. Gross TS, Poliachik SL, Prasad J, Bain SD. The effect of muscle dysfunction on bone mass and morphology. *J Musculoskelet Neuronal Interact* 2010;10:25-34.
106. Ijiri K, Ma YF, Jee WS, Akamine T, Liang X. Adaptation of non-growing former epiphysis and metaphyseal trabecular bones to aging and immobilization in rat. *Bone* 1995;17:207S-12S.
107. Tuukkanen J, Wallmark B, Jalovaara P, Takala T, Sjogren S, Vaananen K. Changes induced in growing rat bone by immobilization and remobilization. *Bone* 1991;12:113-8.
108. Liu D, Zhao CQ, Li H, Jiang SD, Jiang LS, Dai LY. Effects of spinal cord injury and hindlimb immobilization on sublesional and suprallesional bones in young growing rats. *Bone* 2008;43:119-25.
109. Hao Y, Ma Y, Wang X, Jin F, Ge S. Short-term muscle atrophy caused by botulinum toxin-A local injection impairs fracture healing in the rat femur. *J Orthop Res* 2012;30:574-80.
110. Poliachik SL, Bain SD, Threet D, Huber P, Gross TS. Transient muscle paralysis disrupts bone homeostasis by rapid degradation of bone morphology. *Bone* 2010;46:18-23.
111. Thomsen JS, Christensen LL, Vegger JB, Nyengaard JR, Bruel A. Loss of bone strength is dependent on skeletal site in disuse osteoporosis in rats. *Calcif Tissue Int* 2012;90:294-306.
112. Ellman R, Grasso DJ, van Vliet M, et al. Combined effects of botulinum toxin injection and hind limb unloading on bone and muscle. *Calcif Tissue Int* 2014;94:327-37.
113. Aliprantis AO, Stolina M, Kostenuik PJ, et al. Transient muscle paralysis degrades bone via rapid osteoclastogenesis. *FASEB J* 2012;26:1110-8.
114. Zachs SI, Sheff MF. Periosteal and metaplastic bone for-

- mation in mouse minced muscle regeneration. *Lab Invest* 1982;46:405-12.
115. Utvag SE, Grundnes O, Reikeras O. Effects of lesion between bone, periosteum and muscle on fracture healing in rats. *Acta Orthop Scand* 1998;69:177-80.
116. Utvag SE, Grundnes O, Rindal DB, Reikeras O. Influence of extensive muscle injury on fracture healing in rat tibia. *J Orthop Trauma* 2003;17:430-5.
117. Utvag SE, Iversen KB, Grundnes O, Reikeras O. Poor muscle coverage delays fracture healing in rats. *Acta Orthop Scand* 2002;73:471-4.
118. Willett NJ, Mon-Tzu LA, Uhrig BA, et al. Attenuated human bone morphogenetic protein-2-mediated bone regeneration in a rat model of composite bone and muscle injury. *Tissue Eng Pt C-Meth* 2013;19:316-25.
119. Gustilo R, Anderson J. Prevention of infection in the treatment of one thousand and twenty-five open fractures of long bones: retrospective and prospective analyses. *J Bone Joint Surg Am* 1976;58:453-8.
120. Papakostidis C, Kanakaris NK, Pretel J, Faour O, Morell DJ, Giannoudis PV. Prevalence of complications of open tibial shaft fractures stratified as per the Gustilo–Anderson classification. *Injury* 2011;42:1408-15.
121. Giannoudis PV, Harwood PJ, Kontakis G, et al. Long-term quality of life in trauma patients following the full spectrum of tibial injury (fasciotomy, closed fracture, grade IIIB/IIIC open fracture and amputation). *Injury* 2009;40:213-9.
122. Landry PS, Marino AA, Sadasivan KK, Albright JA. Effect of soft-tissue trauma on the early periosteal response of bone to injury. *J Trauma* 2000;48:479-83.
123. Duda GN, Taylor WR, Winkler T, et al. Biomechanical, microvascular, and cellular factors promote muscle and bone regeneration. *Exerc Sport Sci Rev* 2008;36:64-70.
124. Gopal S, Majumder S, Batchelor AG, Knight SL, De Boer P, Smith RM. Fix and flap: the radical orthopaedic and plastic treatment of severe open fractures of the tibia. *J Bone Joint Surg Br* 2000;82:959-66.
125. Reverte MM, Dimitriou R, Kanakaris NK, Giannoudis PV. What is the effect of compartment syndrome and fasciotomies on fracture healing in tibial fractures? *Injury* 2011;42:1402-7.



# Surgical Fixation Hardware for Regeneration of Long Bone Segmental Defects: Translating Large Animal Model and Human Experiences

Emily Jewell<sup>1</sup> · Jeff Rytlewski<sup>1</sup> · Jeffrey O. Anglen<sup>1</sup> · Todd O. McKinley<sup>1</sup> · Karl D. Shively<sup>1</sup> · Tien-Min G. Chu<sup>2</sup> · Melissa A. Kacena<sup>1</sup> 

© Springer Science+Business Media New York 2015

**Abstract** Orthopedic fracture surgery has made significant advances in recent years, but large segmental bone defects remain a significant clinical problem. While surgical techniques have been developed or modified to address these issues, challenges remain. Further, to effectively address this issue, a suitable path from the benchtop to the clinic must be established. This is most commonly done using large animal models, which provide the opportunity to test different treatment options. This is certainly more complicated than it appears, as various anatomic and physiologic differences can produce complications not normally seen in humans. For this reason, proper species and bone selection is critically important. Here we review the current experimental methods, types of internal and external fixation, and large animal models used in segmental bone defect studies conducted in weight-bearing long bones. This review will also provide insight into the efficacy of hardware fixation strategies and the translatability of said strategies into clinical practice.

**Keywords** Pig · Sheep · Dog · Goat · Primate · Human · Bone regeneration · Segmental bone defects · Hardware · Fixation

## Introduction

Critical-sized defects in long bones have historically been defined as the minimal size defect that will not heal without intervention over the lifespan of the animal [1, 2]. This has recently been redefined as being at least 2.5 times the cortical diameter [3]. Critical-sized defects can be due to traumatic injuries, infections, and malignancy, and previous nonunions with subsequent bone resorption. No matter what the root cause, these critical-sized defects remain a major treatment hurdle for orthopedic surgeons today. This has created a need for research and development of techniques to aid in treatment. Bone defect research necessarily spans from molecular level experimentation through pre-clinical models. Translation is dependent on developing physiologically relevant large animal models for preclinical testing. Large animal models share geometric proportions, anatomic positions, and load-bearing patterns with human beings. In addition, proper large animal models also have bone biologic similarities to human bones with comparable mineral composition, turnover, and remodeling when compared to humans. This provides an environment to test new scaffolds and hormones that are very similar to human bone biology and mechanics without the difficulty of implementing a human trial.

Physiologic realism is dependent on optimal species and bone selection. Species including non-human primates, dogs, pigs, goats, and sheep are most similar to humans in regard to bone biology [4]. Weight bearing needs to be comparable; therefore, bone selection needs to be considered. For example, in four-legged animals, an argument could be made to consider the radius and ulna as weight-bearing bones. However, there may be stress shielding of the fractured bone by the intact one. This alteration in mechanical loading would alter the bone healing

✉ Melissa A. Kacena  
mkacena@iupui.edu

<sup>1</sup> Department of Orthopaedic Surgery, Indiana University School of Medicine, 1130 W. Michigan St., FH 115, Indianapolis, IN 46202, USA

<sup>2</sup> Department of Restorative Dentistry, Indiana University School of Dentistry, Indianapolis, IN, USA

environment and make it harder to translate to human application. Ultimately, bone selection typically mimics the human tibia, as the tibia is the most commonly fractured long bone as well as the most common site of segmental bone defects. This is because it has one of the harshest environments for healing. It lacks the same level of soft tissue coverage along its anteromedial aspect that other long bones have. The decreased level of vasculature probably plays a large role because vascularization plays a significant role in the healing process [5].

After the species and specific anatomic location for experimentation have been selected, the fixation method for stabilizing the critical-sized defect must be chosen. Similar to the surgery to stabilize defects in humans, multiple options are available for preclinical models and there has not been a standardization of surgical technique. All of this adds to complexity in understanding the relevance of preclinical models. This manuscript reviews the current literature using large animal models for the healing of critical-sized bone defects. It includes studies done using weight-bearing long bones in large animals, types of fixation used, and complications.

## Fixation Methods

There are many portions of animal model studies that have not been standardized. One is the method of fixation, so the following is a brief overview of the common methods that have been used in studies. One concern is that the different types of fixation that were not originally designed for animal use lead to significant discrepancies in bone loading in animal applications [6]. In many cases, human implants are being used in animals without any purposeful design for the application. There are various methods for fixing a long bone defect in humans. The most common include either external fixation or internal fixation. Internal fixation is then subdivided into two primary groups: use of a single plate or an intramedullary (IM) nail. There are many pros and cons to each method, and their use depends upon the specific circumstances.

## External Fixation

In humans the external fixator is often clinically used as a temporary fixation method. It is most commonly used in severe open or contaminated fractures where the compromise in soft tissue is significant. Once the soft tissue component resolves, the external fixator is often exchanged for internal fixation. The external fixator may also be the definitive fixation method as well. Animals can be viewed as the ultimate non-compliant patient, so it is a viable

method for final fixation [7]. The following method is an external fixation procedure as described by the AO (Arbeitsgemeinschaft für Osteosynthesefragen, a group established by orthopedic surgeons to study internal fixation and improve operative outcomes) Surgery Ref. [8]: prepare to apply external fixation by determining the safe locations for threaded pin insertion as well as the number of pins needed on either side of the critical-sized defect. The threaded pins will be placed through a small incision in the skin and then into the bone. Care must be taken to avoid surrounding nerves, vessels, and other soft tissues. Once the threaded pins are in place on both sides of the defect, clamps are applied to the pins. Bars are then attached between the clamps to stabilize the site.

**Pros:** The main positive of external fixation is the relative ease and speed with which an external fixator can be applied and removed. It does not require surgical dissection or require any periosteal stripping that would be needed for internal fixation [9]. If the surgeon has proper knowledge of the cross-sectional anatomy of the affected limb, then the risk of intraoperative complications is low. Due to minimal bone contact, it causes less damage to the bone's blood supply. Also, the external fixator does not interfere with the defect site or scaffold.

**Cons:** The most common complication is pin track loosening leading to pin track infection. It has also been found that external fixation requires longer healing periods and leads to more malalignment [10, 11]. Other drawbacks can be seen specifically with animal use. External fixators, with their propensity for infection, can be even more problematic in animal models because there will be increased difficulty in keeping them clean [12]. The animal may also try to pull the fixation device off/out, and the device itself may be large and cumbersome to the animal often resulting in a confounding variable when assessing gait and healing.

## Internal Fixation

Internal fixation is the mainstay of correcting large defects and unstable fracture patterns in humans. These fractures require a stable construct to limit motion at the fracture site and improve the overall likelihood of healing. There are many parameters that are important to consider when selecting a method of internal fixation. One critical detail is the location on the long bone of the defect. For example, if the fracture is through the diaphysis, then an IM nail is more commonly used, but if it is through the metaphysis of the same long bone, then a plate is more common [13, 14]. Other things that must be taken into consideration are how the fixation device affects the axis of loading, how stiff the construct is and how that affects motion at the fracture site,

and the extent of tissue dissection that is required to apply the fixation device.

### Single Plating

The following method is a single plating procedure as described by the AO Surgery Ref. [15]. The plate may either be inserted through an incision over the critically sized defect or through a minimally invasive approach. Most likely an incision will be required to create the critical-sized defect, so this may be used for plate insertion. Excess soft tissue is removed, so that the plate can be placed in an extraperiosteal position flush to the surface. The plate will bridge the critical-sized defect to maintain proper defect size. It will then be fixed in place with screws on both sides of the defect.

**Pros:** Plates have the advantage of being outside of the medullary canal. This allows the surgeon to directly visualize where the plate is being placed, and it is easier to modify its placement. Its extramedullary position also allows it to not interfere with the defect site, scaffold, or bone graft placement. The plate is not as limited by the difference in contour of the animal bone versus the bone for which it was originally designed. Plates can be contoured intraoperatively to allow for better apposition along the length of the bone [16]. It has also been found that, when compared to IM nails and external fixation, plates have a lower rate of infection, infection related complications, and non-unions [17].

**Cons:** It has been found that the eccentric placement of plates relative to the load-bearing axis requires that plates be stiffer to resist weight-bearing forces and properly stabilize the fracture. The difficulty is that excessive rigidity of fixation can prevent proper healing [18]. One reason is because it minimizes the micromotion at the fracture site, some of which is actually required for proper bone healing. It also causes stress shielding. The stiffness of the construct does not allow the bone to be under physiologic loading. This lack of stimulus for continued remodeling will result in osteopenic changes of the surrounding bone [19]. Another observation is that the high compressive forces between the plate, periosteum, and bone result in a compromised blood supply [20]. The impaired vascularity may prolong fracture healing, increase risk of infection, and increase re-fracture rate after implant removal due to increased cortical bone porosity along the bone plate interface [21, 22]. There are also more screws needed to secure the plate versus other constructs, and the weakness through the screw holes may compromise mechanical testing [23].

### Double Plating

The following method is a double plating procedure as described by the AO Surgery Ref. [24]. An incision is made to allow for plate insertion. Excess soft tissue is removed, so that the plate can be placed in an extraperiosteal position flush to the surface. The plate will bridge the critical-sized defect to maintain proper defect size. It will then be fixed in place with screws on both sides of the defect. A second plate is then placed, so that it is sitting ninety degrees from the first plate. This plate should also be placed flush to the surface in the extraperiosteal position. The second plate is then fixed in place with screws on both sides of the defect.

**Pros:** It has been found that there is a significant increase in stiffness of a double-plate construct when compared to a single plate when placed under torsional stress as well as four-point bending [25].

**Cons:** One of the plates must be radiolucent to allow for proper imaging. Radiolucent plates are much less common, and their ability to be properly contoured is not the same as normal plates [26]. It was also found that using two plates may lead to late onset healing and incomplete ossification due to load sharing [26]. Another thing to consider is that there will be twice the surface area being subjected to blood supply compression [12].

### Intramedullary Nail

The following method is an intramedullary nailing procedure as described by the AO Surgery Ref. [27]. There is an incision made at the level of the proximal tibia. If the surgeon prefers to ream the intramedullary canal, a guide wire is passed through both the proximal and distal segment of the bone. The intramedullary canal may then be reamed over the guide wire. The nail is then passed through the proximal segment of the bone, through the critical-sized defect, and into the distal segment of bone. The proximal and distal ends are fixed with locking screws. This will aid maintenance of length, rotation, and alignment of the two bone segments.

**Pros:** IM nails are the gold standard for treatment of lower extremity long bone diaphyseal fractures in humans [28]. IM nails also lie in the plane of axial loading. There is also a greater contact surface area, which would reduce stress points [29]. The IM nail is also a medullary cavity space filler. This will allow for less graft to be used. It has also been found to be a guide for tissue growth as well as allows for the formation of a medullary canal during healing [19]. The IM nail is also more flexible, which will allow for micromotion at the fracture site. It has also been

found that reaming can cause an increase in growth factors such as TGF-beta and VEGF [30]. Additionally, it has been found that osteoblasts are still viable in the bone debris after reaming, which essentially acts as internal grafting [31, 32]. Reaming has also been shown to increase the blood supply to the periosteum six-fold [33].

**Cons:** While reaming can increase the blood supply to the periosteum, it has also been shown to possibly decrease blood supply to the rest of the bone [34, 35]. Reaming can cause heat-induced osteonecrosis [36]. Tightly fitted nails may also interfere with revascularization and lead to increased risk of nonunion and infection [36]. Reaming and nail insertion will increase intramedullary pressure, which can lead to fat or air emboli [37, 38]. The nail may also interfere with scaffold design and the amount of implant material that is able to be used [13]. It may also block the medullary canal, which might reduce the regeneration potential in the endosteal area [39]. Further, it has been found that it may be difficult to remove the nail after the animal is killed, making it difficult to conduct mechanical testing [26]. Unreamed nails decrease endosteal necrosis from approximately 70–31 %, but healing rates are consistently higher using reamed nails [40–42].

## Large Animal Models

The majority of orthopedic research using large animal models utilize dogs, sheep, goats, and pigs. Dogs have a similar bone mineral density to humans, and there are fixation devices designed specifically for dogs. Primary disadvantages of using dogs include: They have a higher rate of solid bony fusion and lower nonunion rates when compared to humans [4]. Sheep are very docile animals, and their body weight is similar to that of humans. Their tibias also have geometric proportions and load-bearing patterns similar to humans [43]. The primary drawbacks of using sheep are that they have age-dependent bone remodeling, and they have a larger amount of bone ingrowth than humans [4]. Goats have similar bone remodeling and bone composition to humans. The primary drawback of using goats is that they have a more inquisitive and interactive nature and therefore might not tolerate the surgery and postoperative period as well [4]. Pigs have similar bone remodeling and bone composition to humans. They have the disadvantage of being difficult to handle as well as having excessive body weight compared to humans [4].

Several groups have argued that pigs are the animal of choice for large animal modeling due to their similarity to humans in bone remodeling and bone composition [44, 45]. Unfortunately, their tibiae and femora are relatively small and require special implants [3]. As an example, in our

ongoing pig tibia segmental defect studies, we are using hardware designed for veterinary applications. Sheep, despite their drawbacks, are used most frequently in large animal modeling primarily because human implants can be used [46]. Despite the anatomic and physiologic similarities between humans, non-human primates are seldom used as a large animal model because many pharmaceutical and biotech companies as well as funding agencies do not permit their use.

Table 1 is a collection of the recent studies investigating healing of long bone defects using large animal models. The comprehensive table includes the type of large animal utilized, the specific bone in which the defect was created, the size of the defect, the type of fixation hardware used, and the reported complications. Table 2 summarizes the tabulated complications listed in Table 1 for each type of fixation examined.

## Discussion and Future Directions

There have been many studies using large animal models that assess long bone defects. Unfortunately, these studies have minimal uniformity, and complications are rarely reported. Some researchers are very specific, some vaguely mention adverse events, and others do not report anything at all. This makes analyzing the impact of specific fixation methods on overall outcomes very difficult. Limitations aside, one can make some general observations. The most commonly used fixation devices were IM nails and single plates with approximately the same frequency. The next most common type of fixation was the external fixator. Double plating was the least commonly used. IM nails had the highest rate of infection with 7 of the 18 studies reporting at least one animal with an infection (Table 2). In one study, an animal died due to the infection. IM nails also had the highest rate of plate/nail failure with 4 of 18 studies (Table 2). Single plates had the highest rate of “other complications” with 4 of 17 studies (Table 2). This includes two studies where they found stress shielding due to the plate. Both IM nails and plates also had a relatively high rate of screw failure. External fixator studies had a low reporting rate with half of the studies not including any mention of adverse events.

Of importance, it is unclear why the infection rate is so much higher for IM nails than any other fixation method. Implants in all of the studies had to violate the medullary canal to create the long bone defect, and they all had the slightly unsanitary postoperative conditions due to the animals themselves.

Another obstacle is that the majority of the studies did not report the timing of complications. Early complications, occurring within the initial post-op period, could be

**Table 1** Fixation hardware complications in large animal models

Animal model (reference superscripted)	Bone (defect size)	Fixation type	Complications							Reference
			Infection	Screw failure	Fracture	Plate/nail failure	Other	None	Not reported	
Sheep	Femur (5 cm)	IM nail							✓	[52]
Sheep	Femur (2.5 cm)	Single plate							✓	[53]
Sheep	Femur (2.5 cm)	Single plate							✓	[54]
Sheep	Tibia (4 cm)	External fixator						✓		[55]
Sheep	Tibia (3.5 cm)	External fixator							✓	[56]
Sheep	Tibia (1.8 cm)	External fixator						✓		[57]
Sheep	Tibia (3 mm)	External fixator	✓		✓					[12]
Sheep	Tibia (3 cm)	IM nail	✓							[58]
Sheep	Tibia (3 cm)	IM nail	✓							[59]
Sheep	Tibia (3 cm)	IM nail				✓				[60]
Sheep	Tibia (1, 2, 3, cm)	IM nail	✓	✓						[61]
Sheep	Tibia (3 cm)	IM nail	✓			✓				[62]
Sheep	Tibia (3 cm)	IM Nail							✓	[63]
Sheep	Tibia (5 cm)	IM nail							✓	[64]
Sheep	Tibia (5 cm)	IM nail	✓	✓		✓				[19]
Sheep	Tibia (3 cm)	IM nail	✓			✓				[65]
Sheep	Tibia (5 mm)	IM nail						✓		[66]
Sheep	Tibia (5 cm)	IM nail					✓			[67]
Sheep	Tibia (0.7 mm)	IM nail						✓		[28]
Sheep	Tibia (7 cm)	IM nail						✓		[68]
Sheep	Tibia (3 cm)	Double plate		✓	✓	✓				[26]
Sheep	Tibia (1.6 cm)	Double plate							✓	[69]
Sheep	Tibia (2–3 cm)	Single plate		✓		✓				[13]
Sheep	Tibia (3 cm)	Single plate					✓			[39]
Sheep	Tibia (3.2 cm)	Single plate					✓			[70]
Sheep	Tibia (3.5 cm)	Single plate w/titanium cage							✓	[71]

**Table 1** continued

Animal model (reference superscripted)	Bone (defect size)	Fixation type	Complications							Reference
			Infection	Screw failure	Fracture	Plate/nail failure	Other	None	Not reported	
Sheep	Tibia (3 cm)	Double plate							✓	[72]
Sheep	Tibia (3.5 cm)	External fixator							✓	[73]
Sheep	Tibia (1.6 cm)	Double plate						✓		[74]
Dogs	Femur (3 cm)	Titanium cage w/IM nail						✓		[75]
Dogs	Femur (6 cm)	IM nail						✓		[76]
Dogs	Femur (2.5 cm)	10 IM nail, 10 single plate							✓	[77]
Dogs	Femur (2.1 cm)	Single plate						✓		[78]
Dogs	Femur (7 cm)	Single plate					✓			[79]
Dogs	Femur (2.1 cm)	Single plate					✓			[80]
Dogs	Femur (2.1 cm)	Single plate					✓			[81]
Dogs	Femur (2.1 cm)	Single plate						✓		[82]
Dog	Femur (3 cm)	Single plate		✓						[83]
Dogs	Tibia (5 mm)	External fixator							✓	[84]
Dogs	Tibia (6.5 mm)	IM nail	✓	✓	✓					[85]
Dogs	Tibia (5 mm)	Single plate					✓			[86]
Goat	Tibia (2.6 cm)	External fixator							✓	[87]
Goat	Tibia (2.6 cm)	External fixator							✓	[88]
Pigs	Tibia (2 cm)	Single plate							✓	[89]
Pigs	Tibia (1 cm)	Single plate							✓	[90]
Rhesus Monkeys	Tibia (2 cm)	Single plate							✓	[91]

immobilized to reduce complications. This would effectively force the animals to be non-weight bearing or minimally weight bearing for the initial period. However, this may affect healing because mechanical loading is essential for bone remodeling.

Consistency in reporting experimental complications is critical for accurate determination of ideal fixation methodologies. Thirteen of the forty-six studies reported no complications, and an ideal outcome is unlikely in a large

animal study regardless of the expertise in performing the procedure. Sixteen of the forty-six studies did not, however, report the complications at all. Both instances represent a deficiency in the literature and only increase the challenge of planning additional animal studies and moving bench work to clinical trials. This complication information is an absolute necessity to accurately plan additional research and as such needs to be reported honestly and accurately. This is one of the focuses of the



**Table 2** Summary of complications from Table 1

Fixation type	Total number of studies using fixation	Infection	Screw failure	Fracture	Plate/nail failure	“Other” complication	No complications	Not reported
External fixator	8	1	0	1	0	0	2	5
IM nail	18	7	3	1	4	1	5	4
Single plate	17	0	2	0	1	4	4	7
Double plate	4	0	1	1	1	0	2	1

For reported complications, at least one animal in the study had this type of complication. One study may have had more than one type of complication, so they would be counted in the tally for each of those complications

National Institute of Health’s multifaceted plan to help improve the validity of studies. They created a 20-item checklist to address the issue and aid researchers in planning studies [47]. Spurred on by this work, multiple journals have adapted checklists, such as animals in research: reporting in vivo experiments (ARRIVE), which includes reporting of adverse events. Hopefully, these requirements become ubiquitous throughout the research community to improve reporting and prevent researchers from withholding pertinent details.

Based on this review, it appears that there is no perfect fixation method for large animals being used to study long bone defects. Animals cannot be counseled on weight bearing nor how to keep their wounds clean. Due to this, they will continue to have higher rates of infection and implant failure than would normally be seen in their compliant human counterpart. Thus, it is difficult to determine whether one would be better off using: an IM nail, which has higher rates of infection and may interfere with scaffold design; a plate that may cause stress shielding or implant failure; an external fixator that may prove too cumbersome for the animal or lead to infection; or a fixation method which is not used clinically. Indeed, as double plating is not currently used in long bone defects in human clinical practice, their utility as an animal model is more limited unless being used for efficacy and safety studies for future FDA applications, such as Phase I clinical trials. The desire for plate fixation due to the apparent lesser rate of complications must be weighed against clinical observations that statically locked IM nailing is the gold standard for tibial and femur fracture fixation in humans [31, 48–50]. This is because the IM nail has been shown to have high mechanical efficacy and decreased incidence of non-unions [51]. Therefore, with this in mind, perhaps the best approach for animal testing of grafts or drug delivery (as opposed to development of new fixation hardware) would be to use an IM nail with prophylactic antibiotics to mitigate the increased rate of infections.

**Acknowledgments** This work was supported by the Medical Student Affairs Summer Research Program in Academic Medicine, Indiana University School of Medicine, funded in part by NIH NIAMS T32AR065971 (JR) and the Department of Orthopaedic Surgery, Indiana University School of Medicine (MAK, TOM, JOA, KDS). In addition, research reported in this publication was supported in part by the following Grants: NIH NIAMS R01 AR060863 (MAK), USAMRMC OR120080 (MAK, T-MGC, JOA), an Indiana University Health Values Grant (KDS, MAK), Indiana Clinical and Translational Sciences Institute Grants partially supported by NIH UL1TR001108 (MAK, T-MGC, TOM, JOA), and an Indiana University Collaborative Research Grant (MAK, T-MGC). The content of this manuscript is solely the responsibility of the authors and does not necessarily represent the official views of the NIH. The opinions or assertions contained herein are the private views of the authors and are not to be construed as official or as reflecting the views of the Department of the Army or the Department of Defense.

#### Compliance with Ethical Standards

**Conflicts of interest** Emily Jewell, Jeff Rytlewski, Tien-Min G. Chu, Jeffrey O. Anglen, Karl D. Shively, and Melissa A. Kacena declare they have no conflict of interest. Todd O. McKinley is a consultant for Bioventus.

**Animal/Human Studies** This article does not include any studies with human or animal subjects performed by the author.

#### References

- Schmitz JP, Hollinger JO. The critical size defect as an experimental model for craniomandibulofacial nonunions. *Clin Orthop Relat Res*. 1986;205:299–308.
- Hollinger JO, Kleinschmidt JC. The critical size defect as an experimental model to test bone repair materials. *J Craniofac Surg*. 1990;1(1):60–8.
- Reichert JC, Saifzadeh S, Wulschleger ME, Epari DR, Schutz MA, Duda GN, et al. The challenge of establishing preclinical models for segmental bone defect research. *Biomaterials*. 2009;30(12):2149–63.
- Pearce AI, Richards RG, Milz S, Schneider E, Pearce SG. Animal models for implant biomaterial research in bone: a review. *Eur Cell Mater*. 2007;13:1–10.
- Lovett M, Lee K, Edwards A, Kaplan DL. Vascularization strategies for tissue engineering. *Tissue Eng Part B Rev*. 2009;15(3):353–70.


6. Horner EA, Kirkham J, Wood D, Curran S, Smith M, Thomson B, et al. Long bone defect models for tissue engineering applications: criteria for choice. *Tissue Eng Part B Rev*. 2010;16(2):263–71.
7. Apivatthakakul T, Phornphutkul C, Bunmaprasert T, Sananpanich K, Fernandez Dell'Oca A. Percutaneous cerclage wiring and minimally invasive plate osteosynthesis (MIPO): a percutaneous reduction technique in the treatment of Vancouver type B1 periprosthetic femoral shaft fractures. *Arch Orthop Trauma Surg*. 2012;132(6):813–22.
8. Gebhard F, Kregor P, Oliver C. [https://www2.aofoundation.org/wps/portal/surgery/?showPage=redfix&bone=Femur&segment=Distal&classification=33-A3&treatment=&method=Provisional+treatment&implanttype=Temporary+external+fixator&redfix\\_url=1285238413692](https://www2.aofoundation.org/wps/portal/surgery/?showPage=redfix&bone=Femur&segment=Distal&classification=33-A3&treatment=&method=Provisional+treatment&implanttype=Temporary+external+fixator&redfix_url=1285238413692). Accessed 1 Sept 2015.
9. Mills L, Noble B, Fenwick S, Simpson H. P103 assessment of a novel angiogenic factor in a small animal model of atrophic nonunion. *J Bone Joint Surg*. 2008;90-B(Suppl 2):391.
10. Konrad G, Sudkamp N. Extra-articular proximal tibial fracture. *Chirurg*. 2007;78(2):161–71 (**quiz 172–3**).
11. Beltsios M, Savvidou O, Kovanis J, Alexandropoulos P, Papagelopoulos P. External fixation as a primary and definitive treatment for tibial diaphyseal fractures. *Strateg Trauma Limb Reconstr*. 2009;4(2):81–7.
12. Krischak GD, Janousek A, Wolf S, Augat P, Kinzl L, Claes LE. Effects of one-plane and two-plane external fixation on sheep osteotomy healing and complications. *Clin Biomech (Bristol, Avon)*. 2002;17(6):470–6.
13. Reichert JC, Epari DR, Wulschlegler ME, Saifzadeh S, Steck R, Lienau J, et al. Establishment of a preclinical ovine model for tibial segmental bone defect repair by applying bone tissue engineering strategies. *Tissue Eng Part B Rev*. 2010;16(1):93–104.
14. Seekamp A, Lehmann U, Pizanis A, Pohlemann T. New aspects for minimally invasive interventions in orthopedic trauma surgery. *Chirurg*. 2003;74(4):301–9.
15. Apivatthakakul T, Anurakleha S, Babikian G, Castelli F, Pace A, Phiphobmongkol V, et al. [https://www2.aofoundation.org/wps/portal/surgery/?showPage=redfix&bone=Tibia&segment=Shaft&classification=42-B3&treatment=&method=CRIF++Closed+reduction+internal+fixation&implanttype=MIO++Bridge+plating&redfix\\_url=1285239039132](https://www2.aofoundation.org/wps/portal/surgery/?showPage=redfix&bone=Tibia&segment=Shaft&classification=42-B3&treatment=&method=CRIF++Closed+reduction+internal+fixation&implanttype=MIO++Bridge+plating&redfix_url=1285239039132). Accessed 1 Sept 2015.
16. Sommer C, Gautier E, Muller M, Helfet DL, Wagner M. First clinical results of the Locking Compression Plate (LCP). *Injury*. 2003;34(Suppl 2):B43–54.
17. Beard J, Hessmann M, Hansen M, Rommens PM. Operative treatment of tibial shaft fractures: a comparison of different methods of primary stabilisation. *Arch Orthop Trauma Surg*. 2008;128(7):709–15.
18. Perren SM. Evolution of the internal fixation of long bone fractures. The scientific basis of biological internal fixation: choosing a new balance between stability and biology. *J Bone Joint Surg Br*. 2002;84(8):1093–110.
19. Christou C, Oliver RA, Pelletier MH, Walsh WR. Ovine model for critical-size tibial segmental defects. *Comp Med*. 2014;64(5):377–85.
20. Krettek C, Schandelmaier P, Tschern H. New developments in stabilization of dia- and metaphyseal fractures of long tubular bones. *Orthopade*. 1997;26(5):408–21.
21. Gautier E, Ganz R. The biological plate osteosynthesis. *Zentralbl Chir*. 1994;119(8):564–72.
22. Gautier E, Perren SM, Cordey J. Strain distribution in plated and unplated sheep tibia an in vivo experiment. *Injury*. 2000;31(Suppl 3):C37–44.
23. Johnson BA, Fallat LM. The effect of screw holes on bone strength. *J Foot Ankle Surg*. 1997;36(6):446–51.
24. Peirone B. [https://www2.aofoundation.org/wps/portal/surgery?showPage=redfix&bone=DogFemur&segment=Shaft&classification=d32-C3&treatment=&method=Bridging%20plate%20and%20alternative%20double%20plating&implanttype=&approach=&redfix\\_url=1415874648616&Language=en](https://www2.aofoundation.org/wps/portal/surgery?showPage=redfix&bone=DogFemur&segment=Shaft&classification=d32-C3&treatment=&method=Bridging%20plate%20and%20alternative%20double%20plating&implanttype=&approach=&redfix_url=1415874648616&Language=en). Accessed 1 Sept 2015.
25. Rubel IF, Kloen P, Campbell D, Schwartz M, Liew A, Myers E, et al. Open reduction and internal fixation of humeral nonunions : a biomechanical and clinical study. *J Bone Joint Surg Am*. 2002;84-A(8):1315–22.
26. Hahn JA, Witte TS, Arens D, Pearce A, Pearce S. Double-plating of ovine critical sized defects of the tibia: a low morbidity model enabling continuous in vivo monitoring of bone healing. *BMC Musculoskelet Disord*. 2011;12:214–2474–12–214.
27. Apivatthakakul T, Anurakleha S, Babikian G, Castelli F, Pace A, Phiphobmongkol V, et al. [https://www2.aofoundation.org/wps/portal/surgery?showPage=redfix&bone=Tibia&segment=Shaft&classification=42-C2&treatment=&method=CRIF%20-%20Closed%20reduction%20internal%20fixation&implanttype=Nailing&approach=&redfix\\_url=1285239039726&Language=en#stepUnit=8](https://www2.aofoundation.org/wps/portal/surgery?showPage=redfix&bone=Tibia&segment=Shaft&classification=42-C2&treatment=&method=CRIF%20-%20Closed%20reduction%20internal%20fixation&implanttype=Nailing&approach=&redfix_url=1285239039726&Language=en#stepUnit=8). Accessed 1 Sept 2015.
28. Gradl G, Herlyn P, Emmerich J, Friebe U, Martin H, Mittlmeier T. Fracture near press-on interlocking enhances callus mineralisation in a sheep midshaft tibia osteotomy model. *Injury*. 2014;45(Suppl 1):S66–70.
29. Chao P, Lewis DD, Kowaleski MP, Pozzi A. Biomechanical concepts applicable to minimally invasive fracture repair in small animals. *Vet Clin North Am Small Anim Pract*. 2012;42(5):853–72.
30. Giannoudis PV, Chalidis BE, Roberts CS. Internal fixation of traumatic diastasis of pubic symphysis: Is plate removal essential? *Arch Orthop Trauma Surg*. 2008;128(3):325–31.
31. Hogel F, Schlegel U, Sudkamp N, Muller C. Fracture healing after reamed and unreamed intramedullary nailing in sheep tibia. *Injury*. 2011;42(7):667–74.
32. Frolke JP, Bakker FC, Patka P, Haarman HJ. Reaming debris in osteotomized sheep tibiae. *J Trauma*. 2001;50(1):65–9 (**discussion 69–70**).
33. Reichert IL, McCarthy ID, Hughes SP. The acute vascular response to intramedullary reaming. Microsphere estimation of blood flow in the intact ovine tibia. *J Bone Joint Surg Br*. 1995;77(3):490–3.
34. Mastrogiacomo M, Corsi A, Francioso E, Di Comite M, Monetti F, Scaglione S, et al. Reconstruction of extensive long bone defects in sheep using resorbable bioceramics based on silicon stabilized tricalcium phosphate. *Tissue Eng*. 2006;12(5):1261–73.
35. Mueller CA, Rahn BA. Intramedullary pressure increase and increase in cortical temperature during reaming of the femoral medullary cavity: the effect of draining the medullary contents before reaming. *J Trauma*. 2003;55(3):495–503 (**discussion 503**).
36. Chapman MW. The effect of reamed and nonreamed intramedullary nailing on fracture healing. *Clin Orthop Relat Res*. 1998;355(Suppl):S230–8.
37. Pape HC, Giannoudis PV. Fat embolism and IM nailing. *Injury*. 2006;37(Suppl 4):S1–2.
38. Wenda K, Ritter G, Degreif J, Rudigier J. Pathogenesis of pulmonary complications following intramedullary nailing osteosyntheses. *Unfallchirurg*. 1988;91(9):432–5.
39. Berner A, Reichert JC, Woodruff MA, Saifzadeh S, Morris AJ, Epari DR, et al. Autologous vs. allogenic mesenchymal progenitor cells for the reconstruction of critical sized segmental tibial bone defects in aged sheep. *Acta Biomater*. 2013;9(8):7874–84.
40. Augat P, Penzkofer R, Nolte A, Maier M, Panzer S, Oldenburg G, et al. Interfragmentary movement in diaphyseal tibia fractures fixed with locked intramedullary nails. *J Orthop Trauma*. 2008;22(1):30–6.



41. Kessler SB, Hallfeldt KK, Perren SM, Schweiberer L. The effects of reaming and intramedullary nailing on fracture healing. *Clin Orthop Relat Res.* 1986;212:18–25.
42. Lam SW, Teraa M, Leenen LP, van der Heijden GJ. Systematic review shows lowered risk of nonunion after reamed nailing in patients with closed tibial shaft fractures. *Injury.* 2010;41(7):671–5.
43. Augat P, Merk J, Ignatius A, Margevicius K, Bauer G, Rosenbaum D, et al. Early, full weightbearing with flexible fixation delays fracture healing. *Clin Orthop Relat Res.* 1996;328:194–202.
44. Aerssens J, Boonen S, Lowet G, Dequeker J. Interspecies differences in bone composition, density, and quality: potential implications for in vivo bone research. *Endocrinology.* 1998;139(2):663–70.
45. Thorwarth M, Schultze-Mosgau S, Kessler P, Wiltfang J, Schlegel KA. Bone regeneration in osseous defects using a resorbable nanoparticulate hydroxyapatite. *J Oral Maxillofac Surg.* 2005;63(11):1626–33.
46. Newman E, Turner AS, Wark JD. The potential of sheep for the study of osteopenia: current status and comparison with other animal models. *Bone.* 1995;16(4 Suppl):277S–84S.
47. Manolagas SC, Kronenberg HM. Reproducibility of results in preclinical studies: a perspective from the bone field. *J Bone Miner Res.* 2014;29(10):2131–40.
48. Bong MR, Kummer FJ, Koval KJ, Egol KA. Intramedullary nailing of the lower extremity: biomechanics and biology. *J Am Acad Orthop Surg.* 2007;15(2):97–106.
49. Bhandari M, Guyatt GH, Tornetta P III, Swiontkowski MF, Hanson B, Sprague S, et al. Current practice in the intramedullary nailing of tibial shaft fractures: an international survey. *J Trauma.* 2002;53(4):725–32.
50. Henley MB, Chapman JR, Agel J, Harvey EJ, Whorton AM, Swiontkowski MF. Treatment of type II, IIIA, and IIIB open fractures of the tibial shaft: a prospective comparison of unreamed interlocking intramedullary nails and half-pin external fixators. *J Orthop Trauma.* 1998;12(1):1–7.
51. Tzioupis C, Giannoudis PV. Prevalence of long-bone non-unions. *Injury.* 2007;38(Suppl 2):S3–9.
52. Field JR, McGee M, Wildenauer C, Kurmis A, Margerrison E. The utilization of a synthetic bone void filler (JAX) in the repair of a femoral segmental defect. *Vet Comp Orthop Traumatol.* 2009;22(2):87–95.
53. Kirker-Head CA, Gerhart TN, Armstrong R, Schelling SH, Carmel LA. Healing bone using recombinant human bone morphogenetic protein 2 and copolymer. *Clin Orthop Relat Res.* 1998;349:205–17.
54. Kirker-Head CA, Gerhart TN, Schelling SH, Hennig GE, Wang E, Holtrop ME. Long-term healing of bone using recombinant human bone morphogenetic protein 2. *Clin Orthop Relat Res.* 1995;318:222–30.
55. Gugala Z, Gogolewski S. Healing of critical-size segmental bone defects in the sheep tibiae using bioresorbable polylactide membranes. *Injury.* 2002;33(Suppl 2):B71–6.
56. Marcacci M, Kon E, Zaffagnini S, Giardino R, Rocca M, Corsi A, et al. Reconstruction of extensive long-bone defects in sheep using porous hydroxyapatite sponges. *Calcif Tissue Int.* 1999;64(1):83–90.
57. Maissen O, Eckhardt C, Gogolewski S, Glatt M, Arvinte T, Steiner A, et al. Mechanical and radiological assessment of the influence of rhTGFbeta-3 on bone regeneration in a segmental defect in the ovine tibia: pilot study. *J Orthop Res.* 2006;24(8):1670–8.
58. den Boer FC, Patka P, Bakker FC, Wippermann BW, van Lingen A, Vink GQ, et al. New segmental long bone defect model in sheep: quantitative analysis of healing with dual energy X-ray absorptiometry. *J Orthop Res.* 1999;17(5):654–60.
59. den Boer FC, Wippermann BW, Blokhuis TJ, Patka P, Bakker FC, Haarman HJ. Healing of segmental bone defects with granular porous hydroxyapatite augmented with recombinant human osteogenic protein-1 or autologous bone marrow. *J Orthop Res.* 2003;21(3):521–8.
60. Bloemers FW, Blokhuis TJ, Patka P, Bakker FC, Wippermann BW, Haarman HJ. Autologous bone versus calcium-phosphate ceramics in treatment of experimental bone defects. *J Biomed Mater Res B Appl Biomater.* 2003;66(2):526–31.
61. Tyllianakis M, Deligianni D, Panagopoulos A, Pappas M, Sourgiadaki E, Mavrilas D, et al. Biomechanical comparison of callus over a locked intramedullary nail in various segmental bone defects in a sheep model. *Med Sci Monit.* 2007;13(5):BR125–30.
62. Blokhuis TJ, Wippermann BW, den Boer FC, van Lingen A, Patka P, Bakker FC, et al. Resorbable calcium phosphate particles as a carrier material for bone marrow in an ovine segmental defect. *J Biomed Mater Res.* 2000;51(3):369–75.
63. Field JR, McGee M, Stanley R, Ruthenbeck G, Papadimitrakakis T, Zannettino A, et al. The efficacy of allogeneic mesenchymal precursor cells for the repair of an ovine tibial segmental defect. *Vet Comp Orthop Traumatol.* 2011;24(2):113–21.
64. Regauer M, Jurgens I, Kotsianos D, Stutzle H, Mutschler W, Schieker M. New-bone formation by osteogenic protein-1 and autogenic bone marrow in a critical tibial defect model in sheep. *Zentralbl Chir.* 2005;130(4):338–45.
65. Schneiders W, Reinstorf A, Biewener A, Serra A, Grass R, Kinscher M, et al. In vivo effects of modification of hydroxyapatite/collagen composites with and without chondroitin sulphate on bone remodeling in the sheep tibia. *J Orthop Res.* 2009;27(1):15–21.
66. Lozada-Gallegos AR, Letechipia-Moreno J, Palma-Lara I, Montero AA, Rodriguez G, Castro-Munozledo F, et al. Development of a bone nonunion in a noncritical segmental tibia defect model in sheep utilizing interlocking nail as an internal fixation system. *J Surg Res.* 2013;183(2):620–8.
67. Pluhar GE, Turner AS, Pierce AR, Toth CA, Wheeler DL. A comparison of two biomaterial carriers for osteogenic protein-1 (BMP-7) in an ovine critical defect model. *J Bone Joint Surg Br.* 2006;88(7):960–6.
68. Gerber A, Gogolewski S. Reconstruction of large segmental defects in the sheep tibia using polylactide membranes. A clinical and radiographic report. *Injury.* 2002;33(Suppl 2):B43–57.
69. Gao TJ, Lindholm TS, Kommonen B, Ragni P, Paronzini A, Lindholm TC, et al. Enhanced healing of segmental tibial defects in sheep by a composite bone substitute composed of tricalcium phosphate cylinder, bone morphogenetic protein, and type IV collagen. *J Biomed Mater Res.* 1996;32(4):505–12.
70. Rozen N, Bick T, Bajayo A, Shamian B, Schrift-Tzadok M, Gabet Y, et al. Transplanted blood-derived endothelial progenitor cells (EPC) enhance bridging of sheep tibia critical size defects. *Bone.* 2009;45(5):918–24.
71. Teixeira CR, Rahal SC, Volpi RS, Taga R, Cestari TM, Granjeiro JM, et al. Tibial segmental bone defect treated with bone plate and cage filled with either xenogeneic composite or autologous cortical bone graft. An experimental study in sheep. *Vet Comp Orthop Traumatol.* 2007;20(4):269–76.
72. Niemeyer P, Schonberger TS, Hahn J, Kasten P, Fellenberg J, Suedkamp N, et al. Xenogenic transplantation of human mesenchymal stem cells in a critical size defect of the sheep tibia for bone regeneration. *Tissue Eng Part A.* 2010;16(1):33–43.
73. Chistolini P, Ruspantini I, Bianco P, Corsi A, Cancedda R, Quarto R. Biomechanical evaluation of cell-loaded and cell-free hydroxyapatite implants for the reconstruction of segmental bone defects. *J Mater Sci Mater Med.* 1999;10(12):739–42.
74. Gao TJ, Lindholm TS, Kommonen B, Ragni P, Paronzini A, Lindholm TC, et al. The use of a coral composite implant

- containing bone morphogenetic protein to repair a segmental tibial defect in sheep. *Int Orthop*. 1997;21(3):194–200.
75. Lindsey RW, Gugala Z, Milne E, Sun M, Gannon FH, Latta LL. The efficacy of cylindrical titanium mesh cage for the reconstruction of a critical-size canine segmental femoral diaphyseal defect. *J Orthop Res*. 2006;24(7):1438–53.
76. Zabka AG, Pluhar GE, Edwards RB III, Manley PA, Hayashi K, Heiner JP, et al. Histomorphometric description of allograft bone remodeling and union in a canine segmental femoral defect model: a comparison of rhBMP-2, cancellous bone graft, and absorbable collagen sponge. *J Orthop Res*. 2001;19(2):318–27.
77. Bernarde A, Diop A, Maurel N, Viguier E. An in vitro biomechanical study of bone plate and interlocking nail in a canine diaphyseal femoral fracture model. *Vet Surg*. 2001;30(5):397–408.
78. Kraus KH, Kadiyala S, Wotton H, Kurth A, Shea M, Hannan M, et al. Critically sized osteo-periosteal femoral defects: a dog model. *J Invest Surg*. 1999;12(2):115–24.
79. Weiland AJ, Phillips TW, Randolph MA. Bone grafts: a radiologic, histologic, and biomechanical model comparing autografts, allografts, and free vascularized bone grafts. *Plast Reconstr Surg*. 1984;74(3):368–79.
80. Brodke D, Pedrozo HA, Kapur TA, Attawia M, Kraus KH, Holy CE, et al. Bone grafts prepared with selective cell retention technology heal canine segmental defects as effectively as autograft. *J Orthop Res*. 2006;24(5):857–66.
81. Arinzeh TL, Peter SJ, Archambault MP, van den Bos C, Gordon S, Kraus K, et al. Allogeneic mesenchymal stem cells regenerate bone in a critical-sized canine segmental defect. *J Bone Joint Surg Am*. 2003;85-A(10):1927–35.
82. Bruder SP, Kraus KH, Goldberg VM, Kadiyala S. The effect of implants loaded with autologous mesenchymal stem cells on the healing of canine segmental bone defects. *J Bone Joint Surg Am*. 1998;80(7):985–96.
83. Akagi H, Ochi H, Kannno N, Iwata M, Ichinohe T, Harada Y, et al. Clinical efficacy of autogenous cancellous bone and fibroblast growth factor 2 combined with frozen allografts in femoral nonunion fractures. *Vet Comp Orthop Traumatol*. 2013;26(2):123–9.
84. Markel MD, Bogdanske JJ, Xiang Z, Klohnen A. Atrophic non-union can be predicted with dual energy X-ray absorptiometry in a canine osteotomy model. *J Orthop Res*. 1995;13(6):869–75.
85. Kuzyk PRT, Schemitsch EH, Davies JE. A biodegradable scaffold for the treatment of a diaphyseal bone defect of the tibia. *J Orthop Res*. 2010;28(4):474–80.
86. Boyce AS, Reveal G, Scheid DK, Kaehr DM, Maar D, Watts M, et al. Canine investigation of rhBMP-2, autogenous bone graft, and rhBMP-2 with autogenous bone graft for the healing of a large segmental tibial defect. *J Orthop Trauma*. 2009;23(10):685–92.
87. Xu XL, Tang T, Dai K, Zhu Z, Guo XE, Yu C, et al. Immune response and effect of adenovirus-mediated human BMP-2 gene transfer on the repair of segmental tibial bone defects in goats. *Acta Orthop*. 2005;76(5):637–46.
88. Liu G, Zhao L, Zhang W, Cui L, Liu W, Cao Y. Repair of goat tibial defects with bone marrow stromal cells and beta-tricalcium phosphate. *J Mater Sci Mater Med*. 2008;19(6):2367–76.
89. Pek YS, Gao S, Arshad MS, Leck KJ, Ying JY. Porous collagen-apatite nanocomposite foams as bone regeneration scaffolds. *Biomaterials*. 2008;29(32):4300–5.
90. Raschke M, Kolbeck S, Bail H, Schmidmaier G, Flyvbjerg A, Lindner T, et al. Homologous growth hormone accelerates healing of segmental bone defects. *Bone*. 2001;29(4):368–73.
91. Fan H, Zeng X, Wang X, Zhu R, Pei G. Efficacy of prevascularization for segmental bone defect repair using beta-tricalcium phosphate scaffold in rhesus monkey. *Biomaterials*. 2014;35(26):7407–15.

# Evolution of Bone Grafting: Bone Grafts and Tissue Engineering Strategies for Vascularized Bone Regeneration

Kaitlyn S. Griffin<sup>1</sup> · Korbin M. Davis<sup>1</sup> · Todd O. McKinley<sup>1</sup> · Jeffrey O. Anglen<sup>1</sup> · Tien-Min G. Chu<sup>2</sup> · Joel D. Boerckel<sup>3</sup> · Melissa A. Kacena<sup>1</sup> 

© Springer Science+Business Media New York 2015

**Abstract** The regeneration of bone in segmental defects has historically been a challenge in the orthopedic field. In particular, a lack of vascular supply often leads to non-union and avascular necrosis. While the gold standard of clinical care remains the autograft, this approach is limited for large bone defects. Therefore, allograft bone is often required for defects of critical size though a high complication rate is directly attributable to their limited ability to revitalize, revascularize, and remodel resulting in necrosis and re-fracture. However, emerging insights into the mechanisms of bone healing continue to expand treatment options for bony defects to include synthetic materials, growth factors, and cells. The success of such strategies hinges on fabricating an environment that can mimic the body's natural healing process, allowing for vascularization, bridging, and remodeling of bone. Biological, chemical, and engineering techniques have been explored to determine the appropriate materials and factors for potential use. This review will serve to highlight some of the

historical and present uses of allografts and autografts and current strategies in bone tissue engineering for the treatment for bony defects, with particular emphasis on vascularization.

**Keywords** Allograft · Autograft · Scaffold · Bone tissue engineering · Growth factors · Endothelial cells · Mesenchymal stem cells · Vascularization

## Introduction

Reconstructing and regenerating significant skeletal defects have perplexed mankind for thousands of years. Grafting techniques were utilized as early as 2000 BC when Khurits utilized a piece of animal bone to repair a small skull defect, which proved successful millennia later when anthropologists discovered the remains exhibiting regrowth around the graft [1]. In the modern age, the first documented bone graft was performed in 1668 by Job van Meekeren, a Dutch surgeon. He, too, used a xenograft to repair a skull defect in an injured soldier [2]. Bone grafts and the understanding of orthopedic science were further propelled in the seventeenth century by the work of Antoni van Leeuwenhoek who is famously known for his work on microscopy. He also primitively described the microarchitecture of bone, identifying what we now refer to as Haversian canals [1, 2]. Diligent examination of bone grafting criteria and outcomes surfaced in the early 1900s with the work of Vittorio Putti who outlined the principles of grafting [1]. Putti's work established a foundation for grafting science in the field of orthopedic surgery. Since then, surgeons and researchers alike have continued to hone the science of bone grafting to allow for the most appropriate surgical intervention with the best outcomes.

---

Kaitlyn S. Griffin and Korbin M. Davis have contributed equally to this work.

---

✉ Joel D. Boerckel  
jboercke@nd.edu

✉ Melissa A. Kacena  
mkacena@iupui.edu

<sup>1</sup> Department of Orthopaedic Surgery, Indiana University School of Medicine, 1120 South Drive FH 115, Indianapolis, IN 46202, USA

<sup>2</sup> Department of Restorative Dentistry, Indiana University School of Dentistry, Indianapolis, IN, USA

<sup>3</sup> Department of Aerospace and Mechanical Engineering, University of Notre Dame, 142 Multidisciplinary Research Bldg, Notre Dame, IN 46556, USA

Grafted bone can come from the same individual (autograft) or from other individuals of the same species (allograft). Every year, approximately 1 million bone allografts are used [3]. Between 1992 and 2007, an estimated 1.7 million bone autografts were performed [4]. Both grafts possess unique advantages and disadvantages, but autografts began to come into favor over allograft in the early 1900s with recognition of the benefit that vascularization provides to the integrity of the graft and surrounding bone [5, 6]. Evidence continues to suggest autografts provide improved outcomes over allografts [7–14]. However, autologous and allogeneic bone grafts are now often used in combination with bioengineered scaffolds (frames upon which tissue regeneration can occur) or bone substitutes/adjuncts, which may allow for enhanced applications of allografts [15–23], so much so that allografts may be superior to autografts if combined with bone morphogenetic proteins (BMPs) and a bisphosphonate, suggested by larger and denser calluses with increased peak force in BMP + bisphosphonate graft [24].

The advancement of biomaterials' research in the past few decades has enabled the development of scaffold materials to enhance the regeneration and vascularization of bone in large segmental defects. Scaffolds have been made from many materials and have included growth factors and/or cells to specifically promote vascularization in healing bone grafts. Combinations have included vascular endothelial growth factor (VEGF), platelet-derived growth factor (PDGF), endothelial cells (ECs), and mesenchymal stem cells (MSCs). Addition of these compounds and/or cells to scaffolds has provided potential in improving outcomes in patients undergoing grafting procedures.

As life expectancy continues to increase, orthopedic cases continue to rise as well. In 2008, health care costs for regenerative biomaterials were estimated to exceed \$240 million [25], and it is not unreasonable to assume this value will continue to rise, highlighting the importance of regenerative bone materials in orthopedic care in the near future. The most common uses for bone grafts in the USA are spinal fusion and fracture nonunion [4]. This review will address the use and characteristics of enhanced grafts, scaffolds, and bone substitutes as adjuncts in orthopedic reconstruction and bone regeneration.

## Bone Grafts

Bone grafts and scaffolds are often evaluated for three characteristics: (1) osteoinduction—ability to recruit and induce MSCs to differentiate into mature bone-forming cells; (2) osteoconduction—allowing for cellular invasion of the graft; and (3) osteointegration—functional

integration of the graft with the host tissue through new bone formation [26, 27]. An ideal graft harnesses adequate osteoconductive, osteoinductive, and osteointegrative characteristics; however, the necessary properties for optimal bone scaffold design remain unknown. Below, we discuss the advantages and disadvantages of allografts and autografts and touch upon adjunctive therapies that are in development to improve outcomes with use of either graft.

## Allografts

Bone allografts are harvested tissue from human cadaveric donors. Cancellous allografts provide minimal to no structural strength, mild-to-moderate osteoconductive properties, and mild osteoinductive properties. Cortical allografts, on the other hand, can provide structural strength but little osteoinduction [28]. Studies have demonstrated the advantages of allografts in the setting of very significant bone defects as seen in musculoskeletal malignancies [29, 30]. When autograft use is precluded by the size of the donor site and donor site morbidity secondary to large defect, surgeons turn to allografts for reconstruction. Early research published in the *New England Journal of Medicine* demonstrated large allografts can prove successful in the reconstruction of bone defects following tumor removal [30]. Furthermore, functional status of patients who undergo massive allograft transplantation has been reported as satisfactory in as many as 70 % of patients [29]. Allografts may also include articular surfaces and even ligaments.

Allografts obviate many complications that arise with xenografts that were used thousands of years ago, but they also pose their own set of complexities and dangers [31–33]. Though these grafts are harvested from human cadaveric tissues, they retain the capacity to induce an immune response in recipients [34–38]. In the early use of allografts for segmental bone defects, various protocols surfaced to minimize graft–host interactions, including cryopreservation, irradiation, decalcification, and pharmacologic immunosuppression [39–43]. Cryopreservation, specifically, was demonstrated to produce shorter and more infrequent graft–host immune responses as compared to fresh, vascularized bone grafts [44]. More recently, however, protocols using nonionic detergents, hydrogen peroxide, and denatured alcohol have demonstrated an improved safety profile of allogeneic grafts [45] with union rates comparable to autologous grafts [46].

Aside from immune reactions, allografts pose a problem when concerned with union rates, structural integrity, and infections. In a large retrospective study, Hornicke et al. [47] demonstrated that of 945 patients who underwent allograft transplantation, 17.3 % of the patients experienced nonunion. Furthermore, nonunion was often

associated with infection and graft fracture [47]. Sorger et al. [48] conducted a retrospective review of graft fracture in patients who underwent allograft transplantation. In a 1046 patient sample, 17.7 % experienced structural allograft fracture at a mean time of 3.2 years after transplantation. Patients with graft fractures underwent further reconstruction, but 45.9 % of the allografts completely failed (time to complete failure not specified) [48]. Finally, infection is a large concern for allograft transplant procedures. Infection rates have been suggested to reach 12.9–13.3 % in patients who undergo allogeneic transplantation [49, 50]. Furthermore, 50 % of allograft infections were polymicrobial with poor soft tissue coverage responsible for the majority of the infections [50].

### Autografts

Autografts are harvested from and implanted into the same individual. The most frequently used donor site for bone autografting is the iliac crest with other options including the proximal tibial, distal radius, and greater trochanter [51]. Autografts obviate graft–host reactions mediated by histocompatibility mismatches because the tissue is removed and transplanted in the same individual. However, autografts present their own set of complications with donor site morbidity and limited tissue availability.

Autografts are considered the standard of bone grafting, especially in craniofacial surgery, due to their significant osteoinductive and osteoconductive properties [52, 53]. Cortical autografts also provide significant structural strength to the graft [28]. Cellular viability and neovascularization are critical properties of autografts that partly account for their use over allografts and aid in the osteoinductive, osteoconductive, and osteogenic potential. Vascularization is vital to the structural integrity of bone during the healing process [54–57], and graft integration is no exception [58, 59]. As one can expect, neovascularization between any graft and recipient site during the healing phase is a complex, dynamic interplay between various cell types and growth factors, which is supported by the use of autografts [58]. Cancellous bone autografts have been demonstrated to initiate vascularization within 2 days of grafting [60]. Harnessing the neovascularization in autografts is vital to the success of grafts in recipients.

Disadvantages to the use of autologous bone include donor site pain [61–63], which can be severe and prolonged, as well as more significant complications such as fracture, pelvic instability, hematoma formation, infection, and nerve palsies [64–68]. In addition, the quantity of bone graft needed further limits the use of autografts and contributes to the likelihood of adverse events after harvest.

The limitations of both autogenous and allogeneic bone graft materials have spurred research resulting in a

proliferation of natural and new synthetic biomaterials used to treat bone defects. Nanotechnology and more refined biomechanical techniques have allowed for the analysis and development of osteogenic, osteoinductive, and osteoconductive biomaterials. As the field of bioengineering continues to evolve, allografts and autografts will likely fall out of favor and be replaced by more advanced bone graft substitutes that optimize vascular and cellular potential.

### Scaffold Materials

Bioengineered scaffolds have evolved dramatically over the past 40 years and provide great potential in orthopedic and maxillofacial applications without immunologic or donor site complications that arise with allografts and autografts. Potential for these materials is virtually infinite with the advancement of nanotechnology and derivation of new scaffold materials, materials that will be developed to harbor significant strength and adequate osteoconductive and osteoinductive properties. Variations in scaffold type and architecture are limitless, including material, porosity, cellular seeding capacity, and growth factor seeding capacity [69–71].

### Natural—Collagen, Alginate, Hyaluronic Acid

Collagen is the most abundant protein found in bone. Thus, it has been utilized in orthopedic tissue engineering applications because of its availability and biocompatible properties [72]. It obviates many of the complications associated with the use of bone allografts and autografts, but the mechanical properties of collagen remain in question [73]. More recent developments in collagen scaffolds have provided an improved strength profile of collagen scaffolds by modifying collagen cross-linking [74–76]. Tierney et al. [77] refined the properties of collagen scaffolds, including porosity, matrix, and permeability to increase osteoblast activity. These studies point to the potential of collagen scaffolds in tissue engineering, especially in orthopedic and maxillofacial applications. In virtually, all applications of bone grafts and scaffold materials, including collagen, vascularization, remains paramount for graft success.

Alginate is an additional natural material derived from brown algae that offers potential in biomaterial engineering cell [78, 79] through its ability to form a gel in combination with water. It is a polysaccharide that is easily modified chemically and structurally to allow for enhanced application in regenerative medicine. Its viscosity and porosity allow for cellular immobilization, integration, and extended release of factors and cells from the scaffold [80].

However, it lacks intrinsic mechanical strength [81] and is often combined with other compounds (i.e., chitosan, gelatin, and hydroxyapatite) to improve osteoconductive and osteointegrative properties while providing a strong biodegradable structure [82–85]. Furthermore, alginate can be functionalized with growth factors to enhance neovascularization in and around the scaffold to improve bone growth [86, 87]. One issue within biomaterial engineering is the ability to control the release of such factors and cells to enhance their effects. Alginate has been used as a spatiotemporal delivery vehicle for BMP-2 to enhance bone regeneration in comparison with collagen sponge as a result of sustained release in vivo [88, 89] and to deliver angiogenic factors sequentially to improve scaffold vascularization and bone regeneration due to differences in binding affinity between alginate and the factors [90, 91].

Finally, hyaluronic acid (HA) is another natural compound that has been studied for use in bone tissue engineering. HA is essential to the extracellular matrix in wound healing and is well known in musculoskeletal physiology as a compound that provides lubrication to synovial membranes in joint capsules by aggregating glycosaminoglycans [92, 93]. In tissue engineering applications, HA is similar to alginate in the fact that it is often combined with other compounds [94–96] and functionalized with growth factors [97] to enhance its regenerative potential and provide functional and structural roles in constructs [98, 99]. Like alginate, as a pure compound, it lacks mechanical strength often required for weight-bearing and thus requires either sufficient fixation stability or combination with structural scaffolds.

### **Synthetic Materials—Polyethylene Glycol, Polycaprolactone**

Polyethylene glycol (PEG) is a synthetic compound used in tissue engineering due to low toxicity and absence of an immune response. It is hydrophilic and soluble, yielding poor mechanical strength [100], but it can, like the natural compounds, be combined with other materials to improve strength and biocompatibility. PEG can be functionalized with adhesive peptides [101], growth factors, and polysaccharides, such as glycosaminoglycans [102, 103], which have improved bone growth in and around the scaffold. In addition, PEG can be used to functionalize other scaffold materials and link macromolecules to improve bone formation [104].

Polycaprolactone is a synthetic biodegradable compound used in bone tissue engineering for its mechanical profile and manufacturability. It is a porous compound manufactured via numerous processes from photopolymerization to three-dimensional printing [105, 106]. Multiple studies have demonstrated the ability to seed

mesenchymal cells and growth factors to improve graft integration at the recipient site [107–110]. The opportunity to functionalize polycaprolactone scaffolds largely stems from its porous structure. For these reasons, polycaprolactone has been identified as a viable scaffold option in bone tissue engineering.

### **Ceramics—Bioactive Glass, Hydroxyapatite**

Bioactive glass is an appealing candidate in treating bone defects due to its biocompatibility, strength, and ability to regenerate bone through release of ionic biological stimuli [111]. Pores within the glass also allow for tissue ingrowth and viability [111]. A significant drawback of bioactive glass, however, is its inherent brittleness, making it difficult to handle in implantation [112, 113]. Strategies have been developed to overcome this challenge. For example, coating or combining bioceramic materials such as bioactive glass and hydroxyapatite with a supporting matrix such as poly-L-lactide acid (PLLA) [114], polyethersulfone (PES) [115], poly D,L-lactide-co-glycolide (PLGA) [116], or p(*N*-isopropylacrylamide-co-butyl methacrylate (PIB) [117] improves not only the mechanical properties but the osteogenic potential of such scaffolds as well [115, 118]. Furthermore, the composition of bioactive glass can be altered to a more malleable material, making it easier to manipulate [119].

Another ceramic of interest in tissue engineering is hydroxyapatite (HAp). It is biocompatible, has good osteoconductivity [120], and has been used in bone repair. Similar to bioactive glass, though, it is relatively brittle and is not ideal for bearing weight [121]. However, there are several methods in which the HAp scaffold can be produced to improve the mechanics of these constructs to improve tensile and compressive strength [122, 123]. Interestingly, 3D printing has been utilized to produce HAp scaffolds capable of sustaining cell proliferation deep inside the construct and provides an exciting prospect for the future use of HAp [124].

### **Growth Factors and Cells**

While graft or scaffold material is important to consider, the largest hurdle to bone regeneration is arguably in the challenge of creating a vascularized structure capable of nourishing the surrounding environment and removing wastes. To enhance angiogenesis and bone regeneration, various cell and growth factor combinations have been tested in scaffolds and grafts. Such combinations have largely included VEGF, PDGF, ECs, MSCs, and BMPs. In brief, VEGF functions to regulate angiogenesis and capillary permeability, as well as EC and MSC migration and



proliferation [125, 126]. PDGF recruits fibroblasts and inflammatory cells to sites of injury, induces collagen deposition, and possesses angiogenic potential [127]. ECs are crucial because they form the lumens of blood vessels. MSCs are multipotent cells capable of differentiating into various cells such as osteoblasts, chondrocytes, adipocytes, and muscle cells, but also serve to support neovascularization by acting as mural cells [128]. BMPs function to induce bone formation through the stimulation and differentiation of osteoblasts [129].

## VEGF

VEGF has been a popular candidate in tissue engineering for its angiogenic properties. It is a particularly attractive candidate in bone bioengineering for its additional effects on chondrocytes, osteoblasts, and osteoclasts [56]. VEGF has been shown to mediate chondrocyte and osteoblast survival and differentiation as well as recruit osteoclasts [130]. It has been utilized individually, paired with other growth factors, and has been infected into cells through viral vectors to promote vascularization and bone formation [131]. VEGF appears to function best when used in conjunction with other factors [132–136]. For example, VEGF combined with BMP-7 has been shown to result in earlier osteogenesis, more lamellar and trabecular bone formation, and a higher bone density than the usage of BMP-7 alone [132]. In addition, differences in vascular growth between collagen-coated PLGA scaffolds seeded with either bone marrow MSCs (bmMSCs) or VEGF were minimal, but VEGF and bmMSCs seeded together resulted in continued vascularization 14 days after implantation [133]. Combining multiple cells and growth factors in a scaffold better reflects the composition of the extracellular matrix seen in repairing bone, as the regeneration process naturally requires a multitude of factors and cell interactions.

A hurdle in the application of growth factors for bioengineering techniques is the short half-life or dissipation of growth factors after being implanted into the defect, leading to avascular necrosis or prolonged time of healing [137]. In regard to VEGF, techniques have recently been developed that allow for extended, controlled release. Scaffolds constructed of silk/calcium phosphate/PLGA have been shown capable of releasing PDGF and VEGF at a rate so that bioactivity after 28 days is maintained at 82 and 89 %, respectively [138]. Poldervaart et al. [139] demonstrated that when released from gelatin microparticles in a controlled and prolonged manner in 3D bioprinted scaffolds, VEGF promoted significantly more vascular formation than when released quickly both *in vitro* and *in vivo*. Furthermore, the gelatin microparticles allowed for the creation of heterogeneous constructs, as it was noted

that the microparticles could be administered regionally. A spatiotemporal scaffold construction such as this could be of particular use when considering the potential injurious effects of prolonged action of VEGF. In a nude rat model using genetically modified bmMSCs to express VEGF, Helmrich et al. [140] examined vascular density and bone quantity on osteoconductive material. While VEGF-bmMSCs demonstrated significantly higher vascular density after 8 weeks compared to control bmMSC cells, VEGF expression induced recruitment of osteoclasts and resulted in a reduction in the amount of mature bone. Although VEGF has been supported as a critical player in induction of vascularization and bone formation, overexpression or prolonged expression can lead to deleterious consequences through activation of osteoclasts or increased vascular permeability.

## PDGF

PDGF is a critical element of wound healing and has been shown to promote angiogenesis [141–144] as well as increase wound neovascularization and granulation tissue formation [145–147], early elements of the wound-healing process. PDGF and VEGF are closely related, and VEGF can signal through PDGF receptors to regulate MSC migration and proliferation [148]. In the aspect of bone bioengineering, delivering PDGF on collagen-based demineralized bone matrix scaffolds through the cross-linking of heparin enhances and prolongs its local activity, and it increases both the cellularization and vascularization of the scaffold [149]. It also has been shown to increase the amount of collagen present in bony defects [150]. PDGF's roles in angiogenesis and cellular migration and proliferation, as well as its role in conjunction with VEGF, makes it an enticing candidate in tissue engineering.

## BMPs

Recombinant human BMPs (rhBMPs) 2 and 7 have been approved by the FDA for the treatment for open tibial fractures with intramedullary fixation and tibia long bone nonunion [151]. Acknowledged for their ability to induce osteoblast proliferation and differentiation, BMPs are popular choices in graft and scaffold use to increase rates to union [151]. However, usage of BMPs has been known to carry significant side effects likely due to the high dosage required, including swelling, inflammation, heterotopic bone formation, and most significantly, an increased cancer risk [152, 153].

In addition to their osteogenic potential, BMPs have been shown to increase vascularization in scaffolds as well. Zhang et al. [154] demonstrated BMP-producing bone marrow stromal cells have the potential to increase graft



incorporation and vascularization. In a cuttlefish bone scaffold soaked in BMP-2, Liu et al. [155] demonstrated that cuttlefish bone–BMP composite displays more microvasculature and bone trabeculae in rat skull defects than a scaffold of cuttlefish bone alone. The sustained release of BMP-2 seeded on 2-N,6-*O*-sulfated chitosan nanoparticles on a gelatin sponge induces bridging of segmental defects and a dose-dependent increase in angiogenesis in rabbit radius [156].

### MSCs and ECs

Timing of administration of factors is important to consider when evaluating the angiogenic and osteogenic potential of a scaffold or graft, as bone regeneration is tightly regulated both temporally and spatially. MSCs can be used as a sole cell source to enhance osteogenicity in critical size bone defects [157]; however, they can also be co-transplanted with ECs. Co-transplantation of endothelial progenitor cells and MSCs increases blood vessel formation early in the healing process after 1 month and bone formation in later stages after 3 months [135]. Alternative to co-transplanting ECs and MSCs together, McFadden et al. [158] found that vascularization of a collagen-glycosaminoglycan scaffold occurs best when MSCs are added to preformed endothelial networks, as the MSCs can act as pericytes to the newly formed blood vessels. Pirraco et al. [159] also cultured ECs and subsequently added them to osteogenic cell sheets and found that this technique improves *in vivo* bone and vessel formation. Although MSCs and ECs cultured together provide the appropriate stimulus for vascularization and bone regeneration, MSCs are often derived from bone marrow. A challenge of utilizing bmMSCs lies in the requirement of invasive procedures to harvest the cells, as well as the limited quality of cells that are able to be obtained. It is therefore important to consider other sources. Human umbilical cord MSCs, human embryonic stem cells, and induced pluripotent stem cells have been evaluated as potential alternatives to human bmMSCs, and these alternatives have been shown capable of blood vessel and bone generation comparable to human bmMSCs [160]. These different sources of MSCs provide a potential effective and more cost-effective approach to tissue engineering.

### Scaffold Vascularization Techniques

In addressing the issue of vascularization in a bony defect, one of two broad approaches can be taken. Attempts at vascularization can be done prior to placing the scaffold or graft, or the scaffold or graft can be seeded with proangiogenic factors and implanted as previously discussed.

Prevascularization includes harvesting vascular bundles for the defect [161–165] or vascularizing sheets of cells prior to insertion [158, 166]. Saphenous vascular bundle constructs have shown promise in both large and small animal models, resulting in higher vascularization and osteogenesis [161, 162]. Contrary to transplanting preformed vessels, prevascularization on a smaller level with sheets of vascularized cells can be done. In an effort to construct a biomimetic periosteum prior to insertion, Kang et al. [166] created a vascularized cell-sheet-engineered periosteum by culturing human MSCs (hMSCs) and subsequently adding human umbilical vascular endothelial cells (HUVECs) to mimic the fibrous layer of the periosteum. A sheet of mineralized hMSCs designed to mimic the cambium layer was wrapped around a  $\beta$ -TCP scaffold followed by the vascularized HUVEC/hMSC sheet. The biomimetic scaffold resulted in enhanced angiogenesis that anastomosed with host vessels and increased bone matrix production [166]. While the use of both preformed vessels and proangiogenic factors shows promise, more research is needed to determine the efficacy among the different strategies.

Another emerging approach is stimulation of vasculogenesis through endothelial progenitor cell delivery. While typically considered important primarily during development, vasculogenesis, the process of *de novo* neovessel formation from progenitor cells, may also show promise as a therapeutic strategy for postnatal vascular growth. The identification of circulating endothelial progenitor cells [167], now termed endothelial colony-forming cells (ECFCs) or late-outgrowth endothelial cells (OECs) [168, 169], suggests that vasculogenesis may also be active during postnatal neovascularization. Importantly, this developmental process can be replicated postnatally by transplanted ECFCs, which participate in functional neovascular plexus formation and therefore may carry potential for therapeutic vasculogenesis. Both rat and human ECFCs have been shown to undergo vasculogenesis in bone tissue engineering constructs and enhance bone formation *in vivo* [170, 171].

### Mechanical Regulation of Vascularized Bone Regeneration

In addition to biochemical cues, stem cell lineage specification and neovascularization are also regulated by mechanical stimuli. These mechanical cues can be characterized as either intrinsic (i.e., mechanical properties of the extracellular matrix or scaffold) or extrinsic (i.e., mechanical stimuli applied through either static or dynamic boundary conditions). Intrinsic cues such as matrix rigidity have been shown to control stem cell fate decisions

independent of biochemical signals, with soft substrates promoting adipogenic and chondrogenic differentiation of MSCs and stiff substrates driving osteogenesis [172]. Recently, Mooney and colleagues demonstrated that in addition to the elastic properties, the viscoelastic (time-dependent) properties of the extracellular matrix can also regulate stem cell fate, with stress-relaxing substrates enabling osteogenesis in spite of initially soft elastic moduli [173]. While these observations have been primarily investigated in 2D culture systems, extension of these principles to 3D hydrogels and scaffolds will provide important design constraints in the development of next-generation tissue engineering constructs.

In addition to stem cell differentiation, intrinsic matrix cues have also been shown to influence neovascularization. Early studies controlled matrix rigidity by increasing the ECM concentration [174, 175] or by mixing in additional molecules like collagen to soft matrices such as matrigel [176, 177]. However, driven by the observations that increased or different ligand presentation has the potential to influence cell behavior independent of stiffness, recent studies have developed matrices of variable rigidity that maintain constant ligand identity and density. Several different approaches have been described, including tunable cross-linking polyethylene glycol (PEG) hydrogels [178, 179] and alginate hydrogels [180], which can be modified to control ligand presentation. Other recent studies have explored matrix rigidity control through differential cross-linking of natural ECM materials such as collagen. One such approach is methacrylated gelatin, which features controllable photocross-linking by ultraviolet (UV) light [181]. Another is nonenzymatic glycation [182–184], in which reducing sugars are used to create advanced glycation end products (AGE) on collagen fibers, resulting in cross-link formation [184]. Others have exploited the natural collagen fiber cross-linking that occurs *in vivo* to form matrices of variable rigidity at constant collagen concentration by missing collagen monomers and oligomers, formed through native *in vivo* cross-links [74]. Each of these approaches has demonstrated profound effects of matrix physical properties on neovascular growth and remodeling, and may have important implications for biomaterial scaffold design.

Bone has long been known to respond to extrinsic mechanical stimuli caused by physiological mechanical loading [185], but more recent studies have demonstrated that these mechanical cues also dramatically regulate fracture healing [186] and direct tissue differentiation [187, 188]. These observations have significantly influenced clinical practices for fracture fixation and postoperative management, and emerging understanding of the mechanobiological principles that underlie these responses will further enable tissue engineers to develop viable bone

graft substitutes *in vitro* through bioreactor culture [189, 190] or enhance large bone defect regeneration *in vivo* [191–194]. For example, control of *in vivo* mechanical loading through modulation of fixation plate stiffness can either enhance or prevent bone regeneration depending on load timing and magnitude [192–194].

Extrinsic mechanical stimuli have also been shown to regulate neovascularization [195, 196] and vascularized bone regeneration [192]. Extrinsic cues that have been shown to influence neovascular growth and remodeling include blood flow-induced luminal shear stress [196–198], luminal pressure-induced circumferential stretch [199], tensile matrix stretch [195, 200], and tissue compression [192].

Collectively, these observations may have important implications for the development of novel vascularized tissue engineering strategies. Ongoing research on the role of both intrinsic and extrinsic mechanical cues for large bone defect regeneration will continue to inform biomaterial scaffold and fixation plate design and physical rehabilitation strategies. Important questions regarding underlying molecular mechanisms and interactions with the biochemical cues described above will continue to be explored.

## Conclusion

Bone grafting has served a crucial role in the repair of segmental bone defects for centuries. Pioneers in the field of bone grafting recognized the importance of allografts and autografts, including the benefits and limitations of each. Allografts were very commonly used; however, over time, there was a transition to more commonly using autografts as techniques for harvesting the graft improved. Autografts have proved quite successful but not without their own limitations, including donor site morbidity. Due to the limitations of allografts and autografts and the advancement of biomechanical research, emphasis has been placed on developing artificial scaffolds with optimum osteoinductive, osteointegrative, osteoconductive, and angiogenic properties.

Many growth factors and cells have been studied for their various properties in combination with scaffolds. These compounds and cells include: VEGF, PDGF, BMPs, ECs, and MSCs. Novel research has suggested these compounds and cells provide promising opportunities for the development of optimal materials for bone grafting that allows for vascular and regenerative potential. With the materials, growth factors, and cells available for biomechanical research, the potential for bone graft and scaffold development is endless. Taken together, these studies demonstrate opportunities that lie ahead to improve patient outcomes after a bone graft procedure.

**Acknowledgments** This work was supported in part by the Medical Student Affairs Summer Research Program in Academic Medicine, Indiana University School of Medicine, funded in part by NIH Grant HL110854 (KMD) and the Department of Orthopaedic Surgery, Indiana University School of Medicine (MAK, TOM, JOA). In addition, research reported in this publication was supported in part by the following Grants: NIH NIAMS R01 AR060863 (MAK), USAMRMC OR120080 (MAK, T-MGC, TOM, JOA), an Indiana University Health Values Grant (MAK), Indiana Clinical and Translational Sciences Institute Grants partially supported by NIH UL1TR001108 (MAK, T-MGC, JDB), Indiana Advanced Diagnostics and Therapeutics Initiative (JDB), and an Indiana University Collaborative Research Grant (MAK, T-MGC). The content of this manuscript is solely the responsibility of the authors and does not necessarily represent the official views of the NIH. The opinions or assertions contained herein are the private views of the authors and are not to be construed as official or as reflecting the views of the Department of the Army or the Department of Defense.

### Compliance with Ethical Standards

**Conflict of interest** Kaitlyn S. Griffin, Korbin M. Davis, Jeffrey O. Anglen, Tien-Min G. Chu, Joel D. Boerckel, and Melissa A. Kacena declare they have no conflict of interest. Todd O. McKinley is a consultant for Bioventus.

**Animal/Human Studies** This article does not include any studies with human or animal subjects performed by the author.

### References

- Donati D, Zolezzi C, Tomba P, Vigano A. Bone grafting: historical and conceptual review, starting with an old manuscript by Vittorio Putti. *Acta Orthop*. 2007;78(1):19–25.
- de Boer HH. The history of bone grafts. *Clin Orthop Relat Res*. 1988;226:292–8.
- Ng VY. Risk of disease transmission with bone allograft. *Orthopedics*. 2012;35(8):679–81.
- Kinaci A, Neuhaus V, Ring DC. Trends in bone graft use in the United States. *Orthopedics*. 2014;37(9):e783–8.
- Campbell W. Transference of the fibula as an adjunct to a free bone graft. *J Orthop Surg*. 1919;1:625–31.
- Stone JS. Partial loss of the tibia replaced by transfer of the fibula, with maintenance of both malleoli of the ankle. *Ann Surg*. 1907;46(4):628–34.
- Flierl MA, Smith WR, Mauffrey C, Irgit K, Williams AE, Ross E, et al. Outcomes and complication rates of different bone grafting modalities in long bone fracture nonunions: a retrospective cohort study in 182 patients. *J Orthop Surg Res*. 2013;8:33.
- Shafiei Z, Bigham AS, Dehghani SN, Nezhad ST. Fresh cortical autograft versus fresh cortical allograft effects on experimental bone healing in rabbits: radiological, histopathological and biomechanical evaluation. *Cell Tissue Bank*. 2009;10(1):19–26.
- Kienapfel H, Sumner DR, Turner TM, Urban RM, Galante JO. Efficacy of autograft and freeze-dried allograft to enhance fixation of porous coated implants in the presence of interface gaps. *J Orthop Res*. 1992;10(3):423–33.
- Johnson AL, Stein LE. Morphologic comparison of healing patterns in ethylene oxide-sterilized cortical allografts and untreated cortical autografts in the dog. *Am J Vet Res*. 1988;49(1):101–5.
- Gross TP, Jinnah RH, Clarke HJ, Cox QG. The biology of bone grafting. *Orthopedics*. 1991;14(5):563–8.
- Goldberg VM, Stevenson S. Natural history of autografts and allografts. *Clin Orthop Relat Res*. 1987;225:7–16.
- Friedlaender GE. Bone grafts. The basic science rationale for clinical applications. *J Bone Joint Surg Am*. 1987;69(5):786–90.
- Burchardt H. Biology of bone transplantation. *Orthop Clin North Am*. 1987;18(2):187–96.
- Blokhuis TJ, Lindner T. Allograft and bone morphogenetic proteins: an overview. *Injury*. 2008;39(Suppl 2):S33–6.
- Giannoudis PV, Kanakaris NK, Dimitriou R, Gill I, Kolimarala V, Montgomery RJ. The synergistic effect of autograft and BMP-7 in the treatment of atrophic nonunions. *Clin Orthop Relat Res*. 2009;467(12):3239–48.
- Breitbart EA, Meade S, Azad V, Yeh S, Al-Zube L, Lee YS, et al. Mesenchymal stem cells accelerate bone allograft incorporation in the presence of diabetes mellitus. *J Orthop Res*. 2010;28(7):942–9.
- Pernaa K, Koski I, Mattila K, Gullichsen E, Heikkilä J, Aho A, et al. Bioactive glass S53P4 and autograft bone in treatment of depressed tibial plateau fractures—a prospective randomized 11-year follow-up. *J Long Term Eff Med Implants*. 2011;21(2):139–48.
- Wei LC, Lei GH, Sheng PY, Gao SG, Xu M, Jiang W, et al. Efficacy of platelet-rich plasma combined with allograft bone in the management of displaced intra-articular calcaneal fractures: a prospective cohort study. *J Orthop Res*. 2012;30(10):1570–6.
- Bosemark P, Isaksson H, McDonald MM, Little DG, Tagil M. Augmentation of autologous bone graft by a combination of bone morphogenic protein and bisphosphonate increased both callus volume and strength. *Acta Orthop*. 2013;84(1):106–11.
- Giannoudis PV, Dinopoulos HT. BMPs: Options, indications, and effectiveness. *J Orthop Trauma*. 2010;24(Suppl 1):S9–16.
- Kanakaris NK, Paliobeis C, Nlanidakis N, Giannoudis PV. Biological enhancement of tibial diaphyseal aseptic non-unions: the efficacy of autologous bone grafting, BMPs and reaming by-products. *Injury*. 2007;38(Suppl 2):S65–75.
- Sen MK, Miclau T. Autologous iliac crest bone graft: should it still be the gold standard for treating nonunions? *Injury*. 2007;38(Suppl 1):S75–80.
- Mathavan N, Bosemark P, Isaksson H, Tagil M. Investigating the synergistic efficacy of BMP-7 and zoledronate on bone allografts using an open rat osteotomy model. *Bone*. 2013;56(2):440–8.
- Lysaght MJ, Jaklenec A, Deweerd E. Great expectations: private sector activity in tissue engineering, regenerative medicine, and stem cell therapeutics. *Tissue Eng Part A*. 2008;14(2):305–15.
- Albrektsson T, Johansson C. Osteoinduction, osteoconduction and osseointegration. *Eur Spine J*. 2001;10(Suppl 2):S96–101.
- Miron RJ, Zhang YF. Osteoinduction: a review of old concepts with new standards. *J Dent Res*. 2012;91(8):736–44.
- Giannoudis PV, Dinopoulos H, Tsiridis E. Bone substitutes: an update. *Injury*. 2005;36(Suppl 3):S20–7.
- Gebhardt MC, Flugstad DI, Springfield DS, Mankin HJ. The use of bone allografts for limb salvage in high-grade extremity osteosarcoma. *Clin Orthop Relat Res*. 1991;270:181–96.
- Mankin HJ, Fogelson FS, Thrasher AZ, Jaffer F. Massive resection and allograft transplantation in the treatment of malignant bone tumors. *N Engl J Med*. 1976;294(23):1247–55.
- Burchardt H, Busbee GA 3rd, Enneking WF. Repair of experimental autologous grafts of cortical bone. *J Bone Joint Surg Am*. 1975;57(6):814–9.
- Mohler DG, Yaszay B, Hong R, Wera G. Intercalary tibial allografts following tumor resection: the role of fibular centralization. *Orthopedics*. 2003;26(6):631–7.
- Allan DG, Lavoie GJ, McDonald S, Oakeshott R, Gross AE. Proximal femoral allografts in revision hip arthroplasty. *J Bone Joint Surg Br*. 1991;73(2):235–40.
- Bos GD, Goldberg VM, Powell AE, Heiple KG, Zika JM. The effect of histocompatibility matching on canine frozen bone allografts. *J Bone Joint Surg Am*. 1983;65(1):89–96.

35. Horowitz MC, Friedlaender GE. Immunologic aspects of bone transplantation. A rationale for future studies. *Orthop Clin North Am.* 1987;18(2):227–33.
36. Stevenson S, Emery SE, Goldberg VM. Factors affecting bone graft incorporation. *Clin Orthop Relat Res.* 1996;324:66–74.
37. Strong DM, Friedlaender GE, Tomford WW, Springfield DS, Shives TC, Burchardt H, et al. Immunologic responses in human recipients of osseous and osteochondral allografts. *Clin Orthop Relat Res.* 1996;326:107–14.
38. Ward WG, Heise E, Boles C, Kiger D, Gautreaux M, Rushing J, et al. Human leukocyte antigen sensitization after structural cortical allograft implantations. *Clin Orthop Relat Res.* 2005;435:31–5.
39. Gornet MF, Randolph MA, Schofield BH, Yaremchuk MJ, Weiland AJ. Immunologic and ultrastructural changes during early rejection of vascularized bone allografts. *Plast Reconstr Surg.* 1991;88(5):860–8.
40. Moore JR, Phillips TW, Weiland AJ, Randolph MA. Allogenic transplants of bone revascularized by microvascular anastomoses: a preliminary study. *J Orthop Res.* 1984;1(4):352–60.
41. Paskert JP, Yaremchuk MJ, Randolph MA, Weiland AJ. The role of cyclosporin in prolonging survival in vascularized bone allografts. *Plast Reconstr Surg.* 1987;80(2):240–7.
42. Shigetomi M, Doi K, Kuwata N, Muramatsu K, Yamamoto H, Kawai S. Experimental study on vascularized bone allografts for reconstruction of massive bone defects. *Microsurgery.* 1994;15(9):663–70.
43. Yaremchuk MJ, Nettelblad H, Randolph MA, Weiland AJ. Vascularized bone allograft transplantation in a genetically defined rat model. *Plast Reconstr Surg.* 1985;75(3):355–62.
44. Stevenson S, Shaffer JW, Goldberg VM. The humoral response to vascular and nonvascular allografts of bone. *Clin Orthop Relat Res.* 1996;326:86–95.
45. DePaula CA, Truncala KG, Gertzman AA, Sunwoo MH, Dunn MG. Effects of hydrogen peroxide cleaning procedures on bone graft osteoinductivity and mechanical properties. *Cell Tissue Bank.* 2005;6(4):287–98.
46. Beebe KS, Benevenia J, Tuy BE, DePaula CA, Harten RD, Enneking WF. Effects of a new allograft processing procedure on graft healing in a canine model: a preliminary study. *Clin Orthop Relat Res.* 2009;467(1):273–80.
47. Hornicek FJ, Gebhardt MC, Tomford WW, Sorger JI, Zavatta M, Menzner JP, et al. Factors affecting nonunion of the allograft-host junction. *Clin Orthop Relat Res.* 2001;382:87–98.
48. Sorger JI, Hornicek FJ, Zavatta M, Menzner JP, Gebhardt MC, Tomford WW, et al. Allograft fractures revisited. *Clin Orthop Relat Res.* 2001;382:66–74.
49. Mankin HJ, Hornicek FJ, Raskin KA. Infection in massive bone allografts. *Clin Orthop Relat Res.* 2005;432:210–6.
50. Dick HM, Strauch RJ. Infection of massive bone allografts. *Clin Orthop Relat Res.* 1994;306:46–53.
51. Myeroff C, Archdeacon M. Autogenous bone graft: donor sites and techniques. *J Bone Joint Surg Am.* 2011;93(23):2227–36.
52. Cypher TJ, Grossman JP. Biological principles of bone graft healing. *J Foot Ankle Surg.* 1996;35(5):413–7.
53. Triplett RG, Schow SR. Autologous bone grafts and endosseous implants: complementary techniques. *J Oral Maxillofac Surg.* 1996;54(4):486–94.
54. Lu C, Marcucio R, Miclau T. Assessing angiogenesis during fracture healing. *Iowa Orthop J.* 2006;26:17–26.
55. Carano RA, Filvaroff EH. Angiogenesis and bone repair. *Drug Discov Today.* 2003;8(21):980–9.
56. Street J, Bao M, deGuzman L, Bunting S, Peale FV Jr, Ferrara N, et al. Vascular endothelial growth factor stimulates bone repair by promoting angiogenesis and bone turnover. *Proc Natl Acad Sci USA.* 2002;99(15):9656–61.
57. Yin G, Sheu TJ, Menon P, Pang J, Ho HC, Shi S, et al. Impaired angiogenesis during fracture healing in GPCR kinase 2 interacting protein-1 (GIT1) knock out mice. *PLoS ONE.* 2014;9(2):e89127.
58. Tete S, Vinci R, Zara S, Zizzari V, De Carlo A, Falco G, et al. Long-term evaluation of maxillary reconstruction by iliac bone graft. *J Craniofac Surg.* 2011;22(5):1702–7.
59. Faria PE, Okamoto R, Bonilha-Neto RM, Xavier SP, Santos AC, Salata LA. Immunohistochemical, tomographic and histological study on onlay iliac grafts remodeling. *Clin Oral Implants Res.* 2008;19(4):393–401.
60. Khan SN, Cammisa FP Jr, Sandhu HS, Diwan AD, Girardi FP, Lane JM. The biology of bone grafting. *J Am Acad Orthop Surg.* 2005;13(1):77–86.
61. Arrington ED, Smith WJ, Chambers HG, Bucknell AL, Davino NA. Complications of iliac crest bone graft harvesting. *Clin Orthop Relat Res.* 1996;329:300–9.
62. Summers BN, Eisenstein SM. Donor site pain from the ilium. A complication of lumbar spine fusion. *J Bone Joint Surg Br.* 1989;71(4):677–80.
63. Ross N, Tacconi L, Miles JB. Heterotopic bone formation causing recurrent donor site pain following iliac crest bone harvesting. *Br J Neurosurg.* 2000;14(5):476–9.
64. Seiler JG 3rd, Johnson J. Iliac crest autogenous bone grafting: donor site complications. *J South Orthop Assoc.* 2000;9(2):91–7.
65. Banwart JC, Asher MA, Hassanein RS. Iliac crest bone graft harvest donor site morbidity. A statistical evaluation. *Spine (Phila Pa 1976).* 1995;20(9):1055–60.
66. Yazar S, Lin CH, Wei FC. One-stage reconstruction of composite bone and soft-tissue defects in traumatic lower extremities. *Plast Reconstr Surg.* 2004;114(6):1457–66.
67. Younger EM, Chapman MW. Morbidity at bone graft donor sites. *J Orthop Trauma.* 1989;3(3):192–5.
68. Goulet JA, Senunas LE, DeSilva GL, Greenfield ML. Autogenous iliac crest bone graft. Complications and functional assessment. *Clin Orthop Relat Res.* 1997;339:76–81.
69. Langer R, Vacanti JP. Tissue engineering. *Science.* 1993;260(5110):920–6.
70. Ma PX, Zhang R, Xiao G, Franceschi R. Engineering new bone tissue in vitro on highly porous poly(alpha-hydroxyl acids)/hydroxyapatite composite scaffolds. *J Biomed Mater Res.* 2001;54(2):284–93.
71. Pangborn CA, Athanasiou KA. Growth factors and fibrochondrocytes in scaffolds. *J Orthop Res.* 2005;23(5):1184–90.
72. Glowacki J, Mizuno S. Collagen scaffolds for tissue engineering. *Biopolymers.* 2008;89(5):338–44.
73. O'Brien FJ. Biomaterials & scaffolds for tissue engineering. *Mater Today.* 2011;14(3):88–95.
74. Bailey JL, Critser PJ, Whittington C, Kuske JL, Yoder MC, Voytik-Harbin SL. Collagen oligomers modulate physical and biological properties of three-dimensional self-assembled matrices. *Biopolymers.* 2011;95(2):77–93.
75. Haugh MG, Jaasma MJ, O'Brien FJ. The effect of dehydrothermal treatment on the mechanical and structural properties of collagen-GAG scaffolds. *J Biomed Mater Res A.* 2009;89(2):363–9.
76. Tierney CM, Haugh MG, Liedl J, Mulcahy F, Hayes B, O'Brien FJ. The effects of collagen concentration and crosslink density on the biological, structural and mechanical properties of collagen-GAG scaffolds for bone tissue engineering. *J Mech Behav Biomed Mater.* 2009;2(2):202–9.
77. Tierney CM, Jaasma MJ, O'Brien FJ. Osteoblast activity on collagen-GAG scaffolds is affected by collagen and GAG concentrations. *J Biomed Mater Res A.* 2009;91(1):92–101.

78. Sun J, Tan H. Alginate-based biomaterials for regenerative medicine applications. *Materials*. 2013;6(4):1285–309.
79. Alsberg E, Anderson KW, Albeiruti A, Franceschi RT, Mooney DJ. Cell-interactive alginate hydrogels for bone tissue engineering. *J Dent Res*. 2001;80(11):2025–9.
80. Quinlan E, López-Noriega A, Thompson EM, Hibbitts A, Cryan SA, O'Brien FJ. Controlled release of vascular endothelial growth factor from spray-dried alginate microparticles in collagen-hydroxyapatite scaffolds for promoting vascularization and bone repair. *J Tissue Eng Regen Med*. 2015. doi:10.1002/term.2013.
81. Bouhadir KH, Mooney D. Synthesis of hydrogels: alginate hydrogels. In: Atala A, Lanza RP, editors. *Methods of tissue engineering*. New York: Academic Press; 2002. p. 653–62.
82. Li Z, Ramay HR, Hauch KD, Xiao D, Zhang M. Chitosan-alginate hybrid scaffolds for bone tissue engineering. *Biomaterials*. 2005;26(18):3919–28.
83. Turco G, Marsich E, Bellomo F, Semeraro S, Donati I, Brun F, et al. Alginate/Hydroxyapatite biocomposite for bone ingrowth: a trabecular structure with high and isotropic connectivity. *Biomacromolecules*. 2009;10(6):1575–83.
84. Nguyen TP, Lee BT. Fabrication of oxidized alginate-gelatin-BCP hydrogels and evaluation of the microstructure, material properties and biocompatibility for bone tissue regeneration. *J Biomater Appl*. 2012;27(3):311–21.
85. He X, Dziak R, Mao K, Genco R, Swihart M, Li C, et al. Integration of a novel injectable nano calcium sulfate/alginate scaffold and BMP2 gene-modified mesenchymal stem cells for bone regeneration. *Tissue Eng Part A*. 2013;19(3–4):508–18.
86. De la Riva B, Nowak C, Sanchez E, Hernandez A, Schulz-Siegmund M, Pec MK, et al. VEGF-controlled release within a bone defect from alginate/chitosan/PLA-H scaffolds. *Eur J Pharm Biopharm*. 2009;73(1):50–8.
87. Yang C, Frei H, Rossi FM, Burt HM. The differential in vitro and in vivo responses of bone marrow stromal cells on novel porous gelatin-alginate scaffolds. *J Tissue Eng Regen Med*. 2009;3(8):601–14.
88. Kolambkar YM, Dupont KM, Boerckel JD, Huebsch N, Mooney DJ, Hutmacher DW, et al. An alginate-based hybrid system for growth factor delivery in the functional repair of large bone defects. *Biomaterials*. 2011;32(1):65–74.
89. Boerckel JD, Kolambkar YM, Dupont KM, Uhrig BA, Phelps EA, Stevens HY, et al. Effects of protein dose and delivery system on BMP-mediated bone regeneration. *Biomaterials*. 2011;32(22):5241–51.
90. Freeman I, Cohen S. The influence of the sequential delivery of angiogenic factors from affinity-binding alginate scaffolds on vascularization. *Biomaterials*. 2009;30(11):2122–31.
91. Jeon O, Powell C, Solorio LD, Krebs MD, Alsberg E. Affinity-based growth factor delivery using biodegradable, photocrosslinked heparin-alginate hydrogels. *J Control Release*. 2011;154(3):258–66.
92. Swann DA, Radin EL. The molecular basis of articular lubrication. I. Purification and properties of a lubricating fraction from bovine synovial fluid. *J Biol Chem*. 1972;247(24):8069–73.
93. Swann DA, Radin EL, Nazimiec M, Weisser PA, Curran N, Lewinnek G. Role of hyaluronic acid in joint lubrication. *Ann Rheum Dis*. 1974;33(4):318–26.
94. de Brito Bezerra B, Mendes Brazao MA, de Campos ML, Casati MZ, Sallum EA, Sallum AW. Association of hyaluronic acid with a collagen scaffold may improve bone healing in critical-size bone defects. *Clin Oral Implants Res*. 2012;3(8):938–42.
95. Mathews S, Bhonde R, Gupta PK, Totey S. Novel biomimetic tripolymer scaffolds consisting of chitosan, collagen type I, and hyaluronic acid for bone marrow-derived human mesenchymal stem cells-based bone tissue engineering. *J Biomed Mater Res B Appl Biomater*. 2014;102(8):1825–34.
96. Nguyen TB, Lee BT. A combination of biphasic calcium phosphate scaffold with hyaluronic acid-gelatin hydrogel as a new tool for bone regeneration. *Tissue Eng Part A*. 2014;20(13–14):1993–2004.
97. Kang SW, Kim JS, Park KS, Cha BH, Shim JH, Kim JY, et al. Surface modification with fibrin/hyaluronic acid hydrogel on solid-free form-based scaffolds followed by BMP-2 loading to enhance bone regeneration. *Bone*. 2011;48(2):298–306.
98. Smith JD, Melhem ME, Magge KT, Waggoner AS, Campbell PG. Improved growth factor directed vascularization into fibrin constructs through inclusion of additional extracellular molecules. *Microvasc Res*. 2007;73(2):84–94.
99. Yee D, Hanjaya-Putra D, Bose V, Luong E, Gerecht S. Hyaluronic Acid hydrogels support cord-like structures from endothelial colony-forming cells. *Tissue Eng Part A*. 2011;17(9–10):1351–61.
100. Hern DL, Hubbell JA. Incorporation of adhesion peptides into nonadhesive hydrogels useful for tissue resurfacing. *J Biomed Mater Res*. 1998;39(2):266–76.
101. Shekaran A, Garcia JR, Clark AY, Kavanaugh TE, Lin AS, Guldberg RE, et al. Bone regeneration using an alpha 2 beta 1 integrin-specific hydrogel as a BMP-2 delivery vehicle. *Biomaterials*. 2014;35(21):5453–61.
102. Pratt AB, Weber FE, Schmoekel HG, Muller R, Hubbell JA. Synthetic extracellular matrices for in situ tissue engineering. *Biotechnol Bioeng*. 2004;86(1):27–36.
103. Rizzi SC, Ehrbar M, Halstenberg S, Raeber GP, Schmoekel HG, Hagenmuller H, et al. Recombinant protein-co-PEG networks as cell-adhesive and proteolytically degradable hydrogel matrixes. Part II: biofunctional characteristics. *Biomacromolecules*. 2006;7(11):3019–29.
104. Francis GE, Fisher D, Delgado C, Malik F, Gardiner A, Neale D. PEGylation of cytokines and other therapeutic proteins and peptides: the importance of biological optimisation of coupling techniques. *Int J Hematol*. 1998;68(1):1–18.
105. Cipitria A, Reichert JC, Epari DR, Saifzadeh S, Berner A, Schell H, et al. Polycaprolactone scaffold and reduced rhBMP-7 dose for the regeneration of critical-sized defects in sheep tibiae. *Biomaterials*. 2013;34(38):9960–8.
106. Ekaputra AK, Prestwich GD, Cool SM, Hutmacher DW. The three-dimensional vascularization of growth factor-releasing hybrid scaffold of poly (epsilon-caprolactone)/collagen fibers and hyaluronic acid hydrogel. *Biomaterials*. 2011;32(32):8108–17.
107. Kamath MS, Ahmed SS, Dhanasekaran M, Santosh SW. Polycaprolactone scaffold engineered for sustained release of resveratrol: therapeutic enhancement in bone tissue engineering. *Int J Nanomed*. 2014;9:183–95.
108. Mitsak AG, Kemppainen JM, Harris MT, Hollister SJ. Effect of polycaprolactone scaffold permeability on bone regeneration in vivo. *Tissue Eng Part A*. 2011;17(13–14):1831–9.
109. Rai B, Oest ME, Dupont KM, Ho KH, Teoh SH, Guldberg RE. Combination of platelet-rich plasma with polycaprolactone-tricalcium phosphate scaffolds for segmental bone defect repair. *J Biomed Mater Res A*. 2007;81(4):888–99.
110. Kyriakidou K, Lucarini G, Zizzi A, Salvolini E, Mattioli Belmonte M, Mollica F, et al. Dynamic co-seeding of osteoblast and endothelial cells on 3D polycaprolactone scaffolds for enhanced bone tissue engineering. *J Bioact Compat Polym*. 2008;23(3):227–43.
111. Jones JR, Hench LL. Factors affecting the structure and properties of bioactive foam scaffolds for tissue engineering. *J Biomed Mater Res B Appl Biomater*. 2004;68(1):36–44.
112. Yun HS, Kim SE, Hyun YT, Heo SJ, Shin JW. Hierarchically mesoporous-macroporous bioactive glasses scaffolds for bone tissue regeneration. *J Biomed Mater Res B Appl Biomater*. 2008;87(2):374–80.



113. Wu C, Luo Y, Cuniberti G, Xiao Y, Gelinsky M. Three-dimensional printing of hierarchical and tough mesoporous bioactive glass scaffolds with a controllable pore architecture, excellent mechanical strength and mineralization ability. *Acta Biomater*. 2011;7(6):2644–50.
114. Seyedjafari E, Soleimani M, Ghaemi N, Shabani I. Nanohydroxyapatite-coated electrospun poly(L-lactide) nanofibers enhance osteogenic differentiation of stem cells and induce ectopic bone formation. *Biomacromolecules*. 2010;11(11):3118–25.
115. Ardeshtyrlajimi A, Farhadian S, Jamshidi Adegani F, Mirzaei S, Soufi Zomorrod M, Langroudi L, et al. Enhanced osteoconductivity of polyethersulphone nanofibres loaded with bioactive glass nanoparticles in in vitro and in vivo models. *Cell Prolif*. 2015;48(4):455–64.
116. Chen S, Jian Z, Huang L, Xu W, Liu S, Song D, et al. Mesoporous bioactive glass surface modified poly(lactic-co-glycolic acid) electrospun fibrous scaffold for bone regeneration. *Int J Nanomed*. 2015;10:3815–27.
117. Chen X, Zhao Y, Geng S, Miron RJ, Zhang Q, Wu C, et al. In vivo experimental study on bone regeneration in critical bone defects using PIB nanogels/boron-containing mesoporous bioactive glass composite scaffold. *Int J Nanomed*. 2015;10:839–46.
118. Ardeshtyrlajimi A, Hosseinkhani S, Parivar K, Yaghmaie P, Soleimani M. Nanofiber-based polyethersulfone scaffold and efficient differentiation of human induced pluripotent stem cells into osteoblastic lineage. *Mol Biol Rep*. 2013;40(7):4287–94.
119. Gabbai-Armelin PR, Souza MT, Kido HW, Tim CR, Bossini PS, Magri AM, et al. Effect of a new bioactive fibrous glassy scaffold on bone repair. *J Mater Sci Mater Med*. 2015;26(5):177.
120. Kim BS, Kang HJ, Yang SS, Lee J. Comparison of in vitro and in vivo bioactivity: cuttlefish-bone-derived hydroxyapatite and synthetic hydroxyapatite granules as a bone graft substitute. *Biomed Mater*. 2014;9(2):025004.
121. Cardoso GB, Maniglio D, Volpato FZ, Tondon A, Migliaresi C, Kaunas RR, et al. Oleic acid surfactant in polycaprolactone/hydroxyapatite-composites for bone tissue engineering. *J Biomed Mater Res B Appl Biomater*. 2015. doi:10.1002/jbm.b.33457.
122. Tanner KE. Bioactive ceramic-reinforced composites for bone augmentation. *J R Soc Interface*. 2010;7(Suppl 5):S541–57.
123. Feng P, Niu M, Gao C, Peng S, Shuai C. A novel two-step sintering for nano-hydroxyapatite scaffolds for bone tissue engineering. *Sci Rep*. 2014;4:5599.
124. Leukers B, Gulkan H, Irsen SH, Milz S, Tille C, Schieker M, et al. Hydroxyapatite scaffolds for bone tissue engineering made by 3D printing. *J Mater Sci Mater Med*. 2005;16(12):1121–4.
125. Di Alberti L, Rossetto A, Albanese M, D'Agostino A, De Santis D, Bertossi D, et al. Expression of Vascular Endothelial Growth Factor (VEGF) mRNA in healthy bone tissue around implants and in peri-implantitis. *Minerva Stomatol*. 2013 [Epub ahead of print].
126. Lamalice L, Le Boeuf F, Huot J. Endothelial cell migration during angiogenesis. *Circ Res*. 2007;100(6):782–94.
127. Shah P, Keppler L, Rutkowski J. A review of platelet derived growth factor playing pivotal role in bone regeneration. *J Oral Implantol*. 2014;40(3):330–40.
128. Rao RR, Peterson AW, Ceccarelli J, Putnam AJ, Stegmann JP. Matrix composition regulates three-dimensional network formation by endothelial cells and mesenchymal stem cells in collagen/fibrin materials. *Angiogenesis*. 2012;15(2):253–64.
129. Ohata Y, Ozono K. Bone and Stem Cells. The mechanism of osteogenic differentiation from mesenchymal stem cell. *Clin Calcium*. 2014;24(4):501–8.
130. Zelzer E, Olsen BR. Multiple roles of vascular endothelial growth factor (VEGF) in skeletal development, growth, and repair. *Curr Top Dev Biol*. 2005;65:169–87.
131. Koc A, Finkenzeller G, Elcin AE, Stark GB, Elcin YM. Evaluation of adenoviral vascular endothelial growth factor-activated chitosan/hydroxyapatite scaffold for engineering vascularized bone tissue using human osteoblasts: In vitro and in vivo studies. *J Biomater Appl*. 2014;29(5):748–60.
132. Liu Y, Moller B, Wiltfang J, Warnke PH, Terheyden H. Tissue engineering of a vascularized bone graft of critical size with an osteogenic and angiogenic factor-based in vivo bioreactor. *Tissue Eng Part A*. 2014;20(23–24):3189–97.
133. Kampmann A, Lindhorst D, Schumann P, Zimmerer R, Koke-muller H, Rucker M, et al. Additive effect of mesenchymal stem cells and VEGF to vascularization of PLGA scaffolds. *Microvasc Res*. 2013;90:71–9.
134. Kaipel M, Schutzenberger S, Schultz A, Ferguson J, Slezak P, Morton TJ, et al. BMP-2 but not VEGF or PDGF in fibrin matrix supports bone healing in a delayed-union rat model. *J Orthop Res*. 2012;30(10):1563–9.
135. Zigdon-Giladi H, Bick T, Lewinson D, Machtei EE. Co-transportation of endothelial progenitor cells and mesenchymal stem cells promote neovascularization and bone regeneration. *Clin Implant Dent Relat Res*. 2013;17(2):353–9.
136. Ito H, Koefoed M, Tiyyapatanaputi P, Gromov K, Goater JJ, Carmouche J, et al. Remodeling of cortical bone allografts mediated by adherent rAAV-RANKL and VEGF gene therapy. *Nat Med*. 2005;11(3):291–7.
137. Liu F, Zhang X, Yu X, Xu Y, Feng T, Ren D. In vitro study in stimulating the secretion of angiogenic growth factors of strontium-doped calcium polyphosphate for bone tissue engineering. *J Mater Sci Mater Med*. 2011;22(3):683–92.
138. Farokhi M, Mottaghitalab F, Ai J, Shokrgozar MA. Sustained release of platelet-derived growth factor and vascular endothelial growth factor from silk/calcium phosphate/PLGA based nanocomposite scaffold. *Int J Pharm*. 2013;454(1):216–25.
139. Poldervaart MT, Gremmels H, van Deventer K, Fledderus JO, Oner FC, Verhaar MC, et al. Prolonged presence of VEGF promotes vascularization in 3D bioprinted scaffolds with defined architecture. *J Control Release*. 2014;184:58–66.
140. Helmrich U, Di Maggio N, Guven S, Groppa E, Melly L, Largo RD, et al. Osteogenic graft vascularization and bone resorption by VEGF-expressing human mesenchymal progenitors. *Biomaterials*. 2013;34(21):5025–35.
141. Nicosia RF, Nicosia SV, Smith M. Vascular endothelial growth factor, platelet-derived growth factor, and insulin-like growth factor-1 promote rat aortic angiogenesis in vitro. *Am J Pathol*. 1994;145(5):1023–9.
142. Risau W, Drexler H, Mironov V, Smits A, Siegbahn A, Funa K, et al. Platelet-derived growth factor is angiogenic in vivo. *Growth Factors*. 1992;7(4):261–6.
143. Sato N, Beitz JG, Kato J, Yamamoto M, Clark JW, Calabresi P, et al. Platelet-derived growth factor indirectly stimulates angiogenesis in vitro. *Am J Pathol*. 1993;142(4):1119–30.
144. Battegay EJ, Rupp J, Iruela-Arispe L, Sage EH, Pech M. PDGF-BB modulates endothelial proliferation and angiogenesis in vitro via PDGF beta-receptors. *J Cell Biol*. 1994;125(4):917–28.
145. Pierce GF, Vande Berg J, Rudolph R, Tarpley J, Mustoe TA. Platelet-derived growth factor-BB and transforming growth factor beta 1 selectively modulate glycosaminoglycans, collagen, and myofibroblasts in excisional wounds. *Am J Pathol*. 1991;138(3):629–46.
146. Pierce GF, Mustoe TA, Altrick BW, Deuel TF, Thomason A. Role of platelet-derived growth factor in wound healing. *J Cell Biochem*. 1991;45(4):319–26.



147. Mustoe TA, Pierce GF, Morishima C, Deuel TF. Growth factor-induced acceleration of tissue repair through direct and inductive activities in a rabbit dermal ulcer model. *J Clin Invest.* 1991;87(2):694–703.
148. Ball SG, Shuttleworth CA, Kielty CM. Vascular endothelial growth factor can signal through platelet-derived growth factor receptors. *J Cell Biol.* 2007;177(3):489–500.
149. Sun B, Chen B, Zhao Y, Sun W, Chen K, Zhang J, et al. Crosslinking heparin to collagen scaffolds for the delivery of human platelet-derived growth factor. *J Biomed Mater Res B Appl Biomater.* 2009;91(1):366–72.
150. Sarment DP, Cooke JW, Miller SE, Jin Q, McGuire MK, Kao RT, et al. Effect of rhPDGF-BB on bone turnover during periodontal repair. *J Clin Periodontol.* 2006;33(2):135–40.
151. Ronga M, Fagetti A, Canton G, Paiusco E, Surace MF, Cherubino P. Clinical applications of growth factors in bone injuries: experience with BMPs. *Injury.* 2013;44(Suppl 1):S34–9.
152. Carreira AC, Lojude FH, Halsik E, Navarro RD, Sogayar MC, Granjeiro JM. Bone morphogenetic proteins: facts, challenges, and future perspectives. *J Dent Res.* 2014;93(4):335–45.
153. Carragee EJ, Chu G, Rohatgi R, Hurwitz EL, Weiner BK, Yoon ST, et al. Cancer risk after use of recombinant bone morphogenetic protein-2 for spinal arthrodesis. *J Bone Joint Surg Am.* 2013;95(17):1537–45.
154. Zhang X, Xie C, Lin AS, Ito H, Awad H, Lieberman JR, et al. Periosteal progenitor cell fate in segmental cortical bone graft transplantations: implications for functional tissue engineering. *J Bone Miner Res.* 2005;20(12):2124–37.
155. Liu Y, Yu J, Bai J, Gu JS, Cai B, Zhou X. Effects of cuttlefish bone-bone morphogenetic protein composite material on osteogenesis and revascularization of bone defect in rats. *Chin J Burns.* 2013;29(6):548–53.
156. Cao L, Wang J, Hou J, Xing W, Liu C. Vascularization and bone regeneration in a critical sized defect using 2-N,6-O-sulfated chitosan nanoparticles incorporating BMP-2. *Biomaterials.* 2014;35(2):684–98.
157. Long T, Zhu Z, Awad HA, Schwarz EM, Hilton MJ, Dong Y. The effect of mesenchymal stem cell sheets on structural allograft healing of critical sized femoral defects in mice. *Biomaterials.* 2014;35(9):2752–9.
158. McFadden TM, Duffy GP, Allen AB, Stevens HY, Schwarzaier SM, Plesnila N, et al. The delayed addition of human mesenchymal stem cells to pre-formed endothelial cell networks results in functional vascularization of a collagen-glycosaminoglycan scaffold in vivo. *Acta Biomater.* 2013;9(12):9303–16.
159. Pirraco RP, Iwata T, Yoshida T, Marques AP, Yamato M, Reis RL, et al. Endothelial cells enhance the in vivo bone-forming ability of osteogenic cell sheets. *Lab Invest.* 2014;94(6):663–73.
160. Wang P, Zhao L, Chen W, Liu X, Weir MD, Xu HH. Stem cells and calcium phosphate cement scaffolds for bone regeneration. *J Dent Res.* 2014;93(7):618–25.
161. Fan H, Zeng X, Wang X, Zhu R, Pei G. Efficacy of prevascularization for segmental bone defect repair using beta-tricalcium phosphate scaffold in rhesus monkey. *Biomaterials.* 2014;35(26):7407–15.
162. Hokugo A, Kubo Y, Takahashi Y, Fukuda A, Horiuchi K, Mushi-moto K, et al. Prefabrication of vascularized bone graft using guided bone regeneration. *Tissue Eng.* 2004;10(7–8):978–86.
163. Kneser U, Polykandriotis E, Ohnolz J, Heidner K, Grabinger L, Euler S, et al. Engineering of vascularized transplantable bone tissues: induction of axial vascularization in an osteoconductive matrix using an arteriovenous loop. *Tissue Eng.* 2006;12(7):1721–31.
164. Arkudas A, Beier JP, Heidner K, Tjiawi J, Polykandriotis E, Srouer S, et al. Axial prevascularization of porous matrices using an arteriovenous loop promotes survival and differentiation of transplanted autologous osteoblasts. *Tissue Eng.* 2007;13(7):1549–60.
165. Fan J, Bi L, Jin D, Wei K, Chen B, Zhang Z, et al. Microsurgical techniques used to construct the vascularized and neurotized tissue engineered bone. *Biomed Res Int.* 2014;2014:281872.
166. Kang Y, Ren L, Yang Y. Engineering vascularized bone grafts by integrating a biomimetic periosteum and beta-TCP scaffold. *ACS Appl Mater Interfaces.* 2014;6(12):9622–33.
167. Asahara T, Murohara T, Sullivan A, Silver M, van der Zee R, Li T, et al. Isolation of putative progenitor endothelial cells for angiogenesis. *Science.* 1997;275(5302):964–7.
168. Ingram DA, Mead LE, Tanaka H, Meade V, Fenoglio A, Mortell K, et al. Identification of a novel hierarchy of endothelial progenitor cells using human peripheral and umbilical cord blood. *Blood.* 2004;104(9):2752–60.
169. Richardson MR, Yoder MC. Endothelial progenitor cells: quo vadis? *J Mol Cell Cardiol.* 2011;50(2):266–72.
170. Chandrasekhar KS, Zhou H, Zeng P, Alge D, Li W, Finney BA, et al. Blood vessel wall-derived endothelial colony-forming cells enhance fracture repair and bone regeneration. *Calcif Tissue Int.* 2011;89(5):347–57.
171. Levengood SK, Poellmann MJ, Clark SG, Ingram DA, Yoder MC, Johnson AJ. Human endothelial colony forming cells undergo vasculogenesis within biphasic calcium phosphate bone tissue engineering constructs. *Acta Biomater.* 2011;7(12):4222–8.
172. Engler AJ, Sen S, Sweeney HL, Discher DE. Matrix elasticity directs stem cell lineage specification. *Cell.* 2006;126(4):677–89.
173. Chaudhuri O, Gu L, Darnell M, Klumpers D, Bencherif SA, Weaver JC, et al. Substrate stress relaxation regulates cell spreading. *Nat Commun.* 2015;6:6364.
174. Vernon RB, Sage EH. Between molecules and morphology. extracellular matrix and creation of vascular form. *Am J Pathol.* 1995;147(4):873–83.
175. Sieminski AL, Hebbel RP, Gooch KJ. The relative magnitudes of endothelial force generation and matrix stiffness modulate capillary morphogenesis in vitro. *Exp Cell Res.* 2004;297(2):574–84.
176. Kuzuya M, Satake S, Miura H, Hayashi T, Iguchi A. Inhibition of endothelial cell differentiation on a glycosylated reconstituted basement membrane complex. *Exp Cell Res.* 1996;226(2):336–45.
177. Deroanne CF, Lapiere CM, Nussgens BV. In vitro tubulogenesis of endothelial cells by relaxation of the coupling extracellular matrix-cytoskeleton. *Cardiovasc Res.* 2001;49(3):647–58.
178. Terella A, Mariner P, Brown N, Anseth K, Streubel SO. Repair of a calvarial defect with biofactor and stem cell-embedded polyethylene glycol scaffold. *Arch Facial Plast Surg.* 2010;12(3):166–71.
179. Aimetti AA, Machen AJ, Anseth KS. Poly(ethylene glycol) hydrogels formed by thiol-ene photopolymerization for enzyme-responsive protein delivery. *Biomaterials.* 2009;30(30):6048–54.
180. Alsberg E, Anderson KW, Albeiruti A, Rowley JA, Mooney DJ. Engineering growing tissues. *Proc Natl Acad Sci USA.* 2002;99(19):12025–30.
181. Lin H, Zhang D, Alexander PG, Yang G, Tan J, Cheng AW, et al. Application of visible light-based projection stereolithography for live cell-scaffold fabrication with designed architecture. *Biomaterials.* 2013;34(2):331–9.
182. Roy R, Boskey AL, Bonassar LJ. Non-enzymatic glycation of chondrocyte-seeded collagen gels for cartilage tissue engineering. *J Orthop Res.* 2008;26(11):1434–9.
183. Francis-Sedlak ME, Moya ML, Huang JJ, Lucas SA, Chandrasekharan N, Larson JC, et al. Collagen glycation alters neovascularization in vitro and in vivo. *Microvasc Res.* 2010;80(1):3–9.
184. Mason BN, Starchenko A, Williams RM, Bonassar LJ, Reinhart-King CA. Tuning three-dimensional collagen matrix stiffness independently of collagen concentration modulates endothelial cell behavior. *Acta Biomater.* 2013;9(1):4635–44.

185. Wolff J. The law of bone remodeling [translated from 1892 original, *Das Gesetz der Transformation der Knochen*, by Maquet, P. & Furlong, R.]. Berlin: Springer-Verlag; 1986.
186. Goodship AE, Kenwright J. The influence of induced micro-movement upon the healing of experimental tibial fractures. *J Bone Joint Surg Br.* 1985;67(4):650–5.
187. Palomares KT, Gleason RE, Mason ZD, Cullinane DM, Einhorn TA, Gerstenfeld LC, et al. Mechanical stimulation alters tissue differentiation and molecular expression during bone healing. *J Orthop Res.* 2009;27(9):1123–32.
188. Carter DR, Blenman PR, Beaupre GS. Correlations between mechanical stress history and tissue differentiation in initial fracture healing. *J Orthop Res.* 1988;6(5):736–48.
189. Vunjak-Novakovic G, Meinel L, Altman G, Kaplan D. Bioreactor cultivation of osteochondral grafts. *Orthod Craniofac Res.* 2005;8(3):209–18.
190. Kluge JA, Leisk GG, Cardwell RD, Fernandes AP, House M, Ward A, et al. Bioreactor system using noninvasive imaging and mechanical stretch for biomaterial screening. *Ann Biomed Eng.* 2011;39(5):1390–402.
191. Boerckel JD, Dupont KM, Kolambkar YM, Lin AS, Guldberg RE. In vivo model for evaluating the effects of mechanical stimulation on tissue-engineered bone repair. *J Biomech Eng.* 2009;131(8):084502.
192. Boerckel JD, Uhrig BA, Willett NJ, Huebsch N, Guldberg RE. Mechanical regulation of vascular growth and tissue regeneration in vivo. *Proc Natl Acad Sci USA.* 2011;108(37):E674–80.
193. Boerckel JD, Kolambkar YM, Stevens HY, Lin AS, Dupont KM, Guldberg RE. Effects of in vivo mechanical loading on large bone defect regeneration. *J Orthop Res.* 2012;30(7):1067–75.
194. Glatt V, Miller M, Ivkovic A, Liu F, Parry N, Griffin D, et al. Improved healing of large segmental defects in the rat femur by reverse dynamization in the presence of bone morphogenetic protein-2. *J Bone Joint Surg Am.* 2012;94(22):2063–73.
195. Krishnan L, Underwood CJ, Maas S, Ellis BJ, Kode TC, Hoying JB, et al. Effect of mechanical boundary conditions on orientation of angiogenic microvessels. *Cardiovasc Res.* 2008;78(2):324–32.
196. Song JW, Munn LL. Fluid forces control endothelial sprouting. *Proc Natl Acad Sci USA.* 2011;108(37):15342–7.
197. Galie PA, Nguyen DH, Choi CK, Cohen DM, Janmey PA, Chen CS. Fluid shear stress threshold regulates angiogenic sprouting. *Proc Natl Acad Sci USA.* 2014;111(22):7968–73.
198. Tzima E, del Pozo MA, Shattil SJ, Chien S, Schwartz MA. Activation of integrins in endothelial cells by fluid shear stress mediates Rho-dependent cytoskeletal alignment. *EMBO J.* 2001;20(17):4639–47.
199. Kwak BR, Silacci P, Stergiopulos N, Hayoz D, Meda P. Shear stress and cyclic circumferential stretch, but not pressure, alter connexin43 expression in endothelial cells. *Cell Commun Adhes.* 2005;12(5–6):261–70.
200. Edgar LT, Underwood CJ, Guilkey JE, Hoying JB, Weiss JA. Extracellular matrix density regulates the rate of neovessel growth and branching in sprouting angiogenesis. *PLoS ONE.* 2014;9(1):e85178.



# Novel Therapy for Bone Regeneration in Large Segmental Defects

Grant Log #OR120080/FY12 PRORP-TRPA

Award Number: W81XWH-13-1-0407, W81XWH-13-1-0501, W81XWH-13-1-0500



PIs: Kacena, Chu, McKinley

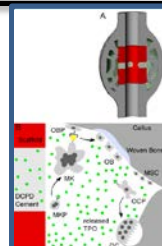
Org: Indiana University Award Amount: \$1,169,833

## Study/Product Aim(s)

- Aim 1: Determine the union rate of tibial mid-shaft critical-size defects in minipigs treated with BMP-2, TPO, and saline control
- Aim 2. Evaluate the safety and side effects of treating tibial mid-shaft critical-size defects in minipigs with BMP-2, TPO, and saline control

## Approach

Tibial critical size defect will be created in minipigs and treated with BMP-2, TPO and saline control. Blood chemistries will be measured to examine safety/side effect profiles. Animals will be euthanized 6 months post-surgery. Samples will be collected and analyzed for bone volume and tissue volume in the defects and the biomechanical properties of the tibia.



**Figure 1. (A)** Depiction of scaffold with DCPD cement drug carrier and **(B)** a simplified model of the hypothetical role of TPO in bone healing. TPO released at the bone defect site binds to MKs to induce megakaryopoiesis. Increased numbers of MKs are then available to influence OB proliferation and likely increase RANKL expression. These OBs increase bone formation and accelerate periosteal bridging. TPO at the bone defect site also binds to OC progenitors which enhances osteoclastogenesis and coupled remodeling to help restore the original bone contour more rapidly and may assist in preventing heterotopic bone formation.

Accomplishments: We received initial IACUC approval in September 2013. We submitted for ACURO in October and received ACURO approval December 6, 2013. We have practiced on hindlimbs from minipigs and conducted first live surgeries 27-03-2014. We euthanized a test minipig to practice sample collection/storage for additional piloting of protocols 25-09-2014. Scaffolds have been fabricated and 27 minipig surgeries have been completed on Yuctan minipigs 31-12-2014. Bone healing has been assessed by 3 orthopaedic surgeons for all xrays to date. All BMP surgeries have healed, all controls have failed, 50% of TPOs healed. We think modification to scaffold/hardware will allow for a higher percentage if not all of TPO treated animals to heal. We have euthanized all 27 minipigs and are analyzing the data 27/10/2015. We have completed our second series of pig surgeries (12 pigs) 06/04/2016 and euthanized all of the pigs. We are continuing with our histological analyses of bone and organs. Based on our finding that TPO healed more quickly than saline but all healed with time, we requested a 3<sup>rd</sup> series of animal surgeries with a larger defect size. IACUC approval was received in September 2016 and ACURO approval was obtained in October 2016. We completed the final series of surgeries in November and December 2016. One pig in the BMP-2 group had a catastrophic hardware failure post-surgery and was euthanized. Blood samples and xrays have now been completed for all pigs and all pigs have euthanized and tissues collected. Data collected to date is contained in the final report. Ex vivo bone healing analysis (CT and histology) and blood chemistries are ongoing and will continue although the granting period has ended.

## Timeline and Cost

Activities	CY	13	14	15	16-17
Task 1: Obtain regulatory approvals					
Task 2. Perform surgeries on minipigs					
Task 3. Determine the bone union rate					
Task 4. Determine the biomechanical properties of callus					
Task 5. Evaluate the potential systemic side effects					
<b>Estimated Budget (\$K)</b>		<b>\$25</b>	<b>\$683</b>	<b>\$380</b>	<b>\$82</b>

## Goals/Milestones

**CY13 Goal** – Obtain regulatory approvals

- ☒ Obtain IACUC approval
- ☒ Obtain ACURO approval

**CY14 Goals** – Complete all surgeries in minipigs and identify potential short term side effects

- X Fabricate scaffolds and perform surgeries
- X Perform biochemistry analysis on blood samples collected up to 4 weeks post-surgery (Blood collected, initial processing completed, ordered supplies for analyses)

**CY15 Goal** – Evaluate quality and quantity of newly formed callus

- ☐ Perform  $\mu$ CT and biomechanical analysis on retrieved tibial samples (non-destructive biomechanical testing completed on tibia from all pigs)

**CY16 Goal** – Complete side effects and callus analysis

- ☐ Perform histological analysis on retrieved tibial samples
- ☐ X Perform biochemistry analysis on blood samples collected at sacrifice (being processed)

**Comments/Challenges/Issues/Concerns:** N/A

**Budget Expenditure to Date**

Projected Expenditure: \$1,169,833

Actual Expenditure: \$1,169,833

Updated: December 29, 2017