

REPORT DOCUMENTATION PAGE

Form Approved
OMB No. 0704-0188

The public reporting burden for this collection of information is estimated to average 1 hour per response, including the time for reviewing instructions, searching existing data sources, gathering and maintaining the data needed, and completing and reviewing the collection of information. Send comments regarding this burden estimate or any other aspect of this collection of information, including suggestions for reducing the burden, to the Department of Defense, Executive Service Directorate, (0704-0188). Respondents should be aware that notwithstanding any other provision of law, no person shall be subject to any penalty for failing to comply with a collection of information if it does not display a currently valid OMB control number.

PLEASE DO NOT RETURN YOUR FORM TO THE ABOVE ORGANIZATION.

1. REPORT DATE (DD-MM-YYYY) 09/16/2017		2. REPORT TYPE Poster		3. DATES COVERED (From - To) 09/16/2017-09/19/2017	
4. TITLE AND SUBTITLE Pseudotumor Cerebri Resulting in Empty Sella Syndrome and Multiple Pituitary Hormone Deficiencies				5a. CONTRACT NUMBER	
				5b. GRANT NUMBER	
				5c. PROGRAM ELEMENT NUMBER	
				5d. PROJECT NUMBER	
				5e. TASK NUMBER	
6. AUTHOR(S) Capt Rebecca Parrish				5f. WORK UNIT NUMBER	
7. PERFORMING ORGANIZATION NAME(S) AND ADDRESS(ES) 59th Clinical Research Division 1100 Willford Hall Loop, Bldg 4430 JBSA-Lackland, TX 78236-9908 210-292-7141				8. PERFORMING ORGANIZATION REPORT NUMBER 17352	
9. SPONSORING/MONITORING AGENCY NAME(S) AND ADDRESS(ES) 59th Clinical Research Division 1100 Willford Hall Loop, Bldg 4430 JBSA-Lackland, TX 78236-9908 210-292-7141				10. SPONSOR/MONITOR'S ACRONYM(S)	
				11. SPONSOR/MONITOR'S REPORT NUMBER(S)	
12. DISTRIBUTION/AVAILABILITY STATEMENT Approved for public release. Distribution is unlimited.					
13. SUPPLEMENTARY NOTES					
14. ABSTRACT					
15. SUBJECT TERMS					
16. SECURITY CLASSIFICATION OF:			17. LIMITATION OF ABSTRACT	18. NUMBER OF PAGES	19a. NAME OF RESPONSIBLE PERSON Clarice Longoria
a. REPORT	b. ABSTRACT	c. THIS PAGE			19b. TELEPHONE NUMBER (include area code) 210-292-7141



Pseudotumor cerebri resulting in empty sella syndrome and multiple pituitary hormone deficiencies

Rebecca L. Parrish MD, Candace S. Percival MD

Department of Pediatrics, San Antonio Military Medical Center, Fort Sam Houston, TX



BACKGROUND

Pseudotumor cerebri (PTC) is frequently associated with an empty sella turcica. While commonly asymptomatic, it may present with non-specific neurologic symptoms or more rarely with pituitary dysfunction. This case highlights a patient with PTC and secondary empty sella syndrome whose symptoms of hypopituitarism were wrongly attributed to complications in the management of his PTC resulting in delayed diagnosis and management.

CASE PRESENTATION

A 17 year old male was referred to pediatric endocrinology with concerns for stalled puberty in the setting of known PTC. He was diagnosed with PTC at 10 years old and was medically managed until 13 years old when a VP shunt was placed. He required multiple shunt revisions and endured chronic headaches and back pain requiring pain specialty management with prolonged opiate and lidocaine patch use. He had decreased energy, poor stamina, and frequent nausea and vomiting that was attributed to his underlying PTC, complications from his surgical interventions, and resulting chronic narcotic use. This resulted in withdrawal from school and bedridden status for four years.

An abnormal genital exam with small phallic and testicular size led to a preliminary laboratory evaluation. This resulted in a referral to pediatric endocrinology for significantly low testosterone and an inappropriately low LH/FSH consistent with hypogonadotropic hypogonadism.

In addition to signs and symptoms of hypogonadism, he continued to complain of chronic headaches, back pain, decreased energy, and frequent nausea and vomiting. His growth velocity had slowed over the previous 3 years. On exam, he had a eunuchoid body habitus without gynecomastia. He had sparse axillary hair, Tanner II pubic hair, and a phallus smaller than expected for age. Testicular exam was concerning for testes measuring approximately 4-5 mL (normal 15-20mL) bilaterally with normal consistency.

EVALUATION

Following preliminary laboratory studies that were consistent with hypogonadotropic hypogonadism, further evaluation of the pituitary demonstrated other abnormalities (Table 1). On cosyntropin stimulation testing, the cortisol peak was 10 mcg/dL, meeting criteria for adrenal insufficiency (normal ≥ 18 mcg/dL).

On radiographic evaluation, his bone age was 14 years at a chronological age of 17 years and 4 months. The patient's previous brain imaging studies were reviewed and a partially empty sella was appreciated by a pediatric radiologist on retrospective evaluation (Image 1). There were no masses or calcifications appreciated on the MRI and CT completed a year prior to endocrine evaluation.

Pituitary hormones were serially evaluated. At 16 months after initial referral, TSH was inappropriately normal for a low FT4, consistent with central hypothyroidism.

Table 1. Serial laboratory evaluations

Lab	Initial evaluation	6 weeks later	16 months later	Normal range for age
Total testosterone (ng/dL)	12.26	646.9	200.2	84-350
LH (mIU/mL)	1.6	<0.1	0.4	0.4-7
FSH (mIU/mL)	3	0.4	0.6	2.6-11
DHT (ng/dL)	6.8			24-65
Prolactin (ng/mL)	12.5			3-18
TSH (mIU/mL)	2.47		0.62	0.5-4.8
Free T4 (ng/dL)	1.33		0.9	0.93-1.6
8am Cortisol (mcg/dL)	8.9	1.9		8-19
Sodium (mmol/L)	140			133-145

TREATMENT

Testosterone was started with gradual titration to adult replacement dosing. He noticed almost immediate improvement in energy with notable progression of puberty and linear growth acceleration. Subsequently, physiologic hydrocortisone replacement therapy resulted in resolution of his nausea, a dramatic increase in energy level, and a much anticipated return to public high school from his home education program. Finally, thyroid hormone replacement was initiated 16 months later following biochemical evidence of hypothyroidism.

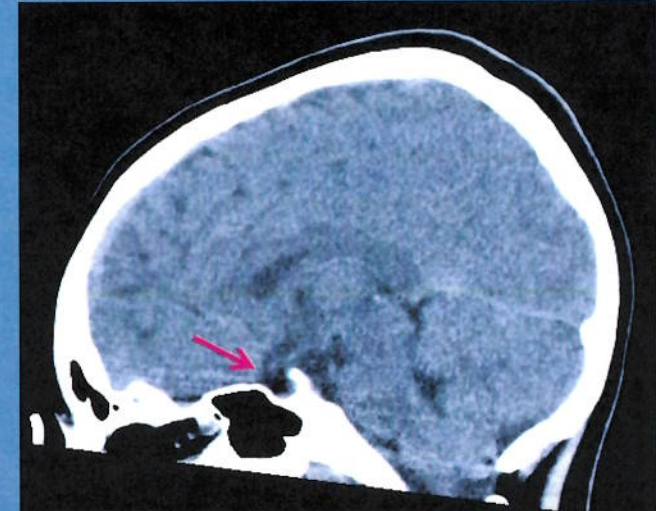


Image 1. Sagittal, midline CT image, 13 years old. The arrow shows the partially empty sella that is mostly filled with CSF and some pituitary tissue is seen flattened along the floor of the sella.

DISCUSSION

We present a case of PTC with empty sella syndrome and multiple pituitary hormone deficiencies that was undiagnosed for several years. Serial pituitary screening is necessary if there are concerns for empty sella syndrome, especially in the setting of abnormal linear growth, pubertal development, or poor energy. Early recognition and management of pituitary dysfunction is essential for normal growth and development. This patient had symptoms of pituitary deficiency for several years leading to bedridden status and significantly poor quality of life. This case stresses the importance of expanding a differential diagnosis when appropriate medical and surgical management does not result in improved symptom control. Avoidance of anchoring in a diagnostic evaluation may help to avoid unnecessary treatments and significantly increase quality of life.

REFERENCES

1. Ammar et al. Empty sella syndrome: does it exist in children? *Journal of Neurosurgery*. 1999, Vol 91, No 6: 960-963
2. De Marinis et al. Primary empty sella. *Journal of Clinical Endocrinology and Metabolism*. 2005, Vol 90: 5471-5477.
3. Foley et al. Does pseudotumor cerebri cause the empty sella syndrome? *Neurology*. 1975, Vol 25, No 6: 595-598.
4. Guillemin et al. Primary empty sella (PES): a review of 175 cases. *Pituitary*. 2013, Vol 16, No 2: 270-278.
5. Saindane et al. Factors Determining the Clinical Significance of an "Empty" Sella Turcica. *American Journal of Roentgenology*. 2013, Vol 200, No 5: 1125-1131.
6. Shekhar et al. Isolated gonadotrophin deficiency with primary empty sella: Causal or casual association? *Journal of Obstetrics and Gynecology*. 2012, Vol 2, No 3: 276-278.