

REPORT DOCUMENTATION PAGE				Form Approved OMB No. 0704-0188	
<p>The public reporting burden for this collection of information is estimated to average 1 hour per response, including the time for reviewing instructions, searching existing data sources, gathering and maintaining the data needed, and completing and reviewing the collection of information. Send comments regarding this burden estimate or any other aspect of this collection of information, including suggestions for reducing the burden, to the Department of Defense, Executive Service Directorate (0704-0188). Respondents should be aware that notwithstanding any other provision of law, no person shall be subject to any penalty for failing to comply with a collection of information if it does not display a currently valid OMB control number.</p> <p>PLEASE DO NOT RETURN YOUR FORM TO THE ABOVE ORGANIZATION.</p>					
1. REPORT DATE (DD-MM-YYYY) 09082018		2. REPORT TYPE Publication/Journal		3. DATES COVERED (From - To)	
4. TITLE AND SUBTITLE Slow-Growing Solitary Bulla of the Upper Arms				5a. CONTRACT NUMBER	
				5b. GRANT NUMBER	
				5c. PROGRAM ELEMENT NUMBER	
				5d. PROJECT NUMBER	
6. AUTHOR(S) Capt Liu Yizhen				5e. TASK NUMBER	
				5f. WORK UNIT NUMBER	
7. PERFORMING ORGANIZATION NAME(S) AND ADDRESS(ES) 59th Clinical Research Division 1100 Willford Hall Loop, Bldg 4430 JBASA-Lackland, TX 78236-9908 210-292-7141				8. PERFORMING ORGANIZATION REPORT NUMBER 17315	
9. SPONSORING/MONITORING AGENCY NAME(S) AND ADDRESS(ES) 59th Clinical Research Division 1100 Willford Hall Loop, Bldg 4430 JBASA-Lackland, TX 78236-9908 210-292-7141				10. SPONSOR/MONITOR'S ACRONYM(S)	
				11. SPONSOR/MONITOR'S REPORT NUMBER(S)	
12. DISTRIBUTION/AVAILABILITY STATEMENT Approved for public release. Distribution is unlimited.					
13. SUPPLEMENTARY NOTES					
14. ABSTRACT					
15. SUBJECT TERMS					
16. SECURITY CLASSIFICATION OF:			17. LIMITATION OF ABSTRACT	18. NUMBER OF PAGES	19a. NAME OF RESPONSIBLE PERSON
a. REPORT	b. ABSTRACT	c. THIS PAGE			Clarice Longoria
					19b. TELEPHONE NUMBER (Include area code) 210-299-714156

Slow-Growing Solitary Bulla of the Upper Arm

Total word count: 577

Yizhen Elizabeth Liu, MD,

Ryan D. Freeland, MD, Assistant Professor, Uniformed Services University of the Health Sciences

Clinical Case

A 13 year-old Caucasian female presented with a slow-growing, solitary bulla on her left upper arm. The bulla first presented one year ago as a pin-sized tan papule. The papule enlarged slowly over one year to its current size of 1.5 cm x 1 cm and now a fluid-filled bulla with a firm nodular core. The bulla was not painful but mildly tender when manipulated. The patient was otherwise healthy and without any personal or family history of similar lesions.

On exam, there was a solitary, transluminating, pink, 1.5cm x 1cm fluid-filled bulla with a solid, nodular core on the left lateral upper arm. [Figure 1] There's a palpable dermal component of the lesion. The overlying skin was normal without telangiectasia, scale, induration, or inflammation. The surrounding skin was characterized by moderate keratosis pilaris. There was no known trauma to the site of lesion. An excisional biopsy of the lesion was performed and gross examination of the specimen revealed a flaccid bulla filled with serous fluid and a white, firm, calcified core. [Figure 2]

What is the diagnosis?

- A. Bullous morphea
- B. Secondary anetoderma
- C. Bullous pilomatricoma
- D. Lymphangioma

Diagnosis

- C. Bullous pilomatricoma

The lesion was excised with a narrow margin of 1mm given its benign clinical behavior: slow growth, no ulceration, and absence of associated systemic findings. Histopathology of the specimen revealed abundant clusters of eosinophilic anucleate "ghost cells" as well as large islands of basoloid cells [Figure 3 & 4] Interestingly, some of the basaloid islands demonstrated a high number (8-10) of mitotic figures per high power field, but given the overall well-circumscribed architecture and the lack of other concerning features, the final pathology was consistent with a bullous pilomatricoma, a rare variant

of a common cutaneous nodule. The excisional surgery was uncomplicated and the patient healed well over the following weeks.

Discussion

While the other listed choices may present as a blister or bulla, the nodular core is a unique feature of bullous pilomatricoma. Pilomatricoma is a common type of benign adnexal tumor that arises from hair matrix cells and are associated with *CTNNB1* mutation, a gene that codes for β -catenin.¹⁻³ Bullous pilomatricoma, also referred to as anetodermic pilomatricoma or lymphangiectatic pilomatricoma, is an uncommon variant of pilomatricoma. In a recent study by Li, *et al*, bullous pilomatricoma is found to share molecular features with classic pilomatricoma as a result of the *CTNNB1* mutation.² Although no clinical syndromes have been linked to bullous pilomatricoma, traditional pilomatricoma has been associated with Rubinstein-Taybi syndrome, myotonic dystrophy, Gardner's syndrome, and Turner's syndrome.⁴⁻⁸ Given the clinical, histological, and genetic resemblance between bullous pilomatricoma and traditional pilomatricoma, it is reasonable to bear in mind these syndromic associations when evaluating patients with bullous pilomatricoma.

Histologically, lymphatic congestion, dilation, and resultant lymphedema have been highlighted in the majority of reported cases. Other characteristic histology findings of bullous pilomatricoma include well-differentiated eosinophilic anucleate shadow cells ("ghost cells") and clusters of basoloid cells, both of which were seen in our patient's specimen.² Among reported cases of bullous pilomatricoma, the most common site of lesion is the upper arm.⁹⁻¹⁰ Based on a literature review by Chen, *et al*, bullous pilomatricoma favors a female predominance and patients between ages of 10-20 years.¹⁰ The goal of this case report is to encourage providers to include bullous pilomatricoma in the differential diagnosis for benign nodular lesions, and it's worth noting that our patient had a classic presentation for bullous pilomatricoma based on current understanding of the condition.

"The views expressed are those of the [author(s)] [presenter(s)] and do not reflect the official views of policy of the Department of Defense or its Components"

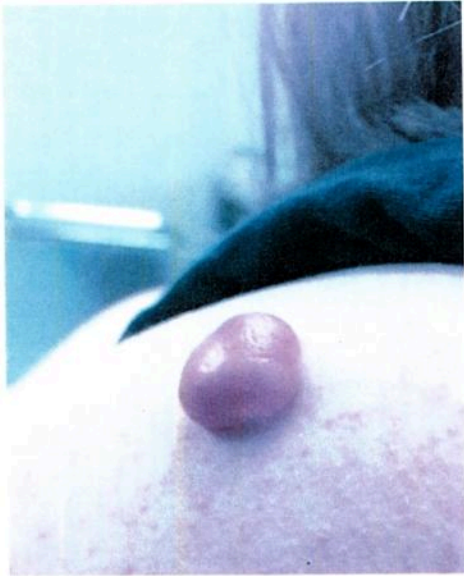

Fig. 1 Pink, 1.5cm x 1cm, fluid-filled bulla on the left lateral upper arm with background keratosis pilaris.

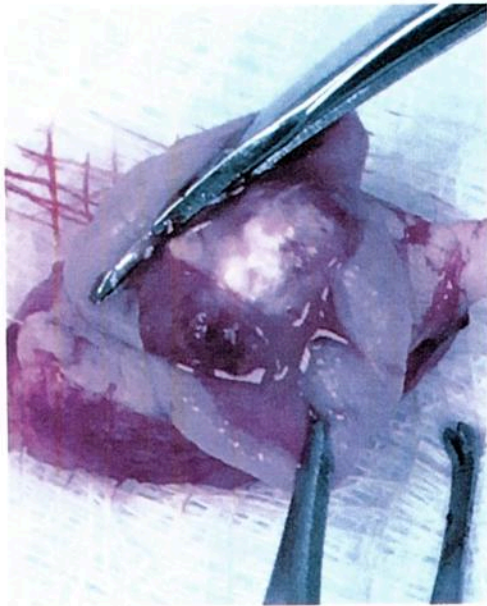

Fig. 2 Gross exam reveals a flaccid bulla filled with serous fluid and a white, firm, calcified core.

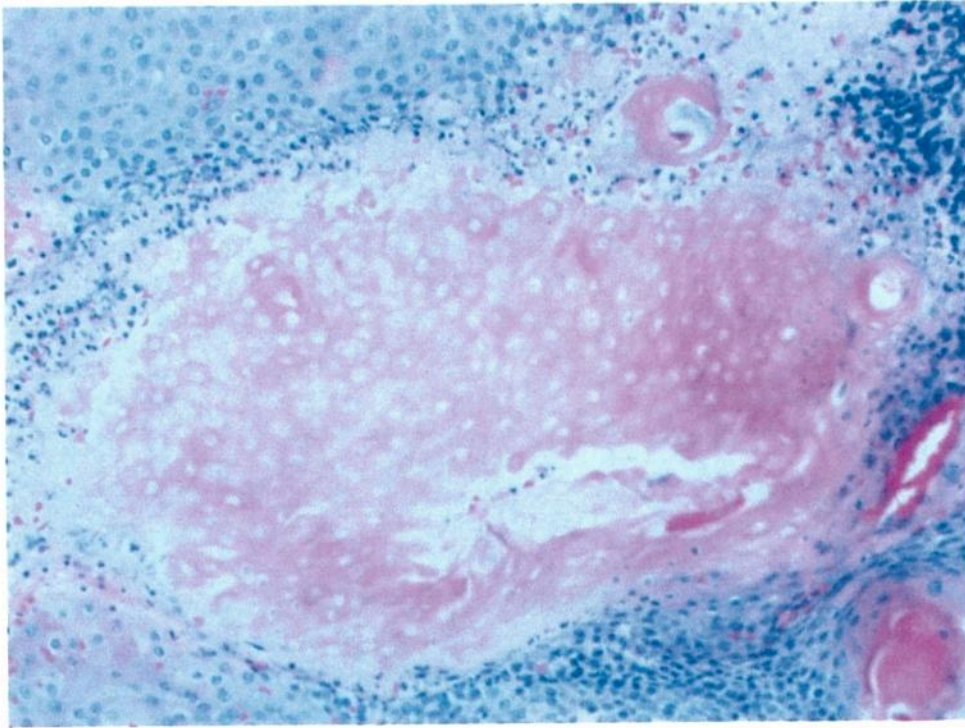


Fig. 3 H&E stain, 20x. Eosinophilic, anucleated shadow cells.

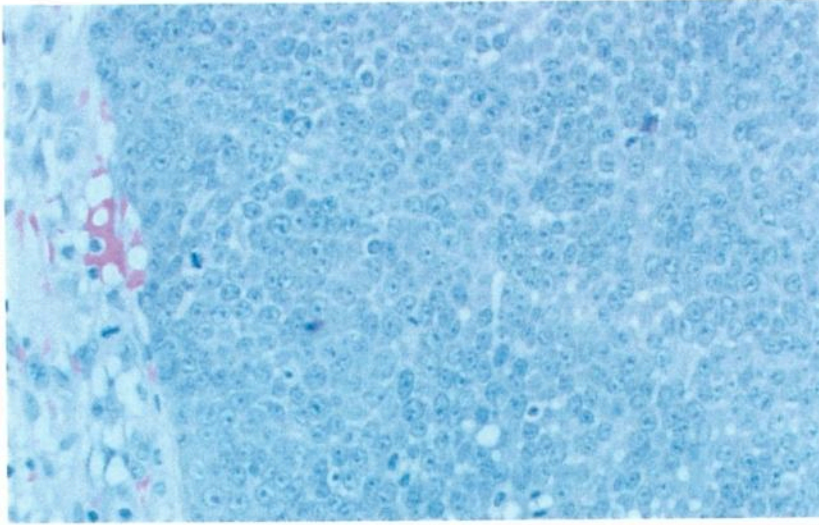


Fig. 4 H&E stain, 40x. Island of basaloid cells.

References

- ¹ Chmara M, Wernstedt A, Wasag B, et al. Multiple pilomatricomas with somatic CTNNB1 mutations in children with constitutive mismatch repair deficiency. *Genes, Chromosomes and Cancer* 2013;52:656–64.
- ² Li L, Zeng Y, Fang K, et al. Anetodermic pilomatricoma: Molecular characteristics and trauma in the development of its bullous appearance. *Am J Dermatopathol* 2012;34:e41–5.
- ³ McCalmont TH. Adnexal neoplasms. In: Bologna JL, Jorizzo JL, Rapini RP, editors. *Dermatology*. 2nd ed. Gurgaon: Mosby; 2009. pp. 1698–9.
- ⁴ Cambiaghi S, Ermacora E, Brusasco A, Canzi L, Caputo R. Multiple pilomatricomas in Rubinstein-Taybi syndrome: A case report. *Pediatr Dermatol* 1994;11:21–5.
- ⁵ Chiaramonti A, Gilgor RS. Pilomatricomas associated with myotonic dystrophy. *Arch Dermatol* 1978;114:1363–5.
- ⁶ Cooper PH, Fechner RE. Pilomatricoma-like changes in the epidermal cysts of Gardner's syndrome. *J Am Acad Dermatol* 1983;8:639–44.
- ⁷ Noguchi H, Kayashima K, Nishiyama S, Ono T. Two cases of pilomatricoma in Turner's syndrome. *Dermatology* 1999;199:338–40.
- ⁸ Belliappa P, Umashankar N, Raveendra L. Bullous Pilomatricoma: A Rare Variant Resembling Bouncy Ball. *International Journal of Trichology* 2013;5:32–4.
- ⁹ Erdogan HK, Kaya Z, Aytap CD, Acer E. A rare variant of pilomatricoma: pseudobullous pilomatricoma. *Act Dermatovenerol Alp Pannonica Adriat* 2015;24:59–60.
- ¹⁰ Chen SY, Wu F, Qian Y, Zhu L, Tu YT, Huang CZ. Pilomatricoma with bullous appearance: a case report and review of literature. *Int J Dermatol* 2011;50:615–8. □