

REPORT DOCUMENTATION PAGE

*Form Approved
OMB No. 0704-0188*

The public reporting burden for this collection of information is estimated to average 1 hour per response, including the time for reviewing instructions, searching existing data sources, gathering and maintaining the data needed, and completing and reviewing the collection of information. Send comments regarding this burden estimate or any other aspect of this collection of information, including suggestions for reducing the burden, to Department of Defense, Washington Headquarters Services, Directorate for Information Operations and Reports (0704-0188), 1215 Jefferson Davis Highway, Suite 1204, Arlington, VA 22202-4302. Respondents should be aware that notwithstanding any other provision of law, no person shall be subject to any penalty for failing to comply with a collection of information if it does not display a currently valid OMB control number.
PLEASE DO NOT RETURN YOUR FORM TO THE ABOVE ADDRESS.

1. REPORT DATE (DD-MM-YYYY) 07/17/2017	2. REPORT TYPE FINAL REPORT	3. DATES COVERED (From - To) 9/16/15-3/16/17
--	---------------------------------------	--

4. TITLE AND SUBTITLE ISLAND FOX VETERINARY AND PATHOLOGY SERVICES ON SAN CLEMENTE ISLAND, CALIFORNIA	5a. CONTRACT NUMBER W9126G-15-2-0031
	5b. GRANT NUMBER
	5c. PROGRAM ELEMENT NUMBER

6. AUTHOR(S) JESSE M. MAESTAS DAVID A GREEN ANDREW S BRIDGES DAVID K GARCELON	5d. PROJECT NUMBER
	5e. TASK NUMBER
	5f. WORK UNIT NUMBER

7. PERFORMING ORGANIZATION NAME(S) AND ADDRESS(ES) INSTITUTE FOR WILDLIFE STUDIES PO BOX 1104 ARCATA, CA 95518	8. PERFORMING ORGANIZATION REPORT NUMBER FINAL
--	--

9. SPONSORING/MONITORING AGENCY NAME(S) AND ADDRESS(ES) US ARMY CORPS OF ENGINEERS 200 FORT POINT ROAD GALVESTON, TX 77550	10. SPONSOR/MONITOR'S ACRONYM(S) ACOE
	11. SPONSOR/MONITOR'S REPORT NUMBER(S)

12. DISTRIBUTION/AVAILABILITY STATEMENT
Available for public release, distribution unlimited

13. SUPPLEMENTARY NOTES
Prepared in cooperation with Naval Base Coronado, Public Works Office, Environmental Div. Code N45

14. ABSTRACT
The San Clemente Island fox (*Urocyon littoralis clementae*) is a focal species for conservation by the U.S. Navy. The Island Fox Veterinary and Pathology Services project was designed to assist the Navy in island fox conservation and management efforts by attempting to mitigate anthropogenic-related injuries or illnesses. We utilized our mobile veterinary hospital with trained staff to provide care for island foxes as needed. Throughout 2015–2016 we also collected 95 fox carcasses and submitted 16 for necropsy. Blood and serology samples were obtained from 99 foxes during 2016 and these were archived and frozen for future analyses.

15. SUBJECT TERMS
Scientific and technical information; unclassified

16. SECURITY CLASSIFICATION OF:			17. LIMITATION OF ABSTRACT	18. NUMBER OF PAGES	19a. NAME OF RESPONSIBLE PERSON	
a. REPORT	b. ABSTRACT	c. THIS PAGE			DAVID GARCELON	
U	U	U	UU	28	19b. TELEPHONE NUMBER (Include area code) 707-822-4258	

**ISLAND FOX VETERINARY AND PATHOLOGY SERVICES ON
SAN CLEMENTE ISLAND, CALIFORNIA**

Final Report

Prepared by

INSTITUTE FOR WILDLIFE STUDIES



PO Box 1104
Arcata, CA 95518

Jesse M. Maestas
David A. Green
Andrew S. Bridges
David K. Garcelon

Prepared for:

US Army Corps of Engineers
2000 Fort Point Road
Galveston, TX 77550

In fulfillment of:

ACOE Agreement W9126G-15-2-0031

February 2017

Recommended citation: Maestas J.M., D.A. Green, A.S. Bridges, and D.K. Garcelon. 2017. Island Fox Veterinary and Pathology Services on San Clemente Island, California – 2016. Unpublished report prepared by the Institute for Wildlife Studies, Arcata, California, USA. 29 pp.

Table of Contents

Abstract.....	1
Introduction.....	1
Objectives	2
Study Area	3
Methods.....	3
Veterinary services center.....	3
Pathology services	5
Serology sample storage	6
Data base development and maintenance	6
Results.....	6
Veterinary services center.....	Error! Bookmark not defined.
Pathology.	12
Discussion.....	13
Acknowledgments.....	15
Literature Cited.....	17
Appendix A.....	19
Appendix B.....	20
Appendix C.....	23

List of Figures

Figure 1. Outside of mobile veterinary hospital on San Clemente Island (A). Veterinary diagnostic and support equipment room (B). Patient treatment and x-ray room (C). Surgery suite room (D)..... 4

Figure 2. Dr.Vickers and David Green performing surgery on a San Clemente Island fox patient. 5

Figure 4. San Clemente Island fox patient unable to stand due to ear infection (A). Side view of ear infection, causing inflammation and puss discharge (B). 8

Figure 5. San Clemente Island fox pup retrieved once its den was disturbed (A). The parents return to the pup placed in an open pet carrier (B), and escort it away (C). The parents return without the pup to further investigate the pet carrier (D). 9

Figure 6. San Clemente Island fox found trapped in a dumpster..... 10

Figure 7. San Clemente Island fox brought in with an unusual infected neck wound (A), which was later determined to be a ruptured abscess (B)..... 11

Figure 8. Motion sensor camera photo attempting to trap 1 of 2 orphaned San Clemente Island fox pups (A). Once captured both pups were deemed healthy in our fox veterinary hospital (B and C). The two pups were raised at the Natural Resources Compound for 1 month before being transferred to the Santa Barbara Zoo (D)..... 12

Figure 9. San Clemente Island fox standing in the doorway of a building (A). San Clemente Island fox witnessed jumping in and out of a garbage can to eat scraps (B)..... 14

Abstract

The San Clemente Island fox (*Urocyon littoralis clementae*) is a focal species for conservation by the U.S. Navy. The Island Fox Veterinary and Pathology Services project was designed to assist the Navy in island fox conservation and management efforts by attempting to mitigate anthropogenic-related injuries or illnesses. In 2016, we used our mobile veterinary hospital with trained staff to provide care for island foxes as needed. We treated 10 fox patients in 2016, 8 of which were either captured in urban areas on San Clemente Island after being observed with injuries, or were directly impacted by anthropogenic means. The remaining 2 were trapped in the wild and brought in due to unusual behavior and wounds. Of the 10 foxes treated, 2 were elderly foxes brought in due to fighting wounds and lethargy. Our third patient was a fox with an exposed tail bone due to fighting. Our fourth patient was a pup who was temporarily abandoned when its den was moved. Our fifth patient was a lactating female trapped in a dumpster. Our sixth patient was brought in for an unusual neck wound. Our seventh and eighth foxes were brought in for unusual ear infections impairing their balance and ability to walk. We also cared for two fox pups whose mother was hit by a car. Throughout 2015–2016 we collected 95 fox carcasses and submitted 16 for necropsy. We received necropsy results from 11 of these carcasses and none of these suggested communicable diseases were involved. Ten of the necropsied foxes had pneumoconiosis and/or interstitial pneumonia, 1 likely had been exposed to cholecalciferol rodenticide, and 1 had significant tumors in its ear. Blood and serology samples were obtained from 99 foxes during 2016 and these were archived and frozen for future analyses.

Introduction

The island fox (*Urocyon littoralis*) is endemic to the California Channel Islands, with a distinct subspecies found on each of the 6 largest islands. Several island populations underwent

dramatic declines in the 1990s (Coonan et al. 2010), which lead to 4 of the subspecies being listed as federally endangered (U.S. Fish and Wildlife Service 2004). The declines on the northern Channel Islands were attributed to predation by golden eagles (*Aquila chrysaetos*; Roemer et al. 2001), and the decline on Santa Catalina Island was attributed to the introduction of a new strain of canine distemper virus (Timm et al. 2009). While the San Clemente Island (SCI) fox population also declined in the early 2000s (Schmidt et al. 2005), the population was not federally listed. Since the early 2000s, the SCI fox population has grown and is found in all habitat types (Gregory et al. 2012, 2013). The Navy continues annual monitoring of fox demography on SCI and has also instituted a sentinel fox monitoring program to assist in the detection of disease outbreaks (Bridges et al. 2014, Maestas et al. 2015). To further fulfill the Commander Navy Region Southwest's (CNRSW) responsibilities pursuant to the Endangered Species Act (16 USC 1531 et seq) and the Sikes Improvement Act (16 USC 670 et seq), the Navy entered into a separate agreement with the Institute for Wildlife Studies (IWS) to provide veterinary care for sick and injured foxes. Since 2006, this program has attempted to mitigate anthropogenic-related injuries or illnesses. Additionally, dead foxes recovered opportunistically or as part of the sentinel monitoring program are shipped to pathologists for necropsy, histopathology, and other associated diagnostics.

Objectives

The objectives for the 2016 Island Fox Veterinary and Pathology Services Project were to: 1) maintain a veterinary services center to provide treatment of sick or injured foxes, 2) provide necessary equipment and supplies for veterinary care and consult as appropriate with qualified veterinarians, 3) collect fox carcasses, submit up to 20 of these carcasses for necropsy, and ensure that necessary ancillary tissues and data are collected for reporting and analyses, 4)

provide long-term storage for fox blood serum samples, and 5) maintain a database of fox carcasses, necropsy results, and serology findings.

Study Area

SCI (118° 30' W, 33° 00' N) is the southern-most of the California Channel Islands and is located approximately 92 km off the coast of California. The island is 14,764 ha in area extending 34 km north-south and from 2.5–6.5 km east-west. The island experiences a Mediterranean Dry Summer Subtropical climate with mild average mean summer and winter temperatures of 18°C and 13°C, respectively (USN 2002). It experiences almost constant 8–24 km/h wind. Annual rainfall averages 13 cm, with most rain occurring from November–April (USN 2013). The island is composed of plant communities including: native grass and shrub lands, maritime desert scrub, canyon woodlands, active and stabilized sand dunes, small patches of coastal saltmarsh and coastal strand vegetation, as well as developed and disturbed areas (USN 2013).

Methods

Veterinary services center. —IWS provided a 48-foot, enclosed trailer that was constructed to serve as a mobile veterinary hospital (Figure 1). The trailer had 3 rooms, and was located at the NRO complex on SCI. One room contained veterinary diagnostic and support equipment such as microscopes, centrifuges, autoclave, blood analysis machines, a -80° F freezer and a computer (Figure 1). It also had storage for medical supplies and reference books. The second room was for treatments and had stainless steel cages for holding sick or injured foxes, an x-ray machine and developer, wash basin to clean wounds or prepare animals for treatment or surgery, a variety of diagnostic equipment such as otoscope, ophthalmoscope, stethoscopes,

scales, syringe pumps, and fluid infusion pumps (Figure 1). The third room was a surgical suite and had the equipment necessary to conduct surgical procedures on foxes as needed. Equipment included a surgery table, anesthetic machine, oxygen tanks and an oxygen generator, patient monitor, x-ray viewer, and surgical lights (Figure 1).

The trailer had dual air conditioners and the patient room could be heated as needed. A washer and dryer for cleaning towels used in the hospital were located under the front overhang of the trailer. Satellite internet was available in the trailer to aid staff in communicating with Dr. Vickers and other project personnel.




Figure 1. Outside of mobile veterinary hospital on San Clemente Island (A). Veterinary diagnostic and support equipment room (B). Patient treatment and x-ray room (C). Surgery suite room (D).

All staff working in the Veterinary Services Center were trained in the care of sick and injured foxes. Training was conducted by IWS staff veterinarian Dr. Winston Vickers and assisted by David Garcelon. Training included: conducting complete examinations, providing supportive care, stabilizing fractures, administering medications, taking radiographs, maintaining patient records, operating diagnostic equipment, and proper fox handling techniques. Dr. Vickers and Mr. Garcelon made multiple visits to SCI to provide training, and Dr. Vickers was on call to answer questions and dispense medical advice and prescribe appropriate medical treatment to patients. Dr. Vickers traveled to SCI as needed in 2016 to conduct surgeries (Figure 2).

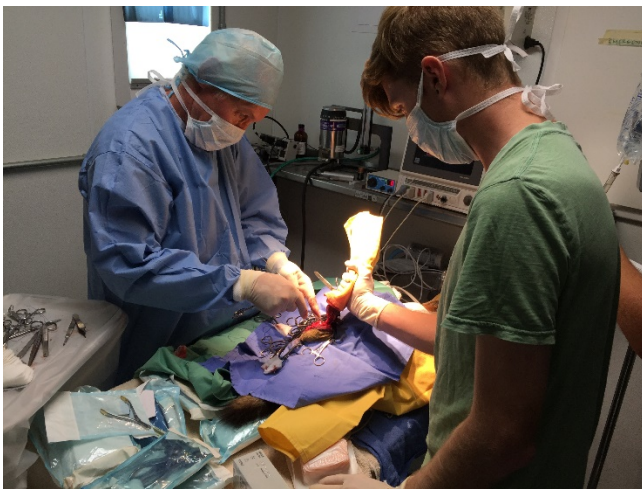

Figure 2. Dr. Vickers and David Green performing surgery on a San Clemente Island fox patient.

Pathology services.—We responded as quickly as possible to reports of fox mortalities, collected the carcasses and recorded pertinent information describing the carcass (e.g., ID if present, location found, date, time, condition). We placed a copy of that information with the carcass in a sealed bag, and also recorded the information in an electronic database. In 2016, no carcasses warranted immediately necropsy (e.g., no indications the foxes might have died from a

communicable disease), so all carcasses were placed in freezers on SCI. After consulting with the SCI Wildlife Biologist, we selected and sent 16 fox carcasses to the California Animal Health and Food Safety Laboratory System (CAHFS), at the University of California, Davis, to be necropsied. Necropsy reports and other laboratory findings were stored electronically in a database.

Serology sample storage.—Blood samples were obtained from 99 foxes during 2016 under agreement W9126G-13-2-0012 (Appendix C). Samples were stored in a -20°F freezer on SCI until they could be shipped frozen to an archival freezer in Arcata, CA. In Arcata they were entered into a database and placed in a -80°F freezer for long-term storage.

Data base development and maintenance. —IWS maintained databases using Microsoft Excel and Access for all data collection as described above. In 2016, we created an additional database cataloging all foxes submitted for necropsy for use in tracking both submissions and subsequent findings. IWS submits full data bases on all fox data, statistical analyses, GIS files and pictures as an electronic appendix to the Navy annually.

Results

Veterinary services center. —We treated 10 island foxes in our veterinary care facility during 2016 (Appendix A). Five foxes were hand-captured near human habitation or operation areas (e.g., Captains barracks, flight tower, fire house, BUDS camp, MAROPS, VC-3). Two of these were of advanced age, and had wounds consistent with fighting. Both foxes admitted to the veterinary care facility, examined thoroughly and had blood chemistry and hematology analyzed. Dr. Vickers determined that one senescent patient was healthy and could be released (Figure 3). The other patient was momentarily stable, but its blood values revealed it was suffering from mid

stages of kidney failure. The patient did not have elevated calcium levels, suggesting the kidney failure was likely due to old age versus exposure to toxins. Based on this diagnoses and its declining health, Dr.Vickers recommended euthanasia (Appendix A).



Figure 3. Releasing an elderly island fox patient on San Clemente Island after treatment in the veterinary care facility.

The two patients captured near BUDS Camp and MAROPS suffered from substantial physical ailments. One patient had a tail wound exposing the bone, and was treated by wrapping the tail in Xeroform gauze to promote tissue re-growth and given antibiotics to prevent infection. The patient was released when the tail had sufficiently healed. The other patient was reported acting erratically, spinning in circles, bleeding from its left ear, and unable to right itself (Figure 4). Upon examination we discovered its ear contained blood, pus, and maggots. We flushed the ear and then medicated to help reduce swelling and infection. When this did not alleviate its condition, Dr.Vickers visited the island to examine the fox. Under anesthesia he determined the fox had irreversible squamosal cell carcinoma (cancer) and euthanized the patient (Appendix A).

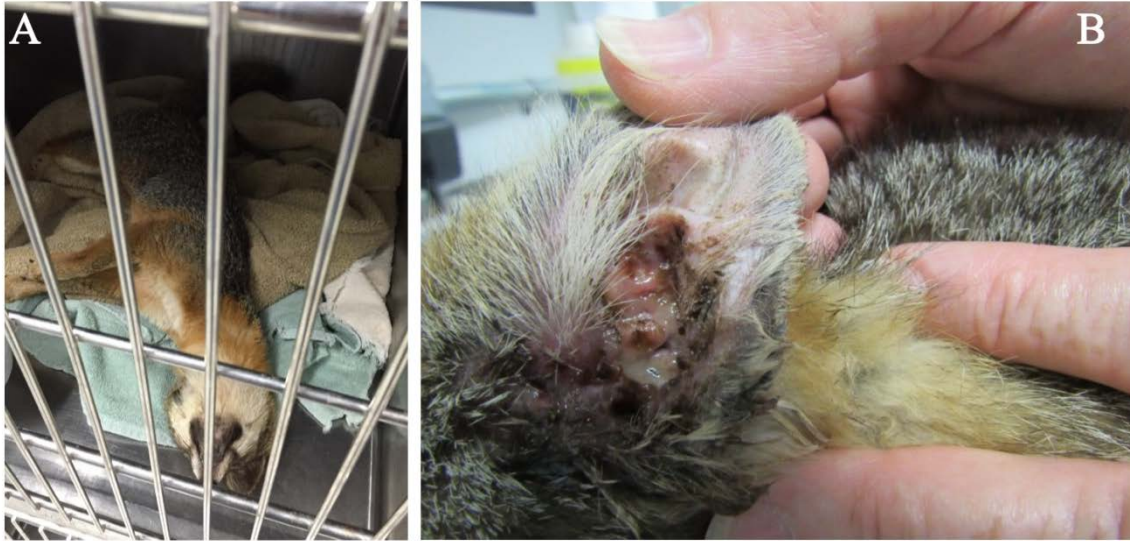

Figure 4. San Clemente Island fox patient unable to stand due to ear infection (A). Side view of ear infection, causing inflammation and puss discharge (B).

We brought in a young fox pup after it was temporarily abandoned by its parents. The pup's parents were scared off when a metal storage container, under which they were denning, was removed. The pup was determined to be in good health (Figure 5), and we placed him in an open pet carrier back at his former den site in hopes that he would be retrieved by his parents. Camera monitoring captured his parents returning to the former den site and retrieving the pup (Figure 5). The parents returned later without the pup to further investigate the pet carrier (Figure 5).



Figure 5. San Clemente Island fox pup retrieved once its den was disturbed (A). The parents return to the pup placed in an open pet carrier (B), and escort it away (C). The parents return without the pup to further investigate the pet carrier (D).

The last patient retrieved near human habitation had been trapped in a dumpster for an undetermined amount of time (Figure 6) and was slightly dehydrated and lethargic (Appendix A). The fox was lactating and presumably had pups, so it was given subcutaneous fluids and high calorie nutrient paste and was released within 5 hours of capture.



Figure 6. San Clemente Island fox found trapped in a dumpster.

The sixth patient was a fox pup hand captured near ridge road when it was displaying similar ear and balance symptoms to the fox captured near MAROPS (Figure 4, Appendix A). The fox pup had heavy ear mite infestations in both ears, and had multiple apparently self-inflicted scratch wounds around its right ear. We flushed its ears to remove pus and blood and medicated the ears to help reduce swelling and control infection. Its ears were cleaned and treated twice daily until they healed, at which point releasing the pup was approved by Dr. Vickers.

The seventh patient was captured in a box trap during annual population monitoring, and we discovered it had a large hole on the underside of its neck (Figure 7, Appendix A). Dr. Vickers speculated that a puncture wound in the neck had become infected and possibly created an abscess that then ruptured, creating a hole. The wound was flushed with a dilute betadine solution and all particulate matter was removed. Excess skin that had sloughed off was excised and a drain was inserted into the wound to keep it from closing too rapidly. Once the wound

closed properly around the drain, it was removed and flushed until it closed completely and the patient was released.

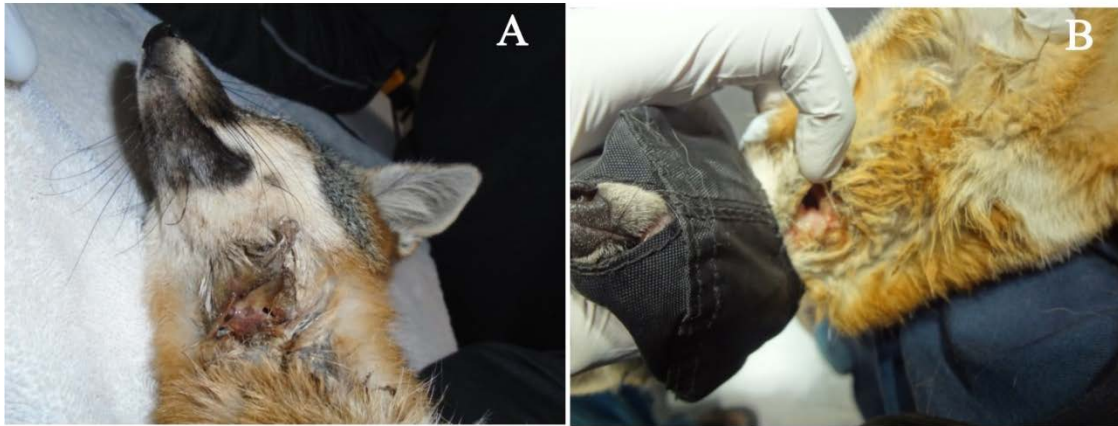

Figure 7. San Clemente Island fox brought in with an unusual infected neck wound (A), which was later determined to be a ruptured abscess (B).

The eighth and ninth patients were sibling pups brought in after their mother had been struck by a vehicle on the night of 5 May 2016. IWS predator management staff found her shortly after being hit at 22:15, and noting that she had been nursing, they immediately began searching the area but were unable to find the pups. The predator management and fox management personnel returned the next day (6 May) and located an active fox den. As we did not know for certain this den was that of the female that had been killed, we placed multiple motion sensor cameras near the den and checked them twice a day (Figure 8). We later confirmed that there were 2 fox pups, and while one adult fox was photographed briefly approaching the den, no fox ever provisioned the pups with food. As >42 hours had passed since the pups received food or water, it became apparent the female's mate was not going to assume provisioning of the pups. We therefore placed several traps outside of the den, and 1 pup was captured 5 hours later. It was given food, a towel and a warm water bag to maintain its temperature, and left in the trap as a lure to assist in the capture of the other pup (Figure 8A). The

second pup was captured 12 hours later and both pups were brought into the veterinary care facility (Figure 8). We continued to maintain the motion sensitive cameras at the den, but no adults visited the site. The pups were deemed healthy, and based on their weights we estimated their age to be approximately 50 days old. After consulting and coordinating with the Navy Installation Biologist, the 2 pups were transported to the Santa Barbara Zoo on month after capture.



Figure 8. Motion sensor camera photo attempting to trap 1 of 2 orphaned San Clemente Island fox pups (A). Once captured both pups were deemed healthy in our fox veterinary hospital (B and C). The two pups were raised at the Natural Resources Compound for 1 month before being transferred to the Santa Barbara Zoo (D).

Pathology.—Sixteen foxes were submitted for necropsy to U.C Davis between April and August 2016. As of January 2017, we have received 11 final necropsy reports from the

veterinary pathologists at U.C. Davis (Appendix B). Necropsy results confirmed the squamous cell carcinoma in the ear of the fox (ID # 160704) that had been treated in our veterinary care facility. The necropsy also revealed that the squamous cell carcinoma had metastasized into the lungs. Of the remaining 10 foxes that were necropsied, 6 died due to vehicular collision.

Although the ultimate cause of death was vehicular collision, necropsy revealed 1 fox had been exposed to cholecalciferol rodenticide and would likely have succumbed to systemic mineralization if it had not be struck. The cause of death of the remaining 4 necropsied foxes was not definitive, but 2 were emaciated, and suffered from secondary lesser ailments (Appendix B). The final 2 fox carcasses were too decomposed for necropsy to determine a cause of death. Seven of the 9 carcasses suitable for necropsy showed signs of pneumoconiosis, interstitial pneumonia (often associated with pneumoconiosis; Appendix B), or both.

Discussion

Eight of the 10 foxes treated in 2016 were either recovered near human habitation or were directly negatively impacted by anthropogenic activity. While direct human wildlife conflicts (such as vehicle collisions) have an obvious impact on island fox health, less obvious are the impacts of human activities such as supplemental feeding. Island foxes may fight with each other to defend territories with valuable resources (Coonan et al. 2010) such as anthropogenic food. Densities and territorial aggression in animals can increase in the presence of high value anthropogenic resources such as garbage (Totten et al. 2002), and domestic cat food (Theimer et al. 2015). The highest densities of foxes exists on the northern part of San Clemente (Maestas et al. 2015), which also overlaps with the primary area of human habitation. The combination of high fox densities and access to localized high-value anthropogenic resources (trash and pet food) could facilitate greater conspecific aggression, as well as explain

the human habituation that we have observed in many of our patients (Figure 9). These factors could increase the likelihood of spreading zoonotic diseases, such as rabies or canine distemper, within the fox population. Residents on SCI can greatly reduce these abnormal fox behaviors by not feeding the foxes. They can also reduce the risk of accidentally entrapping foxes by changing inspecting outside garbage cans frequently and ensuring the lids to their dumpsters are sealed.



Figure 9. San Clemente Island fox standing in the doorway of a building (A). San Clemente Island fox witnessed jumping in and out of a garbage can to eat scraps (B).

One of the necropsies revealed squamosal cell carcinoma. Dr. Vickers collected tissue samples from this fox to determine if there are any similarities with Catalina Island fox ear tumors (Vickers et al. 2016).

Of the 11 sentinel mortalities, none were spatially or temporally close enough to trigger higher than a Tier I Incident Management Response (IMR) as described in the Epidemic Response Plan for San Clemente Foxes (Hudgens et al. 2011). Similarly, of the completed necropsy results, none have indicated communicable infectious diseases. Interstitial pneumonia,

pneumoconiosis, or both were common in necropsied foxes, and although these conditions were not the primary cause of death in any of these foxes, these ailments could have negative effects on a fox's health. Pneumoconiosis continues to be present, as a similar lesser occurrence was detected from fox necropsies in 2013 (Biteman et al. 2013). Five out of the ten carcasses had pneumoconiosis in their lungs. The extent of the impact to foxes is currently unknown and may warrant further investigation.

We found 1 road killed fox had likely ingested cholecalciferol rodenticide that likely would have eventually proved fatal. The fox was an older age class and lived near the terminal, which suggests the fox had likely been exposed to the toxin before it was switched to pellet form in 2012. Without conducting blood tests we cannot determine how recent its exposure was. However, given its age we assume the fox had multiple years to accumulate it in its body. We did not have any other necropsies in 2016 showing a similar exposure.

The veterinary care facility continues to be an effective tool for fox rehabilitation, as well as an advanced means of diagnosing potential detriments to the fox population.

Acknowledgments

Funding for the project was provided by the U.S. Navy Pacific Fleet, Southwest Division. We thank the many people who helped complete the work described in this report. Foremost, we thank Melissa Booker for her dedication to managing island foxes and other natural resources on San Clemente Island. We also thank Kimberly O'Connor of the U.S. Navy Pacific Fleet for her role in funding, Jack Mobley and Kathy Mitchell of the Army Corps of Engineers oversaw contract management, Winston Vickers provided veterinary expertise, and James Coler provided logistic support. Field and lab work was conducted by the authors and Glen Enzfelder, Randy

Bacon, Luke Burlingame, Brandon Boehm, Marcus Collado, Jon Ewanyk, Orlando Tapia, and
Jake Kern.

Literature Cited

- Biteman, D. S., Laursen, C.L., Sieger, J.S., A. S. Bridges, and D. K. Garcelon. 2014. Sentinel Monitoring of the Island fox population on San Clemente Island, California. Unpublished report prepared by the Institute for Wildlife Studies, Arcata, California, USA. 31 pp.
- Bridges, A.S., S.N.D King, and D.K. Garcelon. 2014. San Clemente Island Fox (*Urocyon littoralis clementae*) Monitoring and Demography – 2013. Unpublished report prepared by the Institute for Wildlife Studies, Arcata, California, USA. 33 pp.
- Coonan, T.J., C.A. Schwemm and D.K. Garcelon. 2010. Decline and recovery of the island fox. Cambridge University Press, NY. 212pp.
- Gregory, N.C., B.R. Hudgens and D.K. Garcelon. 2012. San Clemente Island Fox (*Urocyon littoralis clementae*) Monitoring and Demography – 2011. Unpublished report prepared by the Institute for Wildlife Studies, Arcata, California, USA. 57 pp.
- Gregory, N.C., B.R. Hudgens and D.K. Garcelon. 2013. San Clemente Island Fox (*Urocyon littoralis clementae*) Monitoring and Demography – 2012. Unpublished report prepared by the Institute for Wildlife Studies, Arcata, California, USA. 57 pp.
- Hudgens, B. R., T. W. Vickers, D. K. Garcelon and J. N. Sanchez. 2011. Epidemic response plan for San Clemente Island foxes. Unpublished report to the Naval Facilities Engineering Command, Southwest, San Diego, California. 98 pp.
- Maestas J.M., A.S. Bridges, C.N. Gagorik, and D.K. Garcelon. 2015. San Clemente Island fox monitoring and demography – 2014. Unpublished report prepared by the Institute for Wildlife Studies, Arcata, California, USA. 66 pp.
- Roemer, G.W., D.A. Smith, D.K. Garcelon, and R.K. Wayne. 2001. The behavioral ecology of the island fox (*Urocyon littoralis*). *Journal of Zoology* 255:22–23.
- Roemer, G. W., T. J. Coonan, D. K. Garcelon, J. Bascompte, L. Laughrin. 2001. Feral pigs facilitate hyperpredation by golden eagles and indirectly cause the decline of the island fox. *Animal Conservation* vol. 4, no. 4, pp. 307-318.
- Schmidt, G. A., B. R. Hudgens and D. K. Garcelon. 2005. Island fox monitoring and research on naval Auxiliary Landing Field, San Clemente Island, California, Final Report: May 2004-June 2005. Unpublished report prepared by the Institute for Wildlife Studies, Arcata, California. 31pp.
- Timm, S. F., L. Munson, B. Summers, K. Terio, E. Dubovi, C. Rupprecht, S. Kapil, and D. K. Garcelon. 2009. A suspected canine distemper epidemic as the cause of a catastrophic decline in Santa Catalina Island foxes (*Urocyon littoralis catalinae*). *Journal of Wildlife Disease* 45:333-343.

- Theimer, T. C., Clayton, A. C., Martinez, A., Peterson, D. L., and D.L. Bergman. 2015. Visitation rate and behavior of urban mesocarnivores differs in the presence of two common anthropogenic food sources. *Urban Ecosystems*, 18(3): 895-906.
- Totton, S. C., Tinline, R. R., Rosatte, R. C., and L.L Bigler. 2002. Contact rates of raccoons (*Procyon lotor*) at a communal feeding site in rural eastern Ontario. *Journal of Wildlife Diseases*, 38(2): 313-319.
- U.S. Fish and Wildlife Service. 2004. Listing of the San Miguel island fox, Santa Rosa island fox, Santa Cruz island fox, and Santa Catalina island fox as endangered; final rule. *Federal Register* 69(44):63654-63666.
- U.S. Department of the Navy, Southwest Division. 2013. San Clemente Island Integrated Natural Resources Management Plan Final, June 2013. San Diego, California. Prepared by Tierra Data Systems, Escondido, California, USA
- Vickers, T. W., Clifford, D. L., Garcelon, D. K., King, J. L., Duncan, C. L., Gaffney, P. M., & Boyce, W. M. 2015. Pathology and epidemiology of ceruminous gland tumors among endangered Santa Catalina Island Foxes (*Urocyon littoralis catalinae*) in the Channel Islands, USA. *PloS one*, 10:11, e0143211.

Appendix A

Summary of treatment administered to 9 island foxes during 2016.

Date Recovered	Location	Pit Tag Last 6	Ailment	Treatment	Released
9/9/2016	Grid 2	686094	Infected Neck Injury	Would flushed, drain inserted, amoxicillin regime	Yes
7/27/2016	Ridge Road /Ammo Bypass	999287	Heavy ear mite load and ear infection	Ear flush, and medicated ear solution	Yes
7/25/2016	Marops	N/A	Heavy ear mite load with ear infection, maggots, and head tilt	Ear flush, medicated ear solution and maggot removal Euthanasia	No
6/15/2016	BUDS Camp	860843	Tail bite with bone exposed	0.74 mg amoxicillin	Yes
5/5/2016	Ridge Road /Horton	N/A	Mother Killed Abandoned pup	Brought in and cared for, later sent to Santa Barbara zoo	No
5/5/2016	Ridge Road Near Horton	N/A	Mother Killed Abandoned pup	Brought in and cared for, later sent to Santa Barbara zoo	No
5/3/2016	Fire House	75493C	Old Age	Given Fluids	Yes
5/3/2016	Dumpster by Flight Tower	861011	Stuck in Dumpster	Given Fluids	Yes
4/13/16	VC-3 area	N/A	Pups parents scared off when den was moved	Given a checkup and returned to parents	Yes
3/9/2016	Captains Barracks	847671	Kidney Failure	Euthanasia	No

Appendix B

Necropsy results from 11 island fox carcasses submitted in 2015/2016.

PIT ID	Date Death/ Found	Date Recovered	UTMe	UTMn	Recovery Location	Sex	Age Class	Cause of Death	25 (OH) Vit D3 (nmol/L)	Pneumoconiosis	Other Notes
338060	1/11/15	1/13/15	365597	3636265	Near Grid 9	F	1	Emaciation	No	Moderate	Collar wrapped around leg, amputation of tail, myopathy, otitis externa, otodectes,
557C4D	1/27/15	1/27/15	354110	3651753	Ridge Rd at Wilson Cove Rd	M	3	Trauma	No	Mild/Moderate	Gastritis, enteric cestodes
238833	1/29/15	1/29/15	352422	3653944	Curve south of air terminal	F	1	Trauma/Poison	Yes	Mild/Moderate	Trauma with avulsion of lungs, otitis externa
338086	7/9/15	7/11/15	357665	3641909	Tombstone trail	M	3	Undetermined	No	No	Otitis externa, high mercury and selenium, very autolysed
199260	11/15/15	11/15/15	353456	3653040	1 mile south of airport	F	1	Trauma	No	Mild	Otitis externa, otodectes, moderate pyelitis
815461	1/20/15	1/22/15	363040	3639316	Cactus patch next to canyon near grid 12	M	2	Emaciation / Undetermined	No	Moderate	Interstitial pneumonia, otitis externa, red/black intestinal contents
935552	4/12/16	4/12/16	363537	3639366	Box Canyon near fox grid 12	M	1	Undetermined	No	Mild	Pneumoconiosis
855859	3/25/15	3/25/15	359542	3643183	Ridge Rd near Tota	F	4	Trauma	No	Moderate	Crushed skull and maceration of

PIT ID	Date Death/ Found	Date Recovered	UTMe	UTMn	Recovery Location	Sex	Age Class	Cause of Death	25 (OH) Vit D3 (nmol/L)	Pneumoconiosis	Other Notes
					Rd						brain, left elbow fracture, femur fractures, avulsion of lungs, maceration of heart, rib fractures, maceration and tearing of liver, kidneys, and spleen, otitis externa
932034	8/18/15	8/19/15	353958	3647898	Tar 10	M	3	Trauma	No	Mild/Moderate	Trauma, right fracture of femur, possible valvular endocarditis, otitis externa with glandular distension, interstitial pneumonia, granular casts in kidney
199197	6/6/16	6/23/16	354182	3651728	Ridge Rd Curve near Ridge Bypass Rd	F	3	Trauma	No	No	Otitis externa, and deep cellulitis of the pinna, renal focal cortical and medullary tubular drop-out
160704	7/4/16	7/4/16	352292	3654022	BUDS	M	3	Euthanasia	No	Mild/Moderate	Squamous cell carcinoma (ear),

PIT ID	Date Death/ Found	Date Recovered	UTMe	UTMn	Recovery Location	Sex	Age Class	Cause of Death	25 (OH) Vit D3 (nmol/L)	Pneumoconiosis	Other Notes
											metastatic squamous carcinoma (lungs), interstitial pneumonia, otitis externa, mercury and cadmium higher than normal

Appendix C

San Clemente Island fox blood samples collected and stored in 2016

Date	PIT Tag	Box	# of Serum	# of Blood Clot	Comments
	Last 5		Samples	Samples	
1/3/17	237558	5	2	1	Slightly Hemolyzed
1/3/17	378200	5	2	1	Hemolyzed
1/3/17	685130	5	2	1	Slightly Hemolyzed
1/2/17	812456	5	1	1	Hemolyzed
11/25/16	241346	4	3	1	Slightly Hemolyzed
11/18/16	532067	5	3	1	Normal
11/16/16	119239	5	3	1	Normal
11/16/16	222078	5	3	1	Normal
11/16/16	314887	5	3	1	Normal
11/16/16	803319	5	2	1	Slightly Hemolyzed
11/16/16	932437	5	3	1	Slightly Hemolyzed
11/16/16	986182	5	3	1	Normal
11/6/16	220107	4	3	1	Normal
11/6/16	236975	4	2	1	Slightly Hemolyzed
11/6/16	360358	4	3	1	Slightly Hemolyzed
11/6/16	466278	4	3	1	Normal
11/6/16	905290	4	2	1	Slightly Hemolyzed
11/6/16	905387	4	2	1	Slightly Hemolyzed

Date	PIT Tag	Box	# of Serum	# of Blood Clot	Comments
	Last 5		Samples	Samples	
11/6/16	916055	4	2	1	Hemolyzed
11/6/16	853008	5	2	1	Slightly Hemolyzed
11/6/16	898015	5	2	1	Hemolyzed
11/5/16	241635	4	3	1	Normal
11/5/16	279388	4	3	1	Normal
11/5/16	336501	4	2	1	Slightly Hemolyzed
11/5/16	551073	4	2	1	Hemolyzed
11/5/16	831348	4	2	1	Normal
10/25/16	237592	4	3	1	Normal
10/24/16	815578	4	3	1	Normal/Gel formed
10/24/16	834149	4	3	1	Normal
10/23/16	081968	4	3	1	Slightly Hemolyzed
10/23/16	238243	4	3	1	Normal
10/23/16	241146	4	2	1	Slightly Hemolyzed
10/23/16	820615	4	2	1	Hemolyzed Gel Formed
10/23/16	902416	4	3	1	Cloudy
10/11/16	338033	4	2	1	Slightly Hemolyzed
10/10/16	241212	3	3	1	Slightly Hemolyzed
10/10/16	550307	4	3	1	Slightly Hemolyzed
10/9/16	2B7E0B	3	2	1	Hemolyzed

Date	PIT Tag	Box	# of Serum	# of Blood Clot	Comments
	Last 5		Samples	Samples	
10/9/16	393420	3	3	1	Partially Hemolyzed
10/9/16	410315	3	3	1	Slightly Hemolyzed
10/9/16	550345	3	3	1	Normal
10/9/16	6C2747	3	3	1	Slightly Hemolyzed
10/9/16	70205F	3	3	1	Foggy
10/9/16	871322	3	2	1	Slightly Hemolyzed
10/8/16	199222	3	2	1	Hemolyzed
10/8/16	222306	3	3	1	Cloudy
10/8/16	338090	3	3	1	Normal
10/8/16	393022	3	3	1	Slightly Hemolyzed
10/8/16	776232	3	3	1	Normal
10/8/16	824456	3	3	1	Normal
10/8/16	932461	3	2	1	Slightly Hemolyzed
10/8/16	994290	3	2	1	Slightly Hemolyzed
9/29/16	119218	2	3	1	Normal
9/29/16	199209	2	3	1	Foggy
9/29/16	238819	2	1	1	Hemolyzed
9/29/16	214928	3	3	1	Normal
9/28/16	199219	3	3	1	Hemolyzed
9/28/16	199231	3	2	1	Hemolyzed

Date	PIT Tag	Box	# of Serum	# of Blood Clot	Comments
	Last 5		Samples	Samples	
9/28/16	202600	3	3	1	Hemolyzed
9/28/16	370065	3	2	1	Slightly Hemolyzed
9/28/16	932152	3	2	1	Hemolyzed
9/28/16	932152	3	2	1	Hemolyzed
9/20/16	237792	2	3	1	Normal
9/19/16	065331	2	3	1	Slightly Hemolyzed
9/19/16	199244	2	3	1	Slightly Hemolyzed
9/19/16	239026	2	2	1	Slightly Hemolyzed
9/19/16	337777	2	2	1	Slightly Hemolyzed
9/18/16	119174	2	3	1	Normal
9/18/16	202637	2	3	1	Slightly Hemolyzed
9/18/16	3A2C40	2	3	1	Hemolyzed
9/18/16	932639	2	2	1	Hemolyzed
9/18/16	938391	2	3	1	Slightly Hemolyzed
9/17/16	202593	2	2	1	Normal
9/17/16	240923	2	2	1	Hemolyzed
9/17/16	451738	2	2	1	Hemolyzed
9/17/16	686084	2	3	1	Normal
9/17/16	686327	2	3	1	Normal
9/17/16	827865	2	3	1	Normal

Date	PIT Tag	Box	# of Serum	# of Blood Clot	Comments
	Last 5		Samples	Samples	
9/17/16	947628	2	2	1	Hemolyzed
9/10/16	202596	1	3	1	Normal
9/10/16	202608	1	2	1	Slightly Hemolyzed
9/10/16	202651	1	2	1	Hemolyzed
9/10/16	202662	1	2	1	Slightly Hemolyzed
9/10/16	238443	1	3	1	Normal
9/10/16	240187	1	3	1	Slightly Hemolyzed
9/10/16	303818	1	2	1	Slightly Hemolyzed
9/10/16	337907	1	1	1	Hemolyzed
9/10/16	932869	1	1	1	Hemolyzed
9/9/16	021077	1	2	1	Normal
9/9/16	199212	1	3	1	Hemolyzed
9/9/16	199233	1	3	1	Normal
9/9/16	236120	1	1	1	Hemolyzed
9/9/16	319410	1	2	1	Slightly Hemolyzed
9/9/16	372226	1	3	1	Normal
9/9/16	684781	1	3	1	Cloudy/Normal
9/9/16	818690	1	3	1	Normal
9/9/16	836708	1	3	1	Slightly Hemolyzed
9/9/16	897460	1	2	1	Slightly Hemolyzed

Date	PIT Tag Last 5	Box	# of Serum Samples	# of Blood Clot Samples	Comments
9/9/16	932747	1	3	1	Hemolyzed