



DEPARTMENT OF THE AIR FORCE
59TH MEDICAL WING (AETC)
JOINT BASE SAN ANTONIO - LACKLAND TEXAS



11 APR 2017

MEMORANDUM FOR SGO6D

ATTN: MAJ VINCENT TIMPONE

FROM: 59 MDW/SGVU

SUBJECT: Professional Presentation Approval

1. Your paper, entitled **Penetrating Neurotrauma: What the Radiologists Needs to Know** presented at/published to **2017 ASNR Annual Conference, Long Beach, CA, 22-27 April 2017** in accordance with MDWI 41-108, has been approved and assigned local file #**17174**.
2. Pertinent biographic information (name of author(s), title, etc.) has been entered into our computer file. Please advise us (by phone or mail) that your presentation was given. At that time, we will need the date (month, day and year) along with the location of your presentation. It is important to update this information so that we can provide quality support for you, your department, and the Medical Center commander. This information is used to document the scholarly activities of our professional staff and students, which is an essential component of Wilford Hall Ambulatory Surgical Center (WHASC) internship and residency programs.
3. Please know that if you are a Graduate Health Sciences Education student and your department has told you they cannot fund your publication, the 59th Clinical Research Division may pay for your basic journal publishing charges (to include costs for tables and black and white photos). We cannot pay for reprints. If you are a 59 MDW staff member, we can forward your request for funds to the designated Wing POC at the Chief Scientist's Office, Ms. Alice Houy, office phone: 210-292-8029; email address: alice.houy.civ@mail.mil.
4. Congratulations, and thank you for your efforts and time. Your contributions are vital to the medical mission. We look forward to assisting you in your future publication/presentation efforts.

Linda Steel-Goodwin

LINDA STEEL-GOODWIN, Col, USAF, BSC
Director, Clinical Investigations & Research Support

PROCESSING OF PROFESSIONAL MEDICAL RESEARCH/TECHNICAL PUBLICATIONS/PRESENTATIONS

INSTRUCTIONS

USE ONLY THE MOST CURRENT 59 MDW FORM 3039 LOCATED ON AF E-PUBLISHING

1. The author must complete page two of this form:
 - a. In Section 2, add the funding source for your study [e.g., 59 MDW CRD Graduate Health Sciences Education (GHSE) (SG5 O&M); SG5 R&D; Tri-Service Nursing Research Program (TSNRP); Defense Medical Research & Development Program (DMRDP); NIH; Congressionally Directed Medical Research Program (CDMRP) ; Grants; etc.]
 - b. In Section 2, there may be funding available for journal costs, if your department is not paying for figures, tables or photographs for your publication. Please state "YES" or "NO" in Section 2 of the form, if you need publication funding support.
2. Print your name, rank/grade, sign and date the form in the author's signature block or use an electronic signature.
3. Attach a copy of the 59 MDW IRB or IACUC approval letter for the research related study. If this is a technical publication/presentation, state the type (e.g. case report, QA/QI study, program evaluation study, informational report/briefing, etc.) in the "Protocol Title" box.
4. Attach a copy of your abstract, paper, poster and other supporting documentation.
5. Save and forward, via email, the processing form and all supporting documentation to your unit commander, program director or immediate supervisor for review/approval.
6. On page 2, have either your unit commander, program director or immediate supervisor:
 - a. Print their name, rank/grade, title; sign and date the form in the approving authority's signature block or use an electronic signature.
7. Submit your completed form and all supporting documentation to the CRD for processing (59crdpubspres@us.af.mil). **This should be accomplished no later than 30 days before final clearance is required to publish/present your materials.** If you have any questions or concerns, please contact the 59 CRD/Publications and Presentations Section at 292-7141 for assistance.
8. The 59 CRD/Publications and Presentations Section will route the request form to clinical investigations, 502 ISG/JAC (Ethics Review) and Public Affairs (59 MDW/PA) for review and then forward you a final letter of approval or disapproval.
9. Once your manuscript, poster or presentation has been approved for a one-time public release, you may proceed with your publication or presentation submission activities, as stated on this form. **Note:** For each new release of medical research or technical information as a publication/presentation, a new 59 MDW Form 3039 must be submitted for review and approval.
10. If your manuscript is accepted for scientific publication, please contact the 59 CRD/Publications and Presentations Section at 292-7141. This information is reported to the 59 MDW/CC. All medical research or technical information publications/presentations must be reported to the Defense Technical Information Center (DITC). See 59 MDWI 41-108, *Presentation and Publication of Medical and Technical Papers*, for additional information.
11. The Joint Ethics Regulation (JER) DoD 5500.07-R, *Standards of Conduct*, provides standards of ethical conduct for all DoD personnel and their interactions with other non-DoD entities, organizations, societies, conferences, etc. Part of the Form 3039 review and approval process includes a legal ethics review to address any potential conflicts related to DoD personnel participating in non-DoD sponsored conferences, professional meetings, publication/presentation disclosures to domestic and foreign audiences, DoD personnel accepting non-DoD contributions, awards, honoraria, gifts, etc. The specific circumstances for your presentation will determine whether a legal review is necessary. **If you (as the author) or your supervisor check "NO" in block 17 of the Form 3039, your research or technical documents will not be forwarded to the 502 ISG/JAC legal office for an ethics review.** To assist you in making this decision about whether to request a legal review, the following examples are provided as a guideline:

For presentations before professional societies and like organizations, the 59 MDW Public Affairs Office (PAO) will provide the needed review to ensure proper disclaimers are included and the subject matter of the presentation does not create any cause for DoD concern.

If the sponsor of a conference or meeting is a DoD entity, an ethics review of your presentation is not required, since the DoD entity is responsible to obtain all approvals for the event.

If the sponsor of a conference or meeting is a non-DoD commercial entity or an entity seeking to do business with the government, then your presentation should have an ethics review.

If your travel is being paid for (in whole or in part) by a non-Federal entity (someone other than the government), a legal ethics review is needed. These requests for legal review should come through the 59 MDW Gifts and Grants Office to 502 ISG/JAC.

If you are receiving an honorarium or payment for speaking, a legal ethics review is required.

If you (as the author) or your supervisor check "YES" in block 17 of the Form 3039, your research or technical documents will be forwarded simultaneously to the 502 ISG/JAC legal office and PAO for review to help reduce turn-around time. If you have any questions regarding legal reviews, please contact the legal office at (210) 671-5795/3365, DSN 473.

NOTE: All abstracts, papers, posters, etc., should contain the following disclaimer statement:

"The views expressed are those of the [author(s)] [presenter(s)] and do not reflect the official views or policy of the Department of Defense or its Components"

NOTE: All abstracts, papers, posters, etc., should contain the following disclaimer statement for research involving humans:

"The voluntary, fully informed consent of the subjects used in this research was obtained as required by 32 CFR 219 and DODI 3216.02_AFI 40-402."

NOTE: All abstracts, papers, posters, etc., should contain the following disclaimer statement for research involving animals, as required by AFMAN 40-401_IP :

"The experiments reported herein were conducted according to the principles set forth in the National Institute of Health Publication No. 80-23, Guide for the Care and Use of Laboratory Animals and the Animal Welfare Act of 1966, as amended."

PROCESSING OF PROFESSIONAL MEDICAL RESEARCH/TECHNICAL PUBLICATIONS/PRESENTATIONS

1. TO: CLINICAL RESEARCH	2. FROM: (Author's Name, Rank, Grade, Office Symbol) Timpone, Vincent, Maj, O4, 59 RSQ SGO6D	3. GME/GHSE STUDENT: <input type="checkbox"/> YES <input checked="" type="checkbox"/> NO	4. PROTOCOL NUMBER: N/A
5. PROTOCOL TITLE: (NOTE: For each new release of medical research or technical information as a publication/presentation, a new 59 MDW Form 3039 must be submitted for review and approval.) Penetrating Neurotrauma: What the Radiologist Needs to Know			
6. TITLE OF MATERIAL TO BE PUBLISHED OR PRESENTED: Penetrating Neurotrauma: What the Radiologist Needs to Know			
7. FUNDING RECEIVED FOR THIS STUDY? <input type="checkbox"/> YES <input checked="" type="checkbox"/> NO FUNDING SOURCE:			
8. DO YOU NEED FUNDING SUPPORT FOR PUBLICATION PURPOSES: <input type="checkbox"/> YES <input checked="" type="checkbox"/> NO			
9. IS THIS MATERIAL CLASSIFIED? <input type="checkbox"/> YES <input checked="" type="checkbox"/> NO			
10. IS THIS MATERIAL SUBJECT TO ANY LEGAL RESTRICTIONS FOR PUBLICATION OR PRESENTATION THROUGH A COLLABORATIVE RESEARCH AND DEVELOPMENT AGREEMENT (CRADA), MATERIAL TRANSFER AGREEMENT (MTA), INTELLECTUAL PROPERTY RIGHTS AGREEMENT ETC.? <input type="checkbox"/> YES <input checked="" type="checkbox"/> NO NOTE: If the answer is YES then attach a copy of the Agreement to the Publications/Presentations Request Form.			
11. MATERIAL IS FOR: <input checked="" type="checkbox"/> DOMESTIC RELEASE <input type="checkbox"/> FOREIGN RELEASE CHECK APPROPRIATE BOX OR BOXES FOR APPROVAL WITH THIS REQUEST. ATTACH COPY OF MATERIAL TO BE PUBLISHED/PRESENTED.			
<input type="checkbox"/> 11a. PUBLICATION/JOURNAL (List intended publication/journal.)			
<input type="checkbox"/> 11b. PUBLISHED ABSTRACT (List intended journal.)			
<input checked="" type="checkbox"/> 11c. POSTER (To be demonstrated at meeting: name of meeting, city, state, and date of meeting.) 2017 ASNR annual conference, Long Beach, CA, 4/22-4/27			
<input type="checkbox"/> 11d. PLATFORM PRESENTATION (At civilian institutions: name of meeting, state, and date of meeting.)			
<input type="checkbox"/> 11e. OTHER (Describe: name of meeting, city, state, and date of meeting.)			
12. HAVE YOUR ATTACHED RESEARCH/TECHNICAL MATERIALS BEEN PREVIOUSLY APPROVED TO BE PUBLISHED/PRESENTED? <input type="checkbox"/> YES <input checked="" type="checkbox"/> NO ASSIGNED FILE # _____ DATE _____			
13. EXPECTED DATE WHEN YOU WILL NEED THE CRD TO SUBMIT YOUR CLEARED PRESENTATION/PUBLICATION TO DTIC NOTE: All publications/presentations are required to be placed in the Defense Technical Information Center (DTIC).			
DATE ASAP for TDY Funding purposes			
14. 59 MDW PRIMARY POINT OF CONTACT (Last Name, First Name, M.I., email) Timpone, Vincent M. vincent.m.timpone.mil@mail.mil			15. DUTY PHONE/PAGER NUMBER 292-2205
16. AUTHORSHIP AND CO-AUTHOR(S) List in the order they will appear in the manuscript.			
LAST NAME, FIRST NAME AND M.I.	GRADE/RANK	SQUADRON/GROUP/OFFICE SYMBOL	INSTITUTION (If not 59 MDW)
a. Primary/Corresponding Author Michael LanFranchi, MD	Civ		Massachusetts General Hosp
b. Justin Peacock, MD	03/Capt	959 MDG	SAMMC
c. Aaron Betts, MD	04/Maj	USA, Radiology department	SAMMC
d. Brittany Ritchie, MD	04/Maj	USA, Radiology department	SAMMC
e. Vincent Timpone, MD (senior, corre	04/Maj	59 RSQ/ MDG/ SG06D	WHASC
17. IS A 502 ISG/JAC ETHICS REVIEW REQUIRED (JER DOD 5500.07-R)? <input type="checkbox"/> YES <input checked="" type="checkbox"/> NO			
I CERTIFY ANY HUMAN OR ANIMAL RESEARCH RELATED STUDIES WERE APPROVED AND PERFORMED IN STRICT ACCORDANCE WITH 32 CFR 219, AFMAN 40-401 JP, AND 59 MDWI 41-108. I HAVE READ THE FINAL VERSION OF THE ATTACHED MATERIAL AND CERTIFY THAT IT IS AN ACCURATE MANUSCRIPT FOR PUBLICATION AND/OR PRESENTATION.			
18. AUTHOR'S PRINTED NAME, RANK, GRADE Vincent Timpone, Maj, O4		19. AUTHOR'S SIGNATURE TIMPONE.VINCENT.M.1264952570	20. DATE April 05, 2017
21. APPROVING AUTHORITY'S PRINTED NAME, RANK, TITLE Lucas Sheldon, Lt Col, CC		22. APPROVING AUTHORITY'S SIGNATURE SHELDON.LUCAS.M.1024563096	23. DATE April 05, 2017

PROCESSING OF PROFESSIONAL MEDICAL RESEARCH/TECHNICAL PUBLICATIONS/PRESENTATIONS

1st ENDORSEMENT (59 MDW/SGVU Use Only)

TO: Clinical Research Division 59 MDW/CRD Contact 292-7141 for email instructions.	24. DATE RECEIVED April 05, 2017	25. ASSIGNED PROCESSING REQUEST FILE NUMBER 17174
26. DATE REVIEWED April 07, 2017		27. DATE FORWARDED TO 502 ISG/JAC
28. AUTHOR CONTACTED FOR RECOMMENDED OR NECESSARY CHANGES: <input checked="" type="checkbox"/> NO <input type="checkbox"/> YES If yes, give date. _____ <input type="checkbox"/> N/A		
29. COMMENTS <input checked="" type="checkbox"/> APPROVED <input type="checkbox"/> DISAPPROVED Academic presentation of publicly available literature. Appropriate disclaimers included. Approved		

30. PRINTED NAME, RANK/GRADE, TITLE OF REVIEWER Kevin Kupferer/GS13/Human Research Subject Protection Expert	31. REVIEWER SIGNATURE KUPFERER, KEVIN R. 1086667270 <small>Digitally signed by KUPFERER KEVIN R. 1086667270 DN: cn=KUPFERER KEVIN R. 1086667270, email=kupferer.kevin@va.gov, o=VA, ou=59 MDW/CRD, c=US Date: 2017.04.07 09:53:16 -0400</small>	32. DATE April 07, 2017
---	--	----------------------------

2nd ENDORSEMENT (502 ISG/JAC Use Only)

33. DATE RECEIVED	34. DATE FORWARDED TO 59 MDW/PA
35. COMMENTS <input type="checkbox"/> APPROVED (In compliance with security and policy review directives.) <input type="checkbox"/> DISAPPROVED	

36. PRINTED NAME, RANK/GRADE, TITLE OF REVIEWER	37. REVIEWER SIGNATURE	38. DATE
---	------------------------	----------

3rd ENDORSEMENT (59 MDW/PA Use Only)

39. DATE RECEIVED April 07, 2017	40. DATE FORWARDED TO 59 MDW/SGVU April 10, 2017
41. COMMENTS <input checked="" type="checkbox"/> APPROVED (In compliance with security and policy review directives.) <input type="checkbox"/> DISAPPROVED	

42. PRINTED NAME, RANK/GRADE, TITLE OF REVIEWER Kevin Inuma, SSgt/E-5, 59 MDW Public Affairs	43. REVIEWER SIGNATURE IINUMA, KEVIN MITSUGU 1296227 613 <small>Digitally signed by KEVIN MITSUGU IINUMA 1296227 DN: cn=IINUMA, KEVIN MITSUGU 1296227, email=iinuma.kevin@va.gov, o=VA, ou=59 MDW/PA, c=US Date: 2017.04.10 14:22:04 -0400</small>	44. DATE April 10, 2017
---	---	----------------------------

4th ENDORSEMENT (59 MDW/SGVU Use Only)

45. DATE RECEIVED	46. SENIOR AUTHOR NOTIFIED BY PHONE OF APPROVAL OR DISAPPROVAL <input type="checkbox"/> YES <input type="checkbox"/> NO <input type="checkbox"/> COULD NOT BE REACHED <input type="checkbox"/> LEFT MESSAGE	
47. COMMENTS <input type="checkbox"/> APPROVED <input type="checkbox"/> DISAPPROVED		
48. PRINTED NAME, RANK/GRADE, TITLE OF REVIEWER	49. REVIEWER SIGNATURE	50. DATE

Penetrating Neurotrauma: What the Radiologist Needs to Know

ASNR 2017 Electronic Educational Exhibit, #106

Michael Lanfranchi MD¹, Justin Peacock MD, PhD², Aaron Betts MD², Randall McCafferty MD³, Brittany Ritchie MD², Sirishma Kalli MD⁴, Vincent Timpone MD²

*Lanfranchi M and Peacock J contributed equally to this exhibit.



1. Massachusetts General Hospital, Dept of Radiology
2. San Antonio Military Medical Center, Dept of Radiology
3. San Antonio Military Medical Center, Dept of Neurosurgery
4. Tufts Medical Center, Dept of Radiology

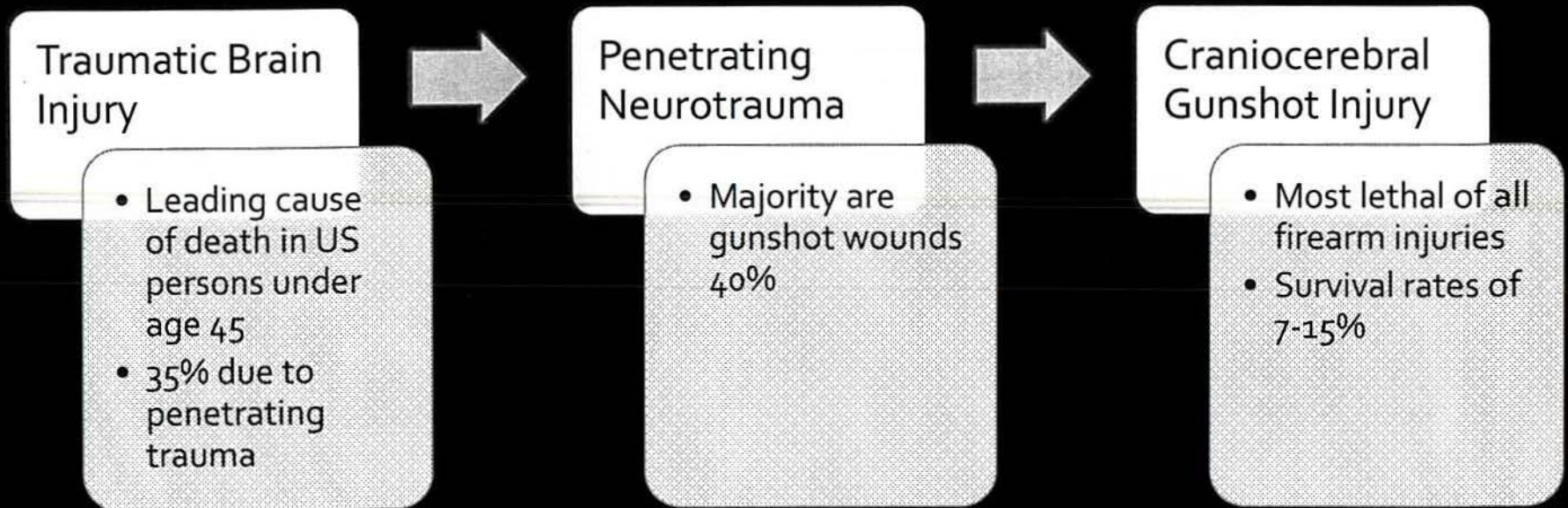


Tufts
Medical
Center

Disclosures

- No financial disclosures
- The opinions and views expressed in this presentation are solely those of the authors and do not represent an endorsement by or the views of the Department of Defense, or the United States Government
- The views expressed are those of the author(s)/presenter(s) and do not reflect the official views or policy of the Department of Defense or its Components.

Penetrating Neurotrauma



The purpose of this exhibit is:

- Timely and accurate imaging interpretation of primary and secondary injury patterns in penetrating neurotrauma
- To describe various patterns of penetrating neurotrauma and secondary complications of these injuries
- is essential in determining prognosis and establishing a treatment plan
- To emphasize imaging findings used for surgical decision making and prognostication

Outline

- Primary Penetrating Injury Patterns
 - Bullet ballistic trauma
 - Low velocity
 - High velocity
 - Blast-related fragment injury
 - Stab wounds
 - Non-metallic projectiles
- Complications
 - Secondary bone missiles
 - Cerebral swelling & herniation syndromes
 - Infection
 - Vascular injury
 - Ballistic fragment migration
- Prognostication
- Treatment Considerations
 - MR Safety

Ballistic Trauma

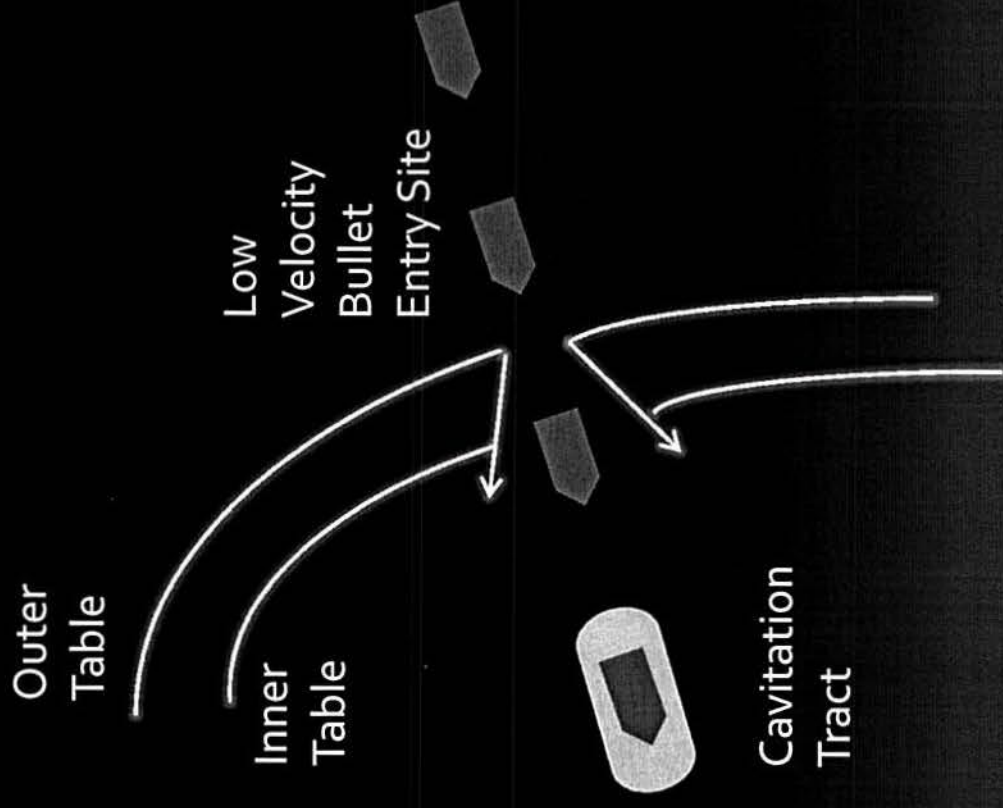
- Ballistic injuries depend on dispersion of kinetic energy
 - Velocity of projectile contributes more than bullet caliber
 - Kinetic Energy = $\frac{1}{2}$ mass x velocity²
- Low velocity projectiles (muzzle velocity < 250 m/s),
 - Handguns
 - Shrapnel from grenades
 - Most improvised explosion devices (IEDs)

$$E_K = \frac{1}{2} m v^2$$

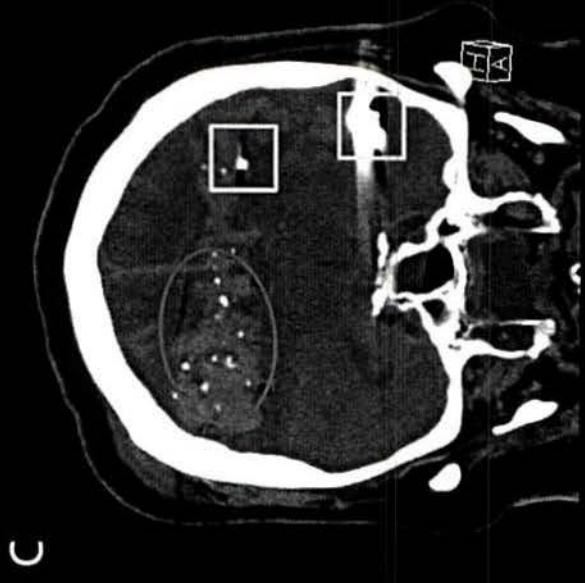
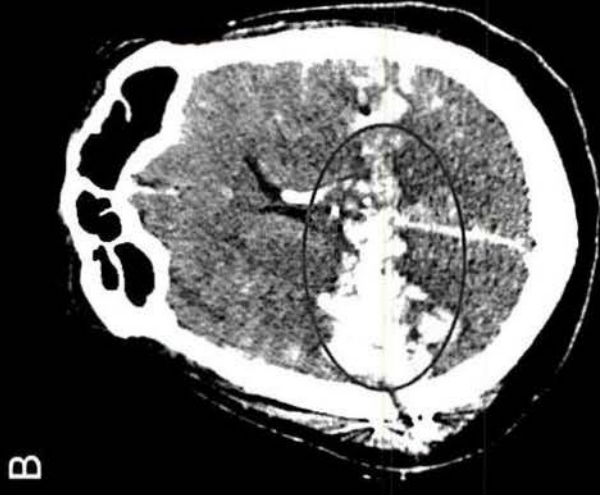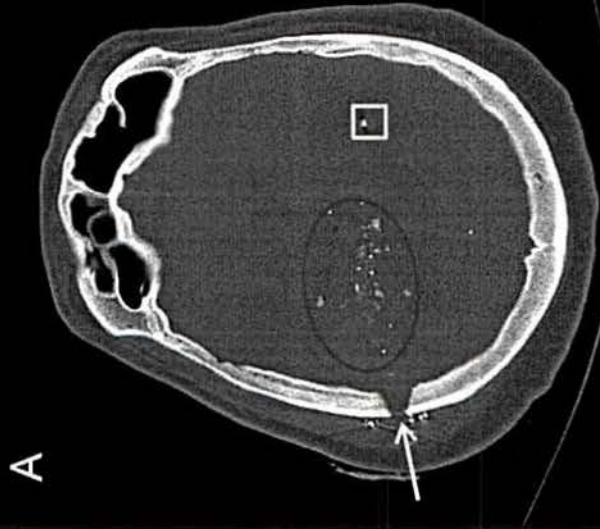
- High velocity projectiles (muzzle velocity > 700 m/s)
 - Military-grade weaponry
 - Hunting rifles

Low Velocity Bullet Ballistic Trauma

- Bullet skull entrance usually show characteristic inward beveling (outer table defect < inner table)
- Cavitation tract is larger than missile diameter due to outward centrifugal forces
- Low velocity projectiles do not cause a exit wound due to insufficient kinetic energy, and may be retained with the cavitation tract, or ricochet off the inner table of the skull, leading to multi-directional injury



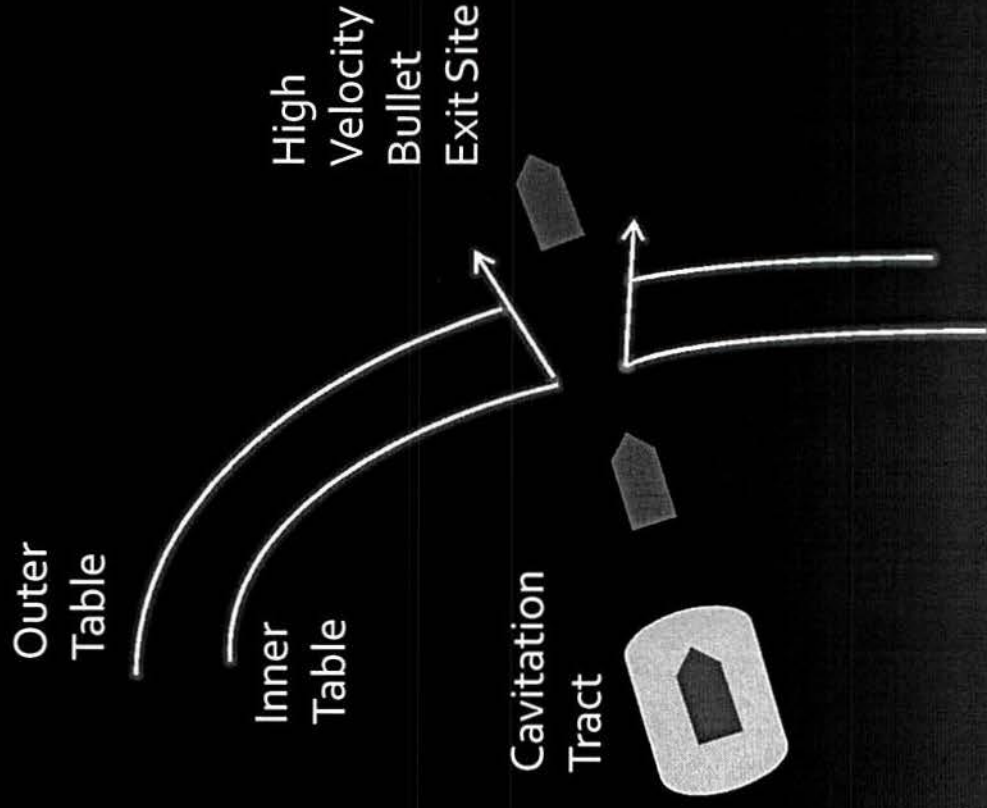
Case 1: Low Velocity Ballistic Trauma



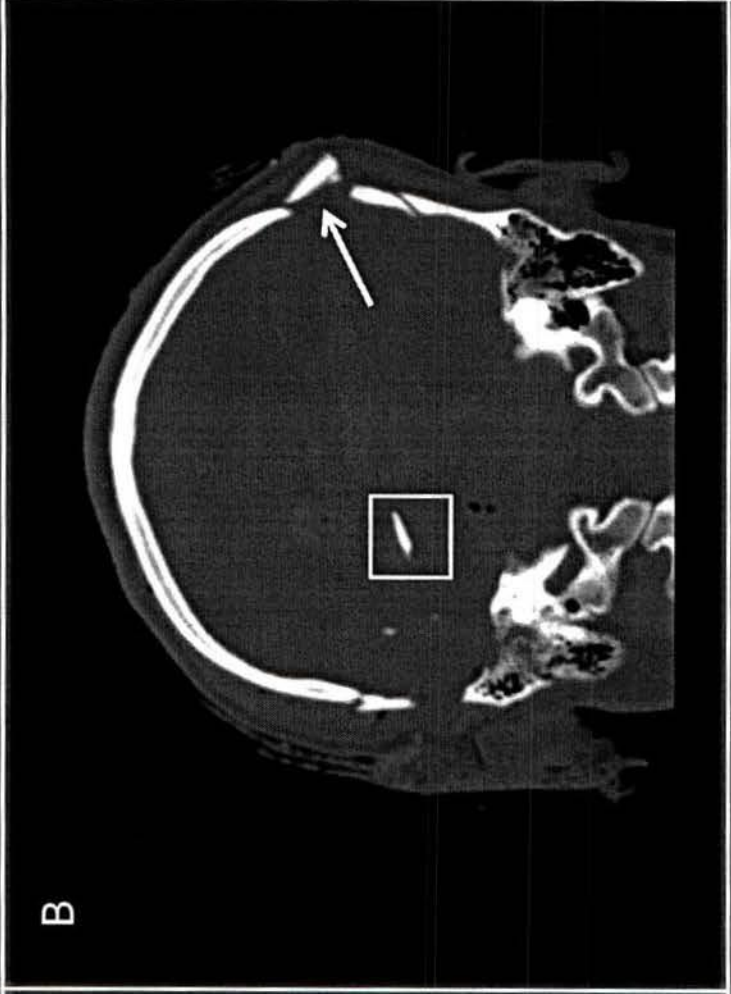
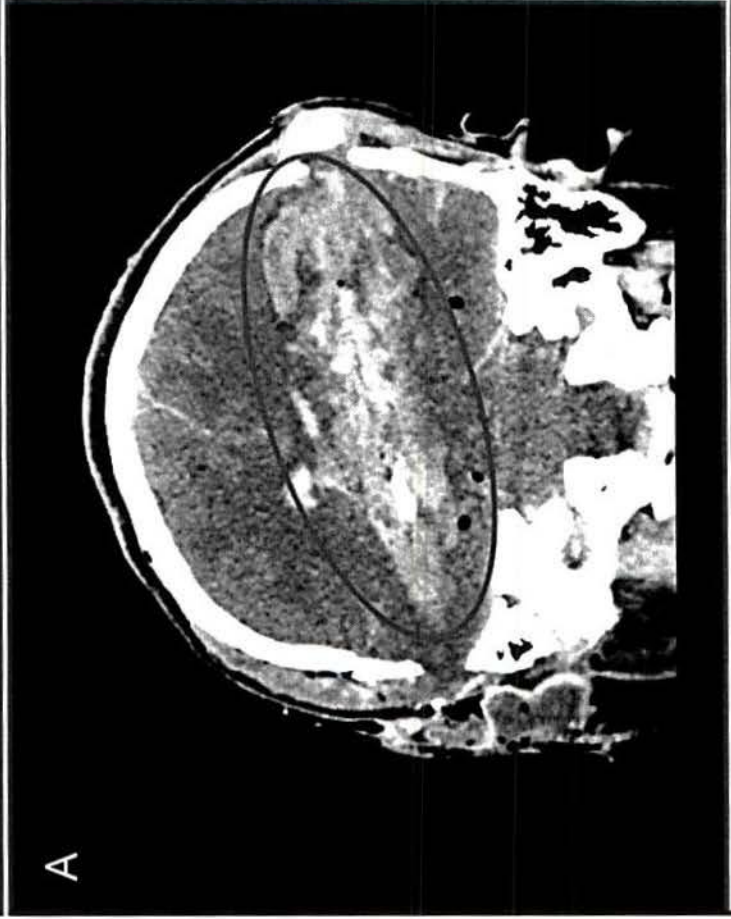63 year-old male with self-inflicted gunshot to the right parietal lobe with handgun. Axial non-enhanced CT images with bone windows (A), soft tissue windows (B), and non-enhanced coronal CT in soft tissue windows (C) show inward beveling of calvarial entry site (arrow), hemorrhagic ballistic tract with bone fragments (circles) and bullet fragments (squares). Coronal CT image (C) demonstrates ricochet of the dominant bullet fragment off the parietal inner table with final localization of bullet in the left temporal lobe (square).

High Velocity Bullet Ballistic Trauma

- Impact emits high pressure wave that cause stretching injury distant from the missile tract
- Higher centrifugal forces result in larger cavitation tracts than low velocity ballistics
- Skull exit wounds usually show outward beveling (inner table defect < outer table defect)
- Bullet fragmentation, yawing, and secondary missiles result in increased bone destruction and brain damage along the cavitation tract
- Superficial soft tissues and debris may be pulled behind ballistic due to vacuum effects



Case 2: High Velocity Ballistic Trauma



18 year-old male with high velocity gunshot wound to the right temporal bone. Coronal non-enhanced CT images with soft tissue (A) and bone (B) windows shows a wide hemorrhagic cavitation tract (circle) due to high velocity bullet projectile and secondary bone missiles (square). There is outward beveling of the skull at the exit site (arrow). Generally, there is greater bone damage at exit site secondary to bullet fragmentation and yawing.

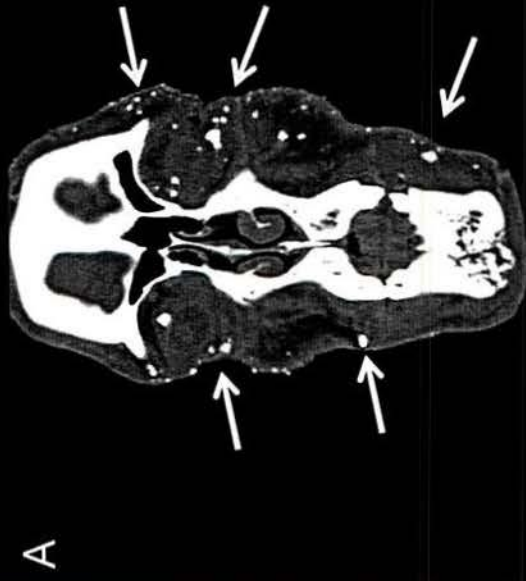
Outline

- Primary Penetrating Injury Patterns
 - Bullet ballistic trauma
 - Low velocity
 - High velocity
 - Blast-related fragment injury
 - Stab wounds
 - Non-metallic projectiles
- Complications
 - Secondary bone missiles
 - Cerebral swelling & herniation syndromes
 - Infection
 - Vascular injury
 - Ballistic fragment migration
- Prognostication
- Treatment Considerations
 - MR Safety

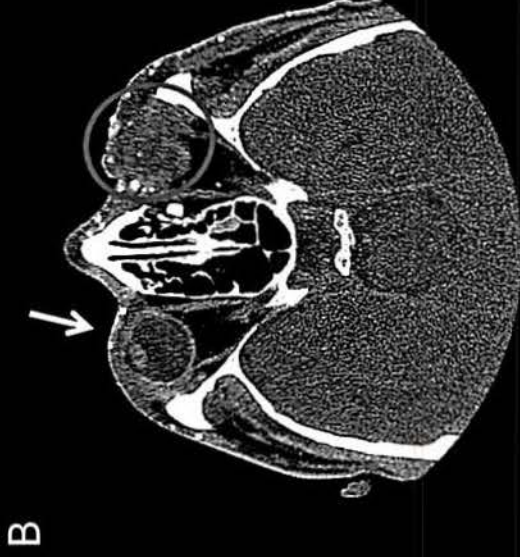Blast-Related Fragment Injury

- Most common penetrating injury to US coalition forces resulting from recent conflicts in Iraq and Afghanistan
- The head and neck are second most commonly injured body parts (after extremities)
- These projectiles have lower kinetic energy, generally cause superficial injury, and are less likely to penetrate the cranial vault
- Additional injuries may be related to pressurization impact (primary blast wave), displacement of victim away from blast site, and detonation-related thermal injuries

Cases 3 & 4: Blast-Related Fragment Injury

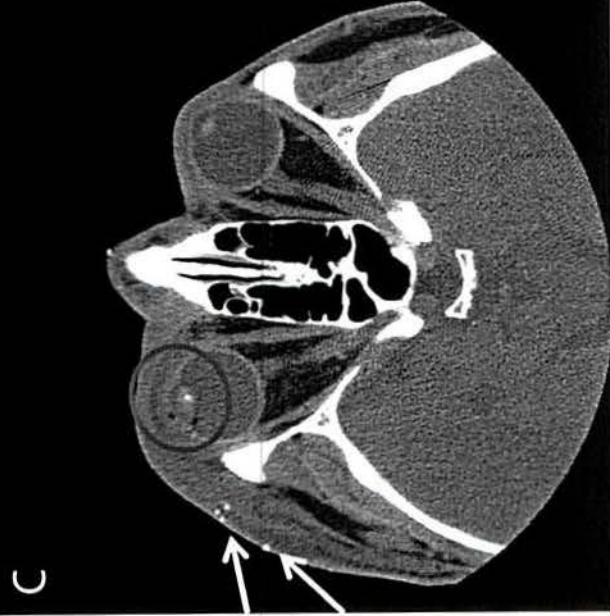


A

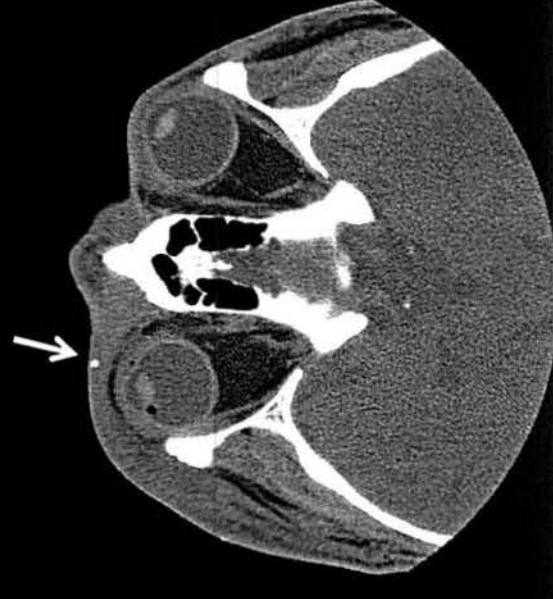

B

30 year-old male involved in an IED blast injury. Coronal (A) and axial (B) non-enhanced CT of orbits shows numerous superficial penetrating low velocity metallic fragments (arrows) resulting in left globe rupture (circle).



C



D

26 year-old male involved in an IED blast injury. Axial non-enhanced CT (C, D) of orbits shows a few superficial penetrating low velocity projectiles. One penetrating the right globe results in traumatic cataract (circle).

Outline

- Primary Penetrating Injury Patterns
 - Bullet ballistic trauma
 - Low velocity
 - High velocity
 - Blast-related fragment injury
 - Stab wounds
 - Non-metallic projectiles
- Complications
 - Secondary bone missiles
 - Cerebral swelling & herniation syndromes
 - Infection
 - Vascular injury
 - Ballistic fragment migration
- Prognostication
- Treatment
- Considerations
 - MR Safety

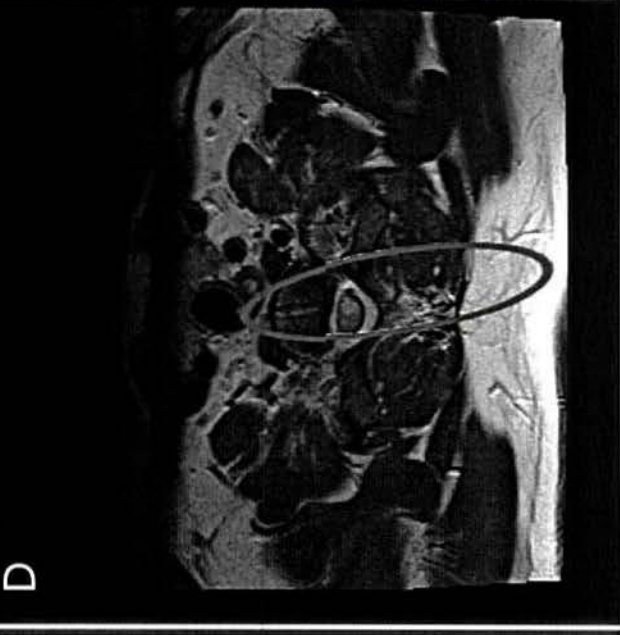
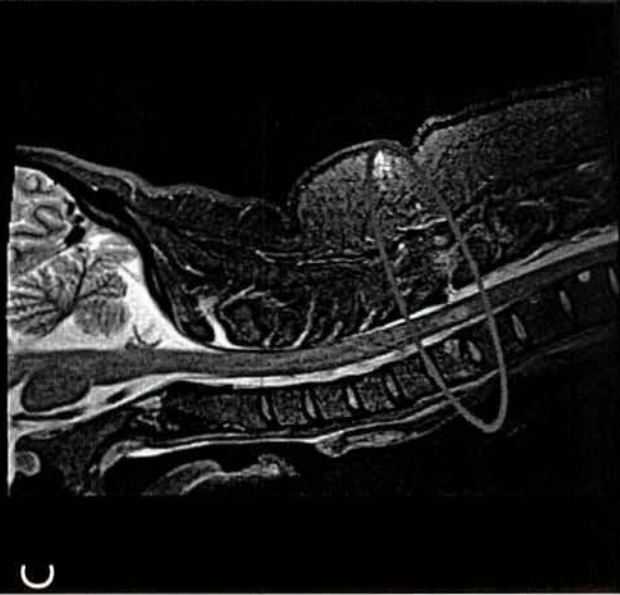
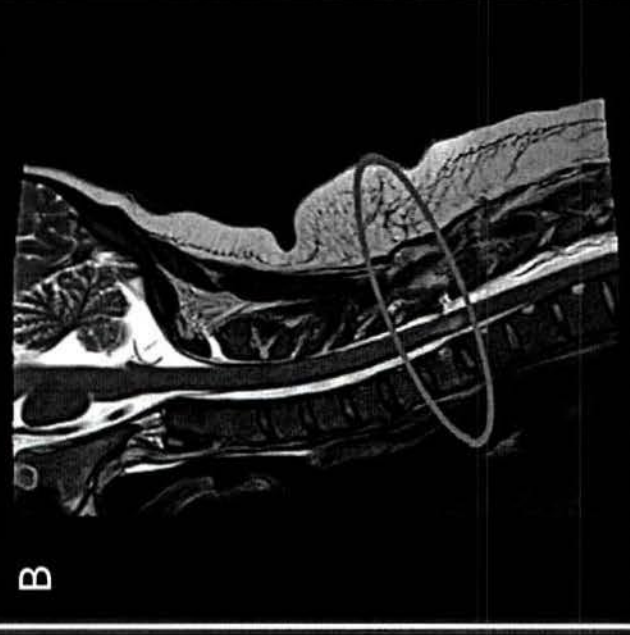
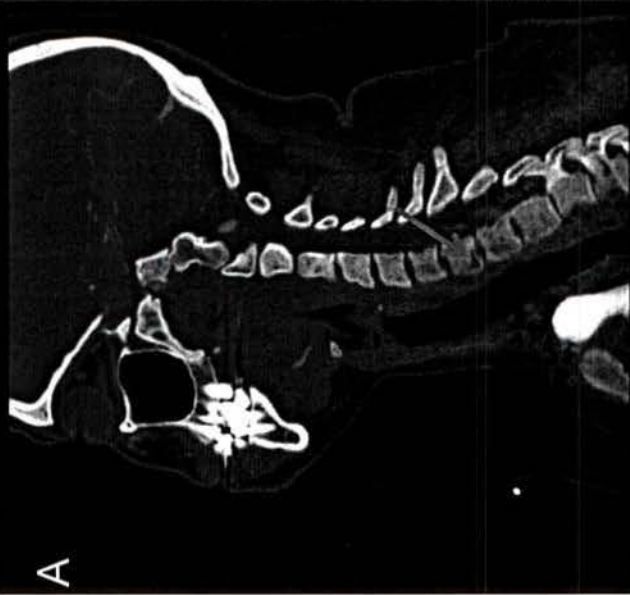Stab Injury

- Ultra low velocity (usually $<100\text{m/s}$) penetrating injuries due to knives, nails, spikes, scissors, and other assorted objects
- Unlike higher velocity missile injuries, there is no concentric dissipation of kinetic energy, and injury is largely limited to laceration of soft tissues along wound tract
- Intracranial injury usually limited to regions where bone is more penetrable (orbit, skull base foramina, floor of anterior cranial fossa, and squamous temporal bone)

Stab Injury

- Blind removal of object is not commonly practiced
- Imaging with unenhanced CT and CTA is generally recommended prior to removal
 - Identify surrounding anatomy and preventing further injury upon removal
- Imaging is also critical for non-retained foreign objects to identify wound tract, as entry site may appear disproportionately small compared to extent of internal injury

Case 5: Stab Injury



25 year-old female with left hemiplegia and contralateral sensory deficits after knife stabbing injury to the posterior neck. Sagittal CT (A) shows linear fracture defect (arrow) at C7 without obvious soft tissue wound tract or retained foreign body. Subsequent cervical MRI with sagittal T2WI (B) and sagittal STIR images (C) shows the linear T2 high signal knife puncture tract extending from the dorsal paraspinal soft tissues through the posterior spinal canal, left half of spinal cord, and C7 vertebral body (circle). Elevated intramedullary T2 signal is seen within the cervical spinal cord at the level of the penetrating injury the level. (D) Cervical spine T2WI shows the knife tract involving all three spinal columns, with transection of the left cervical cord, concordant with patient's Brown-Séquard syndrome.

Outline

- Primary Penetrating Injury Patterns
 - Bullet ballistic trauma
 - Low velocity
 - High velocity
 - Blast-related fragment injury
 - Stab wounds
 - Non-metallic projectiles
- Complications
 - Secondary bone missiles
 - Cerebral swelling & herniation syndromes
 - Infection
 - Vascular injury
 - Ballistic fragment migration
- Prognostication
- Treatment Considerations
 - MR Safety

Non-metallic Projectiles

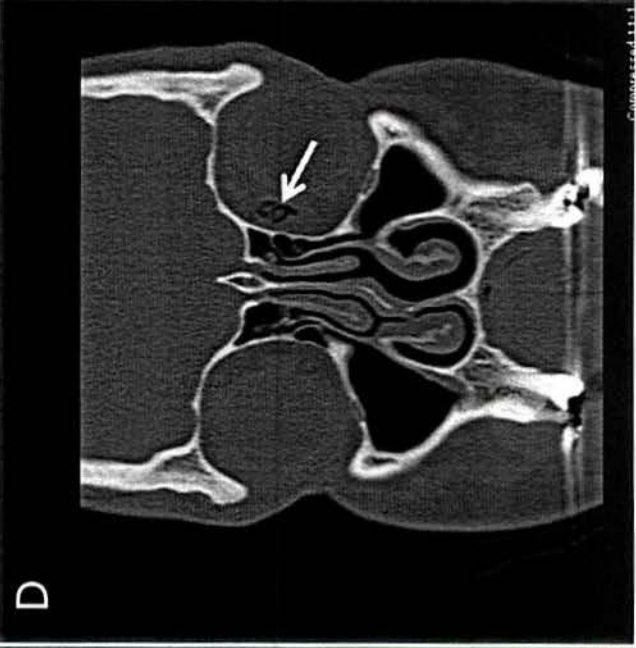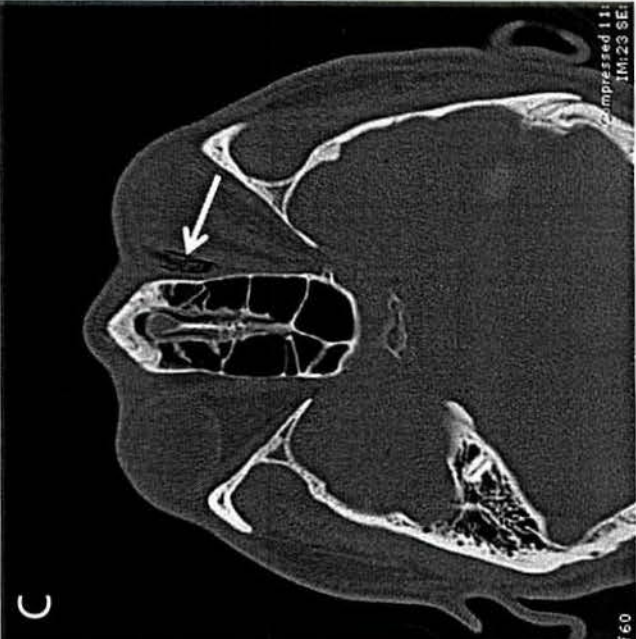
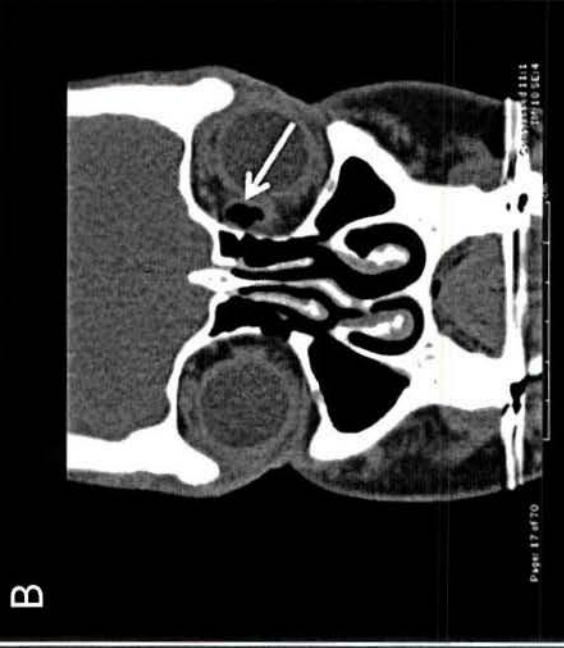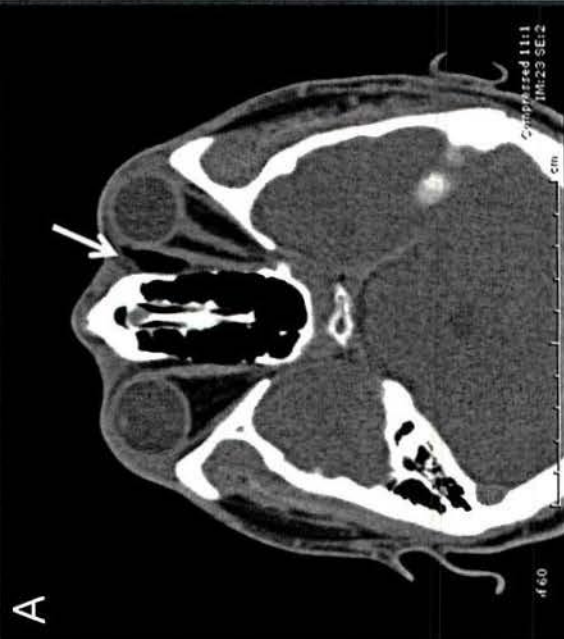Wood fragments

- Layers of organic fibers forming interstices that are often filled with air depending on moisture content within fragment
- Ultrasound: hypoechoic echotexture
- CT: air density
- MRI: susceptibility artifact
- May be confused with soft tissue emphysema (wide window on CT can avoid this pitfall)

Glass fragments

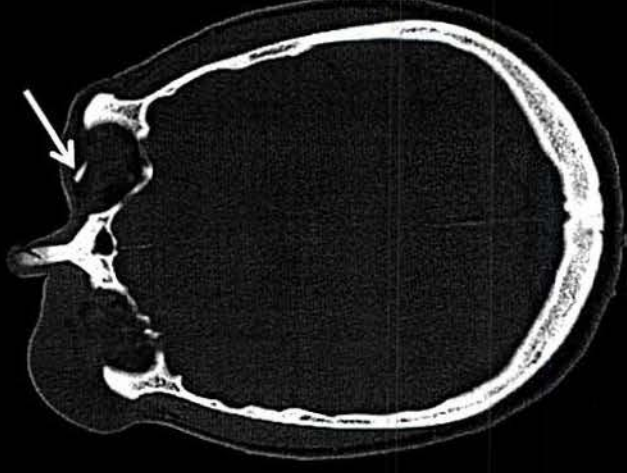
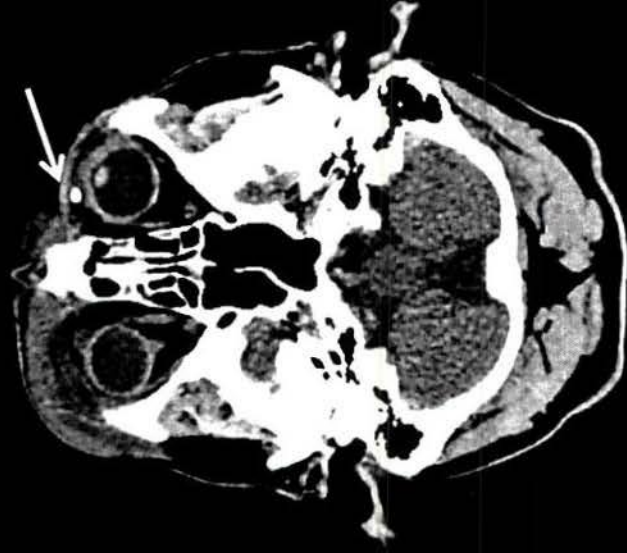
- Often underdiagnosed
- Misconceptions that lucent glass cannot be detected radiographically
- CT most sensitive exam
- Appearance varies based on composition, ranging from approximately 80-550 HU
- Hyperattenuating to surrounding soft tissues
- Ultrasound may appear hyperechoic

Case 6: Non-metallic Projectiles



31 year-old male with orbital injury while running away from police through thick vegetation. Axial (A) and coronal (B) unenhanced CT images at soft tissue windows shows air density within the medial right orbit (arrows). Axial (C) and coronal (D) unenhanced CT images at bone windows shows an interstitial pattern of hypodensity in region of emphysema (arrows) consistent with a retained wood fragment.

Case 7: Non-metallic Projectiles



59 year-old male pedestrian hit by automobile. A linear hyperattenuating focus (arrows) is seen in the pre-septal soft tissues in the left orbit in setting of predominantly right sided peri-orbital trauma. No fracture donor site could be identified on the left side to account for finding, raising suspicion for foreign body. A small piece of windshield glass was subsequently removed from beneath left eyelid.

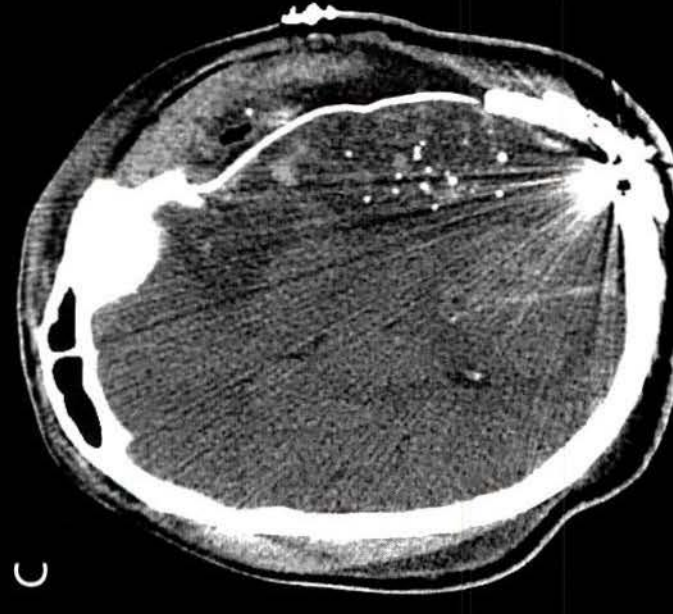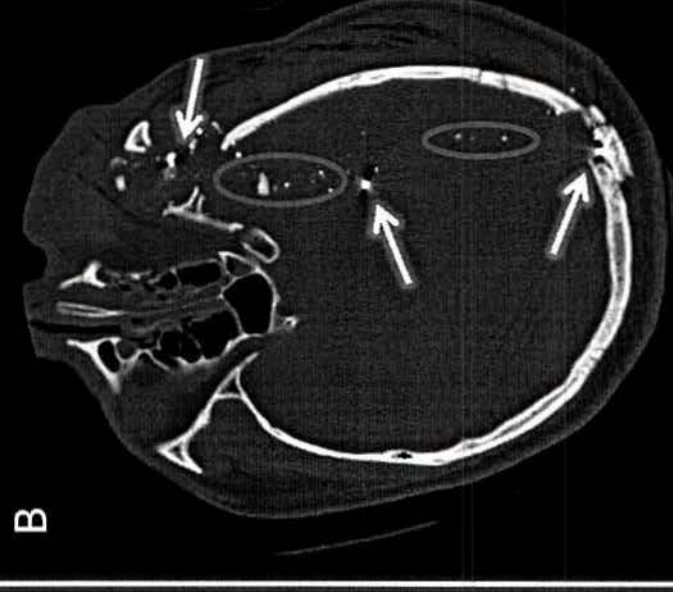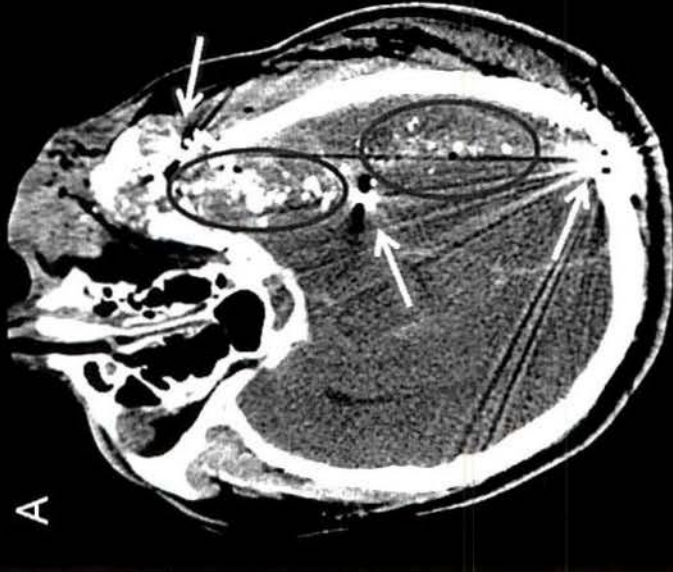Outline

- Primary Penetrating Injury Patterns
 - Bullet ballistic trauma
 - Low velocity
 - High velocity
 - Blast-related fragment injury
 - Stab wounds
 - Non-metallic projectiles
- Complications
 - Secondary bone missiles
 - Cerebral swelling & herniation syndromes
 - Infection
 - Vascular injury
 - Ballistic fragment migration
- Prognostication
- Treatment
- Considerations
- MR Safety

Secondary Bone Missiles

- Kinetic energy deposited to the calvarium by craniocerebral ballistics fracture, fragment, and displace bone
- Bone fragments acquire twice as much kinetic energy as an equivalent length of soft tissue due to density of bone being twice that of soft tissue
- Bone fragments act as secondary missiles and further propagate damage to brain parenchyma and may injure blood vessels within their trajectory

Case 8: Secondary Bone Missiles



37 year-old male with gunshot to the left orbit. Axial non-enhanced CT images with soft-tissue (A) and bone windows (B) at presentation show a traumatic left globe rupture, subarachnoid and subdural hemorrhage, blown-out left lateral orbital wall and sphenoid bone fractures, bone fragments (circles) driven through the parenchyma as secondary missiles along the bullet trajectory, forming temporary cavitation. Bullet fragments are also seen (arrows). Follow-up axial CT image 1-week later (C) shows hemorrhagic contusions and ischemic/necrotic parenchyma along the cavitation tract formed by the bone missiles, in addition to new left cranioplasty findings.

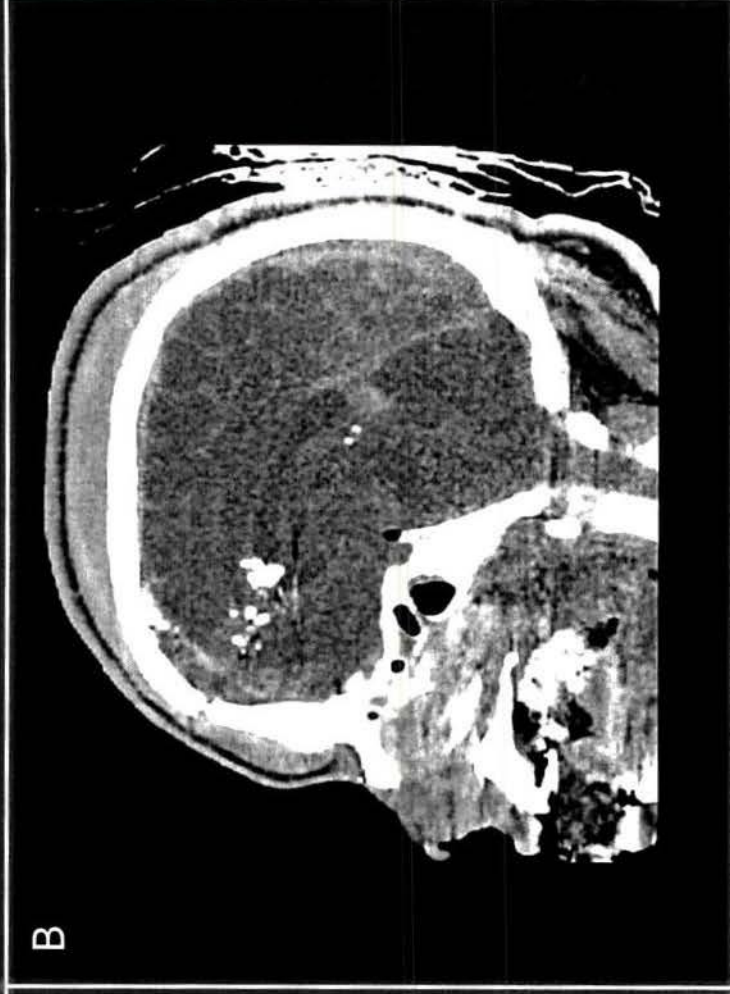
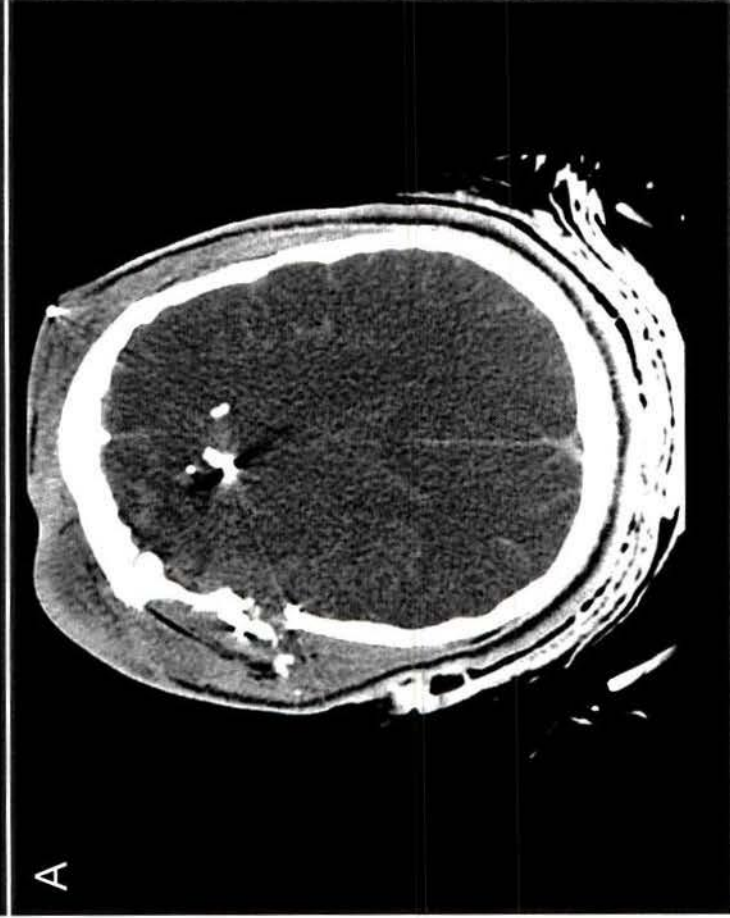
Outline

- Primary Penetrating Injury Patterns
 - Bullet ballistic trauma
 - Low velocity
 - High velocity
 - Blast-related fragment injury
 - Stab wounds
 - Non-metallic projectiles
- Complications
 - Secondary bone missiles
 - Cerebral swelling & herniation syndromes
 - Infection
 - Vascular injury
 - Ballistic fragment migration
- Prognostication
- Treatment
- Considerations
 - MR Safety

Cerebral Swelling and Herniation Syndromes

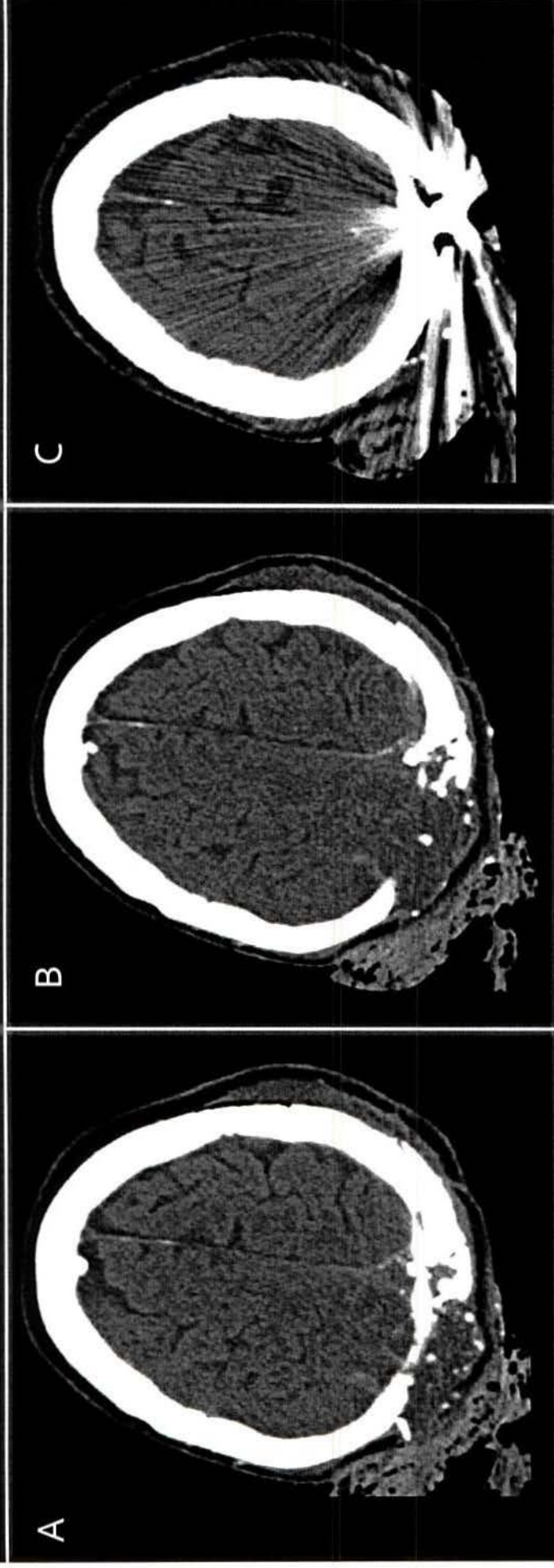- Gunshot victims may present to ED with apnea and bradycardia due to brainstem compression and tonsillar herniation
- Rapid elevation in intracranial pressure caused by brain expansion and cavitation often result in coma or death
- Brainstem dysfunction resulting in respiratory arrest may occur with low velocity ballistics and without damage to eloquent structures due to propagation of damage remote from the ballistic tract

Case 9: Cerebral Swelling and Herniation Syndromes



15 year-old male with gunshot to the head. Glasgow Coma Scale of 3 at the scene with fixed pupils and absence of brainstem reflexes. Axial (A) and sagittal (B) CT images in the ED show bullet fragments embedded in the genu of the corpus callosum and cingulate gyrus, and a blown-out exit wound skull fracture on the right. Cerebral sulci and cerebellar fissures and ventricles are effaced from extensive swelling. Descending transtentorial and tonsillar herniation is evident. Diffuse loss of grey-white matter differentiation is consistent with diffuse hypoxic-ischemic injury.

Case 10: Cerebral Swelling and Herniation Syndromes



97 year-old female with gunshot to the occiput. Axial CT images of the head at multiple levels (A-C) show bony destruction of the right parietal bone, and metallic streak artifact from a lodged bullet fragment. Brain swelling and edema results in herniation of the right parietal lobe through the defect, consistent with a traumatic encephalocele.

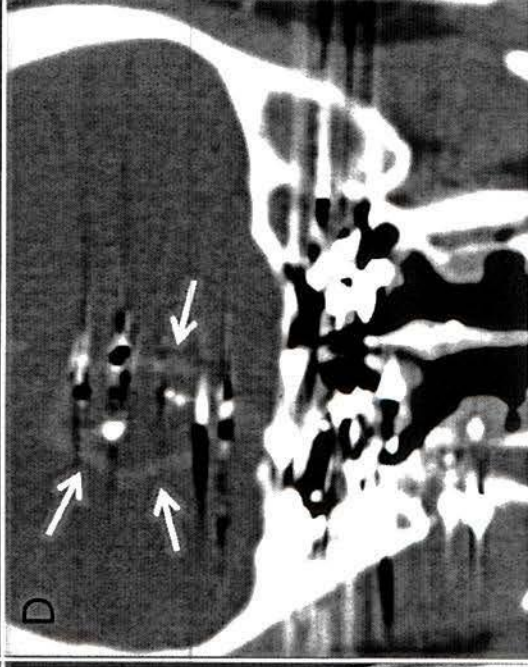
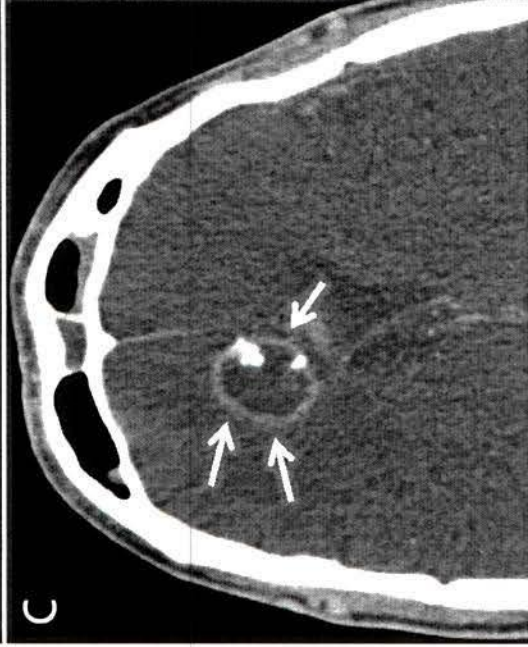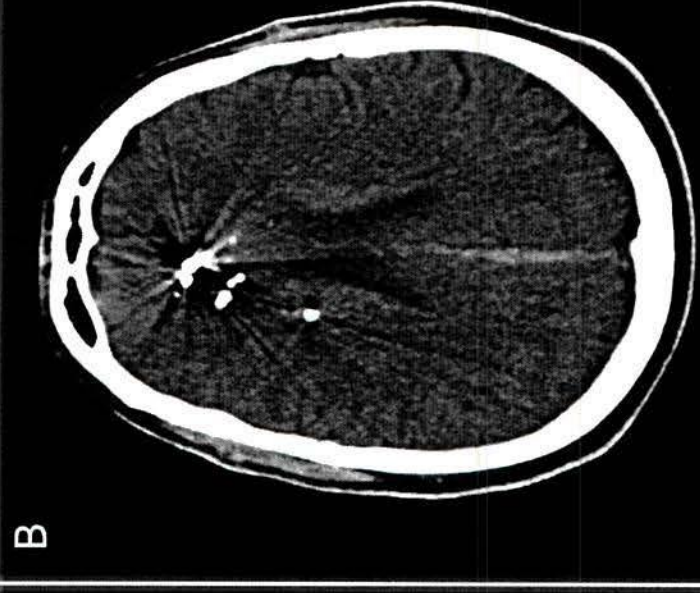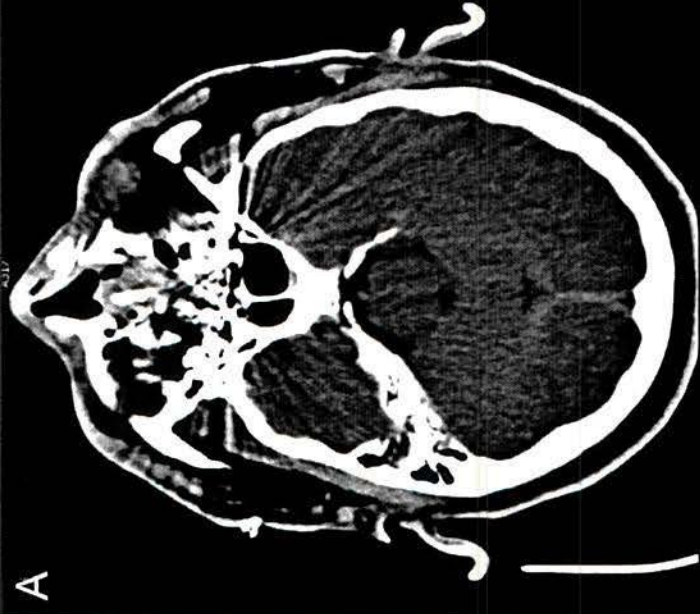Outline

- Primary Penetrating Injury Patterns
 - Bullet ballistic trauma
 - Low velocity
 - High velocity
 - Blast-related fragment injury
 - Stab wounds
 - Non-metallic projectiles
- Complications
 - Secondary bone missiles
 - Cerebral swelling & herniation syndromes
 - Infection
 - Vascular injury
 - Ballistic fragment migration
- Prognostication
- Treatment Considerations
 - MR Safety

Infection

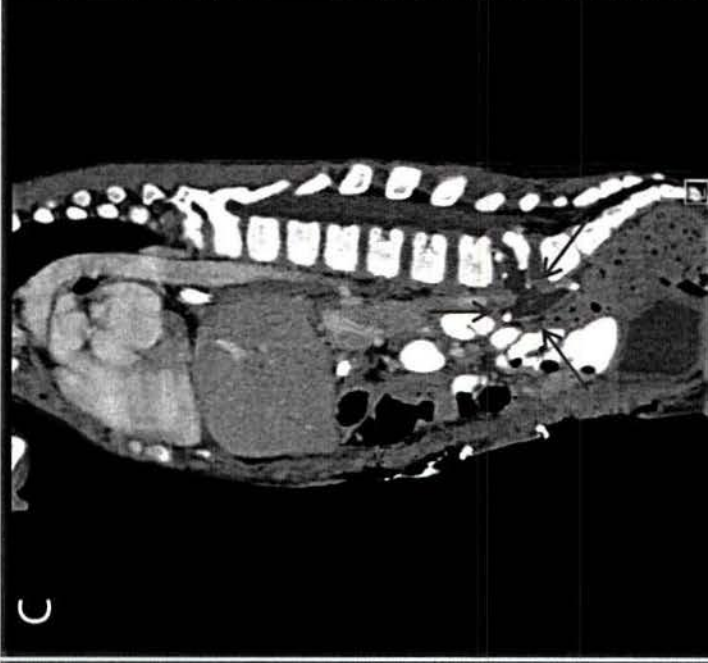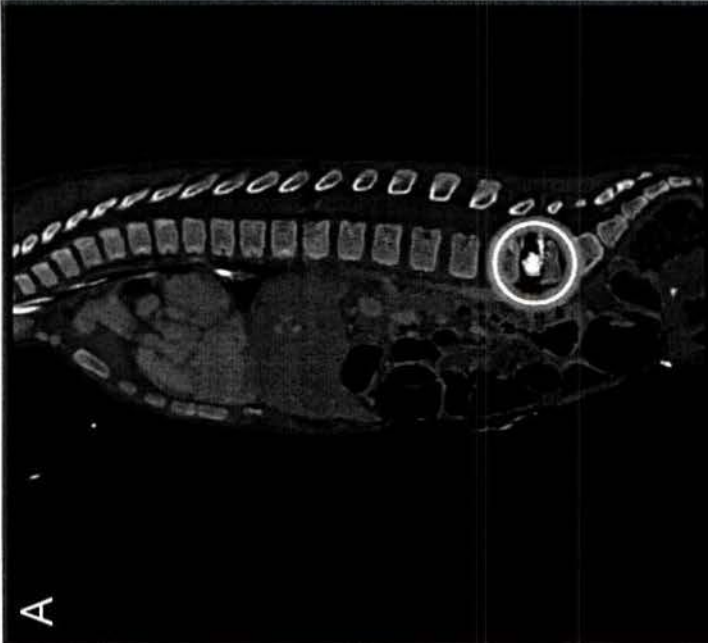
- Infectious complications of penetrating injury increases morbidly and mortality, and is not uncommon (1-5% civilian vs. 4-11% military)
- CSF leak, sinus injury, transventricular injury, and missile tracks crossing midline increase risk for infection
- Abscess, meningitis/ventriculitis, and wound infections may develop due to contamination of foreign bodies or skin, hair, or bone driven along the path of the missile
- *Staphylococcus aureus* is most common organism, but gram negative bacteria also frequent cause

Case 11: Infection



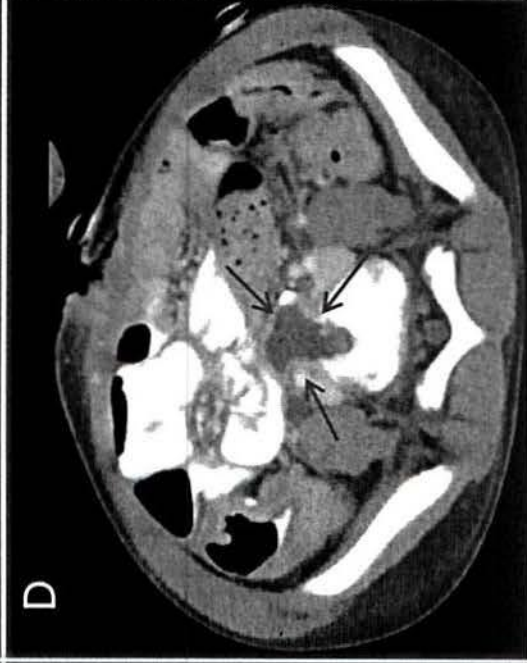
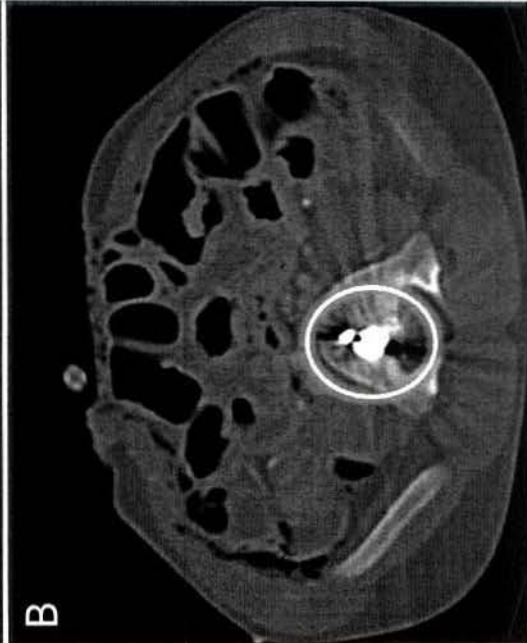26 year-old male with gunshot to the midface. Axial non-enhanced CT images (A & B) at presentation show trans-sinus bullet trajectory with fragments embedded in the paranasal sinuses and brain. The patient experienced progressive headache, fevers and leukocytosis 2-weeks after injury. Axial (C) and coronal (D) contrast-enhanced CT of the face at this time show a rim-enhancing collection surrounding the retained bullet fragments, consistent with a cerebral abscess (arrows).

Case 12: Infection



6 year-old boy with gunshot to the abdomen. Sagittal (A) and axial (B) contrast-enhanced CT images of the spine at presentation show a bullet traversing the superior endplate of L4 and

embedding in the L4-L5 intervertebral disc space (circle). Patient developed fever and leukocytosis 2 weeks following surgical retrieval of bullet. Sagittal (C) and axial (D) contrast-enhanced CT show a rim-enhancing ventral paraspinous collection, consistent with an abscess (arrows).



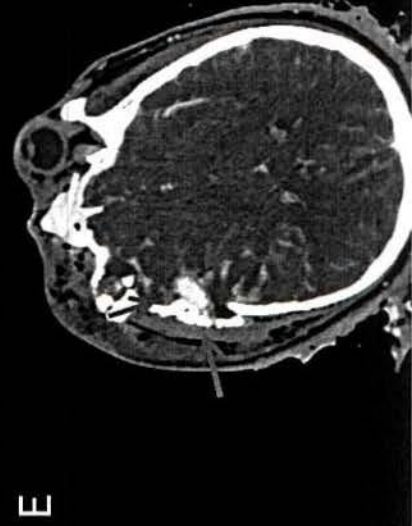
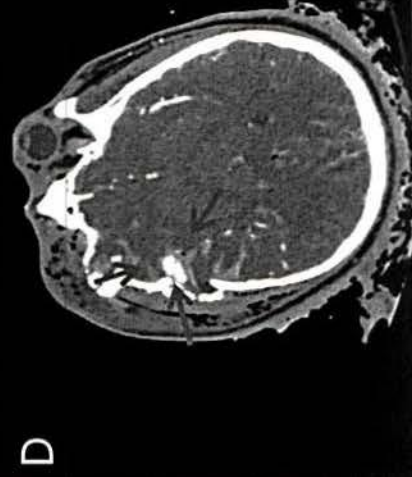
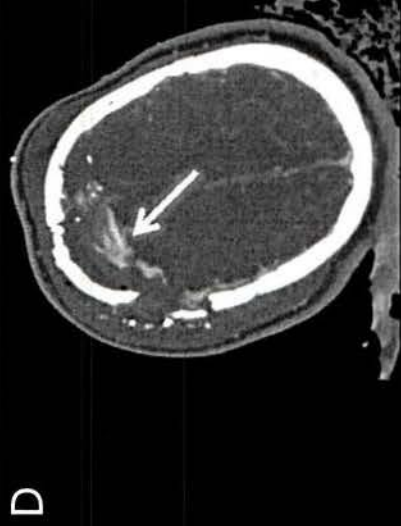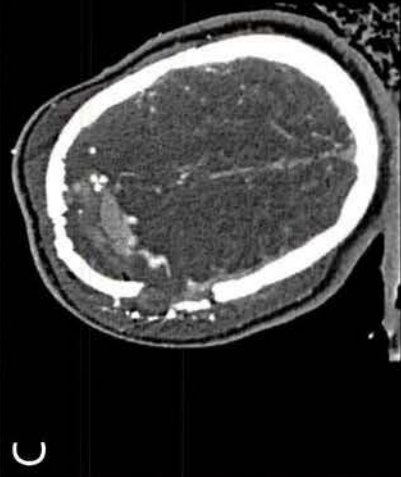
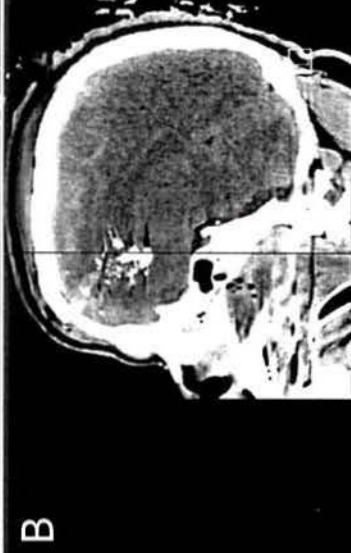
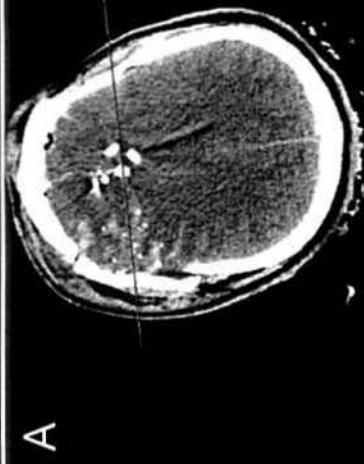
Outline

- Primary Penetrating Injury Patterns
 - Bullet ballistic trauma
 - Low velocity
 - High velocity
 - Blast-related fragment injury
 - Stab wounds
 - Non-metallic projectiles
- Complications
 - Secondary bone missiles
 - Cerebral swelling & herniation syndromes
 - Infection
 - Vascular injury
 - Ballistic fragment migration
- Prognostication
- Treatment
- Considerations
 - MR Safety

Cerebrovascular Injury

- The incidence of traumatic pseudoaneurysm formation after severe penetrating injury is estimated at 20-50% in some groups
- The spectrum of vascular injury includes pseudoaneurysm formation, active extravasation, dissection, venous injury and thrombosis, and traumatic arteriovenous fistula
- Vascular injury more likely when missile or penetrating object trajectory close to the Sylvian fissure, cavernous and other dural venous sinuses, or traverses the midline

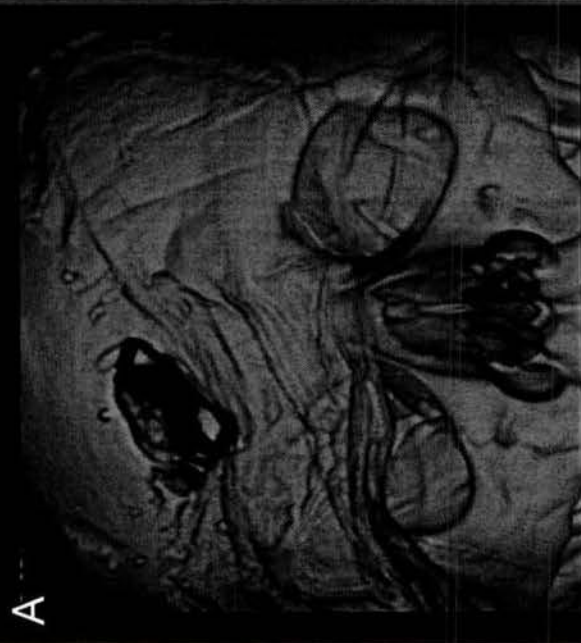
Case 13: Cerebrovascular Injury



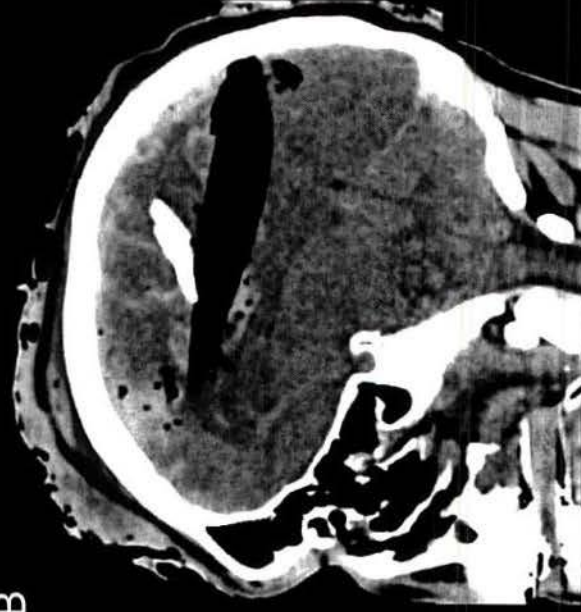
31 year-old male with gunshot to the head. Axial (A) and sagittal (B) non-enhanced CT images show bullet and bone fragments in pericongulate region, and parenchymal and SAH.

Arterial-phase (C & D) and delayed (D & E) CTA images show active extravasation from the superior sagittal sinus (green arrow) and a pseudoaneurysm of a opercular branch of the right MCA (pink arrows) due to injury along the missile trajectory. The inferior sagittal sinus was also torn (not shown).

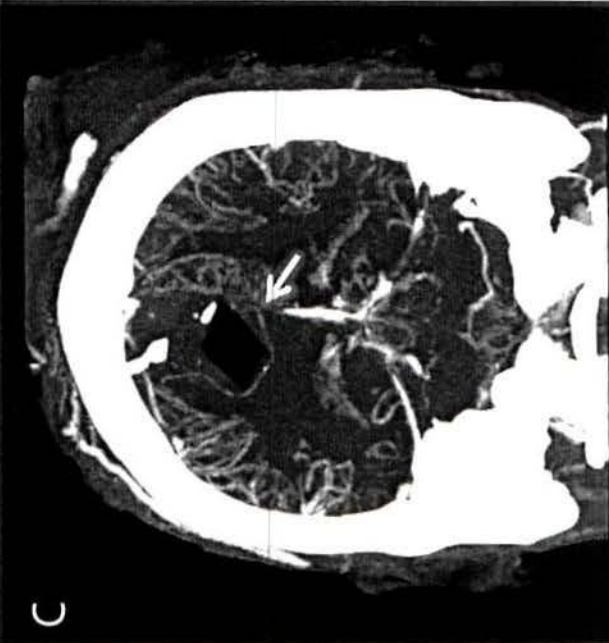
Case 14: Cerebrovascular Injury



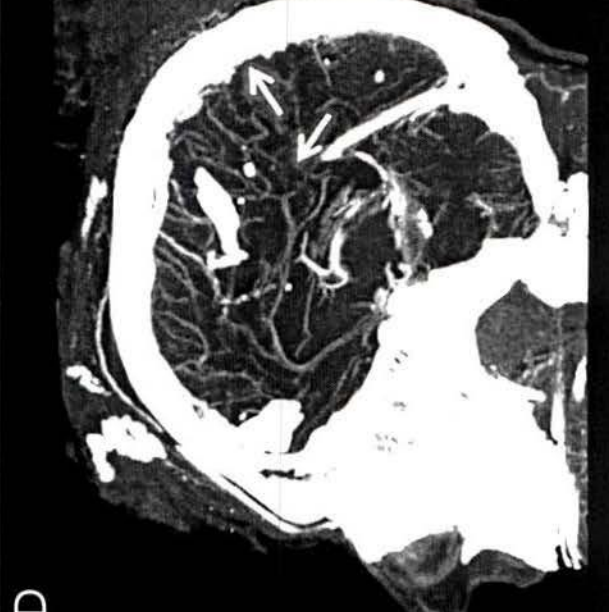
B



42 year-old male passenger in MVC crash with a tree. 3D reconstruction (A) and sagittal (B) CT images show a tree branch penetrating the right frontal lobe and extending through the right cerebral

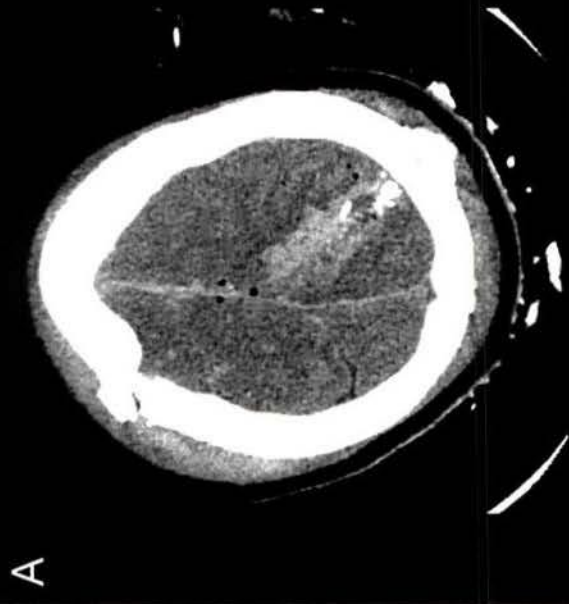


D

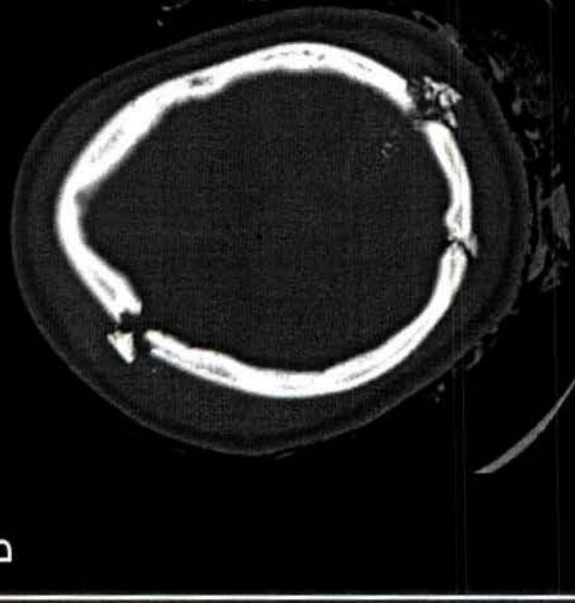


hemisphere. Coronal (C) and sagittal (D) CTA MIP images show traumatic injury and thrombosis of the inferior sagittal sinus and posterior superior sagittal sinus (arrows) due to laceration by the wood

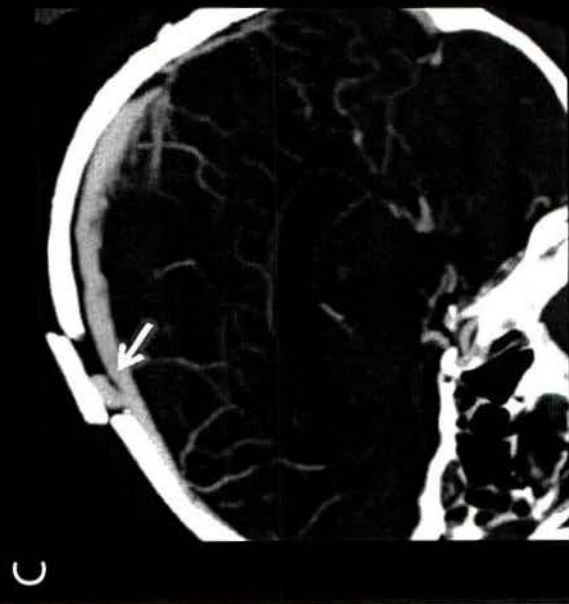
Case 15: Cerebrovascular Injury



B

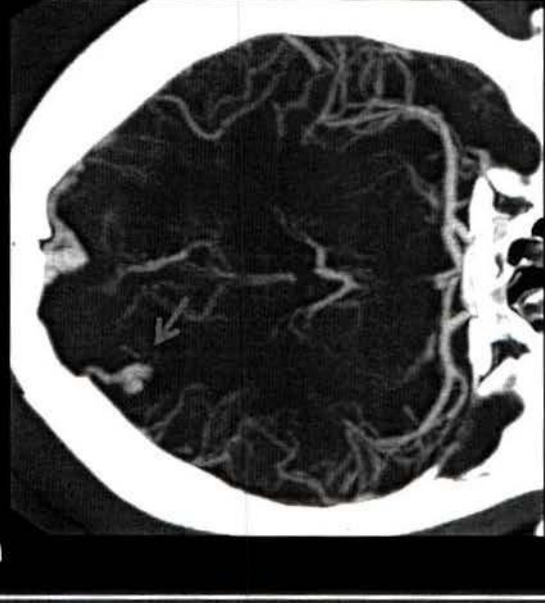


22 year-old male with gunshot to the head. Axial unenhanced CT images at soft tissue (A) and bone windows (B) show the left parietal entry site and right frontal exit site, with a hemorrhagic tract traversing the midline.



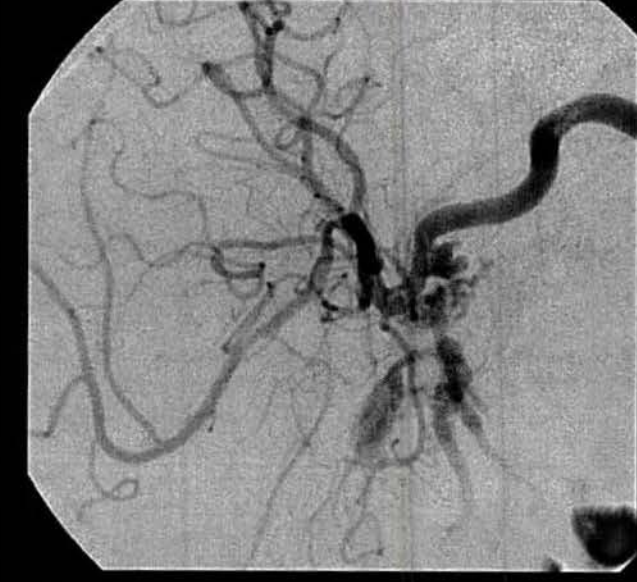
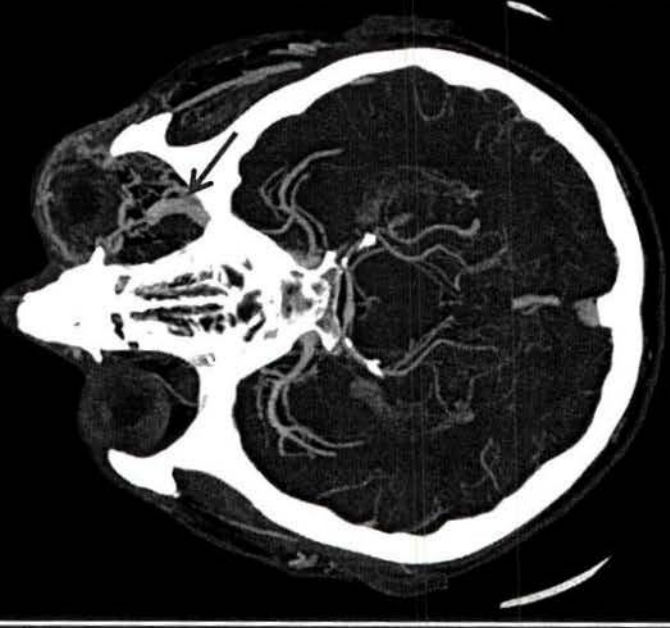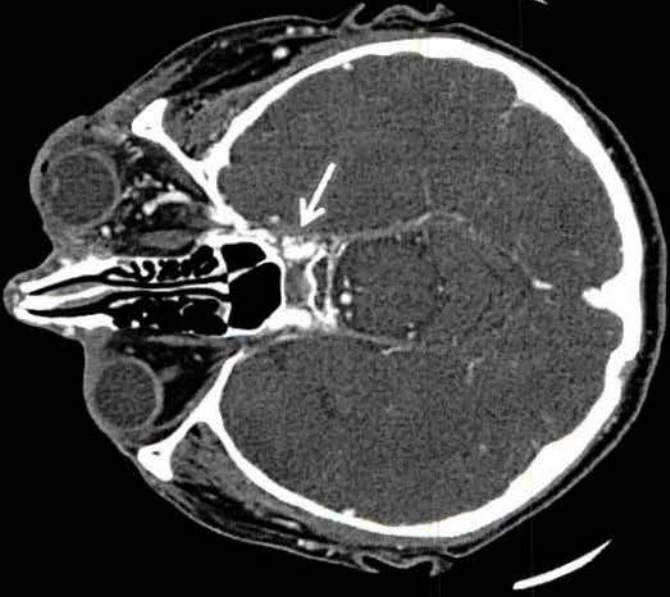Sagittal (C) and coronal (D) CTA MIP images show a venous pseudoaneurysm of the superior sagittal sinus (green arrow)

D



protruding through the skull defect and an arterial pseudoaneurysm (pink arrow).

Case 16: Cerebrovascular Injury

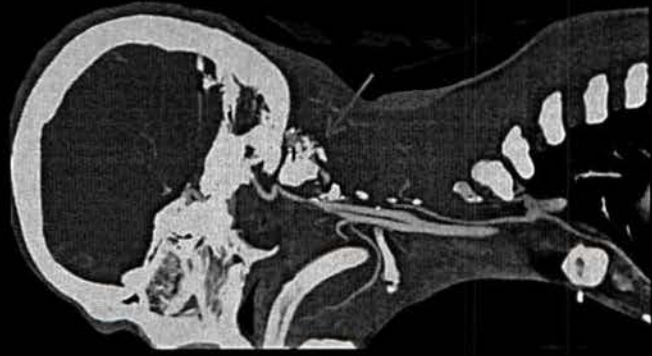

44 year-old male presenting with pulsatile exophthalmos 3 weeks after sustaining multiple facial injuries with a broken bottle in a bar fight. Axial CTA image (A) and axial CTA MIP (B) show marked left exophthalmos, increased number of vessels around the left cavernous sinus (green arrow), and arterialized flow in the left superior ophthalmic vein (pink arrow). Lateral projection image of a left ICA injection on conventional angiogram (C) depicts abnormal filling of the left superior and inferior ophthalmic veins due to a direct cavernous-carotid fistula.

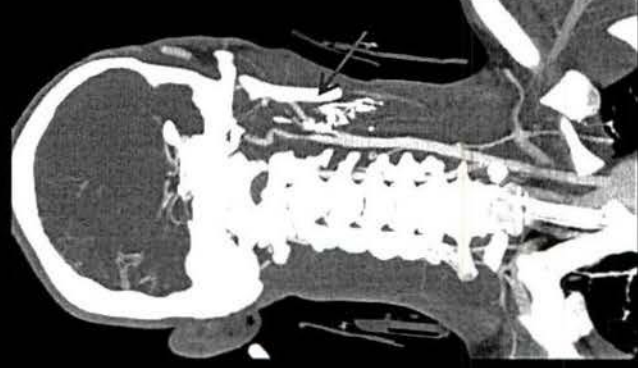Cervical Vascular Injury

- CTA has dramatically limited non-therapeutic neck explorations in cases of penetrating cervical injuries with a high sensitivity and specificity in all reports (>90%)
- Up to 25% of penetrating cervical injuries result in arterial injury (80% carotid vs. 43% vertebral arteries)
- Carotid artery injuries carry a 15% risk of stroke, and 22% risk of death
- Venous injury is seen in 16-18% of patients, and is the most commonly missed vascular injury in penetrating neck trauma

Case 17: Cervical Vascular Injury

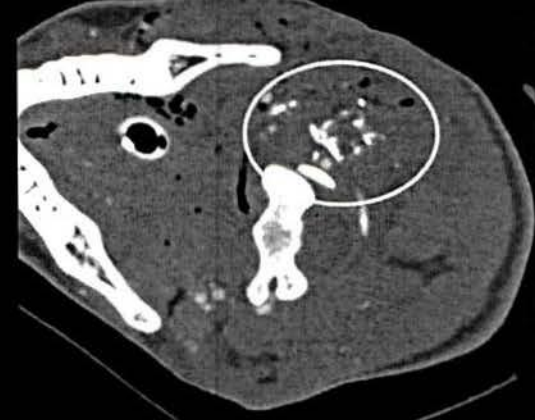


B

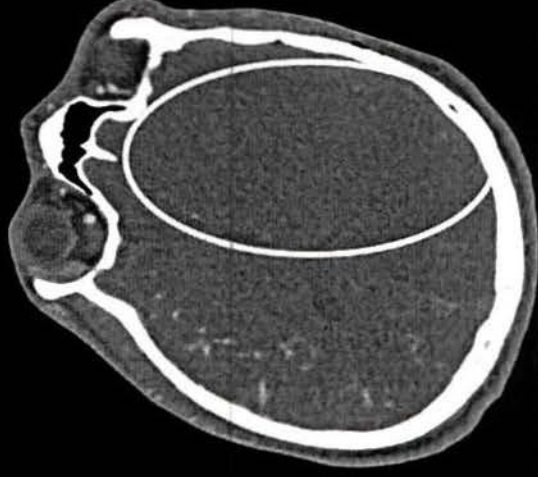

23 year-old male with self inflicted gunshot injury.

Sagittal (A) and coronal (B) CTA MIP images show a traumatic dissection of the left proximal cervical ICA (arrows). Axial CTA images of the head (C & D) show multiple bone fragments surrounded the left atlantoaxial joint (yellow circle) and a large left holohemispheric infarct (blue circle) from a left anterior circulation infarct and left PCA infarct resulting from descending transtentorial herniation (not shown).



C



D

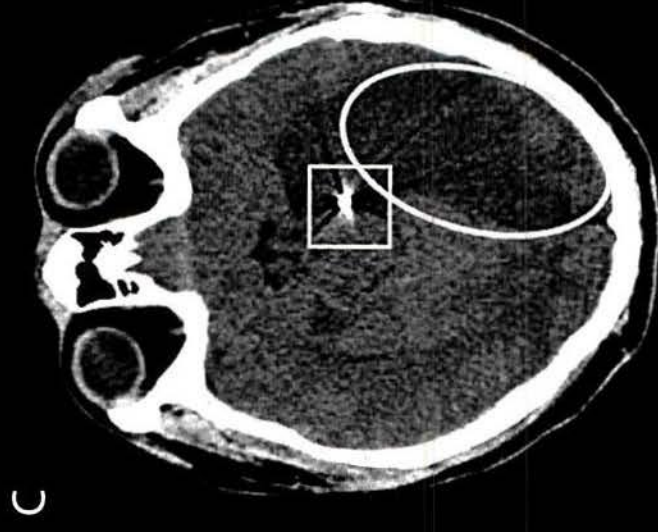
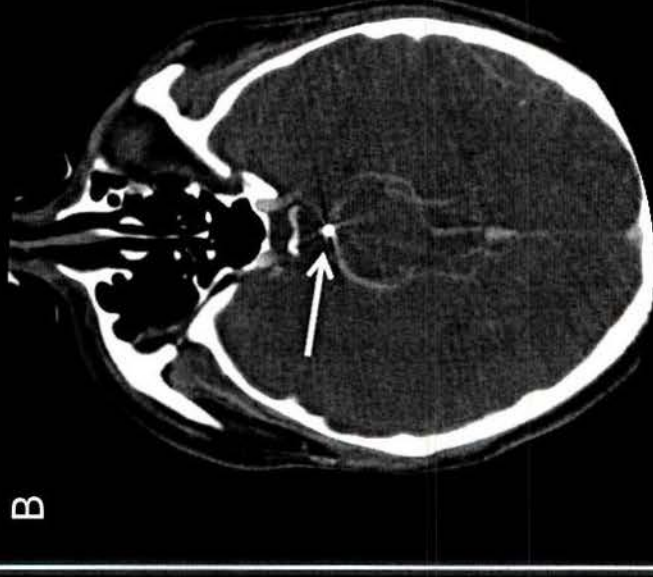
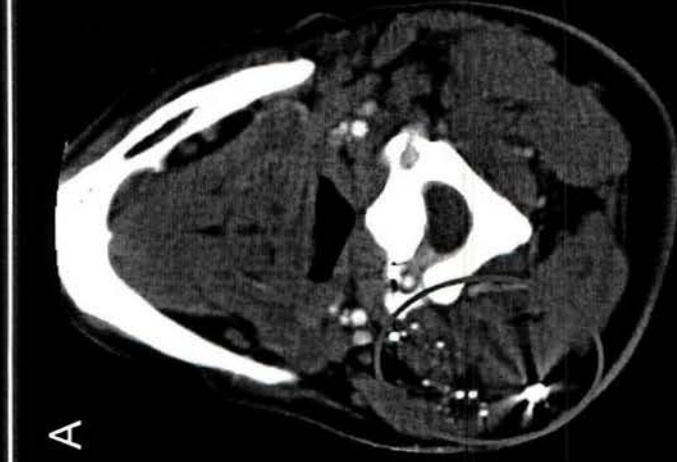Outline

- Primary Penetrating Injury Patterns
 - Bullet ballistic trauma
 - Low velocity
 - High velocity
 - Blast-related fragment injury
 - Stab wounds
 - Non-metallic projectiles
- Complications
 - Secondary bone missiles
 - Cerebral swelling & herniation syndromes
 - Infection
 - Vascular injury
 - Ballistic fragment migration
- Prognostication
- Treatment
- Considerations
- MR Safety

Ballistic Fragment Migration

- Vascular embolism of ballistic fragments is a rare complication that occurs if projectile is of small enough size, and low enough velocity to embed within an arterial or venous lumen
- Embolism of intravascular ballistic fragment usually occurs immediately upon entrance into vessel, however delayed embolism of days to months after injury have been reported
- Intravascular ballistic fragment may lead to vascular occlusion, thrombosis, infarct, septicemia, or lead toxicity
- Ballistic fragments may also migrate within the ventricular system, and can result in obstructive hydrocephalus at level of foramen of Monro or at the cerebral aqueduct

Case 18: Ballistic Fragment Migration



20 year-old active duty soldier presenting with signs of penetrating neck injury after an improvised explosion device (IED) attack. Axial CTA image (A) demonstrates metallic IED fragments in the posterior neck (circle) adjacent to right vertebral artery. Additional metallic fragment (B) is identified in the basilar artery (arrow). 24 hours later patient's neurological status deteriorated and unenhanced CT (C) shows interval embolization of IED fragment to left posterior cerebral artery (square) with associated occipital infarct (circle).

Outline

- Primary Penetrating Injury Patterns
 - Bullet ballistic trauma
 - Low velocity
 - High velocity
 - Blast-related fragment injury
 - Stab wounds
 - Non-metallic projectiles
- Complications
 - Secondary bone missiles
 - Cerebral swelling & herniation syndromes
 - Infection
 - Vascular injury
 - Ballistic fragment migration
- Prognostication
- Treatment Considerations
 - MR Safety

Predicative Features of Mortality

Imaging

- Midline shift >10mm
- Ballistic tract crosses the "Zona Fatalis"
- Geographic center of brain approximately 4cm above dorsum sella
- Penetrating injury to the posterior fossa
- Effacement of basal cisterns portends a poor prognosis
- Presence of SAH
- Increased number of lobes involved

Clinical

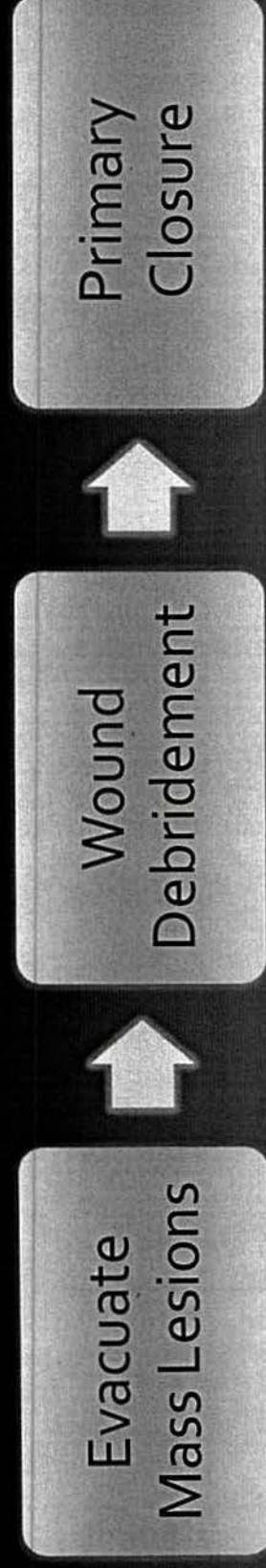- GCS score
- Absent pupillary reflexes
- Missile trajectory
- Self-inflicted gunshot wounds
- Removal of penetrating object at time of stabbing injury

Outline

- Primary Penetrating Injury Patterns
 - Bullet ballistic trauma
 - Low velocity
 - High velocity
 - Blast-related fragment injury
 - Stab wounds
 - Non-metallic projectiles
- Complications
 - Secondary bone missiles
 - Cerebral swelling & herniation syndromes
 - Infection
 - Vascular injury
 - Ballistic fragment migration
- Prognostication
- Treatment Considerations
 - MR Safety

Treatment

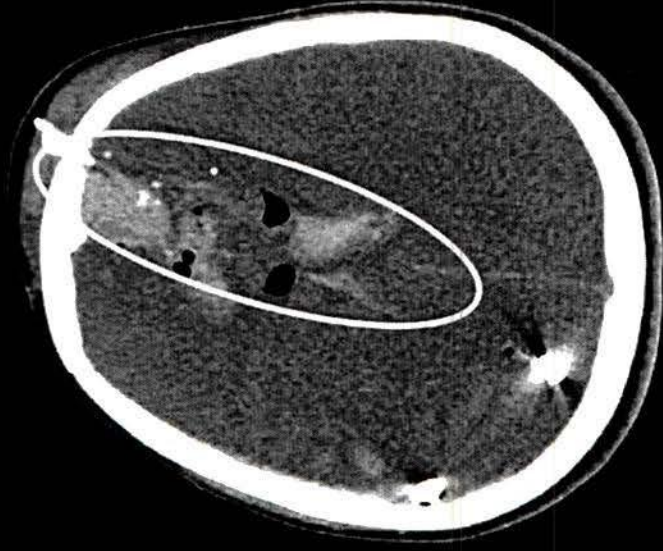- Small penetrating injuries without significant intracranial pathology can often be managed with local wound care
- Broad spectrum antibiotic prophylaxis for 5-14d
- Most critical care management (e.g. ICP monitoring, anti-epileptic prophylaxis, etc.) is extrapolated from the severe TBI literature



Surgical Principles

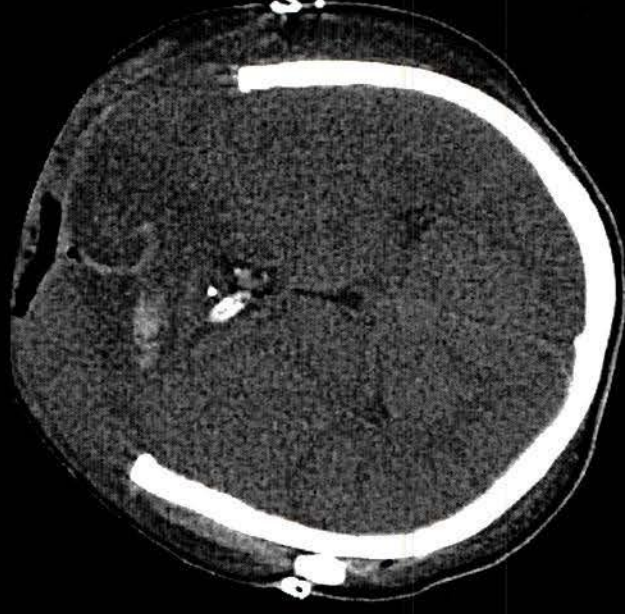
- Craniotomy (versus craniectomy) with debridement is often sufficient in the patient without midline shift or signs of intracranial hypertension
- Debridement and water tight dural closure: Important when there is an air sinus injury or complex laceration. Ventricular injuries are susceptible to CSF leaks. CSF leak or fistula correlates with higher infection rate and mortality
- Evacuate large hematomas. Only perform superficial debridement of bone and foreign bodies. Debridement of devitalized brain tissue should only be performed to allow for appropriate hemorrhage control and 2-layer closure
- Consider retrieval of large accessible bullet fragments that may pose future risk for future migration (ventricle), lead toxicity (ventricle, intervertebral disc spaces), and for possible forensic analysis
- Always be cognizant of imaging findings of arterial or venous injury or air sinus injury. Acute and delayed vascular injuries should be suspected when trajectory is near vascular territories such as Sylvian fissure and supraclinoid carotid

Case 19: Surgical Principles



A

B



20 year-old male status post gunshot wound to head. Axial noncontrast CT (A) demonstrates hemorrhagic ballistic tract (circle) crossing the bilateral frontal lobes, ventricles and the mid-coronal plane with associated intraparenchymal, intraventricular and subarachnoid hemorrhage. Despite numerous negative imaging predictors, patient was deemed salvageable secondary to favorable admission GCS status, and subsequently underwent craniectomy and hematoma evacuation (B).

Outline

- Primary Penetrating Injury Patterns
 - Bullet ballistic trauma
 - Low velocity
 - High velocity
 - Blast-related fragment injury
 - Stab wounds
 - Non-metallic projectiles
- Complications
 - Secondary bone missiles
 - Cerebral swelling & herniation syndromes
 - Infection
 - Vascular injury
 - Ballistic fragment migration
- Prognostication
- Treatment
- Considerations
- MR Safety

MRI Safety Concerns

- Specific concerns resulting from penetrating neurotrauma are largely related to the consequences of retained metallic foreign bodies
- Clinical decision making regarding MR imaging should consider risks versus benefits of MR imaging
- Retained metallic fragments may experience:
 - Translational or rotational forces (static magnetic field)
 - RF heating
 - Magnetic susceptibility artifacts
- Retained metallic foreign bodies should be assessed by CT or radiography prior to MR to determine the following:
 - Size- affects magnitude of forces
 - Geometry- affects propensity of RF heating (coiled object)
 - Proximity to critical anatomy- vasculature, eloquent territory, nerves, spinal cord

Ballistic Foreign Bodies

- Lead is not ferromagnetic
- Bullet fragments may contain ferromagnetic components from steel or copper alloys of the jacket
- Foreign bodies from pellet gun injuries may also be ferromagnetic
- Retained fragments related to combat or terrorism injuries usually contain ferromagnetic components
- Heating of ballistic fragments has not been shown to be clinically significant
- Static magnetic field effects on ferromagnetic ballistic fragments may affect subsequent forensic analysis

References

1. Alvis-Miranda HR, Agrawal A, et al. Craniocerebral Gunshot Injuries; A Review of the Current Literature. *Bull Emerg Trauma* 2016;4:65-74
2. Eskridge SL, Macera CA, Galarneau MR, et al. Injuries from combat explosions in Iraq: injury type, location, and severity. *Injury* 2012;43:1678-1682
3. Temple N, Donald C, Skora A, et al. Neuroimaging in adult penetrating brain injury: a guide for radiographers. *J Med Radiat Sci* 2015;62:122-131
4. Popivanov G, Mutafchyski VM, Belokonski EI, et al. Modern combat trauma. *J R Army Med Corps* 2014;160:52-55
5. Offiah C, Twigg S. Imaging assessment of penetrating craniocerebral and spinal trauma. *Clin Radiol* 2009;64:1146-1157
6. Singh AK, Ditkofsky NG, York JD, et al. Blast Injuries: From Improvised Explosive Device Blasts to the Boston Marathon Bombing. *Radiographics* 2016;36:295-307
7. Timpone VM, Jesinger RA, Johnson T, et al. Answer to last month's radiology case (#40) and images: IED fragment embolism to left posterior cerebral artery. *Mil Med* 2009;174:iv-v
8. Hunter TB, Taljanovic MS. Foreign bodies. *Radiographics* 2003;23:731-757
9. de Barros Filho TE, Cristante AF, Marcon RM, et al. Gunshot injuries in the spine. *Spinal Cord* 2014;52:504-510
10. Jarraya M, Hayashi D, de Villiers RV, et al. Multimodality imaging of foreign bodies of the musculoskeletal system. *AJR Am J Roentgenol* 2014;203:W92-102
11. Rosenfeld JV, Bell RS, Armonda R. Current concepts in penetrating and blast injury to the central nervous system. *World J Surg* 2015;39:1352-1362
12. Aarabi B, Tofghi B, Kufera JA, et al. Predictors of outcome in civilian gunshot wounds to the head. *J Neurosurg* 2014;120:1138-1146
13. Kazim SF, Shamim MS, Tahir MZ, et al. Management of penetrating brain injury. *J Emerg Trauma Shock* 2011;4:395-402
14. Sweeney JM, Lebovitz JJ, Eller JL, et al. Management of nonmissile penetrating brain injuries: a description of three cases and review of the literature. *Skull Base Rep* 2011;1:39-46
15. Dedini RD, Karacozoff AM, Shellock FG, et al. MRI issues for ballistic objects: information obtained at 1.5-, 3- and 7-Tesla. *Spine J* 2013;13:815-822
16. Jandial R et al: Ballistics for the neurosurgeon. *Neurosurgery*. 62(2):472-80; discussion 480, 2008