

AWARD NUMBER: W81XWH-13-1-0324

TITLE: Improved Healing of Large, Osseous, Segmental Defects by Reverse Dynamization:  
Evaluation in a Sheep Model

PRINCIPAL INVESTIGATOR: Christopher H. Evans

CONTRACTING ORGANIZATION: Mayo Clinic  
Rochester, MN 55905 USA

REPORT DATE: October 2016

TYPE OF REPORT: Annual

PREPARED FOR: U.S. Army Medical Research and Materiel Command  
Fort Detrick, Maryland 21702-5012

DISTRIBUTION STATEMENT: Approved for Public Release;  
Distribution Unlimited

The views, opinions and/or findings contained in this report are those of the author(s) and should not be construed as an official Department of the Army position, policy or decision unless so designated by other documentation.

**REPORT DOCUMENTATION PAGE**Form Approved  
OMB No. 0704-0188

Public reporting burden for this collection of information is estimated to average 1 hour per response, including the time for reviewing instructions, searching existing data sources, gathering and maintaining the data needed, and completing and reviewing this collection of information. Send comments regarding this burden estimate or any other aspect of this collection of information, including suggestions for reducing this burden to Department of Defense, Washington Headquarters Services, Directorate for Information Operations and Reports (0704-0188), 1215 Jefferson Davis Highway, Suite 1204, Arlington, VA 22202-4302. Respondents should be aware that notwithstanding any other provision of law, no person shall be subject to any penalty for failing to comply with a collection of information if it does not display a currently valid OMB control number. **PLEASE DO NOT RETURN YOUR FORM TO THE ABOVE ADDRESS.**

<b>1. REPORT DATE</b> October 2016		<b>2. REPORT TYPE</b> Annual		<b>3. DATES COVERED</b> 30Sep2015 - 29Sep2016	
<b>4. TITLE AND SUBTITLE</b> Improved Healing of Large, Osseous, Segmental Defects by Reverse Dynamization: Evaluation in a Sheep Model				<b>5a. CONTRACT NUMBER</b>	
				<b>5b. GRANT NUMBER</b> W81XWH-13-1-0324	
				<b>5c. PROGRAM ELEMENT NUMBER</b>	
<b>6. AUTHOR(S)</b> Christopher H. Evans, Ph.D. Nicholas P. Quirk, BSc  E-Mail: evans.christopher@mayo.edu				<b>5d. PROJECT NUMBER</b>	
				<b>5e. TASK NUMBER</b>	
				<b>5f. WORK UNIT NUMBER</b>	
<b>7. PERFORMING ORGANIZATION NAME(S) AND ADDRESS(ES)</b> Mayo Clinic 200 First Street, SW Rochester, MN 55905				<b>8. PERFORMING ORGANIZATION REPORT NUMBER</b>	
<b>9. SPONSORING / MONITORING AGENCY NAME(S) AND ADDRESS(ES)</b> U.S. Army Medical Research and Materiel Command Fort Detrick, Maryland 21702-5012				<b>10. SPONSOR/MONITOR'S ACRONYM(S)</b>	
				<b>11. SPONSOR/MONITOR'S REPORT NUMBER(S)</b>	
<b>12. DISTRIBUTION / AVAILABILITY STATEMENT</b> Approved for Public Release; Distribution Unlimited					
<b>13. SUPPLEMENTARY NOTES</b>					
<b>14. ABSTRACT</b> This year we finalized testing of the external fixator and instrumented it with a strain gauge. We also initiated sheep surgeries. Three sheep have been operated so far. Two were unsuccessful but the third sheep is doing well in the immediate post-operative period. The surgeries themselves have been unproblematic, but the first sheep had to be euthanized because of hardware failure 4 days post-operatively. The reason for this is unknown, but there appears to have been a discrete, high-impact event. In response to this, we have installed CCTV cameras for constant surveillance and re-designed the sling for post-operative support. The second sheep died during the anesthesia recovery process. Despite thorough necropsy, the cause of death remains unknown. A third sheep was of an unmatched breed and is being kept as a companion animal. A fourth sheep suffered a tendon injury from a sharp shovel while the pen was being cleaned. This was reported to IACUC, OLAW and ACURO. The fifth sheep, the third one to be operated, is recovering well. Data being transmitted wirelessly from the strain gauge is successfully measuring the load being transmitted through the fixator.					
<b>15. SUBJECT TERMS</b> Sheep; tibia; external fixator; dynamization, strain gauge, fracture mechanics					
<b>16. SECURITY CLASSIFICATION OF:</b>			<b>17. LIMITATION OF ABSTRACT</b>  UU	<b>18. NUMBER OF PAGES</b>  14	<b>19a. NAME OF RESPONSIBLE PERSON</b> USAMRMC
<b>a. REPORT</b> U	<b>b. ABSTRACT</b> U	<b>c. THIS PAGE</b> U			<b>19b. TELEPHONE NUMBER</b> (include area code)

## Table of Contents

1. Introduction .....	4
2. Keywords .....	4
3. Overall Project Summary .....	4
4. Key Research Accomplishments .....	5
A. Wireless strain gauge technology development.....	5
i. Strain Gauge Characterization for In-Vivo Mechanics Monitoring.....	5
B. Animal Experiments .....	6
i. Animal 1 .....	6
ii. Animal 2.....	7
iii. Animal 3.....	8
iv. Animal 4.....	8
v. Animal 5 .....	8
5. Conclusion.....	8
6. Publications, Abstracts and Presentations .....	9
7. Inventions, Patents and Licenses.....	9
8. Reportable Outcomes .....	9
9. Other Achievements .....	9
10. References .....	10
11. Appendices .....	11
Appendix 1 FEA Model of Fixator configurations. ....	11
Appendix 2 Strain Gauge system specifications.....	12
Appendix 3 Synthes Schanz Screw insertion technique.....	12
Appendix 4 Attending Veterinarian's summary of animal 2.....	12

## ***1. Introduction***

Large segmental defects in long bones do not heal well and represent a major clinical problem [1]. INFUSE®, comprising recombinant human bone morphogenetic protein-2 (rhBMP-2) delivered on an absorbable collagen sponge, is used by surgeons to assist the healing of large osseous lesions but the clinical results have been disappointing [2]. Moreover, INFUSE® is very expensive.

It is well established that bone healing is influenced by the mechanical environment [3] [4]. Segmental defects may be stabilized mechanically by an external fixator. There has been much interest in the concept of dynamization, whereby the defect is first stabilized rigidly to initiate healing and then subjected to axial motion (dynamization) to promote the subsequent stages of healing and maturation [5]. This axial motion is transmitted as an axial strain or interfragmentary movement (IFM) through the separated bone cortices (fracture gap).

In research funded by a CDMRP Idea Development Award, we used a rat segmental defect model to show that healing in response to rhBMP-2 could be accelerated and improved by “reverse dynamization” in which the fixator is first applied in a loose configuration and then stiffened once bone formation had started [3], [6].

The present research will determine whether reverse dynamization is also effective in sheep, as a stepping stone towards human, clinical trials.

## ***2. Keywords***

Bone healing; segmental defect; reverse dynamization; sheep; external fixator

## ***3. Overall Project Summary***


The period covered by this annual report was dedicated to animal surgeries (SOW 4) and optimizing the technology for real time monitoring of the strain passing through the fixator. Five sheep have been purchased. Three have been operated; one suffered a cut leg and is recovering; one is of the wrong breed and is being kept as a companion animal. The surgeries have been successful. However, the first operated sheep had to be euthanized after 4 days because of hardware failure. The second died shortly after emerging from anesthesia. The reasons for these events are unknown. In response to the hardware failure, we have redesigned the slings used during the post-operative period, and installed 24-hour remote video surveillance. In response to the post-operative death, we have paid greater attention to post-surgical care. As a result, the third operated animal is doing well in the early post-surgical period. The strain gauge is transmitting data in real time, allowing us to determine the loading through the fixator. Before it could be operated, an additional (fourth) sheep suffered a tendon injury from a sharp shovel while the pen was being cleaned. This was reported to IACUC, OLAW and ACURO. This sheep is being kept as a companion animal while the lesion heals.

#### ***4. Key Research Accomplishments***

##### ***A. Wireless strain gauge technology development***

Due to successful mechanical characterization of the external fixator (see last annual report), collaboration with Dr. Keat Ghee Ong and Michigan Technological University was initiated to explore real time monitoring of fracture gap mechanics – new technology that has only just become available. This was adapted for our project through the addition of strain gauges to the fixator and wireless signaling of data through a nearby console. Through mechanical testing and further Finite Element Analysis (FEA) calibration, strain and force through the fracture gap can be approximated. This tool allows extensive monitoring of the healing process.

The system comprises a strain gauge and temperature sensor for calibration of fixator temperature changes (this would affect baseline strain gauge data), transmitter unit, battery unit and USB receiver unit (*Figure 1*). The transmitter and battery units are housed in custom printed boxes for protection;

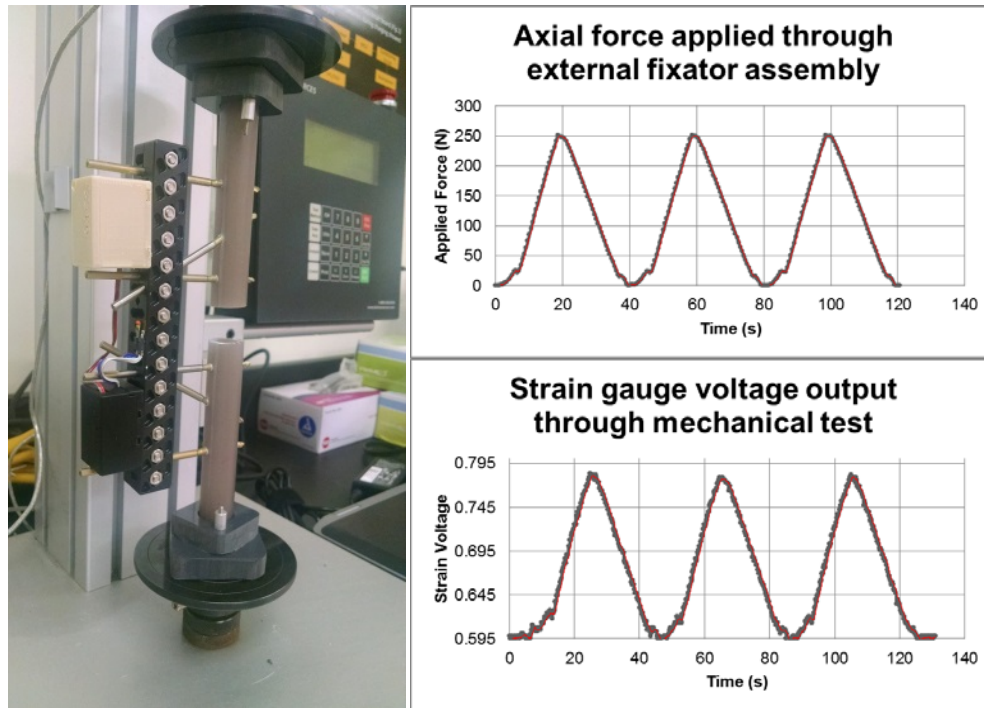


**Figure 1; Left:** Strain gauge and temperature sensor attached to fixator surface with transmitter unit. **Right:** Transmitter unit broken down by component layers and USB receiver unit.

the gauges are covered by a plastic dip that is resistant to ethylene oxide used for sterilization. See *Appendix 2* for the entire system specification details.

##### ***i. Strain gauge characterization for in vivo mechanics monitoring***

Calibration of the gauge was based on mechanical tests assessing the elastic region of the fixator assembly determined through prior testing (*Figure 2*). A sensitivity range of 0-250N was determined for most accurate measurements and voltage output was measured against force applied during controlled axial tests. Linear slopes for force and associated inter-fragmentary motion (IFM) were determined for voltage conversion. *Appendix 1* shows detailed FEA analysis used for characterizing fixator surface strain to inter-fragmentary strain and fixator stress.

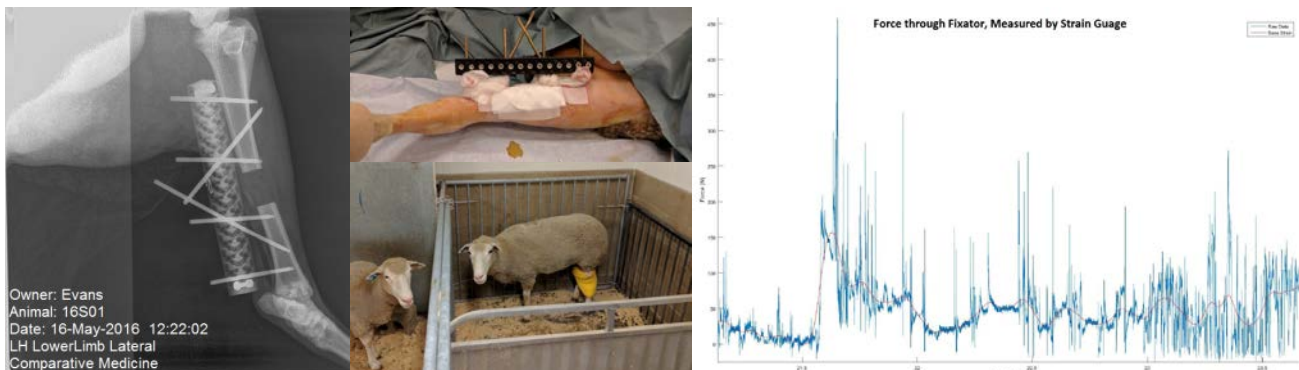


**Figure 2; Left:** Mechanical testing apparatus for strain gauge characterization **Right Top:** Force applied through mechanical testing. **Right Bottom:** Associated strain gauge output voltage during mechanical testing.

## B. Animal Experiments

### i. Animal 1

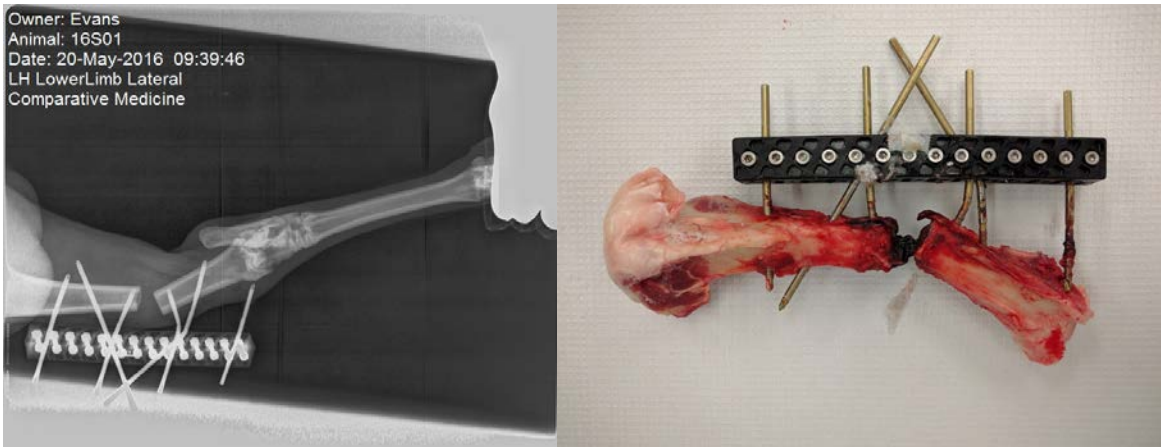
Animal 1 suffered hardware failure 4 days post-operatively (PO). Surgery was successful with no complications. Immediate PO x-ray revealed the distal pin to be only half engaged to the secondary cortex (*Figure 3, left*). This discrepancy was due to following Synthes recommended surgical procedure for insertion of Schanz Screws (*Appendix 3*), recommending that the screw tip should not fully penetrate outer far cortex. This represents a surgical challenge. PO recovery was successful with the animal bearing weight 6 hours PO (*Figure 3, center*). One day PO recovery, the animal continued to bear weight with no significant pain identifiers. Strain gauge data showed significant weight-bearing per design of experiment, with no complications (*Figure 3, right hand image*). Peak strain gauge data showed forces across defect of approximately 450N, which is well below the fixator elastic and testing safety limit. Shifts in baseline were due to temperature fluctuations and associated effect on strain gauge (since rectified).



**Figure 3; Left:** Animal1 post-operative x-ray. **Center top:** Post-operative image of external fixator and segmental tibial defect, wound closed. **Center bottom:** Animal 1 day 2 post-operative, bearing weight and free from major pain identifiers. **Right:** Fixator strain recorded through wireless strain gauge 6 hours post-surgery.



During the third night PO, the animal suffered a significant incident, which resulted in her ‘pulling out’ her distal pin and significantly deforming the fixator and 2 adjacent pins on the distal bone (4). This animal was immediately euthanized after radiographic confirmation per animal use requirements. Analysis of the tibia and fixator determined that hardware failure would have occurred regardless of distal pin position because of the amount of fixator permanent deformation (*Figure 4, right*).



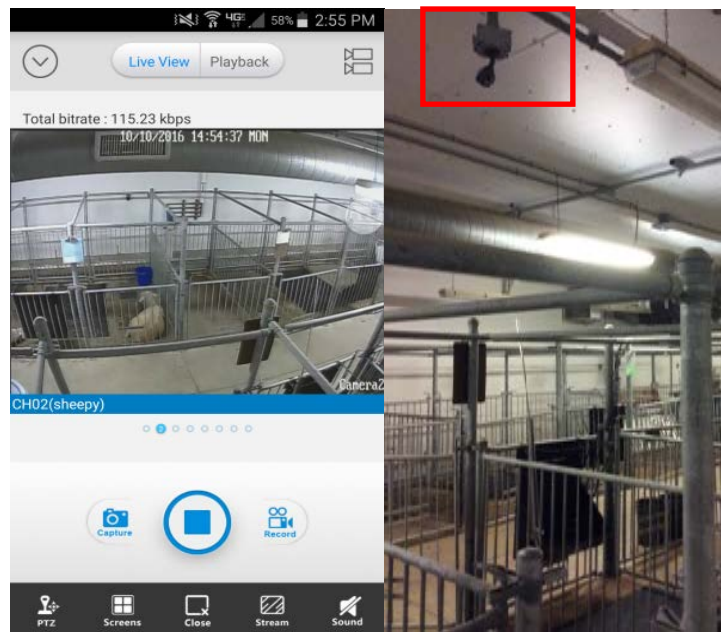
**Figure 4; Left:** 3 day PO X Ray after adverse event. **Right:** Necropsy of tibia with fixator.

Following this incident, animal handling protocols and the facility were modified. CCTV cameras were installed to monitor all sheep, especially during periods when staff were not present. Animals were moved to different pens to allow for longer slinging PO (*Figure 5*).

**ii. Animal 2**


Following the above refinements, we operated on animal 2. Surgery was a success with no complications and all pins engaging bone bi-cortically (*Figure 6, left*). However following PO recovery and subsequent transportation from the surgical suite to the housing pen, animal 2 ceased breathing and did not recover. Below are the attending veterinarian’s notes summarizing the incident and subsequent necropsy (entire discourse in *Appendix 4*).

*‘.....in the short period of time she had been rolled into the west barn, she was in respiratory arrest, with no pulse. This was a very quick event. The necropsy, although worth doing, did not reveal an obvious cause of death, making an acute cardio-pulmonary event the likely cause. The findings were mild erythema of the cranial tracheal mucosa, though no swelling or obstruction. Small amount of mucous exudate in mid-trachea, again no obstruction. Lungs fully aerated, but had a few mottled areas of discoloration consistent with areas of atelectasis with one area of the distal right caudal lobe looking mildly hemorrhagic. The bronchus to that lobe did have some bloody/mucous fluid, but that could have been caused by the CPR compressions. There was no evidence of pneumonia or pulmonary disease. The heart was unremarkable, as were the abdominal organs. She had abundant fat of a well-conditioned animal. Again, it appears she had an acute respiratory/cardiac event which may not have been avoidable.....’*



**Figure 5; Left:** Image capture of CCTV live video monitoring on mobile device. **Right:** New pens for animal holding and cameras installed for real time monitoring.

This setback caused us to refine our recovery procedure, develop a new sling and optimize medication administered pre- and post-surgically. The new sling was designed after consulting veterinarians at the AO Research Institute in Davos, Switzerland (*Figure 6, right hand image*). This Institute has considerable experience with large segmental defect models in the tibiae of sheep.



**Figure 6; Left:** Animal 2 PO surgery X-Ray. **Right:** New sling.

### *iii. Animal 3*

Animal 3 was a mistakenly ordered Rambouillet predominant cross-breed, unsuitable for the current protocol, which uses Polypal sheep. This animal is being used as a companion animal.

### *iv. Animal 4*

Animal 4 suffered a tendon injury to the experimental leg 1 day prior to surgery (information submitted to IACUC, OLAW, ACURO). Surgery is delayed until this wound heals.

### *v. Animal 5*

Animal 5 underwent surgery on October 25, 2016. The surgery was successful and the animal is recovering well. The CCTV system is functioning correctly, and the strain gauge is transmitting force measurements unproblematically.

## **5. Conclusion**

After two false starts, we have developed a surgical protocol and recovery procedure that seems to work. Animal 5 was operated recently and is recovering well; the strain gauge is transmitting data as expected. This suggests we should be able to complete the remaining sheep surgeries expeditiously.



## **6. Publications, Abstracts and Presentations**

- NP Quirk, A Thoreson, RE De la Vega, MJ Coenen, M Trujillo, CM Lopez De Padilla, S Tepic, CH Evans. *Characterization of a novel dynamizable external fixator for ovine tibial segmental defects*. European Cells & Materials Volume 3, Supplement 3, 56, 2016.  
<http://www.ecmjournal.org/journal/supplements/vol032supp03/pdf/Vol032Supp03056.pdf>
- N. P. Quirk, A. Thoreson, R. E. De la Vega, M.D., M. J. Coenen, M. Trujillo, Ph.D, M, Morsey, M.B., B.Ch., A. T. Mohan, MBBS., Y. J. Sur, M.D., Ph.D., S. Tepic, D.Sc., C. H. Evans, Ph.D. *Mechanical characterization of a novel external fixator for dynamizing ovine osseous defects*. Poster No. 2185. Orthopedic Research Society Annual Meeting, Orlando, FL, USA, March 5-8, 2016

## **7. Inventions, Patents and Licenses**

None

## **8. Reportable Outcomes**

- Implementation of wireless strain gauge technology for real-time assessment of fracture gap biomechanics.
- Wireless CCTV installed to monitor all animals through 6 month period and record footage for corroborating with strain gauge data.
- Modification and refinement of animal handling protocol, including new pens, institutional facility protocols and new sling design.
- Initiation of animal studies. Three sheep have undergone surgery. The first sheep (animal 1) had to be euthanized following hardware failure, and the second (animal 2) died during the anesthesia recovery period. Changes were implemented in response to these adverse events, and the third operated sheep (animal 5) is recovering well.

## **9. Other Achievements**

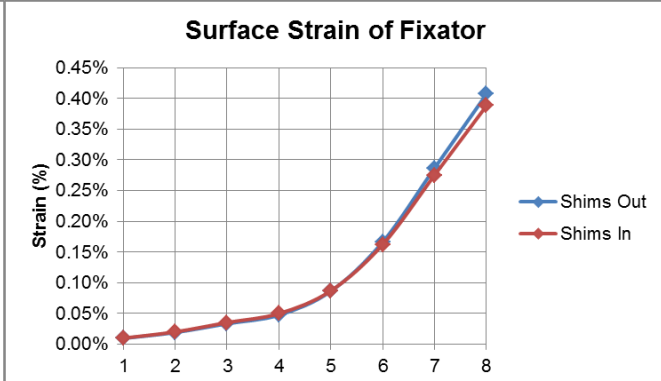
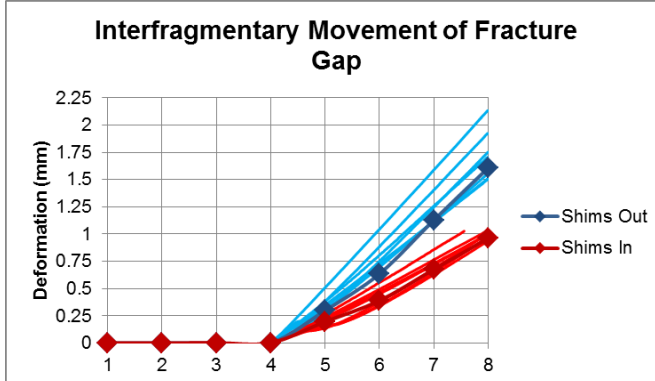
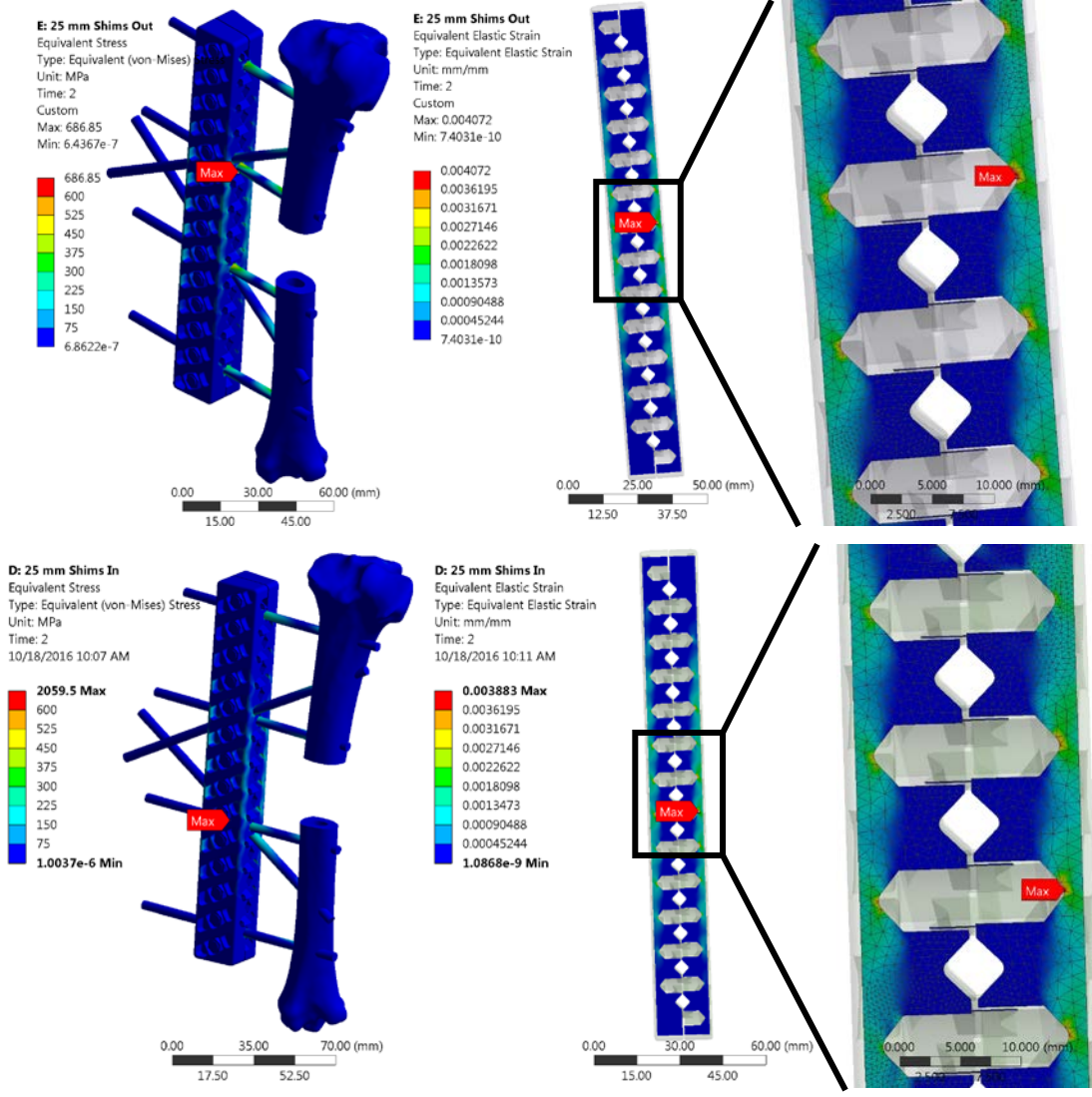
None

## 10. References

- [1] A. N. Pollak and J. R. Ficke, "Extremity war injuries: challenges in definitive reconstruction.," *J. Am. Acad. Orthop. Surg.*, vol. 16, no. 11, pp. 628–634, 2008.
- [2] E. J. Carragee, E. L. Hurwitz, and B. K. Weiner, "A critical review of recombinant human bone morphogenetic protein-2 trials in spinal surgery: emerging safety concerns and lessons learned.," *Spine J.*, vol. 11, no. 6, pp. 471–491, 2011.
- [3] V. Glatt, M. Miller, a Ivkovic, F. Liu, N. Parry, D. Griffin, M. Vrahas, and C. Evans, "Improved healing of large segmental defects in the rat femur by reverse dynamization in the presence of bone morphogenetic protein-2," *J. bone Jt. Surg. Am. Vol.*, vol. 94, no. 22, pp. 2063–2073, 2012.
- [4] M. Mehta, S. Checa, J. Lienau, D. Hutmacher, and G. N. Duda, "In vivo tracking of segmental bone defect healing reveals that callus patterning is related to early mechanical stimuli.," *Eur. Cell. Mater.*, vol. 24, no. 0, pp. 358–71; discussion 371, 2012.
- [5] G. De Bastiani, R. Aldegheri, and L. Renzi Brivio, "The treatment of fractures with a dynamic axial fixator.," *J. Bone Joint Surg. Br.*, vol. 66, pp. 538–545, 1984.
- [6] V. Glatt, C. H. Evans, and R. Matthys, "Design, characterisation and in vivo testing of a new, adjustable stiffness, external fixator for the rat femur.," *Eur. Cell. Mater.*, vol. 23, pp. 289–98; discussion 299, 2012.
- [7] C. A. Grant, M. Schuetz, and D. Epari, "Mechanical testing of internal fixation devices: A theoretical and practical examination of current methods," *J. Biomech.*, Oct. 2015.
- [8] R. J. Nesbitt, S. T. Herfat, D. V. Boguszewski, A. J. Engel, M. T. Galloway, and J. T. Shearn, "Primary and secondary restraints of human and ovine knees for simulated in vivo gait kinematics," *J. Biomech.*, vol. 47, no. 9, pp. 2022–2027, 2014.

## 11. Appendices

**Appendix 1 FEA Model of Fixator configurations.** Entire stress model and strain distribution of fixator surface for strain gauge characterization shown. Graph time scale shown in model 'steps'. Steps 1-4 correspond to model bolt pre-tension. Steps 4-8 show theoretical mechanical testing (500N vertically applied to tibial plateau, distal tibial condyle constrained in all directions). IFM graph shows mechanical testing deformation results for model validation.







***Appendix 4 Attending Veterinarian's summary of animal 2's non-survival and subsequent autopsy.***

From: [REDACTED] Sent: Tue 8/23/2016 4:47 PM  
To: Evans, Christopher H., Ph.D.; De la Vega Amador, Rodolfo E., M.D.; Quirk, Nicholas P.  
Cc: [REDACTED]  
Subject: Sheep Necropsy

Dr. Evans and crew,

Again let me express how sorry I am for the unexpected death of 02 today. It was clear, from all reports, that she was moving her head around when brought off the truck and in the short period of time she had been rolled into the west barn, she was in respiratory arrest, with no pulse. This was a very quick event. The necropsy, although worth doing, did not reveal an obvious cause of death, making an acute cardio-pulmonary event the likely cause. The findings were mild erythema of the cranial tracheal mucosa, though no swelling or obstruction. Small amount of mucous exudate in mid-trachea, again no obstruction. Lungs fully aerated, but had a few mottled areas of discoloration consistent with areas of atelectasis with one area of the distal right caudal lobe looking mildly hemorrhagic. The bronchus to that lobe did have some bloody/mucous fluid, but that could have been caused by the CPR compressions. There was no evidence of pneumonia or pulmonary disease. The heart was unremarkable, as were the abdominal organs. She had abundant fat of a well-conditioned animal. Again, it appears she had an acute respiratory/cardiac event which may not have been avoidable.

Again, I am happy to try to brainstorm for future refinements, if that would be of any help. In that regard, thoughts of the sling fit and design could be discussed in addition to the timing of determining the "sweet spot" of when to hang the animal in the sling in regards to anesthetic recovery.

Regards,  
[REDACTED]

# Improved Healing of Large, Osseous, Segmental Defects by Reverse Dynamization: Evaluation in a Sheep Model

Log number OR120192 / CCCRP R&A – October 2016

Award Number W81XWH-13-1-0324



PI: Evans, Christopher

Org: Mayo Clinic

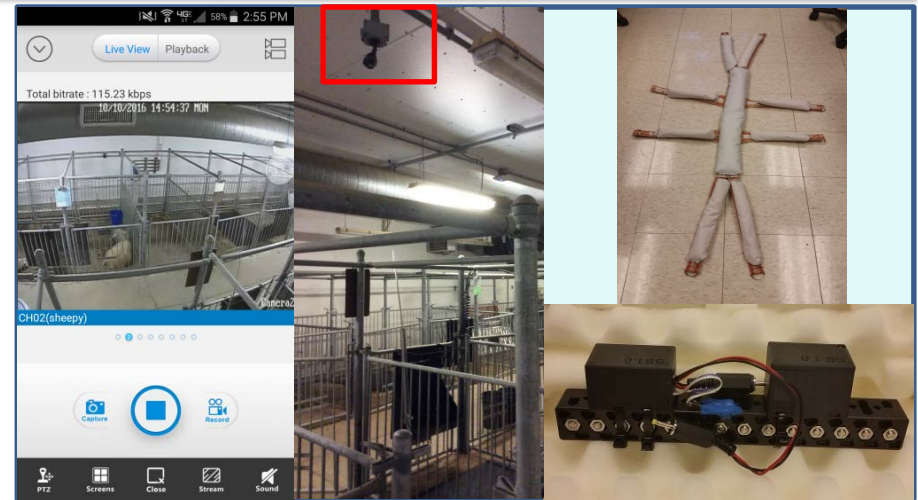
Award Amount: \$855,958

## Study/Product Aim(s)

- To design, construct, characterize and evaluate a scalable, adjustable stiffness, external fixator that is appropriate for use in sheep and will allow reverse dynamization in a clinically expeditious manner.
- To evaluate the ability of reverse dynamization to enhance healing of a 3 cm, tibial defect in sheep.

## Approach

We will first design and construct an external fixator that can be applied to a fractured sheep tibia, allowing us to alter the stiffness of fixation while it is attached to the bone. The mechanical properties of the fixator will be evaluated and characterized. The final design will be used in a sheep, tibial segmental defect model. Fixation of the defect will be initially loose. Once bone has started to form, stiffness will be increased and healing monitored.



Accomplishment: CCTV system installed. New sling developed for sheep post-operative care. Further optimization for wireless strain gauge technology to be used. Animal 2 surgery successfully completed but the animal died for unknown reasons during the post-operative recovery period.

## Timeline and Cost

Activities	CY	13	14	15	16	17 (NCE)
Fixator design & characterization		█			█	
Initiate in vivo ovine animal studies					█	█
Complete in vivo data analysis						█
Text (Major aim/study/milestone)				█	█	█
<b>Estimated Budget (\$K)</b>		\$219,808	\$334,274	\$301,876		NCE

Updated: Mayo Clinic 10/2016

## Goals/Milestones

**CY15/6 Goals** – Initiate in vivo studies in which fixators will be used to accelerate the healing of 3 cm defects in sheep tibiae.

**CY16/7 Goals** – Completion of sheep studies. Preparation of manuscripts for publication.

## Comments/Challenges/Issues/Concerns

- We have experienced a number of challenges with the sheep surgeries:
  - Animal 2 did not survive the immediate post-operative period; necropsy failed to identify reason.
  - Animal 3 ordered by facility was wrong breed.
  - Animal 4 suffered tendon injury on experimental leg during routine pen cleaning (copy of IACUC memo explaining incident will be forwarded to ACURO and included with annual report in October 2016).
  - Animal 5 has been operated and is recovering favorably.

## Budget Expenditure to Date:

Projected Expenditure: \$664,223

Actual Expenditure: \$759,577