

Award Number: W81XWH-FE-1 J

TITLE: [] ~ c^! Áæ ^ãÁ[* } äã^Áã ~ |æã } Á -Áæææ&U~!*^!^

PRINCIPAL INVESTIGATOR: Ö:ÉÑ @Š[^, ^ } •cã

CONTRACTING ORGANIZATION: T æ•æ&@•^c Á^BÁæÁQ-ã{ æ^
Ó[•q } ÉÁ ÖÆGFFI Á

REPORT DATE: Ö^&^ { à^!ÁGFF

TYPE OF REPORT: Öã æ

PREPARED FOR: U.S. Army Medical Research and Materiel Command
Fort Detrick, Maryland 21702-5012

DISTRIBUTION STATEMENT: Approved for public release; distribution unlimited

The views, opinions and/or findings contained in this report are those of the author(s) and should not be construed as an official Department of the Army position, policy or decision unless so designated by other documentation.

REPORT DOCUMENTATION PAGE

Form Approved
OMB No. 0704-0188

Public reporting burden for this collection of information is estimated to average 1 hour per response, including the time for reviewing instructions, searching existing data sources, gathering and maintaining the data needed, and completing and reviewing this collection of information. Send comments regarding this burden estimate or any other aspect of this collection of information, including suggestions for reducing this burden to Department of Defense, Washington Headquarters Services, Directorate for Information Operations and Reports (0704-0188), 1215 Jefferson Davis Highway, Suite 1204, Arlington, VA 22202-4302. Respondents should be aware that notwithstanding any other provision of law, no person shall be subject to any penalty for failing to comply with a collection of information if it does not display a currently valid OMB control number. **PLEASE DO NOT RETURN YOUR FORM TO THE ABOVE ADDRESS.**

1. REPORT DATE (DD-MM-YYYY) 01-12-2011		2. REPORT TYPE Final		3. DATES COVERED (From - To) 23 May 2011 - 22 Nov 2011	
4. TITLE AND SUBTITLE A Computer Based Cognitive Simulation of Cataract Surgery				5a. CONTRACT NUMBER	
				5b. GRANT NUMBER W81XWH-11-1-0359	
				5c. PROGRAM ELEMENT NUMBER	
6. AUTHOR(S) Dr. John Loewenstein E-Mail: john_loewenstein@meei.harvard.edu				5d. PROJECT NUMBER	
				5e. TASK NUMBER	
				5f. WORK UNIT NUMBER	
7. PERFORMING ORGANIZATION NAME(S) AND ADDRESS(ES) Massachusetts Eye & Ear Infirmary Boston, MA 02114				8. PERFORMING ORGANIZATION REPORT NUMBER	
9. SPONSORING / MONITORING AGENCY NAME(S) AND ADDRESS(ES) U.S. Army Medical Research and Materiel Command Fort Detrick, Maryland 21702-5012				10. SPONSOR/MONITOR'S ACRONYM(S)	
				11. SPONSOR/MONITOR'S REPORT NUMBER(S)	
12. DISTRIBUTION / AVAILABILITY STATEMENT Approved for Public Release; Distribution Unlimited					
13. SUPPLEMENTARY NOTES					
14. ABSTRACT The Virtual Mentor Cataract Surgery Trainer is a computer based, cognitive simulation of phacoemulsification cataract surgery. It is designed to teach the steps of the surgery, common errors, error recognition, and error correction. We interviewed phaco experts, and edited video of the interviews into brief "clips" for use as "just in time" feedback to learners, and as answers to "Help and Reference" questions. Our database includes hundreds of edited expert video clips. Combining information from expert interviews with our own observations, we created the overall architecture for the simulation, including action options, questions, and appropriate expert stories for each step of the procedure. We wrote pathways and scenarios for all phaco modules. We wrote questions and answers for "Help and Reference" sections for all modules. We created hundreds of 3D animations for steps and complications phaco. The content of the Cataract Trainer is now complete, with access incision, capsulorhexis, hydrodissection, nucleus removal, cortical removal, IOL insertion, and wound closure modules. The entire program is scheduled for beta testing in December 2011. The value of this teaching method has been validated in a study that has been accepted in a peer reviewed journal.					
15. SUBJECT TERMS No subject terms provided.					
16. SECURITY CLASSIFICATION OF:			17. LIMITATION OF ABSTRACT	18. NUMBER OF PAGES	19a. NAME OF RESPONSIBLE PERSON
a. REPORT	b. ABSTRACT	c. THIS PAGE			19b. TELEPHONE NUMBER (include area code)
U	U	U	UU	20	

Table of Contents

	<u>Page</u>
Introduction.....	5
Body.....	5
Key Research Accomplishments.....	6
Reportable Outcomes.....	6
Conclusion.....	6
References.....	6
Appendices.....	7

INTRODUCTION

The Virtual Mentor Cataract Surgery Trainer is a computer based, cognitive simulation of phacoemulsification cataract surgery. It is designed to teach the steps of the surgery, common errors, error recognition, and error correction. This award supports the completion of the content of the Cataract Trainer.

BODY

Phacoemulsification cataract surgery (phaco) is a difficult procedure to learn, with little margin for error. As in other areas of surgery many, if not most, errors are cognitive rather than motor in origin. Trainees do not have a full mental map of the procedure and may not understand fully the purpose of each step of the surgery. They often do not recognize small errors that may lead to trouble later in the procedure. Lack of recognition may be due to visual cognitive errors (not recognizing subtle details), lack of understanding of the consequences of small deviations from ideal performance, or simply failure to critically judge the results of each step. Traditionally ophthalmology residents watch and assist at phaco, read about the procedure, watch videos, attend lectures, and practice in “wet labs” on animal eyes. Each of these training steps have value, but experienced teachers of phaco find that trainees still begin their early cases on patients with a limited understanding of the procedure. We believe this is due to the lack of effective practice in a realistic environment, and lack of attention to error recognition and correction. The Virtual Mentor Cataract Surgery Trainer is designed to teach the steps of phaco and their variations and common errors in a computer simulation. It places the learner in a realistic environment where they have to make choices and recognize what is happening in the eye. “Just in time” feedback is given in the form of experts telling stories on video. Steps of the surgery, variations and errors are illustrated by 3D animations. The program includes a “Help and Reference” section. This section contains all the expert video clips, answers to questions, and narrated videos of actual steps of phaco surgery.

In year one of the project we interviewed phaco experts and expert teachers to identify common errors in steps of the procedure, including capsulorhexis and nucleus removal. In addition to prior interviews, we attended the ASCRS meeting where we interviewed and recorded over 20 experts. We edited the interviews into small video clips, each addressing a single aspect of the surgery. Our database now includes hundreds of edited expert video clips.

Combining information from expert interviews with our own observations, we created the overall architecture for the simulation, including action options, questions, and appropriate expert stories for each step of the procedure. We outlined all paths through the simulation.

The VRMagic company (Germany) offered to assist us by allowing us access to video of phaco steps derived from their “virtual reality” phaco simulator. We performed extensive testing of the VRMagic EYESI virtual reality eye surgery simulator to determine which cataract surgery complications could be modeled on this platform. Unfortunately there were multiple obstacles. Only a limited number of complications could be modeled. In addition, in the EYESI, the learner cannot move from one step of surgery to another while retaining the state of the eye. Finally, creating video from the EYESI simulation is very time consuming. As a result we decided to revert to our original plan to use 3D animation, created by a computer artist.

In year one of the original award we hired an animator and produced most of the animations required for the capsulorhexis module. We wrote the content for most of the answers to questions for the help and reference section of the capsulorhexis and other modules.

Although not part of our Statement of Work in the original award, we had hoped to include actual surgical video clips of complications of phaco for comparison with 3D animations of these complications. Although many surgeons from a variety of programs had agreed to help collect these for us, it has been very difficult to accumulate video of a sufficient number of complications of cataract surgery. There were several reasons for this: 1) many surgeons do not routinely video record their cases 2) some surgeons who record cases do not obtain permissions that would allow us to use the video 3) after consideration some surgeons were concerned about medico-legal implications and 4) the process of collecting the videos and forwarding to us was more cumbersome than our volunteers expected. We have had to abandon this portion of the program.

In year two of the original award we completed the animations for the capsulorhexis and nucleus removal modules. Although not part of the statement of work, we re-did the animations for the hydrodissection module to achieve a consistent appearance for all animations in the program. We also created animations for a clear corneal incision module. Over 400 animations were completed.

We wrote the key questions and content for clear corneal incision, capsulorhexis, hydrodissection, and nucleus removal modules, and matched edited expert video clips to the appropriate “pop-up” tutoring moments and as answers to key questions.

In the period between the original award and the supplement, we continued work on the remaining modules. The supplement award allowed us to continue work with our animation artist, and to engage our E-Learning partner to complete the software architecture for the Cataract Trainer. It provided funds for a team of phaco surgeons who worked in parallel to complete the modules.

The content for the entire Cataract Trainer is now complete. Beta testing of the program by a team of 20 ophthalmology residents, fellows, and experienced phaco surgeons will begin in January 2011. We have a verbal agreement with a national ophthalmology organization to distribute the program over the internet by yearly subscription. The formal license agreements are being written this month (December 2011). This organization intends to market the Cataract Trainer internationally. We are in discussions with a large ophthalmology equipment manufacturer to create a Mandarin Chinese version of the Cataract Trainer.

KEY RESEARCH ACCOMPLISHMENTS

- Interviewed phaco experts, and edited video of the interviews in to brief “clips” for use as “just in time” feedback to learners, and as answers to “Help and Reference” questions.
- Created overall architecture of the simulation.
- Wrote pathways and scenarios for all modules.
- Wrote questions and answers for “Help and Reference” sections for all modules.
- Created 3D animations for steps and complications of all modules: access incisions, capsulorhexis, hydrodissection, nucleus removal, cortical removal, IOL insertion, and wound closure.

REPORTABLE OUTCOMES

Previously performed multicenter, randomized study of the prototype of the “Virtual Mentor” published in *Ophthalmology*.

CONCLUSION

The value of this teaching method has been validated in a study that has been published in a peer reviewed journal. We have completed content for all modules. Beta testing will begin in January 2011. We expect to partner with a national ophthalmology organization to distribute the program over the internet soon thereafter.

REFERENCES

1. Henderson BA, Neaman A, Kim BH, Loewenstein J. Virtual training tool. *Ophthalmology*. 2006;113(6):1058-9.
2. Henderson BA, Kim JY, Golnik KC, Oetting TA, Lee AG, Volpe NJ, Aaron M, Uhler TA, Arnold A, Dunn JP, Prajna NV, Lane AM, Loewenstein JI. Evaluation of the Virtual Mentor Cataract Training Program. *Ophthalmology*. 2010;117(2):253-258.

APPENDICES

Appendix 1. Sample Pathway

Module: Nucleus Removal A pathway					
State: NR_02_4A (NRA_01): Small amount of central lens sculpted					
Lens: In capsular bag		<i>[image to go here]</i>			
Capsule: Intact CCC					
Instruments: - Dominant: Phaco - Non-dominant: Spatula or chopper					
View 2 Graphic (cross section)					
NA					
Related Questions					
Action NRA_01_1 Correct	Action NRA_01_2 Correct	Action NRA_01_3 Mistake	Action Mistake	Action	Action
Place vacuum settings on low and make a central groove	Place vacuum settings on high and bury phaco probe into middle of lens to chop lens	Place vacuum settings on low and bowl out the lens			
Animation: same animation as NR_02_1 but the start has a small sculpted hole	Animation: same as NR_02_2 but the start has a small sculpted hole	Animation: shows bowling out the lens	Animation	Animation:	Animation:
Pop-up Tutoring: NA	Pop-up Tutoring: NA	Pop-up Tutoring: Mamalis	Pop-up Tutoring:	Pop-up Tutoring:	Pop-up Tutoring:
What just happened? By lowering the vacuums settings, the phaco was able to sculpt the lens rather than holding the lens Related Questions: Discuss settings Discuss phaco tip angulation and how it differs for sculpting, holding, etc. Discuss differences between peristaltic and venturi	What just happened? Increasing the vacuum settings allows the phaco to hold the lens in preparation for chopping Related Questions: How to hold onto the lens (how to avoid having the lens fall off the phaco) Discuss the phaco tip angulation (0 degree better for holding but 45 better for sculpting)	What just happened? Instead of a cruciate pattern, the lens was bowled out. This make it more difficult to remove the lens Related Questions: When is it beneficial to bowl out the lens? What dangers are associated with bowling out a lens? How to avoid bowling out a soft lens	What just happened? Related Questions:	What just happened? Related Questions:	What just happened? Related Questions:
What to do?	What to do? Related	What to do? Related	What to do? Related	What to do? Related	What to do? Related

Related Questions:	Questions:	Questions:	Questions:	Questions:	Questions:
Next state: NR_03	Next state: NRC_01	Next state: Pop up and return to NRA_1	Next state:	Next state:	Next state:

Appendix 2.
Screen shots from the program.
Sample screen shot of the main screen.

Your next action? View 1

- Use canula to dial the nucleus out of the capsular bag
- Use canula to engage center of nucleus and lift lens straight out
- Continue hydrodissection in same location
- Use canula to gently reposit lens back into capsular bag
- Change instruments

Ocular Status:

Lens: Partially prolapsed (~35% out)

Capsule: Intact with neat, irregular capsulorrhexis

Tools in hand:

Hydrodissecting Canula

Nothing in secondary hand

Help and Reference

Ask a question about:

- What just happened
- What is going on now / What to do

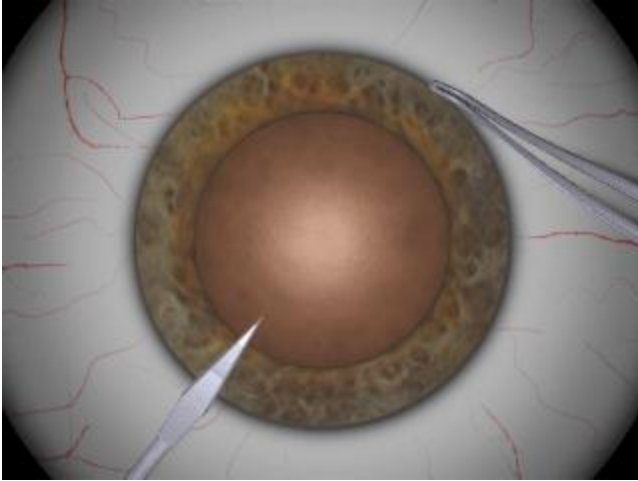
Related questions:

- What ocular structures should I consider when a lens prolapses?
- What are the main approaches to handling a partially prolapsed lens?
- What instruments or agents can be helpful in handling a prolapsed lens?

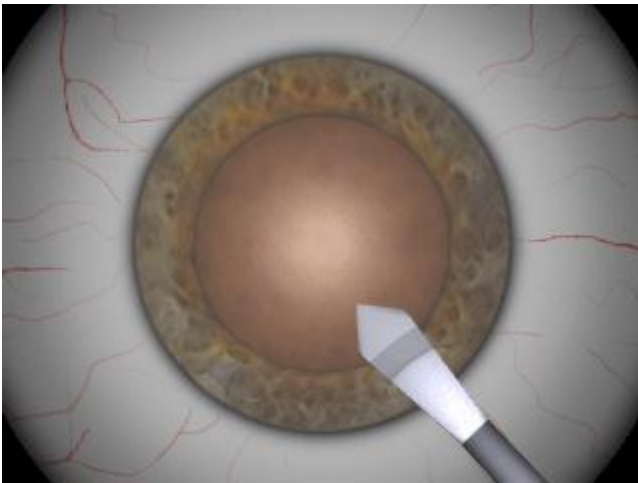
View Reference Material

© Massachusetts Eye and Ear Infirmary

Sample screen shots from animations of clear corneal incision.
A) Creating paracentesis.

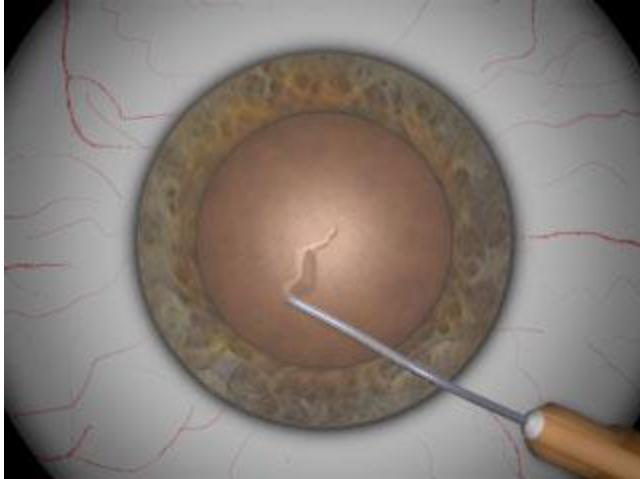


B) Creating clear corneal biplanar incision.

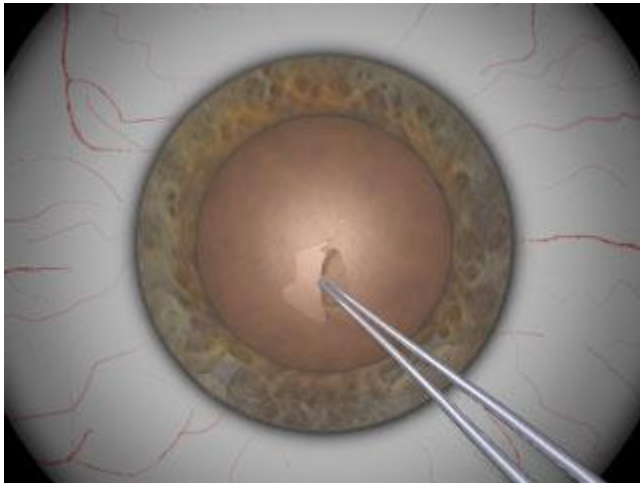


Sample screen shots from animations of capsulorhexis.

A) Cystotome creates capsular flap.

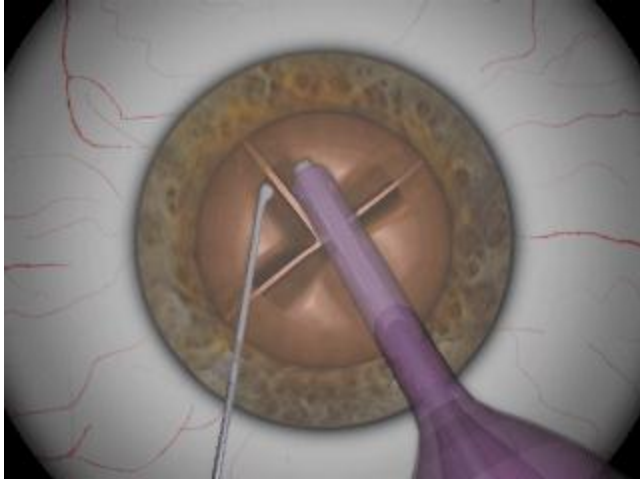


B) Forceps extend capsular flap.

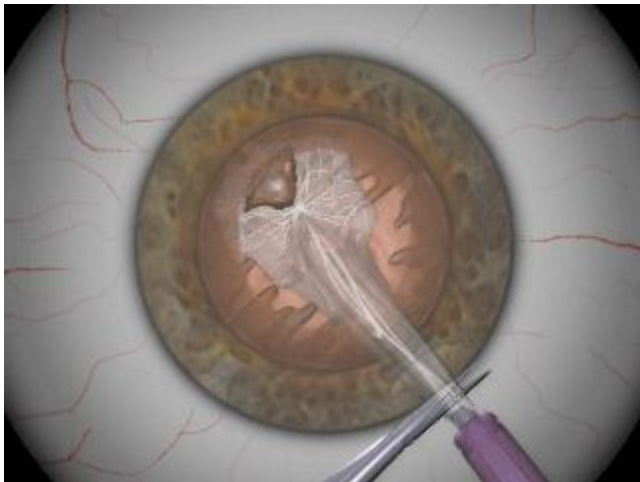


Sample screen shots from animations of nucleus removal.

A) Cracking the nucleus



B) Trimming vitreous that has extruded through break in posterior capsule.



Appendix 3. Sample VM Action Lists for Capsule Incision (Capsulorrhexis) and Nucleus Removal

A) Capsulorrhexis

1. Inject viscoelastic solution to deepen the anterior chamber
 - A. Not enough viscoelastic – anterior chamber too flat, anterior lens capsule convex
(see above “Viscoelastic Insertion”)
2. Using a cystotome (bent 25 gauge needle), puncture the anterior lens capsule in the center of the pupil
 - A. Can't get cystotome into eye- turn tip down rather than up towards the cornea
What happened?
The cystotome did not smoothly enter the eye through the clear corneal wound.
The tip of the cystotome was pointed up as it was passed through the wound,

creating resistance against the wound and risking a descemet tear from inappropriate wound manipulation (link to Descemet tear)

What should you do?

The pointed tip of the cystotome should be parallel to the clear cornea wound (oriented horizontally) when passing through the cornea. Once the tip is inside the eye, it can then be rotated down so that the tip is pointing towards the anterior capsule.

- B. Cystotome tipped too posteriorly – drags cystotome across anterior capsule and rips capsule

What happened?

The cystotome was tipped too posteriorly upon entry into the anterior chamber. The cystotome tip engaged and ripped the anterior capsule.

What should you do?

An effort should be made to incorporate the inadvertent rip in the anterior capsule into the capsulorrhexis.

3. Keeping the bent needle tip engaged in the lens, move the cystotome towards the periphery of the lens and thereby creating a linear cut in the anterior capsule

- A. Cystotome too superficial – does not cut into capsule

What happened?

The cystotome was not angled posteriorly (toward the lens) to a sufficient degree and the tip could not engage the anterior capsule.

What should you do?

Assess that the microscope settings are maximized to visualize and focus on the anterior capsule. Re-direct the cystotome posteriorly and create a linear tear in the anterior capsule.

- C. Cystotome too deep- buries into lens, disrupts cortex with puff of cortex, loses visualization

What happened?

In addition to cutting through the anterior capsule, the cystotome punctured the lens and disrupted cortical material. The “puff” of cortex can hinder visualization of the underlying anterior capsule, making subsequent steps of the capsulorrhexis challenging.

What should you do?

Assess that the microscope settings are maximized to visualize and focus on the anterior capsule. The cystotome can then be used to tease the anterior capsule in the region of the previously created linear tear in an attempt to isolate anterior capsule from disrupted cortex and create a capsular flap. If unsuccessful, the initial anterior capsule tear can be abandoned and a new tear initiated adjacent to the previously created tear. In this scenario, care must be taken to incorporate the full area of prior capsule tear and disrupted cortex into the capsulorrhexis in order to prevent a discontinuity in the capsulorrhexis.

4. After @3mm from the center of the pupil, change the direction of the cystotome so that the tip is now being pulled downward towards corneal incision for @ 1mm to make a flap

- A. Too short radial cut –can’t make flap

What happened?

The previously created radial tear in the anterior capsule was too short and a capsular flap could not be created.

What should you do?

The initial anterior capsule tear can be abandoned and a new tear initiated adjacent to the previously created tear. In this scenario, care must be taken to incorporate the full area of prior capsule tear and disrupted cortex into the capsulorrhexis in order to prevent a discontinuity in the capsulorrhexis.

- B. Too long – goes peripherally under iris, or radius is nearly as long as diameter

What happened?

The previously created tear in the anterior capsule was too long and the tear extended peripherally beneath the iris.

What should you do?

Inject viscoelastic into the anterior chamber to ensure the anterior surface of the lens is flat. Use a Kueglen or Y-hook to gently retract the iris overlying the capsular tear. If the tear has not extended to the zonules, an effort can be made to re-direct the tear centrally and continue the capsulorrhexis (Link). If the tear has extended to the zonules no additional manipulation of the tear should be performed. Additional traction on the tear could cause extension of the anterior capsule tear to the posterior capsule. (Link to peripheral extension of capsulorrhexis to the zonules)

5. With the tip of the cystotome, carefully lift the incised flap and evert the flap so that the flap is now turned upside down and laying on top of itself
 - A. Can't evert flap –wrong placement of cystotome (too deep, too superficial, not dragging cystotome enough)

What happened?

The placement of the cystotome is incorrect. Often the tip is not placed under the flap edge and erroneously placed on top of the flap. By doing this, the flap cannot be lifted and everted.

What should you do?

Just the tip of the cystotome should be used to carefully lift the flap without digging in the tip too posteriorly into the lens. If the tip is placed into the lens material, the lens cortex can be disturbed and decrease the visibility of the flap.

6. Continue creating capsulorrhexis with cystotome
 - A. Extends peripherally – wrong direction with cystotome

How to recover this – choices:

1. Add viscoelastic
2. Redirect cystotome
 - a. which direction (options- 2 correct and incorrect- showing consequences of incorrect with opening going peripherally)

incorrect with opening going peripherally)

3. Use forceps to redirect
 - a. Regular hold onto capsular flap with flap everted
 - b. Little technique- unfold, and pull centrally, then re-evert
4. Stop, and restart flap going the other direction
 - a. successful- shows restarting cut, flap, then reconnect
 - b. not successful – unable to restart flap

i. make into can opener style (see Can opener capsulotomy below)

ii. leave alone, cut flap with scissors and continue onto lens removal

- This leads down pathway of removing lens and posterior capsule tear, lens dislocation or safe removal

(Peripheral extension of the capsulorrhexis)

What happened?

The capsular flap extended peripherally. Risk factors for peripheral extension of the capsular flap include insufficient anterior chamber fill with viscoelastic, positive pressure, intumescent lens, poor red reflex, small pupil, and zonular fragility.

What should you do?

Inject viscoelastic into the anterior chamber to ensure the anterior surface of the lens is flat. Use a Kueglen or Y-hook to gently retract the iris overlying the region where the capsulorrhexis has extended peripherally if it cannot be visualized. Management will depend on the degree of peripheral extension of the capsulorrhexis.

What should you do if the capsulorrhexis has not extended to the zonules?

If the capsulorrhexis has not extended to the zonules, an effort can be made to re-direct the flap centrally and continue the capsulorrhexis. Techniques to try in this scenario:

1) Attempt to re-direct the capsulorrhexis flap that has extended peripherally

A) Ensure that the capsular flap is everted and lying flat on the anterior capsule. Grab the capsular flap with forceps and pull towards the center of the lens, with care being taken to ensure all force applied is tangential to the lens and not directed anteriorly. This motion should re-direct the capsular flap centrally and permit continuation of the capsulorrhexis.

OR

B) As described by BC Little, unfold the capsular flap so that it is lying flat against the surface of the lens. Grab the capsular flap and pull towards the center of the lens. This “backward traction” should re-direct the capsular flap centrally. Once the flap is re-directed, evert the flap and continue the capsulorrhexis.

2) Initiate a capsulorrhexis from the opposite direction

Abandon the capsulorrhexis flap that has extended peripherally and direct your attention to the initial linear tear created in the anterior capsule. Initiate a new capsular flap in the opposite direction from the original capsular flap by creating a nick in the anterior capsule using the cystotome or intra-ocular scissors. Lift the new capsular flap and begin the capsulorrhexis in the opposite direction. The new capsulorrhexis should connect with the old capsulorrhexis. Care should be taken to fully incorporate the region of peripheral capsular extension into the capsulorrhexis. Any discontinuity in the anterior capsule will be a point of weakness and at risk for extending posteriorly for the remainder of the case.

What should you do if the capsulorrhexis has extended to the zonules?

If the capsulorrhexis has extended to the zonules no additional manipulation of the tear should be performed. Additional traction on the anterior capsule could cause extension of the anterior capsule tear to the posterior capsule. Abandon the capsulorrhexis flap that has extended peripherally and direct your attention to the initial linear tear created in the anterior capsule.

Use the cystotome to create a can-opener capsulotomy in the opposite direction from the initial capsular flap (Link to capsulotomy).

Care must be taken for the remainder of the case as the discontinuity in the anterior capsule will be weak and at risk for extending posteriorly.

** How do you handle peripheral extension of the capsulorrhexis? (Expert question)

B. Too small – (this will lead to other problems later such as difficulty grooving/removing lens quadrants, cutting anterior capsule while attempting to chop or grooving into anterior capsule, or ripping capsulorrhexis when lens prolapses with hydrodissection) None of this needs to be shown at this stage

What happened?

The capsulorrhexis was too small. A small capsulorrhexis can make subsequent steps in the surgery challenging including grooving, quadrant removal, and irrigation and aspiration.

What should you do?

If noted to be small prior to completion, the capsulorrhexis can be enlarged by spiraling the flap to the desired diameter.

If the capsulorrhexis is complete before the small diameter is appreciated, it can be enlarged by making a small tangential cut with a cystotome, creating a new capsular flap, and then extending the newly created flap.

- D. Too large- (this can cause lens to prolapse, which is OK but sometimes this causes difficulty in novice surgeons because they are unable to reposit lens back into bag nor are they able to remove/chop the lens in anterior chamber safely – they cut anterior capsule, they cause corneal edema) None of this needs to be shown at this stage

What happened?

The capsulorrhexis was too large. The lens can easily prolapse into the anterior chamber through a large capsulorrhexis, creating difficulty with lens manipulation on subsequent steps of phacoemulsification.

What should you do?

The lens can be gently reposit into the capsular bag if prolapse into the anterior chamber occurs. Alternatively, the lens can be phacoemulsified in the anterior chamber with a chopping technique.

7. Gently grasp this flap with capsule forceps and guide it around to create a circular continuous opening in the anterior capsule

- A. Difficulty picking up the flap- forceps too high or too low

Fix by adding more viscoelastic or changing back to cystotome, or

What happened?

The forceps were not positioned appropriately on the capsular flap, resulting in difficulty grasping the flap.

What should you do?

Inject viscoelastic into the anterior chamber to flatten the anterior surface of the lens and aid in visualizing the leading edge of the capsular flap. Re-position the forceps on the capsular flap and continue the capsulorrhexis.

simply just being able to pick it up after numerous attempts

- B. Grasping flap too close to the tear, causing extension peripherally

This can lead to a normal continuation or this can lead to rhexis going out peripherally

What happened?

The forceps were not positioned appropriately on the capsular flap. In this case the forceps grasped the flap too close to the leading edge of the capsulorrhexis, which predisposed to peripheral extension of the capsulorrhexis.

What should you do?

Inject viscoelastic into the anterior chamber to flatten the anterior surface of the lens and aid in visualizing the leading edge of the capsular flap. If the capsulorrhexis has extended peripherally, assess the degree of peripheral extension and attempt to re-direct the capsular flap centrally. If the capsulorrhexis has not extended peripherally, re-position the forceps on the capsular flap and continue the capsulorrhexis.

- C. Grasping flap too far away from the tear, causing uncontrolled direction – going peripherally

Show re-grasping of flap closer to middle of flap and frequent re-grasping of flap (~ every 2-3 clock hours for novices)

What happened?

The forceps were not positioned appropriately on the capsular flap. In this case the forceps grasped the flap too far from the leading edge of the capsulorrhexis which predisposed to peripheral extension of the capsulorrhexis.

What should you do?

Inject viscoelastic into the anterior chamber to flatten the anterior surface of the lens and aid in visualizing the leading edge of the capsular flap. If the capsulorrhexis has extended peripherally, assess the degree of peripheral extension and attempt to re-direct the capsular flap centrally. If the capsulorrhexis has not extended peripherally, re-position the forceps on the capsular flap and continue the capsulorrhexis.

D. Lifting forceps anteriorly while tearing flap – causing the flap to go peripherally

Show dropping forceps more posteriorly towards lens to better control tear direction
What happened?

The forceps were lifted too anteriorly while extending the flap of the capsulorrhexis, resulting in poor control of the capsular flap and peripheral extension of the capsulorrhexis.

What should you do?

Inject viscoelastic to flatten the anterior curvature of the lens. If the capsulorrhexis has not extended to the zonules, re-grasp the capsular flap with the forceps and pull towards the center of the lens, with care being taken to ensure all force applied is tangential to the lens and not directed anteriorly.

This motion should re-direct the capsular flap centrally and permit continuation of the capsulorrhexis.

E. Pushing on the incision while tearing causing viscoelastic to escape out of eye, flattening anterior chamber and causing tear to extend peripherally (good place to show cross section)

Show reinjection of viscoelastic, deepening of anterior chamber, flattening out of anterior lens configuration (good place to show cross section) or can lead to extension of capsule

What happened?

Viscoelastic egressed from the clear cornea wound as a result of excessive downward force applied on the posterior aspect of the clear corneal wound by the forceps. The loss of viscoelastic fill resulted in flattening of the anterior chamber and allowed the anterior surface of the lens to regain its curvature, predisposing to peripheral capsular extension.

What should you do now?

Inject viscoelastic into the anterior chamber to achieve flattening of the anterior surface of the lens. Re-position the forceps so that minimal downward force is being applied to the posterior aspect of the clear cornea wound. Re-direct the capsulorrhexis centrally if it has not extended to the zonules (link to peripheral capsular extension)

Can Opener Capsulotomy

1. Inject viscoelastic solution to deepen the anterior chamber
2. Using a cystatome (bent 25 gauge needle), puncture the anterior lens capsule near the pupillary margin
3. Make small 0.5mm dash incisions that together will create a large 7mm circular opening in the anterior capsule
 - A. Difficulty connecting the dashes, so end up with dis-connected dashes
4. After the dash incisions have been completed, place the tip of the cystatome in the capsule incision and sweep around the entire circumference of the capsule opening to ensure that it is complete
5. Using capsule forceps or an angled McPherson forceps, grasp the center of the capsule and remove the circular flap that was created
 - a. Difficulty visualizing capsule
 - b. Difficulty making the capsulotomy complete without causing radial extension

****What are risk factors for zonular weakness and how can you assess for zonular instability pre-operatively? (Expert)**

Risk factors: History of trauma, history of retinal surgery, pseudoexfoliation

Pre-operative assessment: look for phacodonesis at slit lamp (ask pt to look side to side while inspecting lens at slit lamp, bang on slit lamp table → look for excessive lens movement), look for zonular absence, assess for notable lenticular astigmatism

**** How and when do you decide to use a capsular tension ring? (Expert)**

Zonular dialysis noted on pre op exam

Zonulolysis intra op (during forceful lens rotation, I/A grabbing capsule, PXF, etc)

****How do you handle a small pupil when performing a capsulorrhexis? (Expert)**

Enlarge the pupil to aid visualization:

Iris stretch – good for PXF

Iris hooks- good for IFIS

****What adjustments do you make in your rhexis technique for a dense, mature lens? (Expert)**

Stain the anterior capsule (trypan)

Ensure AC remains inflated with viscoelastic

Consider more cohesive viscoelastic

Be prepared for liquefied cortex in intumescent lens- may need to remove with syringe vs. move the liquefied cortex with viscoelastic for visualization

**** How do you handle a lost capsulorrhexis flap? (Expert)**

**** What are the causes of positive pressure? (Expert)**

Speculum, patient valsalva or holding breath, increased orbital pressure (small orbit, excessive volume of block, retrobulbar hemorrhage), aqueous misdirection, choroidal hemorrhage

B) NUCLEUS REMOVAL

Divide and Conquer

1. Enter the anterior chamber with the phacoemulsification probe bevel down

A. Otherwise, difficulty getting phaco in eye

What happened?

The bevel of the phacoemulsification probe was pointed up on insertion through the clear corneal wound into the anterior chamber, creating difficulty with instrument insertion.

What should you do?

Rotate the phacoemulsification probe so that the bevel is pointed down. This will allow smoother insertion of the phacoemulsification tip into the eye.

B. Cause descemet's tear with forcing phaco in eye

What happened?

A descemet's tear was created at the clear corneal wound when inserting the phacoemulsification probe into the eye.

What should you do?

Extreme caution should be taken when inserting and extracting instruments into the eye for the remainder of the case so as not to extend the descemet's tear. At the conclusion of the case the flap of descemet's membrane should be re-

apposed to the corneal stroma. If the flap of descemet's membrane is small, a filtered air bubble can be injected into the eye to re-position the flap. If the flap of descemet's membrane is large, a suture may be needed to achieve repair of the descemet's tear.

What are the risk factors for creating a descemet tear/flap?

Frequent re-entry into the eye with phaco probe, excessive wound manipulation, phaco probe angled too anteriorly throughout case

2. Once inside, rotate the bevel up
3. Place the second instrument (i.e. Drysdale) into the eye
4. Vacuum out a small amount of viscoelastic solution immediately above the lens
 - A. If not, can cause a viscoelastic block of tip and cause thermal injury
5. Make a central groove by sculpting out thin layers of the nucleus
6. The ultrasound power is only on when sculpting forward. Only irrigation is kept on while withdrawing the phaco probe to prepare for another sculpting pass
7. Groove down to @ 80-90% of the nucleus depth

A. Groove is too deep-and inadvertently grooves down into and past the capsule – (must continue with broken capsule- new pathway)

What happened?

The groove was too deep and the phacoemulsification probe went through the posterior capsule.

What should you do?

Before extracting the phacoemulsification handpiece from the eye, dispersive viscoelastic should be injected into the anterior chamber. The handpiece should be carefully extracted from the eye. Scissors should be used to cut any strands of vitreous that emerge from the clear corneal wound on extraction of the phacoemulsification handpiece. The anterior chamber should then be assessed and a plan should be made for safely continuing the case in a manner that minimizes vitreous prolapse and the likelihood of dropping lens fragments posteriorly. (link to PC tear)

How can this be prevented in the future?

Slow controlled forward passes with the phacoemulsification handpiece are the best way to minimize the risk of grooving too deeply and penetrating the posterior capsule. Brightening of the red reflex is a key sign that there is minimal residual lens material at the deep aspect of the groove and care should be taken with any additional grooving.

B. too shallow- (unable to crack later on)

What happened?

The groove was not deep enough, preventing cracking of the nucleus into quadrants.

What should you do?

There are several possible causes of difficulty with cracking the nucleus. A common etiology is a shallow or short groove. Deepening or extending the previously created groove can often lead to successful cracking. Another common cause of inability to crack is inappropriate instrument position or motion. The phacoemulsification probe and second instrument should be deep in the groove to exert force on the posterior aspect of the lens. Gentle outward force should be exerted on the distal most portion of the instrument to achieve cracking of the nucleus.

C. inconsistent depth- (unable to crack later on)

What happened?

The groove had inconsistent depth, preventing the cracking of the nucleus into quadrants.

What should you do?

There are several possible causes of difficulty with cracking the nucleus. A common etiology is a shallow or short groove. Deepening

or extending the previously created groove can often lead to successful cracking. Another common cause of inability to crack is inappropriate instrument position. The phacoemulsification probe and second instrument should be deep in the groove to exert force on the posterior aspect of the lens. Gentle outward force should be exerted on the distal most portion of the instrument to achieve cracking of the nucleus.

D. Groove is not peripheral enough – (unable to crack later on)

What happened?

The groove did not extend far enough peripherally, preventing cracking of the nucleus.

What should you do?

There are several possible causes of difficulty with cracking the nucleus. A common etiology is a shallow or short groove. Deepening or extending the previously created groove can often lead to successful cracking. Another common cause of inability to crack is inappropriate instrument position. The phacoemulsification probe and second instrument should be deep in the groove to exert force on the posterior aspect of the lens. Gentle outward force should be exerted on the distal most portion of the instrument to achieve cracking of the nucleus.

F. Loss of groove and creation of a bowl (makes quadrant removal challenging)

What happened?

The grooves were too wide, bowling out the center of the lens and leaving a peripheral shell that can be challenging to safely phacoemulsify.

What should you do?

8. After the groove is of sufficient depth, use the second instrument to rotate the lens 90 degrees
 - A. Rotating incorrectly – pushing lens causing zonulolysis (maybe this could be a pop up when done incorrectly with an expert describing how to rotate – using 2 point rotation or how not to push the lens too peripherally or too posteriorly)
9. Make another central groove in a similar fashion
10. Rotate the lens 90 degrees and continue to sculpt the lens
11. Rotate another 90 degrees and finish sculpting the final groove
12. The grooves should be in a cruciate design
13. Place the phaco probe and the second instrument side by side inside a groove
14. Place the tips as far posterior in the groove as possible
15. Slowly separate the tips of the instruments, pushing the sides of the groove apart and crack the lens down the groove
 - a. Lens does not crack- (this could be a pop up (or multiple pop ups) that describes common errors that cause difficulty in cracking- i.e. wrong placement of instruments too anteriorly on lens, wrong cracking motion of causing separation of the proximal portions of the instrument rather than the tips of the instruments, groove is not deep enough so it won't crack, lens is soft so groove has to be deep and peripheral), or lens is very dense and leathery so posterior portion of the lens won't crack. Another pop up could discuss how sometimes when attempting to crack numerous times in a soft lens, you can end up bowling out the lens rather than cracking it.
 - b. Anterior capsule tear (secondary to excessive movement of instruments)
 - c. Posterior capsule tear (secondary to excessive downward pressure)
16. Rotate 90 degrees and repeat cracking maneuver 3 more times to end up with 4 separate quadrants

** What do you do if you are having difficulty cracking the nucleus into quadrants?

**What do you do if you are having difficulty removing the nuclear quadrants?

** What techniques do you use to extract a “bowled out” lens?

** What do you do if you notice a zonular dialysis during removal of the nucleus?

**What are the signs of a posterior capsule tear?

**How do you manage a posterior capsule tear when nuclear fragments remain in the eye?

Horizontal Chop

1. Enter the anterior chamber with the phacoemulsification probe bevel down
2. Once inside, rotate the bevel up
3. Place the chopper in the eye through the paracentesis site
4. Vacuum out a small amount of viscoelastic solution immediately above the lens
5. Turn phaco tip upside down and embed phaco into lens nucleus
6. Turn the chopper horizontally and slide it underneath the anterior capsule and out to the equator of the lens opposite the phaco probe
 - A. Unable to get chopper out to equator
 - B. Improper placement of chopper on top of anterior capsule and cutting into anterior capsule- (leads to a different pathway – can continue carefully and can continue the rest of the surgery without complications or can cause the anterior capsular tear to continue past the equator and cause a posterior capsular tear. This can cause lens dislocation and or conversion to ECCE) This can lead to anterior vitrectomy, discussion of vitrectomy settings, methods, when to cut, aspirate, etc.
 - C. Unable to hold onto lens with phaco – lens too soft or settings on phaco machine too low (on sculpt settings rather than quadrant removal settings)
7. When the chopper is situated at the lens equator, turn the chopper vertically
8. Bring the chopper towards the phaco probe while continuing to hold the lens half with the phaco probe
9. When the chopper and the phaco meet, slightly lift the phaco that is holding the lens as the chopper is moved sideways towards the limbus and slightly downward
10. Repeat this horizontal chopping maneuver until lens is completely chopped into multiple pie pieces
11. Once lens is divided into pie pieces, aspirate out one fragment at a time.
12. Place chopper between phaco and posterior capsule as a protective barrier to avoid phacoing into posterior capsule (as a result of surge) (this could be a pop up – showing surge causing the posterior capsule to come up and phacoing into posterior capsule)
 - A. Especially for last fragment, discuss use of viscoelastic to float up piece

**In what situations do you choose to chop versus divide and conquer?

**What do you do if you cannot engage the hemi-nucleus with the phacoemulsification probe?

Vertical Chop

1. Enter the anterior chamber with the phacoemulsification probe bevel down
2. Place a sharp tipped chopper in the eye through the paracentesis site
1. Vacuum out a small amount of viscoelastic solution immediately above the lens
2. Bury the phaco probe keeping the bevel down into the center of the nucleus with ultrasound and vacuum
3. While holding the lens, impale the nucleus with the chopper adjacent to the phaco tip
 - A. Unable to hold onto lens with phaco – lens too soft or settings too low
4. Crack the nucleus by separating the chopper and the phaco probe away from each other
 - a. Unable to crack lens- chopper pushes off fragment at end of phaco rather than chopping and cracking lens
5. Repeat this cracking maneuver until smaller fragments are fractured off and can be easily aspirated by the phaco probe
6. Continue to crack then remove fragments

- A. Unable to remove cracked fragment- stuck together because cracks were incomplete (this could be a pop up describing how to deal with getting fragments out of the eye)
- B. Inadvertently rip posterior capsule or anterior capsule while chopping
(this will lead to different pathway with ripped posterior capsule)
Fragment of nucleus falls into vitreous

SUPPORTING DATA

None