

60th Medical Group (AMC), Travis AFB, CA
INSTITUTIONAL ANIMAL CARE AND USE COMMITTEE (IACUC)
FINAL REPORT SUMMARY

(Please type all information. Use additional pages if necessary.)

PROTOCOL #: FDG20120019A

DATE: 3 April 2015

PROTOCOL TITLE: "Porcine (*Sus scrofa*) Chronic Myocardial Infarction Model Development."

PRINCIPAL INVESTIGATOR (PI) / TRAINING COORDINATOR (TC): Lt Col. Daren Danielson

DEPARTMENT: 60MSGs/SGCH

PHONE #: 423-2300

INITIAL APPROVAL DATE: 27 June 2012

LAST TRIENNIAL REVISION DATE: 31 May 2014

FUNDING SOURCE: Surgeon General Office

1. **RECORD OF ANIMAL USAGE:**

Animal Species:	Total # Approved	# Used this FY	Total # Used to Date
<i>Sus scrofa</i>	10	0	10

2. **PROTOCOL TYPE / CHARACTERISTICS:** (Check all applicable terms in **EACH** column)

- | | | |
|--|--|--|
| <input type="checkbox"/> Training: Live Animal | <input type="checkbox"/> Medical Readiness | <input type="checkbox"/> Prolonged Restraint |
| <input type="checkbox"/> Training: non-Live Animal | <input type="checkbox"/> Health Promotion | <input type="checkbox"/> Multiple Survival Surgery |
| <input checked="" type="checkbox"/> Research: Survival (chronic) | <input type="checkbox"/> Prevention | <input type="checkbox"/> Behavioral Study |
| <input type="checkbox"/> Research: non-Survival (acute) | <input type="checkbox"/> Utilization Mgt. | <input type="checkbox"/> Adjuvant Use |
| <input type="checkbox"/> Other () | <input type="checkbox"/> Other (Treatment) | <input type="checkbox"/> Biohazard |

3. **PROTOCOL PAIN CATEGORY (USDA):** (Check applicable) C D E

4. **PROTOCOL STATUS:**

***Request Protocol Closure:**

- Inactive, protocol never initiated
- Inactive, protocol initiated but has not/will not be completed
- Completed, all approved procedures/animal uses have been completed

5. **Previous Amendments:**

List all amendments made to the protocol.. **IF none occurred, state NONE. Do not use N/A.**

For the Entire Study Chronologically

Amendment Number	Date of Approval	Summary of the Change
1		Personnel added: Neff, Gallogly, Humphrey
2		Change from 8 mini pigs to 6 farm pigs and 2 mini pigs
3		Personnel added: Southard, Riddock
4		Personnel added: Julian

6. **FUNDING STATUS:** Funding allocated: \$ Funds remaining: \$ 0.00

7. **PROTOCOL PERSONNEL CHANGES:**

Have there been any personnel/staffing changes (PI/CI/AI/TC/Instructor) since the last IACUC approval of protocol, or annual review? Yes No

If yes, complete the following sections (Additions/Deletions). For additions, indicate whether or not the IACUC has approved this addition.

ADDITIONS: (Include Name, Protocol function - PI/CI/AI/TC/Instructor, IACUC approval - Yes/No)

See section 5. All were approved by the IACUC.

DELETIONS: (Include Name, Protocol function - PI/CI/AI/TC/Instructor, Effective date of deletion)

None.

8. **PROBLEMS / ADVERSE EVENTS:** Identify any problems or adverse events that have affected study progress. Itemize adverse events that have led to unanticipated animal illness, distress, injury, or death; and indicate whether or not these events were reported to the IACUC.

1. LAD arterial dissection resulting in ventricular fibrillation and euthanasia. Reported to IACUC -

9. **REDUCTION, REFINEMENT, OR REPLACEMENT OF ANIMAL USE:**

REPLACEMENT (ALTERNATIVES): Since the last IACUC approval, have alternatives to animal use become available that could be substituted in this protocol without adversely affecting study or training objectives?

None.

REFINEMENT: Since the last IACUC approval, have any study refinements been implemented to reduce the degree of pain or distress experienced by study animals, or have animals of lower phylogenetic status or sentience been identified as potential study/training models in this protocol?

None.

REDUCTION: Since the last IACUC approval, have any methods been identified to reduce the number of live animals used in this protocol?

None.

10. **PUBLICATIONS / PRESENTATIONS:** (List any scientific publications and/or presentations that have resulted from this protocol. Include pending/scheduled publications or presentations).

"Embolization of the first diagonal branch of the left anterior descending artery as a porcine model of chronic ischemic cardiomyopathy". Journal of Translational Medicine. – Under review

Derek W. Hanes, Maelene L. Wong, C.W. Jenny Chang, Sterling Humphrey, J. Kevin Grayson, Walter D. Boyd, Leigh G. Griffiths

11. **Were the protocol objectives met, and how will the outcome or training benefit the DoD/USAF?**

Through this model, we were able to create, minimally invasively, a myocardial infarction that was isolated to the mid-anterior, left ventricular wall. In doing so, we were able to create an infarct that resulted in decreased systolic function and chronic remodeling similar to the native disease found in people, while reducing the number of adverse events (ventricular fibrillation, cardiogenic shock, etc) associated with alternative models. This model will benefit the DoD in that this protocol can be used to investigate new methodologies for treatment of chronic myocardial infarction in individuals afflicted with chronic ischemic cardiomyopathy.

12. **PROTOCOL OUTCOME SUMMARY:** (Please provide, in "ABSTRACT" format, a summary of the protocol objectives, materials and methods, results - include tables/figures, and conclusions/applications.)

(PI / TC Signature)

(Date)

Attachments:

Attachment 1: Defense Technical Information Center (DTIC) Abstract Submission **(Mandatory)**

Attachment 1

Defense Technical Information Center (DTIC) Abstract Submission

This abstract requires a brief (no more than 200 words) factual summary of the most significant information in the following format: Objectives, Methods, Results, and Conclusion.

Objectives:

This study was aimed at the development of a novel closed-chest porcine model of ischemic cardiomyopathy, which closely mimics the native disease found in people, and could be chronically monitored via standard transthoracic echocardiography (TTE), while attempting to reduce the number of adverse events associated with alternate models.

Methods:

Eight Yucatan miniature pigs underwent percutaneous embolization of the D1-LAD via injection of 90 µm polystyrene micro-spheres. Cardiac structure and function were monitored using TTE. Post-mortem histopathology and biochemical analysis were performed to evaluate for changes in myocardial structure and extracellular matrix composition respectively.

Results:

Overall procedural survival rate was 83% (5/6) with one pig excluded due to failure of infarction and another due to deviation from protocol. Systolic dysfunction was appreciated following infarction denoted by a significant reduction in ejection fraction and increase in ventricular internal diameter in systole (LVIDs). Histopathology showed the presence of disorganized fibrosis, and biochemical analysis was consistent with fibrotic replacement of normal myocardium.

Conclusion:

Systolic dysfunction and changes in extracellular matrix composition induced via embolization of the D1-LAD closely mimic those found in individuals with chronic ICM, and represent a location visible without the need for anesthesia.

Grant Number: TR3-05626

From: California Institute of Regenerative Medicine

****If you utilized an external grant, please provide Grant # and where the grant came from. Thank you.**

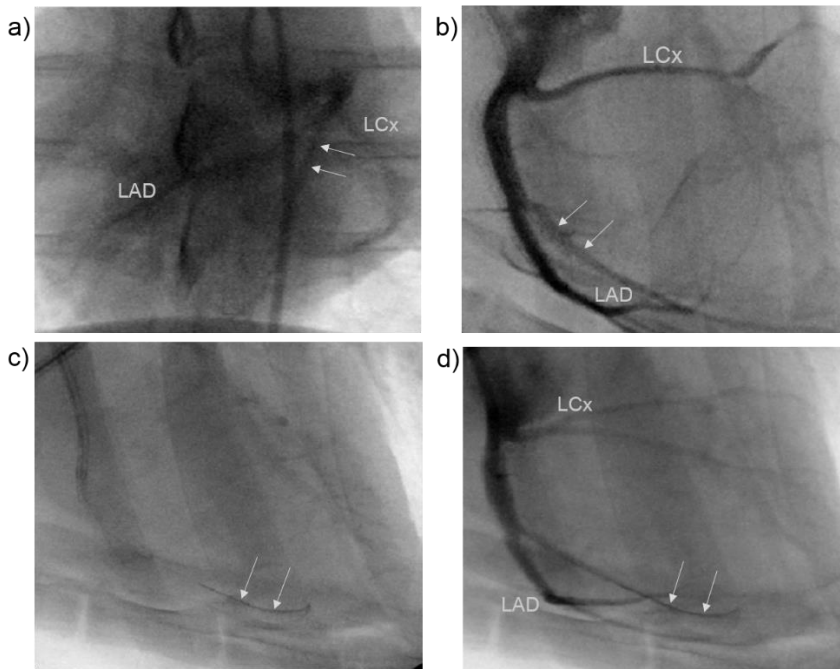


Figure 1. Left main coronary angiography and D1-LAD catheterization. Coronary angiography of the left main coronary artery in ventrodorsal (a) and lateral (b) projections. The left coronary anatomy, including left circumflex coronary (LCx) and left anterior descending (LAD) arteries is clearly visualized. The D1-LAD artery was identified and is shown outlined here by the arrows in the ventrodorsal and lateral views. Following identification of the D1-LAD artery, the artery was then catheterized with a 0.014" micro-guide wire with correct wire positioning designated by arrows on lateral projection (c). Repeat angiography was performed following wire advancement (d) with the wire still present designated by the arrows.

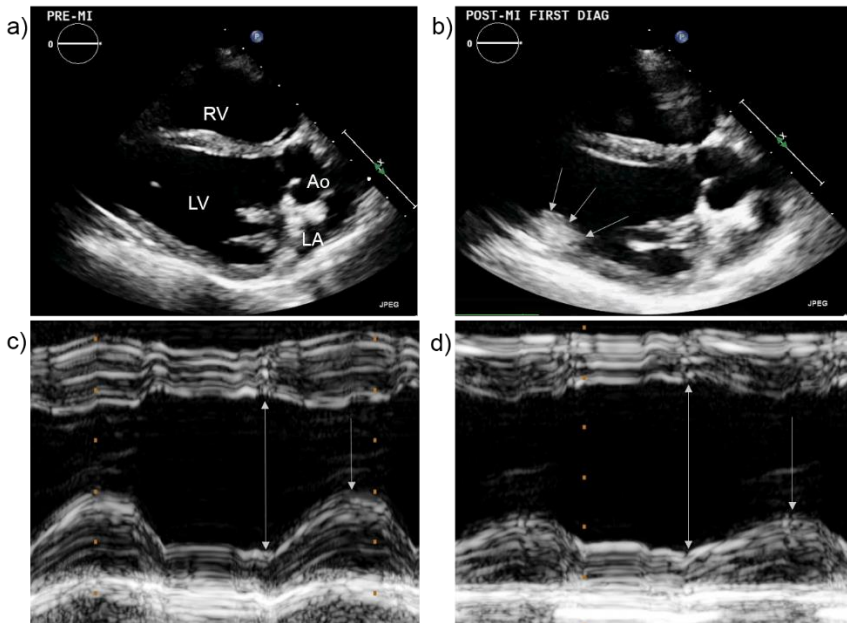


Figure 2. Two-dimensional (2D) and M-mode echocardiography prior to and following D1-LAD occlusion. Echocardiography was performed prior to (a) and following D1-LAD occlusion. Occasionally, the presence of the infarct could be seen as a hyperechoic amorphous mass on 2D images, associated with the left ventricular posterior wall and anterolateral papillary muscle, shown here outlined by arrows (b). Compared to pre-MI M-mode images (c), there was an appreciable decrease in systolic excursion of the left ventricular posterior wall following D1-LAD occlusion (d). The double arrows represent the left ventricle at its maximal diastolic diameter, while the single arrows represent the maximal systolic excursion of the LV posterior wall.

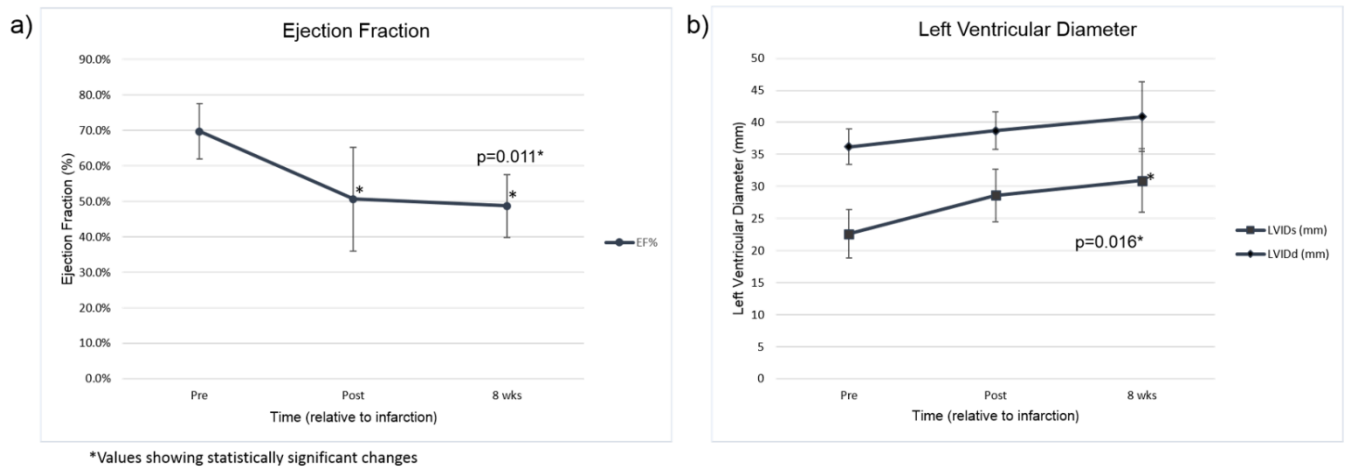


Figure 3. Changes in left ventricular ejection fraction (LVEF) and systolic internal diameter (LVIDs). LVEF decreased immediately following embolization of the D1-LAD artery (a). This decrease in LVEF continued through the 8 week endpoint (a). At 8 weeks post-embolization LVIDs was significantly increased compared to baseline (b). There was an apparent trend to LVIDd enlargement as well throughout the allotted timeframe.

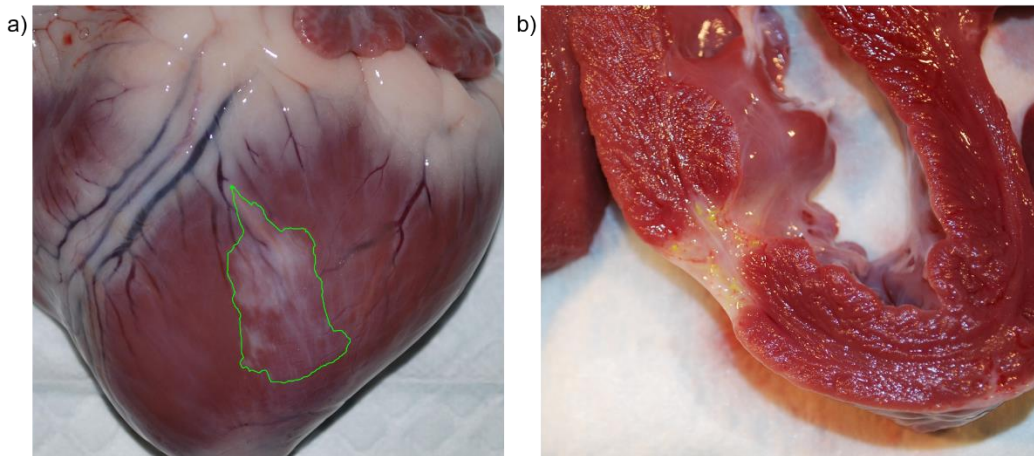


Figure 4. Gross cardiac evaluation of infarct size and distribution. Gross cardiac evaluation at 8 weeks post-MI showed a multifocal, pale, light tan, firm area in the left ventricular posterior wall, midway between the apex and left circumflex coronary artery (arrows) (a). Transverse sections of the heart showed that the infarcted area extended into the full thickness of the myocardium with subsequent ventricular wall thinning when compared to the adjacent normal myocardium (b).

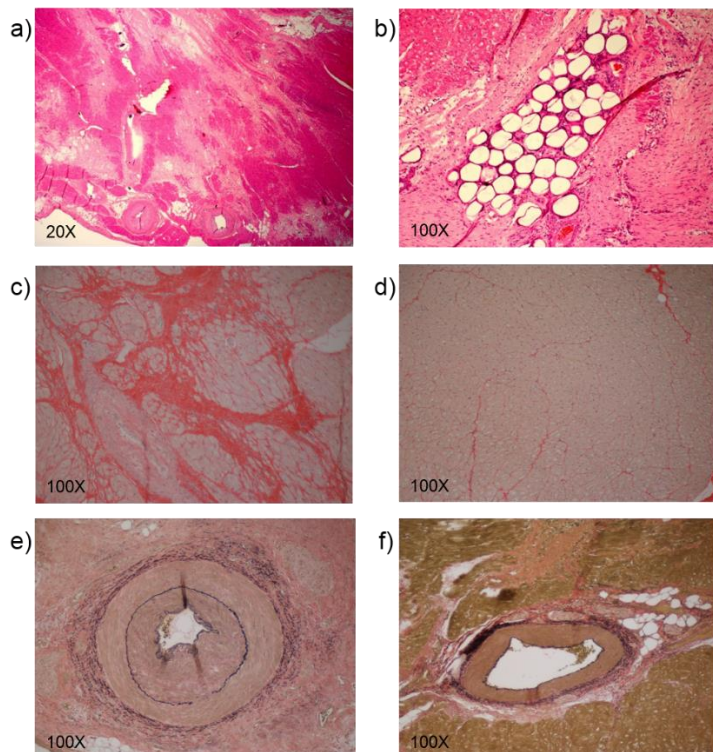


Figure 5. Histopathology of infarcted versus normal myocardium. Hematoxylin and eosin staining of representative infarcted areas demonstrated a heterogenous area of dense, fibrous, connective tissue intermixed with islets of intact cardiomyocytes (a). Microsphere silhouettes were visualized occluding small arteries and arterioles shown here as stain filling defects (b). Further evaluation with Picro Sirius stain revealed a large amount of disorganized collagen deposition and perifer fiber fibrosis in the infarcted region denoted by the deeply red staining sections (c), when compared to normal myocardium (d). Evaluation of VVG stained slides demonstrated hyperplasia of the arterial walls, particularly in the media and adventitial layers (e) when compared to normal arteries (f).

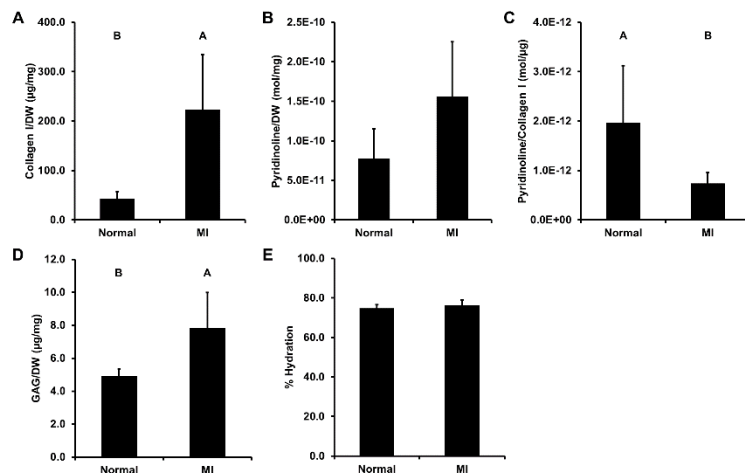


Figure 6. Biochemical composition of normal and infarcted myocardium. Collagen I content was significantly greater in infarcted myocardium than normal septum (a). Although pyridinoline crosslink content trended lower in the septum than the MI, the difference was not statistically significant (b). Pyridinoline crosslink content per collagen I content was significantly lower in infarcted myocardium than normal septum (c). Sulfated GAG content was significantly greater in infarcted myocardium than normal septum (d). Water content in MI was not significantly different than that in normal septum (e). Results plotted as mean \pm standard deviation. Groups not connected by same letter are significantly different, $p < 0.05$ ($n = 5$ per group).