



5158 Blackhawk Road, Aberdeen Proving Ground, Maryland 21010-5403

Toxicological Study No. S.0035303-15, March 2016

Toxicology Portfolio

Division of Toxicologic Pathology

**Pathology Report for Intraperitoneal Sodium Dichromate Exposure in Rats
Protocol No.15-002-3, 8 December 2015**

Prepared by:

Erica E. Carroll, DVM, PhD, Diplomate ACVP

Approved for public release; distribution unlimited.

Specialty: 500C, Toxicity Tests

REPORT DOCUMENTATION PAGE					Form Approved OMB No. 0704-0188	
<p>The public reporting burden for this collection of information is estimated to average 1 hour per response, including the time for reviewing instructions, searching existing data sources, gathering and maintaining the data needed, and completing and reviewing the collection of information. Send comments regarding this burden estimate or any other aspect of this collection of information, including suggestions for reducing the burden, to Department of Defense, Washington Headquarters Services, Directorate for Information Operations and Reports (0704-0188), 1215 Jefferson Davis Highway, Suite 1204, Arlington, VA 22202-4302. Respondents should be aware that notwithstanding any other provision of law, no person shall be subject to any penalty for failing to comply with a collection of information if it does not display a currently valid OMB control number.</p> <p>PLEASE DO NOT RETURN YOUR FORM TO THE ABOVE ADDRESS.</p>						
1. REPORT DATE (DD-MM-YYYY) 08/12/2015		2. REPORT TYPE Technical (Pathology) Report			3. DATES COVERED (From - To) MAR 2015-DEC 2015	
4. TITLE AND SUBTITLE Toxicological Study No. S.0035303-15, Protocol No.15-002-3, Pathology Report for Intraperitoneal Sodium Dichromate Exposure in Rats				5a. CONTRACT NUMBER		
				5b. GRANT NUMBER		
				5c. PROGRAM ELEMENT NUMBER S.0035303-15		
				5d. PROJECT NUMBER		
6. AUTHOR(S) Carroll, Erica E.				5e. TASK NUMBER		
				5f. WORK UNIT NUMBER		
7. PERFORMING ORGANIZATION NAME(S) AND ADDRESS(ES) Division of Toxicologic Pathology, Toxicology Directorate, Army Public Health Center, Aberdeen Proving Ground, MD 21010				8. PERFORMING ORGANIZATION REPORT NUMBER Toxicology Study No. S.0035303-15		
9. SPONSORING/MONITORING AGENCY NAME(S) AND ADDRESS(ES) U.S. Army Center for Environmental Health Research, 568 Doughten Drive, Fort Detrick, MD 21702				10. SPONSOR/MONITOR'S ACRONYM(S) Dr. Michael S. Madejczyk		
				11. SPONSOR/MONITOR'S REPORT NUMBER(S) Protocol No. 15-002-3		
12. DISTRIBUTION/AVAILABILITY STATEMENT Unlimited Distribution						
13. SUPPLEMENTARY NOTES						
14. ABSTRACT This project was a collaboration between USACEHR and APHC (Div Tox Path) to process and microscopically evaluate kidney and liver tissues from rats intraperitoneally injected with sodium dichromate dihydrate for a project to identify molecular markers in blood or urine that predict or indicate liver and/or kidney injury resulting from exposure to specific metal intoxication. The investigator aims to validate hypothesized adverse outcome pathways in rats exposed to toxic metals to identify less invasive, rapid biomarkers that could be used in early disease progression. Sodium dichromate dihydrate caused persistent inflammation on the peritoneal surface of liver and kidney tissues after a single injection.						
15. SUBJECT TERMS biomarkers; chromium; intraperitoneal; kidney; liver; metal; rat; sodium dichromate dihydrate; toxicity						
16. SECURITY CLASSIFICATION OF:			17. LIMITATION OF ABSTRACT	18. NUMBER OF PAGES	19a. NAME OF RESPONSIBLE PERSON	
a. REPORT	b. ABSTRACT	c. THIS PAGE			LTC Erica E. Carroll	
UNCLAS	U	U	U		19b. TELEPHONE NUMBER (Include area code) 410.436.7014	

GOOD LABORATORY PRACTICE COMPLIANCE STATEMENT

This pathology investigation was conducted in a manner consistent with the principles of the United States Environmental Protection Agency (USEPA) Good Laboratory Practice regulations of the Toxic Substances Control Act (TSCA), as detailed in 40 CFR Part 792, plus amendments.

CARROLL.ERICA.E.1027432413[®]

Erica E. Carroll, DVM, PhD, Diplomate ACVP
LTC, VC
Study Pathologist
Toxicology Portfolio
Army Public Health Center (Provisional)

14 March 2016
Date

Table of Contents

	<u>Page</u>
1 Summary	1
1.1 Purpose	1
1.2 Authority	1
2 References	1
3 Methods	1
4 Results	2
5 Discussion	3
6 Photomicrographs	5
7 Point of Contact	11

Appendices

A	References	A-1
B	Quality Assurance Statement	B-1
C	Archives	C-1
D	Incidence of Histologic Observations	D-1
E	Individual Animal Data	E-1

Figures

1	Rat #001 Kidney, Vehicle Control, Day 1 Post-Injection	5
2	Control and Treated Rats, Kidney	6
3	Rat #078, Kidney, 20 mg/kg Day 14	7
4	Liver, Glycogen Depletion	8

	<u>Page</u>
5 Rat #001, Liver, Vehicle Control, Day 1 Post-Injection.....	9
6 Rat #007, Liver, 5 mg, Day 1 Post-Injection.....	10
7 Rat #018, Liver, 20 mg/kg Cr, Day 1 Post-Injection	11

Toxicological Study No. S.0035303-15
Protocol No.15-002-3
Pathology Report for
Intraperitoneal Sodium Dichromate Exposure in Rats
8 December 2015

1 Summary

1.1 Purpose

The U.S. Army Center for Environmental Health Research (USACEHR) requested the Army Public Health Center (Provisional) (APHC (Prov)) [formerly the Army Institute of Public Health (AIPH)]-Toxicology (TOX) Portfolio, Division of Toxicologic Pathology to provide tissue processing and evaluation for a project to identify molecular markers in blood or urine that would predict or indicate liver and/or kidney injury resulting from exposure to specific metal intoxication. The investigators aim was to validate hypothesized adverse outcome pathways in rats exposed to toxic metals to identify less invasive, rapid biomarkers that could be used in early disease progression.

1.2 Authority

The Statement of Work (Project title: Pathology Support for Cr and Cd Gavage and IP Exposures in Rats) was for this single task to be performed between 1 June and 31 December 2015 with analysis of findings, interpretation of results and a comprehensive “unclassified” report delivered to the primary investigator (Dr. Michael Madejczyk, USARMY MEDCOM USACEHR (US)).

2 References

See Appendix A for a listing of references.

3 Methods

Conical tubes containing formalin and liver and kidney tissues from 80 7–8 week-old male Sprague-Dawley rats were received from USACEHR. Identification numbers of 001 – 080 were submitted. Those animals with identification (ID) numbers greater than “20” had half of the right kidney as well as the left kidney submitted. Some sections of liver appeared pink, indicating inadequate formalin fixation. Overall, tissues were adequately preserved for histologic evaluation. Rats were organized in groups of five animals per dosage group with dosages of 0, 5, 10, and 20 milligrams per kilogram (mg/kg) per day. Rats had been administered a single intraperitoneal (IP) injection of sodium dichromate dihydrate and then observed for either 24 hours (Day 1), 3 days, 7 days, or 14 days before being humanely euthanized under isoflurane anesthesia via exsanguination and organ removal. Post-mortem tissue collection was immediately performed, the tissues fixed in 20 volumes of formalin per volume of tissue for at least 4 weeks, and shipped to the APHC (Prov), Division of Toxicologic Pathology for processing and evaluation.

4 Results

Paragraph 6 consists of select photomicrographs to illustrate lesions identified. Appendix D contains tables that summarize the scores assigned to observations and number of animals per group with each score. Appendix E contains individual animal scores.

Kidney: In rats euthanized Day 1 (24 hours) post-sodium dichromate dihydrate injection, there were no appreciable renal lesions at any dosage that differed from background lesions observed in controls (Figure 1). By day 3, however, treated rats were more often exhibited tubule basophilia, leukocyte infiltrate in the capsule (but neither was dose-dependent), subcapsular single cell necrosis was evident only at the highest dose, and minimal capsular fibroplasia in exposed animals. Rats euthanized 7 days after a single IP injection were slightly more likely (i.e., 5 of 15 treated rats compared to zero control rats) to have protein in at least one tubule (a score of “minimal” or “1”) and minimal to mild renal capsular mononuclear and granulocytic infiltrates and fibroplasia (Figure 2). Of rats euthanized 14 days after a single IP injection (at the two higher doses), 6 of 10 medium and high-dose rats compared to 0 of 10 control and low-dose rats had minimal to moderate infiltrates of mononuclear and granulocytic cells in the capsule with capsule fibroplasia (Figure 3).

Liver: In rats euthanized 24 hours post-injection, those administered the high dose of compound, had less lacy hepatocellular cytoplasm which was presumed to be glycogen (Figures 4 and 5). High dose rats exhibited minimal portal lymphocytic infiltrates. Eleven of 15 treated rats compared to zero of five control rats had “minimal” to “mild” subcapsular mononuclear and granulocytic infiltrates (Figure 6). Sample sizes were very small, but the number per group of rats to exhibit any subcapsular granulocytic, mononuclear infiltrates, or single cell hepatocellular necrosis was greater, the higher the exposure. Eleven of 15 treated rats (versus zero of five controls) also had fibrin on the capsular surface (Figure 7).

Three days after a single IP injection of sodium dichromate, all rats exhibited comparable amounts of the lacy hepatocellular vacuolation (presumed glycogen). Treated rats were more likely to have a mononuclear or granulocytic subcapsular infiltrate. Capsular fibrin and fibroplasia were only observed in treated animals but not in a dose-dependent manner. Two rats (one medium dose and one high dose) exhibited minimal bridging fibrosis. Rats euthanized 3 and 7 days post-injection all had lacy hepatocellular cytoplasm suggestive of glycogen accumulation in portal-to-midzonal areas. These rats exhibited minimal portal lymphoplasmacytic or, rarely, granulocytic infiltrates that was not considered to be compound related. Subcapsular mononuclear or granulocytic infiltrates were present only in liver sections of treated rats, but without an apparent dose-dependent relationship. Only livers from rats exposed to the lowest dose exhibited capsule fibrin 3-days post injection and capsular fibroplasia was only observed in rats administered the medium and higher dose injection (4 of 10 medium and high-dose animals versus 0 of 10 control and low-dose rats). Bridging fibrosis was only observed in one medium-dose and one high-dose rat.

Seven days post-injection rat livers exhibited minimal glycogen in virtually every rat. One rat exhibited minimal portal granulocytic infiltrates, but between two and four of five rats per group had lymphocytic portal infiltrates. Treated rats had capsular mononuclear and/or granulocytic infiltrates. Twelve of 15 treated rats (no controls) exhibited minimal capsular fibroplasia and two high-dose rats had focal bridging fibrosis.

Rats euthanized 14 days post-injection exhibited the presumed hepatocellular glycogen in every animal except for two high-dose animals. Treated animals more often had minimal portal granulocytic infiltrates (7 of 15 treated animals versus zero of five controls). Thirteen of 15 treated rats compared to zero of five controls had granulocytic and mononuclear cells capsular infiltrates (minimal to moderate) and capsular fibroplasia. Two of five high-dose animals had minimal, focal, bridging fibrosis.

5 Discussion

Any discussion of renal lesions in the rat must include mention of chronic progressive nephropathy, an almost universal finding in adult, especially older, male rats. Sprague-Dawley rats (although other strains can be affected), especially males, spontaneously develop a constellation of renal lesions associated with aging, quantity of protein in the diet, male hormones and caloric intake referred to as chronic progressive nephropathy (CPN), among other synonyms. The earliest lesion detectable in young adult rats, reportedly as early as 2–4 months of age (Hard et al., 2013) is a basophilic tubule, or “evidence of regeneration in outer kidney.” Tubule basophilia is often accompanied by thickened basement membrane and, later hyaline (i.e., brightly eosinophilic protein) tubule casts and mononuclear infiltrates (Frazier et al., 2012). Many of the rats in this study exhibited minimal tubule basophilia, some with thickened basement membranes and interstitial lymphoplasmacytic infiltrates, suggesting CPN. These are commonly observed background lesions in rats; however, the incidence and/or severity of CPN can be exacerbated by certain chemicals. In this study, the incidence of changes generally attributed to CPN appeared unrelated to treatment dosage. There is general acceptance that the glomerulus is the target in CPN and that hyperfiltration is the underlying basis for pathogenesis (Hard and Khan, 2004). In this study the target appears to be the capsular surface.

The superficial nature of the renal lesion strongly suggests toxicity due to physical contact of the IP-administered compound with the renal surface rather than through absorption and dissemination of metals in the bloodstream. Although adjacent to the liver, the kidney is physically somewhat separate from the liver in that it is retroperitoneal, meaning it has peritoneum only on their anterior (or ventral, in four-legged animals) surface and therefore separated from the abdominal cavity by a thin layer of tissue. The kidney is additionally often cushioned by varying amounts of adipose tissue, which may help explain why histologic changes visible in treated rat liver 24 hours post-injection appear a few days later in kidneys. Rats euthanized 14 days after a single IP injection (at the two higher doses) more often had minimal to moderate infiltrates of mononuclear and few granulocytic cells in the capsule and capsule fibroplasia, a lesion severe enough to elicit a more enduring inflammatory response and/or repair processes. A general wound-healing process (Brown et al., 1989) almost inevitably begins with injury or alteration of blood vessels causing them to become leaky. Injured or inflamed vessels lead to extravasated fibrinogen which rapidly clots into a cross-linked fibrin gel which, if not quickly resorbed, is invaded by macrophages and fibroblasts which begin to make collagen. In time these components organize into granulation tissue and ultimately into, in the normal process, fibrous connective tissue or, if pathological, fibrosis.

Statistical analysis was not performed on results of this study due to the small group size, but the following trends over time were observed: By 7–14 days post-exposure four to five animals of each

Toxicological Study No. S.0035303-15, December 2015

five-animal dosage group had a minimal-mild capsular fibroplasia (i.e., increase in fibroblasts). Table D-5, "Histologic Effects of Intraperitoneal Injection of Sodium Dichromate Dihydrate in Sprague-Dawley Rats at 20 mg/kg OVER 14 Days" pertains. There was a clear distinction between exposed and unexposed rats but there was no clear dose response.

Liver from five of five vehicle control-treated animals exhibited minimal to mild hepatocellular lacy cytoplasmic vacuolation which is generally interpreted as glycogen (Thoolen et al., 2010), although special stains such as Periodic Acid Schiff (PAS) are required for confirmation. Of interest, 24 hours after being given the 20 mg/kg dose, the presumptive glycogen had disappeared from the livers of five of five animals examined. Loss of glycogen can occur from inanition from deliberate (i.e., protocol-driven pre-necropsy) fasting, which was not observed in the other time-points, or can be a test-article effect, with many causes (e.g., nausea, central or gastrointestinal, neurological or neuromuscular interfering with food prehension and mastication). In this study, animals were not deliberately fasted prior to euthanasia but did exhibit a drop in body weight 24 hours after exposure, which seemed to resolve by day 3. At subsequent sampling time-points, the glycogen was present, suggesting it had returned. This suggests a temporary effect of test article exposure, possibly associated with insult to homeostasis. Within 24 hours of the IP injection, high-dose rat liver sections exhibited a mononuclear leukocytic and granulocytic capsular infiltrate, occasionally accompanied by single-cell or, rarely, patchy hepatocellular necrosis. Capsular fibrin appeared within 24 hours of injection but disappeared over time. Probably associated was the presence of fibroplasia that appeared in three rats by day 3, but was present in every treated rat to some extent by day 7 and was more pronounced in four of five rats by day 14. These results appear consistent with previously published results (Madejczyk MS et al., 2015) in which delayed increased in reactive oxygen species, DNA damage and lipid peroxidation occurred. In that study, liver metal concentrations were high at 24 hours post-exposure, quickly decreased over time, in contrast to the biochemical markers.

In summary, the effects of a single IP administration of sodium dichromate dihydrate in 8-week-old male Sprague-Dawley rats appear to include direct injury to the exposed, capsular surface of the liver, leading to fibrinogen leakage, fibrin formation and fibroplasia with an acute granulocytic and, subsequently a subacute mononuclear capsular infiltrate that remained superficial in the liver. A similar, delayed response was observed in kidneys of exposed rats. Liver and kidney were the only tissues submitted for histological examination from rats in this study, but it is reasonable to surmise that other abdominal serosal surfaces may have been comparably affected. Of the tissues examined, histologic evidence of organ dysfunction, parenchymal or vascular injury was not evident, suggesting that IP injection of sodium dichromate dihydrate does not enter the bloodstream to an appreciable extent within 14 days of injection, but causes direct injury to exposed tissue with which it comes into contact.

6 Photomicrographs

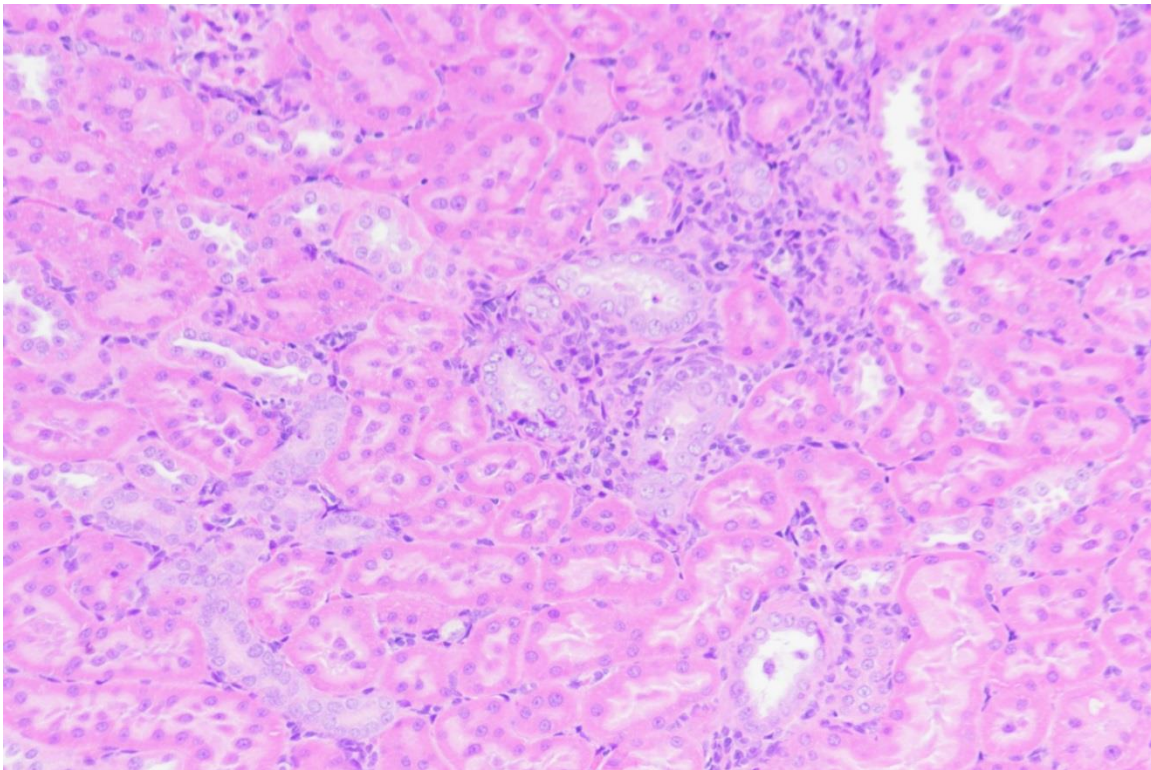


Figure 1. Rat #001 Kidney, Vehicle Control, Day 1 Post-Injection

Rare basophilic tubules, surrounded by minimal lymphocytic infiltrates, are a common background lesion in male Sprague-Dawley rats. 20X.

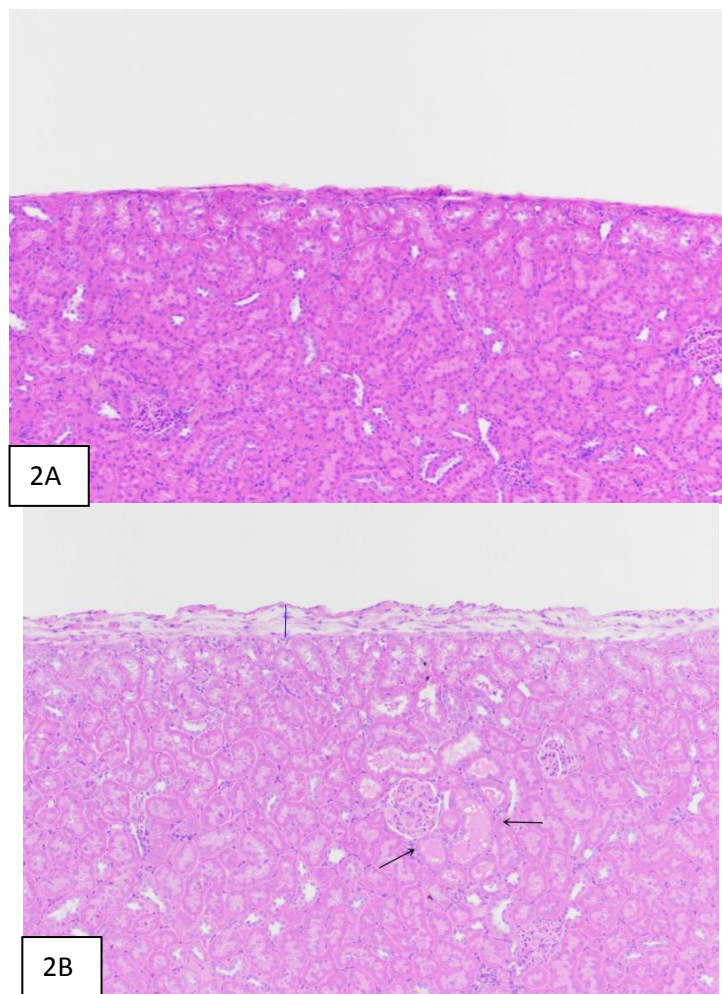


Figure 2. Control and Treated Rats, Kidney

2A: Rat #042 Vehicle Control, Day 7. Normal capsular surface. 10X.

2B: Rat #058, 20 mg/kg, Day 7 post-injection. Renal capsular fibroplasia (blue line) and tubule protein (arrows) 10X.

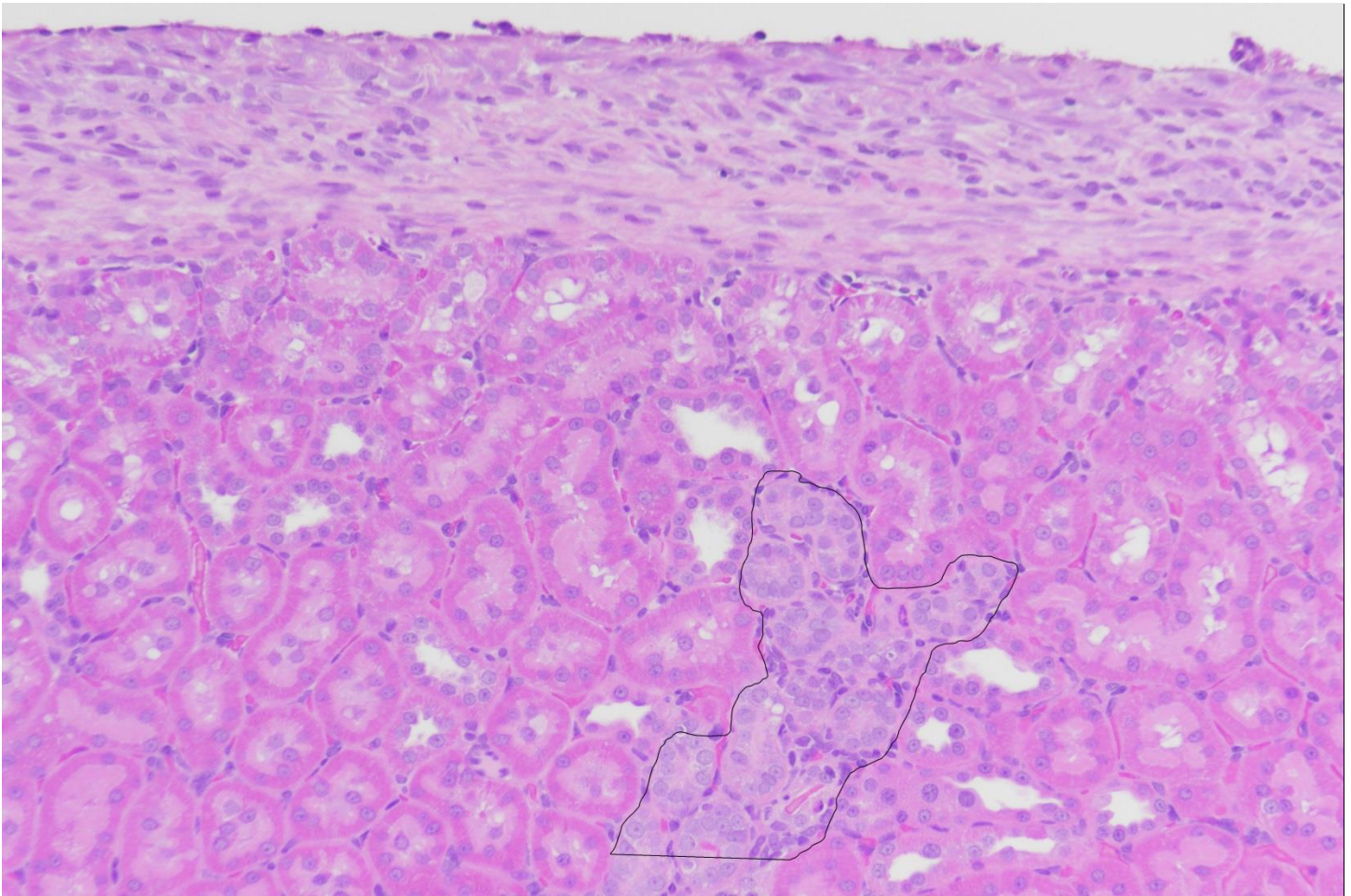


Figure 3. Rat #078, Kidney, 20 mg/kg Day 14

Capsular fibroplasia, leukocytic infiltrate, and tubule basophilia (outlined). 20X

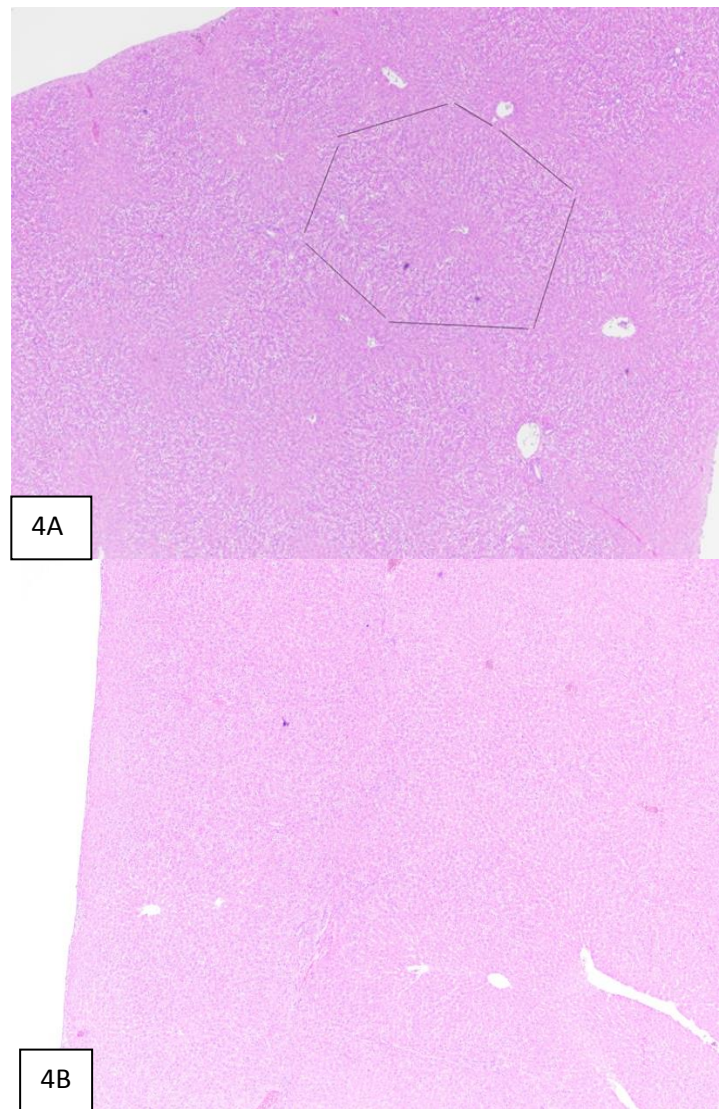


Figure 4. Liver, Glycogen Depletion

4A: Rat #001 vehicle control, Day 1 post-injection. Lacy hepatocellular cytoplasmic vacuolation (presumed glycogen) in a portal-to-mid-zonal pattern (outlined), 4X.

4B: Rat #007, 5 mg/kg exposure. Day 1. Compare to 4A. The vacuolation is now absent.

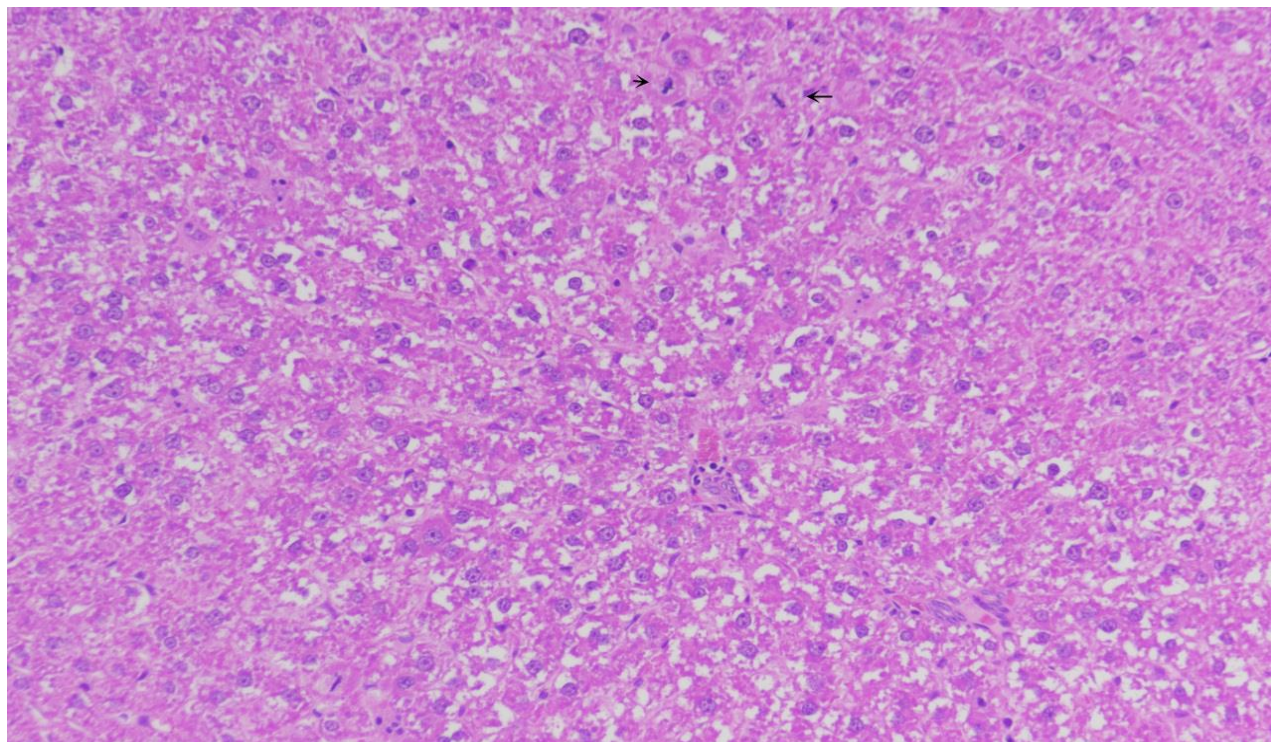


Figure 5. Rat #001, Liver, Vehicle Control, Day 1 Post-Injection

Lacy hepatocellular cytoplasm (presumed glycogen), portal-to-mid-zonal pattern. There are occasional hepatocellular mitotic figures (arrows). 20X

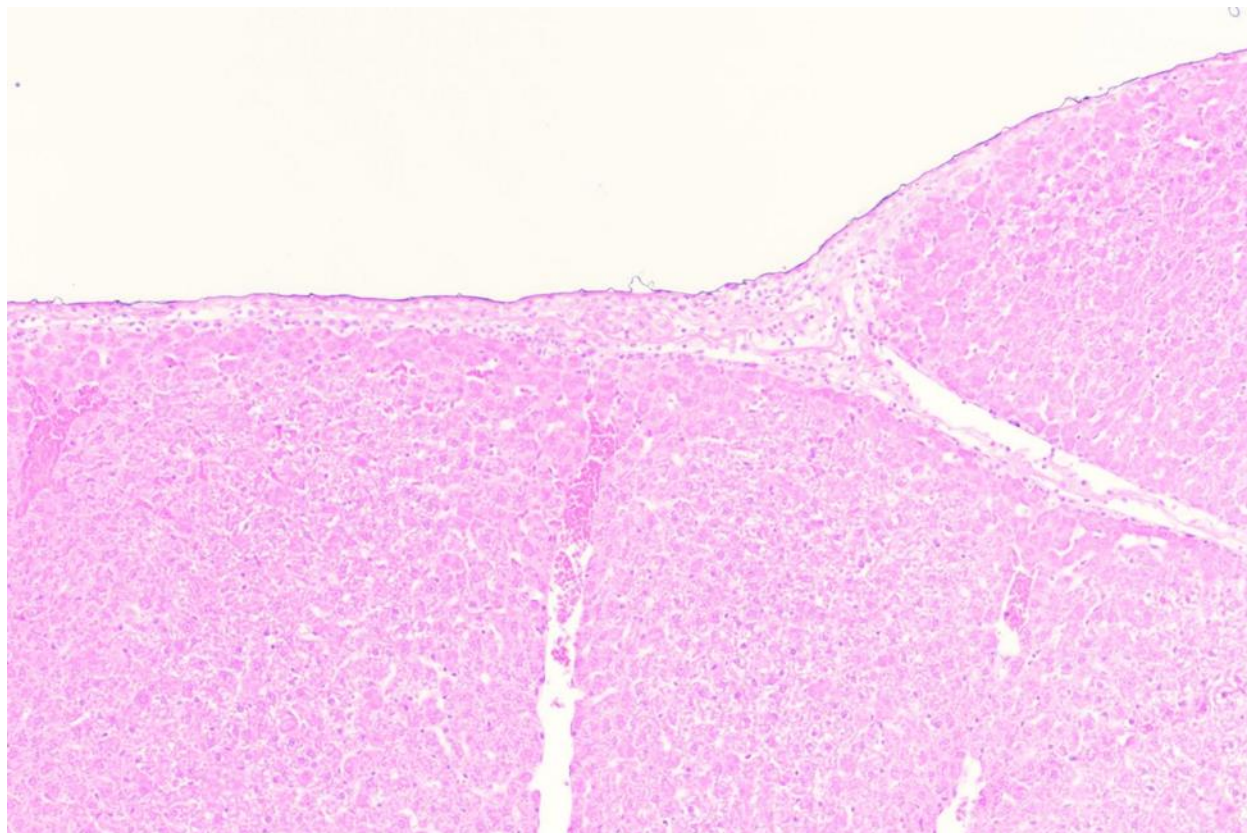


Figure 6. Rat #007, Liver, 5 mg/kg, Day 1 Post-Injection

The liver capsule is expanded by fibrin, mononuclear infiltrates (lymphocytes, monocytes) and granulocytes (neutrophils). 10X

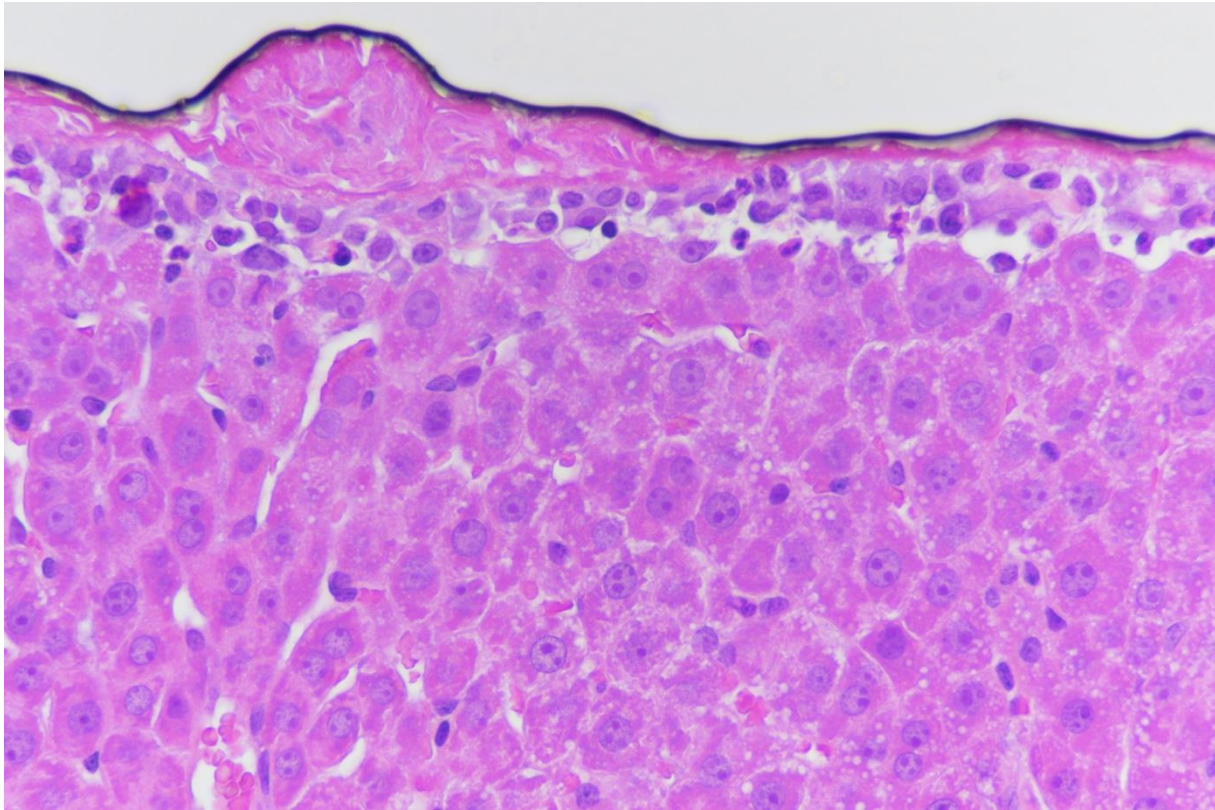


Figure 7. Rat #018, Liver, 20 mg/kg Cr, Day 1 Post-Injection

Capsular fibrin and mononuclear and granulocytic infiltrate. 40X

7 Point of Contact

The APHC (Prov) point of contact for this assessment is LTC Erica E. Carroll. She may be contacted at DSN 584-7014, commercial 410-436-7014, or via email at erica.e.carroll.mil@mail.mil.



ERICA E. CARROLL, DVM, PhD, DACVP
LTC VC
Chief, Division of Toxicologic Pathology

Approved:



MARK S. JOHNSON, PhD
Director, Toxicology

Appendix A

References

- Brown L.F., A.M. Dvorak, and H.F. Dvorak. 1989. Leaky Vessels, Fibrin Deposition and Fibrosis: A Sequence of Events Common to Solid Tumors and to Many Other Types of Disease. *Am Rev Respir Dis.* 140(4):1104-1107.
- Frazier K.S., J.C. Seely, G.C. Hard, G. Betton, R. Burnett, S. Nakatsuji, A. Nishikawa, B. Durchfeld-Meyer, and A. Bube. 2012. Proliferative and Nonproliferative Lesions of the Rat and Mouse Urinary System. *Toxicol Pathol.* 40(4 Suppl):14S-86S.
- Hard G.C. and K.N. Khan. 2004. A contemporary overview of Chronic Progressive Nephropathy in the Laboratory Rat, and its Significance for Human Risk Assessment. *Toxicol Pathol.* 32(2):171–180.
- Hard G.C., M.I. Banton, R.S. Bretzlaff, W. Dekant, J.R. Fowles, A.K. Mallett, D.B. McGregor, et al. 2013. Consideration of Rat Chronic Progressive Nephropathy in Regulatory Evaluations for Carcinogenicity. *Toxicol Sci.* 132(2):268-275.
- Madejczyk M.S., C.E. Baer, W.E. Dennis, V.C. Minarchick, S.S. Leonard, D.A. Jackson, J.D. Stallings, and J.A. Lewis. 2015. Temporal Changes in Rat Liver Gene Expression after Cadmium and Chromium Exposure. *PLoS One.* 10(5):e0127327.
- Thoolen B., R.R. Maronpot, T. Harada, A. Nyska, C. Rousseaux, T. Nolte, D.E. Malarkey, et al. 2010. Proliferative and Nonproliferative Lesions of the Rat and Mouse Hepatobiliary System *Toxicol Pathol.* 38(7 Suppl):5S-81S.

Appendix B

Quality Assurance Statement


The following critical phases were audited by the APHC (Prov) Quality Systems and Regulatory Compliance Office (QSARC), Laboratory and Toxicology Accreditation and Compliance Office (LTACO):

Critical Phase Inspected/Audited	Date Inspected /Audited	Date Reported to Management/SD
Pathology Contributing Scientist Inspection - Quality Assurance Audit of Excel Entered Data	12/15/2015	12/22/2015
Pathology Contributing Scientist Inspection -Interim Pathology Report GLP Standard Regulation Review	12/17/2015	12/22/2015
Pathology Contributing Scientist Inspection- Final Pathology Report GLP Standard Regulation Review	12/22/2015	12/22/2015

Note 1. All findings were made known to the Study Director and the Program Manager at the time of the audit/inspection. If there were no findings during the inspection, the inspection was reported to Management and the Study Director on the date shown in the table.

Note 2. In addition to the study specific critical phase inspections listed here, general facility and process based inspections not specifically related to this study are done monthly or annually in accordance with QSARC, LTACO Standing Operating Procedures.

Note 3. This report has been audited by the Quality Assurance Unit (QSARC, LTACO) and is considered to be on accurate account of the data generated and of the procedures followed



Michael P. Kefauver
Quality Assurance Specialist, QSARC

22 December 2015

Date

Appendix C

Archives

C-1 Archives

All trim sheets, equipment logs, master data file (when present), and a copy of the final pathology report generated, as a result of providing pathology support, will be archived in the storage facilities of the Directorate of Toxicology, APHC (Prov), for a minimum of (10) years following submission of the final pathology report to the Sponsor.

A signed final pathology report is, for the purposes of Good Laboratory Practices, considered the raw data. The investigator will be provided a copy and the Army Public Health Center (Provisional) (APHC (Prov))-Toxicology (TOX) Portfolio will keep an electronic copy and one scanned copy to a computer disk. Scanned study files will be stored electronically in building E-2100, room 3010, APHC (Prov), Aberdeen Proving Ground, MD 21010. Any remaining wet tissue, paraffin blocks, and histology slides will be stored in building E-5158, unless the investigator requests them.

Pathology standing operating procedures are maintained by the Quality Assurance Unit in the Master Control database. Instrument maintenance logs are stored in room 1026 upon completion.

The archivist is Martha L. Thompson.

Appendix D

Incidence of Histologic Observations

Table D-1. Histologic Observations per Severity Score per Dosage Group – Male Rats Euthanized Day 1 Post-Intraperitoneal Injection of Sodium Dichromate Dihydrate

HISTOLOGIC OBSERVATIONS PER SEVERITY SCORE PER DOSAGE GROUP - MALE RATS EUTHANIZED DAY 1 POST-INTRAPERITONEAL INJECTION OF SODIUM DICHROMATE DIHYDRATE																										
	Control (0)						Low Dose (5)						Medium Dose (10)						High Dose (20)							
	0	1	2	3	4	Total	0	1	2	3	4	Total	0	1	2	3	4	Total	0	1	2	3	4	Total		
KIDNEY																										
Basophilia, tubule	3	2	0	0	0	5	4	1	0	0	0	5	4	1	0	0	0	5	5	0	0	0	0	5		
Proteinuria, tubule	4	1	0	0	0	5	3	2	0	0	0	5	5	0	0	0	0	5	4	1	0	0	0	5		
Infiltrate, interstitial, I-p	4	1	0	0	0	5	4	1	0	0	0	5	4	1	0	0	0	5	5	0	0	0	0	5		
Intratubule cells	4	1	0	0	0	5	4	1	0	0	0	5	4	1	0	0	0	5	5	0	0	0	0	5		
Capsule, infiltrate, mono- nuclear and neutrophilic	3	2	0	0	0	5	5	0	0	0	0	5	3	2	0	0	0	5	3	2	0	0	0	5		
Subcapsular single cell necrosis	5	0	0	0	0	5	5	0	0	0	0	5	4	1	0	0	0	5	5	0	0	0	0	5		
Capsular fibroplasia	5	0	0	0	0	5	5	0	0	0	0	5	5	0	0	0	0	5	5	0	0	0	0	5		
Capsule fibrin	5	0	0	0	0	5	5	0	0	0	0	5	5	0	0	0	0	5	4	1	0	0	0	5		
LIVER																										
Lacy cytoplasm periportal-midzonal (glycogen?)	0	4	1	0	0	5	2	3	0	0	0	5	3	2	0	0	0	5	5	0	0	0	0	5		
Infiltrate, portal, granulocytic	4	1	0	0	0	5	5	0	0	0	0	5	4	1	0	0	0	5	5	0	0	0	0	5		
Infiltrate, portal, lymphoplasmacytic	4	1	0	0	0	5	4	1	0	0	0	5	4	1	0	0	0	5	0	5	0	0	0	5		
Infiltrate, subcapsular or capsular, granulocytic	5	0	0	0	0	5	3	2	0	0	0	5	1	4	0	0	0	5	0	5	0	0	0	5		
Infiltrate, subcapsular or capsular, mononuclear	5	0	0	0	0	5	3	2	0	0	0	5	2	3	0	0	0	5	0	4	1	0	0	5		
Necrosis, single cell, hep.	5	0	0	0	0	5	4	1	0	0	0	5	1	4	0	0	0	5	0	4	1	0	0	5		
Necrosis, hepatocellular	5	0	0	0	0	5	5	0	0	0	0	5	4	1	0	0	0	5	0	2	3	0	0	5		
Fibrin, capsular	5	0	0	0	0	5	3	2	0	0	0	5	1	4	0	0	0	5	0	5	0	0	0	5		
Capsular fibroplasia	5	0	0	0	0	5	5	0	0	0	0	5	5	0	0	0	0	5	5	0	0	0	0	5		
Fibrosis with Histiocytic infiltrate, bridging, focal	5	0	0	0	0	5	5	0	0	0	0	5	5	0	0	0	0	5	5	0	0	0	0	5		
Scoring system: 0 = no lesion; 1 = < 5% of tissue affected (minimal); 2 = 6-20% affected (mild); 3 = 21-40% affected (moderate); 4 = >41% of tissue affected (marked)																										

Table D-2. Histologic Observations per Severity Score per Dosage Group – Male Rats Euthanized Day 3 Post-Intraperitoneal Injection of Sodium Dichromate Dihydrate

HISTOLOGIC OBSERVATIONS PER SEVERITY SCORE PER DOSAGE GROUP - MALE RATS EUTHANIZED DAY 3 POST-INTRAPERITONEAL INJECTION OF SODIUM DICHROMATE DIHYDRATE																										
	Control (0)						Low Dose (5)						Medium Dose (10)						High Dose (20)							
	0	1	2	3	4	Total	0	1	2	3	4	Total	0	1	2	3	4	Total	0	1	2	3	4	Total		
KIDNEY																										
Basophilia, tubule	5	0	0	0	0	5	1	4	0	0	0	5	4	1	0	0	0	5	1	4	0	0	0	5		
Proteinuria, tubule	4	1	0	0	0	5	4	1	0	0	0	5	5	0	0	0	0	5	4	1	0	0	0	5		
Infiltrate, interstitial, I-p	5	0	0	0	0	5	5	0	0	0	0	5	4	1	0	0	0	5	5	0	0	0	0	5		
Intratubule cells	5	0	0	0	0	5	5	0	0	0	0	5	5	0	0	0	0	5	4	1	0	0	0	5		
Capsule, infiltrate, mono- nuclear and neutrophilic	5	0	0	0	0	5	1	3	1	0	0	5	1	4	0	0	0	5	2	3	0	0	0	5		
Subcapsular single cell necrosis	5	0	0	0	0	5	5	0	0	0	0	5	5	0	0	0	0	5	2	1	2	0	0	5		
Capsular fibroplasia	5	0	0	0	0	5	2	3	0	0	0	5	4	1	0	0	0	5	4	1	0	0	0	5		
Capsule fibrin	5	0	0	0	0	5	5	0	0	0	0	5	5	0	0	0	0	5	5	0	0	0	0	5		
LIVER																										
Lacy cytoplasm periportal-midzonal (glycogen?)	0	3	2	0	0	5	0	3	2	0	0	5	0	3	2	0	0	5	0	4	1	0	0	5		
Infiltrate, portal, granulocytic	5	0	0	0	0	5	4	1	0	0	0	5	5	0	0	0	0	5	5	0	0	0	0	5		
Infiltrate, portal, lymphoplasmacytic	3	1	1	0	0	5	5	0	0	0	0	5	5	0	0	0	0	5	3	2	0	0	0	5		
Infiltrate, subcapsular or capsular, granulocytic	5	0	0	0	0	5	1	4	0	0	0	5	2	3	0	0	0	5	2	3	0	0	0	5		
Infiltrate, subcapsular or capsular, mononuclear	5	0	0	0	0	5	1	4	0	0	0	5	1	4	0	0	0	5	2	2	1	0	0	5		
Necrosis, single cell, hep.	4	1	0	0	0	5	4	1	0	0	0	5	3	2	0	0	0	5	4	1	0	0	0	5		
Necrosis, hepatocellular	4	1	0	0	0	5	5	0	0	0	0	5	5	0	0	0	0	5	4	1	0	0	0	5		
Fibrin, capsular	5	0	0	0	0	5	1	4	0	0	0	5	3	2	0	0	0	5	5	0	0	0	0	5		
Capsular fibroplasia	5	0	0	0	0	5	5	0	0	0	0	5	4	0	1	0	0	5	2	2	1	0	0	5		
Fibrosis with Histiocytic infiltrate, bridging, focal	5	0	0	0	0	5	5	0	0	0	0	5	4	1	0	0	0	5	4	1	0	0	0	5		
Scoring system: 0 = no lesion; 1 = < 5% of tissue affected (minimal); 2 = 6-20% affected (mild); 3 = 21-40% affected (moderate); 4 = >41% of tissue affected (marked)																										

Toxicological Study No. S.0035303-15, December 2015

Table D-3. Histologic Observations per Severity Score per Dosage Group – Male Rats Euthanized Day 7 Post-Intraperitoneal Injection of Sodium Dichromate Dihydrate

HISTOLOGIC OBSERVATIONS PER SEVERITY SCORE PER DOSAGE GROUP - MALE RATS EUTHANIZED DAY 7 POST-INTRAPERITONEAL INJECTION OF SODIUM DICHROMATE DIHYDRATE																									
	Control (0)					Total	Low Dose (5)					Total	Medium Dose (10)					Total	High Dose (20)					Total	
	0	1	2	3	4		0	1	2	3	4		0	1	2	3	4		0	1	2	3	4		
KIDNEY																									
Basophilia, tubule	2	3	0	0	0	5	4	1	0	0	0	5	3	2	0	0	0	5	3	2	0	0	0	5	
Proteinuria, tubule	5	0	0	0	0	5	3	2	0	0	0	5	4	1	0	0	0	5	3	2	0	0	0	5	
Inilfrate, interstitial, I-p	3	2	0	0	0	5	5	0	0	0	0	5	4	1	0	0	0	5	5	0	0	0	0	5	
Intratubule cells	5	0	0	0	0	5	5	0	0	0	0	5	5	0	0	0	0	5	5	0	0	0	0	5	
Capsule, infiltrate, mono- nuclear and neutrophilic	5	0	0	0	0	5	1	3	1	0	0	5	1	0	4	0	0	5	2	1	2	0	0	5	
Subcapsular single cell necrosis	5	0	0	0	0	5	5	0	0	0	0	5	5	0	0	0	0	5	5	0	0	0	0	5	
Capsular fibroplasia	5	0	0	0	0	5	3	0	2	0	0	5	1	2	2	0	0	5	0	4	1	0	0	5	
Capsule fibrin	5	0	0	0	0	5	4	1	0	0	0	5	3	2	0	0	0	5	5	0	0	0	0	5	
LIVER																									
Lacy cytoplasm periportal-midzonal (glycogen?)	1	4	0	0	0	5	0	4	1	0	0	5	0	5	0	0	0	5	0	5	0	0	0	5	
Infiltrate, portal, granulocytic	4	1	0	0	0	5	4	1	0	0	0	5	4	0	1	0	0	5	5	0	0	0	0	5	
Infiltrate, portal, lymphoplasmacytic	3	2	0	0	0	5	1	4	0	0	0	5	4	0	1	0	0	5	3	2	0	0	0	5	
Infiltrate, subcapsular or capsular, granulocytic	5	0	0	0	0	5	3	2	0	0	0	5	0	5	0	0	0	5	2	3	0	0	0	5	
Infiltrate, subcapsular or capsular, mononuclear	5	0	0	0	0	5	4	1	0	0	0	5	1	3	1	0	0	5	4	1	0	0	0	5	
Necrosis, single cell, hep.	5	0	0	0	0	5	5	0	0	0	0	5	5	0	0	0	0	5	4	1	0	0	0	5	
Necrosis, hepatocellular	5	0	0	0	0	5	5	0	0	0	0	5	5	0	0	0	0	5	5	0	0	0	0	5	
Fibrin, capsular	5	0	0	0	0	5	5	0	0	0	0	5	5	0	0	0	0	5	5	0	0	0	0	5	
Capsular fibroplasia	5	0	0	0	0	5	3	2	0	0	0	5	0	3	2	0	0	5	0	5	0	0	0	5	
Fibrosis with Histiocytic infiltrate, bridging, focal	5	0	0	0	0	5	5	0	0	0	0	5	5	0	0	0	0	5	3	2	0	0	0	5	
Scoring system: 0 = no lesion; 1 = < 5% of tissue affected (minimal); 2 = 6-20% affected (mild); 3 = 21-40% affected (moderate); 4 = >41% of tissue affected (marked)																									

Table D-4. Histologic Observations per Severity Score per Dosage Group – Male Rats Euthanized Day 14 Post-Intraperitoneal Injection of Sodium Dichromate Dihydrate

HISTOLOGIC OBSERVATIONS PER SEVERITY SCORE PER DOSAGE GROUP - MALE RATS EUTHANIZED DAY 14 POST-INTRA PERITONEAL INJECTION OF SODIUM DICHROMATE DIHYDRATE																									
	Control (0)					Total	Low Dose (5)					Total	Medium Dose (10)					Total	High Dose (20)					Total	
	0	1	2	3	4		0	1	2	3	4		0	1	2	3	4		0	1	2	3	4		
KIDNEY						Total						Total					Total						Total		
Basophilia, tubule	3	2	0	0	0	5	3	2	0	0	0	5	3	2	0	0	0	5	3	1	0	1	0	5	
Proteinuria, tubule	5	0	0	0	0	5	3	2	0	0	0	5	3	2	0	0	0	5	4	1	0	0	0	5	
Inltrate, interstitial, I-p	4	1	0	0	0	5	5	0	0	0	0	5	3	2	0	0	0	5	3	0	1	0	0	4	
Intratubule cells	5	0	0	0	0	5	5	0	0	0	0	5	5	0	0	0	0	5	5	0	0	0	0	5	
Capsule, infiltrate, mono- nuclear and neutrophilic	5	0	0	0	0	5	5	0	0	0	0	5	3	0	0	2	0	5	1	4	0	0	0	5	
Subcapsular single cell necrosis	5	0	0	0	0	5	5	0	0	0	0	5	5	0	0	0	0	5	5	0	0	0	0	5	
Capsular fibroplasia	5	0	0	0	0	5	5	0	0	0	0	5	3	0	0	2	0	5	1	0	4	0	0	5	
Capsule fibrin	5	0	0	0	0	5	5	0	0	0	0	5	5	0	0	0	0	5	5	0	0	0	0	5	
LIVER																									
Lacy cytoplasm periportal-midzonal (glycogen?)	0	5	0	0	0	5	0	5	0	0	0	5	0	5	0	0	0	5	2	2	1	0	0	5	
Infiltrate, portal, granulocytic	5	0	0	0	0	5	2	3	0	0	0	5	4	1	0	0	0	5	2	3	0	0	0	5	
Infiltrate, portal, lymphoplasmacytic	4	1	0	0	0	5	2	3	0	0	0	5	3	2	0	0	0	5	4	1	0	0	0	5	
Infiltrate, subcapsular or capsular, granulocytic	5	0	0	0	0	5	0	5	0	0	0	5	1	4	0	0	0	5	2	2	0	1	0	5	
Infiltrate, subcapsular or capsular, mononuclear	5	0	0	0	0	5	0	5	0	0	0	5	1	4	0	0	0	5	1	3	0	1	0	5	
Necrosis, single cell, hep.	5	0	0	0	0	5	5	0	0	0	0	5	5	0	0	0	0	5	4	1	0	0	0	5	
Necrosis, hepatocellular	5	0	0	0	0	5	5	0	0	0	0	5	5	0	0	0	0	5	5	0	0	0	0	5	
Fibrin, capsular	5	0	0	0	0	5	5	0	0	0	0	5	5	0	0	0	0	5	4	0	1	0	0	5	
Capsular fibroplasia	5	0	0	0	0	5	0	3	1	1	0	5	0	3	1	1	0	5	1	1	1	1	1	5	
Fibrosis with Histiocytic infiltrate, bridging, focal	5	0	0	0	0	5	5	0	0	0	0	5	5	0	0	0	0	5	3	2	0	0	0	5	
Scoring system: 0 = no lesion; 1 = < 5% of tissue affected (minimal); 2 = 6-20% affected (mild); 3 = 21-40% affected (moderate); 4 = >41% of tissue affected (marked)																									

Toxicological Study No. S.0035303-15, December 2015

Table D-5. Histologic Effects of Intraperitoneal Injection of Sodium Dichromate Dihydrate in Sprague-Dawley Rats at 20 mg/kg OVER 14 Days

HISTOLOGIC EFFECTS OF INTRAPERITONEAL INJECTION OF SODIUM DICHROMATE DIHYDRATE IN SPRAGUE-DAWLEY RATS AT 20mg/kg OVER 14 DAYS																														
	Control (0)						High Dose (20)						High Dose (20)						High Dose (20)						High Dose (20)					
	0	1	2	3	4	Total	0	1	2	3	4	Total	0	1	2	3	4	Total	0	1	2	3	4	Total	0	1	2	3	4	Total
KIDNEY																														
Basophilia, tubule	3	2	0	0	0	5	5	0	0	0	0	5	1	4	0	0	0	5	3	2	0	0	0	5	3	1	0	1	0	5
Proteinuria, tubule	4	1	0	0	0	5	4	1	0	0	0	5	4	1	0	0	0	5	3	2	0	0	0	5	4	1	0	0	0	5
Inifltrate, interstitial, I-p	4	1	0	0	0	5	5	0	0	0	0	5	5	0	0	0	0	5	5	0	0	0	0	5	3	0	1	0	0	4
Intratubule cells	4	1	0	0	0	5	5	0	0	0	0	5	4	1	0	0	0	5	5	0	0	0	0	5	5	0	0	0	0	5
Capsule, infiltrate, mono- nuclear and neutroph	3	2	0	0	0	5	3	2	0	0	0	5	2	3	0	0	0	5	2	1	2	0	0	5	1	4	0	0	0	5
Subcapsular single cell necrosis	5	0	0	0	0	5	5	0	0	0	0	5	2	1	2	0	0	5	5	0	0	0	0	5	5	0	0	0	0	5
Capsular fibroplasia	5	0	0	0	0	5	5	0	0	0	0	5	4	1	0	0	0	5	0	4	1	0	0	5	1	0	4	0	0	5
Capsule fibrin	5	0	0	0	0	5	4	1	0	0	0	5	5	0	0	0	0	5	5	0	0	0	0	5	5	0	0	0	0	5
LIVER																														
Lacy cytoplasm periportal-midzonal (glycogen?)	0	4	1	0	0	5	5	0	0	0	0	5	0	4	1	0	0	5	0	5	0	0	0	5	2	2	1	0	0	5
Infiltrate, portal, granulocytic	4	1	0	0	0	5	5	0	0	0	0	5	5	0	0	0	0	5	5	0	0	0	0	5	2	3	0	0	0	5
Infiltrate, portal, lymphoplasmacytic	4	1	0	0	0	5	0	5	0	0	0	5	3	2	0	0	0	5	3	2	0	0	0	5	4	1	0	0	0	5
Infiltrate, subcapsular or capsular, granulocytic	5	0	0	0	0	5	0	5	0	0	0	5	2	3	0	0	0	5	2	3	0	0	0	5	2	2	0	1	0	5
Infiltrate, subcapsular or capsular, mononuclear	5	0	0	0	0	5	0	4	1	0	0	5	2	2	1	0	0	5	4	1	0	0	0	5	1	3	0	1	0	5
Necrosis, single cell, hep.	5	0	0	0	0	5	0	4	1	0	0	5	4	1	0	0	0	5	4	1	0	0	0	5	4	1	0	0	0	5
Necrosis, hepatocellular	5	0	0	0	0	5	0	2	3	0	0	5	4	1	0	0	0	5	5	0	0	0	0	5	5	0	0	0	0	5
Fibrin, capsular	5	0	0	0	0	5	0	5	0	0	0	5	5	0	0	0	0	5	5	0	0	0	0	5	4	0	1	0	0	5
Capsular fibroplasia	5	0	0	0	0	5	5	0	0	0	0	5	2	2	1	0	0	5	0	5	0	0	0	5	1	1	1	1	1	5
Fibrosis with Histiocytic infiltrate, bridging, foca	5	0	0	0	0	5	5	0	0	0	0	5	4	1	0	0	0	5	3	2	0	0	0	5	3	2	0	0	0	5
	Day 1						Day 1						Day 3						Day 7						Day 14					

Appendix E

Individual Animal Data

Table E-1. Sprague-Dawley Male Rats 7–8 weeks-old

Male 7-8 wk Sprague-Dawley rats	For rats with ID# < 20, only left kidney was submitted for evaluation																			
Animal ID#-->	1	2	3	4	5	6	7	8	9	10	11	12	13	14	15	16	17	18	19	20
Dosage group-->	Ctrl	Ctrl	Ctrl	Ctrl	Ctrl	5	5	5	5	5	10	10	10	10	10	20	20	20	20	20
# of Post-Exposure Days before Euthanasia-->	1	1	1	1	1	1	1	1	1	1	1	1	1	1	1	1	1	1	1	1
KIDNEY																				
Basophilia, tubule	1	0	1	0	0	0	0	0	0	1	0	1	0	0	0	0	0	0	0	0
Proteinuria, tubule	1	0	0	0	0	0	0	1	0	1	0	0	0	0	0	0	0	1	0	0
Infiltrate, interstitial, I-p	1	0	0	0	0	0	0	0	0	1	0	1	0	0	0	0	0	0	0	0
Intratubule cells	0	0	0	0	1	0	1	0	0	0	0	0	0	0	1	0	0	0	0	0
Capsule, infiltrate, mono- nuclear and neutrophilic	1	0	0	0	1	0	0	0	0	0	0	1	0	1	0	0	0	1	1	0
Subcapsular single cell necrosis	0	0	0	0	0	0	0	0	0	0	0	0	0	1	0	0	0	0	0	0
Subcapsular tinctorial change (basophilia) poss tubule degen	0	0	0	0	0	0	0	0	0	0	0	0	0	1	0	0	0	0	0	0
Capsular fibroplasia	0	0	0	0	0	0	0	0	0	0	0	0	0	0	0	0	0	0	0	0
Capsule fibrin	0	0	0	0	0	0	0	0	0	0	0	0	0	0	0	0	0	0	0	0
LIVER																				
Lacy cytoplasm periportal-midzonal (glycogen?)	2	1	1	1	1	1	0	0	1	1	0	0	0	1	1	0	0	0	0	0
Infiltrate, portal, granulocytic	0	0	0	1	0	0	0	0	0	0	0	0	1	0	0	0	0	0	0	0
Infiltrate, portal, lymphoplasmacytic	0	0	0	1	0	0	0	0	1	0	0	0	1	0	0	1	1	1	1	1
Infiltrate, subcapsular or capsular, granulocytic	0	0	0	0	0	0	1	1	0	0	1	1	1	1	0	1	1	1	1	1
Infiltrate, subcapsular or capsular, mononuclear	0	0	0	0	0	0	1	1	0	0	1	1	1	0	0	2	1	1	1	1
Necrosis, single cell, hep.	0	0	0	0	0	0	0	1	0	0	1	1	1	1	0	1	1	2	1	1
Necrosis, hepatocellular	0	0	0	0	0	0	0	0	0	0	0	0	1	0	0	1	1	2	2	2
Fibrin, capsular	0	0	0	0	0	0	1	1	0	0	1	1	1	1	0	1	1	1	1	1
Capsular fibroplasia	0	0	0	0	0	0	0	0	0	0	0	0	0	0	0	0	0	0	0	0
Fibrosis with Histiocytic infiltrate, bridging, focal	0	0	0	0	0	0	0	0	0	0	0	0	0	0	0	0	0	0	0	0

Note:

Scoring system: 0 = no lesion; 1 = < 5% of tissue affected (minimal); 2 = 6–20% affected (mild); 3 = 21–40% affected (moderate); 4 = >41% of tissue affected (marked)

Toxicological Study No. S.0035303-15, December 2015

Table E-1. Sprague-Dawley Male Rats 7–8 weeks-old (continued)

Male 7-8 wk Sprague-Dawley rats	For animals with ID # >20, 1/2 of right kidney as well as left kidney was submitted																			
Animal ID#-->	21	22	23	24	25	26	27	28	29	30	31	32	33	34	35	36	37	38	39	40
Dosage group-->	Ctrl	Ctrl	Ctrl	Ctrl	Ctrl	5	5	5	5	5	10	10	10	10	10	20	20	20	20	20
# of Post-Exposure Days before Euthanasia-->	3	3	3	3	3	3	3	3	3	3	3	3	3	3	3	3	3	3	3	3
KIDNEY							C									C				C
Basophilia, tubule	0	0	0	0	0	1	1	1	1	0	0	0	0	0	1	1	1	1	0	1
Proteinuria, tubule	0	1	0	0	0	0	0	0	0	1	0	0	0	0	0	1	0	0	0	0
Infiltrate, interstitial, I-p	0	0	0	0	0	0	0	0	0	0	0	0	0	0	1	0	0	0	0	0
Intratubule cells	0	0	0	0	0	0	0	0	0	0	0	0	0	0	0	0	0	1	0	0
Capsule, infiltrate, mono- nuclear and neutrophilic	0	0	0	0	0	2	1	1	0	1	1	0	1	1	1	1	0	1	0	1
Subcapsular single cell necrosis	0	0	0	0	0	0	0	0	0	0	0	0	0	0	0	1	0	2	0	2
Subcapsular tinctorial change (basophilia) poss tubule degen	0	0	0	0	0	0	0	0	0	0	0	0	0	1	1	1	0	2	0	2
Capsular fibroplasia	0	0	0	0	0	1	1	1	0	0	0	0	0	0	1	0	0	0	0	1
Capsule fibrin	0	0	0	0	0	0	0	0	0	0	0	0	0	0	0	0	0	0	0	0
LIVER																				
Lacy cytoplasm periportal-midzonal (glycogen?)	1	2	1	2	1	1	2	2	1	1	1	1	2	1	2	1	1	1	1	2
Infiltrate, portal, granulocytic	0	0	0	0	0	0	0	0	1	0	0	0	0	0	0	0	0	0	0	0
Infiltrate, portal, lymphoplasmacytic	1	0	0	2	0	0	0	0	0	0	0	0	0	0	0	0	0	0	1	1
Infiltrate, subcapsular or capsular, granulocytic	0	0	0	0	0	1	1	0	1	1	0	0	1	1	1	1	0	1	0	1
Infiltrate, subcapsular or capsular, mononuclear	0	0	0	0	0	1	1	0	1	1	1	0	1	1	1	1	0	2	0	1
Necrosis, single cell, hep.	0	0	0	1	0	1	0	0	0	0	0	0	0	1	1	0	0	0	0	1
Necrosis, hepatocellular	1	0	0	0	0	0	0	0	0	0	0	0	0	0	0	0	0	0	0	1
Fibrin, capsular	0	0	0	0	0	1	1	1	0	1	0	0	1	1	0	0	0	0	0	0
Capsular fibroplasia	0	0	0	0	0	0	0	0	0	0	0	0	0	0	2	1	0	2	0	1
Fibrosis with Histiocytic infiltrate, bridging, focal	0	0	0	0	0	0	0	0	0	0	0	0	0	0	1	0	0	0	0	1

Note:

Scoring system: 0 = no lesion; 1 = < 5% of tissue affected (minimal); 2 = 6–20% affected (mild); 3 = 21–40% affected (moderate); 4 = >41% of tissue affected (marked)

Table E-1. Sprague-Dawley Male Rats 7–8 weeks-old (continued)

Male 7-8 wk Sprague-Dawley rats	For animals with ID # >20, 1/2 of right kidney as well as left kidney was submitted																			
Animal ID#-->	41	42	43	44	45	46	47	48	49	50	51	52	53	54	55	56	57	58	59	60
Dosage group-->	Ctrl	Ctrl	Ctrl	Ctrl	Ctrl	5	5	5	5	5	10	10	10	10	10	20	20	20	20	20
# of Post-Exposure Days before Euthanasia-->	7	7	7	7	7	7	7	7	7	7	7	7	7	7	7	7	7	7	7	7
KIDNEY				C																
Basophilia, tubule	1	1	1	0	0	0	0	0	0	1	0	1	1	0	0	1	0	0	1	0
Proteinuria, tubule	0	0	0	0	0	0	1	0	0	1	0	1	0	0	0	0	0	1	0	1
Iniftrate, interstitial, I-p	1	0	1	0	0	0	0	0	0	0	0	0	1	0	0	0	0	0	0	0
Intratubule cells	0	0	0	0	0	0	0	0	0	0	0	0	0	0	0	0	0	0	0	0
Capsule, infiltrate, mono- nuclear and neutrophilic	0	0	0	0	0	1	0	2	1	1	2	2	0	2	2	0	2	0	2	1
Subcapsular single cell necrosis	0	0	0	0	0	0	0	0	0	0	0	0	0	0	0	0	0	0	0	0
Subcapsular tinctorial change (basophilia) poss tubule degen	0	0	0	0	0	0	0	0	0	0	0	0	0	0	0	1	1	1	1	1
Capsular fibroplasia	0	0	0	0	0	0	0	2	0	2	2	2	0	1	1	1	2	1	1	1
Capsule fibrin	0	0	0	0	0	0	1	0	0	0	0	0	0	1	1	0	0	0	0	0
LIVER																				
Lacy cytoplasm periportal-midzonal (glycogen?)	1	0	1	1	1	2	1	1	1	1	1	1	1	1	1	1	1	1	1	1
Infiltrate, portal, granulocytic	0	0	0	0	1	1	0	0	0	0	0	0	2	0	0	0	0	0	0	0
Infiltrate, portal, lymphoplasmacytic	0	1	0	1	0	1	1	1	1	0	0	0	2	0	0	1	1	0	0	0
Infiltrate, subcapsular or capsular, granulocytic	0	0	0	0	0	1	0	0	0	1	1	1	1	1	1	1	0	0	1	1
Infiltrate, subcapsular or capsular, mononuclear	0	0	0	0	0	0	0	0	0	1	1	1	1	0	2	1	0	0	0	0
Necrosis, single cell, hep.	0	0	0	0	0	0	0	0	0	0	0	0	0	0	0	0	1	0	0	0
Necrosis, hepatocellular	0	0	0	0	0	0	0	0	0	0	0	0	0	0	0	0	0	0	0	0
Fibrin, capsular	0	0	0	0	0	0	0	0	0	0	0	0	0	0	0	0	0	0	0	0
Capsular fibroplasia	0	0	0	0	0	1	0	0	0	1	1	1	1	2	2	1	1	1	1	1
Fibrosis with Histiocytic infiltrate, bridging, focal	0	0	0	0	0	0	0	0	0	0	0	0	0	0	0	1	1	0	0	0

Note:

Scoring system: 0 = no lesion; 1 = < 5% of tissue affected (minimal); 2 = 6–20% affected (mild); 3 = 21–40% affected (moderate); 4 = >41% of tissue affected (marked)

Toxicological Study No. S.0035303-15, December 2015

Table E-1. Sprague-Dawley Male Rats 7–8 weeks-old (continued)

Male 7-8 wk Sprague-Dawley rats	For animals with ID # >20, 1/2 of right kidney as well as left kidney was submitted																			
Animal ID#-->	61	62	63	64	65	66	67	68	69	70	71	72	73	74	75	76	77	78	79	80
Dosage group-->	Ctrl	Ctrl	Ctrl	Ctrl	Ctrl	5	5	5	5	5	10	10	10	10	10	20	20	20	20	20
# of Post-Exposure Days before Euthanasia-->	14	14	14	14	14	14	14	14	14	14	14	14	14	14	14	14	14	14	14	14
KIDNEY																				
Basophilia, tubule	0	1	0	0	1	0	1	0	1	0	0	0	0	1	1	3	0	1	0	0
Proteinuria, tubule	0	0	0	0	0	0	0	0	1	1	0	1	0	1	0	0	0	1	0	0
Iniftrate, interstitial, I-p	0	0	0	0	1	0	0	0	0	0	0	1	0	0	1	2	0		0	0
Intratubule cells	0	0	0	0	0	0	0	0	0	0	0	0	0	0	0	0	0	0	0	0
Capsule, infiltrate, mono- nuclear and neutrophilic	0	0	0	0	0	0	0	0	0	0	3	0	0	0	3	0	1	1	1	1
Subcapsular single cell necrosis	0	0	0	0	0	0	0	0	0	0	0	0	0	0	0	0	0	0	0	0
Subcapsular tinctorial change (basophilia) poss tubule degen	0	0	0	0	0	0	0	0	0	0	0	0	0	0	0	1	1	1	1	1
Capsular fibroplasia	0	0	0	0	0	0	0	0	0	0	3	0	0	0	3	0	2	2	2	2
Capsule fibrin	0	0	0	0	0	0	0	0	0	0	0	0	0	0	0	0	0	0	0	0
LIVER																				
Lacy cytoplasm periportal-midzonal (glycogen?)	1	1	1	1	1	1	1	1	1	1	1	1	1	1	1	1	0	2	1	0
Infiltrate, portal, granulocytic	0	0	0	0	0	1	1	0	0	1	0	0	0	1	0	0	1	1	0	1
Infiltrate, portal, lymphoplasmacytic	0	0	0	1	0	1	0	0	1	1	0	1	1	0	0	0	1	0	0	0
Infiltrate, subcapsular or capsular, granulocytic	0	0	0	0	0	1	1	1	1	1	1	1	1	1	0	0	3	1	1	0
Infiltrate, subcapsular or capsular, mononuclear	0	0	0	0	0	1	1	1	1	1	1	1	1	1	0	0	3	1	1	1
Necrosis, single cell, hep.	0	0	0	0	0	0	0	0	0	0	0	0	0	0	0	0	1	0	0	0
Necrosis, hepatocellular	0	0	0	0	0	0	0	0	0	0	0	0	0	0	0	0	0	0	0	0
Fibrin, capsular	0	0	0	0	0	0	0	0	0	0	0	0	0	0	0	0	2	0	0	0
Capsular fibroplasia	0	0	0	0	0	3	1	1	1	2	3	2	1	1	1	0	4	3	2	1
Fibrosis with Histiocytic infiltrate, bridging, focal	0	0	0	0	0	0	0	0	0	0	0	0	0	0	0	0	1	1	0	0

Note:

Scoring system: 0 = no lesion; 1 = < 5% of tissue affected (minimal); 2 = 6–20% affected (mild); 3 = 21–40% affected (moderate); 4 = >41% of tissue affected (marked)