

ACCURACY OF 3D IMAGING SOFTWARE IN CEPHALOMETRIC ANALYSIS

by

Robert Bracken Godfrey  
LCDR, DC, USN

A thesis submitted to the Faculty of the  
Comprehensive Dentistry Graduate Program  
Naval Postgraduate Dental School  
Uniformed Services University of the Health Sciences  
in partial fulfillment of the requirements of the degree of  
Master of Science  
in Oral Biology

June 2013

Naval Postgraduate Dental School  
Uniformed Services University of the Health Sciences  
Bethesda, Maryland

CERTIFICATE OF APPROVAL

---

MASTER'S THESIS


---


This is to certify that the Master's thesis of


Bracken Robert Godfrey  
Lieutenant Commander, Dental Corps, U.S. Navy

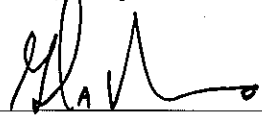
has been approved by the Examining Committee for the thesis requirement  
for the Master of Science degree in Oral Biology at the June 2013 graduation.

Thesis Committee:

  
\_\_\_\_\_  
Kim E. Diefenderfer, DMD, MS, MS  
Professor, Dental Research  
Thesis Supervisor

  
\_\_\_\_\_  
Vlasta M. Miksch, DDS, MS  
Captain, Comprehensive Dentistry  
Chairman Research Committee


  
\_\_\_\_\_  
Michael E. Rudmann, DMD, MS  
Commander, Comprehensive Dentistry

  
\_\_\_\_\_  
Glen A. Munro, DDS, MBA  
Dean  
Naval Postgraduate Dental School

The author hereby certifies that the use of any copyrighted material in the thesis manuscript titled:

“Accuracy of 3D Imaging Software in Cephalometric Analysis”

is appropriately acknowledged and, beyond brief excerpts, is with the permission of the copyright owner.



Bracken Robert Godfrey  
Comprehensive Dentistry Department Graduate Program  
Naval Postgraduate Dental School  
21 June 2013

NAVAL POSTGRADUATE DENTAL SCHOOL  
Bracken Robert Godfrey

2013

This thesis may not be re-printed without the expressed written permission of the author.

## ABSTRACT

### ACCURACY OF 3D IMAGING SOFTWARE IN CEPHALOMETRIC ANALYSIS

BRACKEN ROBERT GODFREY  
MS, COMPREHENSIVE DENTISTRY DEPARTMENT, 2013

Thesis directed by: CAPT Kim E. Diefenderfer, DC, USN  
Professor, Dental Research Department  
Naval Postgraduate Dental School

**Introduction:** The rapidly emerging availability of cone beam computed tomography (CBCT) equipment and technology is expanding the use of 3D imaging. However, there is a lack of data regarding the accuracy of linear measurements obtained from 3D CBCT data constructed from orthodontic software. Studies to assess accuracy and precision are mandatory to validate these software tools.

**Purpose:** The purpose of this study is to compare the accuracy of linear measurements made from 3D reconstructions generated from CBCT data using a proprietary orthodontic image and analysis program with measurements made on three ex vivo porcine skulls using a coordinate measuring machine.

**Methods:** The research design is an observational comparative laboratory study. Three ex vivo porcine skulls will be used as the standard measurement models. Seventeen craniofacial anatomic landmarks will be identified on each of the three skulls. Using a coordinate measuring machine, each anatomic landmark will be measured three times and a mean ( $\pm$  standard deviation) value calculated for each of the three specimen skulls. CBCT data of the specimens will be imported into a proprietary orthodontic software

program used for measurement and analysis of craniofacial dimensions. The same 17 cephalometric landmarks will be located and marked on the 3D surface of the image; measurements between specific landmarks will be made using the orthodontic software. The mean values obtained via the computer software will be compared to the values obtained by the coordinate measurement machine via Paired Sample *t*-Tests.

**Results:** The study has been approved by the Department of Research Programs, WRNMMC. Data collection will begin as soon as the software is available.

**Discussion:** The findings have the potential to validate or cause us to question the use of orthodontic software as a tool used in establishing anatomical relationships, improving diagnosis, treatment planning, and prognosis.

## TABLE OF CONTENTS

	Page
CHAPTER	
I. REVIEW OF THE LITERATURE .....	1
History of Cephalometry .....	1
Transition from Conventional to Digital Radiography .....	2
Transition from 2D to 3D Cephalometry .....	4
CBCT compared to CT.....	5
CBCT Use in Orthodontics .....	8
Radiation Dose Comparison.....	11
Summary.....	12
II. MATERIALS AND METHODS .....	14
Measurements of Three Standard Models.....	14
Measurement of CBCT Data.....	17
Comparison of CMM measurements to CBCT Measurements...	18
Statistical Analysis .....	18
III. DISCUSSION.....	19
Limitations of the study.....	19
Significance of this study .....	21
Future Applications of CBCT in Orthodontics .....	21
IV. CONCLUSIONS .....	22
APPENDIX DATA COLLECTION FORM .....	23
REFERENCES.....	27

# CHAPTER I: REVIEW OF THE LITERATURE

## History of Cephalometry

In 1895 Wilhelm Röntgen revolutionized medicine and dentistry with the discovery of X-rays. The first intraoral radiograph was obtained in 1896 (Broadbent, 1931). Intraoral radiography is still the most common radiographic technique used in dental imaging (Vandenberghe, Jacobs & Bosmans, 2010). By using an x-ray generator and intraoral receptor, a projection radiograph is obtained of a small region. The two most common types are periapical and bitewing radiographs. Periapical radiographs obtain an image of the entire tooth, including the roots and surrounding bone. Bitewing radiographs image only the crowns of the teeth and alveolar crest; they are most often used for visualization of interproximal areas associated commonly with dental caries lesions (Brooks & Atchinson, 2004).

Traditional two-dimensional radiographic cephalometry was introduced to the dental profession 36 years later, simultaneously by Broadbent in the US and Hofrath in Germany (Broadbent, 1931; Ioi, Nakata, Nakasima & Counts, 2007). Broadbent stated that, by means of a custom fabricated head stabilizer and using standardized radiographic technique, it was possible to make accurate determinations of changes to the craniofacial region. Previous methods used landmarks in the skull of the living child by securing the head with a device that penetrated the through the skin and soft tissues. Broadbent's proposed technique registered craniometric landmarks on the face and cranial base of the living head, which, until then, could be measured only on dead skulls with a craniostat (Broadbent, 1931).

The techniques introduced in 1931 have remained relatively unchanged since then. Cephalometry has been used as an anthropologic technique to quantify shapes and sizes of skulls, as well as the study of growth, development, and treatment.

Cephalometric analysis has been developed to help diagnose skeletal malocclusions and dentofacial deformities. In 1931, Broadbent predicted that the potential range of future possible uses of the lateral cephalometric radiograph in research would include quantifying craniofacial parameters in both individuals and populations, distinguishing normal from abnormal, comparing treated samples to untreated controls, differentiating populations as homogenous or mixed, and assessing patterns of change over time (Quintero, Trosien, Hatcher & Kapila, 1999).

### **Transition from Conventional to Digital Radiography**

The analysis of cephalometric lateral skull radiographs is critically dependent on the accurate location of carefully defined anatomic landmarks. Errors in landmark identification are a significant source of error. The methodology used to identify landmarks must be meticulous. Three techniques are commonly used to identify landmarks (Turner & Weerakone 2001):

1. Overlay tracings of the lateral skull radiograph on an X-ray view, followed by direct measurement of cephalometric lines and angles on the tracing paper using a ruler and protractor.
2. Overlay tracing of the radiograph to identify anatomical and constructed points, followed by transfer of the tracing to a digitizer linked to a computer.
3. Direct digitization of the lateral skull X-ray using a digitizer linked to a computer.



With the development of computer technology, it has become possible to capture a radiographic image and display this on a computer monitor. Compared to the other methods, direct digitization of X-rays involves fewer stages to record landmarks, and because the angles and distances are calculated automatically with computer software, there is less possibility for error.

Images are points of information that can be produced by either an analog process or a digital process. Digital radiography offers a number of important advantages over traditional film: reduced radiation exposure to the patient; instantaneous acquisition of the radiographic image; elimination of darkroom facilities and development processing time and expense; simplified storage, handling, and sharing of images with appropriate professionals; and the ability to enhance the image to suit the orthodontist's needs. These advantages, coupled with clinical performance equal to that of conventional radiographic film, have shifted the standard of cephalometric radiography from film to the digital version (McClure, Sadowsky, Ferreria & Jacobson, 2005; Hagemann, Vollmer, Niegel, Ehmer & Reuter, 2000; Geelen, Wenzel, Gotfredsen, Kruger & Hansson, 1998). These advantages facilitate landmark identification and, therefore, overall accuracy.

Geelen and colleagues (1998) compared 21 landmarks on 19 images captured digitally to normal hand tracings and found no significant differences between methods. There were small statistically significant differences in measurements of digitized cephalograms compared to the traditional film versions; however, there were no observable trends that one modality was more accurate. The authors suggested that an increase in resolution of computer systems would improve results.

Turner and Weerakone (2001) compared the accuracy of the cephalometric measurements of film radiographs to digital radiographs of 25 lateral skulls. The mean measurement differences ranged between 0.2 mm and 0.5 mm, which illustrated that both forms of radiographs were sufficiently accurate to use in a clinical setting.

Demura, Tsurusako and Segami (2001) compared visual and physical characteristics such as resolution and grain size of digital and film cephalograms from ten orthodontic patients. Orthodontic landmarks were identified more accurately on the digital cephalogram compared to the traditional film versions. Similarly, Cziraki and colleagues (2002) compared 17 cephalometric landmarks and measurements on 21 conventional radiographic films and corresponding digital images. The clinical accuracy of the digital images was found to be equivalent to conventional film. This conclusion has been supported by other previous studies (Lim & Foong, 1997; Nimkarn & Miles, 1995; Macri & Wenzel, 1993; Eppley & Sadove, 1991).

### **Transition from 2D to 3D Cephalometry**

A further progression of radiology has brought a change from two-dimensional to three-dimensional radiography. Introduced in the 1970s, X-ray computed tomography (CT) scans use X-rays to produce two-dimensional (2D) tomographic images of the body, which are then processed to generate a three-dimensional (3D) image. The X-ray source is rotated around the object and is received by sensors positioned on the opposite side of the circle from the X-ray source. The three-dimensional images can be manipulated by computer software to be viewed in the axial, coronal, and sagittal planes (Scarfe & Farman, 2008).

Three-dimensional imaging systems have been compared to traditional two-dimensional cephalograms. Adams, Gansky, Miller, Harrell and Hatcher (2004) evaluated traditional 2D cephalometry and 3D imaging systems for accuracy. They recorded 13 skeletal landmarks on dry human skulls with a calibrated digital caliper. As compared to these gold standard measurements, landmark locations exhibited great variability, ranging from -17 mm to +15 mm on the 2D images. In contrast, the 3D method produced landmark locations within -4 mm to +3 mm of the gold standard. These results indicated that when compared to actual distances measured on a human skull, the 3D method was more precise and four to five times more accurate than the 2D approach. The 2D images exaggerated the true measurements and offered a distorted view of craniofacial growth. Similarly, other studies have reported greater accuracy of 3D imaging as compared to 2D (Markose, Vikraman & Veerabahu, 2009; Varghese, Kailasam, Padmanabhan, Vikraman & Chithranjan, 2010; Bholsithi, Tharanon, Chintakanon, Komolpis & Sinthanayothin, 2009).

### **CBCT compared to CT**

Cone beam computed tomographic imaging (CBCT) provides an alternative to traditional CT systems, using reduced radiation and shorter scan times. In CBCT, a conical beam of X-rays rotates about the patient in a circular path. The CBCT system acquires volumetric image data in a single revolution, as opposed to a stack of multiple slices of a scanned object as in conventional CT (Sukovic, 2003).

CBCT offers numerous advantages over 2D radiography, including less superimposition of anatomic structures, 1:1 measurements due to reduced geometric distortion, 3D display of 3D objects, and relatively low amounts of ionizing radiation.

Although conventional CT systems provide information about soft tissue, this requires much higher levels of ionizing radiation and a longer scanning time (Tetradis, Anstey & Graff-Radford, 2010). Additionally, CBCT datasets can be imported as Digital Imaging and Communication in Medicine (DICOM) files into personal computer-based software to enable 3D reconstruction of the craniofacial skeleton. These possibilities are facilitating the movement from 2D cephalometry to 3D visualization of craniofacial morphology (Periago & colleagues, 2008).

An advantage of CBCT is the ability to slice the image into cross sections. This allows surgeons to see the anatomy in the location where dental implants are going to be placed. Similarly, the excellent bony depiction is useful for temporomandibular joint (TMJ) evaluation; CBCT provides detail on the joint's bony morphology (Alexiou, Stamatakis & Tsiklakis, 2009). For periodontal defects, CBCT allows accurate periodontal bone loss measurements and is superior in observing complex periodontal defects (Misch, Yi & Sarment, 2006). With endodontics, CBCT provides more adequate diagnosis of periapical lesions, obturations, and improved surgical planning (Low, Dula, Burgin & von Arx, 2008; De Vos, Casselman & Swennen, 2009).

Current applications of CBCT in dentistry include all of the following fields: oral and maxillofacial surgery, endodontics, implant dentistry, orthodontics, general dentistry, orofacial pain, periodontics, and forensic dentistry (Alamri, Sadrameli, Alshalhoob, Sadrameli & Alshehri, 2012; De Vos, Casselman & Swennen, 2009). CBCT can be reliably used to assess the proximity of impacted teeth to vital structures. When using temporary anchorage devices in orthodontics, CBCT assists the clinician in identifying

critical structures to facilitate safe placement, thus avoiding critical structures (Poggio, Incorvati, Velo & Carano, 2006).

For orthodontic treatment planning, CBCT data can be processed to obtain cephalometric views without magnification or distortion errors (Alamri, Sadrameli, Alshalhoob, Sadrameli & Alshehri, 2012). Orthodontic assessment software programs allow dentists to use CBCT images for cephalometric analysis (Macleod & Heath, 2008). CBCT images are a practical 1:1 measuring ratio, resulting in a more accurate cephalometric option than traditional panoramic and 2D images (Peck, Sameshima, Miller, Worth & Hatcher, 2007).

CBCT is rapidly becoming the radiographic standard in 3D dental imaging. One of the concerns expressed is whether the information obtained through CBCT technology is worth the additional risk of exposure to increased radiation. On this topic the American Dental Association Council on Scientific Affairs released an advisory statement in August 2012. The Council reiterated the longstanding ethical obligation of dentists to protect patients from harm. Further, the Council listed the following recommendations for safe and appropriate clinical use of CBCT (ADA Council on Scientific Affairs, 2012).

- CBCT should be used only after reviewing the patient's medical history, and performing a clinical examination.
- Providers should perform any radiographic imaging only after professional justification that the potential clinical benefits will outweigh the radiation risks. The radiographic examination should not be used as a screening procedure. Extra consideration should be given to children and adolescents

due to these patients having a higher risk of developing cancers with the longer lifetime expected.

- Providers of CBCT should take every precaution to reduce the radiation dose including the use of thyroid collars and lead aprons except in circumstances where the collar or apron may obstruct the area of interest.
- CBCT should be prescribed only by dentists who have been properly trained in CBCT.
- CBCT images should only be evaluated by dentists with proper training in CBCT.
- The evaluator should provide a thorough radiological report and a copy should be placed in the patient's record, as well as communicated to the patient or patient's parent or legal guardian if the patient is a minor.

### **CBCT Use in Orthodontics**

Malocclusion is a three-dimensional problem resulting from discrepancies in the teeth, maxilla and/or mandible. The traditional method of diagnosing and treatment planning for orthodontists includes cephalometrics using 2D lateral cephalograms. The resulting measurements are compared to an existing database of population norms. An existing database with standard population norms is not available for 3D CBCT measurements; however, traditional 2D lateral cephalograms can be synthesized from 3D CBCT data. Two studies have compared measurements from synthesized CBCT lateral cephalograms with those from conventional lateral cephalometric radiographs. The results were compared to measurements taken with digital calipers on dried human skulls. Both studies reported that the CBCT-synthesized lateral cephalograms provided greater

accuracy than conventional lateral cephalograms (Kumar, Ludlow, Mol & Cevidanes, 2007; Moshiri & colleagues, 2007).

Studies have compared the diagnostic and outcome measurements taken from CBCT images against measurements taken from conventional 2D radiographs. There is widespread agreement that CBCT images are better for landmark identification and measurement accuracy. Even when compared against the gold standard of caliper measurements on dry skulls, the CBCT measurements have been shown to be clinically acceptable (Nervina, 2012; Stratemann, Huang, Maki, Miller & Hatcher, 2008).

Periago and colleagues (2008) compared the accuracy of linear measurements made on cone beam computed tomographic (CBCT)-derived 3D images to direct measurements made on human skulls. Twenty orthodontic linear measurements between anatomical landmarks on each of 23 human skulls were measured using a digital caliper. The skulls were imaged with CBCT and 3D volumetric reconstructions generated with a proprietary orthodontic software. These linear measurements were compared to the CBCT 3D reconstructed measurements. In this study, 40% of measurements had an average difference of less than 1 mm, and 90% had an average difference of less than 2 mm. These results were statistically significant; however, they were judged to be sufficiently clinically accurate for craniofacial analysis.

Lagravere, Carey, Toogood and Major (2008) compared the accuracy of measurements made on CBCT cephalometric images with those made on a coordinate measuring machine (CMM), which measures the geometric parameters of an object and operates in three dimensions. The machine reads the input from the touch probe tip, which can be controlled by the operator or computer program, to determine size and

position with micrometer precision. Using a dry human skull, Lagravere and colleagues compared 10 measurements obtained by using a CMM to measurements on a CBCT 3D reconstruction. CBCT measurements were not statistically significantly different from CMM measurements. The authors concluded that CBCT 3D reconstructions have a 1-to-1 ratio with real coordinates.

Another study (Strateman & colleagues, 2008) compared the accuracy of orthodontic landmark measurements using two CBCT systems. Measurements of length were taken using volumetric data and compared with direct linear measurements using a caliper applied to one human adult skull. Both CBCT systems provided highly accurate data, with less than 1% relative error.

The strength of CBCT use in orthodontics is its ability to image craniofacial anatomy in three dimensions. For orthodontists, this means improved visualization of tooth position, skeletal features, and soft tissue. Impacted and ectopic teeth, especially canines, are very common problems in orthodontic patients. Conventional 2D radiographs are sufficient to localize the tooth to one side of the alveolus or the other using the “same lingual, opposite buccal” (SLOB) rule (Maverna & Gracco, 2007). However, CBCT not only provides this information, it also shows the proximity of the impacted tooth to adjacent roots (Botticelli, Verna, Cattaneo, Heidmann & Melsen, 2011). This is critical information for treatment planning. Orthodontists report greater confidence in their diagnosis and treatment for impacted canines when they have a CBCT image of the patient (Haney, Gansky, Lee 2010).



Similarly, CBCT is helpful in the accurate measurement of external apical root resorption (EARR). Lund, Grondahl and Grondahl (2010) reported that CBCT images of root length were within 0.05 mm of their actual length.

### **Radiation Dose Comparison**

There is generalized agreement that CBCT provides highly detailed radiographic images suitable for diagnosis and treatment planning. Debate arises when considering the need for CBCT, rather than conventional 2D imaging. A lateral cephalograph or panoramic radiograph does not require as much radiation as a CBCT scan. Table 1 illustrates approximate dosages of radiation exposure for different types of radiographs. A large field of view CBCT produces 93 microsieverts ( $\mu\text{Sv}$ ) radiation. In comparison, exposure of one periapical digital radiograph using rectangular collimation results in 6  $\mu\text{Sv}$  ; full mouth radiographs with F-speed film and round collimation result in 171  $\mu\text{Sv}$  ; digital panoramic radiographs produce 9 to 26  $\mu\text{Sv}$  lateral cephalometric radiographs result in 3 to 6  $\mu\text{Sv}$  radiation (Ludlow, Davies, Brooks & Howerton, 2006; ADA Council on Scientific Affairs, 2012).

Radiation exposure and cost have decreased significantly, and the diagnostic value has become very high compared with traditional radiographic options. Advances in computer hardware and software enable interactive display of the data on personal computers, with the ability to selectively view soft or hard tissues from any angle. Due to these advances, computed tomography has become one of the main diagnostic modalities in current orthodontic practice (Halazonetis, 2005).

**Table 1.** Comparison of radiation doses. Adapted from Ludlow, Davies, Brooks and Howerton (2006). Used with permission.

1 day background radiation at sea level	Effective Dose (μSv)	Days of Equivalent Background Radiation
	7- 8	1
Digital PA	6	0.75
Digital Pano	9 - 26	1 - 3
Digital Ceph	3 - 6	0.5 - 1
FMX	171	21
Kodak CBCT (small volume)	5 - 38	0.71 – 5.47
Kodak CBCT (medium volume)	76	9.5
Kodak CBCT (large volume)	93	12
Medical CT, head	2,000	243
Medical CT, abdomen	10,000	1515
Chest x-ray	170	21
Mammogram	700	106

### Summary

Recently, cone beam computed tomography (CBCT) systems have been developed specifically for the maxillofacial region. Many devices are capable of a large field of view imaging of the skull to include most landmarks used in cephalometric analysis. CBCT-derived 3D cephalometry has a number of potential advantages over conventional CT for cephalometric imaging, including submillimeter resolution and reduced radiation exposure, while still permitting reconstruction of the soft tissue profile. CBCT data can be imported as DICOM files into personal computer–based software to provide 3D reconstruction of the craniofacial skeleton. These possibilities and increasing

access to CBCT imaging for orthodontics are enabling movement from 2D cephalometry to 3D visualization of craniofacial morphology.

However, there is a lack of data regarding the reliability and accuracy of linear measurements obtained from 3D volumetric renderings of CBCT data constructed from orthodontic software. Studies indicate that 3D reconstructions of conventional fan beam CT datasets have a high degree of accuracy, with differences between measured and actual dimensions being 2 to 3 mm. Recently, methodological approaches to cephalometric analysis of 3D CT images have also been described. Studies to assess accuracy and precision are mandatory before these applications become standard. Further research is needed in the interpretation of orthodontic information from CBCT data. Most available software tools have not yet been validated.

Therefore, the purpose of this study was to compare the reliability and accuracy of linear measurements made from 3D reconstructions generated from CBCT data using a proprietary orthodontic image and analysis program with measurements made on ex vivo pig skulls using a coordinate measuring machine (CMM), which is the gold standard.

## CHAPTER II: METHODS AND MATERIALS

### Measurements of Three Standard Models

Three dry pig skulls are available to be used as the standard models. The three skull specimens will be mounted to a stable workbench using a custom fabricated mounting platform, conformal to the base of the skull, but providing access to anatomical landmarks. Thirty-one craniofacial anatomic landmarks will be identified on each of the three skulls.

Anatomical landmarks will be measured by a coordinate measuring machine (CMM) (FARO Gage Series Contact Probe Coordinate Measurement Device, FARO Technologies, Lake Mary, FL, USA) with a point stylus tip to obtain the 3D coordinates. Landmarks will be sampled on each skull by positioning the tip of the coordinate measuring machine (CMM) at the desired location and recording the sampled position in space. All measurements will be referenced to the same fixed reference coordinate system at the base of the CMM. Each landmark will be measured independently by the primary investigator; all measurements will be made three times. The mean of the measurements will be designated as the dimensional truth. The following landmarks will be sampled (see Figures 1-5):

**PA** (Parietale): Highest part of the skull in the midline (formed by the nuchal crest of the occipital bone and parietal bone).

**PC{Right and Left}** (Bilateral Parietal Crests)

**PRN** (Pronasale): Upper edge of the snout in the midline

**ZY {Right and Left}** (Bilateral Zygion): Most lateral point of malar bone

**GO {Right and Left}** (Gonion): Angle of mandible.

**OS {Right and Left}** (Orbitale Superius): Highest point of orbit.

**OI {Right and Left}** (Orbitale Inferius): Lowest point of orbit.

**SB** (Snout Base): Middle point on the lower edge of the snout.

**LN {Right and Left}** (Nasofrontal Suture Line): Lateral terminal points of nasofrontal suture line; Point where lacrimal, nasal, frontal and maxilla meet.

**AL {Right and Left}** (Ala): Most lateral point of snout.

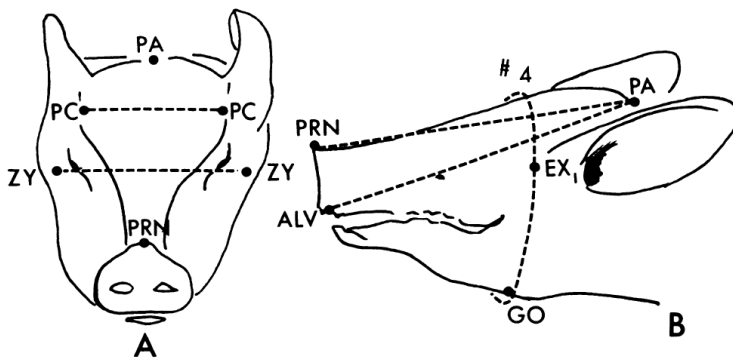


Fig. 1. Longitudinal, horizontal and circumferential measurements of the pig's head.

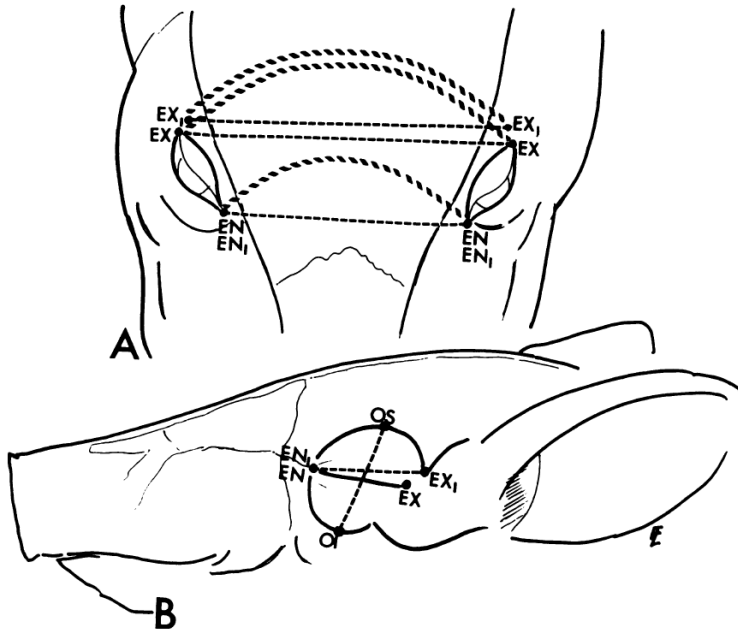


Fig. 2. Measurements of the orbital region.

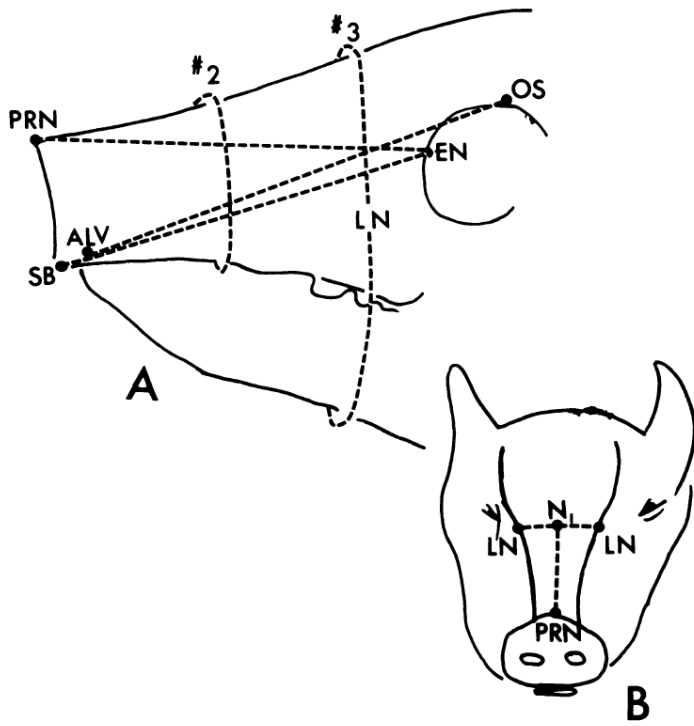


Fig. 3. Anterior-posterior, horizontal and circumferential measurements of the "upper face" of the pig.

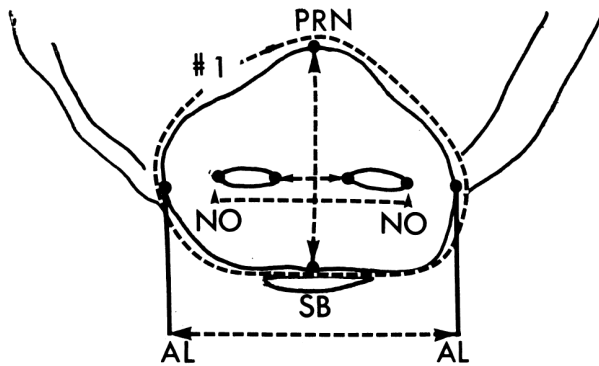


Fig. 4. Measurements of the snout.

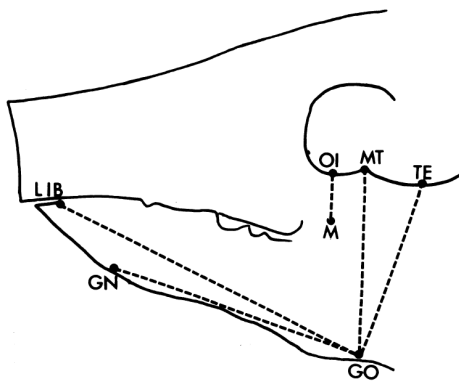


Fig. 5. Anterior-posterior and vertical measurements of the "lower face" of the pig.

(Figures obtained from Farkas, Munro, Vanderby, 1976)

### Measurement of CBCT Data

CBCT images have been acquired for the three pig models. The CBCT data were exported into DICOM multi-file format. They will be imported into a proprietary orthodontic software program (Dolphin 3D, mfg, city, state) used for measurement and analysis of craniofacial dimensions. Three-dimensional reconstructions and measurements will be undertaken in three stages.

First, 3D surface rendering will be manually adjusted using the threshold of visible pixel levels to adjust segmentation.

Second, the same cephalometric landmarks that were identified on the skulls will be located and marked on the 3D surface of the image. The software provides various views using rotation and translation of the images. Landmarks will be identified by using a cursor-driven pointer.

Third, measurements between specific landmarks will be made. Linear measurements will be exported as text data.

This process will be repeated three times by the principal investigator. The mean of the measurements will be designated as the dimensional truth.

### **Comparison of CMM measurements to CBCT Measurements**

All linear measurements from the CMM measurements will be compared to the CBCT measurements.

### **Statistical Analysis**

For each anatomic landmark, mean ( $\pm$  standard deviation) linear measurements will be calculated from the corresponding values recorded for each of the three specimen skulls. The mean values obtained via the computer software will be compared to the values obtained by the coordinate measurement device via Paired Samples *t*-Tests. Data will be analyzed using Statistical Package for the Social Sciences (SPSS) Version 18 computer software (SPSS, Inc., Chicago, IL). All statistical significance levels will be set at  $\alpha = 0.05$ .



## CHAPTER III: DISCUSSION

The rapidly emerging availability of CBCT equipment and technology is expanding the use of 3D imaging, particularly in the field of orthodontics. The purpose of this study was to compare the reliability and accuracy of linear measurements made from 3D reconstructions generated from CBCT data using a proprietary orthodontic image and analysis program compared with measurements made on pig skulls using a coordinate measuring machine (CMM), which is the gold standard.

In orthodontics, cephalometric analysis has been an important tool for diagnosis, treatment planning, and for the assessment of changes over time. Due to the reduction in errors occurring in 2D systems a trend has developed shifting away from traditional 2D analog films towards 3D digital imaging systems. Typical errors of 2D imaging include magnification and distortion. These errors are compounded by incorrect patient positioning and operator inexperience. Three-dimensional reconstructions claim to produce images that are anatomically true 3D representations in a 1 to 1 ratio.

If the error is negative compared with the CMM measurements then that would indicate compression distortion of the CBCT image. If the error is positive compared with the CMM measurements then that would indicate magnification distortion of the CBCT image.

### **Limitations of the Study**

Other authors of similar studies have found statistically significant differences between the CBCT measurements and the actual measurements. However, after analyzing the absolute and percentage differences, this statistical significance probably

does not translate into clinical relevance. Statistical differences may be derived from some potential limitations of the study.

First and foremost, this study was performed on deceased pig skulls instead of living human skulls.

A second limitation is the reduction in image quality that affects the accuracy of CBCT data known as segmentation. Segmentation produces deficiencies or voids on CBCT images in regions that are represented by few voxels such as the walls of the maxillary sinus, bone overlying the teeth, and bone of the condyles. This may lead to greater landmark identification error and subsequent measurement error. Anatomic landmarks that are frequently affected include A point, ANS, PNS, porion, and condyilion (Periago 2008).

A third limitation is the method of measurement that could have potentially contributed to bias in the results. Blinding during data collection was not possible. While the landmark identification and measurement on the skulls were repeated by three observers, the landmark identification and measurement on the 3D rendered images was performed only once.

A fourth limitation is we were unable to simulate soft tissue effects of attenuation on image quality. The lack of soft tissue peripheral attenuation allowed easier identification of landmarks on 3D surface rendered images.

A fifth limitation and possible explanation is that this error may have been introduced by the proprietary orthodontic image and analysis measurement software.

### **Significance of this Study**

The verification of this 1-to-1 ratio of CBCT to real linear measurements will provide great opportunity for qualitative analysis of craniofacial structures.

Opportunities can be created for the development of new methods of volumetric assessment and the establishment of normative parameters. This technology will give clinicians new possibilities in determining changes produced by various orthodontic interventions. The findings have the potential to validate the use of CBCT and orthodontic software as a tool used in establishing anatomical relationships, improving diagnosis, treatment planning, and prognostication.

### **Future Applications of CBCT in Orthodontics**

There is a significant trend toward improved treatment planning and outcomes prediction using CBCT images and 3D modeling. There are applications for predicting stress distributions on the dentition using orthodontic appliances during treatment e.g. during rapid palatal expansion or using temporary anchorage devices. The goal of this research is to determine how the patient's skeletal features will respond to appliance designs in order to generate patient specific approaches of orthodontic treatment.

## **CHAPTER IV: CONCLUSION**

Many linear measurements between cephalometric landmarks may be statistically significantly different from anatomic dimensions, most can be considered to be sufficiently clinically accurate for craniofacial analysis. This finding helps to validate the tool to be used in establishing diagnostic evaluations of the craniofacial region.

# APPENDIX

## Data Collection Form

### Landmarks:

**PA** (Parietale): Highest part of the skull in the midline (formed by the nuchal crest of the occipital bone and parietal bone).

**PC {Right and Left}** (Bilateral Parietal Crests)

**PRN** (Pronasale): Upper edge of the snout in the midline

**ZY {Right and Left}** (Bilateral Zygion): Most lateral point of malar bone

**GO {Right}** (Gonion): Angle of mandible.

**OS {Right}** (Orbitale Superius): Highest point of orbit.

**OI {Right}** (Orbitale Inferius): Lowest point of orbit.

**SB** (Snout Base): Middle point on the lower edge of the snout.

**LN {Right and Left}** (Nasofrontal Suture Line): Lateral terminal points of nasofrontal suture line; Point where lacrimal, nasal, frontal and maxilla meet.

**AL {Right and Left}** (Ala): Most lateral point of snout.

## Specimen #1

### Transverse Plane

	1	2	3	CBCT Mean Distance	1	2	3	FARO Mean Distance	Difference
PA to PRN									
PA to SB									
OS to SB									
OS to PRN									

### Sagittal Plane

	1	2	3	CBCT Mean Distance	1	2	3	FARO Mean Distance	Difference
PRN to SB									
OS to GO									
PA to GO									
OS to OI									

### Frontal Plane

	1	2	3	CBCT Mean Distance	1	2	3	FARO Mean Distance	Difference
PCL to PCR									
ZYL to ZYR									
ALL to ALR									
LNL to LNR									

**Specimen #2**

**Transverse Plane**

	1	2	3	CBCT Mean Distance	1	2	3	FARO Mean Distance	Difference
PA to PRN									
PA to SB									
OS to SB									
OS to PRN									

**Sagittal Plane**

	1	2	3	CBCT Mean Distance	1	2	3	FARO Mean Distance	Difference
PRN to SB									
OS to GO									
PA to GO									
OS to OI									

**Frontal Plane**

	1	2	3	CBCT Mean Distance	1	2	3	FARO Mean Distance	Difference
PCL to PCR									
ZYL to ZYR									
ALL to ALR									
LNL to LNR									

### Specimen #3

#### Transverse Plane

	1	2	3	CBCT Mean Distance	1	2	3	FARO Mean Distance	Difference
PA to PRN									
PA to SB									
OS to SB									
OS to PRN									

#### Sagittal Plane

	1	2	3	CBCT Mean Distance	1	2	3	FARO Mean Distance	Difference
PRN to SB									
OS to GO									
PA to GO									
OS to OI									

#### Frontal Plane

	1	2	3	CBCT Mean Distance	1	2	3	FARO Mean Distance	Difference
PCL to PCR									
ZYL to ZYR									
ALL to ALR									
LNL to LNR									



## REFERENCES

- Adams G, Gansky S, Miller A, Jarrell W, Hatcher D. (2004). Comparison between traditional 2 dimensional cephalometry and a 3 dimensional approach on human dry skulls. *American Journal of Orthodontics and Dentofacial Orthopedics*, 126(4), 397-409.
- Alamri H, Sadrameli M, Alshalhoob M, Sadrameli M, Alshehri M. (2012). Applications of CBCT in dental practice: A review of the literature. *General Dentistry*, 60(5), 390-400.
- Alexiou K, Stamatakis H, Tsiklakis K. (2009). Evaluation of the severity of temporomandibular joint osteoarthritic changes related to age using cone beam computed tomography. *Dentomaxillofacial Radiology*, 38(3), 141-147.
- American Dental Association Council on Scientific Affairs. (2012). The use of cone-beam computed tomography in dentistry. *The Journal of the American Dental Association*, 143(8), 899-902.
- Baik H, Jeon J, Lee H. (2007). Facial soft tissue analysis of Korean adults with normal occlusion using a 3-dimensional laser scanner. *American Journal of Orthodontics and Dentofacial Orthopedics*, 131(3), 759-766.
- Bholsithi W, Tharanon W, Chintakanon K, Komolpis R, Sinthanayothin C. (2009). 3D vs. 2D cephalometric analysis comparisons with repeated measurements from 20 Thai males and 20 Thai females. *Biomedical imaging and Intervention Journal*, 5(4), 21-29.
- Botticelli S, Vern C, Cattaneo PM, Heidmann J, Melsen B. (2011). Two versus three dimensional imaging in subjects with unerupted maxillary canines. *European Journal of Orthodontics*, 33(2), 344-349.
- Broadbent BH. (1931). A new x-ray technique and its application to orthodontia. *Angle Orthodontics*, 1, 45-66.
- Brooks SL, Atchinson KA. (2004). Guidelines for prescribing dental radiographs. *Oral Radiography. Principles and Interpretation*, 5<sup>th</sup> edition, Mosby, St. Louis, pp 265-277.

- Cavalcanti MG, Haller JW, Vannier MW. (1999). Three-dimensional computed tomography landmark measurement in craniofacial surgical planning: experimental validation in vitro. *Journal of Oral and Maxillofacial Surgery*, 57(6), 690-694.
- Cavalcanti MG, Rocha SS, Vannier MW. (2004). Craniofacial measurements based on 3D-CT volume rendering: implications for clinical applications. *Dentomaxillofacial Radiology*, 33(3), 170-176.
- Changsheng X, Zhenming X, Songde M. (1998). Research and application on automatic cephalometric measurement and facial prediction system. *High Technology Letters*, 4(2), 42-45.
- Cziraki S, Pharoah M, Lawrence H, Petrikowski C, Birek P, Rossouw P. (2002). The reproducibility and accuracy of cephalometric analysis using different digital imaging modalities and image compression. *American Journal of Orthodontics and Dentofacial Orthopedics*, 122(1), 117-120.
- Demura N, Tsurusako Y, Segami N. (2001). Characteristics of digital cephalograms and film/screen cephalograms: a comparative study. *World Journal of Orthodontics*, 2(4), 350-355.
- De Vos W, Casselman J, Swennen GRJ. (2009). Cone-beam computerized tomography (CBCT) imaging of the oral and maxillofacial region: A systemic review of the literature. *International Journal of Oral Maxillofacial Surgery*, 38(2), 609-625.
- Eppley BL, Sadove AM. (1991). Computerized digital enhancement in craniofacial cephalometric radiology. *Journal of Oral and Maxillofacial Surgery*, 49(10), 1038-1043.
- Farkas L, Munro I, Vanderby B. (1976). Quantitative Assessment of the Morphology of the Pig's Head Used as a Model in Surgical Experimentation Part 1: Methods of Measurements. *Canadian Journal of Comparative Medicine*, 40(4), 397-403.
- Feldkamp LA, Davis LC, Kress JW. (1994). Practical cone-beam algorithm. *Journal of the Optical Society of America A*, 1(6), 612-619.
- Geelen W, Wenzel A, Gotfredsen E, Kruger M, Hansson LG. (1998). Reproducibility of cephalometric landmarks on conventional film, hardcopy, and monitor-displayed images obtained by the storage phosphor technique. *European Journal of Orthodontics*, 20(3), 331-340.

- Grauer D, Cevidanes LH, Proffit WR. (2009). Working with DICOM craniofacial images. *American Journal of Orthodontics and Dentofacial Orthopedics*, 136(3), 460-470.
- Grayson B, Bookstein F, Kim H. (1988). The three-dimensional cephalogram: theory, technique, and clinical application. *American Journal of Orthodontics and Dentofacial Orthopedics*, 94(4), 327-337.
- Hagemann K, Vollmer D, Niegel T, Ehmer U, Reuter I. (2000). Prospective study on the reproducibility of cephalometric landmarks on conventional and digital lateral headfilms. *Journal of Orthofacial Orthopedics*, 61(2), 91-99.
- Haney E, Gansky SA, Lee JS. (2010). Comparative analysis of traditional radiographs and cone beam computed tomography volumetric images in the diagnosis and treatment planning of maxillary impacted canines. *American Journal of Orthodontics and Dentofacial Orthopedics*, 137(3), 590-597.
- Harrell Jr WE, Hatcher DC, Bolt RL. (2002). In search of anatomic truth: 3-dimensional modeling and the future of orthodontics. *American Journal of Orthodontics and Dentofacial Orthopedics*, 122(3), 325-330.
- Halazonetis D. (2005). From 2-dimensional cephalograms to 3-dimensional computed tomography scans. *American Journal of Orthodontics and Dentofacial Orthopedics*, 127(5), 627-637.
- Hatcher DC. Maxillofacial imaging. In: McNeill C, ed. Science and practice of occlusion. Chicago: Quintessence; 1997.
- Herman GT. Fundamentals of computerized tomography: Image reconstruction from projection, 2<sup>nd</sup> edition, Springer 2009.
- Hildebolt CF, Vannier MW, Knapp RH. (1990). Validation study of skull three-dimensional computerized tomography measurements. *American Journal of Physical Anthropology*, 82(3), 283-294.
- Ioi H, Nakata S, Nakasima A, Counts AL. (2007). Comparison of cephalometric norms between Japanese and Caucasian adults in antero-posterior and vertical dimension. *European Journal of Orthodontics*, 29(5), 493-499.

- Kumar V, Ludlow JB, Mol A, Cevidanes L. (2007). Comparison of conventional and cone beam CT synthesized cephalograms. *Dentomaxillofacial Radiology*, 36(5), 263-269.
- Lagravere M, Major P. (2005). Proposed reference point for 3-dimensional cephalometric analysis with cone-beam computerized tomography. *American Journal of Orthodontics and Dentofacial Orthopedics*, 128(5), 657-660.
- Lagravere M, Carey J, Toogood R, Major P. (2008). Three-dimensional accuracy of measurements made with software on cone-beam computed tomography images. *American Journal of Orthodontics and Dentofacial Orthopedics*, 134(1), 112-116.
- Lim KF, Foong KW. (1997). Phosphor-stimulated computed cephalometry: Reliability of landmark identification. *British Journal of Orthodontics*, 24(4), 301-308.
- Low KM, Dula K, Burgin W, von Arx T. (2008). Comparison of periapical radiography and limited cone-beam tomography in posterior maxillary teeth referred for apical surgery. *Journal of Endodontics*, 34(5), 557-562.
- Ludlow JB, Davies LE, Brooks SL, Howerton WB. (2006). Dosimetry of 3 CBCT devices for oral and maxillofacial radiology: CB Mercuray, NewTom 3G and i-CAT. *Dentomaxillofacial Radiology*, 35(4), 219-226.
- Lund H, Grondahl K, Grondahl HG. (2010). Cone beam computed tomography for assessment of root length and marginal bone level during orthodontic treatment. *Angle Orthodontics*, 80(4), 466-473.
- Macri V, Wenzel A. (1993). Reliability of landmark recording on film and digital lateral cephalograms. *European Journal of Orthodontics*, 15(2), 137-148.
- Markose E, Vikraman B, Veerabahu M, (2009). Three dimensional CT reconstruction: a comparison between 2D, 3D CT and original anatomical structures. *Journal of Maxillofacial Oral Surgery*, 8(1), 8-12.
- McClure S, Sadowsky P, Ferreira A, Jacobson A. (2005). Reliability of digital versus conventional cephalometric radiology: A comparative evaluation of landmark identification error. *Seminars in Orthodontics*, 11(2), 98-110.
- Macleod I, Heath N. (2008). Cone-beam computed tomography (CBCT) in dental practice. *Dental Update*, 35(9), 590-598.

- Maverna R, Gracco A. (2007). Different diagnostic tools for the localization of impacted maxillary canines: clinical considerations. *Progress in Orthodontics*, 8(1), 28-44.
- Misch KA, Yi ES, Sarment DP. (2006). Accuracy of cone beam computed tomography for periodontal defect measurements. *Journal of Periodontology*, 77(7), 1261-1266.
- Moshiri M, Scarfe WC, Hilgers ML, Scheetz JP, Silveira AM, Farman AG. (2007). Accuracy of linear measurements from imaging plate and lateral cephalometric images derived from cone-beam computed tomography. *American Journal of Orthodontics and Dentofacial Orthopedics*, 132(4), 550-560.
- Nervina, J M. (2012). Cone Beam Computed Tomography Use in Orthodontics. *Australian Dental Journal*, 57(1), 95-102.
- Nimkarn Y, Miles PG. (1995). Reliability of computer-generated cephalometrics. *The International Journal of Adult Orthodontics and Orthognathic Surgery*, 10(1), 43-52.
- Peck JL, Sameshima, GT, Miller A, Worth P, Hatcher DC. (2007). Mesiodistal root angulation using panoramic and cone beam CT. *Angle Orthodontics*, 77(2), 206-213.
- Periago DR, Scarfe WC, Moshiri M, Scheetz JP, Silveira AM and Farman AG. (2008). Linear accuracy and reliability of cone beam CT derived 3-dimensional images constructed using an orthodontic volumetric rendering program. *Angle Orthodontics*, 78(3), 387-395.
- Poggio PM, Incorvati C, Velo S, Carano A. (2006). "Safe zones": A guide for miniscrew positioning in the maxillary and mandibular arch. *Angle Orthodontics*, 76(2), 191-197.
- Quintero JC, Trosien A, Hatcher D, Kapila S. (1999). Craniofacial imaging in orthodontics: Historical perspective, current status, and future developments. *Angle Orthodontics*, 69(6), 491-506.
- Rungcharassaeng K, Caruso JM, Kan JY, Kim J, Taylor G. (2007). Factors affecting buccal bone changes of maxillary posterior teeth after rapid maxillary expansion. *American Journal of Orthodontics and Dentofacial Orthopedics*, 132(4), 428-438.

- Santoro, Jarjoura K, Cangialosi T. (2006). Accuracy of digital and analogue cephalometric measurements assessed with the sandwich technique. *American Journal of Orthodontics and Dentofacial Orthopedics*, 129(3), 345-351.
- Scarfe WC, Farman AG. (2008). What is cone-beam CT and how does it work? *Dental Clinics of North America*, 52(4), 707-730.
- Stratemann SA, Huang JC, Maki K, Miller AJ, Hatcher DC. (2008). Comparison of cone beam computed tomography imaging with physical measures. *Dentomaxillofacial Radiology*, 37(2), 80-93.
- Sukovic P. (2003). Cone beam computed tomography in craniofacial imaging. *Orthodontics and Craniofacial Research*, 6(1), 31-36.
- Tetradis S, Anstey P, Graff-Radford S. (2010). Cone beam computed tomography in the diagnosis of dental disease. *Journal of the California Dental Association*, 38(1), 27-32.
- Turner P J, Weerakone S. (2001). An evaluation of the reproducibility of landmark identification using scanned cephalometric images. *Journal of Orthodontics*, 28(2) 221-229.
- Vandenberghe B, Jacobs R, Bosmans H. (2010). Modern dental imaging: a review of the current technology and clinical applications in dental practice. *European Radiology*, 20 (11), 2637-2655.
- Varghese S, Kailasam V, Padmanabhan S, Vikraman B, Chithranjan A. (2010). Evaluation of the accuracy of linear measurements on spiral computed tomography-derived three-dimensional images and its comparison with digital cephalometric radiography. *Dentomaxillofacial Radiology*, 39(4), 216-223.
- Vig PS. Orthodontic controversies: their origins, consequences, and resolution. In: Melsen B, ed. *Current controversies in orthodontics*. Chicago: Quintessence; 1991.
- Williams FL, Richtsmeier JT. (2003). Comparison of mandibular landmarks from computed tomography and 3D digitizer data. *Clinical Anatomy*, 16(6), 494-500.