

Award Number: W81XWH-12-1-0066

TITLE: Subharmonic Imaging and Pressure Estimation for Monitoring
Neoadjuvant Chemotherapy

PRINCIPAL INVESTIGATOR: Flemming Forsberg, Ph.D.

CONTRACTING ORGANIZATION: Thomas Jefferson University
Philadelphia, Pennsylvania 19107

REPORT DATE: November 2015

TYPE OF REPORT: Final

PREPARED FOR: U.S. Army Medical Research and Materiel Command
Fort Detrick, Maryland 21702-5012

DISTRIBUTION STATEMENT: Approved for public release;
Distribution Unlimited

The views, opinions and/or findings contained in this report are those of the author(s) and should not be construed as an official Department of the Army position, policy or decision unless so designated by other documentation.

REPORT DOCUMENTATION PAGEForm Approved
OMB No. 074-0188

Public reporting burden for this collection of information is estimated to average 1 hour per response, including the time for reviewing instructions, searching existing data sources, gathering and maintaining the data needed, and completing and reviewing this collection of information. Send comments regarding this burden estimate or any other aspect of this collection of information, including suggestions for reducing this burden to Washington Headquarters Services, Directorate for Information Operations and Reports, 1215 Jefferson Davis Highway, Suite 1204, Arlington, VA 22202-4302, and to the Office of Management and Budget, Paperwork Reduction Project (0704-0188), Washington, DC 20503

1. AGENCY USE ONLY (Leave blank)		2. REPORT DATE November 2015	3. REPORT TYPE AND DATES COVERED Final 1Sep2012 - 31Aug2015	
4. TITLE AND SUBTITLE Subharmonic Imaging and Pressure Estimation for Monitoring Neoadjuvant Chemotherapy			5. FUNDING NUMBERS W81XWH-12-1-0066	
6. AUTHOR(S) Flemming Forsberg, Ph.D. email: flemming.forsberg@jefferson.edu				
7. PERFORMING ORGANIZATION NAME(S) AND ADDRESS(ES) Thomas Jefferson University Philadelphia, Pennsylvania 19107			8. PERFORMING ORGANIZATION REPORT NUMBER	
9. SPONSORING / MONITORING AGENCY NAME(S) AND ADDRESS(ES) U.S. Army Medical Research and Materiel Command Fort Detrick, Maryland 21702-5012			10. SPONSORING / MONITORING AGENCY REPORT NUMBER	
11. SUPPLEMENTARY NOTES				
12a. DISTRIBUTION / AVAILABILITY STATEMENT Approved for public release; distribution unlimited				12b. DISTRIBUTION CODE
13. ABSTRACT (Maximum 200 Words) Neoadjuvant chemotherapy is currently the standard of care for locally advanced breast cancer (LABC). Monitoring tumor response is advantageous for patients. This project aims to using the subharmonic signals from ultrasound contrast agents to improve the monitoring of breast cancer treatment response to neoadjuvant therapies in women diagnosed with LABC by imaging tumor angiogenesis with 3D subharmonic imaging (SHI) and by estimating the interstitial fluid pressure (IFP) using 3D subharmonic aided pressure estimation (SHAPE). Software for analyzing RF data from a Logiq 9 ultrasound scanner (GE Healthcare, Milwaukee, WI) to produce 3D SHAPE pressure estimates has been successfully developed and tested <i>in vivo</i> in 2 canines. Difficulty in obtaining the necessary approvals for our human clinical trial has delayed the project by approximately 12 months, but we have received a one year no cost extension. Our clinical trial of SHAPE for noninvasive evaluation of the IFP in breast lesions with Definity started in May of 2014 and 17 subjects have been enrolled, out of which 12 are expected to complete the trial. Preliminary clinical results indicate that 5 patients saw complete resolution of the primary mass, while 3 subjects achieved partial response only. Complete responders demonstrated greater vascularity at baseline and greater overall change in flow and IFP relative to partial responders; albeit not statistically significant ($p > 0.19$).				
14. SUBJECT TERMS Breast Cancer, Ultrasound Imaging, Ultrasound Contrast Agent, Pressure Estimation, Neoadjuvant chemotherapy			15. NUMBER OF PAGES 16	
			16. PRICE CODE	
17. SECURITY CLASSIFICATION OF REPORT Unclassified	18. SECURITY CLASSIFICATION OF THIS PAGE Unclassified	19. SECURITY CLASSIFICATION OF ABSTRACT Unclassified	20. LIMITATION OF ABSTRACT Unlimited	

NSN 7540-01-280-5500

Standard Form 298 (Rev. 2-89)
Prescribed by ANSI Std. Z39-18
298-102

3 TABLE OF CONTENTS

1	FRONT COVER	1
2	SF 298	2
3	TABLE OF CONTENTS	3
4	INTRODUCTION	4
5	BODY	5
	5.1 Methods	6
	5.2 Results and Discussion	7
6	KEY RESEARCH ACCOMPLISHMENTS	10
7	REPORTABLE OUTCOMES	11
8	CONCLUSIONS	14
9	REFERENCES	14
	Appendix I	16

4 INTRODUCTION

In the United States, close to 5 – 20 % of newly diagnosed breast cancer and 10 – 30% of all primary breast cancer is diagnosed as locally advanced breast cancer (LABC) [1, 2]. Neoadjuvant chemotherapy (systemic preoperative chemotherapy) is currently the standard of care for LABC [3, 4]. When compared with adjuvant chemotherapy (postoperative therapy), neoadjuvant chemotherapy yields similar results for both overall survival (70% for both) and disease-free survival (53% adjuvant, 55% neoadjuvant) [5]. Thus, the postponement of surgery does not affect the outcome of the treatment [5, 6]. In addition, neoadjuvant chemotherapy offers considerable benefits to the patient as the treatment can shrink the tumor and even in some cases offer complete pathologic response [3, 7]. This reduction in tumor size increases the possibility of breast conservation [3, 5-7]. Maximizing the conservation of breast tissue can be of great personal importance for the self-esteem and quality of living of the patient [6]. Neoadjuvant chemotherapy can also offer an early indication of the patient's response to chemotherapy. Consequently, monitoring tumor response to neoadjuvant therapy gives the possibility of adjusting the treatment if the patient is responding poorly or not at all resulting in substantial advantages for the patient [3, 6]. This project aims at establishing noninvasive monitoring of neoadjuvant chemotherapy in the breast using subharmonic aided pressure estimation (SHAPE; U.S. Patent 6,302,845).

Generally interstitial fluid pressure (IFP) is 10-30 mmHg higher in cancerous tissue than in normal tissue although values of up to 60 mmHg have been recorded [8, 9]. Similarly, IFP in breast cancer tumors has been shown to be higher than that of surrounding breast tissue [9]. This increase is believed to be due to vascularity, fibrosis and difference in the interstitial matrix in tumors and it can result in poor transport of therapeutic drugs to tumors [8]. Taghian et al. used a wick-in-needle technique to monitor the IFP of breast cancer before and after neoadjuvant chemotherapy with two drugs used consecutively [10]. When used as a first drug Paclitaxel decreased the IFP by 36% ($p=0.02$) whereas with Doxorubicin as a first drug there was only 8% reduction ($p=0.41$). As this was a hypothesis-generating study they did not show any outcome related to the relationship between IFP and therapy response [10]. However, the level of IFP has been shown to predict disease free survival for cervix cancer (34% disease free survival (DFS) if $IFP > 19$ mmHg, 68% DFS if $IFP < 19$ mmHg ($p = 0.002$)) [11]. Thus, the level of interstitial fluid pressure (IFP) in breast cancer tumors could potentially be used to monitor the response to neoadjuvant chemotherapy.

Contrast agents have been used for two decades to improve visualization in ultrasound (US) imaging as they enhance the difference in reflectivity between tissues [12]. Because of the difference in compressibility between the medium and the microbubble any changes in pressure induce changes in the size of the microbubble [13]. This in turn affects the reflectivity and resonant frequency of the bubble [13, 14]. In subharmonic imaging (SHI) pulses are transmitted at a frequency f_0 and the echoes are received at half that frequency $f_0/2$. SHI has been showed to be a feasible option for contrast enhanced imaging due to subharmonic generation by contrast agents and limited subharmonic generation in tissues [15]. Our group came up with a novel technique, SHAPE, utilizing

microbubbles and the subharmonic amplitude of the scattered signal [13]. We showed that there is a linear relationship between the hydrostatic pressure and the subharmonic amplitude. We propose the use of SHAPE to monitor treatment response by noninvasively measuring the IFP in breast tumors. This offers several benefits to the patient. As opposed to the wick-in-needle technique SHAPE is noninvasive and does not inflict pain. Furthermore, it allows for an early indication of responders vs. non-responders and thereby makes adjustments to therapy easier. Moreover, SHAPE has been shown to have a favorable signal-to-noise ratio so the subharmonic amplitude is not affected by background noise [13].

The SHAPE algorithm will be implemented on a state-of-the-art ultrasound scanner (Logiq 9, GE Healthcare, Milwaukee, WI) for *in vivo* monitoring of angiogenesis and IFP. This implementation will be tested with the 4D10L 3D probe and optimized *in vivo* (in canines) with the contrast agent Definity. The ability of SHI to depict macro- and micro-vascularity (the latter as a model for tumor angiogenesis) will also be assessed. Finally, the ability of 3D SHI and SHAPE to monitor neoadjuvant chemotherapy in women with LABC (i.e., the ability to track changes in tumor angiogenesis and IFP, respectively) will be evaluated in a first in humans clinical trial. We plan to recruit 10 – 25 subjects per year who will be studied with contrast US (SHI and SHAPE) before as well as after the 1st, 3rd and last chemotherapy cycle. All subjects will also receive an MRI as part of their standard of care (before and after completion of the chemotherapy), and these results together with pathology will be compared to the 3D SHI and SHAPE studies (independently as well as combined) as a means for treatment monitoring.

Our group has proposed that SHAPE and contrast enhanced US imaging can be used to measure the IFP in LABC tumors, thus, making it possible to noninvasively monitor the tumor response to neoadjuvant chemotherapy. This method would be a considerable improvement from the wick-in-needle technique currently used for IFP measurements in LABC and allow for individualized treatments options.

5 BODY

The hypothesis of this project is that IFP in breast tumors can be measured noninvasively using SHAPE and contrast enhanced US thus improving the monitoring of neoadjuvant chemotherapy. First 3D SHI and SHAPE will be implemented on a commercial scanner. The scanner will be used to monitor neoadjuvant chemotherapy in women with LABC in a first in humans clinical trial. We plan to recruit 20 – 50 subjects who will be studied with contrast SHI and SHAPE before as well as after the 1st, 3rd and last chemotherapy cycle. The specific tasks of the project (as presented in the original Statement of Work) can be found in Appendix I.

First an outline of the methods applied will be given followed by a presentation of the results to date. Finally, the conclusions and future directions of the research will be discussed.

5.1 Methods

Obtaining regulatory approval for the human subjects' components of this proposal has been problematic. We submitted our human pilot study protocol to Lantheus Medical Imaging (for access to the ultrasound contrast agent Definity) on December 6th, 2012. Next, we prepared an amendment to our existing IND application (#112,241) with the Food and Drug Administration (FDA), which was approved by the FDA without comments on March 25th, 2013. While the FDA were reviewing our protocol, we prepared the required documentation for the TJU human subjects' approval and, as described in last year's report, final TJU approval was received on June 6th, 2013. Then we prepared documentation to be in compliance with the USAMRMC human subjects' protection requirements under the Office of Research Protections (ORP). The ORP provides human subjects protection review and compliance oversight under the Human Research Protections Office (HRPO), which received our submission on June 17th, 2013. After having received several ORP HRPO reviews and made the appropriate amendments (which also had to be approved by the TJU IRB), we were granted approval by the ORP HRPO on December 6th, 2013.

Unfortunately, Lantheus Medical underwent major financial turmoil during 2013, which resulted in most senior staff being replaced. This in turn required us to resubmit our proposal and all associated documentation for re-evaluation. The assessment at Lantheus lasted another 4 months, before we received final approval and had the contrast signed on April 23rd, 2014.

Given the delay caused by the efforts required to obtain regulatory approval for the human clinical trial, the project was approximately 12 months behind schedule and we, therefore, requested a one year no cost extension to complete the SOW (Appendix I). This extension was granted on October 16th, 2014.

In vivo animal experiments

Our group has worked in partnership with GE to implement SHAPE on a state-of-the-art commercial scanner Logiq 9 with a mechanical 3D linear array (4D10L). Software to automatically optimize the acoustic output power for SHAPE has been developed on the scanner. Briefly, the optimization algorithm steps the ultrasound scanner from 0 to 100% output power [16]. A logistic equation fitting function was applied with the criterion of minimum least squared error between the fitted subharmonic amplitudes and the measured subharmonic amplitudes as a function of the output levels and the optimum level is chosen as the inflection point calculated from the fitted data. Likewise, software has also been developed to perform 3D SHAPE on the Logiq 9.

Several experiments have been carried out in 2 canines to investigate 3D SHI and SHAPE for *in vivo* renal imaging and pressure estimation obtained with IV infusions of the microbubble based ultrasound contrast agent Definity (infusion rate: 3-10 ml/min for a 3 ml vial of Definity mixed with 50 ml of saline, which is the allowed range for human studies). For these optimization experiments, the dogs' kidneys were imaged (transcutaneously), because this is the most vascular organ and a good model for blood perfusion in tissue. We used regular imaging i.e., grayscale B-mode to confirm the

appropriateness of the SHI imaging sites. We will also acquire simultaneous measurements of pressure in the kidneys with a Logiq 9 ultrasound scanner modified to obtain subharmonic microbubble signal amplitudes and with an intravenous 5F high-fidelity manometer-tipped pressure catheter (SPC-350; Millar Instruments, Houston, TX). The subharmonic and the pressure catheter data were compared.

In vivo human clinical trial

Our clinical trial of SHAPE with Definity for noninvasive evaluation of the IFP in breast lesions during neoadjuvant chemotherapy started in May of 2014. Briefly, the protocol evaluated the ability of 3D SHI and SHAPE to track changes in LABC angiogenesis and IFP, respectively, by studying women undergoing neoadjuvant chemotherapy before as well as with around 10% and 60% of the neoadjuvant chemotherapy treatment delivered and after completion of the neoadjuvant chemotherapy treatment. Results will be compared to MRI and pathology. The modified Logiq 9 scanner will be used to acquire conventional and SHI images (at a transmit frequency of 5.8 MHz with the subharmonic obtained at 2.9 MHz). Using this setup, acoustic pressure amplitudes will all be below 1.5 MPa peak negative pressure, 2.5 MPa peak positive pressure ($MI < 0.33$).

A baseline US grayscale scan will be used to identify the mass or abnormal area seen by mammography (or another concomitant imaging mode, such as US or MRI) and to evaluate the following criteria: diagnosis; size, shape, and orientation of the lesion; echogenicity compared to surrounding tissue. Standard Power Doppler (PDI) of the lesion or target area will also be performed. The distribution of color signals and the overall color content of the lesion will be evaluated by comparing the pattern and amount of color to the normal surrounding breast. Irregularity of the course of the vessels and anastomoses will be evaluated. Digital clips of the two baseline imaging modes will be acquired

The contrast administration will be an intravenous infusion of 2 vials of Definity/50ml saline through a peripheral vein with infusion rates of 4 to 10 ml/min (titrated to effect). Next, we will run a power optimization algorithm to establish the individualized acoustic parameter settings for the case (on the first imaging study only). We will use those parameters for all subsequent imaging studies to sweep the area of the LABC to acquire 3D, pulse inversion SHI grayscale volume data. The digital clips and RF data obtained from each 3D SHI injection will be transferred to a PC for off-line analysis. The SHI images will be qualitatively analyzed and compared to clinical outcomes. The relative changes in blood flow and IFP were scored (from -3 to 3 where 0 indicates baseline conditions). Results were grouped by complete (> 99% reduction in tumor volume) or partial treatment response and compared with Mann-Whitney tests.

5.2 Results and Discussion

In vivo animal experiments

Software has been developed and implemented on the Logiq 9 scanner to analyze RF data and produce SHAPE pressure estimates. Two (2) canines have been imaged with good results to provide *in vivo* proof-of-concept of the feasibility of implementing 3D SHAPE

on a commercial scanner. An example of the SHI images obtained in maximum intensity projection (MIP) mode (as part of the optimization algorithm) can be seen in Figure 1 for the left kidney. The corresponding curve showing the change in subharmonic amplitude as a function of acoustic power is shown in Figure 2. This effort represents the completion of task 2.




Figure 1. MIP subharmonic data with a renal ROI marked (in blue) over a contrast enhanced blood vessel.

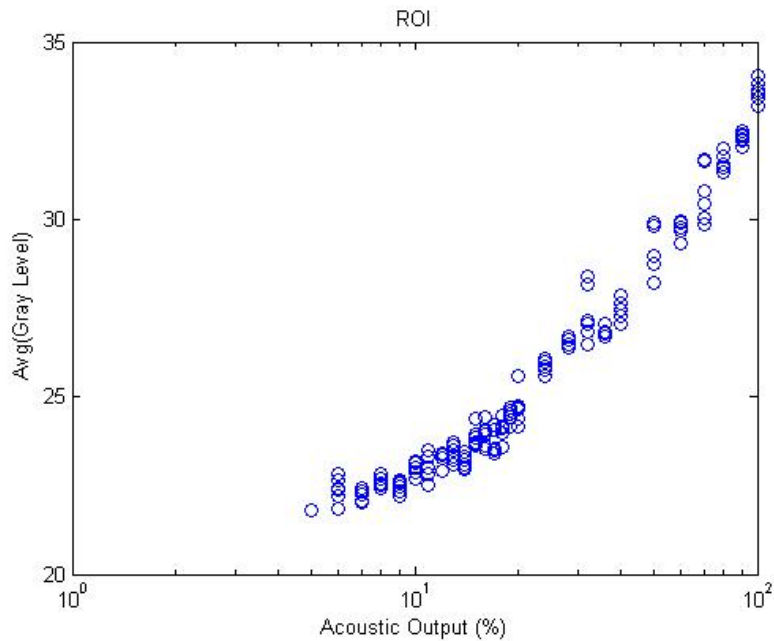


Figure 2. The subharmonic amplitude as a function of acoustic power from within the renal ROI marked in Figure 1. Five images were analyzed at each power setting.

In vivo human clinical trial

A total of 17 adult women have been enrolled in our pilot study, but 5 subjects withdrew after the baseline ultrasound scan (3 due to worsening of the underlying disease and 2 stopped treatment at Thomas Jefferson University altogether for unknown reasons). The study cohort included 5 African-American, 1 Asian and 11 Caucasian women. There were no Hispanics studied. Out of the remaining 12 subjects, 10 have completed all 4 3D SHI scans (i.e., they have finished the study), while 2 subjects have completed 3 out of 4 scans. Hence, we are awaiting the completion of the neoadjuvant chemotherapy regimen for the last 2 subjects in order to complete this pilot study. It is important to note that the follow-up data acquisitions performed after the completion of this BRCP award (i.e., after August 31st, 2015) were financed by internal departmental funds.

One minor adverse event did occur during this pilot study. A subject presented with difficult IV access and the decision was made to use the available vascular port for Definity infusion. While the port was patent when the subject concluded the ultrasound scan, the port was blocked when chemotherapy was to be initiated later that afternoon. Following flushing with Heparin the port opened up again and the subject's chemotherapy was delivered as scheduled. It was decided to never use a subject's vascular access port for ultrasound contrast agent infusion again. The subject stayed in the study and completed all subsequent ultrasound scans without problems and using regular IV access.

An example of the SHI images obtained for the first subject and converted into maximum intensity projection (MIP) mode (as part of the optimization algorithm) can be seen in Figure 3. The corresponding curve showing the change in subharmonic amplitude as a function of acoustic power is also shown in Figure 1 (bottom), and it can be seen that the steepest slope (i.e., the greatest SHAPE sensitivity) corresponds to an acoustic output power of 12 %. In Figure 4, the time course of the LABC treated to completion is presented. This lesion reduced in size from 2.82 x 2.22 cm to 1.04 x 0.98 cm over 15 weeks of treatment.

While the RF data processing of the studies completed to date (i.e., the IFP estimation) is still ongoing (as the complete data set has not been acquired yet), it is clear that marked subharmonic enhancement can be seen; even at the lower acoustic output powers associated with SHAPE (Figure 5). The Logiq 9 scanner used in this project displays the 3D SHI volumes in a 2 x 2 grid representing the 3D reconstruction (lower right) as well as three orthogonal planes (sagittal, transverse and coronal). In Figure 5, the contrast enhancement can clearly be seen in the transverse and coronal planes. Overall, 47 SHI/SHAPE studies have been performed. Volume acquisition rates ranged from 0.6-3.2 volumes/second. Preliminary clinical results to date indicate that 5 patients saw complete resolution of the primary mass, while 3 subjects achieved partial response only. Complete responders demonstrated greater vascularity at baseline and greater overall change in flow and IFP relative to partial responders; albeit not statistically significant ($p > 0.19$). Additionally, fully responding masses showed a trend towards significance for decreased tumor vascularity at 60% and completion compared to partial responders (p from 0.07 to 0.08). These efforts represent the near completion of task 3.

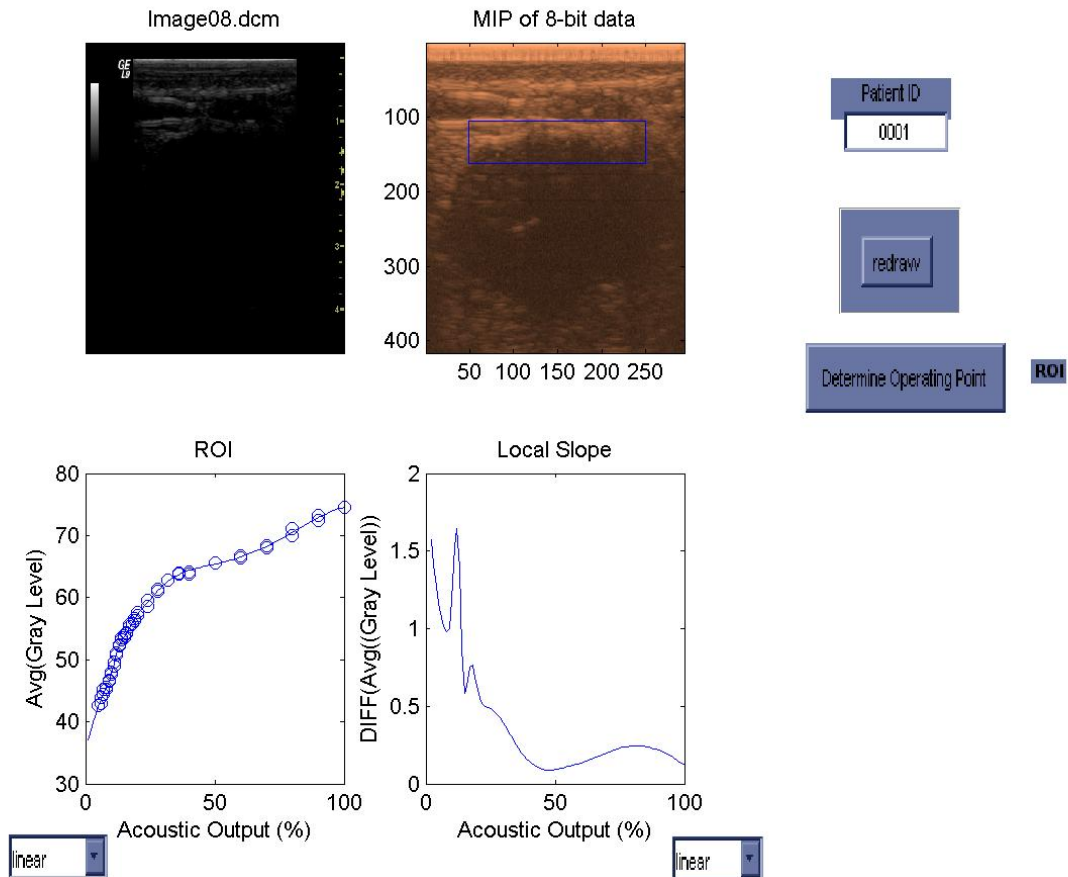


Figure 3. Subharmonic data from a human LABC (top left) with an ROI marked (in blue) over the anterior portion of the tumor showing contrast enhancement in MIP mode (top right). The average grayscale levels within the ROI and the local slope are also displayed (bottom) showing that 12 % acoustic output power is optimal for SHAPE in this subject.

6 KEY RESEARCH ACCOMPLISHMENTS

- The regulatory requirements for conducting this clinical trial are finally complete.
- Software for processing of *in vivo* 3D SHAPE data directly on the Logiq 9 scanner has been developed.
- SHAPE *in vivo* experiments were conducted in 2 canines with Definity using the Logiq 9 scanner and the 4D10L probe.
- The *in vivo* SHAPE pilot study for monitoring neoadjuvant chemotherapy with Definity using the Logiq 9 scanner and the 4D10L probe is almost finished.

- Seventeen patients have been enrolled (5 dropped out due to disease progression or withdrew from treatment altogether) and 2 are still awaiting completion (their last scan is outstanding).

7 REPORTABLE OUTCOMES

Publications

F. Forsberg. Subharmonic pressure measurements in human clinical trials. *J Ultrasound Med*, vol 33, pp. S45-S46, 2014.

F. Forsberg. Subharmonic imaging and pressure estimation: pre-clinical and clinical experiences. *Proc CCUM 2014*, pp. 1-10, 2014.

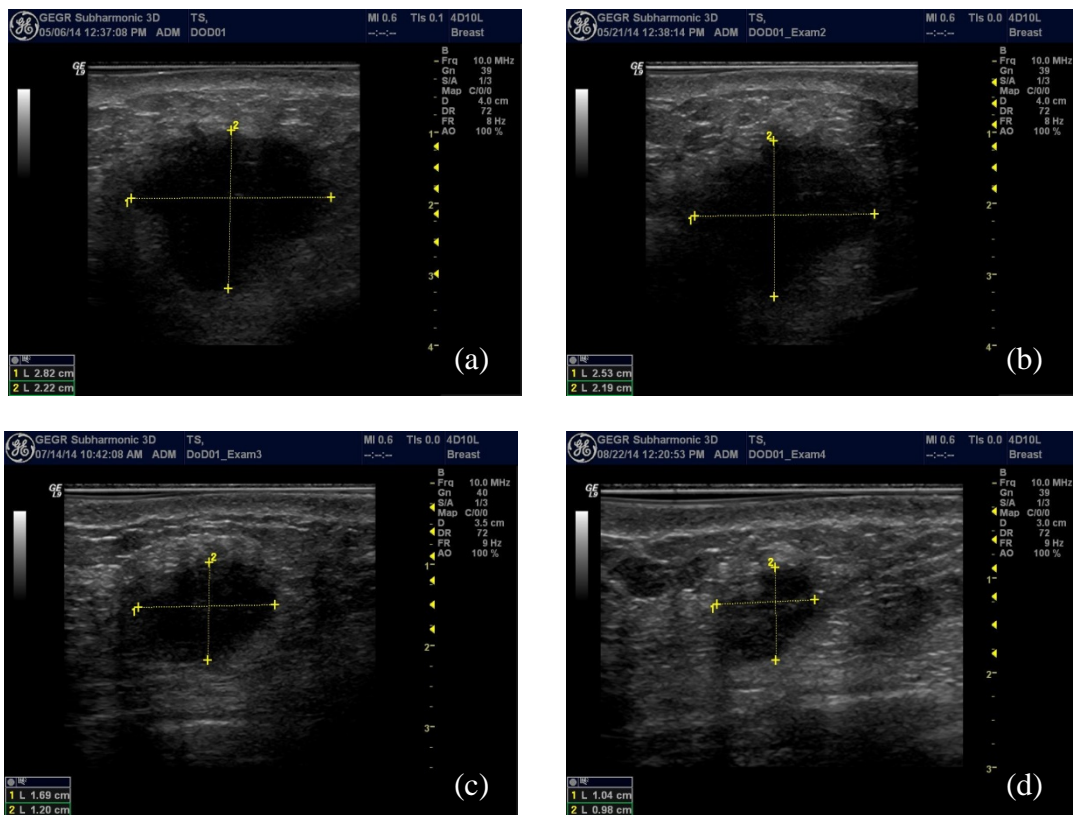


Figure 4. The size of the breast cancer in this subject is seen to shrink dramatically during the time of neoadjuvant chemotherapy (about 15 weeks). Pre scan (a), after 10 % of treatment was administered (b), after 60 % was administered (c) and after treatment completion (d).

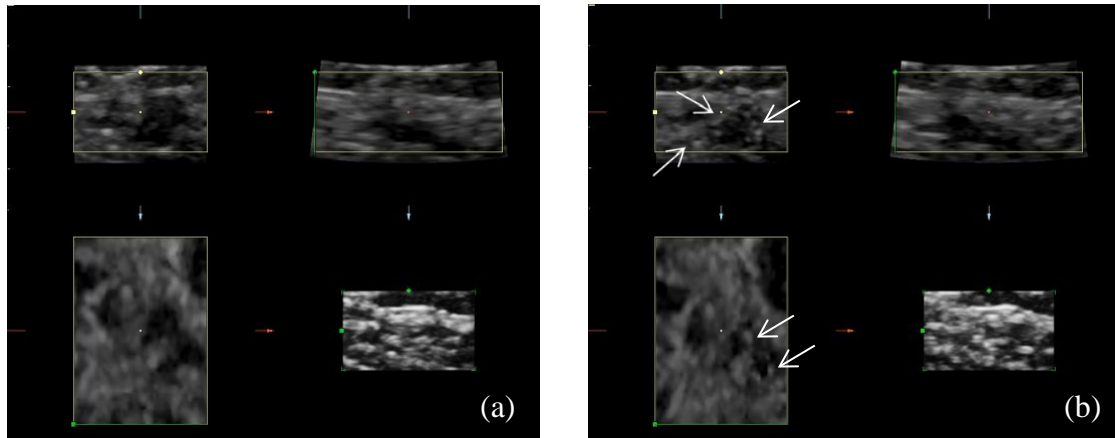


Figure 5. 4D SHI before (a) and after contrast administration (b), showing the 3D reconstruction (bottom right) as well as three orthogonal planes. Enhancement can clearly be seen in the transverse and coronal planes (arrows).

V. G. Halldorsdottir, A. Marshall, J. K. Dave, A. I. Forsberg, P. Machado, T. B. Fox, J. B. Liu, F. Forsberg. Subharmonic pressure estimation in breast tumors: an *in vivo* calibration study. *Ultrasound Med Biol*, vol. 41, no 4S, pp. S79-S80, 2015.

J. R. Eisenbrey, J. B. Liu, A. Sridharan, F. Forsberg. Contrast-enhanced subharmonic imaging. *Ultrasound Med Biol*, vol. 41, no 4S, pp. S93, 2015.

F. Forsberg, M. Stanczak, E. Hsu, A. Sridharan, A. C. Berger, T. Avery J. R. Eisenbrey. 4D subharmonic contrast imaging for monitoring neoadjuvant chemotherapy of breast cancer. Accepted for publication in *J Ultrasound Med*, 2016.

V. Halldorsdottir, J. K. Dave, A. Marshall, A. I. Forsberg, P. Machado, T. B. Fox, J. B. Liu, J. Eisenbrey, F. Forsberg. Subharmonic pressure estimation in breast tumors: calibration and treatment. Accepted for publication in *J Ultrasound Med*, 2016.

V. G. Halldorsdottir, J. K. Dave, J. R. Eisenbrey, P. Machado, H. J. Zhao, J. B. Liu, D. A. Merton, F. Forsberg. Subharmonic aided pressure estimation for monitoring interstitial fluid pressure in tumors: *in vitro* and *in vivo* proof of concept. *Ultrasonics*, vol. 54, no. 7, pp. 1938 – 1944, 2014.

J. R. Eisenbrey, A. Sridharan, J. B. Liu, F. Forsberg. Recent experiences and advances in contrast-enhanced subharmonic ultrasound. *Biomed Res Int*, vol. 2015, Article ID 640397, 6 pages, 2015.

A. Gupta, M. A. Forsberg, K. Dulin, S. Jaffe, J. K. Dave, V. G. Halldorsdottir, A. Marshall, A. I. Forsberg, J. Eisenbrey, P. Machado, T. B. Fox, J. B. Liu, F. Forsberg. Comparing quantitative immunohistochemical markers of angiogenesis to subharmonic contrast imaging. Accepted for publication in *J Ultrasound Med*, 2015.

Presentations

- May 21 – 23, 2012 The Leading Edge in Diagnostic Ultrasound, Atlantic City, NJ, USA.
• Monitoring neoadjuvant chemotherapy with subharmonic pressure estimates.
- October 3 – 4, 2013 28th Annual Advances in Contrast Ultrasound & ICUS Bubble Conference, Chicago, IL, USA.
• Monitoring interstitial fluid pressure in breast cancer with subharmonics.
- March 19, 2014 Biology of Breast Cancer program meeting, Kimmel Cancer Center, Thomas Jefferson University, Philadelphia, PA, USA.
• Ultrasound imaging in breast cancer research.
- March 29 - April 2, 2014 The 58th Annual Convention of the American Institute of Ultrasound in Medicine, Las Vegas, NV, USA.
• Subharmonic pressure measurements in human clinical trials.
- April 18-20, 2014 The 2014 Chinese Congress of Ultrasound in Medicion (CCUM), Beijing, P. R. China.
• Subharmonic imaging and pressure estimation: pre-clinical and clinical experiences.
- April 24 - 27, 2014 2014 Westlake International Forum on Ultrasound in Medicine and Biology, Hangzhou, P. R. China.
• Subharmonic imaging and pressure estimation: pre-clinical and clinical experiences.
- May 13 – 15, 2014 The Leading Edge in Diagnostic Ultrasound, Atlantic City, NJ, USA.
• Subharmonic pressure estimation for monitoring neoadjuvant chemotherapy.
- October 10, 2014 Department of Diagnostic Radiology, Yale University School of Medicine, New Haven, CT, USA.
• Subharmonic microbubble signals for ultrasound imaging and pressure estimation.
- November 5, 2014 Research Seminar Series, Department of Surgery, Thomas Jefferson University, Philadelphia, PA, USA.
• Ultrasound imaging from preclinical models to human clinical trials.

- | | |
|---------------------|---|
| March 21 - 25, 2015 | The 59 th Annual Convention of the American Institute of Ultrasound in Medicine, Orlando, FL, USA. <ul style="list-style-type: none"> • Quantitative pressure estimation with subharmonics. |
| April 20 – 22, 2015 | 44 th Annual Meeting of the Ultrasonic Industry Association, Washington DC, USA. <ul style="list-style-type: none"> • Quantitative subharmonic pressure estimation in vivo. |
| April 28 – 30, 2015 | The Leading Edge in Diagnostic Ultrasound, Atlantic City, NJ, USA. <ul style="list-style-type: none"> • A new biomarker for monitoring neoadjuvant chemotherapy of breast cancer. |
| September 19, 2015 | Sidney Kimmel Cancer Center Multidisciplinary Breast Care Symposium, Thomas Jefferson University, Philadelphia, PA, USA. <ul style="list-style-type: none"> • Ultrasound imaging in breast cancer research (poster). |
| November 23, 2015 | Drexel IEEE Graduate Forum, Drexel University, Philadelphia, PA, USA. <ul style="list-style-type: none"> • Quantitative subharmonic imaging and pressure estimation in vivo. |

8 CONCLUSIONS

The development and implementation of 3D SHI and SHAPE software on the Logiq 9 scanner has been completed. However, the efforts required to obtain approvals for both animal and human trials were markedly more cumbersome than envisaged in the original submission. Nonetheless, the necessary paperwork was completed after 16 months, but due to the delay caused by the efforts required to obtain regulatory approval for the animal and human clinical trials, the project is approximately 12 months behind schedule and we, therefore, requested - and were granted - a one year no cost extension. We started the human clinical trial in May of 2014. In the 16 months available for our pilot study, 17 subjects were enrolled (with 5 subsequently dropping out of the study for various reasons) and 2 of these are still awaiting their final SHI/SHAPE scan. In summary, tasks 1 and 2 have been completed, while task 3 is almost complete.

9 REFERENCES

1. Favret AM, et al., *Locally Advanced Breast Cancer: Is Surgery Necessary?* The Breast Journal, 2001. **7**(2): p. 131-137.
2. Kaufmann M, et al., *International Expert Panel on the Use of Primary (Preoperative) Systemic Treatment of Operable Breast Cancer: Review and Recommendations.* J Clin Oncol, 2003. **21**(13): p. 2600-2608.
3. Guarneri V, et al. *Primary systemic therapy for operable breast cancer: A review of clinical trials and perspectives.* Cancer Letters, 2007. **248**(2): p. 175-185.

4. Esteva, FJ, Hortobagyi GN, *Integration of Systemic Chemotherapy in the Management of Primary Breast Cancer*. *Oncologist*, 1998. **3**(5): p. 300-313.
5. Waljee JF, Newman LA, *Neoadjuvant Systemic Therapy and the Surgical Management of Breast Cancer*. *Surgical Clinics of North America*, 2007. **87**(2): p. 399-415.
6. McMasters KM, Hunt KK, *Neoadjuvant Chemotherapy, Locally Advanced Breast Cancer, and Quality of Life*. *J Clin Oncol*, 1999. **17**(2): p. 441-.
7. Mauri D., Pavlidis N, and Ioannidis JPA, *Neoadjuvant Versus Adjuvant Systemic Treatment in Breast Cancer: A Meta-Analysis*. *J. Natl. Cancer Inst.*, 2005. **97**(3): p. 188-194.
8. Heldin CH, et al., *High interstitial fluid pressure - an obstacle in cancer therapy*. *Nat Rev Cancer*, 2004. **4**(10): p. 806-13.
9. Less JR, et al., *Interstitial hypertension in human breast and colorectal tumors*. *Cancer Res*, 1992. **52**(22): p. 6371-4.
10. Taghian AG, et al., *Paclitaxel Decreases the Interstitial Fluid Pressure and Improves Oxygenation in Breast Cancers in Patients Treated With Neoadjuvant Chemotherapy: Clinical Implications*. *J Clin Oncol*, 2005. **23**(9): p. 1951-1961.
11. Milosevic M, et al., *Interstitial fluid pressure predicts survival in patients with cervix cancer independent of clinical prognostic factors and tumor oxygen measurements*. *Cancer Res*, 2001. **61**(17): p. 6400-5.
12. Goldberg BB, Liu JB, Forsberg F, *Ultrasound contrast agents: A review*. *Ultrasound in Medicine & Biology*, 1994. **20**(4): p. 319-333.
13. Shi WT, Forsberg F, et al., *Pressure dependence of subharmonic signals from contrast microbubbles*. *Ultrasound in Medicine & Biology*, 1999. **25**(2): p. 275-283.
14. Ishihara K, et al., *New Approach to Noninvasive Manometry Based on Pressure Dependent Resonant Shift of Elastic Microcapsules in Ultrasonic Frequency Characteristics* *Japanese Journal of Applied Physics*, 1988. **27**(Suppl. 27-1): p. 125-127.
15. Forsberg F, Shi WT, Goldberg BB, *Subharmonic imaging of contrast agents*. *Ultrasonics*, 2000. **38**(1-8): p. 93-98.
16. Dave JK, Halldorsdottir VG, Eisenbrey JR, Merton DA, Liu JB, Machado P, Zhao H, Park S, Dianis S, Chalek CL, Thomenius KE, Brown DB, Forsberg F. *On the implementation of an automated acoustic output optimization algorithm for subharmonic aided pressure estimation*. *Ultrasonics*, 2013. **53**(4): p. 880 – 888.

Appendix I

The Statement of Work from the original proposal:

Objective 1

Task 1: Design and implementation of SHAPE on a commercial US scanner (months 1 - 4)

- a. Optimize 3D SHI and SHAPE based on the parameters associated with the designated transducer; the 4D10L (month 1).
- b. Modify a state-of-the-art US imaging system (the Logiq 9) to perform 3D SHAPE (since the 3D SHI contrast imaging modality was already incorporated on this system as part of R01 CA140338; months 1 - 3).
- c. Evaluate the 3D SHI imaging modality and 3D SHAPE in an *in vitro* flow phantom using the modified US scanner (month 3).
- d. Prepare regulatory submissions for clinical studies and obtain institutional approval for animal studies (month 2 - 4).

Objective 2

Task 2: Optimize and calibrate *in vivo* 3D SHI and SHAPE in animals (months 4 – 5)

- a. Calibrate *in vivo* 3D SHAPE results based on pressure measurements obtained with a manometer-tipped pressure catheter (as the reference standard) in 3 mongrel dogs (months 4 - 5).
- b. Evaluate the ability of 3D SHI to depict macro- and micro-vascularity (the latter as a model for tumor angiogenesis) in the kidneys of 3 canines (months 4 - 5).

Objectives 3 - 4

Task 3: Conduct human clinical trial, data collection and analysis (months 5 - 24)

- a. Validate the clinical potential of 3D SHI as a tool to monitor neoadjuvant chemotherapy (i.e., the ability to track changes in tumor angiogenesis) in women with LABC by studying 20 – 50 subjects before as well as after the 1st, 3rd and last chemotherapy cycle and comparing results to MRI and pathology findings (months 5 - 23).
- b. Validate the clinical potential of 3D SHAPE as a tool to monitor neoadjuvant chemotherapy (i.e., the ability to track changes in IFP) in women with LABC by studying 20 – 50 subjects before as well as after the 1st, 3rd and last chemotherapy cycle and comparing results to MRI and pathology (months 5 - 23).
- c. Evaluate the ability of 3D SHI to depict LABC neovascularity in women compared to CD31 stained specimens (Months 5 - 23).
- d. Perform statistical analyses and write final report (months 23 - 24).