

UNCLASSIFIED

AD NUMBER
AD840894
NEW LIMITATION CHANGE
TO Approved for public release, distribution unlimited
FROM Distribution authorized to U.S. Gov't. agencies and their contractors; Administrative/Operational Use; 25 JUL 1967. Other requests shall be referred to Department of the Army, Fort Detrick, Frederick, MD.
AUTHORITY
SMUFD D/A ltr, 15 Feb 1972

THIS PAGE IS UNCLASSIFIED

AD840894

TRANSLATION NO. 1984

DATE: 25 July 1967

DDC AVAILABILITY NOTICE

Reproduction of this publication in whole or in part is prohibited. However, DDC is authorized to reproduce the publication for United States Government purposes.

STATEMENT #2 UNCLASSIFIED

This document is subject to special export controls and each transmittal to foreign governments or foreign nationals may be made only with prior approval of Dept. of Army, Fort Detrick, ATTN: Technical Release Branch/T10, Frederick, Maryland 21701

OCT 14 1968

DEPARTMENT OF THE ARMY
Fort Detrick
Frederick, Maryland

ANTIDOTE ACTION OF BIS-4-HYDROXYIMINOMETHYL-
PYRIDINIUM-(1)-METHYL7-ETHER DICHLORIDE IN RATS
POISONED BY ALKYLPHOSPHATE

Sonderdruck aus Arzneimittel-
Forschung (Drug Research)
Vol. 14, 1964, pages 85-88.

K. Bisa, G. Fischer, O. Mueller,
H. Oldiges and E. Zoon

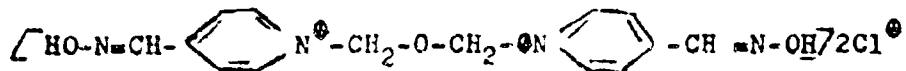
The action of organic phosphoric acid esters, used occasionally as insecticides, on animal life and acetylcholinesterase (ACHE) has been thoroughly investigated (1, 2, 3), in vitro. When ACHE is irreversibly blocked by alkylphosphates, stimulation of nerves leads to the accumulation of acetylcholine (ACH) and to a disturbance of the transmission of the impulse (1,4). It is assumed, the blocking of the ACHE is caused by a phosphorylation of its active center and the esterase activity is thereby eliminated (1,2,3,5).

Antidotes capable of restoring ACHE activity include Wilson's pyridine-2-aldoxime-N-methylolide (2-PAM) and N,N'-trimethylene-1,3-bis-(4-hydroxyiminomethyl-pyridinium)-bromide (TMB-4) (6,7,8,9,10,11).

The therapeutic effect of both oximes is considerably enhanced in combination with atropin (13,14).

A. Luettringhaus and I. Hagedorn synthesized a new antidote, bis-4-hydroxyiminomethyl-pyridinium-(1)-methyl7-ether dichloride (LueHb)*:

*We thank Prof. Luettringhaus, Freiburg im Breisgau, for supplying LueHb, which is now manufactured by E. Merck, Darmstadt, under the trade-name Foxogonin.



The antidote activity of LueH6 was tested in rats experimentally poisoned by 0,0'-dichloropropylfluorophosphate (DFP), 0,0'-diethyl-p-nitrophenylthiophosphate (Parathion) and 0,0'-diethyl-p-nitrophenylphosphate (Paraoxon). Tissues of detoxified organs were histologically examined. Additional tests included a paperchromatographic analysis of LueH6, *in vivo*, to determine its effect on AChE activity in serum, brain and liver of rats poisoned by alkylphosphates.

MATERIALS AND METHODS

The purity of the phosphoric acid esters, DFP, Parathion and Paraoxon, was tested by measuring the diffraction index and by infrared spectroscopy. If necessary, the preparation was further purified by vacuum distillation.

Alkylphosphate Solutions

A 2 ml solution was used for the injection. The dose was LD_{50} or a multiple of it, using a given alkylphosphate mixed with ethanol to 16%. The solution also contained 84% physiological saline when DFP was used or 84% of a 10% aqueous solution of Makrodex (a commercial dextran preparation) when the almost water-insoluble Parathion or Paraoxon was used.

Oxime Solutions

LueH6 or 2-PAM, used as a comparison, was injected as a 1 ml quantity of 0.33, 0.7 or 1.4% aqueous solution per rat.

Animal Experiments

In 362 separate experiments, 10 animals were used per experiment, a total of 3,620 female albino rats of approximately equal weight, but of different origins. The alkylphosphate was injected intraperitoneally. The antidote was administered the same way. In order to determine antidote activity, injections were made prophylactically (30 minutes before), simultaneously (immediately following the toxic injection) and therapeutically (5 minutes after the toxic injection).

Histology

Organs, examined histologically, were removed 24 hours after the start of the experiment. After sectioning, liver and kidney slices were placed into 4% formalin, lung slices into sublimate-formol-acetic acid and were fixed according to Stieve. Frozen sections, 6-8 micron thick, were stained with scarlet red, acc. to Herxheimer and with haematoxilin-eosine acc. to Bohmer. Lung sections, embedded in paraffin, were also stained with haematoxilin-eosine. The histological examinations, depending on the organ examined, are described under RESULTS.

Paperchromatographic Analysis of Esterase Activity

Rats were killed between 3 minutes and 26 hours after the intraperitoneal injection of DFP or Paraoxon. When LueH6 was tested, the oxime was injected prophylactically 30 minutes before the alkyphosphate injection. After killing the rat, the brain and liver were immediately removed and extracts prepared. Blood was sampled in vivo. Brain or liver were homogenized in 10 ml phosphate buffer, pH 6.2. The homogenates were sharply centrifuged and the resulting extracts were tested for acetylcholinesterase and cholinesterase, respectively. Serum was separated from the blood, diluted 1:5 with phosphate buffer, pH 6.2, and tested.

An assay consisted of 0.5 ml organ extract or serum and 0.5 ml of cholinester solution in phosphate buffer, pH6.2 (using 0.1 g acetylcholin chloride or benzoylcholin chloride in 10 ml buffer) as substrate solution. Controls consisted of acetylcholin chloride or benzoylcholin chloride without added enzyme solution, in order to determine autolysis of the cholinester. The mixtures were incubated at 37°C for 23 hours. At times t_0 and t_{23} , end products were analyzed paperchromatographically on Schleicher & Schuell paper 2043b, by spotting 0.01 ml and by developing one-dimensionally ascending, with n-butanol:ethanol:acetic acid:water 8:2:1:3.

The chromatogram was sprayed with a potassium bismuth iodide solution, according to Jatzkewitz (15). Cholin appears as a violet, acetylcholin and benzoylcholin as red spots. By comparing the extent and color intensity of the spot with known concentrations it was possible to estimate the degree of enzymic hydrolysis of the cholinester under the conditions used.

RESULTS

I. Results without using an antidote

a) Biological reactions after poisoning by DFP, Paraoxon and Parathion

Clinical Symptoms

When acutely toxic doses were injected, female albino rats showed toxic symptoms within a few minutes. Nervous disturbances appeared without indicating any damage to the central nervous system. Basically, three types could be distinguished:

1. muscarine-like activity
2. nicotine-like activity
3. central nervous system activity

Koelle (1) and Heath (2) published reviews on the known nervous disturbances and blocking effects. When toxic doses of the three alkylphosphates were given, the main toxic symptoms differed so little from each other, we decided to discuss them together.

The first toxic symptoms are fibrillar twitchings of the head region and extremities with a slight exophthalmus. Simultaneously, the frequency of breathing increases. The breathing passages become clogged because of increasing bronchial secretions and salivation. Dyspnea increases. Disturbed coordination, defecation and urination become noticeable. Particularly interesting is the appearance of "red tears" which are actually a secretion of Harder's glands. Cyanosis and edema of the extremities follow. The fibrillar twitchings of the head change to trismus. The prevailing convulsions become more intense and change to tonic-clonic cramps. Paresis of the extremities changes to paralysis. Inactivation of neck and back musculature leads to opisthotonus. The animals die under extreme prostration, fighting for a breath of air. The intensity, development and duration of the symptoms depend on the toxic effect of individual substances. Those animals which survive recover. At first, such animals show apathy and great weakness, a return to strong tonic-clonic cramps and seem to be deteriorating. Eventually, the paralysis of the extremities turns into paresis. The disturbed coordination disappears. Breathing becomes normal and salivation ceases. This process of recovery from acute poisoning goes through a certain series of events. The slowest recovery occurred after poisoning by DFP and Parathion. A faster recovery occurred after poisoning by Paraoxon.

b) Pharmacology of Parathion, DFP and Paraoxon

The following LD₅₀ dosages were established by intra-peritoneal injections of female albino rats, weighing 150-160 g:

Parathion	3.57	(+0.7) mg/kg
DFP	1.28	(±0.14) mg/kg
Paraoxon	0.93	(±0.14) mg/kg of body weight.

When these amounts were injected, all animals showed the above described symptoms. A lower dosage was tolerated by all animals, but they caused slight convulsions, fibrillar twitching and, occasionally, increased rate of breathing. When a lethal dose is given, single symptoms may be obscured because the extent of reactions differed between different regions of the body. Nervous reactions were completely disorganized. Death occurred sooner or later, depending how quickly a vital organ was put out of action. Consequently, the classical symptoms do not always appear in proper sequence.

c) Sectionings

Examination of animals killed 24 hours after acute poisoning indicated an increase in the volume and a partial increase in the flow of blood in the parenchymatous organs. The liver was frequently covered with macroscopic, light yellow or ochre-colored patches.

d) Pathological-histological examinations

After being damaged by Parathion, DFP and Paraoxon, the liver shows upon microscopic examination lipoidosis and varying visible structural changes of the cytoplasm, especially strong granulation and vacuole formation. Occasionally, the nuclei show alterations. Disse's space is enlarged. Paralysis and cessation of the lipolytic function of the liver cells leads to the accumulation of undigested fat eaten by the rat. Actually, we are dealing with a toxic fatty degeneration.

Kidney vessels in the substantia corticalis and medullaris are enlarged and filled with blood. The same is true of the capillary loops in the glomeruli which, often, fill completely Bowman's capsule. If the space of Bowman's capsule is not completely filled, it contains much serous exudate. Vacuolar degeneration with partial loss of epithelium appears in the protoplasm of the cylindrical cells. When the preparations were stained for fat, minute fat droplets were occasionally seen in the epithelium of the tubuli. Secretions appeared in the bronchial branches of the lungs. Respiratory bronchi were filled with blood.

II. Results after a single antidote

a) Pharmacological and clinical symptoms of LueH6

Given intraperitoneally, the dioxime LueH6 was tolerated by the female albino rats up to 140 mg/kg of body weight. Actually, the LD₅₀ was 215 mg/kg of body weight. This is a relatively high dose. LueH6 must be considered to be only "slightly toxic" by the international standards for poisons (16).

After 10 minutes, the LD₅₀ produced somnolence, which occurred also with lower doses. The drowsiness is accompanied by a reversible paralysis of the extremities. When higher doses were administered, there appeared after 15 minutes excited motor reflexes. Death occurred spontaneously because of respiratory failure. If a large dose of LueH6 did not kill the rat within 20-30 minutes, the surviving animals showed, at first, the excited phase which gradually decreased, then, a certain sleepiness.

When 500 mg of the standard antidote 2-PAM was given intravenously, together with atropin and artificial respiration, success was variable, but without any clinical side-effects (10). The literature was reviewed by Erdmann (17) who listed the applications of 2-PAM and its limited action when highly toxic doses of alkylphosphates were used.

b) Histological results after administration of LueH6

A single intraperitoneal injection of 150 mg of LueH6 per kg of body weight resulted in 100% survival. However, this dose frequently produced single, narrowly circumscribed diffused fatty infiltration in the liver, reversible in every case. The kidneys and lungs showed no pathological changes.

III. Results after several doses of antidote

The antidote activity of LueH6 was tested by injecting different doses into rats poisoned by Parathion, DFP and Para-oxon. The LueH6 doses were 25, 50 and 100 mg/kg of body weight. These concentrations were tested by intraperitoneal injection given prophylactically, simultaneously and therapeutically.

GRAPHIC NOT REPRODUCIBLE

Figure 1. Antidote Activity Range of LueH6 and 2-PAM

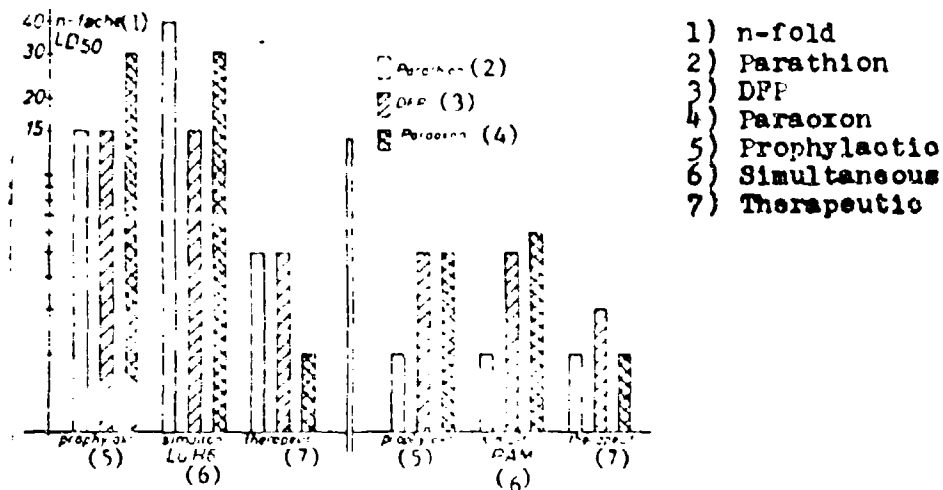


Figure 1 shows the prophylactic, simultaneous and therapeutic activity of LueH6 after poisoning by Parathion, DFP and Paraoxon, using doses up to the n-th LD₅₀. The figure also shows the comparatively weaker activity of 2-PAM. Some rats survived much higher doses, e.g. they withstood a 150-fold LD₅₀.

Clinical symptoms were minimized only when LueH6 was applied prophylactically or simultaneously when poisoning was produced by a 1-2-fold LD₅₀. Generally, there were no tonic-clonic cramps. The rate of breathing was increased. The clinical picture was dominated by fibrillar twitchings and convulsions. With higher concentrations of the poisons, the classical toxic symptoms appeared.

The activity spectrum of LueH6, especially its activity in protecting the parenchyma of liver and kidney, gave these results:

Parathion 3.57 mg/kg of body weight and LueH6 100 mg/kg, administered intraperitoneally, did not produce any significant histological-pathological changes.

LueH6 in combination with Paraoxon, 0.93 mg/kg of body weight also did not produce any pathological changes in the liver. The same was true for kidneys, except for a greater flow of blood.

When a 15-fold LD₅₀ of DFP was injected simultaneously with LueH6 between 50 and 100 mg/kg of body weight, the liver tissue contained minute fatty droplets. The kidney showed a stronger flow of blood in the vessels and in the epithelium of the urinary canal there existed narrowly circumscribed areas containing tiny fat droplets.

IV. Results of the paperchromatographic examination of cholinesterase activities

Acetylcholin was used as substrate for acetylcholin-esterase (acetylcholin-acetylhydrolase), while benzoylcholin (18) was used as a substrate for the characterization of nonspecific cholinesterase activity (acylcholin-acylhydrolase).

The results of the paperchromatographic analyses of cholinesterase activities of four rats per group are shown in Tables 1-5. In the tables, enzymic hydrolysis is evaluated by the following symbols:

- no hydrolysis
- (+) very weak hydrolysis
- + weak hydrolysis
- ++ medium hydrolysis
- +++ strong hydrolysis
- ++++ very strong hydrolysis of the substrate.

Table 1. Untreated rats: esterase activity

Substrate	Serum	Brain	Liver
Acetylcholin	++	++	++++
Benzoylcholin	++	-	++++

In Table 1, acetylcholin is compared with benzoylcholin as a substrate for the hydrolysis by preparations from the serum, brain and liver of untreated rats. As expected, on both substrates, the esterase activity in liver extracts was exceptionally high. It is interesting to note that pseudo-cholinesterase activity was practically absent in brain extracts. Benzoylcholin was split, but only in trace amounts.

Table 2. DFP (2 x LD₅₀ ip.): esterase activity

Substrate	Serum		Brain		Liver	
	3 min	30 min	3 min	30 min	3 min	30 min
Acetylcholin	-	-	(+)	-	+	+
Benzoylcholin	-	-	-	-	-	-

After injecting a two-fold LD₅₀ of DFP, ACH-esterase and Ch-esterase in serum were completely inhibited within the first three minutes. In the brain, only very weak ACH-esterase activity persisted. The liver, also, showed only very weak enzymic activity. After about 30 minutes after the injection of the brain was completely inhibited. The corresponding spots of ACH and BzCH on the chromatogram remained intact, i.e. not hydrolyzed by enzymes. When rats were injected prophylactically with 7 mg of LueH6 before the injection of the two-fold LD₅₀ of DFP (Table 3), ACHE in serum and liver was only partly inhibited. However, ACHE in the brain was completely inhibited. The esterase activity was very slow regenerated. Only three hours after the DFP injection was there a significant increase in Ch-esterase activity in serum, liver and brain. After six hours, normal esterase activity had been regained. At t₂₃, the spots of ACH and BzCH had disappeared from the chromatogram and a corresponding cholin spot had formed. This means, both cholin esters were completely degraded.

Table 3. DFP (2 x LD₅₀). intraperitoneal, prophylactically LueH6 7 mg ip.: esterase activity

Substrate	Serum				Brain				Liver			
	3min	1h	3h	6h	3min	1h	3h	6h	3min	1h	3h	6h
Acetylcholin	+	+	2+	2+	-	(+)	+	2+	+	2+	4+	4+
Benzoylcholin	-	-	+	2+	-	-	-	-	-	-	3+	4+

Table 4. DFP (5 x LD₅₀ ip.), prophyl. LueH6 7 mg ip.:
esterase activity (after hours)

Substrate	Serum					Brain					Liver				
	3min	1h	2	20	26	3min	1h	2	20	26	3min	1h	2	20	26
Acetylcholin	+	+	2+	2+	2+	-	+	+	+	2+	2+	2+	2+	3+	4+
Benzoylcholin	-	-	-	(+)	+	-	-	-	-	-	-	-	-	3+	4+

After injecting higher doses, e.g. DFP 5 x LD₅₀, and LueH6 prophylactically, a certain protective action by LueH6 was noticeable for ACH-esterase activity in serum, brain and liver (Table 4). Of course, the restoration of normal esterase activity in brain and liver was slower than when only 2 x LD₅₀ was used. In contrast to the specific ACH-esterase, the BzCH esterase of serum and liver was much more strongly inhibited by the poison, despite some protection by LueH6. Twenty hours after the DFP injection, only very weak BzCH hydrolysis had occurred. However, in the same time interval, the enzymic activity against BzCH in the liver was completely restored. It seems, the regeneration of esterase activity by means of LueH6 in DFP poisoning occurred optimally in the liver. After 26 hours, animals showed practically normal levels of esterase.

Table 5. Paraoxon (2 x LD₅₀ ip.), prophyl. LueH6 7 mg ip.:
esterase activity

Substrate	Serum		Brain		Liver	
	3 min	6 hr	3 min	6 hr	3 min	6 hr
Acetylcholin	++	++	++	++	+++	++++
Benzoylcholin	++	++	-	-	+++	++++

In Table 5 a comparison is presented of the two cholin-esterases upon poisoning by a two-fold LD₅₀ and a prophylactic injection of LueH6. This is a much more favorable result than that obtained in the case of DFP poisoning (see Table 3). Within three minutes after the injection of Paraoxon, enzymic activity against ACH and BzCH is hardly affected. Six hours after the Paraoxon injection, esterases remained at a normal

level of activity. The prophylactic injection of LueH6 in Paraoxon poisoning has a remarkably good protective action for ACh-esterase and Ch-esterase. This is in agreement with biological-pharmacological experiments.

DISCUSSION

The severe damage produced by alkylphosphate poisons presents a serious therapeutic problem. Thus far, therapy has been symptomatic for the irreversible biological reactions and has been unsatisfactory. Consequently, the synthesis and use of antidotes offered some promise. Briefly stated, the action of the antidote is directed towards the restoration of blocked enzymic reactions. The usefulness of the antidote is reflected by its mechanism of action and time factor.

Paperchromatographic analysis indicated a quasi-spontaneous inactivation of pseudo-cholinesterase (CHE) in serum and liver in the case of poisoning by DFP or Paraoxon. For practical purposes, the ACHE activity is completely inhibited in serum and brain only. In the liver tissue it is only partly inhibited. This is taken as proof of the presence of some other hydrolase in the liver extract. This enzyme is either weakly or not at all inhibited by the organic phosphoric acid esters tested.

It is interesting to note that when LueH6 was injected prophylactically, the activity of acetylcholinesterase was quicker restored than the enzymic activity against benzoylcholine, in all organs tested. ACHE activity was especially quickly restored in the serum and liver.

On the contrary, in the brain the reactivation of the enzyme activity was slower. This may have something to do with the penetration of LueH6 into the blood-brain space.

Auto-toxicity of LueH6 and of 2-PAM could be ignored in relation to their antidote action and in view of the severe toxic damage produced by the alkylphosphates. The ratio of the effective antidote dose to the LD_{50} was 1:6. Histological examination revealed that if a sufficiently large dose of LueH6 was used, no irreversible damage occurred in the organs of detoxification.

The complex of symptoms of alkylphosphate poisoning takes its classical course and is not prevented by the use of LueH6. However, regeneration of enzymic activity starts earlier and proceeds favorably. As expected, optimal activity was obtained when the antidote was injected in a sufficient amount at the time of poisoning.

SUMMARY

The antidote efficacy of bis-(4-hydroxyiminomethyl-pyridinium-(1)-methyl)-ether dichloride (LueH6, Toxogonin) against alkylphosphate poisoning in rats was tested in vivo and in vitro. Paperchromatic analyses indicated the restoration of cholinesterase activity in the brain, serum and liver when LueH6 was used prophylactically after the rats were poisoned by O,O'-diethyl-p-nitrophenylphosphate (Paraoxon) and O,O'-diisopropylfluorophosphate (DFP). The tolerance of LueH6 was 150 mg/kg of body weight. The LD₅₀ was 215 mg/kg of body weight. Effective antidote activity was obtained by using 1/6th of the lethal dose. Within the limits of tolerance, no irreversible histological changes were observed. The LD₅₀ of the alkylphosphates tested was for o,o'-diethyl-p-nitrophenylthiophosphate (Parathion) 3.57 ± 0.7 mg/kg, for DFP 1.28 ± 0.14 mg/kg and for Paraoxon 0.93 ± 0.14 mg/kg of body weight. When LueH6 was injected intraperitoneally before, during and after poisoning with alkylphosphates, the extent of the toxicity of the phosphoric acid esters was greatly reduced. Even a 5-fold to 40-fold LD₅₀ could be counteracted. In some rats, even a 150-fold LD₅₀ was tolerated. The parenchymatous damage, produced histologically by alkylphosphate poisoning, was also greatly diminished. The activity range of pyridine-2-aldoxime-N-methyl iodide (2-PAM), used until now, was much lower than that reported here for LueH6 and became ineffective when 2-fold to 6-fold LD₅₀ of alkylphosphates were injected.

BIBLIOGRAPHY

- 1) Koelle, B., Cholinesterases and Anticholinesterases Agents, (Handbuch der Experimentellen Pharmakologie, Ergänzungswerk 15. Bd.), Springer-Verlag Berlin/Göttingen/Heidelberg 1963.
- 2) Health, D. F., Organophosphorus Poisons, Pergamon Press 1962.
- 3) O'Brien, R. D., Toxic Phosphorus Esters, Academic Press, New York/London 1960.
- 4) Nachmansohn, P., Dtsch. Med. Wschr. 80, 196 (1955).
- 5) Augustinsson, K.-B., Arzneim-Forsch. 4, 242 (1954).
- 6) Kewitz, H., Arch. Biochem. and Biophys. 66, 263 (1957).

- 7) Kewitz, H. u. Nachmansohn, D., Arch. Biochem. and Biophys. 66.271 (1957).
- 8) Kewitz, H., Wilson, I. B. u. Nachmansohn, D., Arch. Biochem. and Biophys. 64. 456 (1956).
- 9) Wilson, I. B. u. Bergmann, F., J. Biol. Chem. 185, 479 (1950).
- 10) Wilson, I. B. u. Ginsburg, S., Biochem. et Biophys. Acta 18, 167 (1955).
- 11) Hobbiger, F., Brit. J. Pharmacol. 11, 295 (1956).
- 12) Hobbiger, F., Pitman, M. u. Sadler, P. W., Biochem. J. 75, 563 (1960).
- 13) Namba, J. u. Hiraki, K., J. Amer. med. Ass. 166, 1834 (1958).
- 14) Erdmann, W. D., Sakai, F. u. Scheler, P., Dtsch. med. Wschr. 1339 (1958).
- 15) Jatzkewitz, H., Hoppe Seyler's Z. physiol. Chem. 292, 94 (1953).
- 16) Handbook of Toxicology; Bd. I, Philadelphia/London 1956.
- 17) Erdmann, W. D., Dtsch. med. Wschr. 1014 (1960).
- 18) Augustinsson, K.-B., Acta Physiol. Scand. 15. (1948) Supp. 52.

Received 27 June 1963.

Dr. K. Biss o/o Fraunhofer Gesellschaft zur Foerderung der angewandten Forschung (Fraunhofer Society for the Advancement of Applied Research), 8 Munich 19, Roman Street 13.