

UNCLASSIFIED

AD NUMBER
AD840458
NEW LIMITATION CHANGE
TO Approved for public release, distribution unlimited
FROM Distribution authorized to U.S. Gov't. agencies and their contractors; Administrative/Operational Use; JAN 1967. Other requests shall be referred to Department of the Army, Fort Detrick, Attn: Technical Releases Branch/TID, Frederick, MD 21701.
AUTHORITY
SMUFD, d/a ltr, 15 Feb 1972

THIS PAGE IS UNCLASSIFIED

AD840458

CD ①

TRANSLATION NO. 1949

DATE: 18 Jan 1967

DDC AVAILABILITY NOTICE

Reproduction of this publication in whole or in part is prohibited. However, DDC is authorized to reproduce the publication for United States Government purposes.

DDC  
OCT 4 1963  
C

STATEMENT #2 UNCLASSIFIED

This document is subject to special export controls and each transmittal to foreign governments or foreign nationals may be made only with prior approval of Dept. of Army, Fort Detrick, ATTN: Technical Release Branch/TID, Frederick, Maryland 21701

79

**Best  
Available  
Copy**

## Q-FEVER PATHOLOGY IN ANIMALS

- Czechoslovakia -

Collection of Studies of the  
Faculty of Medicine of P. J.  
Safarik University in Kosice,  
Slovakia, Czechoslovakia,  
Vol. V, No. 3, 1962, pages 3-80

A. Rychlo, of the Scientific  
Laboratory at the Surgical  
Clinic of the Faculty of  
Medicine of P. J. Safarik  
University in Kosice,  
Director Professor J.  
Knazovicky, MD.

### PREFACE

This study is a summary of the results of more than four years of research activities concerning the problem of morphology and pathogenesis of Q fever. The results are presented in a consolidated form in such a way that the experimental data are the basis for the handling of current problems concerning the Q fever in man.

I was engaged in research concerning the Q fever in 1954-1959. I worked together with C. Sc. B. Pospisil, MD, chief of the Institute for Hygiene of this faculty. While Dr. Pospisil dealt with epidemiological-serological problems of Q fever, I concentrated on the problems of morphology and pathogenesis. The reason for this research on Q fever was that there are many aspects of the pathology of this disease which are not clear. The disease appears rather frequently within the territory of Czechoslovakia. The cooperation of an epidemiologist with a morphologist proved to be advantageous. Our joint work led to the solution of several important problems concerning infection by Q fever (54, 60, 61, 62). By using experimental animals we obtained valuable material which I am using in this study to a considerable extent. I am obligated to Dr. Pospisil for his kind consent to use the experimental material which we have collected together in the present publication. I also thank him for supplying me with tables which illustrate the results of serological reactions in experimental Q fever induced in a guinea pig.

A. Demkova, chief specialist physician of the Microbiological  
Department of the KUNZ [Krajsky ustav narodnihe zdravi -- Kraj National

Health Institute] in Kosice, handled all the necessary bacteriological examinations concerning the animals subjected to post-mortem examination. I wish to express here my thanks to Dr. Demkova.

In addition, I consider it as my pleasant duty to thank professor doctor of sciences A. Fingerland, MD, for his valuable advice and critical observations concerning certain partial themes which have been worked out in detail in this publication, and also for his reading of the manuscript.

Several laboratory assistants of the Institute for Hygiene, Institute for General Biology, and of this Scientific Laboratory took part in laboratory work which is a necessary part of histological examination of the material. These persons were as follows: laboratory assistant V. Sidorova, who processed most of the material used in necropsy and participated in the preparation of certain photographic illustrations, and laboratory assistants E. Vranayova, N. Spacilova, N. Sevcikova, and A. Nosalova, who completed several partial assignments in an exemplary fashion.

Kosice, March 1961.

#### INTRODUCTION

Q fever (Qh) is a disease which has been known since 1937 when Derrick (14, 15) was first to diagnose it correctly and classified it as a separate infectious disease in the group of the so-called "influenza ailments". It is a disease which is widespread in nature: Qh occurs in all parts of the world and affects in addition to the man a large number of domestic animals as well as animals living in the open nature. As to its biological dignity it is a benign disease. In spite of frequent epidemics caused by the disease, the infection rarely results in death.

The first publication dealing with Qh in the Czechoslovak Republic was written by Patočka and Kubelka (46). The study was published in 1953. The first clinical observations of Qh in Czechoslovakia which were verified by laboratory tests come from Kubasek (35). Kubasek's work was published in 1954.

Qh is considered generally as an old disease. Its origin is placed to the times before the creation of the present continents according to studies of macrobiological experts.

The cause of Qh — *Coxiella burnetii* — is a microorganism which has a great resistance: It is able to live for a long time in the infected material.

The ways by which the body is infected are the nose and throat (infection by inhalation), the digestive tract (most frequently infection by food — animal products originating from diseased animals, or infection brought to the mouth by soiled hands or objects). Also, it may be a wound in the skin or mucous membrane (transmission of the disease by vectors, particularly ticks).

Q fever affects man in various ways. Different locations of pathological changes and the changeable course of the disease make it possible to distinguish the following clinical forms of Q fever:

1. Pneumonic form — In this case we are dealing with Q fever when pneumonia is a major feature of the process of the disease. Pneumonia can manifest itself as follows:

a) One or more soft infiltrates which under X rays recall the specific process of tuberculosis. Physical findings are usually not indicated. The disease takes a light course and the recovery is relatively rapid.

b) Massive infiltration of one or several lobules of the lungs. There is similarity with extensive bronchial pneumonia or lobar pneumonia. From the clinical point of view it is a serious disease with a positive physical finding, heavy dyspnea, cyanosis, general toxic symptoms, followed in particular by a circulatory disturbance. The disease usually takes a protracted course. Resorption of the inflammatory infiltrate is slow.

c) Pseudomiliary form, otherwise also called "pseudomiliary tuberculosis". It is a rare form of Q fever characterized by a relatively benign course.

d) Pseudotumorous form, which consists basically of a massive pneumonic infiltrate located in the perihilum and of an enlargement of the corresponding lymphatic nodules at the hilum. It is a rare form, and its seriousness depends primarily on the extent to which the lungs are affected.

2. Pseudoinfluenza-type feverish form of Q fever — This form of Q fever occurs as a rule in epidemics and affects the population in endemic areas. The finding on the lungs is negative in this case. The disease differs from influenza by the fact that the feverish condition lasts longer and complications are more frequent, particularly with regard to the lungs.

3. Meningoencephalitic form — This is a relatively rare form of the ailment. It is usually observed in particularly serious cases when toxic phenomena are prevalent. This form as a rule is combined with the pneumonic form.

4. Icteric form — In this case the Q fever affects the liver. The ailment manifests itself in the form of jaundice, and according to its clinical manifestations it may imitate infectious virus hepatitis. The liver is usually enlarged and sensitive to pressure. In contrast to infectious hepatitis, we have not observed as yet the formation of yellow atrophy of the liver after Q fever-hepatitis.

5. In addition to the forms described above which display clinical features, Q fever also has nonapparent forms. Their significance is primarily epidemiological (Note\*: Note added during proofreading. — Recent studies indicate that there exists an additional sixth form, namely the endocarditic form of Q fever. See also on this subject the supplement on pages 22-23).

In the case of clinical forms of Q fever we should emphasize in particular the important fact that secondary bacterial infection is just as important as in the case of rickets and many other virus infections, in which — as we know — bacterial superinfection is very frequently the immediate cause of death.

Since the time when the Q fever was discovered by Derrick, a great deal of valuable information has been accumulated on the subject of this disease. Q fever attracted more and more attention of practicing physicians and scientific workers, particularly when it appeared that it is an epidemic disease which is wide-spread in the nature. At the present time, Q fever has become the central theme of research in the foremost scientific centers of the world. Epidemiologists who received most of the credit for the development of our knowledge of Q fever made great efforts to find the sources of the infection, to explain the way in which the infection is transmitted, etc. Together with natural scientists, epidemiologists made great efforts to study the biological characteristics of the cause of Q fever, they dealt with problems of its laboratory diagnosis, etc., etc. As to the survey of the present status of our knowledge of Q fever, we refer the reader to comprehensive reports on Q fever (4, 9, 13, 16, 26, 28, 31, 51, 52, 53, 57, 65, 75) and to the rich professional literature which deals with the problem both in foreign countries as well as in Czechoslovakia (17, 71).

When we evaluate the present status of our knowledge of Q fever, we can see that our knowledge of this disease did not develop evenly in every respect. While a great deal has been done so far in epidemiology and epidemiological research has made the greatest strides, we have done little in clinical and laboratory diagnostics and even less in pathomorphology.

There are several objective reasons why pathomorphology lagged behind epidemiology with regard to the problem of Q fever. In this article we shall try to enumerate at least the most important ones.

Q fever is a disease which we have known only for a relatively short period of time as an independent disease. Its diagnosis is not easy in early stages, particularly since the disease is complicated from the beginning by secondary bacterial infection which may mislead not only a clinical worker but also a pathologist. For example, bacterial bronchopneumonia or exacerbated chronic tuberculosis complicate Q fever and may erroneously give the impression that they are the basic ailment. This is the real reason why Q fever was diagnosed correctly only in isolated cases on the dissecting table.

In addition, the work of a pathologist is made more difficult because laboratory methods of examination and result in a lack of uniformity. We have in mind in addition to the isolation of the carrier of Q fever especially its color representation in histologic cross sections which until recently involved great difficulties.

As to the research concerning Q fever, its present organization includes in this work on the world level primarily microbiologists, entomologists, epidemiologists, hygienists, and clinical workers, both those dealing with human beings as well as veterinarians. Pathologists are used in this work only on special occasions and as a rule we not only do not attribute any significance to their participation in the handling of the problems, but unfortunately as a rule they do not participate in such work at all. Epidemiological research is carried out as a rule without the participation of a morphologist. However, it is often desirable to support documented examinations by pathological-anatomic findings. It happens sometimes that in certain cases the persons who make anatomic diagnoses are not pathologists. The result is that sometimes the described changes are evaluated erroneously.

What was said above indicates that under the present conditions it is an up-to-date problem to deal with the morphology of Q fever. A good pathomorphological knowledge is equally justified in this case as in the case of other diseases. Therefore it may not be necessary to discuss this problem in greater detail. What is more important is to answer the question as to what path we should follow in view of the present need for up-to-date morphological research of Q fever. It seems that under the given conditions of our knowledge of the morphology of Q fever, which is not very satisfactory, up-to-date morphological research concerning Q fever may consist only in determining the basic morphological manifestations of the disease, while we respect fully its dynamics. Our present study should contribute to solve this task. Its essence is an explanation of morphological changes which occur in the body of a macroorganism during the course of infection by Q fever. The working method is to experiment on a live animal, more specifically on a guinea pig which reacts to the infection in the same way as man. An evaluation of the results is based on an analysis of the findings involving the use of experimental material, because such material is used to explain findings in the area of human pathology which are available in world literature.

As to the long-range significance of the processing of the described theme, it seems to us that the knowledge of morphology will enable pathologists to diagnose Q fever more frequently and will enable experimental pathologists and clinical workers to understand correctly the functional changes and external manifestations of the disease. For that reason the knowledge of the morphology of Q fever may exercise an indirect influence on the choice of the medical treatment. If we know the possible after-effects of Q fever we can make a contribution at last to the evaluation of the significance of infection of man by Q fever.



## SURVEY OF LITERATURE

We classify the literature dealing with the problem of morphology and pathogenesis of Q fever in three groups in order to provide a clear view of the subject.

- a) Publications dealing with morphology of Q fever of man.
- b) Sources dealing with morphology of Q fever of animals.
- c) Studies dealing with other than morphological subjects, which nevertheless provide frequently valuable data on the morphology of Q fever, and other sources.

We present a special survey of each group.

Literary sources dealing with the subject were taken carefully from the Quarterly Cumulative Index Medicus (56), 1937-1956, the Current List of Medical Literature (10), pp 1937-1957, the Excerpta Medica, section V (18), pp 1951-1960, and from Czechoslovak as well as foreign professional literature which we studied carefully with regard to this problem in the last seven years.

### Publications Dealing with the Morphology of Q Fever of Man

Studies dealing with the morphology of Q fever of man are almost exclusively casuistic publications dealing with post-mortem findings in cases of Q fever. Since the discovery of Q fever by Derrick (14) in 1937 up to the present time the world literature registered only a few publications of this type. We present a review of such publications in this study (See also table 1 which contains a survey of clinical and anatomic findings of histologically confirmed cases of deaths of human beings due to Q fever).

1. The Annual Report of the Health and Medical Services of the State of Queensland (1a) of 1936-37 recorded the first case of death due to Q fever which was confirmed by a post-mortem examination. Unfortunately, pathological-anatomic findings are not confirmed in this case by histological examination.

It was the case of a 62 year old man who suffered for a long time from chronic pulmonary tuberculosis. The Q-fever infection did not affect his lungs and its presence was demonstrated by isolating the carrier from the blood of the patient. The blood sample was taken five days before the patient died.

During the post-mortem examination it was found that the patient suffered from extensive fibrous-antracotic and partly caseous tuberculosis of both lungs, together with an infection of the pulmotracheal lymphatic apparatus, lung emphysema in the form of deposits, and adhesive pleurisy. Bacemonia was not found during the post-mortem examination. The spleen

showed an inflammatory tumor, the liver showed venostasis of the first degree. The terminal sector of the small intestine was hyperemic with mucal-catarhal inflammation. No pathological changes were found in the other organs, if they could be detected microscopically.

It was not possible to make an analysis of the morphological findings because of a lack of histological examinations of pathological changes of the organs. The purpose of the publication was merely to register the deaths caused by Q fever within the territory of Queensland. The publication has fulfilled this goal.

2. We find a record of the second death caused by Q fever which was subjected to a post-mortem examination in the Annual Report of the Health and Medical Services of the State of Queensland of 1938-1939 (2). But even in this case there was no histological examination of the organs.

In the case of a 50-year old man who died of pneumonia the carrier of Q fever was isolated from his blood. During the post-mortem examination it was found that the deceased suffered from extensive inflammatory infiltration of both lungs and his right pleural cavity contained fluid.

The data on this case are even more modest than on the previous case. The entire report has 16 lines of the text. It is impossible to make a critical analysis of the case for the same reasons as in the previous case.

3. Lillie, Perrin and Armstrong (39) report in 1941 about a third case of death caused by Q fever which was recorded in literature. It was a death which was reported previously from the clinical point of view by Hornibrook and Nelson (30). Since it was a laboratory infection, the course of the disease was studied very carefully from the very beginning. In the study by Lillie and associates the microscopic findings are supported by histological examinations.

Because the original source (39) could not be obtained, we use comprehensive reports by Huebner and associates (31) and other studies which discuss the case (17, 19, 25, 43, 47, 73).

The case refers to a 59-year old man who suffered from universal atherosclerosis combined with degeneration of coronary arteries. Infection by Q fever occurred in a laboratory. Pneumonia of both sides of the lower lobes of the lungs, which was accentuated to the right, led to the patient's death within a week from the first symptoms of the disease.

On the dissecting table the finding on the lungs gave the impression of pneumococcal croup by the microscopic appearance. Histologically it was an interstitial inflammation combined with fibrinous cellular exudation to the transparent parts of the alveoli, alveolar passages, bronchi and bronchiola. The cellular elements which took part in the inflammatory process were lymphocytes, plasmatic cells, large

mononuclear cells, and also erythrocytes. The authors evaluated the enlarged soft spleen as an infectious tumor. The other organs did not show any particularly significant changes, if we disregard ordinary degenerative processes and circulatory disturbances which occur in almost all infectious diseases.

Whittick (73), who compares these findings with the findings of his own case, evaluates them as analogical to those which he described himself. We learn from Whittick's study that Lillie and associates did not succeed to prove the presence of coxiellae in histological sections.

In this particular case the diagnosis of Q fever was based on the proof on an infectious agent which was isolated by means of a biological experiment from the spleen of the deceased. Monkeys, mice, and guinea pigs were used for the isolation experiment.

4. Another case of death due to Q fever was reported in detail by Beneke (3) at the congress of the Society of West-German Pathologists in Karlsruhe in 1948. Beneke's contribution is based on a specifically histological examination.

Because the original source is not available (3), we are using in this case the comprehensive report by Bieling (4). Bieling does not mention the sex and age of the patient. Nor does he reproduce the records concerning the clinical course of the disease. However, he quotes almost literally the anatomic finding.

The cases involved serious Q-fever pneumonia on both sides of the lungs which affected almost the entire lungs. Streptococcal sepsis was responsible for the exitus. It complicated the basic ailment. According to Beneke's opinion, carrionic denture was most likely the origin of the sepsis.

The microscopic finding on the lungs corresponded to diffusion pneumonia on both sides, affecting both lower and central lobes (to the left of the lingula) and the paravertebral parts of the upper lobes. The pneumonia was accompanied by serofibrinous pleurisy on both sides. The microscopic aspect of the process in the lungs reminds us of croup pneumonia during the transition from the stage of red to gray hepatization. In contrast to true croupiness the affected texture did not seem brittle from the outside. Only in some places a finger penetrated in the parenchyma when pressed against it.

A histological examination revealed typical interstitial inflammation in the lungs. Coarse peribronchial, interalveolar and interlobular texture was circulated with edema and infiltrated diffusely by histocytes, lymphocytes, plasmatic cells, and a few granulocytes which were quite polymorphous. The alveolar and bronchial exudation consisted of edematous fluid and analogical cell elements as an infiltrate. However, in addition it contained peeled-off epithelial cells and phlegmatic

fibrous substance which did not lead to Weigert reaction to fibrin. Vacuolized macrophages appeared in large quantities both in the stroma as well as in the exudation in addition to the cellular elements described above. Giemsa coloring revealed the presence of cocco-bacterial embolus in several places. In addition, coccal microorganisms could be observed phagocytosed in the histiocytes of the stroma.

Typical sinus catarrh and infiltration of medullar ligaments by plasmatic cells were observed in pulmotracheal lymphatic nodules. The cells of sinus endothelia showed fattening in the form of fine drops. Germinating centers developed well in secondary lymphatic follicles of the skin, sometimes accompanied by fattening epitheloid cells which appeared in them.

The tests of the material did not include efforts to demonstrate the presence of coxiellae in histological sections.

Beneke evaluates critically the changes described above. He considers interstitial inflammation, which is characterized by lymphoplasmocellular infiltration as the basic morphological manifestation of Q fever, while he evaluates the presence of leucocytes as a manifestation of bacterial (streptococcal) superinfection. Beneke rightfully considers the finding in lymphatic nodules as a manifestation of a lymphogenic resorption process. There is no report on a laboratory proof of Q fever. In view of the importance of the reporting physician (Bieling), we can assume that isolation of the virus and its identification were not left out.

5. Gaell (25) reports on the fifth case of a post-mortem examination in his study dated in 1948. The histological material of this case of death due to Q fever which was recorded in documents was prepared by Uehlinger.

The Gaell's case referred to a 41-year old woman. She suffered from Q-fever pneumonia which was complicated from the fifth day of the ailment by acute deencephalitis. From the very beginning the ailment took a serious typhoidal course. Death occurred ten days from the beginning of the ailment.

Post-mortem examination (Uehlinger) revealed toxic encephalitis, edema, atypical pseudolobular pneumonia of the right central lobe of the lungs in the stage of gray-red hepatitis, edema, hypostasis and emphysema of the lungs, tumor of the spleen (140 gr), and dilatation of the right part of the heart. Additional findings of the post-mortem examination were chronic callous ulcer of the duodenum and cholelithiasis. The microscopic description of the affected central lobe of the right lung is identical with the description of crepous pneumonia. The pleura did not show any pathological changes which could be observed microscopically.

The histological finding, documented by microphotographs, indicates typical interstitial pneumonia. The finding does not refer to any appearance of large vacuolized cells. However, these can be observed clearly in the microphotographs.

Isolated minor points of bleeding were found in the brain and the perivascular areas were enlarged. In the area of the olivary bodies perivascular edema caused a compression of the veins. Neither inflammation infiltrates nor glial granulomata were found in any excision of the brain.

The histological material was not examined to determine the presence of coxiellae. The diagnosis of Q fever was based on the identification of the infecting agent which was isolated from the spleen of the diseased.

6. From the comment by Aufdermaur (25) on the Gsell's case we learn about a sixth case of post-mortem examination. It is the pathological analysis of a clinical study of a death caused by Q fever, which was prepared by Pulver and Fellmann (55).

A 59-year old man died of chronic Q-fever pneumonia. Clinically it was a heavy bilateral pneumonia. The finding in the lungs remained unchanged in spite of a decrease of temperature which was caused by specific anti-rickettsia treatment. A reaction of the combination of the complement with a specific antigen reached the titer of 1:2560 while the patient was still alive.

From the pathological-anatomic point of view it was a case of bilateral interstitial pneumonia. The nature of the inflammation process corresponded partly to a fresh and partly to a chronic intra-alveolar and interstitial inflammation. In the upper and central lobes of the lung the nature of the Q-fever pneumonia was the same as we know about it from other publications, with the difference that in this case the affected lungs contained enormous cells with multiple cores in addition to the usual description of cellular elements. In the lower lobes of the lungs the findings corresponded to chronic intra-alveolar and interstitial pneumonia. The alveolae were filled to a considerable extent by a fibrinous exudation in the stage of organization. Inter-alveolar and interlobular septa were infiltrated by lymphocyte and plasmatic cells. The participation of leucocytes in the inflammation process was also minimal in these parts of the lungs. In terms of deposits both lobes of the lungs were affected by several anemic infarcts which formed as a result of massive thrombemboli of the corresponding branches of the pulmonary cavity. The origin of emboli was thrombosis of femoral veins on both sides. Histological sections did not reveal either bacteria or Rickettsiae or Coxiellae (The author does not mention the color method which he used).

Aufdermaur attributes the transition of pneumonia into a chronic stage to inadequate participation of leucocytes in the Q-fever inflammation. Indeed, proteolytic fermentations which are released as a result of the decomposition of leucocytes dissolve fibrin which is excreted. However, the fermentations mentioned above were inadequate in this case, because leucocytes did not take part in the inflammation process to a sufficient degree. In the opinion of the author the fibrin exudation could not be dissolved and therefore was organized.

We must consider it as a shortcoming of the description of patho-histological changes that we do not find in it any data concerning vacuolized cellular elements which can be observed in the exudate of the inflammation on a microphotograph.

7. Brown, Knight, and Gellison (7) are the authors of the seventh case of death resulting from Q fever which was published (in 1948). Ferris (47) published specially the histopathology of the case in 1949.

Serious Q-fever pneumonia developed gradually in a 43-year old man. It resulted in death 15 days after the first symptoms of the disease. During the first days the ailment looked like influenza.

From the pathological-anatomic point of view it was a case of heavy pneumonia on both sides. The lungs were affected by the process of the sickness almost entirely. Only a small portion of the right upper lobe retained the air. The pleural cavity and the pericardial cavity contained an average amount of serous fluid. In the branch of the thorax in front of the lower lobe of the right lung there was a distorted thrombus which was eight cm long. The spleen was not enlarged, but it was soft and brittle. The kidneys showed irregularities in terms of excessive blood content but otherwise there was nothing unusual about them. Femoral veins showed thrombosis on both sides. An additional finding revealed atherosclerosis of the aorta and coronary veins, and a histological examination confirmed an old organized infarct in the area of the descending branch of the left coronary artery. The other organs did not reveal any striking morphological changes. Death was caused by heavy pneumonia on both sides and terminal thromboembolism of the left branch of the pleural cavity.

A histological examination revealed diffused interstitial pneumonia of the lungs. The entire stroma of the lungs, particularly inter-alveolar and interlobular septa were saturated with edema and infiltrated intensively with inflammation. The inflammatory infiltration contained mostly large mononuclear cells and plasmatic cells, to a lesser extent lymphocytes and very few leucocytes. The alveolae, alveolar passages, and small bronchia were filled with rich inflammatory exudate which consisted of cellular elements similar to the infiltrate. However, in addition the exudate also contained erythrocytes. The cellular elements of the exudate were deposited in a fine net of fibrin which was thick in some places and formed little conspicuous hyaloid membranes. In the capillaries of inter-alveolar septa hyaloid thrombi appeared in some places.

As to the large mononuclear cells, the author describes them but does not say anything about their classification. The few mononuclear cells which showed phagocytastic activities were classified by the author as macrophages, while the others which represent a majority remain without any more specific functional or histiogenic determination. The author describes them as elements with rich but scattered basophilic cytoplasm and a round or oval leptochromous or trachy chromous core.

The spleen contained red pulp infiltrated by plasmatic cells and a great number of large mononuclear cells.

A great quantity of large mononuclear cells, which were located in enlarged lymphatic sinuses, were found in the mesenteric lymphatic nodule.

In the bone marrow there were slight layers of cytoplasm of the marrow followed by subdued granulocytopenia.

The kidneys showed light arteriosclerosis, liver and suprarenal glands did not show any evidence of pathohistological changes. There was no proof of coxiellae in histological sections. The methods which were used were "Azuro-Eosin" according to the prescription by Lillie (38), and "Gram".

The author evaluates pneumonia and cytoplasm of the marrow of the bone as specific manifestations of Q fever, while he considers the other changes as nonspecific. He evaluates the changes in the lungs as analogical to the changes described by Lillie and associates (39) (See page 14 [of the original, 7 of the translation]). The author explains the exitus of the patient by the fact that he was a person suffering from a chronic disease of the veins (atherosclerosis) accompanied by changes of the myocardium (infarct) and claims that in two other cases accompanying diseases played an important role with regard to the fate of the patients. These accompanying diseases were in one case tuberculosis (case mentioned sub. 1) and in another case hypertrophy of the heart muscle with resulting enlargement of the mitral valve (case quoted sub. 3).

Perrin's publication describes in detail a case of Q fever resulting in death. The proof that it was a case of Q fever is based on isolation of the carrier from the blood of the diseased and its identification as *Coxiella burnetii* DERRICK.

8. Whittick (73) published in 1950 a case of death resulting from Q fever which we list in our publication as the eighth case. Whittick's publication is a pathological-anatomic study of a fatal case of Q fever. The clinical aspect of the case was reported by Harman (27).

A 78-year old man became sick from Q fever while hospitalized because of dysphagic difficulties. He died on the 11th day from the first symptoms of the disease.

The principal finding during the post-mortem examination was pneumonia which affected the entire upper lobe of the right lung. The microscopic finding resembled lobar pneumonia. The upper part of the lobe had a reddish color, the lower part was grayish. Small malatic deposits were found in the brain in basal ganglia and in the pons. The spleen was enlarged, soft, with increased red pulp. In the mediastinum of the right testis there was a light-brown discrete node three mm in diameter. A secondary finding was adhesive pleurisy on the right side with the resulting obliteration of the right pleural cavity. The other organs did not show any striking pathomorphological changes.

In the histological sections red and gray parts of the affected lungs showed differences as to the advance of the inflammation process. While in the red hepatized parts the inflammatory process was still developing, the gray areas corresponded to developed interstitial pneumonia. It was basically a case of hyperemia, edema, and inflammatory infiltration of the interstice with serous and cellular exudation to the transparent parts of the alveolae, alveolar passages, and small bronchia. Functional parenchyma was partly damaged as a result of degenerative-necrobiotic changes. Epithelial cells which were released from combinations were at the stage of necrobiosis. The composition of the inflammatory exudate corresponded exactly to the composition of the infiltrate: In the forefront there were large mononuclear macrophages, followed in terms of quantity by lymphocytes and plasmatic cells, while neutrophile leucocytes occurred very rarely in the exudate. As to erythrocytes, these were found in the exudate of those parts of the lungs where the inflammatory process was more advanced and the organ was damaged more severely. The coarsening of the walls of the alveolae was not caused only by hyperemia, edema, and inflammatory infiltration, but also by fresh proliferation of fibroblasts. In some places it was possible to observe necrosis and disappearance of inter-alveolar septa. No bacteria were discovered by using Gram coloring in the lungs.

Large mononuclear macrophages appeared in various forms. The current forms were large vacuolized cells with oval perforated c located on the periphery. The cytoplasm of other macrophages was finely granulated. Macrophages which were smallest in terms of volume had a relatively thick cytoplasm and their nuclei absorbed dyes well. All the forms of macrophages gave negative reaction to fats.

Coarsening of endothelial cells of veins with small thromboses and inflammatory proliferation of elements of neuroglia was found to be the cause of malatic processes in the brain.

In the spleen, numerous large mononuclear macrophages were found in large quantities in the red pulp. There was a smaller amount of lymphocytes and neutrophile leucocytes.

The nodule described in the testis corresponded in a microscopic picture to the group of a heavy concentration of large macrophages surrounded by fine capillaries and young fibroblasts. Thrombi were



found in nearby veins. The center of the nodule showed degenerative-necrotic changes.

In kidneys, the findings revealed in addition to overall parenchymatous degeneration deposits of infiltrates of round cells in the skin and ischemic fibrosis of certain glomerules.

The liver was not examined histologically. In the other organs (which were not enumerated) there were reportedly no substantial changes.

The author used successfully the Wolbach modification of the Giemsa method (74) to give color representation of the Coxiellae in histological sections. It was established that Coxiellae were present in large quantities in the lungs, spleen, testis, brain, and kidneys of the deceased, and they also occurred intracellularly and extracellularly. In the first three organs the Coxiellae were located mostly in the macrophages, in the brain they were located in elements of the neuroglia and in endothelial cells of the capillaries. There was a small number of Coxiellae in kidneys in the cells of tubular epithelium and in elements of intertubular texture.

The author compares his own findings with the findings of Lillie and associates (39) and Perrin (47) and evaluates them as being similar. With regard to Q-fever pneumonia he says that in a microscopic examination the disease resembles lobar pneumonia, while in the histological picture the findings are similar to psittacosis and other virus-type pneumonias. Whittick refers on this occasion to the study by Binford and Hauser (5) and uses the results obtained by these authors in their comparative study to evaluate his own case. Whittick's publication is the first publication which established the presence of Coxiellae in histological sections thanks to the use of correct coloring method. Changes observed in the spleen were evaluated by the author as changes of the "toxic" type corresponding to the findings of his predecessors. Whittick did not prepare documentation on cerebral complications and changes in the testes, even though their existence could be expected on the basis of clinical studies by Irons and Hooper (32) with regard to orchitis, and Wegmann (69) with regard to encephalitis.

9. Forconi and Curri (21) described in 1951 another case of death caused by Q fever. The anatomic findings are based on histological examinations. Since the original source is not accessible, we are quoting a literal translation of the report from Excerpta Medica, section V, 1952, No. 2292.

A 60-year old man died as a result of toxic infection which lasted 20 days. Complement-fixation reaction to Q fever was positive in his case in titration of 1:32. During the autopsy the only typical finding was pneumonia of the hemorrhagic-desquamative nature. A histological examination revealed typical infiltration of alveolar walls by mononuclear cellular elements. There were no significant changes in other organs (reported by Fraccare, Pavia).

10. Another casuistic publication dealing with death caused by Q fever is the study by Kuhn and Waag (36) of 1954. Since the publication is not accessible, we cannot report anything about it, not even whether a histological examination was made in that case.

11. In 1958 Ockur and Popova (45) published a short study which they entitled "Case of Protracted Course of Q Fever with Lethal Termination". Since this is obviously a case of diagnostic error, I mention the study only to make the bibliographic references complete.

A 57-year old man was hospitalized because of Q-fever pneumonia and was discharged after clinical recovery. On the 33rd day from the beginning of the disease he had a highly positive titration of specific complement-fixation antibodies for Q fever, namely 1:320. Since the fever reappeared repeatedly, the patient was admitted to a hospital several months later. At the time of repeated hospitalization, on the 180th day from the beginning of the original start of the ailment, the complement-fixation reaction to Q fever was completely negative. Death occurred as a result of cardiopulmonary insufficiency on the 202nd day from the original start of the disease.

Pathological-anatomic findings indicate that there was some sort of a latent infection of a morphologically nonspecific nature. During histological examinations of samples taken from organs no changes were found which could be described as characteristic of Q fever. The carrier of Q fever was not isolated from the pathological material. The negative result of the complement-fixation reaction at the time of repeated hospitalization indicates clearly that there was no Q fever. It should be noted that in chronic cases of Q fever the titrations of specific antibodies are particularly high.

12. At this time the latest casuistic publication dealing with death caused by Q fever is the study by Tonge and Derrick (67) of 1959.

It was the case of a 52-year old stockyard employee who survived an ulcerous disease and prior to the ailment he reported that he suffered from fever combined with jaundice. These feverish conditions always lasted several days and occurred three-four times a year. The patient was admitted to a hospital for treatment when he suddenly became sick. The sickness was accompanied by general symptoms of a fever, muscular aches, pains in joints, head, and dyspnoic difficulties. During hospitalization the patient suffered from lesion of the liver combined with jaundice and inflammation of the lungs. Two days before he died the patient was subjected to probational laparotomy. The patient died on the 17th day from the beginning of the sickness. His blood serum, which was sampled on the fifth and 11th days from the first symptoms of the disease, produced a negative reaction to Q fever. The serum which was collected on the day when exitus occurred (17th day of the sickness) gave a positive result to Q fever in titration 1:60. *Coxiella burnetii* was isolated from the urine which was collected three days before the patient died.

The main findings of the post-mortem examination were changes in the lungs and liver. The lungs showed diffusive inflammatory infiltration, they were strongly congested and were edematous. The liver was enlarged (it weighed 2296 g), moist, saturated, and icterically colored. Changes in other organs were as follows. The brain was icterically colored and was saturated with small petechial hemorrhages. The heart weighed 356 g, microscopically it appeared to be parenchymatously degenerated. The kidneys also showed microscopically symptoms of parenchymatous degeneration. The spleen (170 g) was soft, moist, saturated to the point of being "semi-liquid".

A microscopic examination revealed interstitial pneumonia in the lungs combined with phlegm-suppurative inflammation of terminal bronchia and bronchioles. The stroma of the lungs was infiltrated with mononuclear cells, polymorphonuclear numerous macrophages of the type of the so-called "heart failure cells", and plasmatic cells. Large macrophages are said to have been dispersed diffusely over the entire lungs. Hyaline membranes could be observed in some alveolae.

The liver showed diffusive degeneration to necrobiosis of the liver cells. In the stroma of the liver there were monocytes, plasmatic cells, lymphocytes, and polymorphonuclear leucocytes. There were no findings of proliferation of liver outlets or regeneration of liver cells.

There were no morphologically symptomatic changes in the brain. In addition to hemorrhages, in some places there were small perivascular granulations consisting of mononuclear cells of microglia, among which there were also erythrocytes.

In the kidneys there was interstitial nephritis which in the skin part was rather in the nature of deposits, but in the marrow it had a diffused form. Among cellular elements there are references to plasmatic cells, lymphocytes, and polymorphonuclear leucocytes.

With regard to the spleen, in addition to changes which form part of the picture of the usual infectious swelling, there are references to large mononuclear phagocytes which were present both in the white as well as in the red pulp.

The authors of the publication did not find any striking pathohistological changes in the thyroid gland, in the heart, in suprarenal glands, or in the pancreas.

The authors did not succeed to prove the presence of Coccidiae in histological sections "in spite of a careful examination", as they say in their study. The authors used the Giemsa method to prove the presence of Coccidiae. The authors do not state whether the method was adapted to the easier proof of Coccidiae (!).

Coxiellae were isolated in a biological experiment involving guinea pigs from liver, kidneys, and spleen.

The authors discuss the question of the relationship of Q fever to diseases of the liver. They exclude virus hepatitis and *Leptospira* hepatitis, but they lack a direct proof showing Q fever etiology. As to the evaluation of the repeated feverish attacks of the patient during the period prior to the formation of the subsequent ailment, the authors believe that they were some sort of disturbances of the digestive tract which may not have been related to the actual ailment.

The publication by Tonge and Derrick does not contain any illustrations.

#### Supplement Added During Proofreading

After the manuscript has been prepared for the print, several additional publications appeared dealing with death resulting from Q fever in human beings. We list them all as briefly as possible. These studies are important, especially since they discuss the possibility that endocardium may be affected by Q fever.

13. The study by Evans, Powell, and Burrell (17a) refers to a 60-year old engineer who became ill because of an "influenza infection". After three weeks of sickness the diagnosis was that he suffered from endocarditis. A complement-fixative reaction with a specific Q-fever antigen was positive at the beginning of the fourth week in titration of 1:32. The titer increased later on to 1:64. At the time when the patient died (five and half months from the beginning of the ailment), the titer decreased to the value of 1:8. A pathological-anatomic examination revealed ulcerous-verruucose endocarditis of semilunary valves of the aorta which took place on the basis of primary aortal sclerosis. When histological sections were made from the aortal valve and colored by the Macchiavelli method, the examination revealed the existence of microcolonies of small, intracytoplasmatically located microorganisms of the size of Coxiellae. An experiment of biological isolation was also made involving the use of guinea pigs. Coxiellae were cultivated from the aortal valve and from the spleen.

14. Robson and Shimmin (58a) described the case of a 47-year old geophysicist who died as a result of chronic endocarditis. At first the patient suffered from pneumonia (Q fever?) from which he recovered. After five months he became sick again. This time he suffered from endocarditis which resulted in death after a protracted course lasting 20 months. Andrews and Marmion (1) presented the pathological-anatomical and bacteriological analysis in a separate publication. The diagnosis of Q fever is based on an isolation of the carrier from a pathologically reduced aortal valve, from the lungs, and from the spleen, and on the positive complement-fixatory reaction with a specific antigen (positive titer up to 1:2000). The principal finding of the post-mortem examination

was a cicatricose endocarditis with vegetations on the aortal and mitral valve. Histological sections revealed under Giem's coloring microcolonies of microorganisms in the scarified valves. The microorganisms were of the size and shape of Coxiellae. They were found in groups and were frequently surrounded by a membrane in the form of a cellular membrane. However, cellular nuclei could not be observed. The authors state that they were under the impression the microcolonies of Coxiellae were located in some places inside of the cells. Str. Viridans was also cultivated from the aortal valve. We can conclude that it was a case of Q fever which affected the endocardium and the ailment was combined with endocarditis lenta.

15. Marmion, Higgins, Bridges, and Edwards (41a) describe the death of a 48-year old window cleaner who got pneumonia (Q-fever pneumonia?) from which he did not recover. The ailments of the patient ended after several months in endocarditis which led to death in the course of the following ten months. It took altogether 26 months from the formation of pneumonia to the exitus. The titer of the complement-binding antibodies against *C. burneti* reached the value of 1:256 in the patient. The post-mortem findings were similar to those in the case of the previous case. However, the process leading to endocarditis did not show any manifest activity. The carrier of Q fever was isolated from the scarified mitral valve which was removed during the post-mortem examination. The histological finding on the valves which showed pathological changes was also similar to the finding in the previous case. Microcolonies of microorganisms of the size of Coxiellae were found between the fibrils of the collagen and were not located inside of any cells. The authors admit that the Coxiellae may have been located originally inside of the cells. They may have become extracellular as a result of the destruction of the cells affected by the disease. The authors used Giem's coloring to prove the presence of Coxiellae in histological sections. In this particular case the Q-fever infection affected the valvular endocardium of the heart, and the infection was combined with subacute bacterial endocarditis.

#### Literary Sources Dealing With Morphology of Q Fever in Animals

A natural Q-fever infection usually does not result in a death in the case of animals. As a result the morphology of Q fever is not known better in veterinary medicine than in human medicine. However, studies based on experiments present valuable material.

The first pathomorphological findings of experimental Q fever in animals come from Burnet and Freeman (8) in 1937. At that time the carrier of Q fever was just discovered, and the authors give in their publication dealing with biological properties brief diagnostic conclusions concerning histological changes in the liver and the spleen of mice which have been infected experimentally. The observations of the authors were limited actually to the finding of characteristic vacuolized cells containing microcolonies of Coxiellae in the cytoplasm.

Lillie and associates (39) gave in 1941 a description of morphological changes accompanying experimental Q fever in monkeys. Their findings are generally in agreement with the findings of Q fever in man. However, in contrast to Q fever in man the authors observed granules of epitheloidal cells in monkeys. These granules were found in various organs. The authors do not give their opinion about the finding of granules (quoted according to Huebner and associates /31/). Critical notes on the Lillie's study (37) (See page 24 [of the original, 20 of the translation]) also apply partly to that publication.

Stoenner and associates (64) examined the morphology of experimental Q fever of horned cattle. The publication written by Stoenner and associates is not available in Czechoslovakia. For that reason we cannot analyze it critically.

Findlay (19) described microscopic and histological findings in the lungs of mice which have been infected intranasally by the carrier of Q fever. They compared their findings with the findings concerning a control group of animals which were infected in a similar way by the carrier of human and Negro spotted fever. The description of the morphology of Q-fever pneumonia, as given by the author, agrees fully with the description by Lillie and associates (39). Lillie and associates also describe the same changes in man and in a monkey which was infected experimentally. Findlay discusses the case in his publication. Findlay succeeded to prove the presence of Coxiellae only in large mononuclear cells which existed on the surface of the pleura, in alveolae of the lungs, and in the translucent parts of the bronchi.

The pneumonia of the control group of mice (which were infected by a carrier of spotted fever) provided roughly the same picture as the pneumonia caused by the carrier of Q fever. However, the lungs were affected more extensively and the degree of damage of the parenchyma which was affected by the inflammation was also more serious.

The author does not say anything about the details of the structure of large mononuclear cells in which parasites appear in the case of spotted fever -- in the same way as in the case of Q fever --, but he states that *Proxazek Rickettsia* do not attack exclusively this type of cells. For example in the case of pneumonia resulting from spotted fever it was established that *Rickettsia* were also present in leucocytes.

Perrin and Bengtson (48), who experimented independently from Findlay and also infected mice through the respiratory tract, did not get a perfect analogy with human Q fever. This was probably due primarily to proteins of outside origin which were mixed with the inoculating substance. Indeed, the authors used Coxiellae from the yolk of the egg to inoculate the culture. A proof that the described changes are not specific is the finding of granulomatose lesions which the authors observed both in the case of infected mice as well as in the control mice (which inhaled only the white of the egg which was sterile). The

4  
combination of specific and nonspecific findings confused the authors in their evaluation of the changes which they described. However, on the basis of a critical analysis of the documented material we can conclude that the nature of the morphological changes agree in essence with the findings obtained from human pathology. The authors describe the inflammation caused by the carrier of Q fever, and in addition to the lymphocytes and plasmatic cells they also mention large mononuclear phagocytes in which the authors managed to prove the presence of Coxiellae.

Several animals were infected intraperitoneally. In these cases the lungs were intact, while the spleen and other organs of the abdominal cavity showed changes which were similar to those in the group of mice which have been infected aerogenically.

Lillie (37) described pathohistological changes in the body of guinea pigs after intraperitoneal infection by the carrier of Q fever. In about half of the cases the lungs were affected by stratified pneumonia. In addition to this basic affection there appeared occasionally granuloma with enormous cells in various organs of the guinea pigs. These have not been observed before in human cases, but morphologically they were identical with the granuloma which the same author discovered in experimental Q fever of monkeys (39). Lillie considers the described granuloma with giant cells as a manifestation of infection by Q fever. However, his view is not supported either microbiologically (by reverse cultivation) or histologically (by a proof of the presence of the carrier in histological sections). The author describes organic changes globally with regard to all the animals. On the basis of such documentation we cannot determine whether nodular lesions with giant cells occurred in all the animals or only in a certain group.

On the basis of our own experience with experimental Q fever in guinea pigs, we believe that the granuloma described by Lillie were of an origin other than Q fever (they may have been caused even by tuberculosis). However, changes caused by the carrier of Q fever were not absent in this case. Their presence was confirmed by the "large polygonal epitheloidal cells", as the author calls the cellular elements which represent a constant component of pneumonia caused by Q fever.

The combination of tuberculous pneumonia with Q-fever pneumonia gives the impression that this process is characteristic. It is not easy to diagnose the infection correctly, particularly when the tuberculous pneumonia is relatively recent. This view is based on our own experience of several years with experimental Q fever in guinea pigs. Indeed, during the experiments we also found the same coincidence. We must admit that for more than a year we did not diagnose it correctly.

It is impossible to evaluate reliably the degenerative-atrophic processes which Lillie describes, or the stratified pneumonic infiltrates in various organs which are little characteristic, if we admit coincidence of such a serious ailment as tuberculosis. The presence of Coxiellae was not proved in histological sections.

Serov (63) described in 1952 pathological-anatomic changes in experimental Q fever in guinea pigs. We were not able to submit the study to a critical analysis, because the source was not available.

Another publication dealing with morphology of experimental Q fever in guinea pigs is the study by Germer (22), who examined histologically the organs of guinea pigs after intraperitoneal infection. The findings by Germer give the characteristics of the morphology of Q fever and agree with the findings in connection with lethal cases of Q fever in man. The difference is in the location of the pathological changes. While changes in lungs are predominant in man, in guinea pigs the major feature of the pathological-anatomic picture after intraperitoneal infection was changes in the spleen and other organs of the abdominal cavity. Lungs were affected only in some cases. However, the extent and intensity of the changes never reached the level of those found in man. On the basis of the material obtained from guinea pigs Germer qualifies the morphological manifestations of Q fever as a histiogenic cellular reaction to antigenic exudation with particularly accentuated participation of reticular cells. The tumor of the spleen, which in the case of intraperitoneal inoculation was the most conspicuous manifestation of infection by Q fever, was evaluated by the author as the result of proliferation of reticular-endothelial elements. The pneumonic leucocytic infiltrate in the spleen according to the author is not the answer of the microorganism to the antigenic irritation by the carrier of Q fever, but it is an answer to the regressive processes in elements of RES. Since the RES elements react to the presence of Coxiellae by regressive changes only at the beginning of the disease, the pneumonic leucocytic infiltrate also appears only during the initial stages of infection by Q fever. Later on, when the RES elements do not necrotize anymore to the antigenic irritation on the part of the Coxiellae, but on the contrary proliferate, the leucocytes disappear from the pneumonic infiltrate. We reproduce in detail the explanation of the significance of leucocytes in pneumonia caused by Q fever, because it is an original explanation which is well documented and is a contribution to an understanding of the manifestations of infection by Q fever.

According to the concept formulated by the author, the author sees proliferative pneumonic reaction in the large mononuclear cells of histiogenic origin which were found in the spleen, liver, and sometimes in the lungs. We cannot agree with this explanation entirely, as it will become apparent from our own observations.

The shortcoming of Germer's study is that it does not establish the presence of the carrier of Q fever in histological sections.

In 1955 Vasileva and associates (68) published their study on pathohistological experimental Q fever in guinea pigs which has been infected subcutaneously, intraperitoneally, and intratesticularly. In this publication we encounter for the first time the term "granular inflammations", which the authors used when referring to pneumonia



caused by the carrier of Q fever. They talk about it on the occasion of their description of changes in the subcutaneous tissue at the point of injection (after subcutaneous inoculation) and in the testes (after intratesticular inoculation). The authors do not give a description of the granular tissue, but they talk about inflammatory elements which infiltrate the granular tissue. In addition to leucocytes and lymphocytes they are primarily histiocytes and macrophages, in which Coxiellae appear in large numbers at the peak of infection. The authors do not describe the histiocytes and macrophages. The changes in the testes after intratesticular infection can be qualified on the basis of the description as productive interstitial orchitis, which after the cure results in atrophy and sclerosis of the organ. The authors do not mention the lungs, nor do they say anything about whether they found any changes at all in the lungs. The findings in the spleen and lymphatic nodules are analogical to the findings by Gormer (See pages 25-26 [of the original, 21 of the translation]). The study by Vasileva and associates does not contain any documentary photo material.

#### Literary Sources With Occasional Data on the Morphology of Q Fever and Other Sources

Herzberg and associates (29) studied in detail the proliferation of the carrier of Q fever in the testis of a guinea pig after intratesticular inoculation. The authors used the method of impressed preparations in their examinations. However, in each case they also made supplementary histological examinations (the author of the histological findings is Bienengraber). We want to refer briefly to these findings. The inflammatory process in the testis was characterized by the presence of numerous large vacuolized cells located in the stroma, by intensive lymphoplasmocellular infiltration of the stroma, and by regressive changes in the embryonic epithelium of the little winding canals. Coxiellae, the presence of which was demonstrated in histological sections, appeared during the initial stages in fixed reticular cells and in wandering histiocytic phagocytes. During the multiplication of Coxiellae in the cytoplasm of the attacked cells intracytoplasmatic vacuoles were formed as a result of the activities of the Coxiellae. The vacuoles kept increasing in volume and pushed the nucleus to the periphery until finally they burst. The Coxiellae which were located in the cell penetrated in the process in extracellular areas, from which they entered new mezenchymal elements. Since the cells in which the Coxiellae multiplied were released from the combinations, the author comes to the conclusion that the Coxiellae multiply in the wandering mezenchymal cells, namely histiocytes. In view of the fact that Coxiellae were found also in fixed mezenchymal elements, about which the same author talks in another place, we must correct his statement in the sense that the attacked mezenchymal cells are not necessarily wandering cells at the time when the Coxiellae attack them. However, the fixed cells in which the Coxiellae multiply continuously can be released from their combinations in the course of time and may become wandering cells.

DeMottia and associates (12) deal in their study with organotropism and elimination of *Coxiella burnetii*. Noury (44) studied the distribution of *Coxiellae* in the body of diseased animals. Unfortunately, none of these two studies is available in Czechoslovakia. We did not succeed to get the studies from foreign countries. We mention these publications merely to make the bibliography complete. Indeed, in this study we shall touch on the problem of organotropism of *Coxiella burnetii*.

In order to understand the problems of the morphology of Q fever, it may be purposeful to refer to one important clinical observation described by Blanc, Bruneau, Poitrot, and Delage (6). These authors used artificial Q-fever infection as a pyrotherapeutic means to treat mental patients. They infected the patients in various ways and then used different doses of inoculations.

After intradermal inoculation of a live culture of *Coxiella burnetii* some patients suffered from fever which lasted a maximum of two days and did not affect the lungs. Many of the patients did not react at all to this method of infection by revealing any increased temperature. At the place of inoculation there appeared in all cases an infiltrate which healed completely and spontaneously within two-three days.

After an intramuscular infection the patients had a fever lasting three-five days after two days of incubation and withstood the disease rather well. At the place of inoculation there appeared a local inflammatory reaction which lasted more than a week. If a larger dose or a more concentrated emulsion was used for intramuscular inoculation, the fever lasted 12 days, was frequently biphasic, but in no case was there any affection of the lungs.

After intranasal inoculation with one drop of virulent suspension under narcosis (after an electric shock), three out of six patients became sick, in each case suffering from a pneumonic form of Q fever. The sickness lasted several days to two weeks.

After intrapulmonary inoculation with aerosol, it was not only the inoculated patients who became sick (two of them), but also the experimentators (in spite of the fact that they used masks) as well as two assistants who did not wear masks. They are contracted a pulmonary form of Q fever. The disease culminated on the 15-20th day from the infection, the infiltrates disappeared on the 40-50th day. In one case the disease also affected the pleura, and in one case X rays revealed a decomposition.

Blanc and associates came to the conclusion on the basis of their own observations that the clinical picture of Q fever depends directly on the quantity of the inoculated substance and on the method by which the substance is introduced in the organism. Q-fever pneumonia is induced only through respiratory infection, while the benign course

following an intradermal inoculation by a large culture opened the way to an effective and at the same time a safe method of vaccination against Q fever.

Ponseca and associates (20) also tested the peroral method of infection on mental patients. In this case Q fever did not have any clinical manifestations, and only in the case of two out of 12 infected persons antibodies were found after a certain period of time at the titer of 1:20. On the basis of this observation it appears that peroral infection may be secondary in Q fever of man. However, experience obtained from epidemiological practice does not indicate that entirely. Even though infection through the digestive tract is not as important as infection through inhalation, nevertheless it may lead to organic changes which may be anatomically important.

Clinical studies by Wendt (70), Ludwig (40, 41), Giroud and associates (23b), Korting (34) discuss some less frequent forms of Q fever. The study of Moeschlin and associates (42) deals with complications caused by Q fever from the clinical viewpoint.

Gerstl and associates (23) demonstrated the presence of inflammatory infiltrates in the stroma of the liver of man in materials obtained from diagnostic punctures of liver in the case of icteric forms of Q fever. Numerous histiocytes appeared in the infiltrates in addition to elements of round cells. Gerstl and associates did not attempt to prove the presence of Coxiellae in histological sections (quoted from the study by Westi /72/).

## OUR OWN EXPERIMENTAL MATERIAL

### Working Method

The survey of literature summarized in the preceding chapter shows that several authors dealt with the morphology of experimental Q-fever infection of a guinea pig (Burnet and Freeman /8/, Germer /22/, Lillie /37/, Scavo /63/, Vaesileva and associates /68/, and partly also Herzberg and associates /29/). These authors used intraperitoneal, subcutaneous, or some other parenteral infection. There is no description in available sources of pathomorphological changes after infection of the respiratory tract.

When we studied the morphology of experimental Q fever of a guinea pig, we found that the way of infection is of a decisive significance for the pathology and clinical aspects of this disease. Indeed, in a guinea pig only intranasal infection leads to the formation of manifest Q-fever pneumonia which — as we found out — represents the analogy of the most serious form of Q fever of man, namely the pectoral form. The lungs are affected only in exceptional cases when the infection takes place in another way. In positive cases the extent and intensity of changes in the lungs never reach the same dimensions as after infection of the upper respiratory organs.

When we introduce an inoculation by an other way than through inhalation, the result as a rule is the formation of apneumonic forms of Q fever.

In view of these facts we concentrated our attention above all on studies of the pectoral form of experimental Q fever in a guinea pig. That is why the groups of guinea pigs infected intranasally is the largest group in our material. True, it was difficult to characterize exactly certain important morphological changes in the case of Q fever, specifically the Q-fever inflammation, when the infection was located exclusively in the lungs. Other groups of animals helped to solve this as well as other problems. We are referring to animals which have been infected intratesticularly, intramuscularly, and subcutaneously.

Because of external reasons over which the author of this study had no control, it was not possible to complete the material by using a group of animals infected through the digestive tract. Two guinea pigs infected through the digestive tract at a time when we have outlined the plan of our study represent a much too modest material, and therefore we could not use it in this publication.

Our own experimental material is as follows:

- a) 24 guinea pigs infected intranasally,

- b) 12 guinea pigs infected intratesticularly,
- c) 12 guinea pigs infected intraperitoneally,
- d) 10 guinea pigs infected intramuscularly, and
- e) 8 guinea pigs infected subcutaneously.

Total 66 guinea pigs

The pathological process was studied in its full dynamic expansion only with regard to the first group of animals. That is why that group also includes the largest number of animals. The guinea pigs of that group were killed in gradual intervals of time. In the other four groups the purpose of the morphological examination was to determine the type of pathological reaction of the microorganism according to the method of infection. For that reason the animals of these four groups were killed almost exclusively at the time when the disease reached the peak of intensity. The criterion which was used to determine when the infection culminated was the temperature curve and overall condition of the animals (overstrain, tremor, dyspnoeal breathing, rejection of food, etc.). The animals which survived the disease were killed, so that we could find out what morphological changes the Q fever left in them.

We used only healthy guinea pigs for the experiment. In most cases the guinea pigs were males. Their weight varied from 400 to 600 g. Several days before the experiment and during the experiment the animals were kept separately in large glass containers. They received normal mixed food consisting of vegetables. During the experiment we took rectal temperatures of each animal twice a day. The animals were weighed every third day.

We used for the inoculum 0.5 ccm of 10-20% suspension from testes of guinea pigs in a physiological solution. They were used, vessels of guinea pigs infected intratesticularly by the carrier of Q fever and killed at the peak of the disease, i.e. seven-eight days after the infection. The inoculum was always examined in terms of bacteriological sterility by inoculating samples in two broths of liver. The stock of *Coxiella burnetii* (Derrick, 49) which we used was the so-called "Henslerling" stock which was isolated by Robbins and associates (58) in 1946 from one case of death caused by Q fever in Italy. The name of the stock comes from the name of the deceased.

The guinea pigs were inoculated by means of a tuberculin syringe. In case of parenteral infection a given amount of inoculum was simply injected in the given case (intraperitoneally, intramuscularly in the gluteal muscle, subcutaneously in the thigh, and in the case of intratesticular infection the inoculum was injected in both testicles). In the case of intranasal infection we had to narcotize the animals first. Then under narcosis we placed drops of the inoculum alternately in both nasal apertures. Narcotized animals inhaled in the inoculum without resistance.

There are 24 guinea pigs in the experiment which were infected intranasally. Two of them died spontaneously (one on the tenth day, the

second on the 14th day after the infection). Both cases were subjected to a complete histological examination. The other guinea pigs were killed by ether in the following time intervals after the infection: six animals on the sixth day (of which four were subjected to a complete histological examination), four animals on the eighth day (two subjected to complete histological examination), two animals on the ninth day (one subjected to histological examination), two animals on the 11th day (one subjected to histological examination), two animals on the 56th day (one subjected to histological examination), two animals on the 73rd day (one subjected to histological examination), four animals on the 182nd day (two subjected to histological examination).

There are 12 animals in the experiment which have been infected intratesticularly. One of them died spontaneously (on the 32nd day after the infection), the others were killed by ether in the following time intervals after the infection: on the seventh day one, on the eighth day two, on the ninth day two, on the tenth day two, and on the 12th day one. All the animals were subjected to a complete histological examination.

Out of 12 animals which had been infected intraperitoneally, five died spontaneously (one on the 11th day after the infection, two on the 12th day, one on the 13th day, and one on the 22nd day). The others were killed in the following time intervals after the infection: on the third day one, on the sixth day two, on the eighth day two, on the ninth day one, and on the 11th day one. All the animals were subjected to a complete histological examination.

Ten animals were infected intramuscularly. Two of them died spontaneously: one on the 13th day, the second on the 36th day after the infection. The other animals were killed in the following time intervals after the infection: on the sixth day two, on the eighth day two, on the ninth day two, on the tenth day two, and on the 12th day one. All the animals were subjected to a complete histological examination.

Out of eight guinea pigs which were infected subcutaneously three died spontaneously (one died on the sixth day and two on the 14th day after the infection). The others were killed by ether: one on the sixth day, two on the eighth day, one on the 12th day, and one on the 37th day after the infection. All the animals were subjected to a complete histological examination.

The animals were killed under a bell in which we inserted cotton saturated thoroughly with ether.

The animals were dissected in a sterilized box, as a rule within two hours after the killing. In the case of guinea pigs which died spontaneously the dissection was carried out next day in the morning. We protected ourselves against infection by observing scrupulously the principles proposed for work with *Rickettsiae* and tested in practice by

Sutorisova and Dubny (66). In the case of guinea pigs which were infected intranasally we collected as a standard procedure the following material for histological examination during the post-mortem examination: excisions from all lobes of the lungs, from tracheobronchial lymphatic ganglia, from the rear wall of the myocardium, from the spleen, liver, pancreas, intestine (in the area of the Bauhini's valve), from the left kidney and suprarenal gland, from the testis, from the bone marrow of the proximal epiphysis of the femoral bone, and from the brain (the brain was examined histologically only in the frontal section which was made through the basal ganglia). In the case of guinea pigs which were infected parenterally, we collected in addition excisions from the place of injection and from regional lymphatic ganglia. However, when the findings in the lungs were negative, we limited the histological examination of these animals to one and maximum two excisions. In the overwhelming majority of the animals we collected as a standard procedure material for bacteriological examination, the purpose of which was to demonstrate bacteriological sterility of the samples as far as secondary bacterial flora is concerned. For purposes of control we collected from some animals samples for the purpose of attempting to isolate the carrier.

The histological material designed for further processing in a refrigeration microtome was fixed and deposited in formol (The purpose of it was to prove the presence of fat and to bring about oxydase reaction). All the other material was fixed in Kelly's solution and covered with paraffin.

We used color methods for the coloring of hemalauneosin and three trioxhematein-picrofuchsin according to van Gieson. We used an original method designed by the author to prove the presence of Coxiellae in histological sections (59).

The method involves fixation of the material in Helly's solution and use Giemsa dyes for color representation of Coxiellae. The dye must be diluted by a buffer solution before it is used. The preparation is covered with excess color (We let the dye act for 16-20 hours) and is subjected to a dual differentiation: The preparation is differentiated first of all in the buffer solution and then a strongly diluted citric acid.

The fat was represented in scarlet color. The oxydase reaction were carried out according to Gräff. On occasions we used color methods as follows: coloring of reticulin fibers according to Lillie, coloring the mucus by thionine and mucicarmine, coloring of elastin according to Weigert, coloring of bacteria in histological sections according to the Gram principle, etc. When we processed the bones we used the method of rapid decalcification which was designed by the author in cooperation with Flank (50).

# GRAPHIC NOT REPRODUCIBLE

## Findings in the Case of Guinea Pigs Infected Intranasally

### a) Records of the Course of the Disease

We registered the first symptoms of the disease only on the fourth day of the infection, when the temperature began to rise. The guinea pigs ceased to accept the usual amount of food, were covering, their fur was bristly, and they crouched against the walls of the glass container. In

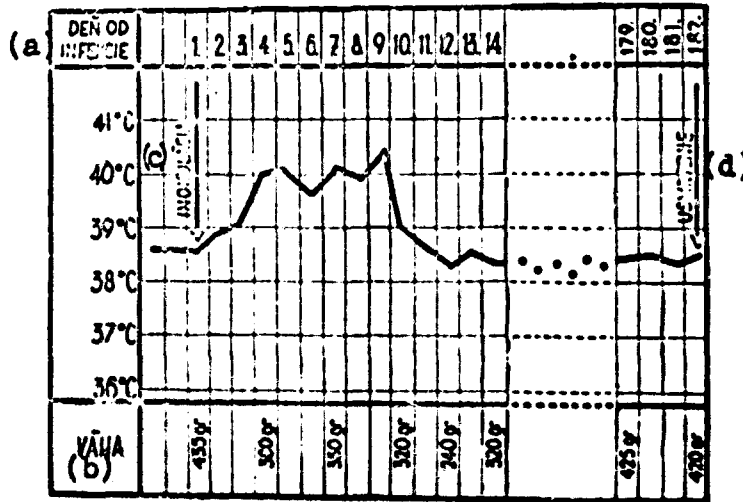


Table 2. Rectal temperature and body weight of a guinea pig infected intranasally, which survived the infection. Key to table 2: a — Number of days after infection, b — weight, c — inoculation, d — putting to death.

the following days they showed high fever, they began to breathe faster and with difficulties. The clinical culmination of the disease was recorded on the seventh-eighth day after the infection. From the ninth day the temperature started to decrease and the condition of the animals gradually became normal. When the infection terminated in death, the overall physical difficulties continued until the animal died (i.e. until the tenth or 14th day). Death was preceded as a rule by a lytic decrease of temperature which lasted a short time. The temperature during the infection is illustrated by two temperature curves: one represents the temperature of a guinea pig which survived the infection (table 2), the other represents the temperature of a guinea pig which succumbed to the infection (table 3). About two weeks after the infection the animals showed clear symptoms of recovery. They became alert again and started to accept food as usual. Three weeks after the infection the guinea pigs gave the impression of being healthy.



## b) Microscopic Findings During Dissection

At the peak of the disease, i.e. on the eighth day after the infection, we found during the post-mortem examination in all cases that the lungs were affected in the form of sediments, the hilar and lymphatic ganglia were enlarged, there was dilatation and hypertrophy of the heart, mostly on the right side, the size of the spleen had doubled, and there were dystrophic changes in the large parenchyma. The testes were as a rule slightly atrophic. In the case of guinea pigs which exited spontaneously the findings described above were also accompanied by symptoms of serious heart inadequacy.

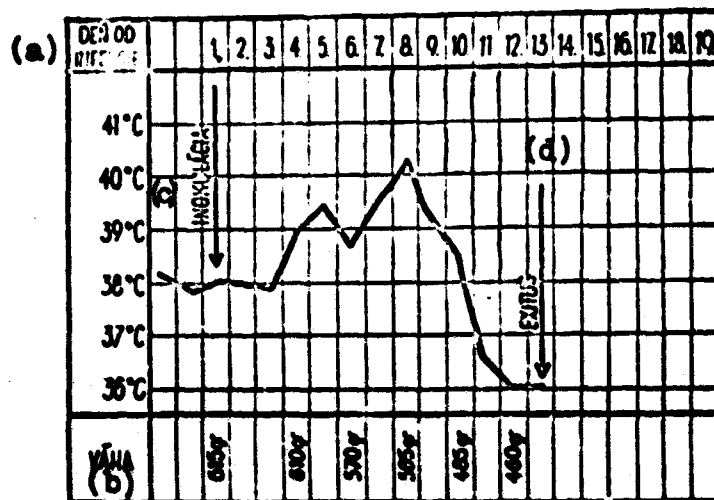


Table 3. Rectal temperature and body weight of a guinea pig infected intranasally which succumbed to the infection. Key to table 3: a - Number of days after infection, b - weight, c - inoculation, d - exitus.

During convalescence there was gradual morphological restitution. The animals which were killed and dissected two or more months after the infection did not show any changes which could be observed microscopically.

### Description of Organs of the Pectoral Cavity

At the peak of the disease changes in the lungs were the outstanding features of the pathological findings. Pneumonic layers of the size of several lung lobules were localized in the proximity of the bronchi and their ramifications. We could observe frequently infiltrates which were located perihelially. They were connected per continuitatem with the layers which were located subpleurally. In cases of average seriousness about one-third of the lungs was affected by pneumonia. In the case of guinea pigs which succumbed to the infection the pneumonia affected a predominant portion of the lungs. The color of the pneumonia

infiltrates was blue-red, and they had a fine granulated structure. When we observed carefully these changes under a magnifying glass, we could see how the affected tissue was covered with a fine blue texture. The air portions of the lungs were compensationally emphysematous. Emphysematous vesicles were located in close proximity of the lung infiltrates or in peripheral portions of the infiltrates themselves. As a result the boundary lines of the pneumonic layers were not sharp. The bronchi did not show any changes which could be determined microscopically. However, peribronchial stroma of the tissue was coarser in the areas of pneumonic infiltrates. When the lungs were subjected to pressure, a small amount of foamy blue fluid poured out of the lungs.

The area below the thorax did not show any striking features. Tracheobronchial lymphatic ganglia were enlarged, but their anatomic structure remained unchanged. The heart was enlarged 1.5-2 times (in lethal cases as much as 3 times). The cavities of the right side of the heart in particular were enlarged. The elasticity of slightly hypertrophic muscles was reduced. In lethal cases the consistency of the myocardium was almost tattered. The color of the muscles was brown-red with a shade of blue, in lethal cases it had a yellowish shade.

#### **Description of Organs of the Abdominal Cavity**

At the peak of the disease the spleen was enlarged 1.5-2 times, its color was dark red at the point of dissection. Malpighi's bodies in the section were always clearly prominent above the level of the hyperplastic red pulp. The liver and the suprarenal glands were more voluminous, their congestion was increased. The structure of the organs was anatomic, the color was slightly yellowish in some places. The testes were somewhat reduced, but their structure was intact. The intestines and the suprarenal glands did not show any striking abnormalities.

#### **Description of Organs of the Cranial Cavity**

The crane and the brain membranes did not show any changes which could be detected microscopically.

#### **Bone Marrow of the Proximal Epiphysis of the Femora**

The microscopic findings were always within normal limits.

#### **c) Pathohistological Findings**

Lungs (figures 1 - 9 /Note\*: All the figures are in the enclosure at the end of the study, after page 80/). In the histological picture the process which took place in the lungs corresponded to acute interstitial pneumonia characterized by the presence of a large number of histiocytic cellular elements which occurred in the infiltrate as well as in the exudate (figures 1 and 2). These were primarily histocytes of three types:

1. Cellular elements of the size of macrophages with oval normochromous nucleus located centrally or excentrically and with thin and slightly basophilic cytoplasm. 2. Histiocytes, which were larger in comparison to the previous group and in addition they were characterized by the presence of fine vacuoles in their cytoplasm. Small cytoplasmatic vacuoles gave the morphological characteristics of these cells. They were elements which are usually described in pathohistology as foamy cells (the so-called "Schaumzellen" of the German authors). 3. Large histiocytes of round shapes with the nucleus pushed to the periphery. The nucleus usually showed regressive changes. The cytoplasm of these cells contained one or more large vacuoles. Histiocytes of various shapes and sizes gave a negative reaction to fat and mucus. The inflammatory infiltrate which penetrated evenly into the stroma of the affected portions of the lungs, was not particularly intensive even at the peak of the disease. It consisted of lymphocytes and plasmatic cells, while leucocytes were present in it only on some occasions. Leucocytes appeared in large quantities at the beginning of the disease or when the peak had passed, in the period of resolution. The inflammatory exudate which filled the alveolae and alveolar passages included a modest amount of a serous and in some places serofibrinous fluid which contained large amounts of peeled-off cells of the alveolar epithelium in the stage of necrobiosis (These cells gave a positive reaction to fat). Inflammatory infiltrates in the form of round cells occurred perivascularly in hepatized as well as air-filled portions of the lungs. Bronchi and bronchioles showed in most cases only a light catarrhal inflammation without any striking desquamation of epithelial cells. On occasions there was also acute endobronchitis which led to obliteration of the affected bronchus and consequently to atelectasis of the corresponding parts of the lungs. During the period when the inflammatory process subsided, hyaline membranes appeared in the lungs in the border portions of pneumonic infiltrates (figure 6).

Vicarious emphysema of the lungs was formed and developed together with pneumonia. It affected those portions of the parenchym of the lungs which were in the periferal part of the infiltrates and their immediate neighborhood (figure 7). The largest vesicles were found inside of the lungs between individual pneumonic layers. The extent and intensity of the emphysema were directly proportional to the extent of the pneumonia. In severe cases which took a lethal course, the entire aeriad parenchym of the lungs was compensationally emphysematous when pneumonia affected most of the lungs.

When pneumonia subsided and the inflammatory exudate was resorbed, in no case was there restitution in the lungs of the guinea pigs as far as emphysema was concerned. Within two, three, and six months after the infection we could demonstrate the presence of layers of substantial emphysema in the lungs. The emphysema affected approximately  $1/4 - 1/3$  of the parenchym and was localized in periferal parts of the lobules of the lungs directly below the pleura or inside of the lungs (figure 8). The extent and location of the emphysema were similar to those as

in the case of animals killed at the peak of the disease. However, in this case the emphysematous vesicles were slightly smaller. The layers of substantial emphysema were not lacking even in the area of the atelectases of the lungs which were formed as a result of obliterating endobronchitis which was observed on some occasions (figure 9).

Collagenic fibers showed only slight deviations from normal conditions during the disease. At the peak of the disease the collagenic fibers were poorly visible due to the edematous saturation of the stroma, and they were more substantial when the disease receded. However, they did not multiply. The compartments between emphysematous vesicles contained a large quantity of collagenic fibers. This is due to the origin of the compartments which — as we mentioned before — are to a great extent derivatives of interlobular septa of the tissue. In post-pneumonic atelectases, in which the parenchyma atrophied and disappeared, collagenic fibers became more conspicuous. It seems that even in this case their multiplication was only relative.

Tracheobronchial lymphatic ganglion (figures 10 - 13). — Inflammatory hyperplasia was characterized by swellings of the endothelia of the sinuses or cells of the reticulum, by multiplication of elements consisting of round cells, and by the appearance of large vacuolized cells. Vacuolized cells appeared in perifollicular sinuses and also in the lymphatic folliculi or in medular cores (figures 10 and 11). Vacuolized cells of lymphatic sinuses were formed from reticular cells of the pulp of the ganglion, as we shall describe it in another place. When the inflammatory process subsided, for a long period of time there was demonstrable and measureable post-inflammatory sclerosis in the ganglion.

Myocardium. — In myocardium there was a cloudy swelling which in lethal cases was combined with degeneration of the fatty tissues of the muscles. The stroma of the myocardium was infiltrated by a few lymphocytes and plasmatic cells. Only in a few cases did the infiltrate reach an intensity at which the finding could be evaluated as slight interstitial myocarditis. Several months after the disappearance of the infection no pathohistological changes could be demonstrated in the myocardium.

Spleen. — At the peak of the disease the histological picture of the spleen corresponded to an acute inflammatory tumor. The proliferative processes were combined in this case with regressive changes which affected particularly the reticuloendothelial system of the red pulp. In the sinuses of the red pulp there were as a rule more or less numerous layers of necrotic coagulations. The inflammatory infiltrate consisted of lymphocytes, leucocytes, and plasmatic cells. In individual cases there were large vacuolized cells, particularly in the red pulp, which came from RES elements. In the sinuses of the red pulp there was an increased quantity of decomposing cellular detritus which added to the inflammatory tumor of the spleen a character of spudogenic tumors. In the case of guinea pigs which were killed 56 and 73 days after the

infection, the red pulp was still slightly hyperplastic and the stroma of the spleen was slightly sclerotic. Six months after the infection no pathohistological changes were discovered in the spleen.

Liver. — At the peak of the disease there was a cloudy swelling and a slight degree of degeneration of the fatty tissue. In lethal cases the overall venostasis was most pronounced in this particular organ.

Pancreas and intestines. — No pathohistological changes were found either in the pancreas or in the intestines during the sickness.

Kidneys. — At the peak of the disease there was a cloudy swelling in the kidneys, and in some cases there was also discreet fattening of the coiled canals. When the acute stage subsided, the kidneys did not show any pathohistological changes.

Suprarenal glands. — In the skin part of the suprarenal glands there was degenerative damage of epithelial cells of the zona reticularis and also partly of the zona fasciculata during the peak of the sickness. Morphological changes in the cells corresponded to the cloudy swelling with various degrees of damage of the cellular nuclei. Caryolysis could be observed only in rare cases. When the morbid process subsided, no pathohistological changes could be demonstrated in the suprarenal glands.

Testes. — A temporary atrophy of the organ resulted in a temporary suppression of spermatocytogenesis. During convalescence there was restitutio ad integrum in all cases.

Brain and brain membranes. — No pathohistological changes were found either in the brain or in the brain membranes.

Bone marrow. — In the course of the sickness there was temporary activation of the bone marrow. Yellowish bone marrow was temporarily substituted by active red marrow which obviously proliferated. During convalescence the condition became again normal.

#### d) Presence of Coxiellae in Histological Section

At the peak of the sickness it was established that Coxiellae were present in the lungs (figures 3-5), in the tracheobronchial lymphatic ganglia (figures 12 and 13), and in the spleen. Their presence was closely related to the described cells of reticuloendothelial origin. Coxiellae appeared in the cytoplasm of these cells. While the histiocytes which were not vacuolized contained only a small number of Coxiellae, the histiocytes with foamy cytoplasm contained many of them. However, the largest number of Coxiellae was found in large vacuolized histiocytes in which the Coxiellae were deposited in peripheral portions of the vacuoles. After the bursting of the vacuoles the presence of Coxiellae could be proved also extracellularly. In addition, in tracheobronchial lymphatic ganglia and in the spleen Coxiellae were present on occasions even in reticular cells themselves (figure 17).

e) Results of Auxiliary Examinations

A cultivation examination of samples taken from the lungs and from the spleen confirmed the fact that the examined material was bacteriologically sterile. All the inoculated soils remained sterile.

We isolated the carrier from the lungs of the diseased guinea pigs only at the peak stage of the disease. The results were positive.

The reaction of the combination of the complement was negative in the first eight days of the ailment. Positive symptoms with a titer of 1:8 began to appear only ten days after the infection. Titers of 1:16 and over were recorded ten-12 days after the infection, i.e. at the time when the disease receded (according to clinical and anatomic findings the disease culminated approximately on the eighth day after the infection). Maximum titers (1:512 and over) were recorded at the time when clinical and anatomic manifestations of Q fever disappeared completely. The level of antibodies binding the complement of this group of animals is illustrated in table 4 (Note\*: The results of serological examinations of this and other groups of animals are given merely to make the laboratory data complete).

Doba krvi či infekcie za (a)	Titer protilátok (b)						Spolu (c)	
	neg.	1:16	1:32	1:64	1:128	1:256		1:512
8 dni	23	—	—	—	—	—	—	23
10 dni	19	2	2	—	—	—	—	23
12 dni	—	8	5	6	4	—	—	23
14 dni	—	2	4	5	9	3	—	23
21 dni	—	—	—	3	4	5	11	23
26 dni	—	—	—	—	2	6	7	15
33 dni	—	—	—	2	3	6	1	12
42 dni	—	—	2	2	3	4	1	12
49 dni	—	—	1	5	2	2	—	10
77 dni	—	—	4	4	2	—	—	10
91 dni	—	2	5	1	1	—	—	9
105 dni	—	4	2	1	1	—	—	8
175 dni	—	2	2	1	—	—	—	5
189 dni	—	1	1	—	—	—	—	2

Table 4. Antibodies binding the complement in a blood serum of guinea pigs after intranasal infection.

Key to table 4: a - Collection of blood from the infection after the given number of days. b - Titer of antibodies. c - Total.

Findings in the Case of Guinea Pigs Which Have Been Infected Intrathecally

a) Records of the Course of the Disease

During the first three days after the infection the guinea pigs did not show any morbid symptoms. On the fourth day their temperature began to rise. The guinea pigs began to show restlessness. On the fifth and sixth days the restlessness was replaced by apathy. The guinea pigs covered, their fur bristled, and they took only a small amount of food. Approximately after the seventh day the guinea pigs began to recover gradually. The animal which died on the 32nd day spontaneously gave the impression of a healthy animal after the ninth day. It died suddenly.

The rectal temperature and body weight of the guinea pigs which have been infected intratesticularly are illustrated by two thermal curves (figures 5 and 6).

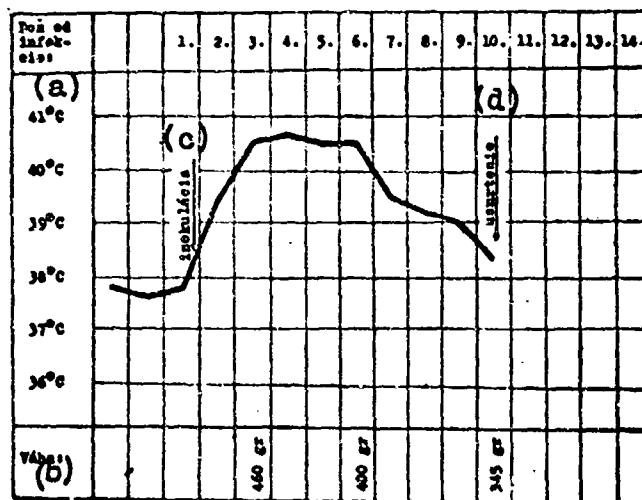


Table 5. Rectal temperature and body weight of a guinea pig after intratesticular infection by the carrier of Q fever. This animal survived the infection.

Key to table 5: a - Number of days after the infection. b - Weight. c - Inoculation. d - Animal put to death.

#### b) Microscopic Findings During Dissection

At the peak of the ailment the outstanding feature of the anatomic findings was the fact that the testes were enlarged approximately 1.5-2 times, the ilial lymphatic ganglia were enlarged about three times, and the spleen was enlarged about five times. The heart was slightly enlarged in all cases. It was a dilatation of the heart cavities without any thickening of the muscles.

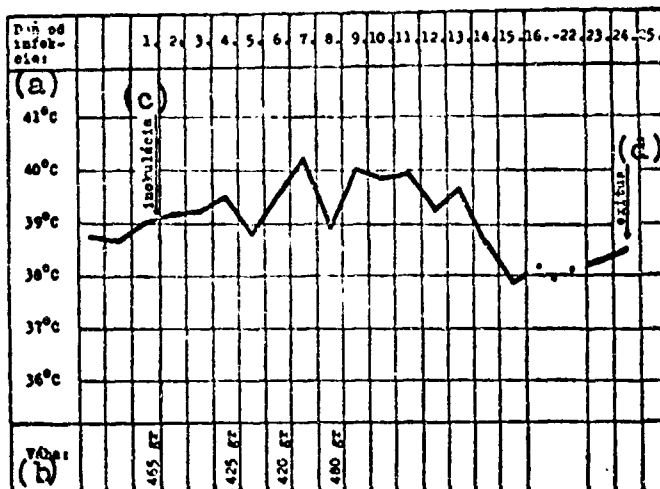


Table 6. Rectal temperature and body weight of a guinea pig after intratesticular infection by the carrier of Q fever. The animal succumbed to the infection.

Key to table 6: a - Number of days after the infection. b - Weight. c - Inoculation. d - Exitus.

#### Description of Individual Organs

The testes reached maximum size about on the eighth day after the infection. Their size at that time was 1.5-2 times the normal size. The sheathing of the organ was very tight, below the sheathing it was possible to see strong swollen veins. The structure of the organ was clearly visible on a section, the color of the testicles was bluish-rose in the section, their consistency was soft.

On the other hand, ilial lymphatic ganglia were enlarged three-five times as compared to the normal size and the anatomic structure remained unchanged.

The spleen was enlarged four-six times. Its color was dark blue-violet both on the surface as well as in a section. The pulp in a section was swelling over and as a result the Maltighi's bodies could be hardly noticed. By using the blunt side of a knife it was possible to scrape from the pulp a small amount of the softened tissue. The consistency of the organ was soft.

The liver and the kidneys had a dull glaze and showed a light violet spray. In some animals the liver and the kidneys were yellowish.



The suprarenal glands were only slightly enlarged and their anatomic structure remained intact.

The stomach, intestines, and the pancreas did not show any significant features.

In the pectoral cavity the only finding was an enlargement of the cavities in the heart which was not accompanied by any thickening of the walls of the myocardium. The heart was enlarged about 1.5 times as compared to the normal size.

The brain, brain membranes, and the bone marrow did not show any significant features.

### c) Pathohistological Findings

Testes (figures 14-16). — At the peak of the sickness the stroma of the organ was noticeably extended. When it was colored it looked very much like a fatty tissue. This resemblance was caused by the existence of large vacuolized cells which were interwoven thickly in the stroma. The expanded stroma of the organ compressed the seed-forming canals. Vacuolized cellular elements were found among the cells of the embryonic epithelium in larger or smaller amounts depending on the case. The morphology of the vacuolized cellular elements corresponded exactly to the morphology of the vacuolized cells of the stroma. The reaction to fat had negative results in these cells. When we used a special coloring we could demonstrate the presence of Coxiellae in the large vacuolized cells. The large vacuolized cells corresponded genetically to histiocytes which underwent morphological changes as a result of the intracellular parasitism of the Coxiellae, as we described it on page 37 [of the original, 34 of the translation, cf transl.]. Histiocytes were found in the testis as well as in the lungs. They contained only a few small vacuoles and histiocytes with one giant vacuole. In some places we were able to observe also histiocytes the vacuoles of which have burst. In the areas of such cells the presence of Coxiellae could be demonstrated also extracellularly. The stroma of the testis was infiltrated by a rather modest amount of lymphoplasmucellular inflammatory infiltrate. There were practically no leucocytes in the inflammatory infiltrate. The small sperm-bearing canals were atrophic. Many epithelial cells of the small canals were in the stage of necrobiosis.

The following pathohistological changes were found in the testicles of the guinea pig which died spontaneously on the 32nd day from the infection. The sperm-bearing canals either disappeared or were atrophic. Neither spermatohistogenesis or cytogenesis could be observed anywhere. The basal membranes of the small channels and the entire stroma of the testis were collagenous. Thick lymphoplasmocellular infiltrate in the stroma indicated that a diffusion interstitial inflammation has just ended. We did not find any large vacuolized histiocytes. The Coxiellae in the histological sections were negative.

Inguinal lymphatic glands (figure 17). — When the sickness reached its peak the lymphoreticular tissue of the glands was hyperplastic. Large vacuolized cells with a positive finding of Coxiellae in cytoplasm were found in large numbers in modular cords of the glands and in the peripheral portion of lymphatic follicules. There is no histological finding in the case of the guinea pig which died on the 32nd day after the infection, because in that case the appropriate lymphatic gland was not collected during the dissection.

Spleen (figure 18). — The red pulp of the spleen was noticeably enlarged, while the white pulp was reduced. In some animals there were small layers of necrotic coagulations in the red pulp. A striking finding in the spleen were large vacuolized cells of reticular origin which infiltrated heavily the entire red pulp. Large vacuolized cells were also found in smaller amounts in Maltighi's lymphatic corpuscles. The blood sinuses of the red pulp were filled with plasma and blood elements, mostly lymphocytes and plasmatic cells, and to a lesser extent monocytes and leucocytes. Coxiellae were found in great numbers in large vacuolized cells (macrophages) and individual coxiellae or groups of Coxiellae were also found in nonvacuolized reticular cells of the spleen pulp. A slight degree of hemosiderosis of the red pulp could be demonstrated in the spleen of the guinea pig which died on the 32nd day after the infection. Thin lymphoplasmacellular infiltration and multiplication of reticular cells of the spleen constituted a proof of the fact that the inflammatory swelling of the spleen has not disappeared yet. However, large vacuolized cells could not be found anymore. Even the special coloring used to determine the presence of Coxiellae gave negative results.

Liver (figures 19 - 21). — During the stage of culminating infection the stroma of the liver was affected in a more or less diffused manner by an inflammatory process, the nature of the which from the morphological point of view was the same as in the testicles. Portobiliary areas and interlobular septa contained groups of large vacuolized cells surrounded by lymphocytes and plasmatic cells. Isolated vacuolized cells were also found between the walls of liver cells in the places where normally Kupfer cells are present. Consequently we could assume that the formation of vacuolized cells of Q-fever pneumonia from Kupfer cells was likely, but there was no proof of it. On the basis of the material used in this study we could not provide a direct proof in this respect. Intracapillary we were able to observe the formation of "foamy cells" of Q-fever pneumonia (See also pages 35 and 37 [32 and 34 of the translation, cf transl.]) from blood monocytes. The nuclei of the monocytes were located centrally during all the development stages of the formation of vacuoles. The vacuoles, as a rule multiple vacuoles, were located around the cellular nucleus. It is true that in the immediate proximity of the pneumonic infiltrates of the stroma of the liver isolated liver cells were destroyed, but we did not observe anywhere that the inflammation would expand to the detriment of the liver parenchyma. The liver parenchyma showed diffused parenchymatous degeneration and a slight degree of degeneration of the fatty tissue.

In the liver of the guinea pig which died on the 32nd day after the infection only the lymphoplasmocellular infiltrates of the stroma in the form of layers were a reminder that the guinea pig had just recovered from interstitial hepatitis.

Suprarenal glands (figures 22 - 24). — At the peak of the disease the marrow of the suprarenal glands contained small pneumonic deposits, the morphology of which was the same as when the pneumonia affected the lungs, liver, or the testes. Large vacuolized cells containing Coxiellae in their cytoplasm were also found as isolated cells between the walls of epithelial cells in substantia reticularis, and in some places also in substantia fasciculata.

Kidneys. — In all cases we were able to observe only a cloudy swelling and discreet fattening of isolated coiled canals and Henle's loops.

Lungs. — Out of the entire group we diagnosed discreet layer-forming pneumonia at the time of the dissection only in the case of two guinea pigs (they were the guinea pigs which were killed on the tenth day after the infection). The histological picture corresponded fully to Q-fever interstitial pneumonia described on page [page not given, cf transl.]. In all the other cases the lungs were healthy, or they showed in some places nonspecific mucocatarrrhal bronchitis. In the case of the guinea pig which died spontaneously on the 32nd day after the infection there was heavy venostatic congestion and edema in the lungs, which in this case were the natural consequences of failing functioning of the heart. Indeed, this particular guinea pig also suffered from myocarditis which was the direct cause of the death.

Tracheobronchial lymphatic gland. — In the case of two guinea pigs in which we found layer-forming Q-fever pneumonia, tracheobronchial lymphatic glands showed changes similar to those which we observed in the Q fever of the lungs of guinea pigs which have been infected intranasally. It was a case of pneumonic hyperplasia of the lymphoid tissue accompanied by the appearance of large vacuolized cells which contained Coxiellae in the cytoplasm. In the other cases the glands were not conspicuous or showed only a slight swelling of reticular cells (the so-called sinus catarrh).

Myocardium. — There was a cloudy swelling in the myocardium and thin infiltration of the interstitium by lymphocytes and plasmatic cells. One animal was killed precisely at the time when serum myocarditis was formed in it (on the tenth day after the infection). In the case of the guinea pig which died spontaneously on the 32nd day after the infection we found during the histological examination that the animal suffered from diffused interstitial myocarditis accompanied by a heavy damage of the muscle elements. The transversely-stripped muscles were partly replaced by collagenous tissue at the time when the animal died.

Brain. — We did not find any pathomorphological changes in the brain.

Bone marrow. — The histological picture of the bone marrow was normal.

d) Presence of Coxiellae in Histological Sections

At the peak of the disease we proved the presence of Coxiellae in histological sections in the testis (figure 16), in inguinal lymphatic glands (figure 17), in the liver (figure 21), spleen, suprarenal glands (figure 24), and in the case of two animals in which layer-forming Q-fever pneumonia occurred, we also found Coxiellae in the lungs. When the lungs were affected, we also proved the presence of Coxiellae in the corresponding regional tracheobronchial lymphatic glands. Coxiellae were located intracellularly in RES cells, specifically in histiocytes, blood monocytes, reticular cells of the spleen and lymphatic glands, in endothelial cells of the capillaries of the suprarenal glands, and in the Kupfer cells of the liver. All these cellular forms mentioned above changed morphologically under the influence of intracellular parasitism of the Coxiellae. The final forms of all the cellular types were vacuolized cells with nucleus pushed to the periphery, in which Coxiellae formed a sort of a lining directly below the surface of the vacuoles. Coxiellae were also temporarily present extracellularly, when some vacuoles

burst and its content together with the Coxiellae was washed out to the extracellular space.

Odběr krvi od infekcie za: (a)	Titer protitělo (b)						Spolu (c)
	neg.	1:16	1:32	1:64	1:128	1:256	
8 dní	15	—	—	—	—	—	15
10 dní	3	5	3	1	—	—	12
12 dní	—	2	3	4	1	—	10
14 dní	—	—	1	2	3	1	7
21 dní	—	—	—	—	1	3	4
28 dní	—	—	—	—	1	2	3
35 dní	—	—	—	—	2	1	3
42 dní	—	—	1	—	3	1	5
49 dní	—	—	1	—	3	1	5
77 dní	—	—	1	1	2	1	5
91 dní	—	—	2	1	2	—	5
105 dní	—	—	3	1	1	—	5
175 dní	—	1	2	1	1	—	5

Table 7. Complement binding antibodies in blood serum of guinea pigs infected intratesticularly.

Key to table 7: a - Collection of blood after the given number of days following the infection: 8 days, 10 days, etc. b - Titer of antibodies. c - Total.

#### e) Results of Auxiliary Examinations

The testes of the guinea pigs were bacteriologically sterile. However, it was possible to isolate Coxiellae in them without any difficulties by cultivating the material on a yolk sac or by carrying out a biological experiment, namely by inoculating the material in a guinea pig by using any of the given methods.

A complement-fixation reaction with a specific antigen gave in this group of guinea pigs the same results as in the group of animals which were infected intranasally. Antibodies in titer of 1:16 or more began to appear in the blood serum of the guinea pigs on the ninth day after the infection. On the 12th day after the infection all the animals were serologically positive without exception (See table 7).

#### Findings in the Case of Guinea Pigs Which Have Been Infected Intraperitoneally

##### a) Records on the Course of the Disease

During the first three days after the infection the guinea pigs did not show any morbid symptoms. On the fourth day (in some cases only on the fifth day) the temperature of the guinea pigs began to rise. The guinea pigs began to be restless and stopped to accept the usual amount of food. Up to the tenth day the symptoms of general exhaustion kept increasing and terminated in complete apathy of the diseased animals. The guinea pigs lay motionless on the bottom of the container. Their breathing was accelerated and difficult. Prior to death we observed frequently convulsions of various groups of muscles. None of the guinea pigs survived the infection. About two days before death the body temperature of the guinea pigs began to decrease. Shortly before death their temperature was normal or below normal. The temperature during the sickness is illustrated by the temperature curve (figure 8). Spontaneous exiti were recorded on the 11th - 13th day after the infection. One of the animals died only 21 days after the infection.

##### b) Microscopic Findings During Dissections.

At the peak of the disease (six - eight days after the infection) the peritoneum did not show any pathological changes and did not contain any exudate. Exudate was observed only during the first days after infection and only in a rather small amount. In no case was there any formation of peritonitis. The spleen was enlarged five - six times at the peak of the disease as compared to normal condition and was covered all over by a fine fibrinous coating. The lymphatic glands of the abdomen were hypoplastic at the peak of the disease. The heart was enlarged about 1.5 times as compared to its normal size. Large parenchyma were parenchymatous to the point of degeneration of the fatty tissue and were venostatic. The testicles were slightly atrophic. During the dissection we found layer-forming interstitial pneumonia in two guinea pigs. In addition, one of these two guinea pigs showed during the dissection thrombosis of a. pulmonalis with subsequent hemorrhagic

infarct which affected a large portion of one lower lobe of the lungs.

#### Description of Individual Organs

The spleen showed the greatest enlargement six-eight days after the infection. At that time its size was five-six times its normal size. The surface of the spleen was covered with a fine blue-yellowish coating which could be peeled off easily. When the coating was peeled off the surface of the organ was smooth and had a dark red-violet color. The red pulp was foaming in a section. The structure of the spleen in a section was slightly less clear than normal. Hyperplastic red pulp covered the Malpighi's corpuscles which as a result were visible only as small bluish points. The consistency of the spleen was soft elastic. In some cases it was possible to wipe off a little amount of softened pulp from a section of the spleen by using the blunt edge of a knife.

Ilially and mesenterially lymphatic glands were enlarged, but their anatomic structure remained the same.

The liver and the kidneys had a dull sheen. Their veins had a sprinkle of violet color. In some cases the liver and the kidneys had a touch of yellowish coloring.

Suprarenal glands as a rule were enlarged 1.5 times. Their structure was anatomic.

The stomach, intestines, and the pancreas did not show any significant features.

The testicles were about 1/3 smaller than under normal conditions, and their anatomic structure remained the same.

In the lungs we found in most cases a mere venostatic congestion of the organ which in some cases was combined with acute vesicular emphysema. In the case of one guinea pig which died 11 days after the infection almost the entire lower lobe of one side of the lung (right side) was infarcted hemorrhagically. On the contralateral side of the lungs the same guinea pig showed diffusive interstitial pneumonia. Layer-forming interstitial pneumonia was also registered in the case of one of the guinea pigs which were killed nine days after the infection.

The heart was enlarged approximately 1.5 times as compared to its normal size. The muscles of the chamber part did not show any striking increase of thickness. The myocardium had a tattered consistency.

The brain, brain membranes, and the bone marrow did not show any striking changes.

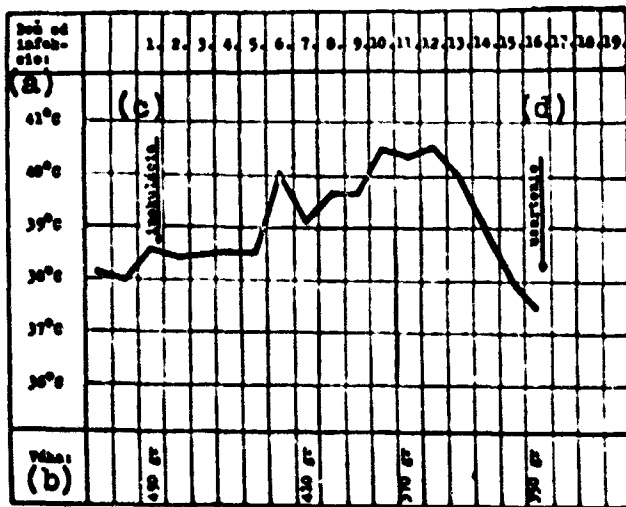


Table 8. Rectal temperature and body weight of a guinea pig which has been infected intraperitoneally by a carrier of Q fever. Key to table 8: a - Number of days after infection. b - Weight. c - Inoculation. d - Killing of the animal.

### c) Pathohistological Findings

**Peritoneum.** — In the first days after infection the peritoneum contained a modest amount of thin clear exudate. We could demonstrate the presence of Coxiellae in coatings of exudate. They were found in large vacuolized cells. At the peak of the disease the peritoneum did not show any pathohistological changes.

**Spleen.** — Spleens of guinea pigs of this group gave a similar histological picture as the spleens of the guinea pigs of the previous group (See page 41 [of the original, 39 of the translation, of transl.]). Blue-yellow coating of the spleen corresponded in a microscopic picture to a thick fibrinous network containing plasmatic cells, leucocytes, and epitheloid cells. In the eyes of the fibrinous network there was also a small number of lymphocytes.

**In lymphatic glands, liver, suprarenal glands, and kidneys** the present group of guinea pigs showed the same changes as the group of guinea pigs which have been infected intratesticularly (See pages 41-42 [of the original, 38 of the translation, of transl.]).

**Testes.** — In the testicles of all the guinea pigs there was general atrophy of the organ and spermatocytogenesis was reduced or disappeared completely.

Lungs. — The main feature of the histological finding on the lungs was venostasis with venostatic catarrh of the alveolae and occasional small venostatic bleeding. In some guinea pigs venostasis was accompanied by acute vesicular emphysema. Occasionally in some cases there were circumscribed small atelectases of the lungs. These appeared rarely. In two guinea pigs (one of them was killed nine days after the infection, the second died spontaneously 11 days after the infection) there appeared interstitial Q-fever pneumonia with the formation of typical large vacuolized histiocytes with positive Coxiellae (for a description of Q-fever pneumonia, see pages 35-36 [of the original, 31-33 of the translation, cf. transl.]). In one of these cases (this refers to the guinea pig which died 11 days after the infection) we found in addition a hemorrhagic infarct from thrombosis of a branch of a. pulmonalis. The infarct affected the lungs on the opposite side as in the case of pneumonia. The thrombus was by its composition a mixed thrombus with clear regressive changes on the fibrin and on the cellular elements.

Myocardium. — In myocardium there was a cloudy swelling and in some animals also a general thin infiltration of the interstium by lymphocytes, monocytes, and plasmatic cells.

Brain. — No pathohistological changes were found in the brain.

Bone marrow. — The histological picture of the bone marrow was normal.

#### d) Presence of Coxiellae in Histological Sections

The presence of Coxiellae was demonstrated in histological sections in the spleen, in abdominal lymphatic glands, in the liver, in the suprarenal glands, and in the two animals which also suffered from deposit-forming Q-fever pneumonia they were also found in the lungs. The appearance of Coxiellae was related to the appearance of large vacuolized cells as we described them on page 43 [of the original, 41 of the translation, cf. transl.]. In the peritoneal exudate the presence of Coxiellae was demonstrated only in the case of the guinea pig which was killed three days after the infection. Later on after the infection it was not possible to find Coxiellae in the peritoneum anymore.

#### e) Results of Auxiliary Examinations

The spleens of the guinea pigs were bacteriologically sterile. We did not isolate the carrier of the disease in this group of animals.

The results of the reaction of the combination of the complement with a specific antigen corresponded to the results of this reaction in the two previous groups of animals. The first antibodies (in titer 1:16)



appeared eight-nine days after the infection. In the following days the titers of the antibodies increased rapidly and reached high values (1:128 and more), in the same way as in the preceding two groups of animals. Table 9 illustrates the level of the complement of the binding antibodies in this group of animals.

Odber krvi od infekcie za: (a)	Titer protitátok (b)								Spolu (c)
	neg.	1:8	1:16	1:32	1:64	1:128	1:256	1:512	
8 dni	10	1	—	1	1	—	—	—	15
10 dni	8	—	1	2	2	—	—	—	13
12 dni	2	—	1	3	4	1	—	—	11
14 dni	—	1	1	2	1	2	2	—	9
21 dni	—	—	—	—	1	2	3	2	8
28 dni	—	—	—	—	1	1	2	4	8
35 dni	—	—	—	—	—	1	2	5	8
42 dni	—	—	—	—	—	2	1	5	8
49 dni	—	—	—	—	1	1	2	4	8
77 dni	—	—	—	1	1	1	2	1	6
91 dni	—	—	2	2	1	—	—	—	5
105 dni	1	—	2	2	—	—	—	—	5
175 dni	1	—	1	2	—	—	—	—	4
250 dni	—	1	—	2	—	—	—	—	3
270 dni	—	1	—	2	—	—	—	—	3

Table 9. Complement of binding antibodies in the blood serum of guinea pigs after intraperitoneal infection.

Key to table 9: a - Sampling of blood after the indicated number of days from the infection: 8 days, 10, days, etc. b - Titer of antibodies. c - Total.

#### Findings in Guinea Pigs Infected Intramuscularly

##### a) Records of the Course of the Disease

During the first two days after the infection the guinea pigs did not show any morbid symptoms. On the third-fourth day the guinea pigs ceased to accept the usual portion of food. Starting on the fifth day from the infection the animals covered, their fur bristled, and they pressed their bodies against the wall of the glass container. On the seventh day the animals were exhausted, they found it difficult to breathe, and frequently they remained almost motionless. The disease culminated on the ninth-tenth day.

Table 10 gives an example of the temperature curve during the course of the disease.

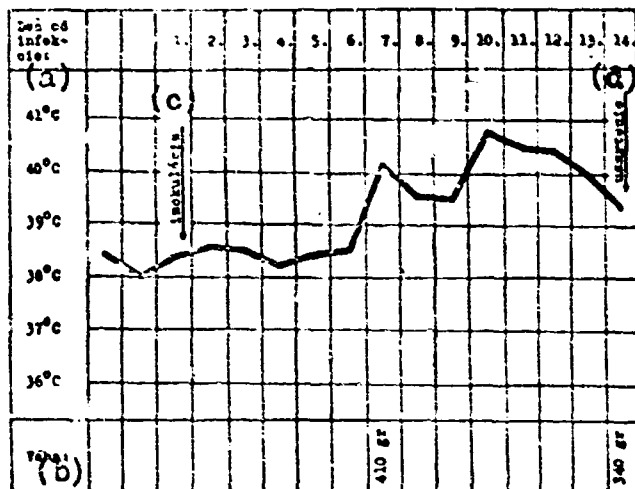


Table 10. Rectal temperature and body weight of a guinea pig after intramuscular infection

Key to table 10: a - Number of days after the infection. b - Weight. c - Inoculation. d - Killing of the animal.

Two guinea pigs which died spontaneously (one died 11 days after the infection and the other 36 days) did not show any pathological symptoms which would be reflected in their behavior at the time when exitus occurred. The death occurred when they were seemingly entirely healthy, suddenly. The body temperature of these animals was normal at the time when exitus occurred.

#### b) Microscopic Findings During Dissection

At the peak of the sickness, i.e. nine-ten days after the infection, we did not find any changes which would be microscopically visible at the point of injection. On the side where the animals were inoculated the regional lymphatic glands increased significantly during the sickness. The spleen was enlarged as a rule about five times at the peak of the sickness, while the heart was enlarged about 1.5 times. The organs of the abdominal cavity showed microscopically only symptoms of parenchymatous degeneration or a slight degree of degeneration of the fatty tissue. In the great majority of the animals the lungs did not show any conspicuous features. In one case we found pneumonic infiltrates in the lungs (in the case of a guinea pig which was killed ten days after the infection). It was a deposit-forming interstitial pneumonia.

#### Description of Individual Organs

Iliac lymphatic glands on the side where the animals were inoculated were enlarged several times, but their anatomic structure remained the same. Mesenteric glands were also enlarged.

The spleen, which was enlarged approximately five times, retained the same structure. Its color was dark blue-violet on the surface as well as on the section. Maltighi's corpuscles were generally pushed in the background by the hyperplastic red pulp. We could not scrape the pulp from the surface of the section by the blunt side of a knife. The consistency of the organ was soft elastic.

The liver and the kidneys had a dull sheen and a slightly violet sprinkle of color. In some animals these organs had a touch of yellow coloring.

The suprarenal glands were generally little enlarged, their color was ochre-yellow, the structure was anatomic.

The stomach, intestines, and the pancreas did not show any changes which could be determined microscopically.

The heart was enlarged approximately 1.5 times at the peak of the sickness. Its muscles were not thickened, or the thickening was rather slight. The myocardium had a tattered consistency.

The lungs did not show any pathological changes or showed only symptoms of venostasis. Only in one guinea pig did we find blue-red pneumonic infiltrates (in the case of the guinea pig which was killed ten days after the infection). The infiltrates were deposited parahilarly. They formed protuberances and continued to reach deeper parts of the pulmonar parenchyma. The microscopic picture of pneumonia corresponded fully to the description of pneumonia given in the group of animals which have been infected intranasally (See page 34 [of the original, 30-31 of the translation, cf. transl.]).

The brain, brain membranes, and the brain marrow did not show any significant features.

#### e) Pathohistological Findings

Place of injection (figures 25-27). -- Pneumonic infiltrate was found between sheaves of muscular fibers. The infiltrate was characterized by the presence of large vacuolized histiocytes with positive Coxiellae. The pneumonic infiltrate consisted of lymphocytes, plasmatic cells, monocytes, and to a smaller extent of leucocytes. At the place of inflammation the muscular elements disappeared. The extent of the inflammation was small. The inflammatory layer had microscopic dimensions.

Spleen. -- In the spleen of the guinea pigs of this group we found the same pathohistological changes as in the spleen of the guinea pigs which have been infected intratesticularly or intraperitoneally (See page 41 [of the original, 39 of the translation, cf. transl.]). In contrast to the guinea pigs which have been infected intraperitoneally, we did not observe any fibrinous coating on the spleen in this group of animals.

In ilial lymphatic glands, in the liver, and in the kidneys we found the same pathohistological changes as in the guinea pigs of the preceding two groups (See pages 41-42 and 46 [of the original, 39-40 and 44 of the translation, cf. transl.]).

Suprarenal glands showed basically changes which correspond to the descriptions given on page 42 [40 of the translation]. In one of the guinea pigs which died spontaneously, namely in the one which died 18 days after the infection, we found a large bleeding spot in the skin of the suprarenal gland. The center of the hematoma was autolyzed.

Testes. — In the testicles of all the guinea pigs there was temporary atrophy of the organ and spermatocytogenesis was reduced to the point of complete disappearance.

Lungs. — In the lungs there was venostasis and venostatic catarrh of the alveolae. In some cases we observed a generally discreet catarrhal endobronchitis. In the guinea pig which died spontaneously ten days after the infection and which suffered from interstitial pneumonia, a histological examination showed that it was Q-fever pneumonia, a description of which is given on pages 35-36 [31-33 of the translation].

Myocardium. — The histological finding agreed fully with the findings in the previous groups of animals. We were dealing with parenchymatous degeneration of the myocardium and thin infiltration of the stroma by lymphocytes, monocytes, and plasmatic cells. The extent of the infiltration of the myocardium never reached such an intensity that we could qualify the finding as myocarditis.

The brain and the bone marrow did not show any changes which could be determined histologically.

Odběr krvi od infekce za: (a)	Titer protilátok (b)								Spolu (c)
	neg.	1:8	1:16	1:32	1:64	1:128	1:256	1:512	
8 dni	11	—	—	—	—	—	—	—	11
10 dni	5	4	2	—	—	—	—	—	11
12 dni	1	7	2	1	—	—	—	—	11
14 dni	—	2	2	4	3	—	—	—	11
21 dni	—	—	2	—	4	2	—	—	8
28 dni	—	—	—	2	3	3	—	—	8
35 dni	—	—	—	1	3	2	2	—	8
42 dni	—	—	—	1	2	2	1	—	6
49 dni	—	—	3	1	2	—	—	—	6
77 dni	—	2	—	3	1	—	—	—	6
91 dni	—	2	—	3	—	—	—	—	5
105 dni	—	2	2	1	—	—	—	—	5
175 dni	—	2	3	—	—	—	—	—	5

Table 11. Complement-binding antibodies in blood serum of guinea pigs which have been infected intramuscularly.  
Key to table 11: a - Sampling of blood after the given number of days from the infection. b - Titer of antibodies. c - Total.

#### d) Presence of Coxiellae in Histological Sections

The presence of Coxiellae was demonstrated in histological sections in the pneumonic infiltrate which was formed at the point of injection, in regional lymphatic glands (iliac and mesenteric glands), in the liver, suprarenal glands, in the spleen, and in the case of the animal which suffered from deposit-forming Q-fever pneumonia also in the lungs and in regional tracheobronchial lymphatic glands. The existence of Coxiellae was related to the existence of large vacuolized cells in the same way as well described it on page 43 [41 of the translation].

#### e) Results of Auxiliary Examinations

The samples taken from the spleens of the guinea pigs of this group were bacteriologically sterile. We did not isolate the carrier of the disease in this group of animals.

The results of the examinations of the level of specific complement-binding antibodies were the same as in the previous groups of animals (compare table 11 with tables 4, 7, and 9).

#### Findings in Guinea Pigs Which Have Been Infected Subcutaneously

##### a) Records of the Course of the Sickness and Pathological-Anatomic Findings

Most of the guinea pigs of this group showed from the clinical and anatomic point of view the same picture as the group of guinea pigs which have been infected intramuscularly. The difference was in the fact that while in the group of guinea pigs which have been infected intramuscularly the Q-fever inflammatory infiltrate was formed in the muscles, in the group of guinea pigs which have been infected subcutaneously the infiltrate was formed in the subcutis. The findings on large parenchyma were generally the same in these two groups of animals. The only exceptions were the two guinea pigs which were infected subcutaneously and which died spontaneously 14 days after the infection. Indeed, in these animals we found heavy diffusive interstitial myocarditis. The inflammation in the myocardium was of a nonspecific nature. Wherever it appeared the contractile elements of the myocardium showed degenerative damage to the point of destruction.

##### b) Presence of Coxiellae in Histological Sections

The presence of Coxiellae was demonstrated in histological sections in the inflammatory infiltrate at the point of the injection, in regional lymphatic glands, in abdominal lymphatic glands, in the spleen, kidneys, and in the suprarenal glands. The appearance of the Coxiellae was related to the appearance of large vacuolized cells in the same way as we described it in the previous chapter.

c) Results of Auxiliary Examinations

The spleens of the guinea pigs of this group were bacteriologically sterile. In some cases we isolated the carrier from the spleen. The results of the isolation were positive.

Reaction of the combination of the complement with a specific antigen (table 12) gave the same results in this group of animals as in the previous groups (compare tables 4, 7, 9, 11, and 12).

Odber krvi od infekcie za: (a)	Titer protilátok (b)								Spolu (c)
	neg.	1:8	1:16	1:32	1:64	1:128	1:256	1:512	
8 dní	8	—	1	—	—	—	—	—	9
10 dní	2	—	2	3	2	—	—	—	9
12 dní	—	1	1	3	1	—	—	—	9
14 dní	—	—	1	4	3	1	—	—	9
21 dní	—	—	—	2	3	1	—	1	7
28 dní	—	—	—	2	2	—	2	1	7
35 dní	—	—	—	1	4	1	—	1	7
42 dní	—	—	—	2	2	1	—	—	5
49 dní	—	—	1	2	1	1	—	—	5
77 dní	—	—	2	—	2	1	—	—	5
91 dní	—	—	—	1	2	—	—	—	3
105 dní	—	—	—	—	2	—	—	—	2
175 dní	—	—	1	—	1	—	—	—	2

Table 12. Complement-binding antibodies in the blood serum of guinea pigs which have been infected subcutaneously.  
Key to table 12: a - Sampling of blood after the given number of days from the infection. b - Titer of antibodies. c - Total.

## DISCUSSION

The purpose of this chapter is to discuss and evaluate the findings from our own experimental material, to compare our own findings with the findings of other authors, and finally to use the results of the experiments in solving current problems of morphology and pathogenesis of the Q fever in man.

### Evaluation of Experimental Results

Q-fever infection, regardless how it was brought about, always resulted in our guinea pigs in the specific infection ailment, i.e. Q fever. From the pathological-anatomic point of view the Q fever was characterized by specific and nonspecific changes. As a specific morphological manifestation of Q-fever infection we consider the Q-fever inflammation which took place in various organs of the diseased guinea pigs, depending on the way of infection we used and on the method of spreading of the disease in the body of the infected animals. As nonspecific morphological manifestations of Q fever we consider dystrophic changes, circulatory disturbances, etc. Compensatory processes together with the healing processes were related partly to specific and partly to nonspecific manifestations of Q fever.

### Specific Morphological Manifestation of Q-Fever Infection: Q-Fever Inflammation

A Q-fever inflammation which we observed in all experimental material in various organs of the infected guinea pigs (in lungs, testes, liver, suprarenal glands, spleen, and in the lymphatic gland), is an inflammation of nonulcerous organs with diffusion interstitial propagation. In pathomorphology this type of inflammation is designated usually as inflammation of the interstitial membrane. With regard to cellular elements, the inflammation was characterized by large vacuolized cells of a reticulo-endothelial origin which contained microcolonies of Coxiellae in their cytoplasm. These were cells which were formed both from mobile elements of RES (more specifically from histiocytes and monocytes) as well as from fixed cells of RES (reticular cells of the pulp of the spleen and lymphoid tissue, from endothelial cells of the spleen sinuous sinuses or capillaries of the liver, etc). The size of these cells varied in sections made of paraffin blocks within the limits of 20-45  $\mu$ m. Occasionally we found also giant forms reaching a diameter of as much as 50  $\mu$ m. However, these giant forms were an exception rather than a rule. At the peak of the infection most of the vacuolized cells had a diameter of about 25-30  $\mu$ m.

From the pathological-anatomic point of view large vacuolized cells of the Q-fever inflammation are elements of RES, the vacuolae of which have degenerated as a result of the parasitism of Coxiellae in their cytoplasm. A reaction to fat (by using scarlet red) and to mucus (by thionium and mucicarmine) gave negative results in the case of these cells. The Hale-Müller reaction, which is used for a histochemical proof of acid

mucopolysaccharides, was negative) (Note \*: We express our thanks to comrade R. Kodousek, MD, assistant specialist of the Institute for Pathological Anatomy of the Faculty of Medicine of Palacky University in Olomouc, for making and evaluating the Hale-Müller reaction).

The formation of vacuolae in the cytoplasm of RES cells was related in our experiment to the functional activities of Coxiellae. Multiple small intracytoplasmatic vacuolae were formed in the cytoplasm of RES cells which were penetrated by Coxiellae. These vacuolae kept increasing in volume and fused together to form larger units. The nuclei of the affected cells were coming to the periphery and gradually died off. As a result of the growth of the vacuolae the RES cells became round and gradually reached giant dimensions. During the peak stage the vacuolized cells exceeded by their size many times the dimensions of reticular cells which remained intact. The process of enlargement of the vacuolae continued hand in hand with an intensive multiplication of Coxiellae located inside of the vacuolae. While small vacuolae were filled with Coxiellae, in the large vacuolae the parasite was found only in peripheral portions where it was in direct contact with the cellular cytoplasm. In the final stage, when the cellular cytoplasm was represented only by one or several giant vacuolae and when the nucleus which underwent regressive changes was pushed to the periphery, the thinned cellular membrane burst. The Coxiellae which were washed out in the process into extracellular areas reached new elements of RES and the process was repeated.

As we can see, in our material the morphology of large vacuolized cells of a Q-fever inflammation was directly related to the functional phenomena of the intracellular parasite which penetrated in the cytoplasm of RES cells where it multiplied. The affected cells which changed morphologically during the intracellular parasitism of the Coxiellae, received the principal credit for the special characteristics of the histological picture of a Q-fever inflammation.

Small-vacuolized elements of RES (with microcolonies of Coxiellae in the cytoplasm) cannot be diagnosed as easily as phagocytes with large vacuolae when we use colors for survey purposes. Indeed, in colored preparations cells with degenerated fatty tissue can be interpreted erroneously as small vacuolized phagocytes of RES, for example cells of alveolar epithelium - when the inflammation takes place in the lungs -, and the same applies to degenerated cells of other epithelial tissues - when the inflammation is located elsewhere. From the point of view of differential diagnosis it is also important to distinguish vacuolized phagocytes from degenerated plasmatic cells.

When we evaluate the intracellular parasitism of the Coxiellae in RES cells, we cannot base our considerations exclusively on the phagocytary activity of the RES elements and explain the presence of Coxiellae in the cytoplasm of RES elements only by increased phagocytosis of RES cells. We must assume that in the case of Coxiellae the parasite has a certain affinity to cells of reticulo-endothelial origin. Indeed, as we



know, in addition to RES elements other body cells also have increased capacity of phagocytosis, for example leucocytes, but we never found Coxiellae in their cytoplasm. In our material Coxiellae were found exclusively in cells of reticulo-endothelial origin and temporarily outside of the cells when the vacuolae burst, as we mentioned it before.

Large vacuolized cells which we observed in our guinea pigs at the peak of the Q-fever inflammation were found by almost all authors who studied the morphology of Q fever, regardless whether they dealt with the Q fever of human beings or animals. However, the nomenclature of the cellular elements described above is not uniform. Some authors base their description exclusively on the morphology of the described cells (Lillie /37/ calls them "large polygonal epitheloid cells", Findlay /19/ and Perrin /47/ called them "large mononuclear cells"). Other authors named these cells on the basis of their function ("vacuolized macrophages" of Beneke /3/ and Whittick /73/). The third group of authors base their nomenclature on the histogenesis of these cells (Bienengraber /29/ calls "large vacuolized cells of histiogenic origin", Germer /22/ calls them "large mononuclear cells of histiogenic origin", Vasileva and associates /68/ talk directly about "histiocytes" and "macrophages") (See Note \*).

(Note \*: Added during proofreading. - When we delivered the manuscript for printing we received separately a study by Giroud and Gaillard /23a/. These authors studied the morphology of Coxiellae in preparations in the form of spreads prepared from the spleen of guinea pigs which were infected intraperitoneally. With regard to the vacuolized cells which contained Coxiellae in their cytoplasm, they thought correctly that they were all kinds of types of RES elements, starting with the large reticular cell and ending with the mobile histiocyte and monocyte).

The inflammatory infiltrate in a Q-fever inflammation consisted mostly of lymphocytes and plasmatic cells in our animals. We found an increased number of leucocytes in a Q-fever inflammation only in two time intervals. The first time during the period of expansion of pathological-anatomic changes, the second time during the period of lysis of the inflammation exudate. At the peak of the inflammation we found practically no leucocytes.

It is likely that leucocytes take part in a Q-fever inflammation only to the extent to which the inflammation involves an intensification of resorption processes. According to this concept which was formulated by Germer (22), the presence of leucocytes is not an answer of the macro-organism to antigenic irritation by the Coxiellae, but is its reaction to regressive changes which take place in the cells or tissues. At the beginning of the inflammatory process, when the body cells degenerate or become necrotic under the influence of Coxiellae, the leucocytic infiltrate is clearly visible. Later on, when the cellular elements of the tissue (primarily RES cells) resist the effects of the Coxiellae and do not become necrotic as a result of their toxic irritation, but on the contrary proliferate, the leucocytes disappear from the inflammatory infiltrate.

Leucocytes multiply again during the period of lysis. The presence of leucocytes is conditioned by repeated intensification of the resorption processes. We can deduce from the concept described above that the intensity of the leucocytary infiltrate is actually an indirect index of the degree of regressive changes which take place in the tissue that has been affected by a Q-fever inflammation.

The striking intensity of the leucocytary infiltrate of the inflammation indicated that in our material we were confronted with a complication of the Q fever by another disease or pathological condition (Note \*: This refers to material which has not been published yet and was not included in this study). In most cases it was a secondary bacterial infection which led frequently to the formation of microabscesses of the lungs when they complicated a Q-fever pneumonia. We also encountered in our work a case of coincidence of Q fever with tuberculosis. In this case again the leucocytary infiltrate of the inflammation was strikingly intensive.

The aftereffects of the recovery from a Q-fever inflammation varied in different organs of our guinea pigs. While Q-fever orchitis led to a complete destruction of the semen-forming canals of the testes, a Q-fever inflammation of the spleen did not leave practically any permanent after-effects. During a Q-fever pneumonia layers of substantial emphysema were formed in the lungs. The emphysema represented a permanent aftereffect of a Q-fever pneumonia.

The healing of the inflammation was not accompanied by any striking scarification in the case of our animals. It seems that the reason for it was that fibrin and leucocytes were lacking in the Q-fever exudate, and as we know fibrin and leucocytes stimulate fermentatively the process of scarification.

Inflammation caused by *Coxiella burnetii* looks to a great extent like an inflammation caused by *Rickettsia prowazekii* and other *Rickettsias*. Unfortunately, the anatomical material dealing with these diseases was not accessible for us. On the basis of our studies of the literature we came to the conclusion on this subject that a Q-fever inflammation provides a characteristic picture precisely because of the existence of large vacuolized RES phagocytes to such an extent that in a typical case there is no possibility that it could be mistaken for inflammations caused by *Rickettsia*. But of course a histological diagnosis of a developing inflammation and an inflammation which was discovered in its retreating process can encounter considerable difficulties.

#### **Nonspecific Morphological Manifestations of Q-Fever Infection in a Guinea Pig**

Nonspecific morphological manifestations of experimental Q fever in guinea pigs are dystrophic changes and circulatory disturbances which are observed in animals of all groups and are also known in human pathology. They were parenchymatous degeneration of the fatty tissue and in rare cases

also degeneration of the fatty tissue in forms of small drops. This applies to the liver, suprarenal glands, myocardium, and to the infectious-toxic tumor of the spleen which in serious cases of Q-fever infection was combined with spodogenous swelling. An infectious-toxic tumor of the spleen was combined in relatively frequent cases with specific Q-fever splenitis. Q-fever inflammation occurred in these cases especially in the red pulp, but quite frequently also in the white pulp. A combination of splenitis with toxic-infectious swelling resulted in a serious damage of the reticular apparatus of the spleen. We found rather frequently diffusion-interstitial myocarditis which was morphologically nonspecific during histological examinations of animals which died during the period of convalescence.

In various organs of infected animals we observed during the course of Q fever the formation of perivascular inflammatory infiltrates of the round cells. The infiltrates varied in intensity from case to case and occurred particularly in the lungs, less frequently in the liver, myocardium, suprarenal glands, and kidneys.

We consider the regressive changes in large parenchyma as the result of the toxic effects of the Coxiellae, and last but not least of the toxic influence of the products of decomposition of the cells of the tissue itself. There was decomposition of the cells in various organs during all the forms of experimental Q fever in guinea pigs.

#### Some Major Pathological-Anatomic Findings

Vicarious emphysema of the lungs formed during experimental infections of all the guinea pigs which became sick as a result of Q-fever pneumonia. The emphysema is basically a substantial emphysema and consequently represents a process which is irreversible. The location of the emphysema was characteristic. It affected the peripheral portions of the lobules of the lungs regardless whether the lobules were located below the pleura or inside of the lungs.

We did not find any reports on emphysema of the lungs in Q fever either in human medicine or in pathology of laboratory animals. Koller (33) who reports in detail on Q fever as an internal disease, does not say anything in his study about the aftereffects of Q fever in the lungs. In the same way other studies of a clinical or morphological nature do not deal with the permanent aftereffects of Q fever.

The formation of substantial emphysema in the course of the pulmonary form of experimental Q fever of guinea pigs shows how serious it is when the lungs are affected by Q fever in terms of their subsequent functional capacity.

In the course of Q-fever pneumonia we found hyaline membranes in the lungs of guinea pigs at the time when the disease began to recede. Hyaline membranes appeared in the marginal portions of pneumonic infiltrates. Their appearance indicates how seriously Q-fever pneumonia affects

the respiratory function of the lungs.

A unique finding in our material was a hematoma in the skin of the suprarenal glands of a guinea pig which was infected intramuscularly. The animal died spontaneously 18 days after the infection. Arterial thromboses occurred relatively often, particularly in the lungs and in the spleen. The formation of thromboses was related to a considerable extent to the slowdown of circulation which occurred when the organ began to fail in its functioning as a result of a degeneration of the damaged myocardium.

#### Spreading of the Infection in the Body of Infected Guinea Pigs

When we evaluated the results of our experiment, we made some findings which pertain to the spreading of the infection in the body of the infected guinea pigs.

At the place where the carrier penetrated the body (= at the place of inoculation) there was a specific inflammation in the case of experimental animals. The intensity of the inflammation depended not only on the amount and virulence of the microbes but also and above all on the anatomic and physiological nature of the organ which has been infected.

The spreading of the infection in the body of guinea pigs was lymphogenous, less frequently hematogenous. The fact that the spreading of the infection was lymphogenous was indicated by the fact that the infection affected regularly the regional lymphatic glands. Hematogenous infection led for example to the deposit-forming Q-fever pneumonia (in the case of animals which have been infected parenterally), by Q-fever hepatitis, epinephritis, etc.

#### On the Question of "Pneumotrophism" of the Carrier of Q Fever

It has been said generally that Q fever is a disease which usually affects the lungs. And so many authors talk about Q fever as pneumorickettsiosis. The view that Q fever was pneumorickettsiosis required that the carrier of Q fever be attributed pneumotrophic properties.

Our experimental material speaks against pneumotrophism of the carrier of Q fever. In our experiment the clinical and anatomic form of the disease depended primarily on the way of the infection. Only intranasal infection led to the formation of manifest pneumonia in our guinea pigs. When we used another way of infection the lungs were affected only in exceptional cases. In positive cases the extent and intensity of the changes in the lungs never reached such dimensions as in the cases of infection of the respiratory organs. The seriousness of apneumonic forms of Q fever is indicated by the fact that on occasion the course of the disease in guinea pigs was lethal, while the lungs were not affected by pathological changes.

## Opportunities to Utilize Experimental Results for Human Pathology

The application of experimental results to human pathology encounters difficulties, even if we disregard the fact that guinea pigs and people are biologically different species. The difficulties consist in the fact that in an experiment we cannot very well maintain all the conditions under which a disease develops when it starts under natural conditions.

We want to utilize the experimental results primarily to clarify the findings described in cases of Q fever in man which ended in death and to discuss important pathomorphological changes observed in experiments involving the use of guinea pigs in order to find whether similar changes may occur in man.

All the available publications dealing with pathomorphology of Q fever in man were evaluated critically on pages 13-23 /of the original, 6-18 of the translation/. Table 1 contains in a succinct form a survey of the most important clinical and anatomic data of cases of death resulting from Q fever which have been studied histologically.

### Significance of the Way of Infection in Q Fever of Man

The way of infection was important in our experiment with regard to the formation of a clinical form of the sickness. This finding is entirely in agreement with observations by Blanc and associates (6) and Fonseca and associates (20) (See also pages 27-28 /23-24 of the translation/. The authors whom we cited showed in their studies rather clearly how important the way of the infection is for the formation of a clinical form of Q fever. In our material, in the same way as in the experiments of the authors whom we cited, only the intranasal way of infection resulted in the formation of a pulmonary form of Q fever. In cases of subcutaneous or other parenteral infection the lungs were affected only in rare cases. In positive cases the extent and intensity of the changes of the lungs never reached the same dimensions as after infection through the respiratory organs. Using the results of the studies of the authors whom we cited and who experimented on human beings, and acting on the basis of our own observations in experiments involving guinea pigs, we are inclined to accept the view that the way of the infection is eminently important in Q fever. An infection of the respiratory tract is particularly dangerous, because it may lead to the formation of a pulmonary form of Q fever which is the most serious form of Q-fever infection due to the fact that it has most serious consequences.

### Q-Fever Pneumonia in Man

Table 1 shows that in all the eight cases of death resulting from the infection of man by Q fever which have been published so far and in which the anatomic findings are supported by histological examinations, inflammatory changes were found in the lungs. In all cases we were dealing with interstitial pneumonia which macroscopically did not differ in any way from

interstitial pneumoniae of a different etiology. In a histological examination Q-fever pneumonia gave a characteristic morphological picture. However, pneumonia was not always at its peak at the time when exitus occurred. In the given material dealing with human pathology Q-fever pneumonia was described in the following stages of development:

1. Q-fever pneumonia in the formative stage. - In the case of Lillie and associates (39) pneumonia was recorded at the time of the increase of pathomorphological changes. In the histological picture the authors dealt with deposit-forming infiltration of the pulmonary tissue by macrophages, plasmatic cells, and elements consisting of round cells. Another striking feature at that stage was the large proportion of neutrophil leucocytes in the inflammatory infiltrate as compared to the culminating Q-fever inflammation in which in contrast the leucocytes occurred in a very small number. A proof of the presence of Coxiellae is not included in the study of the authors we quote above.

2. Culminating Q-fever pneumonia. - In the cases of Beneke (3), Uehlinger (25), and Whittick (73) the authors were dealing mostly with culminating Q-fever pneumonia. "Large vacuolized mononuclear macrophages" constituted striking cellular elements of the inflammatory infiltrate. They contained Coxiellae in their cytoplasm (Whittick). In addition to these cells, lymphocytes and plasmatic cells took part in the formation of the inflammatory infiltrate. There were many leucocytes present only in the case of Beneke. However, their presence was justified by bacterial superinfection which complicated Q fever in that case and was also the direct cause of death. Whittick alone managed to prove the presence of Coxiellae in histological sections, undoubtedly because Whittick was the only person who used the correct color method to represent the Coxiellae (it was the Wolbach /74/ modification of the Giemsa method). During that stage of the disease there occurred in addition to developed pneumonia fresh deposits of the inflammation which was in the process of formation. This agrees with the method of the formation and the spreading of interstitial inflammation in general.

3. Q-fever pneumonia in recess. - The cases described by Perrin (47), Forconi and associates (21), and Tonge and associates (67) dealt with pneumonia in the stage of insipient resolution. Large mononuclear cells appeared in smaller numbers than at the peak of the disease, while lymphocytes and plasmatic cells were present in the inflammatory infiltrate in the same number as in an insipient inflammation. Hyaline membranes were found at this stage in the affected lungs (Perrin, Tonge, and associates). Perrin did not succeed to prove the presence of Coxiellae in histological sections. In order to prove the presence of the parasite Perrin used an unsuitable color method. Neither azur-eosin according to Lillie's recipe nor the Gram's method used by Perrin are suitable to prove the presence of Coxiellae in histological sections. There is no doubt that the reason why the findings of Coxiellae in histological sections were negative was the fact that the authors used an inappropriate color method. The use of Giemsa colors does not work when we use the standard method of representation.

With regard to the work of Forconi and associates, we do not know whether the presence of Coxiellae was established at all in histological sections.

4. Transition of Q-fever pneumonia to chronic stage. - This is the case described by Aufdermauer (25). In the histological picture the major morphological change was a chronic interstitial inflammation combined with the appearance of giant cells with multiple nuclei. In addition to the chronic inflammation there appeared in some places layers of acute inflammation, the morphological structure of which corresponded to the forming or culminating Q-fever inflammation (which is described in points 1 and 2). There were practically no leucocytes in the inflammatory infiltrate. The author does not mention which color method he used for this purpose. It may be that he used an inappropriate color method, as it happened in other cases.

Out of the four stages of Q-fever pneumonia described above, the first three stages correspond to the normal course and have their analogy in experimental Q-fever pneumonia of a guinea pig. According to clinical experience of Pulver (55), any of these three development stages of Q-fever pneumonia can be cured.

There is no analogical case in our experimental material for the transition of pneumonia to a chronic stage. Even in human pathology the case of Aufdermauer is unique. Since it involved a patient who suffered from chronic Bang disease, it may be that disposition factors and other conditions of pathological changes of reactivity in the macroorganism could play an important role in that case. True, there may have been also coexistence of Q fever with some other infection (virus infection?). We must emphasize repeatedly that it was a unique case dealing with Q-fever pneumonia which reached a chronic stage.

Descriptions of development stages of pneumonia in cases of Q fever indicate that we are dealing here with a certain constant finding, to be more specific with special vacuolized cellular elements in which Whittick managed to prove reliably the presence of Coxiellae. True, there are also other, less characteristic symptoms of Q-fever pneumonia, such as the cellular composition of the inflammatory infiltrate, the appearance of hyaline membranes in the period of resolution, etc. We must also mention the fact that pneumonia usually appears in different stages of advancement in various parts of the lungs.

#### Presence of Hyaline Membranes in the Course of Q-Fever Pneumonia in Man

Perrin (47) described the appearance of hyaline membranes in the course of Q-fever pneumonia in man. In the case which he described the pneumonia was caught during its receding stage. Perrin's finding is in harmony with our experimental observations. Just like Perrin in his studies of man, we also observed in our experimental animals the presence of hyaline membranes only at the time when Q-fever pneumonia began to recede.

## Changes in Myocardium in the Case of Q Fever in Man

During a Q-fever infection of our experimental animals we observed rather frequently the formation of toxic myocarditis. In view of the fact that we used a large dose of inoculum, we cannot exclude the possibility that the changes in the myocardium were caused by the endotoxins contained in the inoculum. In view of the cardiac death which occurred in two cases of Q fever in man on which the documentation is available (the cases of Lillie and associates /39/ and Pulver and associates /55/), we have to consider also the possibility that myocardium may be affected in the course of Q fever in man. Appropriate examinations in this direction are lacking in the studies made by the authors named above. A clinical study by Wendt (70) also indicates that myocardium may be affected in the course of Q fever in man.

## Findings in Other Organs During Q Fever in Man

In some cases of death caused by Q fever the patient occasionally showed characteristic changes in the brain, spleen, and testes. Whittick (73) observed small malatic deposits in the brain. There was a proliferation of gliomatous cells around these deposits. The author succeeded to prove macroscopically the presence of Coxiellae in these cells. Perrin (47) and Whittick (73) described the presence of large mononuclear cells in the pulp of the spleen. Whittick proved microscopically the presence of Coxiellae in these cells. Whittick also described Q-fever orchitis, characterized by the presence of macrophages which contained Coxiellae in the cytoplasm.

These findings in the spleen and testes in cases of Q-fever infection of man correspond from the morphological point of view fully to the findings we made on the basis of our own material.

Changes in the central nervous system have no analogy in our experiments. We must admit that we did not pay sufficient attention to the pathology of the brain in our guinea pigs. The histological examination consisted only of an informative examination of the brain in one frontal section. Consequently we cannot exclude definitely the possibility that the brains of our animals were also affected.

Gerstl and associates (23) proved the presence of inflammatory infiltrates in the stroma of the liver in man in cases of icteric form of Q fever in materials obtained from diagnostic punctures. There were not many histiocytes in the infiltrates, except for elements of large cells. It is a pity that Gerstl and associates did not try to prove the presence of Coxiellae in histological sections. We believe that in puncture biopsy a proof of the presence of a parasite would contribute to make the diagnosis more accurate at the time when other examinations do not give unequivocal results. The case of Tonge and Derrick (67) is a clear proof that the liver is affected in cases of Q fever. However, it is a pity that these authors did not manage to prove the presence of Coxiellae in histological sections.



The Giemsa color method which the authors used for this purpose gives positive results only if the method is adjusted purposefully to prove the presence of Coxiellae. Therefore in the given case we can base our findings only on the biological proof of the presence of the parasite, which was positive.

The suprarenal glands were not examined histologically in cases of Q fever of man. In guinea pigs, the Q-fever inflammation took place rather frequently in that organ.

In the cases of Q fever in man which were subjected to post-mortem examinations many organs were not examined histologically at all. We must evaluate very carefully the conclusions which are arrived at only on the basis of a macroscopic examination. In no case can we assume that changes characteristic of Q fever could not occur in organs which do not show macroscopic symptoms. Q-fever hepatitis could be diagnosed in our guinea pigs only by the histological method. During macroscopic examinations we could not determine whether the liver of our animals was infected by interstitial Q-fever inflammation. This applies certainly also to regional lymphatic glands, suprarenal glands, and also to the other organs. Clinical studies by Kortring (34), Ludwig (40, 41), Wespi (72), and other authors point out that Q-fever inflammation may affect various organs of man (Note \*: Footnote made during proofreading. - On the subject of Q-fever infection of the endocardium see the appropriate text added during the proofreading on pages 22-23 [17-18 of the translation]).

#### Dystrophic Organic Changes in the Case of Q Fever in Man

Dystrophic organic changes in human corpses subjected to post-mortem examinations were the same as in guinea pigs. In human bodies there was also parenchymatous degeneration and less frequently a slight degree of degeneration of the fatty tissue of the liver and suprarenal glands.

#### Causes of Death in Cases of Q Fever of Man

As we know, lethality is low in cases of Q fever. This applies above all to extrapulmonary forms. Consequently the prognosis of the disease is generally favorable. Q fever led relatively frequently to death in the case of our guinea pigs. Perhaps we should look for the reason of the high lethality of Q fever under experimental conditions in the fact that we used an enormous amount of inoculum which was administered to the animals. In the group of animals which were infected parenterally the decisive element was probably the way of the infection itself, particularly when the infection affected the peritoneum.

Cases of death of human beings due to Q fever involved only elderly people. In our survey the age of the youngest patient was 41 years (Gsell's case /25/), the oldest patient was 78 years old (Whittick's case /73/). When we recall that Q fever is a disease which occurs epidemically and affects all age groups of people, it is obvious that the cause of the

lethal course of the disease are not as a rule the biological properties of the carrier of the disease (virulence of the microbe), but above all the complications - particularly with regard to the cardiovascular system - or concomitant diseases which are more frequent in elderly people than in young people and which are obviously important, as indicated by the few deaths discussed on pages 13-23 [6-18 of the translation] (See Note \*).

(Note \*: Footnote added during proofreading. - Q-fever endocarditis, which also is usually lethal, is formed as a rule on the basis of a pre-existing or at least coexisting disease of the endocardium. On this subject see the footnote on pages 22-23) [17-18 of the translation].

A clinical study by Moeschlin and associates (42) deals with complications of Q fever.

#### Possible Aftereffects of Q Fever in Man

So far we have no description of any permanent aftereffects of Q-fever infection of man. True, in most clinical studies the authors mention that reconvalescence of Q fever was protracted.

In our animals, Q-fever pneumonia resulted in the formation of deposits of pulmonary emphysema (See pages 35-36 and 57 [of the original, 31-33 & 56-57 of the translation]). Emphysema may also occur in the course of Q-fever pneumonia in man, because Q-fever pneumonia in man represents from the morphological point of view a process analogical to the process which takes place in a guinea pig (as we mentioned it before).

We know in pathology about the formation of vicarious pulmonary emphysema in interstitial pneumonias. However, in many cases its significance is not evaluated adequately. It is frequently forgotten that a vicarious emphysema is one of the forms of substantial emphysema and therefore means only an increase of the volume of the lungs (volumen pulmonum auctum).

#### Ways of Spreading of Q-Fever Infection in Man

Experimental material provides some data which can be used successfully to solve the problem of the spreading of the infectious agent in the body of the attacked macroorganism. In the experimental material we observed the spreading of the infection by the lymphogenous way (in cases of pneumonia the tracheobronchial lymphatic glands were always affected, in cases of orchitis the ilial lymphatic glands were always affected by the disease, etc) and by the way of blood. The spreading through blood was less frequent in the experiments (formation of pulmonary deposits after intramuscular infection, formation of interstitial Q-fever hepatitis or epinephritis in the course of Q-fever orchitis, etc). Hematogenous spreading can be considered as a demonstrated fact in cases of human patients (Whittick's case /73/), but it is less frequent (in the same way as in guinea pigs). There are no reliable proofs of lymphogenous spreading of

the infection in human pathology, because the authors of publications did not pay the necessary attention to regional lymphatic glands.

In our experimental material the Q-fever lymphadenitis appeared macroscopically merely as a hyperplasia of the lymphoid tissue. On the basis of experimental results we can assume that the lymphatic glands are affected and therefore that the infection also follows the lymphatic way in human patients.

#### On the Question of "Pneumotrophism" of the Carrier of Q Fever on the Basis of Material Obtained from Human Pathology

We do not find any basis for pneumotrophism of the carrier of Q fever, as it has been generally claimed, either in human medicine or in our own experimental material. An infection of the lungs is not necessarily a manifestation of Q fever in man. Apneumonic forms of Q fever occur rather frequently in patients. Therefore it is not appropriate to use the term of pneumorickettsiosis in reference to Q fever (See also page 58 /of the original, 57 of the translation/).

#### Cellulotrophism of Coxiellae to RES Elements in Man

In our experimental material Coxiellae occurred only intracytoplasmatically in RES elements. The Coxiellae were observed extracellularly, but only temporarily after the vacuolae had burst. In no case did we succeed to prove the presence of Coxiellae in the endothelium of the veins, either in the mesothelium or leucocytes, or in the epithelial cells of various organs. In the blood, we observed Coxiellae exclusively in monocytes, about which we know that they are derivatives of RES. Because of a lack of factual material we cannot say whether the conditions are similar in man. On the basis of one single case in which the presence of Coxiellae was proved in histological sections (this refers to observations by Whittick /73/), we cannot make conclusions which would be generally valid. For that reason the question of cytrophism of Coxiellae with regard to RES elements in man must remain unsolved.

#### Criteria of Pathological-Anatomic Diagnosis of Q Fever in Man

When we summarize the data obtained from world literature and have to answer the question as to what ways we have at present to make a pathomorphological diagnosis of Q fever, we can answer the question as follows: up to now nobody formulated any criteria for pathomorphological diagnosis of Q fever, and consequently Q fever could not be diagnosed as such only on the basis of a morphological examination. In our opinion, the reason for this state of affairs was in the past primarily a lack of suitable color method by which it would be possible to prove the presence of Coxiellae in histological material by post-mortem examinations or from bioptic material. As shown by the studies which we referred to before and by our own experience concerning experimental Q fever in guinea pigs, the appearance of Coxiellae, specifically their appearance in lungs, lymphatic glands, liver,

suprarenal glands, and in other organs is related to the appearance of large vacuolized cells of reticuloendothelial origin. These cellular elements were described by almost all authors of publications dealing with cases of death resulting from Q fever in man, even though most of them did not know the relationship of these cells to Q fever. What has been said above indicates that studies of the fate of Coxiellae in the body of a macroorganism involving the use of an experimental model helped to solve the problem of morphology and pathogenesis of Q-fever infection in man.

In diagnosing Q fever the work of a pathologist is made difficult by the fact that Q fever coincides frequently with other diseases or pathological conditions. For example, if Q fever is complicated by bacterial superinfection, during a post-mortem examination the complication may give the impression of being the basic ailment and consequently may detract the attention of the pathologist from the right direction. Naturally, justified difficulties may also occur in various cases of histological examinations.

The results of experiments cannot be applied in human medicine without due care. For example, with regard to Q-fever pneumonia we must remember that this disease is very frequently complicated by associated bacterial bronchopneumonia. In the course of Q-fever pneumonia the patient may also show activation of latent tuberculosis, etc. We discussed findings in other organs of human beings on pages 61-63 [of the original, of the translation]. In a diagnosis of Q fever the determination of specific morphological changes in distant organs may be valuable diagnostically, if we manage in this case to find Q-fever inflammation which is morphologically specific and contains Coxiellae. By the term distant organs we mean lymphatic glands, liver, spleen, and suprarenal glands, in which the Q-fever inflammation usually takes place in a pure form, i.e. it is not complicated by secondary bacterial infection which - as we mentioned before - makes the diagnosis of Q-fever pneumonia very difficult.

To say it briefly, the criteria for a pathological-anatomic diagnosis of Q fever consist in a correct diagnosis of the manifestation of Q fever which is morphologically characteristic, i.e. Q-fever inflammation (See pages 53-56 [of the original, 52-55 of the translation].

In spite of the fact that our knowledge of the morphology and pathogenesis of Q fever has become to a considerable extent more accurate as a result of research involving animals, we believe that it would be still premature to base a diagnosis of Q fever today on morphological findings alone. A diagnosis of Q fever must still be based today on the results of microbiological findings, more specifically on isolation and identification of the carrier of the disease and on serological findings.

Many professional publications deal with problems of microbiological diagnosis of Q fever. It is true that the problem of microbiological diagnosis of Q fever is complex, but after all it is a specialized and highly professional matter. It is not the purpose of this study to analyze microbiological diagnosis of Q fever in greater detail. However, we should

recall for purposes of general information that microbiological methods of examination have been worked out with regard to the diagnosis of Q fever to such an extent that it is no problem for a microbiologist to isolate the carrier of the disease in cases which have not been treated. Nor is it a problem to determine the level of specific antibodies in cases of patients who have been treated. On the other hand, in cases where Q fever was treated - and a pathologist encounters such cases during his post-mortem examinations - the isolation of the carrier may encounter difficulties, particularly if the patient was given an antibiotic to which Coxiellae are sensitive, for example specifically Aureomycin. A therapeutic measure can make it impossible to isolate the carrier of the disease. However, this does not mean that we should not try to isolate it. As to the significance of the determination of specific antibodies in the diseased patient, we must remember the important fact that specific antibodies can be usually demonstrated in low titers as a rule many months and frequently many years after the patient recovered from Q fever. If a diagnosis of Q fever on a dissecting table was based only on the determination of the antibodies, we could easily get the wrong idea that the given case was actually a case of Q fever. The facts could be different, namely that there may have been Q fever in the past. The patient may have died as a result of some other disease which by coincidence could appear during the dissection as Q fever. The absolute level of antibodies is not decisive in a diagnosis of Q fever, if we make only a single examination. Antibodies show values which may be considerably different in different cases. That is why in cases of Q fever we must apply the results of individual examinations in a complex manner. Morphological tests are very important, but they must be always confronted with other tests, particularly microbiological tests. When a pathologist diagnoses Q fever, he must cooperate closely with a microbiologist, epidemiologist, and with the clinic. This requirement is particularly imperative since we are dealing with a disease which has been diagnosed correctly only in isolated cases on the dissecting table.

#### CONCLUSIONS

The conclusions which ensue from our own experimental research concerning Q fever are as follows:

1. A characteristic morphological manifestation of experimental Q fever in a guinea pig is Q-fever inflammation which under different conditions may take place in different organs of the infected animal. Q-fever inflammation is a nonsuppurative inflammation with diffused interstitial propagation. It provides a characteristic picture only during the peak stage. When the inflammation forms as well as when it subsides, it may cause diagnostic difficulties. Typical cellular elements of Q-fever inflammation are large vacuolised cells of reticuloendothelial origin which contain microcolonies of Coxiellae in their cytoplasm. The inflammatory infiltrate consists mostly of lymphocytes and plasmatic cells. Leucocytes occur in the infiltrate only on occasion, a striking increase of leucocytes indicates that there is a complication (for example bacterial superinfection). A Q-fever inflammation heals without any noticeable scarification.

2. Noncharacteristic morphological manifestations of experimental Q fever in a guinea pig are various serious forms of dystrophy of parenchymatous organs, perivascular inflammatory infiltrates of round cells, and disturbances of the circulatory system. These vary from one case to another.

3. The infection spreads in the body of infected guinea pigs lymphogenously and hematogenously.

4. The way of the infection is rather important for clinical and anatomic forms of the disease. While in an infection of the respiratory organs there occurs as a rule manifest pneumonia, in other forms of infection the lungs are affected only as an exception. In positive cases the extent and intensity of pulmonary changes never reach the dimensions of those which occur after an infection of the respiratory organs.

5. A massive infection by the carrier of Q fever results in the case of guinea pigs in a dystrophic damage of the vital organs and consequently as a rule it leads to death.

6. Experimental Q fever of a guinea pig provides an analogical macroscopic and microscopic picture of Q fever in man which we know from a few casuistic publications in the world literature.

In man, an evaluation of pathological-anatomic changes is made difficult because Q fever coincides frequently with other diseases or pathological conditions. Therefore, if we know the morphology of pure experimental Q fever which occurs in guinea pigs and is not complicated by anything else, which takes its course without any concomitant diseases, we can not only understand and evaluate better the pathomorphological findings which we observe occasionally and which have been described by various authors in cases of infection of human beings, but we can also solve more easily certain important problems which cannot be solved by using human beings, for example the relationship between the way of the infection and the clinical and anatomic picture of the disease, the influence of massive infection on the course of the disease, the question of parasitic cytotrophism of the Coxiellae, etc.

If we know about Q fever under experimental conditions, we can also anticipate to some extent its complications which are likely to occur and its effects on man. Our most important finding in this respect was that we found the relationship between Q-fever pneumonia and the deposit-forming substantial pulmonary emphysema which in the case of guinea pigs represents an aftereffect of Q-fever pneumonia.

#### SUMMARY

This study is a summarization of the results of more than four years of research concerning the problem of morphology and pathogenesis of Q fever (Qh). The results are presented in a comprehensive form in such a

way that the experimental data are the basis for the solution of current problems concerning Q fever in man. The methodology of experimental examinations which we used is used routinely in pathomorphology. It consists of a macroscopic and microscopic (histological) examination of the organs of animals which have been killed in staggered time intervals after the infection.

We used the so-called "Henzerling race" of *Coxiella burnetii* (Derrick) for experimental infection. It is a race which was isolated by Robbins and associates from one case of death due to Q fever which occurred in Italy in 1946.

The experimental material consists altogether of 66 guinea pigs, of which 24 were infected intranasally, 12 intratesticularly, 12 intraperitoneally, 10 intramuscularly, and eight subcutaneously. The pathological process was studied in its full dynamics only with regard to the first group of animals. That is why this group also includes the largest number of the animals. In the other four groups we were interested in determining the pathomorphological changes at the peak of the disease. For that reason the animals in these four groups were killed almost exclusively at the time when the disease reached its peak.

The guineapigs in all the groups were subjected to a complete morphological examination. Macroscopic findings determined during dissection were supplemented by detailed histological examinations of all the parenchymatous organs. In order to prove the presence of *Coxiellae* in histological sections we used successfully an original color method which was designed by the author. Among auxiliary testing methods we used the following: bacteriological cultivation for a proof of bacteriological sterility of organs which were changed pathologically, and reaction of the combination of the complement to prove the presence of specific antibodies in the blood of the experimental animals. We made an experiment of biological isolation at least on one animal from each group.

The results of morphological tests were subjected to a detailed analysis. Specific and nonspecific manifestations of the disease are discussed in separate chapters. The author considers a Q-fever inflammation as a specific manifestation of infection by Q fever which took place in various organs of the diseased guinea pigs depending on the way of infection we used and on the method by which the disease spread in the body of the infected animals. We consider as nonspecific morphological manifestations of Q fever dystrophic changes, circulatory disturbances, etc.

The Q-fever inflammation which was observed and described in various organs of the infected animals was a nonsuppurative inflammation with diffused interstitial propagation. It was an inflammation which is described routinely in pathomorphology as an "interstitial" inflammation. As to the cellular elements, the inflammation was characterized by large vacuolized cells of reticuloendothelial origin which contained microcolonies of *Coxiellae* in their cytoplasm. They were cells which were

formed both from the mobile elements of RES (more specifically from histiocytes and monocytes) as well as from fixed RES cells (reticular cells of the pulp of the spleen and lymphoid tissue, endothelial cells of spleen sinuses, or liver capillaries, etc).

The formation of vacuolae in the cytoplasm of RES cells was related in the experiment to the functional activities of the Coxiellae. Numerous small intracytoplasmatic vacuolae were formed in the cytoplasm of RES cells in which Coxiellae had penetrated. These vacuolae continued to grow in volume and fused to form larger units. At the same time the nuclei of the affected cells moved to the periphery and gradually disappeared. As a result of the growth of the vacuolae the RES cells became round and gradually reached giant dimensions. In the culminating stage vacuolized cells exceeded many times by their size the dimensions of reticular cells which remained intact. The expansion of the vacuolae was accompanied by intensive multiplication of Coxiellae which were located intravacuolarly. While the small vacuolae were almost filled with Coxiellae, in the large cells the parasite was found only in peripheral portions where it was in direct contact with the cellular cytoplasm. In the final stage, when the cellular cytoplasm was represented only by one or few giant vacuolae and the nucleus which had changed regressively was pushed out to the periphery, the thinned cellular membrane burst. The Coxiellae which were washed out in the process into extracellular spaces reached new elements of RES, and the process was repeated.

The nonspecific morphological manifestations of experimental Q fever in guinea pigs was parenchymatous degeneration, less frequently degeneration of the fatty tissue of large parenchymas in the form of small drops, and also infectious-toxic tumor of the spleen and perivascular inflammatory infiltrates of round cells which appeared in various organs of the guinea pig.

Degenerative changes were particularly important when they were localized in the myocardium. Degenerative-toxic myocarditis led in relatively frequent cases to death. Death occurred at the time when the sick animals reached the stage of convalescence.

Thromboses of the veins were a relatively frequent finding. These occurred most frequently in the lungs and in the spleen (iliacal veins were not dissected). The formation of thromboses was related to a considerable extent to the slowdown of the circulation which took place when myocardium, which was damaged by degeneration, began to fail.

The guinea pigs which contracted Q-fever pneumonia also suffered from vicariating pulmonary emphysema during the sickness. The emphysema was in the nature of a substantial emphysema and consequently represented an irreversible process.

The spreading of the infection in the body of the infected guinea pigs was lymphogenous and hematogenous.



The question of "pneumotrophism" of the carrier of Q fever is dealt with in a separate chapter. The experimental results testify against the concept which has been generally preconized concerning the assumed pneumotrophic properties of the carrier of Q fever. Under the experimental conditions only those guinea pigs suffered from massive infection of the lungs which have been infected intranasally. When we used other ways of infection the lungs as a rule were not affected at all. In a few cases, when the lungs were nevertheless affected, the extent and intensity of pulmonary changes never reached the same dimensions in case of infection of the respiratory tract.

In the closing chapter the findings obtained from the experiments are compared with findings concerning human beings, when such findings are available. We find that in the case of guinea pigs the pathological process is morphologically identical with the process in human beings, and for this reason a guinea pig represents a suitable instrument for experimental morphological research concerning Q fever. The experimental results are used to solve current problems of the morphology of Q fever in man. Finally, the study presents the criteria for a pathological-anatomic diagnosis of Q fever obtained from material subjected to dissection.

#### BIBLIOGRAPHY

1. Andrews, P. S., "Chronic Q Fever: 2. Morbid Anatomical and Bacteriological Findings in a Patient with Endocarditis", British Medical Journal, London, 1959/2, 983.
- 1a. Annual Report of the Health and Medical Services of the State of Queensland for the Year 1936-37, pages 22-23.
2. Annual Report of the Health and Medical Services of the State of Queensland for the Year 1938-39, page 52.
3. Beneke, Tagung der Vereinigung westdeutscher Pathologen (Meeting of the Association of West-German Pathologists), Karlsruhe, 1948. Quoted according to Bieling R., "The Balkanic Influenza (Q Fever of the Old World)", Beitr. Hyg. Epid., Leipzig, 1950, Issue No. 5 /in German/.
4. Bieling, R., "The Balkanic Influenza (Q Fever of the Old World)", Beitr. Hyg. Epid., Leipzig, 1950, Issue No. 5 /in German/.
5. Binford, C. H., Hauser, G. H., "Epidemic of Severe Pneumonitis in Bayou Region of Louisiana; Pathologic Observations; Autopsy on Two Cases with Brief Comparative Note on Psittacosis and Q Fever", Public Health Reports, Washington, 59, 1363 (1944).
6. Blanc, G., Bruneau, J., Poitrot, R., Delage, B., "Some Data on Experimental Q Fever (Derrick-Burnet disease)", Bulletin of the National Academy of Medicine, Paris, 132, 243 (1948) /in French/.

7. Brown, D. C., Knight, L. A., Jellison, W. L., California Med., 69, 200 (1948). Quoted according to Ferrin, T. L., "Histopathologic Observations in a Fatal Case of Q Fever", Arch. Path., Chicago, 47, 361 (1949).
8. Burnet, F. M., Freeman, M., "Experimental Studies on the Virus of Q Fever", M. J. Australia, Sydney, 1937, 299.
9. Caporale, G., Mirri, A., Rosati, T., "Q Fever ... Zoological Relations" /in Italian, misspelled/. Italian Society for Veterinary Medicine, Convention at Cortina d'Ampezzo, August 1953.
10. Current List of Medical Literature, Armed Forces Medical Library, Washington, 1937-1957.
11. Davoli, R., Rosati, T., "Seminar on Epidemiology of Q Fever in Italy, Perugia, 10-11 October 1951", Ann. San. Pubbl. (Public Health Annals), Rome, 13, 1 (1952) /in Italian/.
12. De Mattia, R., Angela, G. C., Turletti, G., "Organotrophism and Elimination of *Coxiella Burneti*; Experimental Study", Arch. Sc. med. Montpellier, 93, 481 (1952) /in English/.
13. Dennig, H., "Fever (Balkaninfluenza)", Dtsch. med. Wschr. Stuttgart, 72, 369 (1947) /in German/.
14. Derrick, E. H., "Q Fever, A New Fever Entity: Clinical Features, Diagnosis and Laboratory Investigation", M. J. Australia, Sydney, 1937, 281.
15. Derrick, E. H., "*Rickettsia Burneti*: The Cause of Q Fever", M. J. Australia, Sydney, 1939, 14.
16. Derrick, E. H., "The Epidemiology of Q Fever: A Review", M. J. Australia, Sydney, 1953, 245.
17. Dinger, J. E., "Q Fever: Review of Literature", Med. scandbl., 1946, 61.
- 17a. Evans, A. D., Powell, D. E. B., Burrell, C. D., "Fatal Endocarditis Associated with Q Fever", Lancet, London, 1959/1, 864.
18. Excerpta medica, Section V, The Excerpta Medica Foundation, Amsterdam, 1951-1960.
19. Findlay, G. M., "Pneumonitis in Mice, Infected Intranasally with Q Fever", Trans. roy. Soc. trop. Med. Hyg., London, 35, 213 (1942).
20. Fonseca, F., Pinto, M. R., Azevedo, J. F., Lacerda, M. T., Rev. Clin. Contem., 3, 23 (1949). Quoted according to Geell, O.,

Clinical Aspects and Epidemiology of Q Fever", Helvet. med. Acta.  
(Swiss Medical Journal), Basel, 17, 279 (1950) /in German/.

21. Forconi, A., Curri, S. B., "Anatomic-Clinical Observations on  
a Case of Q Fever", Riv. Anat. pat. Oncol., (Review of Anatomic and  
Pathological Oncology), Rome, 4, 1243 (1951) /in Italian/.

22. Germer, W. D., "Q Fever in a Guinea Pig", Arch. ges. Virus-  
forsch., (Archives of the Society for Virus-Infection Research), Vienna,  
5, 336 (1954) /in German/.

23. Gerstl, B., Movitt, E. R., Skahen, J. R., Gastroenterology.  
Baltimore 30, 813 (1956). Quoted according to Wespi, H., "A Case of  
Q-Fever Hepatitis", Schweiz. med. Wschr., Basel, 87, 90 (1957) /in German/.

23a. Giroud, P., Gaillard, J. A., "Development of Rickettsias at  
the Expense of Cytoplasm of Host Cells During Infection by Rickettsia  
Burneti, Rickettsia Orientalis, Rickettsia Mooseri, Rickettsia Prowazeki  
and Rickettsia Conori", Bull. Soc. Path. exot., (Bulletin of the Society  
for Exotic Pathology), Paris, 46, 16 (1953) /in French/.

23b. Giroud, P., Vermorel, M., Pfister, R., "A Surgical Aspect of  
Q Fever. Peritoneal Reactions Forming an Occlusion Syndrome", Pres. Med.,  
Paris, 65, 1797 (1957) /in French/.

24. Gsell, O., "Q-Fever (Queensland Fever) in Switzerland  
(Endemic Pneumoniae Resulting from Rickettsia Burneti)", Schweiz. med.  
Wachr., Basel, 17, 279 (1948) /in German/.

25. Gsell, O., "Studies of Queensland Fever (Rickettsia-Burneti  
Infections in Central Europe 1947/48)", Helv. med. Acta., Basel, 15, 372  
(1948) /in German/.

26. Gsell, O., "Clinical Aspects and Epidemiology of Q Fever",  
Helv. med. Acta., Basel, 17, 279 (1950) /in German/.

27. Harman, J. B., "Q Fever in Great Britain, etc", Lancet.  
London, 1949/II, 1028. Quoted according to Whittick, J. W., "Necropsy  
Findings in a Case of Q Fever in Britain", Brit. med. J., London, 4660,  
979 (1950).

28. Hengel, R., Kausche, G. A., Laur, A., Rabenschlag, K.,  
"Q Fever", Erg. inn. Med. Kinderh., Berlin, 5, 219 (1954) /in German/.

29. Herzber, K., Herzberg-Kremmer, H., Urbach, H., "Further  
Findings on Morphology and Diagnosis of Q Fever Infection, IV Report",  
Zbl. Bakt. I. abt. Orig., Jena, 156, 14 (1950) /in German/.

30. Hornibrook, J. W., Nelson, K. R., "An Institutional Outbreak of  
Pneumonitis (Due to Rickettsia of Q Fever); Epidemiologic and Clinical

Studies", Public Health Reports, Washington, 55, 1936 (1940).

31. Huebner, R. J., Jellison, W. L., Beck, M. D., "Q Fever, A Review of Current Knowledge", Ann. intern. Med., Lancaster, 30 495 (1949).

32. Irons, J. V., Hooper, J. M., J. Amer. med. Ass., Chicago, 133, 815 (1947). Quoted according to Perrin, T. L., "Histopathologic Observations in a Fatal Case of Q Fever", Arch. Path., Chicago, 47, 361 (1949).

33. Kollar, K., "Coxiellosis Burneti - Q-Fever - as an Internal Disease", Bratislavske Lekarske Listy (Bratislava Medical Journal), 36/I, 3 (1956).

34. Korting, G. W., "Orchitis and Epididymitis as Symptoms of Q Fever", Hautarzt (Skin Specialist), Berlin, 2, 168 (1951) [in German].

35. Kubasek, M., "Queensland Fever in Czechoslovakia", Casopis Lekaru Ceskych (Journal of Czech Physicians), Prague, 93, 474 (1954) [in Czech].

36. Kuhn, R., Waag, A., "Fatal Outcome of Q-Fever Infection (Queensland Fever)", Medizinische [part of the title missing, cf. transl.], Vienna, 1954, 191 [in German].

37. Lillie, R. D., "Pathologic Histology in Guinea Pigs Following Intraperitoneal Inoculation with the Virus of Q Fever", Public Health Reports, Washington, 57, 296 (1942).

38. Lillie, R. D., Histopathologic Technic, The Blakiston Company, Philadelphia and Toronto, 1948, page 82.

39. Lillie, R. D., Perrin, T. L., Armstrong, C., "An Institutional Outbreak of Pneumonitis; Histopathology in Man and Rhesus Monkeys in the Pneumonitis Due to the Virus of Q Fever", Public Health Reports, Washington, 56, 149 (1941).

40. Ludwig, H., "Q Fever - Pericarditis", Schweiz. med. Wochr., Basel, 86, 490 (1956) [in German].

41. Ludwig, H., "Q-Fever Hepatitis", Schweiz. med. Wochr., Basel, 86, 1052 (1956) [in German].

41a. Marmion, B. P., Higgins, F. E., Bridges, J. B., Edwards, A. T., "A Case of Subacute Rickettsial Endocarditis; with a Survey of Cardiac Patients for This Infection", Brit. med. J., London, 1960/2, 1264.

42. Moeschlin, S., Koszewski, B. J., "Q-Fever Complications", Schweiz. med. Wochr., Basel, 80, 929 (1950) [in German].

43. Nauck, E. G., Weyer, F., "Laboratory Infections in Cases of Q Fever", Dtsch. med. Wschr., Stuttgart, 74, 198 (1949) /in German/.
44. Moury, M., "Comparative Studies on Spread of Rickettsia in Guinea Pigs", Bull. Soc. Path. exot., Paris, 45, 721 (1952).
45. Ockur, P. P., Popova, S. N., "A Case of Protracted Course of Q Fever with Fatal Outcome", Arch. patol. (Pathological Archives), Moscow, 1958, IX, 69 /in Russian/.
46. Patocka, F., Kubelka, V., "Studies of Q Rickettsia I", Csl. Hyg. Epid. (Czechoslovak Hygiene and Epidemiology), Prague, 5, 340 (1953) /in Czech/.
47. Ferrin, T. L., "Histopathologic Observations in a Fatal Case of Q Fever", Arch. Path., Chicago, 47, 361 (1949).
48. Ferrin, T. L., Bengtson, J. A., "Histopathology of Experimental Q Fever in Mice", Public Health Reports, Washington, 57, 790 (1942).
49. Philip, C. B., "Comments on the Name of the Q-Fever Organism", Public Health Reports, Washington, 63, 58 (1948).
50. Plank, J., Rychlo, A., "A Quick Decalcification Method", Zbl. allg. Path. path. Anat., Jena, 89, 252 (1952).
51. Pospisil, R., "Q Fever", Lek. Obzor (Medical Horizon), Bratislava, 4, 295 (1955).
52. Pospisil, R., "Queensland Fever", Encyklopedie praktického lekara (Encyclopedia of a Practical Physician), VIII Volume, Publishing House of Public Health Literature, Prague, 1955, page 449.
53. Pospisil, R., "Rickettsia burneti - povodca Q horucky (Rickettsia Burneti - Cause of Q Fever), not published.
54. Pospisil, R., Rychlo, A., "Dynamics of the Formation of Complement-Binding Antibodies After Intranasal Infection of a Guinea Pig by a Carrier of Q Fever", Sbornik (Almanac) of the Medical Faculty of Komensky University, Kosice, 1, 203 (1958).
55. Pulver, W., Fellmann, N., "Fatal Cases of Q-Fever Infections", Schweiz. med. Wschr., Basel, 87, 73 (1957).
56. Quarterly Cumulative Index Medicus, American Medical Association, Chicago, 1937-1956.
57. Rivers, T. M., "Viral and Rickettsial Infections of Man", 1952. Russian translation by M. K. Vorosilova and B. I. Kaplan, edited by M. P. Chumakov, Publishing House of Foreign Literature, Moscow, 1955, pages 731-744.

58. Robbins, F. C., Rustigian, R., Snyder, M. J., Smadel, J. E., "Q Fever in Mediterranean Area: Report of Its Occurrence in Allied Troops. III. The Etiological Agent", Am. J. Hyg., Baltimore, 44, 51 (1946).

58a. Robson, A. O., Shimmin, C. D. G. L., "Chronic Q Fever. I. Clinical Aspects of a Patient with Endocarditis", Brit. med. J., London, 1959/2, 980.

59. Rychlo, A., "Contrast Representation of Rickettsiae in Histological Sections by Giemsa Coloring Matter", Schweiz. Z. allg. Path. Bakt., Basel, 21, 858 (1958).

60. Rychlo, A., "Substantial Emphysema of the Lungs Formed in the Course of Pulmonary Form of Experimental Q Fever in a Guinea Pig", Sbornik (Almanac) of the Faculty of Medicine of P. J. Safarik University, Kosice, 3, 19 (1960).

61. Rychlo, A., Pospisil, R., "Pathomorphology of Experimental Q Fever in a Guinea Pig After Intranasal Infection", Sbornik of the Faculty of Medicine of Komensky University, Kosice, 1, 53 (1958).

62. Rychlo, A., Pospisil, R., "Morphology and Pathogenesis of Experimental Q Fever in Guinea Pigs", Path. Microbiol., Basel, 23, 489 (1960).

63. Scavo, R., "Anatomic-Pathological Lesions of Rickettsia Burneti in Guinea Pigs", Bolletino (Bulletin) of the Italian Society for Experimental Biology, Bologna, 28, 329 (1952) /in Italian/.

64. Stoenner, H. G., Bell, E. J., Lackman, D. B., Kissling, R., Parker, R. R., "Symptomatology and Pathology of Experimental Q Fever in Dairy Cattle", Public Health Reports, Washington, 1949. Quoted according to Bell, E. J., Parker, R. R., Stoenner, H. G., "Experimental Q Fever in Cattle", Amer. J. Publ. Health, New York, 39, 478 (1949).

65. Stoker, M. G., "Q Fever I. Clinical Features and Laboratory Diagnosis", Translations of the Royal Society of Tropical Medicine and Hygiene, London, 48, 191 (1954).

66. Sutorisova - Stolzova, M., Dubay, L., "Revival of Old Dried Cultures of Rickettsiae", Cal. Hyg. Epid. Mikrobiol., Prague, 2, 107 (1953).

67. Tonge, J. I., Derrick, E. H., "A Fatal Case of Q Fever Associated with Hepatic Necrosis", Medical Journal, Australia, Sydney, 1959, 594.

68. Vasileva, L. V., Korokin, I. N., Kekohayeva, N. G., Jablonskaya, V. A., "Experimental Q-Rickettsia and Its Histopathology in Guinea Pigs", Zhurnal mikrobiol. (Journal of Microbiology), Moscow, 1953, VI, 54 /in Russian/.

69. Wegmann, T., "Encephalitis Resulting from Q Fever", Schweiz. med. Wschr., Basel, 79, 690 (1949) /in German/.
70. Wendt, M. L., "Myocarditis in Q Fever", Zschr. ges. inn. Med., Leipzig, 1953, 93 /in German/.
71. Wentworth, B. B., "Historical Review of the Literature on Q Fever", Bact. Rev., Baltimore, 19, 129 (1955).
72. Wespi, H., "A Case of Q-Fever Hepatitis", Schweiz. med. Wschr., Basel, 87, 90 (1957) /in German/.
73. Whittick, J. W., "Necropsy Findings in a Case of Q Fever in Britain", Brit. med. J., London, 4660, 979 (1950).
74. Wolbach, S. B., Tood, J. L., Palfrey, F. W., "The Etiology and Pathology of Typhus", Harvard University Press, Cambridge, 1922, pages 13-14.
75. Zdrodovskiy, P. F., Golinevich, E. M., Ucheniye o rickettsiakh i rickettsiozakh (Studies of Rickettsiae and Rickettsioses), Medgiz (Publishing House of Medical Literature), Moscow, 1953, pages 282-300.

TABLE OF CONTENTS

	<u>Original</u>	<u>Translation</u>
PREFACE . . . . .	5	1
INTRODUCTION . . . . .	9	2
SURVEY OF LITERATURE . . . . .	13	6
Publications Dealing with the Morphology of		
Q Fever of Man . . . . .	13	6
Literary Sources Dealing with Morphology of		
Q Fever in Animals . . . . .	23	18
Literary Sources with Occasional Data on the		
Morphology of Q Fever and Other Sources . . . .	26	22
OUR OWN EXPERIMENTAL MATERIAL . . . . .	29	25
Working Method . . . . .	29	25
Findings in the Case of Guinea Pigs Infected		
Intranasally . . . . .	32	29
a) Records of the Course of the Disease . .	32	29
b) Microscopic Findings During Dissection .	33	30
c) Pathohistological Findings . . . . .	35	31
d) Presence of Coxiellae in Histological		
Section . . . . .	37	34
e) Results of Auxiliary Examinations . . . .	37	35
Findings in the Case of Guinea Pigs Which Have		
Been Infected Intratesticularly . . . . .	38	35
a) Records of the Course of the Disease . .	38	35
b) Microscopic Findings During Dissection .	40	36
c) Pathohistological Findings . . . . .	40	38
d) Presence of Coxiellae in Histological		
Sections . . . . .	43	41
e) Results of Auxiliary Examinations . . . .	44	42
Findings in the Case of Guinea Pigs Which Have		
Been Infected Intraperitoneally . . . . .	44	42
a) Records on the Course of the Disease . .	44	42
b) Microscopic Findings During Dissections .	45	42
c) Pathohistological Findings . . . . .	46	44
d) Presence of Coxiellae in Histological		
Sections . . . . .	47	45
e) Results of Auxiliary Examinations . . . .	47	45
Findings in Guinea Pigs Infected Intramuscularly	48	46
a) Records of the Course of the Disease . .	48	46
b) Microscopic Findings During Dissection .	48	47
c) Pathohistological Findings . . . . .	49	48
d) Presence of Coxiellae in Histological		
Sections . . . . .	51	50
e) Results of Auxiliary Examinations . . . .	51	50
Findings in Guinea Pigs Which Have Been Infected		
Subcutaneously . . . . .	51	50
a) Records of the Course of the Sickness and		
Pathological-Anatomic Findings . . . . .	51	50



	<u>Original</u>	<u>Translation</u>
b) Presence of Coxiellae in Histological Sections . . . . .	51	50
c) Results of Auxiliary Examinations . . . . .	52	51
<b>DISCUSSION</b> . . . . .	<b>53</b>	<b>52</b>
<b>Evaluation of Experimental Results</b> . . . . .	<b>53</b>	<b>52</b>
<b>Specific Morphological Manifestation of Experimental Q-Fever Infection in a Guinea Pig - Q-Fever Inflammation</b> . . . . .	<b>53</b>	<b>52</b>
<b>Nonspecific Morphological Manifestations of Q-Fever Infection in a Guinea Pig</b> . . . . .	<b>56</b>	<b>55</b>
<b>Some Major Pathological-Anatomic Findings</b> . . . . .	<b>57</b>	<b>56</b>
<b>Spreading of the Infection in the Body of Infected Guinea Pig</b> . . . . .	<b>58</b>	<b>57</b>
<b>On the Question of "Pneumotrophism" of the Carrier of Q Fever</b> . . . . .	<b>58</b>	<b>57</b>
<b>Opportunities to Utilize Experimental Results for Human Pathology</b> . . . . .	<b>58</b>	<b>58</b>
<b>Significance of the Way of Infection in Q Fever of Man</b> . . . . .	<b>59</b>	<b>58</b>
<b>Q-Fever Pneumonia in Man</b> . . . . .	<b>59</b>	<b>58</b>
<b>Presence of Hyaline Membranes in the Course of Q-Fever Pneumonia in Man</b> . . . . .	<b>61</b>	<b>60</b>
<b>Changes in Myocardium in the Case of Q Fever in Man</b> . . . . .	<b>61</b>	<b>61</b>
<b>Findings in Other Organs During Q Fever in Man</b> . . . . .	<b>61</b>	<b>61</b>
<b>Dystrophic Organic Changes in the Case of Q Fever in Man</b> . . . . .	<b>62</b>	<b>62</b>
<b>Causes of Death in Cases of Q Fever of Man</b> . . . . .	<b>63</b>	<b>62</b>
<b>Possible Aftereffects of Q Fever in Man</b> . . . . .	<b>63</b>	<b>63</b>
<b>Ways of Spreading of Q-Fever Infection in Man</b> . . . . .	<b>63</b>	<b>63</b>
<b>On the Question of "Pneumotrophism" of the Carrier of Q Fever on the Basis of Material Obtained from Human Pathology</b> . . . . .	<b>64</b>	<b>64</b>
<b>Cellulotrophism of Coxiellae to RES Elements in Man</b> . . . . .	<b>64</b>	<b>64</b>
<b>Criteria of Pathological-Anatomic Diagnosis of Q Fever in Man</b> . . . . .	<b>65</b>	<b>64</b>
<b>CONCLUSIONS</b> . . . . .	<b>67</b>	<b>66</b>
<b>SUMMARY</b> . . . . .	<b>69</b>	<b>67</b>
<b>BIBLIOGRAPHY</b> . . . . .	<b>71</b>	<b>70</b>
<b>FOREIGN-LANGUAGE SUMMARIES</b> . . . . .	<b>74</b>	
<b>PICTORIAL SUPPLEMENT (figures 1-27)</b> . . . . .	after page 80	