

UNCLASSIFIED

AD NUMBER
AD840397
NEW LIMITATION CHANGE
TO Approved for public release, distribution unlimited
FROM Distribution authorized to U.S. Gov't. agencies and their contractors; Administrative/Operational Use; SEP 1967. Other requests shall be referred to Department of the Army, Fort Detrick, Attn: Technical Releases Branch/TID, Frederick, MD 21701.
AUTHORITY
SMUFD D/A ltr, 15 Feb 1972

THIS PAGE IS UNCLASSIFIED

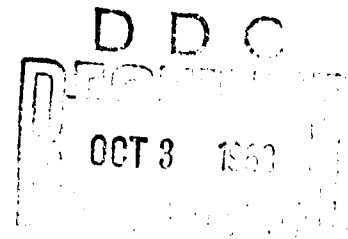
AD840397

TRANSLATION NO. 2004

DATE: 28 Sept 1967

DDC AVAILABILITY NOTICE

Reproduction of this publication in whole or in part is prohibited. However, DDC is authorized to reproduce the publication for United States Government purposes.



STATEMENT #2 UNCLASSIFIED

This document is subject to special export controls and each transmittal to foreign governments or foreign nationals may be made only with prior approval of Dept. of Army, Fort Detrick, ATTN: Technical Release Branch/TID, Frederick, Maryland 21701

EXPERIMENTAL BLASTOMYCOSES IN THE GOLDEN HAMSTER

Annales de l'Institut Pasteur
(Annals of the Pasteur Institute)
Vol. 89, No 5, 1955, pp. 593-596.

G. Segretain and
E. Drouhet
(Division of Mycology and
Plant Physiology, Pasteur
Institute).

During the past few years, the Golden Hamster has assumed a leading position among laboratory animals utilized for studying experimental mycoses. In 1952, we demonstrated that hamsters inoculated with Histoplasma capsulatum developed a generalized infection of the reticulo-endothelial system (1). Drouhet and Schwarz (2) published several papers on histoplasmosis in the hamster and mouse. Dubois et al. (3) achieved an experimental infection after inoculating animals with Histoplasma duboisii (large form histoplasmosis). Mariat and Drouhet (4) reported that experimental sporotrichosis in the hamster can assume two forms: chronic, with gumous lesions of the paws and infection of the testes; subacute, with a generalized, fatal outcome. They observed in tissue sections that the pathogen would assume a typical (classical) asteroid arrangement during its development. Finally, during actinomycosis caused by an anaerobic microorganism and considered for a long time to be a mycosis, Hazen et al. (5) observed in the hamster pathological changes which resembled the spontaneous disease because of the typical granular masses in the pus.

Since we have used the Golden Hamster as an experimental animal in the study of blastomycosis for many years, we wish to summarize our results here and to compare them with those of Guimaraes (6) and other investigators.

Cultures used for inoculations were supplied by the Mycology Division of the Instituto Oswaldo Cruz: Blastomyces dermatitidis, two strains, were No. 60 and 61 in our mold collection; Blastomyces (Paracoccidioides) brasiliensis, two strains, were No. 55 and 56 in our mold collection. All hamsters were inoculated intraperitoneally with 1 ml of a saline suspension of the yeast-phase or mycelial phase of the organism. We also used suspensions prepared from infected hamsters.

The yeast-phase of B. dermatitidis, No. 60, was particularly pathogenic. The four inoculated hamsters died after 18, 34, 35, and 35 days respectively. Animals inoculated with the mycelial phase of No. 61 survived for six months. Six hamsters, inoculated with B. dermatitidis, had serious congested areas in their lungs with hepatic and extremely hardened zones. In four animals, the peritoneum had more or less numerous and disseminated nodules. In four hamsters the liver showed an identical picture with congested and exaggerated lobular involvement. In one animal, an abscess was present on the wall of the testicle. Kidney, spleen and lungs were normal. The lesions resembled those described by Heilman (7) in mice inoculated intravenously and by Baker (8) who inoculated the same animal intraperitoneally. Vermeil et al. (9), with a Tunisian pathogen, produced an experimental infection in meriones (Meriones shawi), animals related to the hamster, and in gerbils (Gerbillus hirtipes). The microscopic aspect of the lesion resembled a granuloma with a necrotic center and with the yeast-phase pathogen located peripherally, often intracellularly. The reacting cells, the mono- or polynuclear lymphocytes, often assumed the shape of rounded follicles. In the lungs, the alveoli were permeated by the disseminated pathogen. Among the reacting cells, there occurred polymorphs and a few plasmodia.

Hamsters inoculated with B. brasiliensis had the following survival times: with the yeast-phase of No. 55, 71 days; with the mycelial phase of No. 56, 145 days. When 18 hamsters were inoculated with the pathogen, 12 developed lesions. Nine of the 12 were inoculated with No. 55 and three of six were inoculated with No. 56. Four animals were contaminated among the eight inoculated with suspensions of organs from infected animals and they were sacrifices after 90 days. Suspensions prepared from biopsy material were less virulent than suspensions of cultures. Autopsy of 36 inoculated hamsters indicated the following organs were infected: peritoneal cavity 13, rows of nodules on the peritoneum, epiploon and diaphragm 11, liver 9 (hypertrophy with nodular reaction or microabscesses), testes 7 (with orchitis and nodular granulations), and congested lungs 5 cases. Kidney and brain remained normal.

On the cupa (i.e. cup), lesions were nodular or follicular, often well circumscribed. In the liver, the nodules were located on the periphery of the lobules, well delineated by a fibrous membrane which covered the rest of the organ. In the center of the nodule there occurred 1 - 3 enormous plasmodia, which were often located in a dilated sinusoid. The nuclei were pushed back to the periphery of the plasmodia, while their center was filled with a mass of round cells of the pathogen. In the liver especially, some parasitic multi-budding forms could be clearly seen when stained according to Hotchkiss-MacManus, either as small but numerous buds along the periphery of the cell (like a wheel) or less numerous inside the cell which harbors them. The very rare renal lesions are encountered in this form.

In the lymphoid tissue beside the nodular lesions, there occur typical well delineated follicles containing 1 - 10 cells of the pathogen in the center, surrounded by polynuclear cells, then by lymphocytes. Some pathogens exhibit walls thickened by deposits of eosinophilic substance which in some cases produced narrow, elongated masses which included certain cells. The whole picture strongly resembled the granular masses seen in actinomycosis. All of this was described by Almeida (11) but not without criticism (10). In the lung or in the alveoli there occurred accumulations (heaps) of reactive cells, but the pathogen was only very rarely present in such lesions.*

Guimaraes (6) obtained experimentally generalized infections in five hamsters which had received intratesticular injections of suspensions of human biopsy material rich in yeast-phase cells of B. brasiliensis. He noted the animals did not die until 200 days later and he emphasized the importance of the use of the hamster for studying experimental, paracoccidioidomycotic infections.


In summary, according to our results, the hamster is a very useful animal for studying experimentally blastomycosis, especially South American blastomycosis. It is the only animal in which a generalized infection is easily obtained. Intraperitoneal infections produce particularly interesting results. Masses of cells consisting entirely of B. brasiliensis have been observed.

Bibliography


1. E. Drouhet et G. Segretain. Ces Annales, 1952, 83, 381.
2. E. Drouhet et J. Schwarz. International Symposium on Therapy of fungus infections. Los Angeles, 1955.
3. A. Dubois et R. Vanbreuseghem. Ann. Soc. Belge Med. trop., 1953, 33, 383.
4. F. Mariat et E. Drouhet. Ces Annales, 1954, 86, 485.
5. E. Hazen, G. N. Little et H. Resnick. J. Lab. Clin. Med., 1952, 40, 914.
6. F. N. Guimaraes. O. Hospital, 1951, 40, No 4.
7. F. R. Heelman. J. Invest. Dermatol., 1947, 9, 87.
8. R. D. Baker. Amer. J. trop. Med., 1939, 19, 547.
9. C. Vermeil, A. Gordeef et N. Haddad. Ces Annales, 1954, 86, 636.
10. M. Moore. Arch. Pathol., 1946, 42, 113.
11. F. P. de Almeida. Ann. Fac. Med. Univ. Sao Paulo, 1934, 10, 163.

* We thank Miss Couteau for her assistance in pathological anatomy.

PHOTO APPENDIX



1. Nodule in the liver. Giant cells with masses of B. brasiliensis in the center and nuclei on the periphery. One giant cell has developed in a sinusoid. Hemalun stain. 325X.



2, 3, 4. Multi-budding cells of B. brasiliensis. In Fig. 4 note the wheel-shaped arrangement. Hotchkiss-MacManus stain. 800X.

GRAPHIC NOT REPRODUCIBLE

5

5. B. brasiliensis in the center of a follicle (lymphoid tissue). The wall is thickened by deposits of eosinophilic substance. Hemalun stain. 800X.

6

6. B. brasiliensis, located in the center of a follicle, and narrow, elongated masses at the periphery. Ziehl-Gram stain. 800X.

- 5 -

GRAPHIC NOT REPRODUCIBLE