

AD-759 115

ATLAS OF GOAT ANATOMY. PART III. MYOLOGY

Clarence E. Hopkins, et al

Edgewood Arsenal
Edgewood, Maryland

April 1973

DISTRIBUTED BY:

NTIS

National Technical Information Service
U. S. DEPARTMENT OF COMMERCE
5285 Port Royal Road, Springfield Va. 22151

AD

AD 759115

**EDGEWOOD ARSENAL
TECHNICAL REPORT**

EATR 4706

**ATLAS OF GOAT ANATOMY
PART III: MYOLOGY**

by

Clarence E. Hopkins, Sr.
Thomas E. Hamm, Jr., CPT, VC
Gary L. Leppart

Biomedical Laboratory

April 1973

DDC
RECEIVED
MAY 1 1973
REGISTRY
C



Reproduced by
**NATIONAL TECHNICAL
INFORMATION SERVICE**
U S Department of Commerce
Springfield VA 22151

DEPARTMENT OF THE ARMY
Headquarters, Edgewood Arsenal
Aberdeen Proving Ground, Maryland 21010

Approved for public release; distribution unlimited.

38

ACCESSION ID#	
NTIS	<input checked="" type="checkbox"/>
DOC	<input type="checkbox"/>
UNCLASSIFIED	<input type="checkbox"/>
JUSTIFICATION	
BY	
LICITATION/AVAILABILITY CODES	
Lic.	S. ALL. REG./SP. SPECIAL
A	

Disclaimer

The findings in this report are not to be construed as an official Department of the Army position unless so designated by other authorized documents.

Disposition

Destroy this report when it is no longer needed. Do not return it to the originator.

UNCLASSIFIED

Security Classification

DOCUMENT CONTROL DATA - R & D

(Security classification of title, body of abstract and indexing annotation must be entered when the overall report is classified)

1. ORIGINATING ACTIVITY (Corporate author) Commander, Edgewood Arsenal Attn: SMUEA-BL-BB Aberdeen Proving Ground, Maryland 21010		2a. REPORT SECURITY CLASSIFICATION UNCLASSIFIED	
		2b. GROUP NA	
3. REPORT TITLE ATLAS OF GOAT ANATOMY. PART III: MYOLOGY			
4. DESCRIPTIVE NOTES (Type of report and inclusive dates) This work was started in July 1971 and completed in August 1972.			
5. AUTHOR(S) (First name, middle initial, last name) Clarence E. Hopkins, Sr., Thomas E. Hamm, and Gary L. Leppart			
6. REPORT DATE April 1973		7a. TOTAL NO. OF PAGES 39	7b. NO. OF REFS 6
8a. CONTRACT OR GRANT NO.		8a. ORIGINATOR'S REPORT NUMBER(S) EATR 4706	
b. PROJECT NO. 1T061101A91A15			
c.		8b. OTHER REPORT NO(S) (Any other numbers that may be assigned this report)	
d.			
10. DISTRIBUTION STATEMENT Approved for public release; distribution unlimited.			
11. SUPPLEMENTARY NOTES In-house laboratory independent research		12. SPONSORING MILITARY ACTIVITY	
13. ABSTRACT The Angora goat (<i>Capra hircus</i>) has been the main experimental animal used by the Biophysics Division for many years. Knowledge of goat anatomy is important during both the planning and experimental stages of projects. Because no readily usable information on goat anatomy is available, a series of reports on the subject is being prepared. The first in the series described the skeletal anatomy. The second in the series described the anatomy of serial cross sections. The present report, Part III, Myology, describes the muscles on superficial and deep dissection of the head, neck, and pectoral and pelvic limbs. Part IV, Internal Organs, which will describe the major organs and its structures, is near completion.			
14. KEYWORDS Myology Goat Atlas Superficial dissection Deep dissection Head Neck Thoracic Pectoral limbs Pelvic limbs Musculature			

DD FORM 1473 1 NOV 66

REPLACES DD FORM 1473, 1 JAN 64, WHICH IS OBSOLETE FOR ARMY USE.

UNCLASSIFIED

Security Classification

EDGEWOOD ARSENAL TECHNICAL REPORT

EATR 4706

ATLAS OF GOAT ANATOMY

PART III: MYOLOGY

by

**Clarence E. Hopkins, Sr.
Thomas E. Hamm, Jr., CPT, VC
Gary L. Leppart**

**Biophysics Division
Biomedical Laboratory**

April 1973

Approved for public release; distribution unlimited.

Task 1T061101A91A15

**DEPARTMENT OF THE ARMY
Headquarters, Edgewood Arsenal
Aberdeen Proving Ground, Maryland 21010**

FOREWORD

The work described in this report was authorized under Task 1T0611Q1A91A1J, In-House Laboratory Independent Research. This work was started in July 1971 and completed in August 1972.

In conducting the research described in this report, the investigators adhered to the "Guide for Laboratory Animal Facilities and Care," as promulgated by the Committee on the Guide for Laboratory Animal Resources, National Academy of Sciences-National Research Council.

Reproduction of this document in whole or in part is prohibited except with permission of the Commander, Edgewood Arsenal, Attn: SMUEA-TS-R, Aberdeen Proving Ground, Maryland 21010; however, DDC and the National Technical Information Service are authorized to reproduce the document for US Government purposes.

Acknowledgments

The authors wish to acknowledge the technical assistance of John Holter, Joseph B. Scott, and Garnet Affleck, Jr., Biophysics Division, who performed the photographic procedures.

CONTENTS

	<u>Page</u>
I. INTRODUCTION	7
II. MATERIALS AND METHODS	7
III. SUPERFICIAL AND DEEP DISSECTIONS	9
LITERATURE CITED	35
DISTRIBUTION LIST	37

LIST OF FIGURES

<u>Figure</u>		
1	Goat Suspended in Metal Frame	7
2	Superficial Musculature of the Domestic Goat (Left Lateral View)	9
3	Superficial Dissection of Face (Left Lateral View)	10
4	Deeper Dissection of Face (Left Lateral View)	11
5	Deepest Dissection of Face (Left Lateral View)	12
6	Superficial Dissection of Neck and Thoracic Region (Right Lateral View)	13
7	Deep Dissection of Neck and Thoracic Region (M Trapezius and M Brachiocephalicus Removed) (Right Lateral View)	14
8	Deeper Dissection of Neck and Thoracic Region (Right Lateral View)	15
9	Deeper Dissection of Neck and Thoracic Region (Right Lateral View)	16
10	Deepest Dissection of Neck and Thoracic Region (Right Lateral View)	17
11	Superficial Dissection of Head and Neck (Ventral Aspect)	18
12	Deeper Dissection of Head and Neck (Ventral Aspect)	19
13	Deepest Dissection of Head and Neck (Ventral Aspect)	20
14	Superficial Dissection of Right Pectoral Limb (Medial View)	21

CONTENTS (Contd)

<u>Figure</u>		<u>Page</u>
15	Deep Dissection of Right Pectoral Limb (Medial View)	22
16	Deeper Dissection of Right Pectoral Limb (Medial View)	23
17	Deeper Dissection of Right Pectoral Limb (Medial View)	24
18	Deepest Dissection of Right Pectoral Limb (Medial View)	25
19	Superficial Dissection of Right Pectoral Limb (Lateral View)	26
20	Deeper Dissection of Right Pectoral Limb (Lateral View)	27
21	Superficial Dissection of Left Pelvic Limb (Medial View)	28
22	Deep Dissection of Left Pelvic Limb (Medial View)	29
23	Deeper Dissection (Still) of Left Pelvic Limb (Medial View)	30
24	Deepest Dissection of Left Pelvic Limb (Medial View)	31
25	Superficial Dissection of Left Pelvic Limb (Lateral View)	32
26	Deeper Dissection of Left Pelvic Limb (Lateral View)	33
27	Deepest Dissection of Left Pelvic Limb (Lateral View)	34

ATLAS OF GOAT ANATOMY

PART III: MYOLOGY

I. INTRODUCTION.

The Angora goat (*Capra hircus*) has been the main experimental animal used by the Biophysics Division, Edgewood Arsenal, Maryland, for many years. Knowledge of goat anatomy is important during both the planning and experimental stages of projects. Because no readily usable information on goat anatomy is available, a series of reports on the subject is being prepared. The first in the series¹ described the skeletal anatomy. The second in the series² described the cross sections of the Angora goat. The present report concerns the muscles on superficial and deep dissection of the head, neck, and pectoral and pelvic limbs of the Angora goat. Part IV, Internal Organs, which will describe the structures of each organ, is near completion.

II. MATERIALS AND METHODS.

Three castrated Angora goats were used for dissecting purposes. Each goat was anesthetized with pentobarbital sodium. The goat was then suspended in a metal frame by ropes attached to the horns, tail, and nuchal ligaments with its feet just touching the floor of the frame (figure 1). This was done so that the goat would not be distorted.²




Figure 1. Goat Suspended in Metal Frame

¹ Hopkins, Clarence E., Sr., Hamm, Thomas E., Jr., and Leppart, Gary L. EATR 4431. Atlas of Goat Anatomy. Part I: Osteology. September 1970. UNCLASSIFIED Report.

² Hopkins, Clarence E., Sr., Hamm, Thomas E., Jr., and Leppart, Gary L. EATR 4626. Atlas of Goat Anatomy. Part II: Serial Cross Sections. April 1972. UNCLASSIFIED Report.

The goat was then exsanguinated through a polyethylene cannula (0.106-inch ID) placed in the carotid artery. The body was perfused with 12,000 ml of formalin solution passing through a gravity flow system from a stand 10 feet above the floor. This fluid was allowed to flow slowly through the system until the exiting fluid had a distinct odor of formalin.

The goat remained in the frame at room temperature until the next day. At that time the animal was dissected. After the skin was removed, each muscle was dissected and drawn. A total of 26 drawings was made while the dissection was taking place (figures 2 through 27).

The nomenclature prescribed in *Nomina Anatomica Veterinaria*³ was used for labeling the drawings. The anatomy books of Sisson and Grossman⁴ and May⁵ and the excellent book by Miller *et al.*⁶ were also used as references during preparation of this atlas.

³ *Nomina Anatomica Veterinaria*. Department of Anatomy, New York State Veterinary College, Ithaca, New York. 1968.

⁴ Sisson, S., and Grossman, J. D. *Anatomy of Domestic Animals*. 4th Ed. W. B. Saunders Company, Philadelphia, Pennsylvania. 1953.

⁵ May, N. *Anatomy of Sheep*. 2d Ed. University of Queensland Press, Wilke Company, Australia. 1964.

⁶ Miller, M. E., Christensen, G. C., and Evans, H. E. *Anatomy of Dog*. W. B. Saunders Company, Philadelphia, Pennsylvania. 1964.

III. SUPERFICIAL AND DEEP DISSECTIONS.

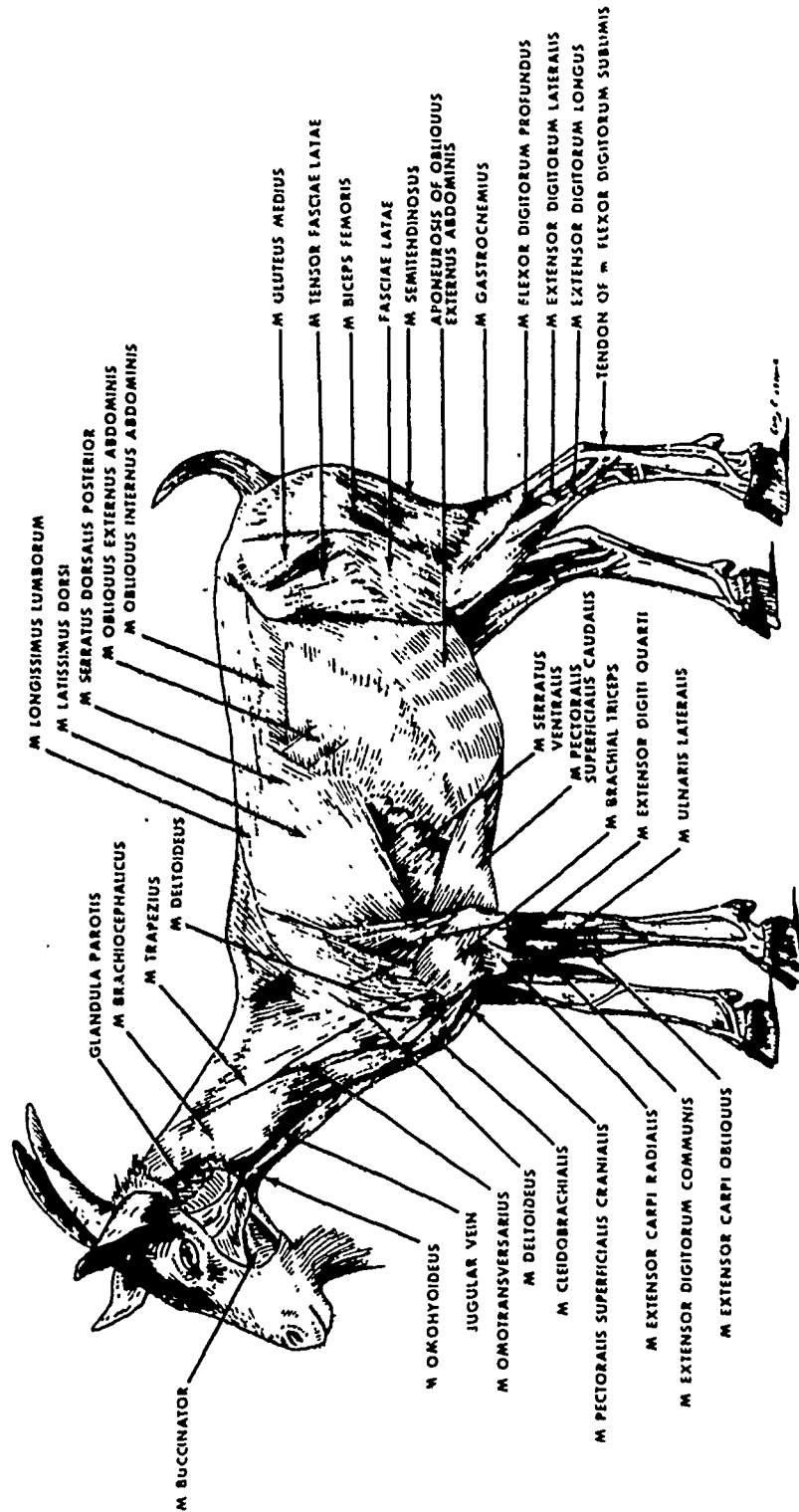


Figure 2. Superficial Musculature of the Domestic Goat (Left Lateral View)

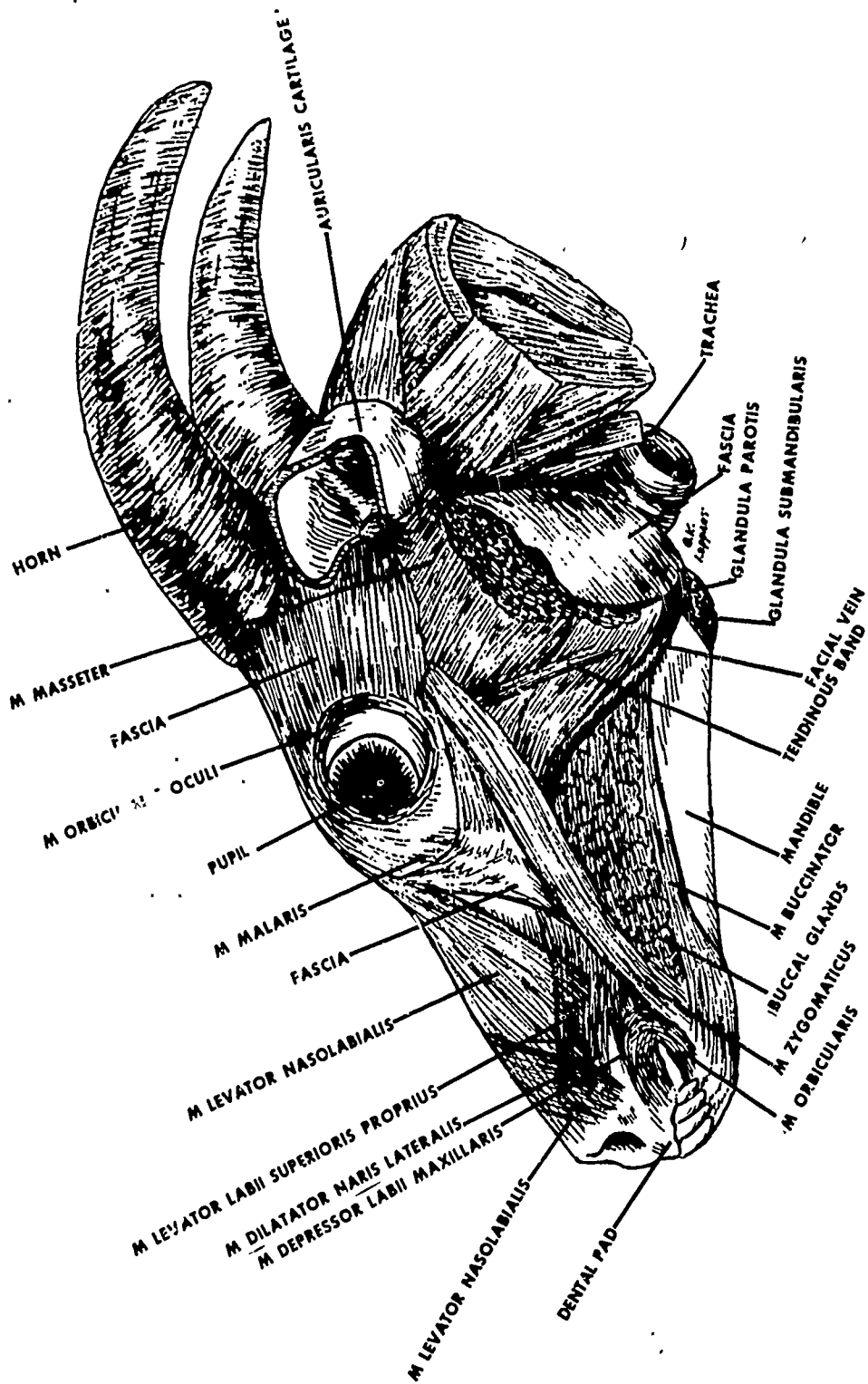


Figure 3. Superficial Dissection of Face (Left Lateral View)

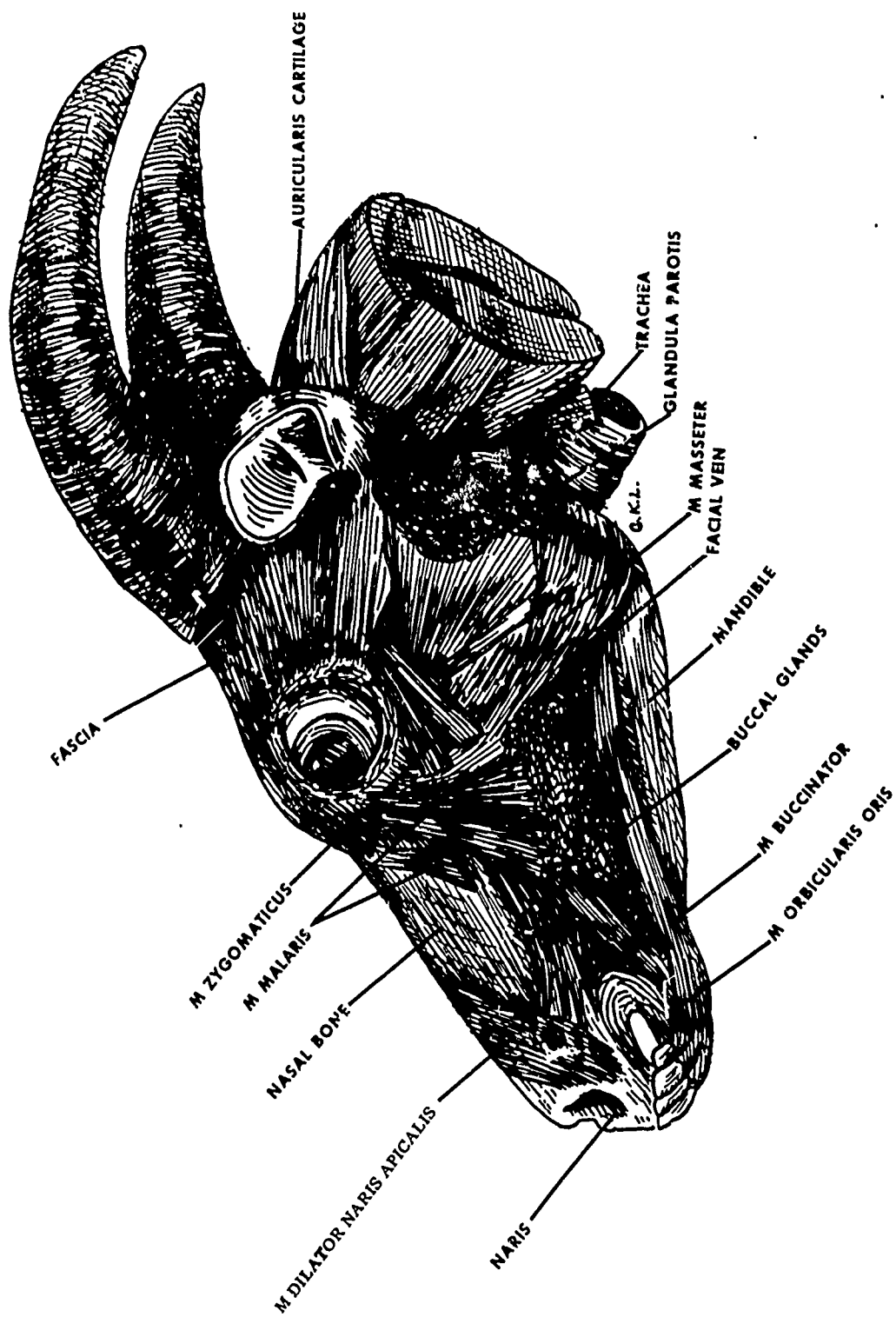


Figure 4. Deeper Dissection of Face
(Left Lateral View)

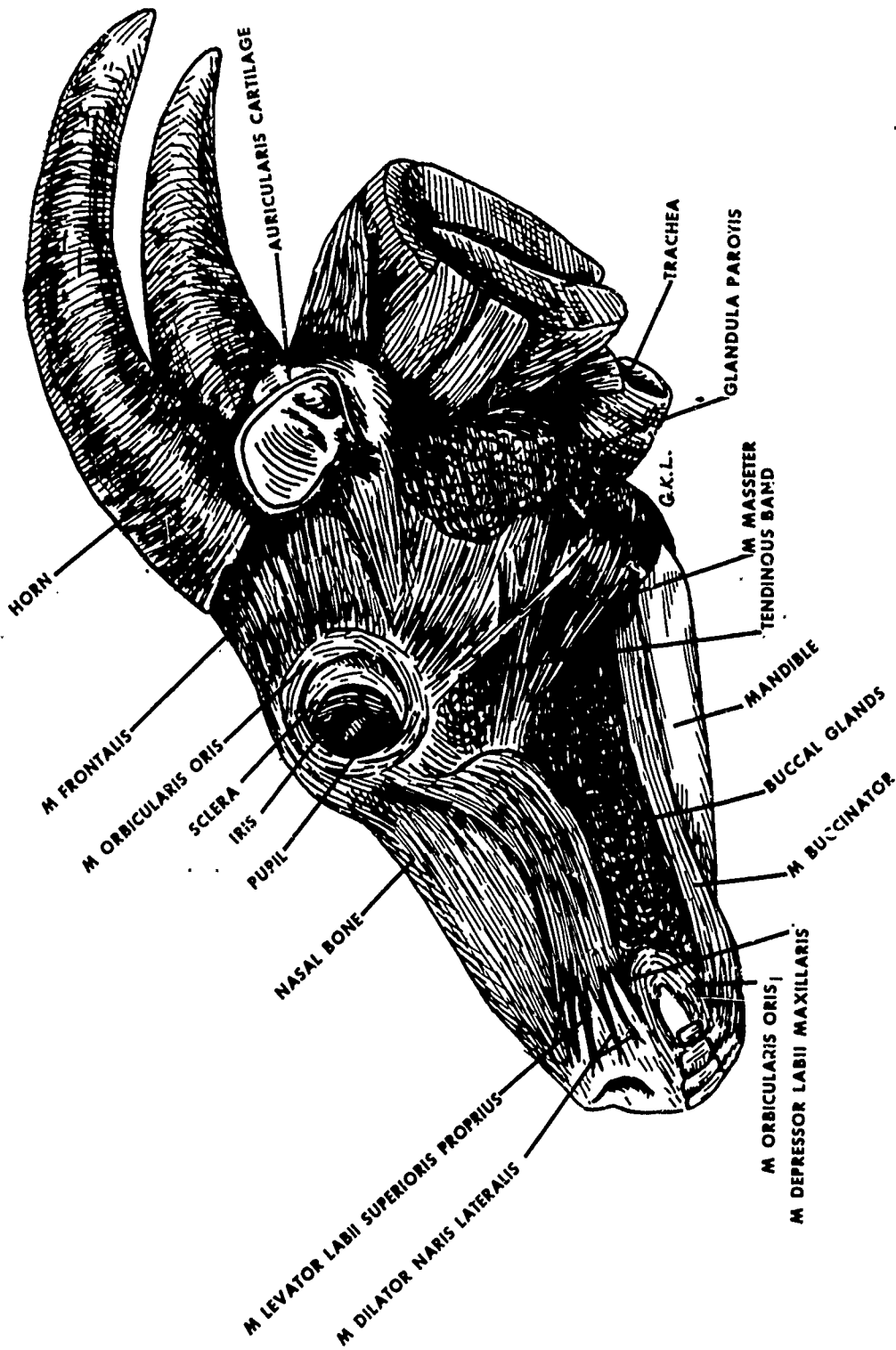


Figure 5. Deepest Dissection of Face
(Left Lateral View)

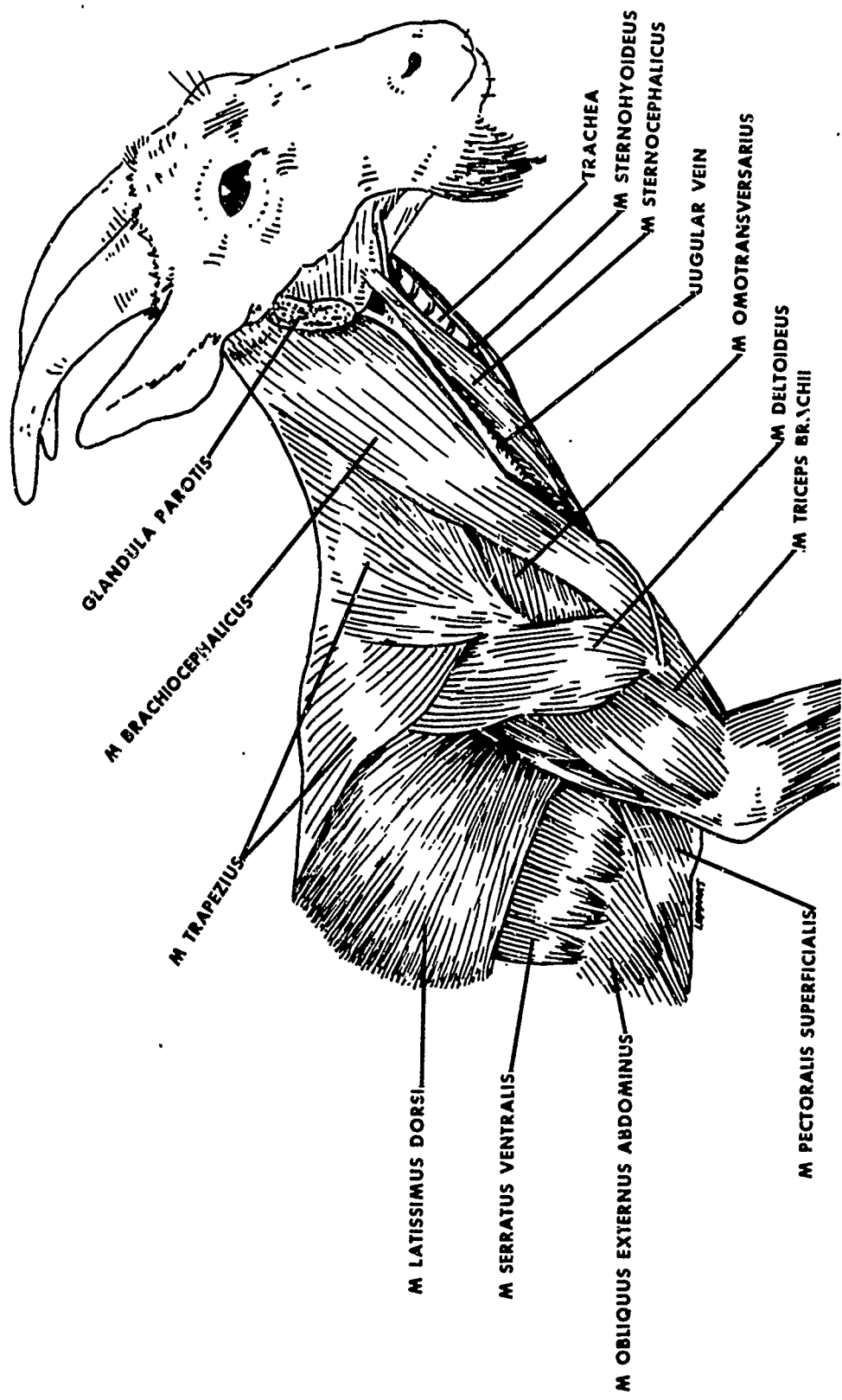


Figure 6. Superficial Dissection of Neck and Thoracic Region (Right Lateral View)

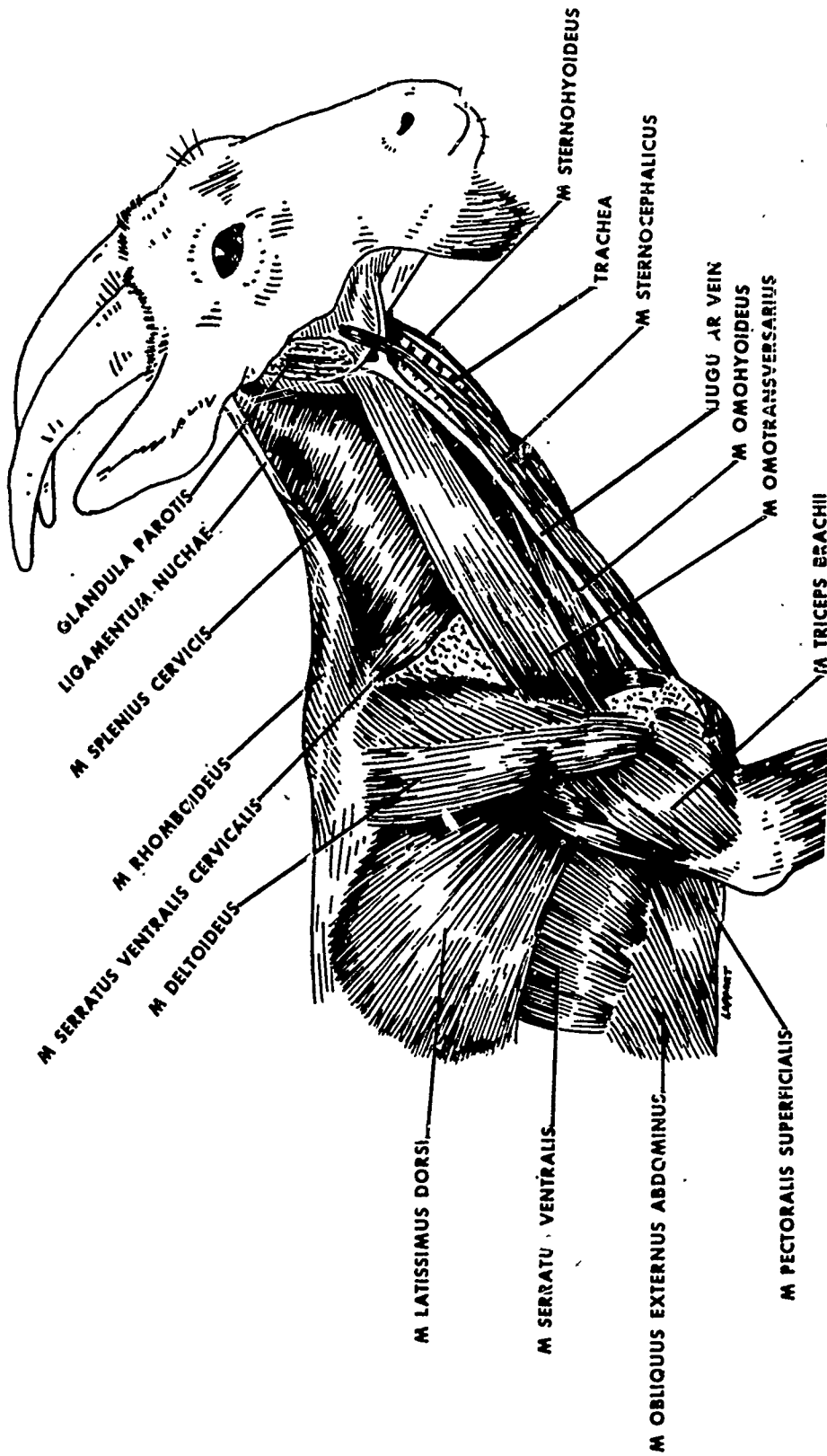


Figure 7. Deep Dissection of Neck and Thoracic Region
 (M. Trapezius and M. Brachiocephalicus Removed)
 (Right Lateral View)

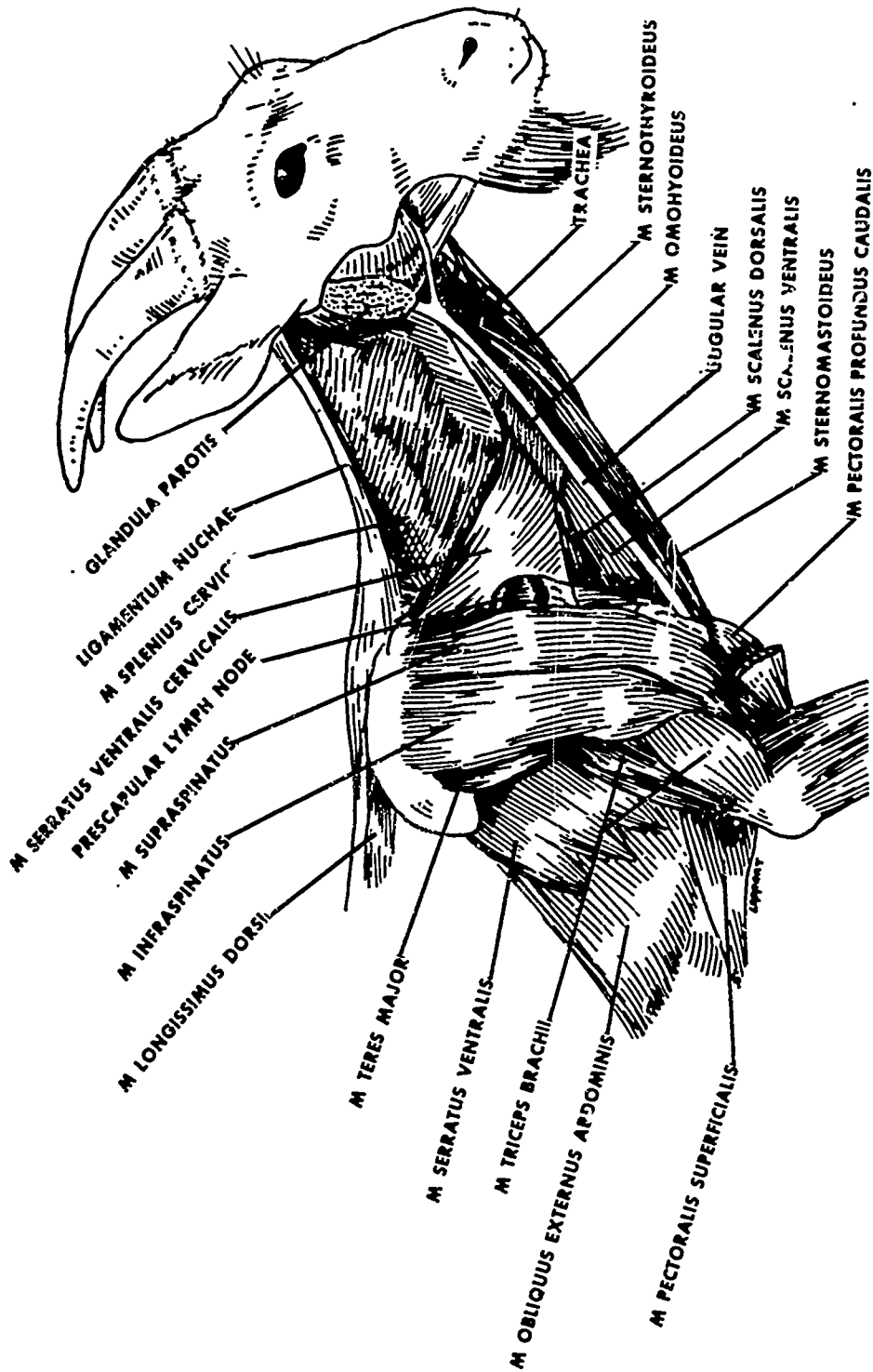


Figure 8. Deeper Dissection of Neck and Thoracic Region
(Right Lateral View)

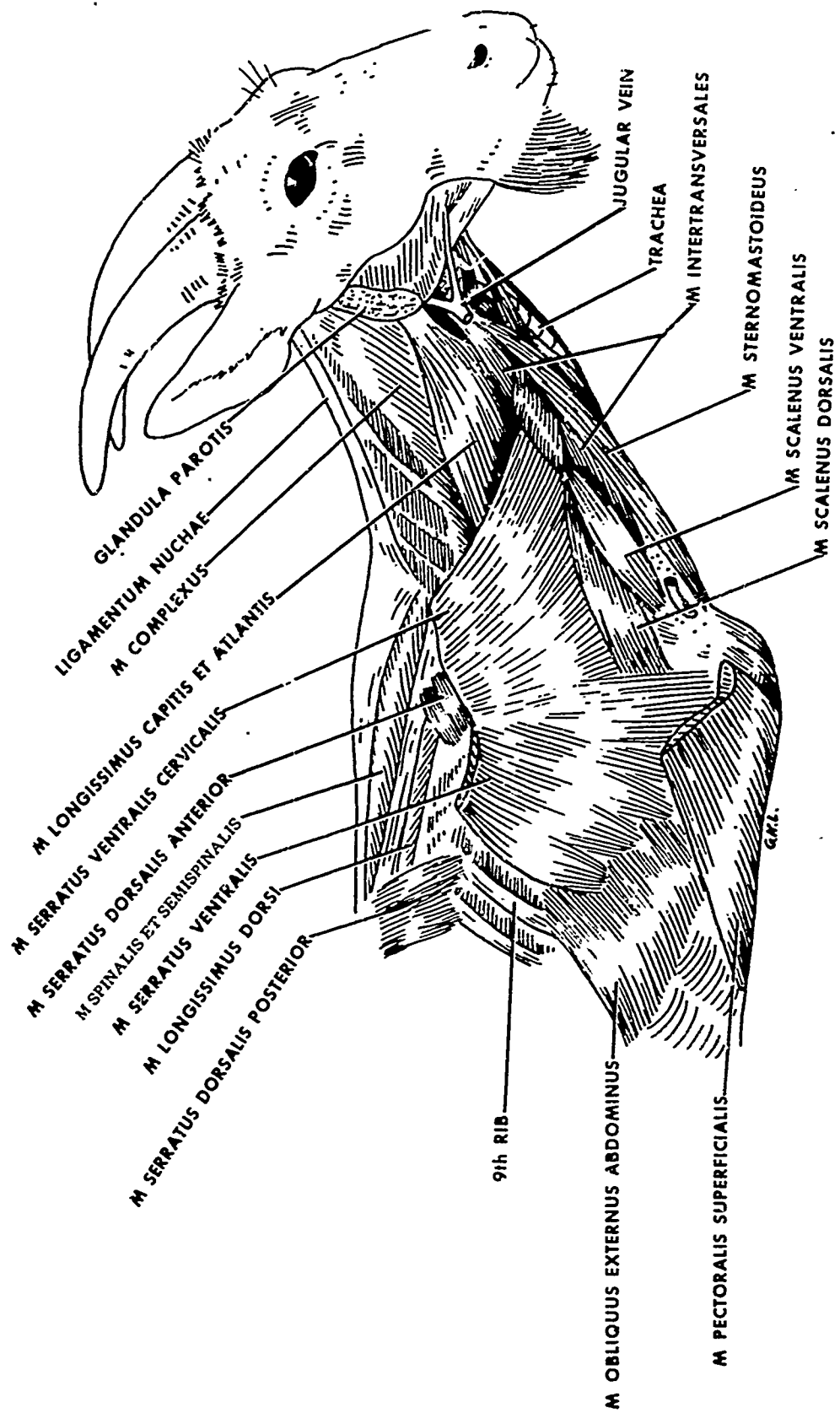


Figure 9. Deeper Dissection of Neck and Thoracic Region
(Right Lateral View)

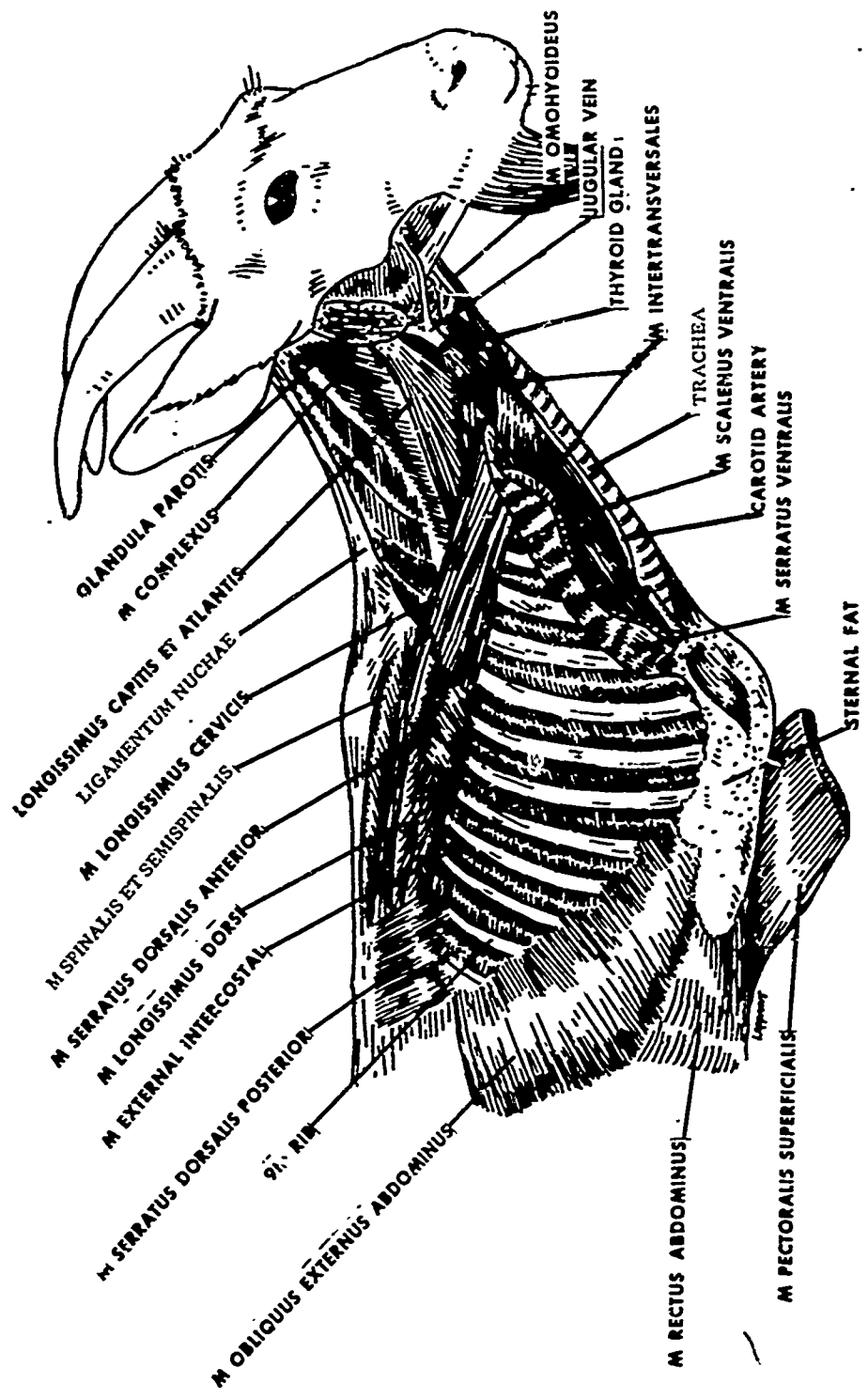


Figure 10. Deepest Dissection of Neck and Thoracic Region
(Right Lateral View)

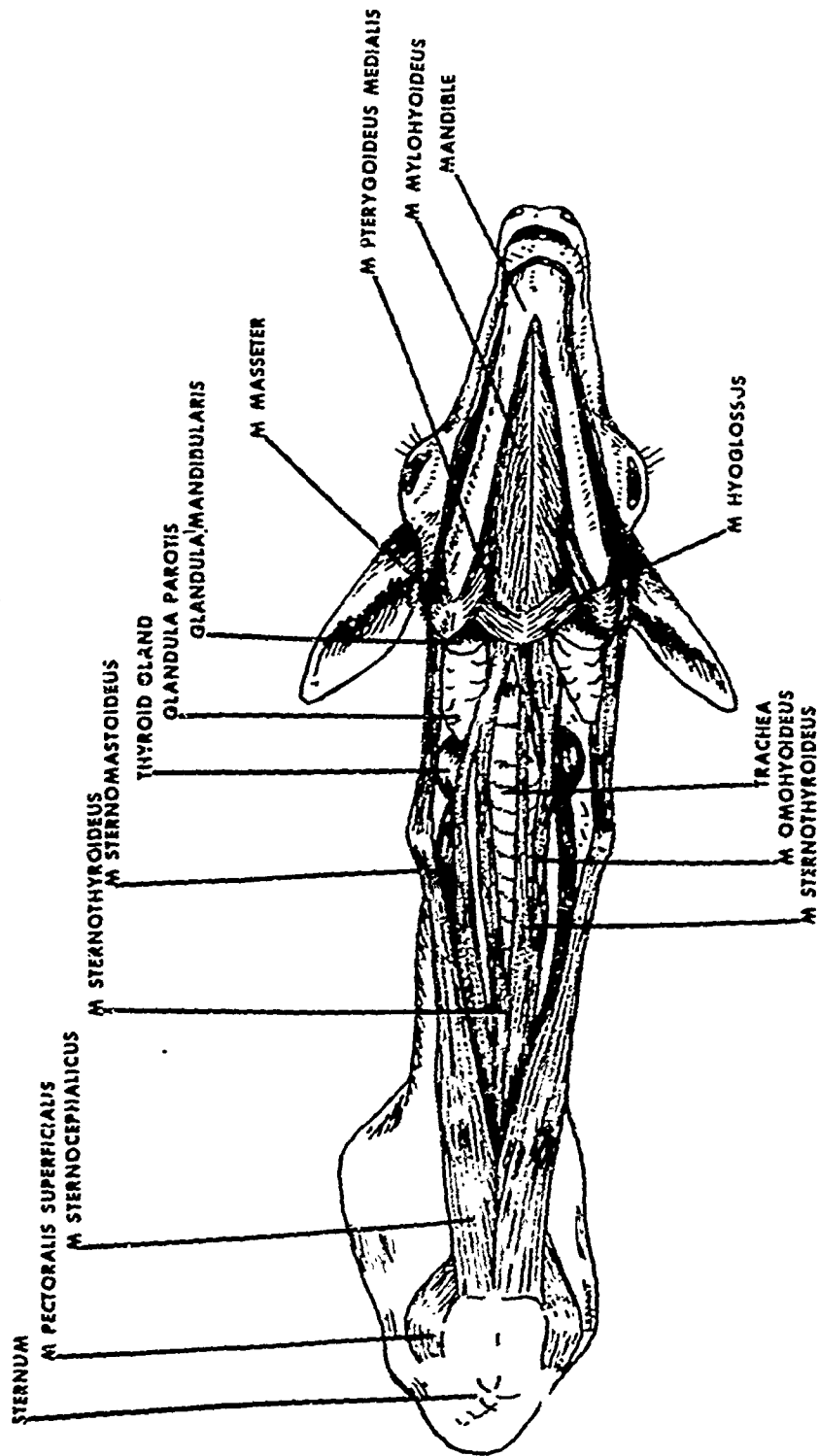


Figure 11. Superficial Dissection of Head and Neck
(Ventral Aspect)

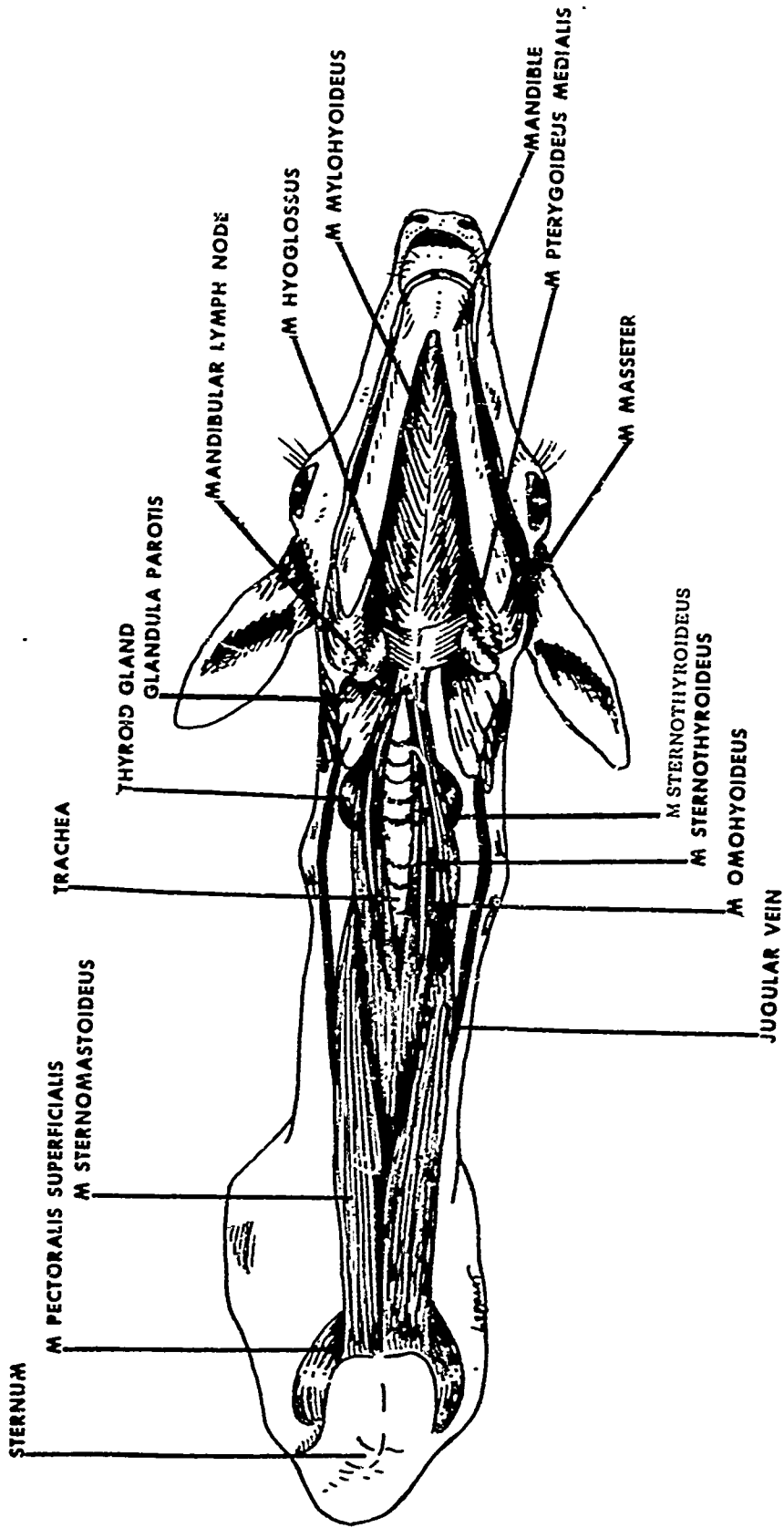


Figure 12. Deeper Dissection of Head and Neck (Ventral Aspect)

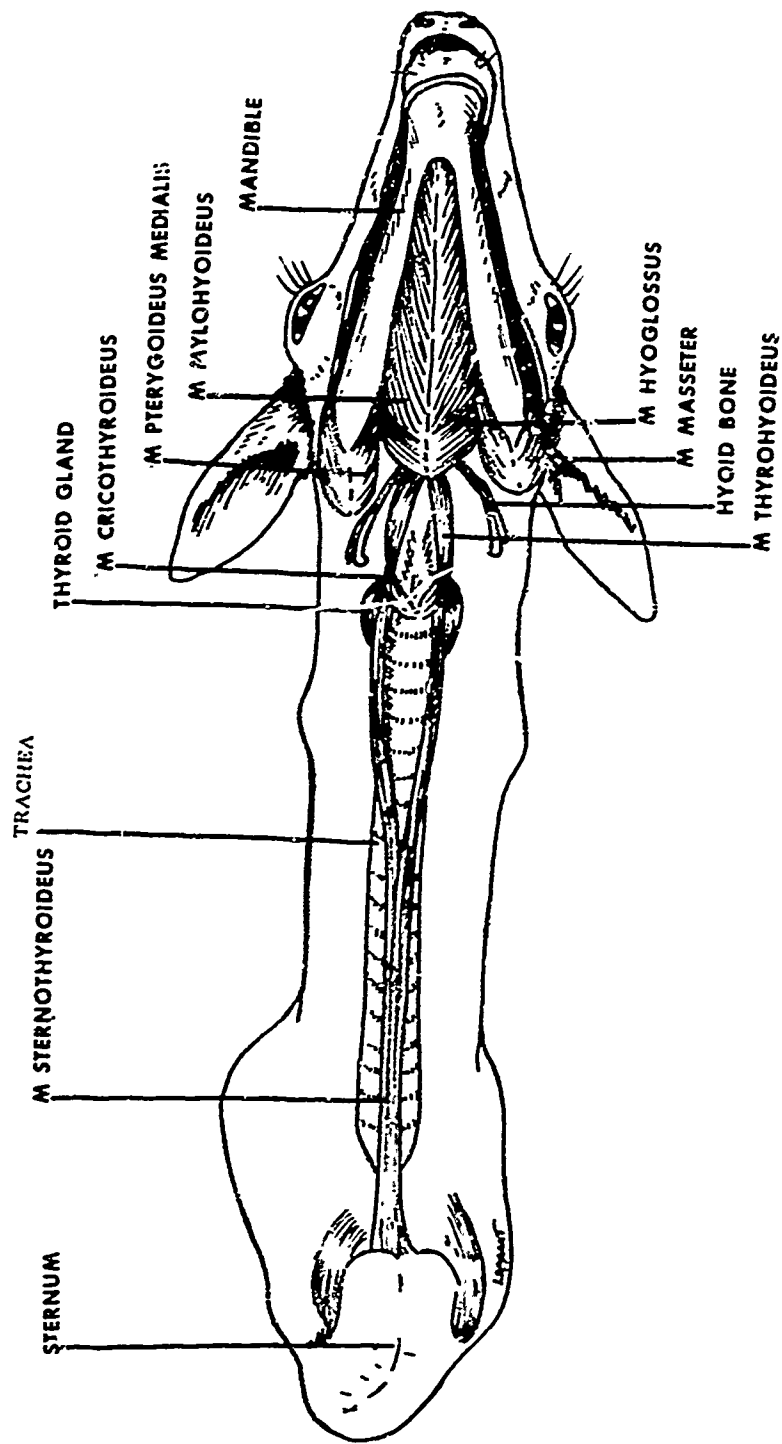


Figure 13. Deepest Dissection of Head and Neck (Ventral Aspect)

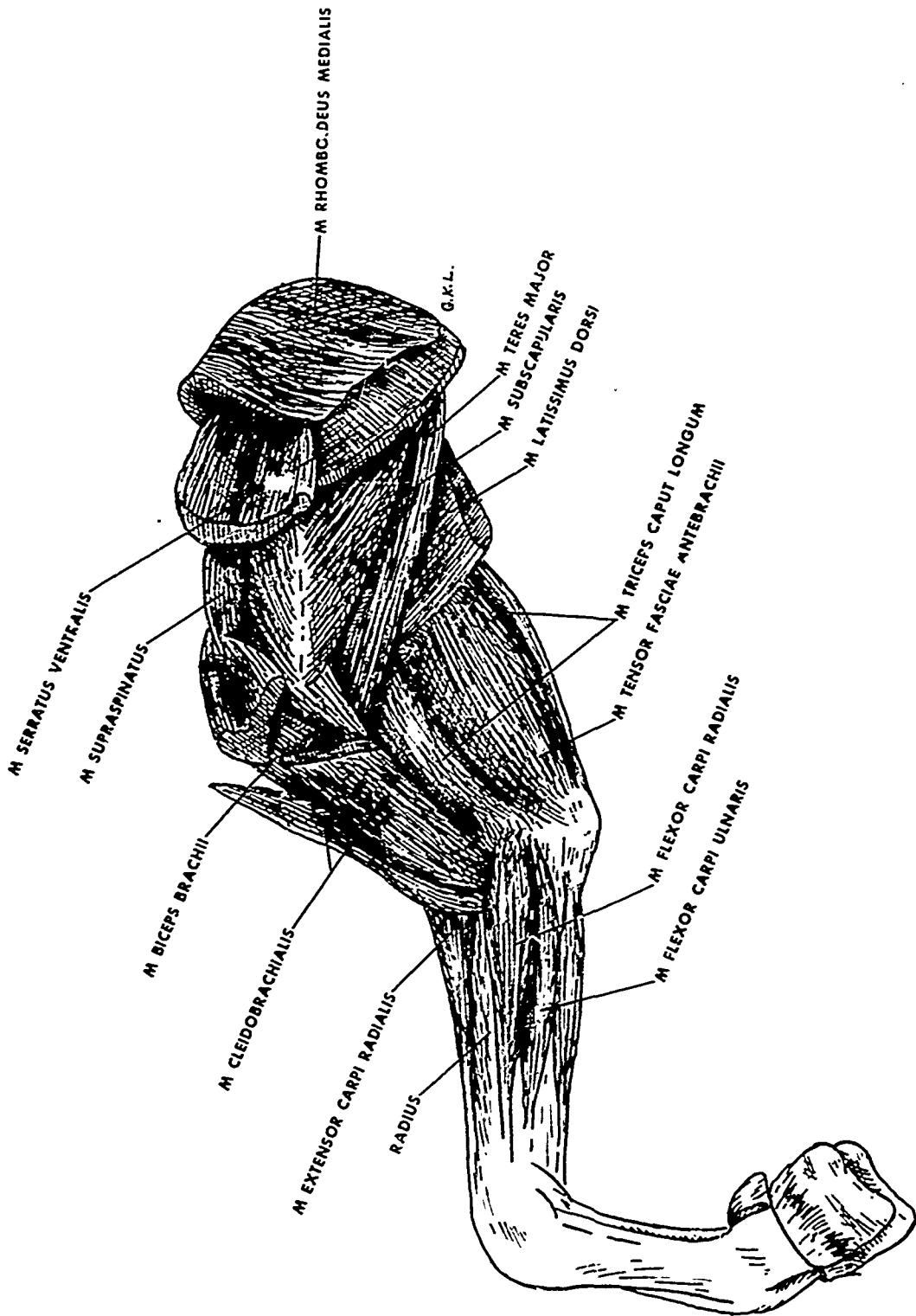


Figure 14. Superficial Dissection of Right Pectoral Limb
(Medial View)

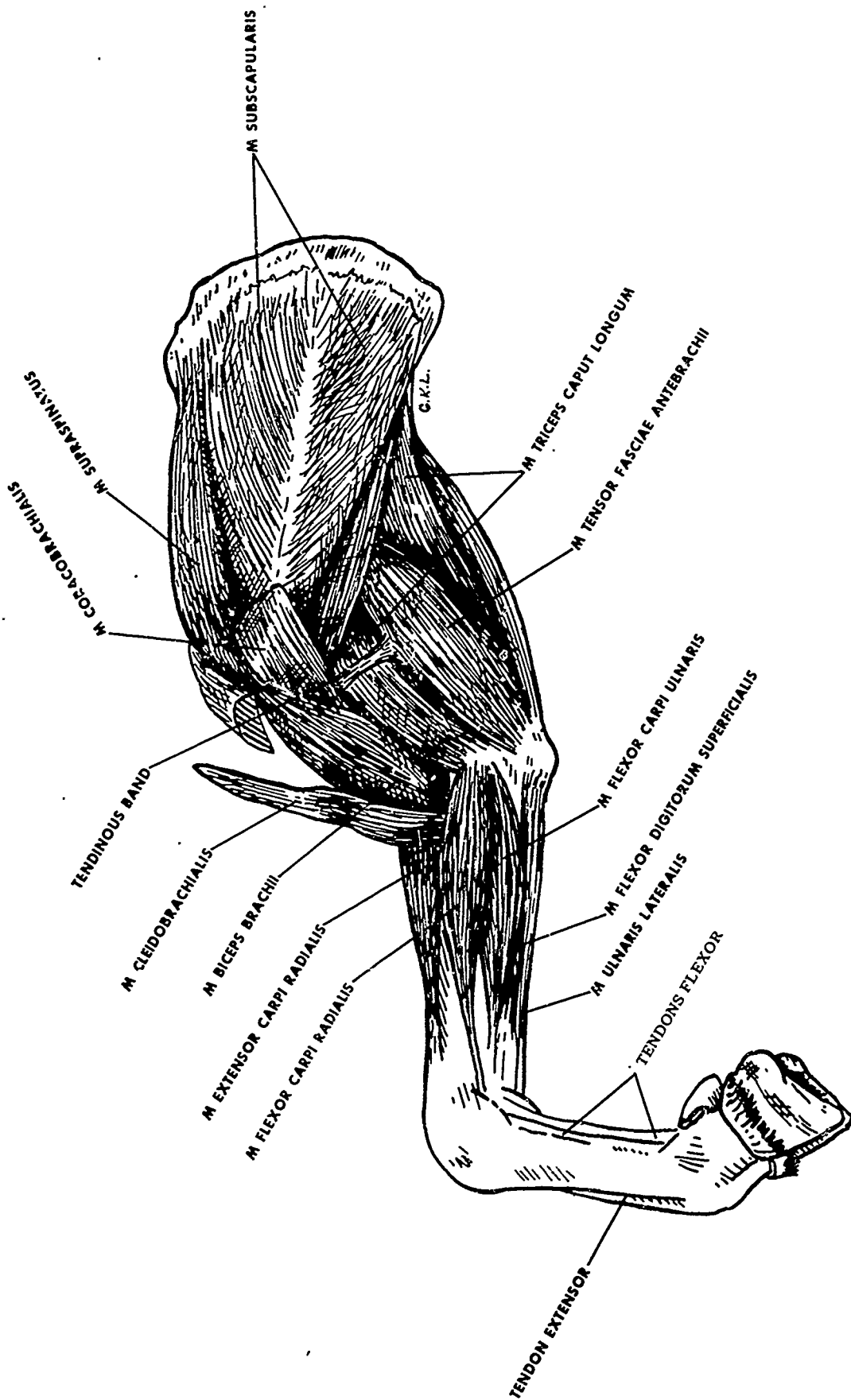


Figure 15. Deep Dissection of Right Pectoral Limb
(Medial View)

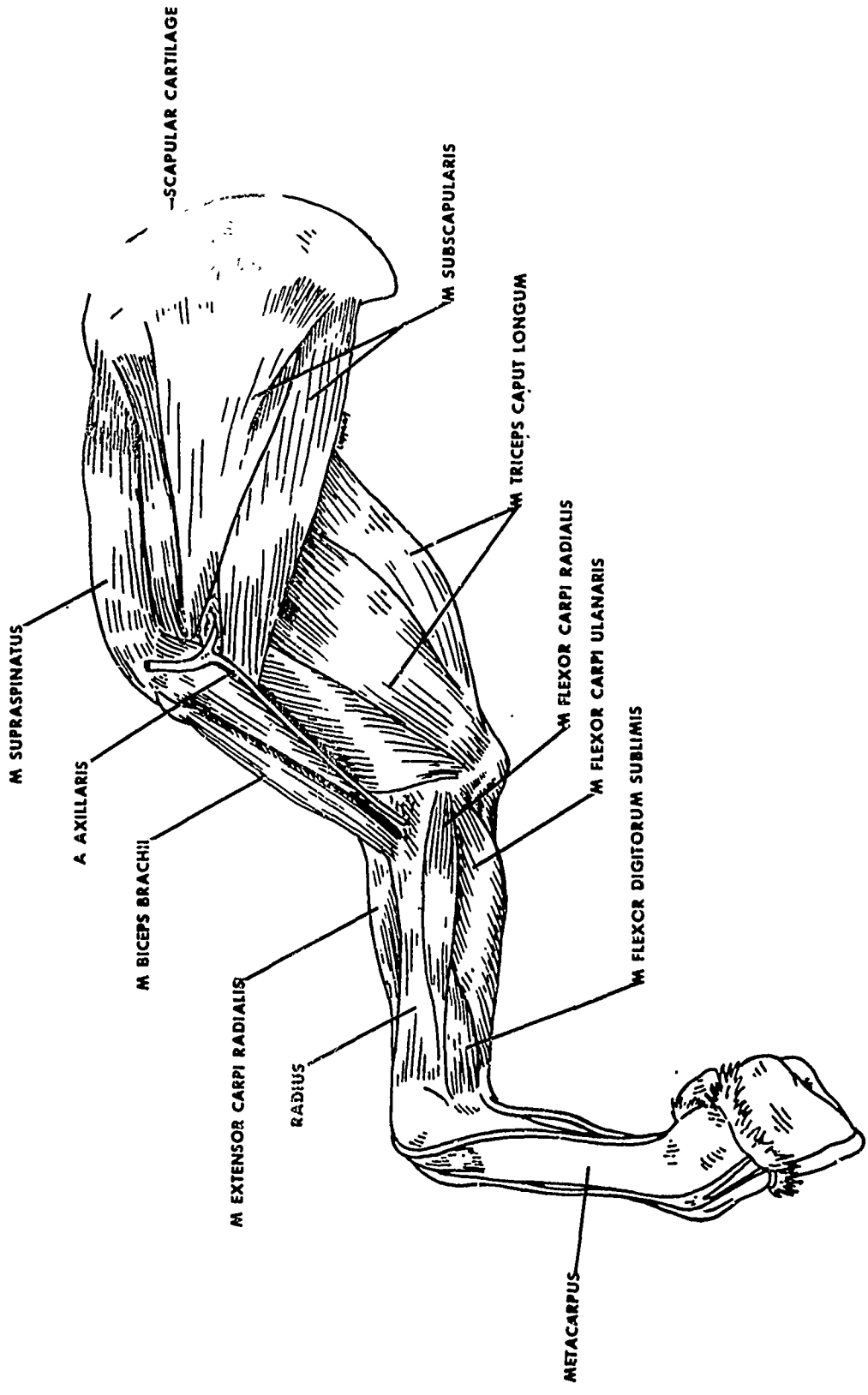


Figure 16. Deeper Dissection of Right Pectoral Limb (Medial View)

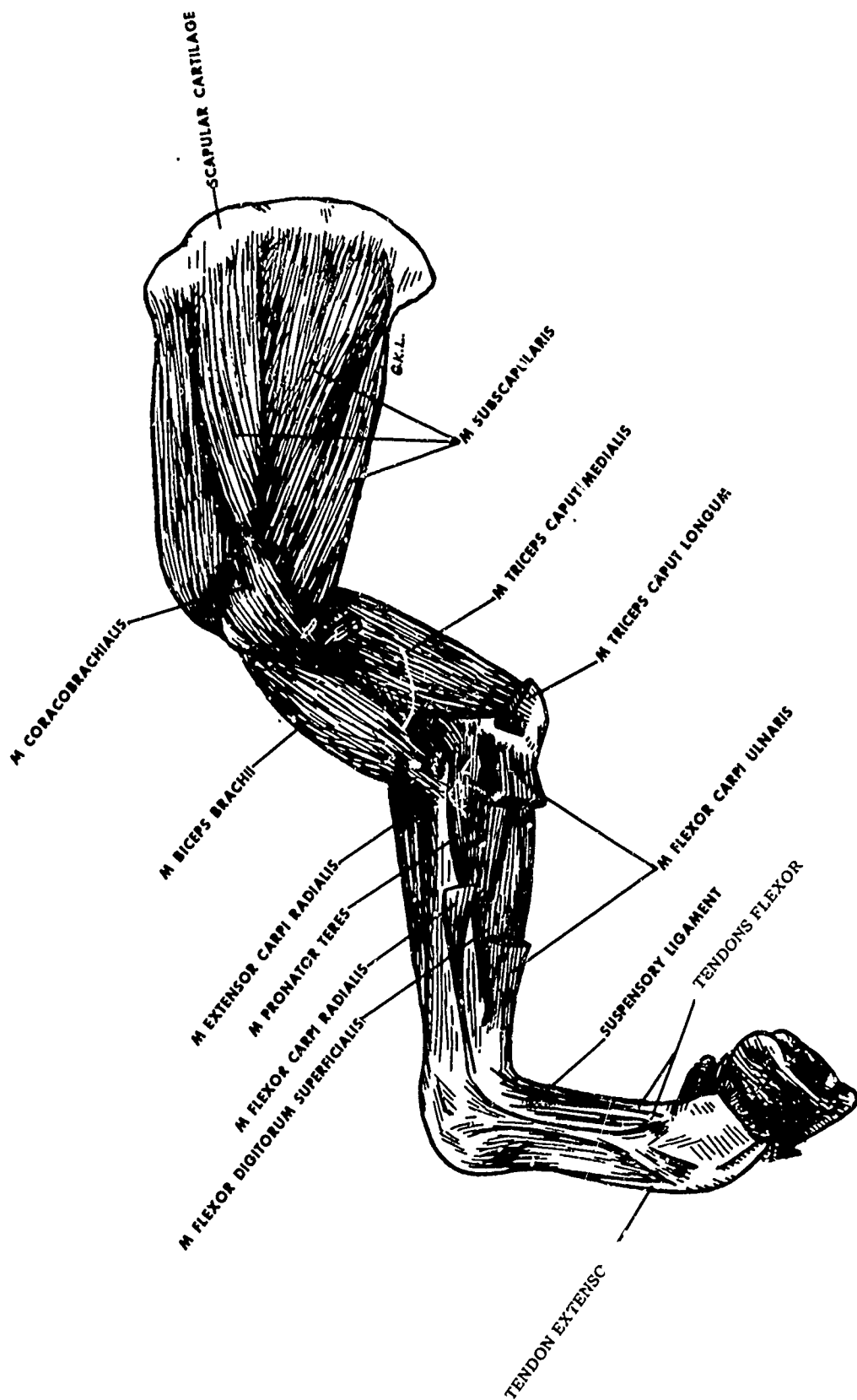


Figure 17. Deeper Dissection of Right Pectoral Limb
(Medial View)

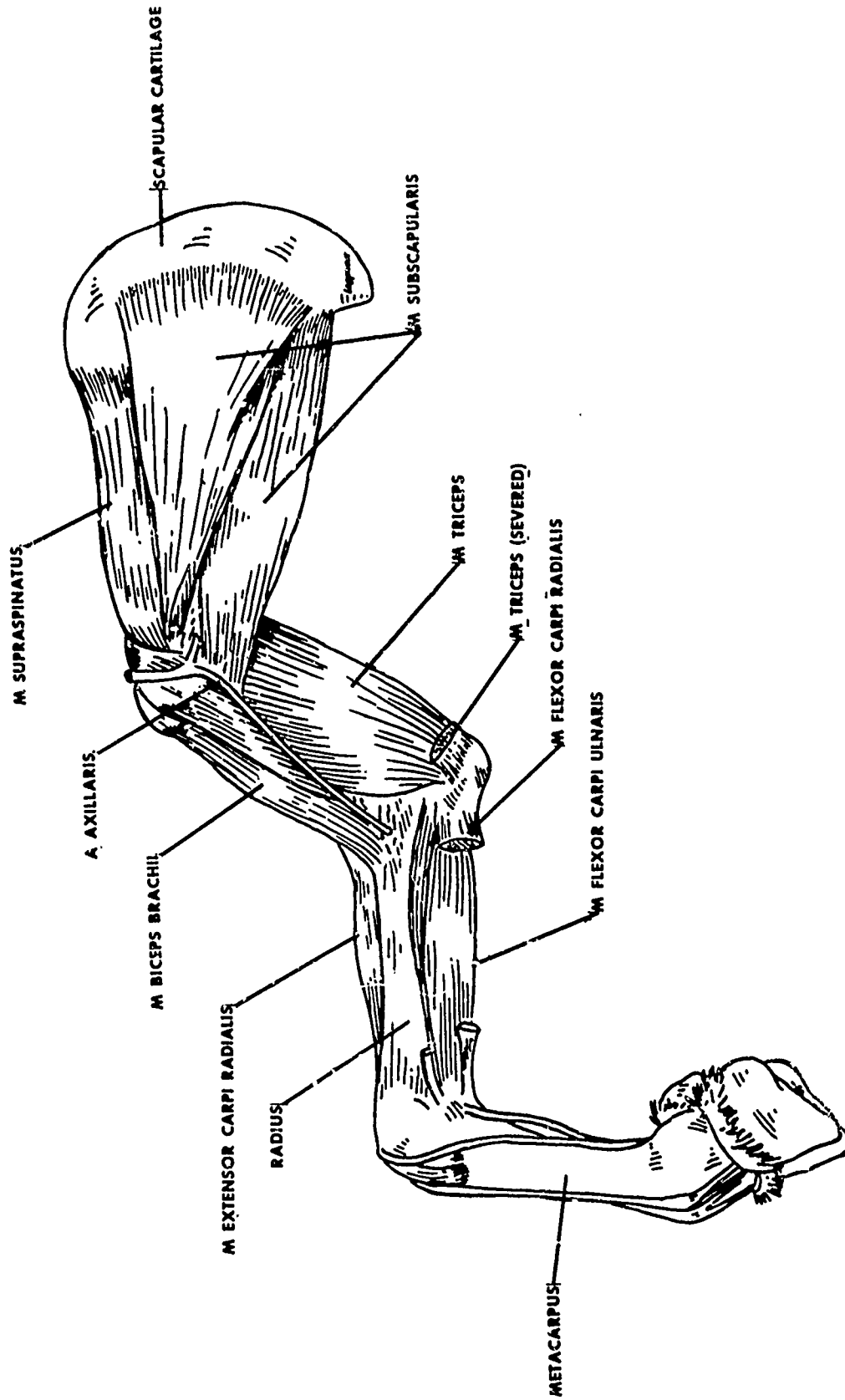


Figure 18. Deepest Dissection of Right Pectoral Limb (Medial View)

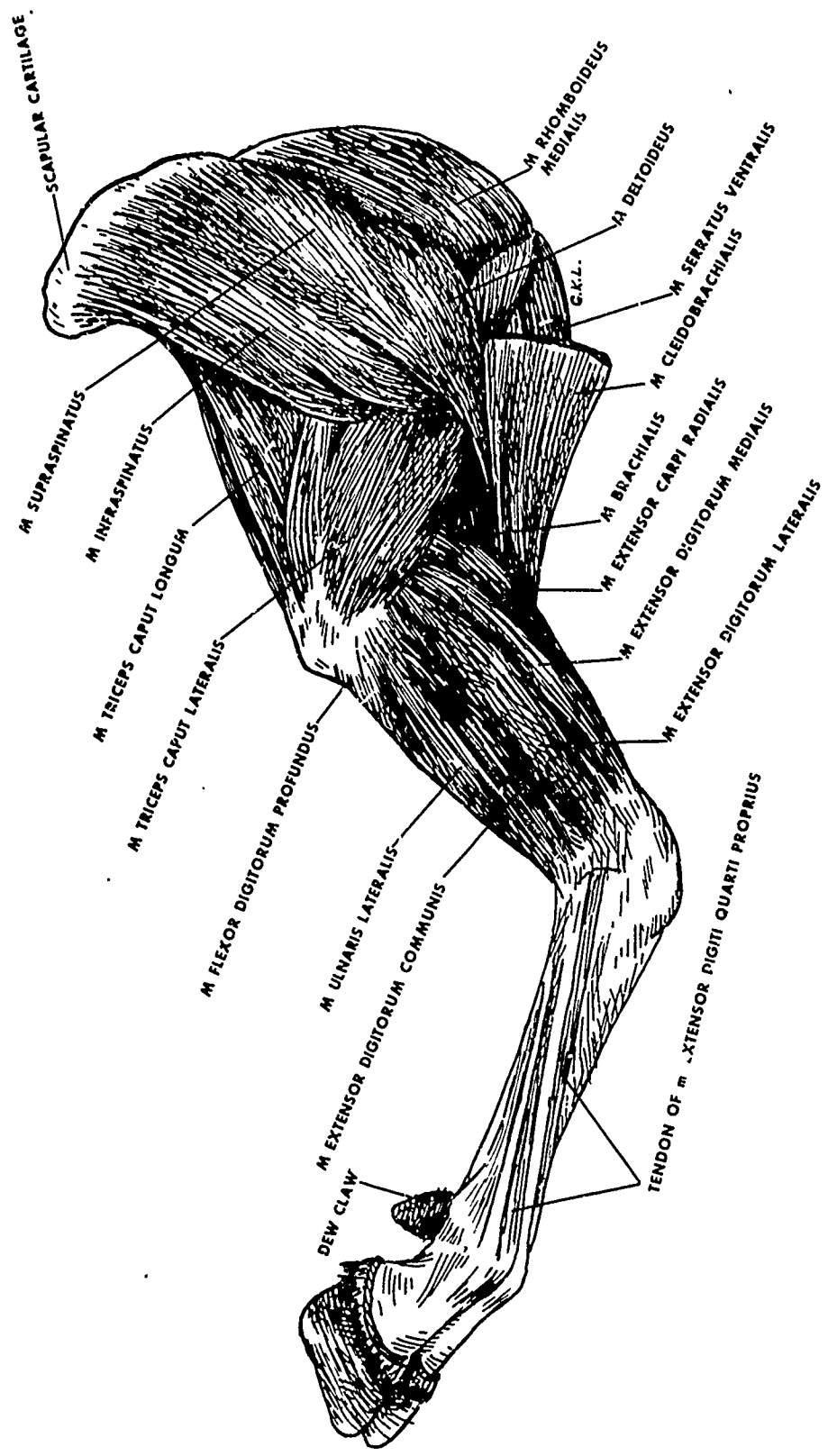


Figure 19. Superficial Dissection of Right Pectoral Limb
(Lateral View)

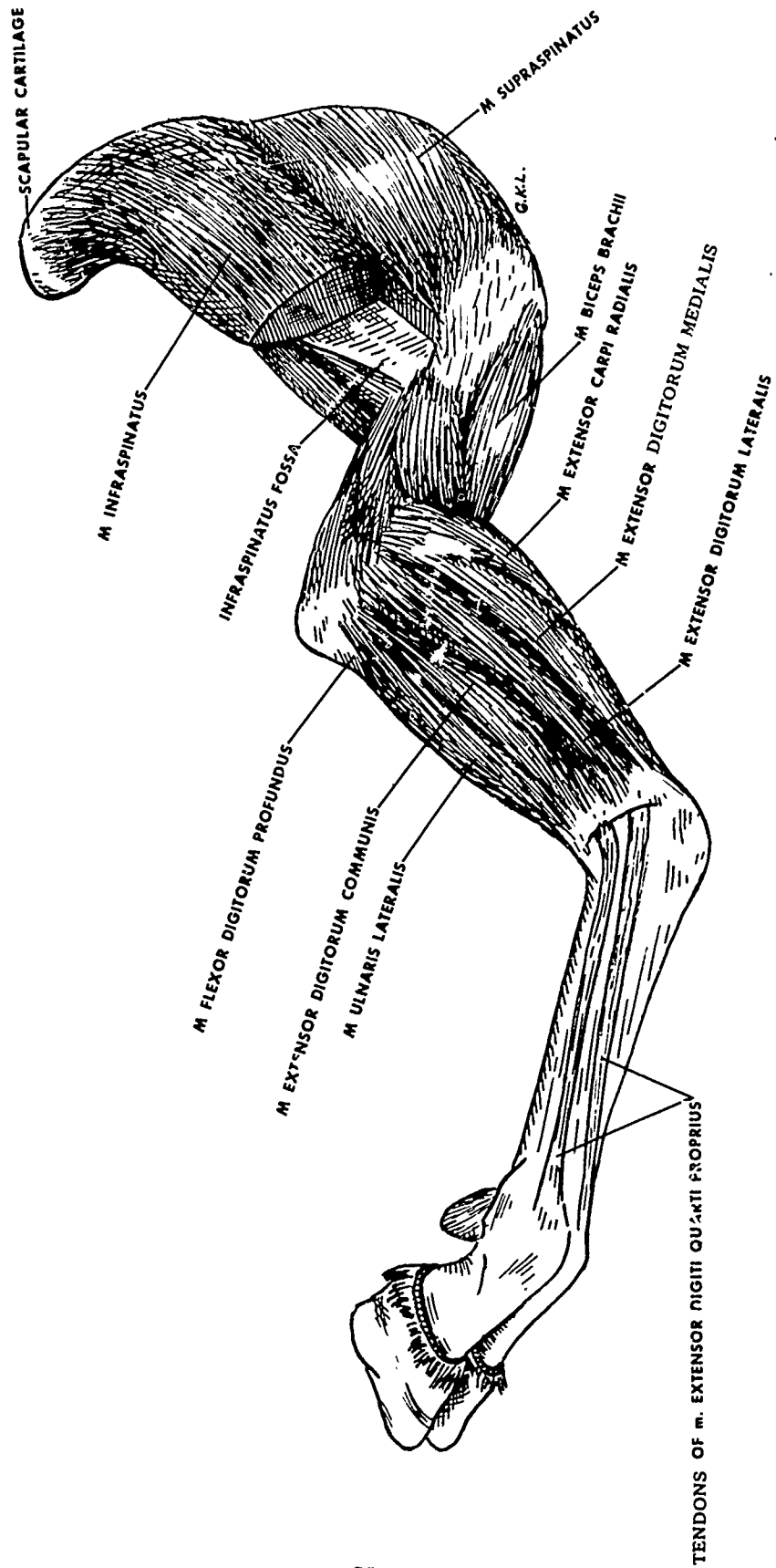


Figure 20. Deeper Dissection of Right Pectoral Limb (Lateral View)

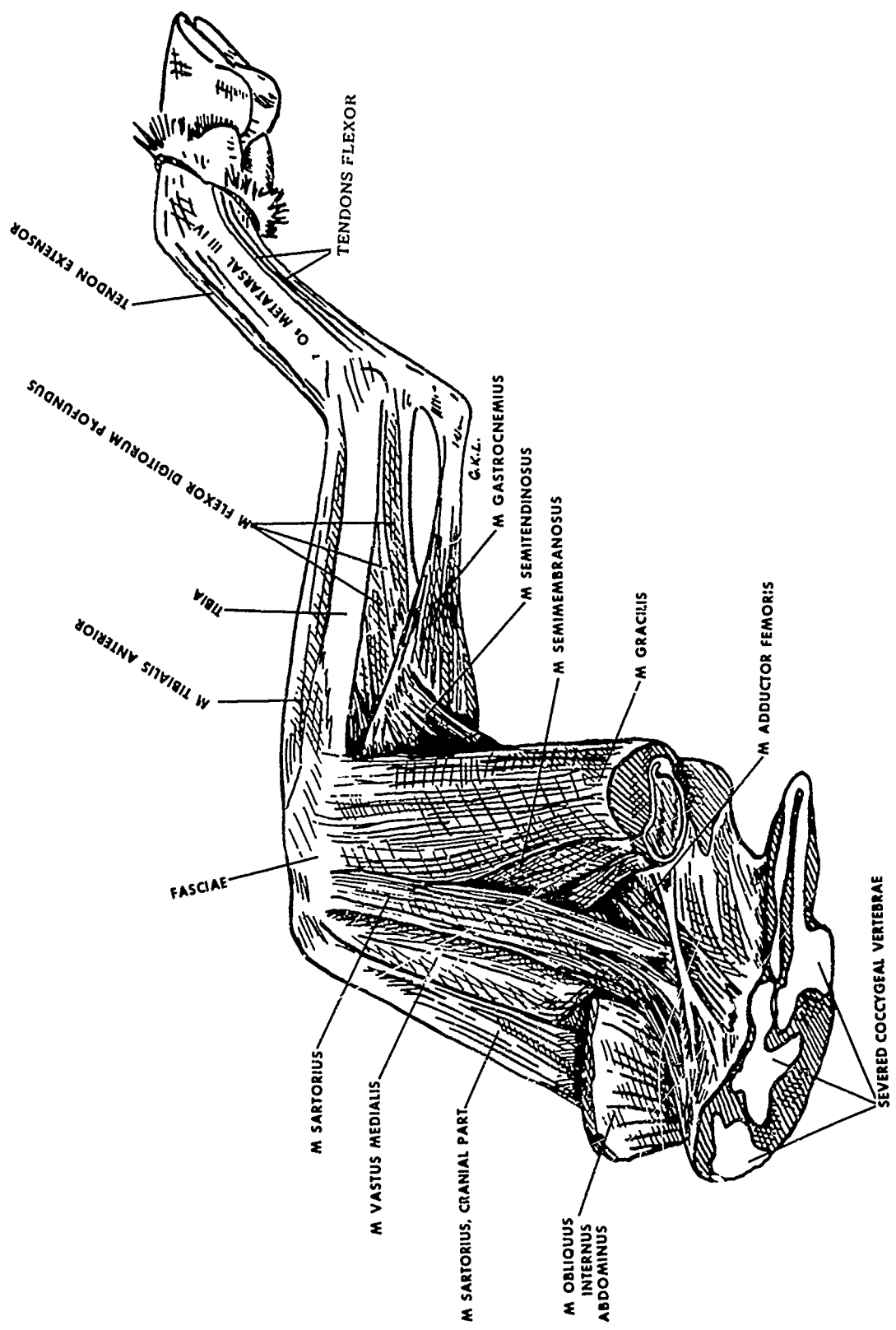


Figure 21. Superficial Dissection of Left Pelvic Limb (Medial View)

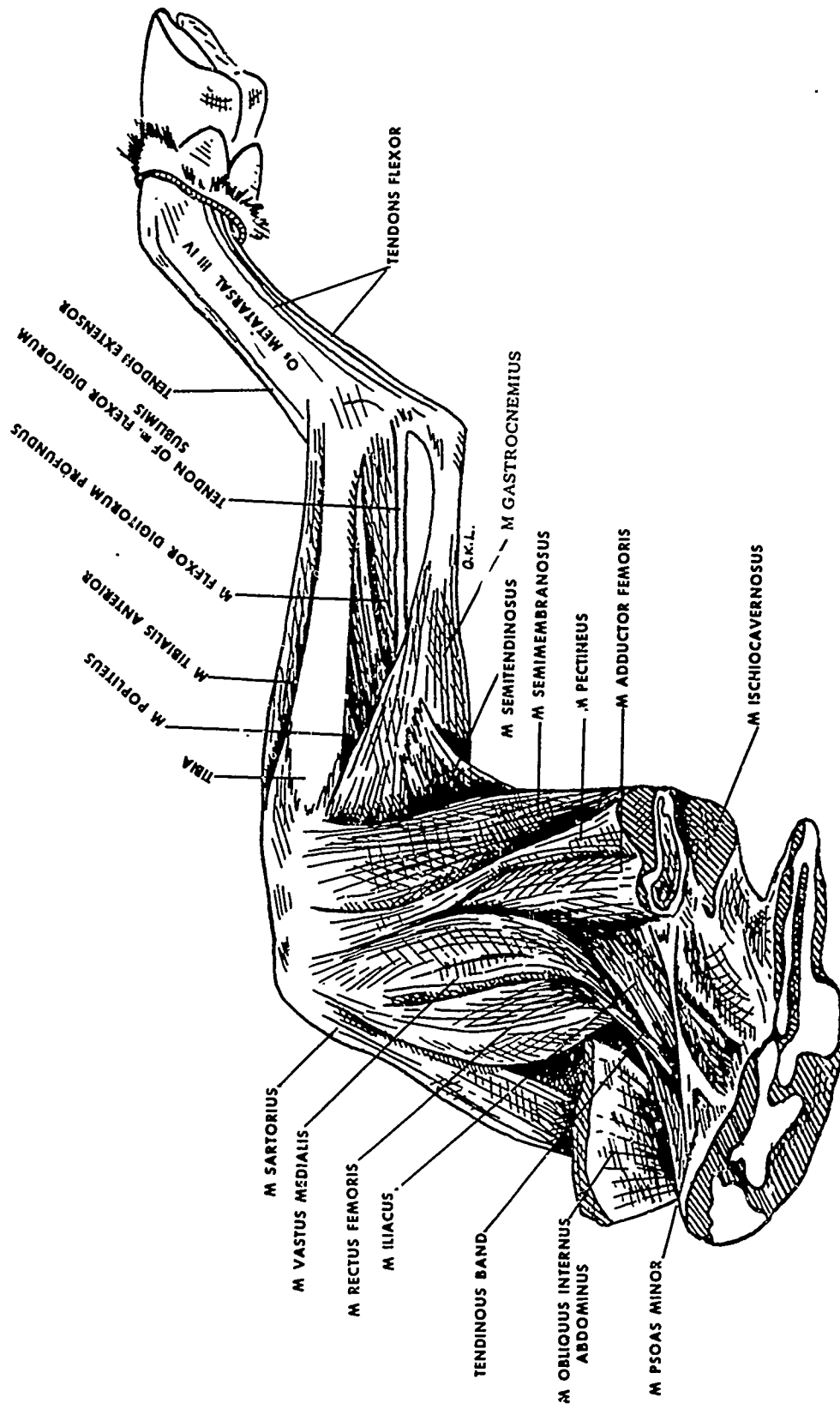


Figure 22. Deep Dissection of Left Pelvic Limb (Medial View)

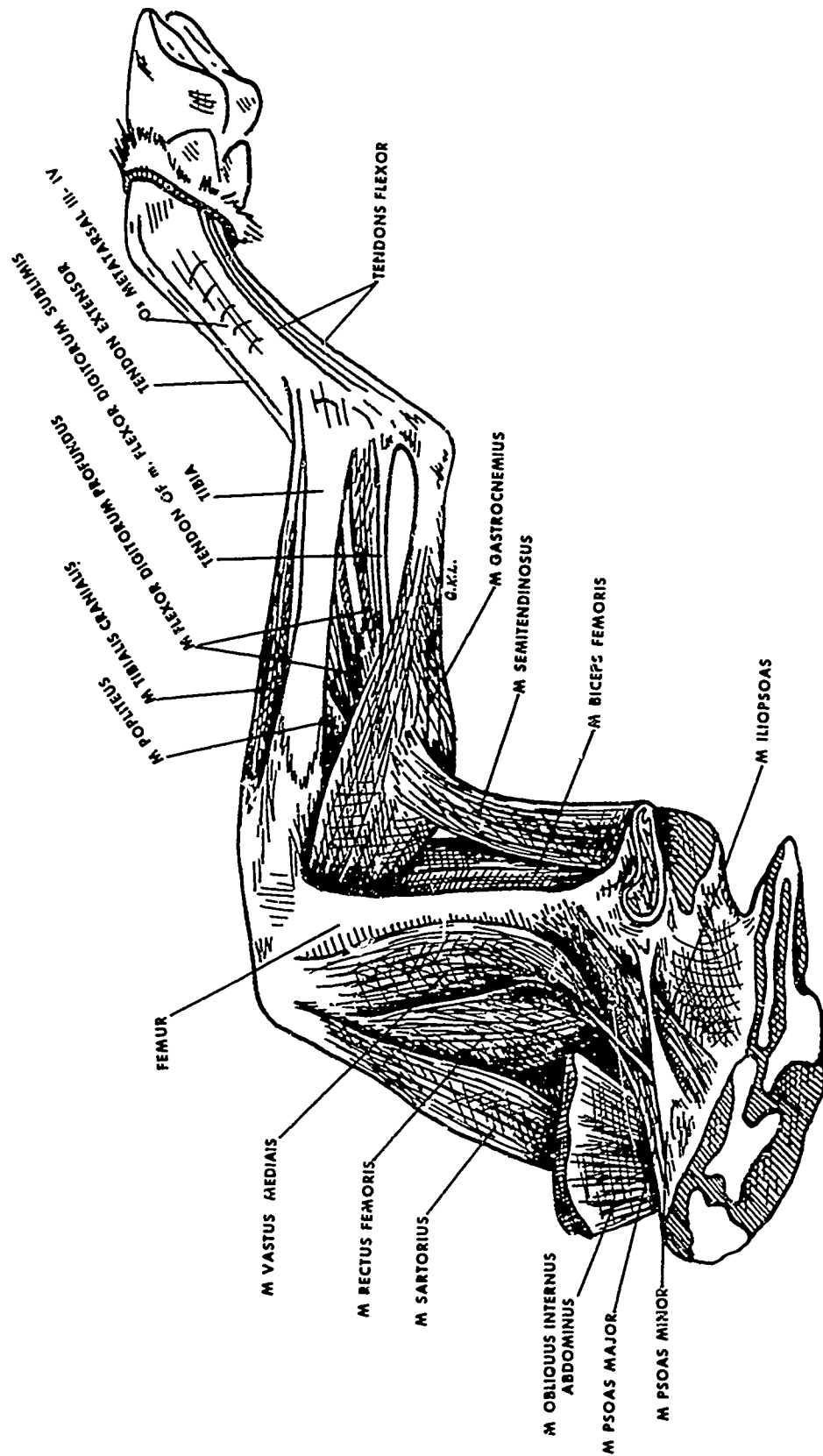


Figure 23. Deeper Dissection (Still) of Left Pelvic Limb (Medial View)

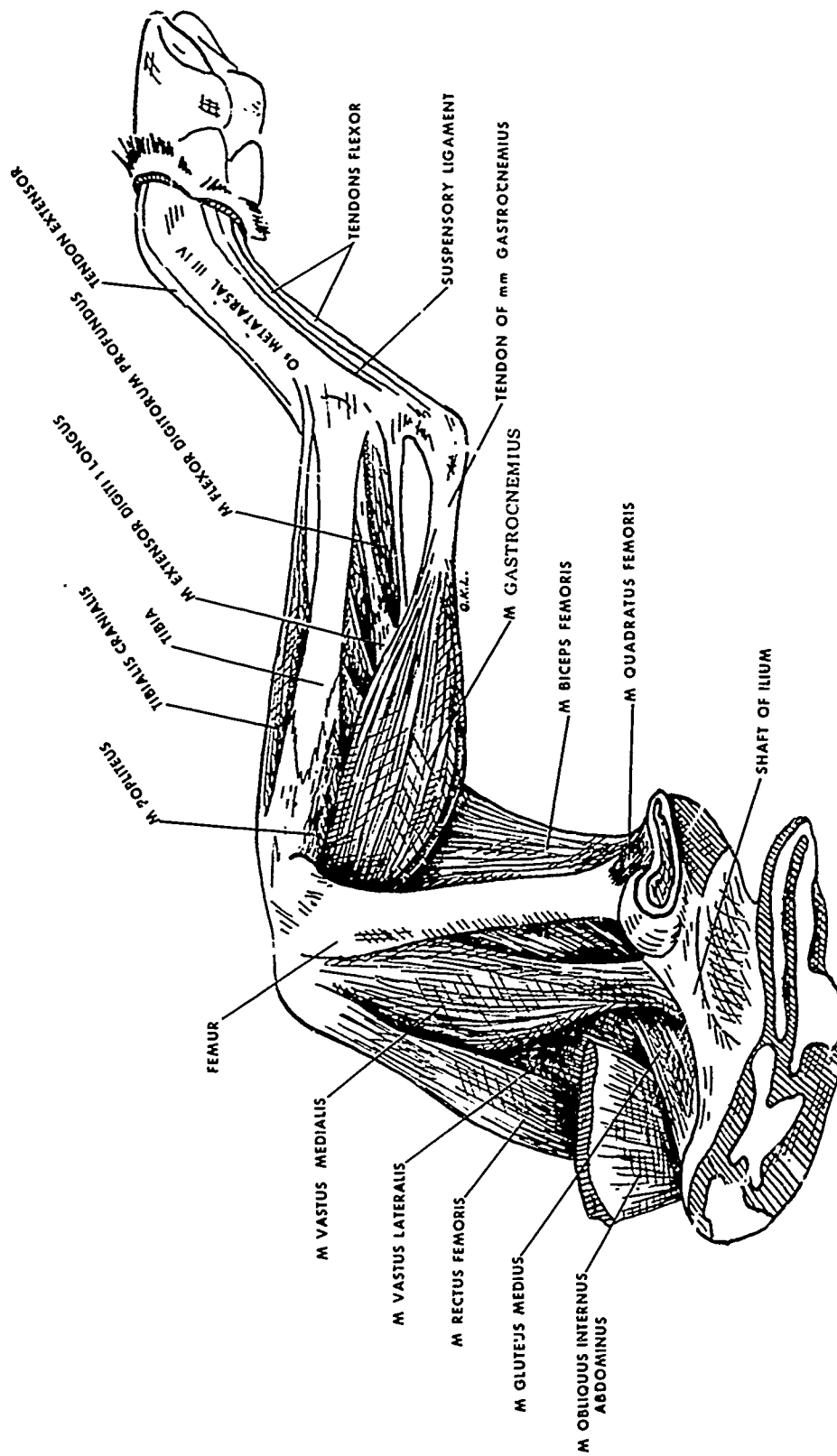


Figure 24. Deepest Dissection of Left Pelvic Limb (Medial View)

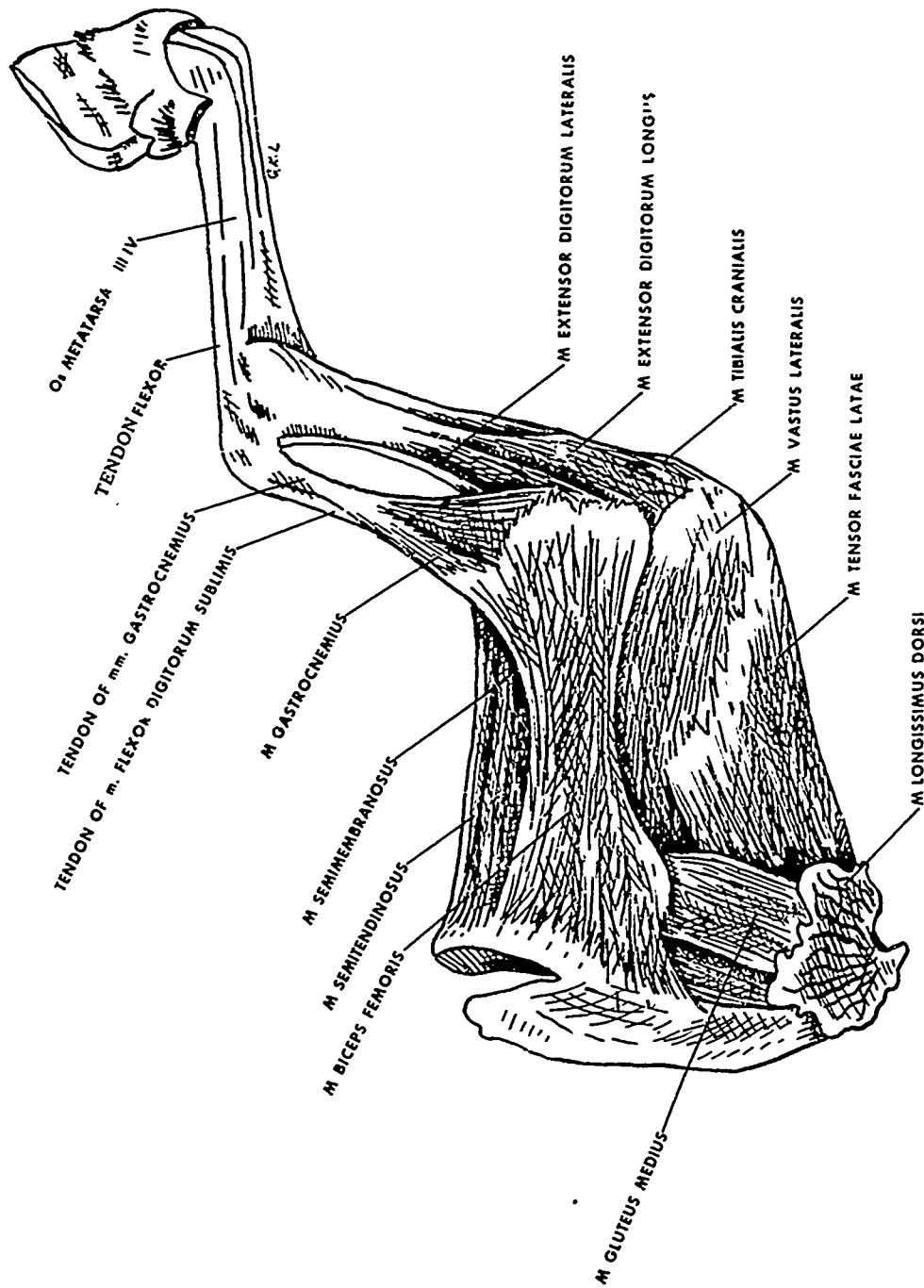


Figure 25. Superficial Dissection of Left Pelvic Limb (Lateral View)

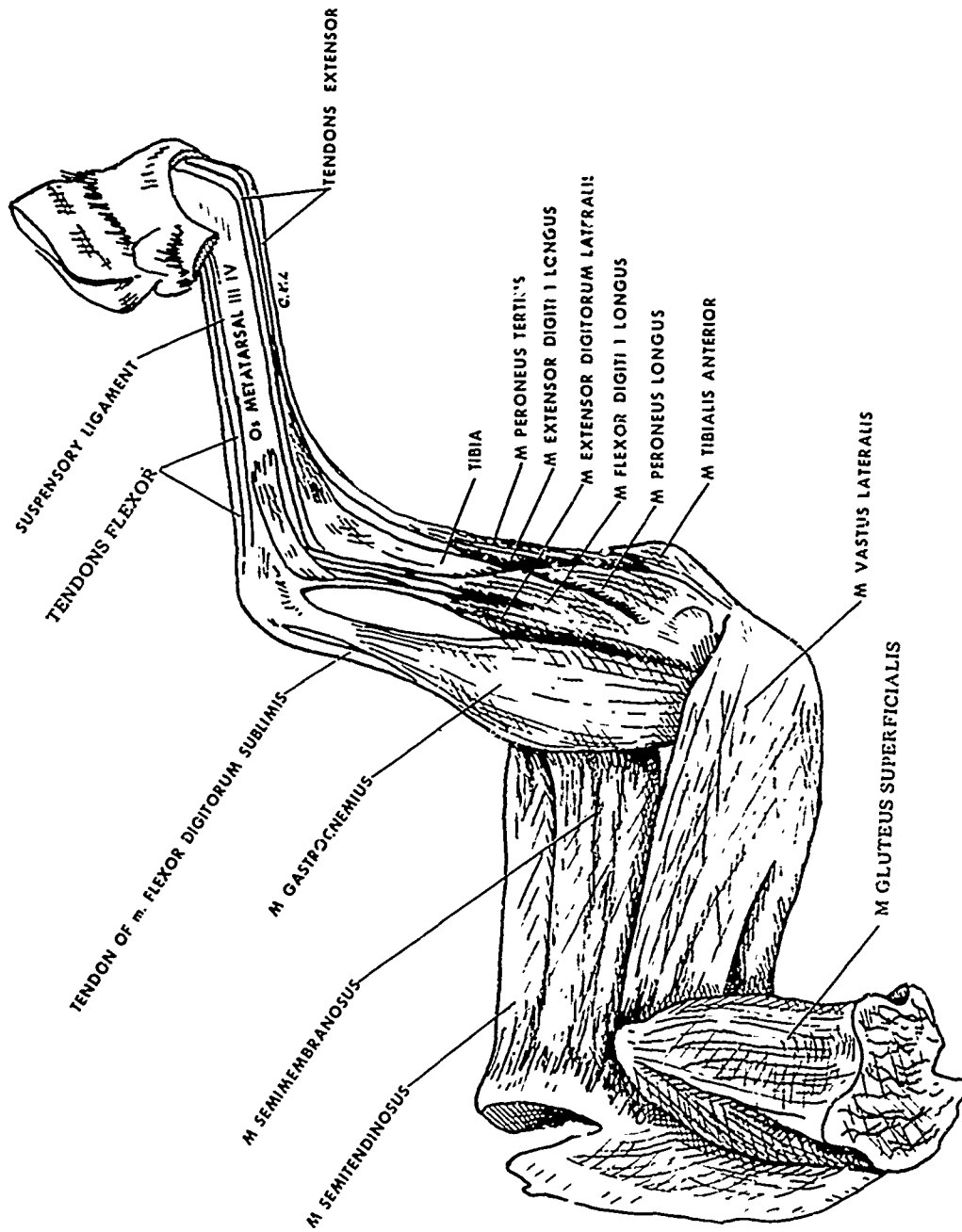


Figure 26. Deeper Dissection of Left Pelvic Limb
(Lateral View)

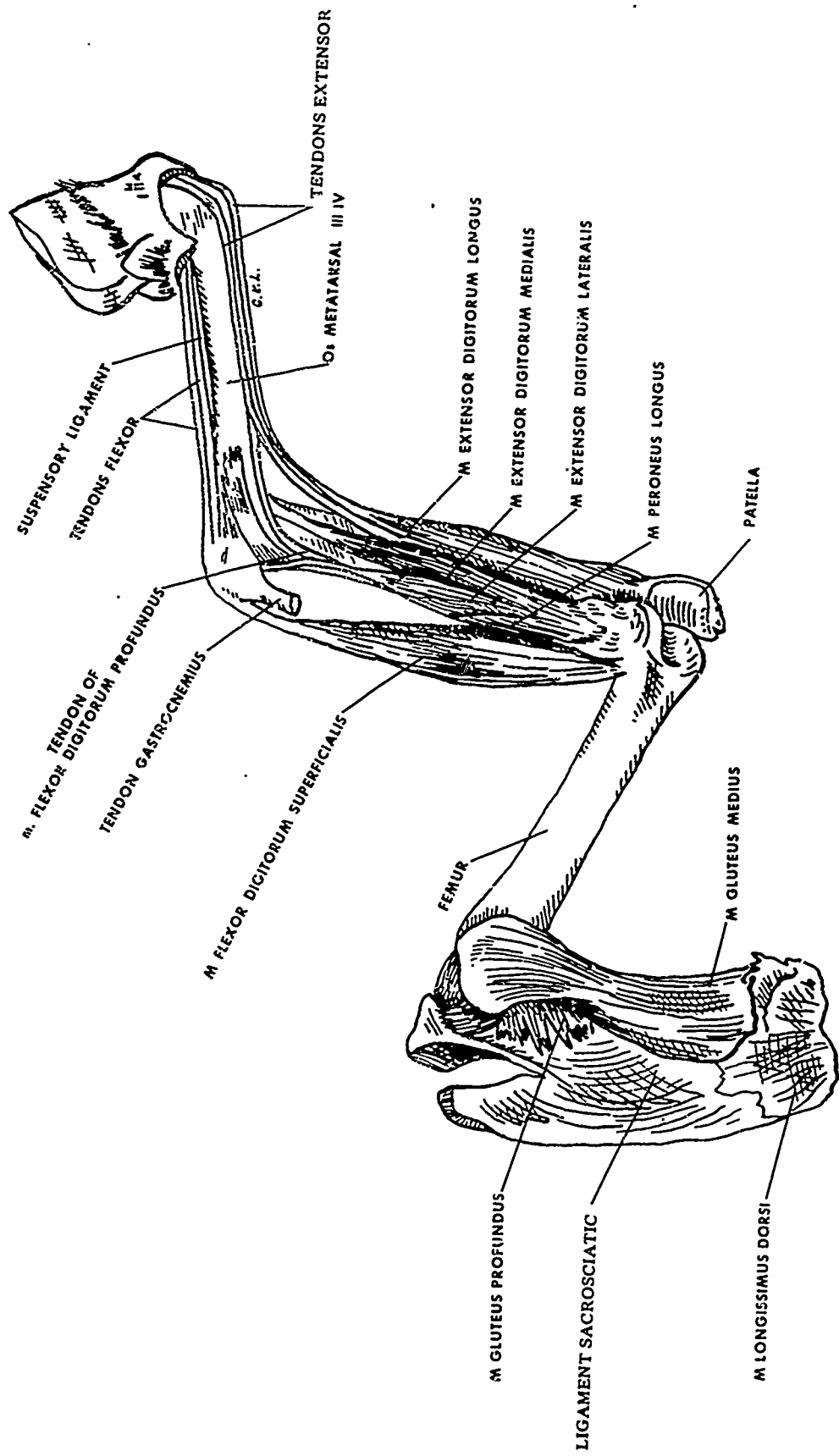


Figure 27. Deepest Dissection of Left Pelvic Limb (Lateral View)

LITERATURE CITED

1. Hopkins, Clarence E., Sr., Hamm, Thomas E., Jr., and Leppart, Gary L. EATR 4431. Atlas of Goat Anatomy. Part I: Osteology. September 1970. UNCLASSIFIED Report.
2. Hopkins, Clarence E., Sr., Hamm, Thomas E., Jr., and Leppart, Gary L. EATR 4626. Atlas of Goat Anatomy. Part II: Serial Cross Sections. April 1972. UNCLASSIFIED Report.
3. Nomina Anatomica Veterinaria. Department of Anatomy, New York State Veterinary College, Ithaca, New York. 1968.
4. Sisson, S., and Grossman, J. D. Anatomy of Domestic Animals. 4th Ed. W. B. Saunders Company, Philadelphia, Pennsylvania. 1953.
5. May, N. Anatomy of Sheep. 2d Ed. University of Queensland Press, Wilke Company, Australia. 1964.
6. Miller, M. E., Christensen, G. C., and Evans, H. E. Anatomy of Dog. W. B. Saunders Company, Philadelphia, Pennsylvania. 1964.