

TECHNICAL REPORT

72-69-FL

AD 744 440

**OBSERVATIONS ON THE OCCURRENCE
OF A DERMATOMYCOSIS IN A COLONY
OF LONG-EVANS RATS**

by

W. B. Pollock

May 1972

Approved for public release;
distribution unlimited.

UNITED STATES ARMY
NATICK LABORATORIES
Natick, Massachusetts 01760



Food Laboratory

FL-160

Approved for public release; distribution unlimited.

Citation of trade names in this report does not constitute an official indorsement or approval of the use of such items.

Destroy this report when no longer needed. Do not return it to the originator.

Approved for public release; distribution unlimited.

Citation of trade names in this report does not constitute an official indorsement or approval of the use of such items.

Destroy this report when no longer needed. Do not return it to the originator.

~~SECRET~~
A-111

UNCLASSIFIED

Security Classification

DOCUMENT CONTROL DATA - R & D		
<i>(Security classification of title, body of abstract and indexing annotation must be entered when the overall report is classified)</i>		
1. ORIGINATING ACTIVITY (Corporate author) U. S. Army Natick Laboratories Natick, Massachusetts 01760		2a. REPORT SECURITY CLASSIFICATION UNCLASSIFIED
		2b. GROUP
3. REPORT TITLE Observations on the Occurrence of a Dermatomycosis in a Colony of Long-Evans Rats		
4. DESCRIPTIVE NOTES (Type of report and inclusive dates)		
5. AUTHOR(S) (First name, middle initial, last name) William B. Pollock		
6. REPORT DATE May 1972	7a. TOTAL NO OF PAGES 17	7b. NO OF REFS 5
8a. CONTRACT OR GRANT NO.	9a. ORIGINATOR'S REPORT NUMBER(S) TR-72-69-FL	
b. PROJECT NO. 1J061102A71C	9b. OTHER REPORT NO(S) (Any other numbers that may be assigned this report)	
c.	FL-160	
d.		
10. DISTRIBUTION STATEMENT Approved for public release; distribution unlimited		
11. SUPPLEMENTARY NOTES	12. SPONSORING MILITARY ACTIVITY U. S. Army Natick Laboratories Natick, Massachusetts 01760	
13. ABSTRACT The gross lesions associated with a Dermatomycosis are discussed. The occurrence of the spores within the hair shaft (endothrix) is demonstrated, while the inability to grow the organism on artificial media is noted.		

Copy of report
sent to
Natick, Mass.

ja

DD FORM 1473 1 NOV 65

REPLACES DD FORM 1473, 1 JAN 64, WHICH IS OBSOLETE FOR ARMY USE.

UNCLASSIFIED

Security Classification

14. KEY WORDS	LINK A		LINK B		LINK C	
	ROLE	WT	ROLE	WT	ROLE	WT
tests	8		7			
performance tests	8		7			
experiments	8		7			
diets			6,8			
formula diets..			6,8			
rats	9		1			
conventional	0					
observations	4					
machine time			6,8			
running time			6,8			
skin diseases			3			
dermatomycosis			3			
alopecia			3			
spores			3			

18-

Approved for public release;
distribution unlimited

AD _____

TECHNICAL REPORT

72-69-FL

OBSERVATIONS ON THE OCCURRENCE OF A
DERMATOMYCOSIS IN A COLONY OF LONG-EVANS RATS

by

W. B. Pollock

Series: FL-160

Project Reference:
1J061102A71C

May 1972

Food Laboratory
U. S. ARMY NATICK LABORATORIES
Natick, Massachusetts 01760

ie.

FOREWORD

The work being reported here is based on observations made after a 25 to 40% decrease in running time of rats on a treadmill was noted. The importance of the pathogenesis is discussed. The importance of dermatological problems in relation to the experimental results and the experimenter are discussed. The literature is deficient on both points.

The work reported was conducted under Project No. 1J061102A71C.

001-10 10010

- 1 In conducting the research described in this report, the investigator adhered to the "Guide for Laboratory Animal Facilities and Care" as promulgated by the Committee on the Guide for Laboratory Animal Resources, National Academy of Sciences - National Research Council, and by the National Society for Medical Research.

ABSTRACT

The gross lesions associated with a Dermatomycosis are discussed. The occurrence of the spores within the hair shaft (endothrix) is demonstrated, while the inability to grow the organism on artificial media is noted.

INTRODUCTION

A colony of 46 male Long-Evans (350-375 gms) conventional rats was housed individually in galvanized cages. Water and feed were provided ad libitum. These rats were trained to run on a treadmill for an experiment involving treadmill performance with respect to varying mineral ratios in the diet.

Approximately 12 weeks after initiation of the experiment, alopecia was first noted in several of the animals and at the same time a sharp drop-off of 25 to 40% occurred in running times. In all, 14 out of the 46 animals were ultimately involved - five animals fed Purina Lab Chow and nine from the treatment groups.

FINDINGS

The animals were found to have areas of alopecia over wide areas of their bodies: ventral thorax, ventral abdomen, latero-dorsal thorax, lateral cervical, submandibular regions. The spots of alopecia varied in size from minute to areas as large as 2 cm x 6 cm (see figure 1). Examination with Wood's light revealed no fluorescence. There was a steady progression of the pathological processes. As the disease progressed in any given animal, the areas of intense pruritis became evident. The subsequent scratching produced local trauma with secondary pyoderma (see figures 1, 2, 3, and 4). Scab formation in these areas was common (see figure 5).

Skin scrapings were obtained and found to be negative for external parasites. However, examination of the hair shafts with 10% KOH revealed suspicious opaque objects within the hair shafts. Mycelia were not seen. Further, samples of hair were examined by our mycology group (see figure 6) and a presumptive diagnosis of Trichophyton mentagraphytes infection was made on the basis of the history, clinical signs and microscopic examination of the hair shafts (see figures 1, 2, 3, 4, and 5). Attempts to grow the organism on Sabouraud's media have failed, thus preventing the formation of a conclusive diagnosis.

Four apparently normal animals (albino, Holtzman males at 350 grams) were chosen as subjects in an attempt to transfer the process from one animal to another. One animal was placed in the cage with an infected animal for a period of four hours. Two animals were exposed by first handling infected animals and then handling normal animals. The fourth animal was exposed by contaminating his cage environment with hair from an infected animal. Results from these trials were equivocal. The first animal started developing alopecia and pruritis in the latero-dorsal aspect of the left thorax within two weeks as did one of the next two. However, the other two (one handled, one with contaminated environment) exhibited no signs of alopecia after six weeks.

DISCUSSION

This disease process, although lacking a definitive diagnosis, was important from two standpoints: (1) the animals affected were unable to perform as expected, greatly affecting the experiment; and (2) the contagious aspect of the disease threatened other experiments in the building. One of the workers was diagnosed as having "ringworm" at about the time the performance of the rats was affected. Prompt treatment took care of this problem. Hygienic practices were reviewed with the workers and further outbreaks were contained by improved personal hygiene.

Previously reported discussions of dermatomycoses have been limited in their scope and pathogenesis has been a neglected area (2, 3, 4, 5, and 6). Figure 5 indicates that the pruritis apparently is the most important clinical sign. The itching is so intense that the animals appear to be more interested in satisfying the scratch reflex than in eating or performing. The pruritis is important from the aspect that the resulting scratching produces trauma and the attending pyoderma.

Problems with "ringworm" have not occurred in subsequent treadmill experiments conducted with Cesarean-Derived Barrier Sustained rats. As shown in this paper, ringworm presents a definite hazard to both the experiment and the experimenter, therefore, it is recommended that: (1) gnotobiotic animals be used; (2) animals be examined at time of delivery and at frequent intervals thereafter; and (3) proper hygienic techniques be reviewed with workers periodically.

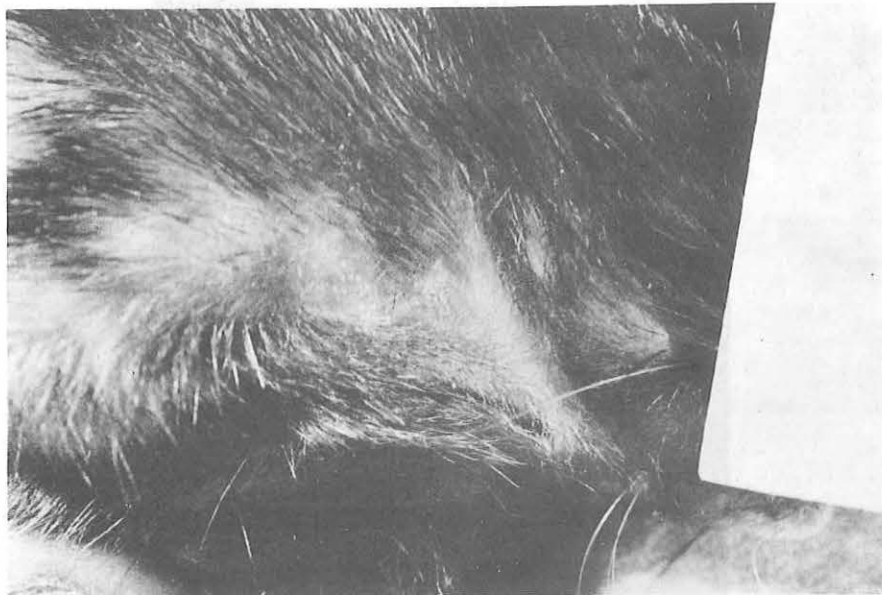

FIGURE 1

Rat with Alopecia of right shoulder region

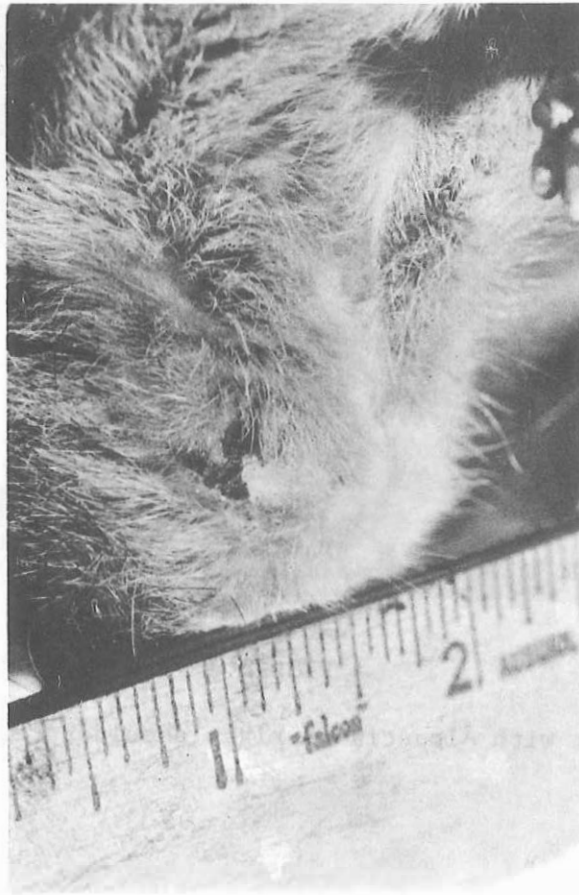

FIGURE 2

The Alopecia has progressed. The pruritis has triggered the scratch reflex and trauma has resulted.

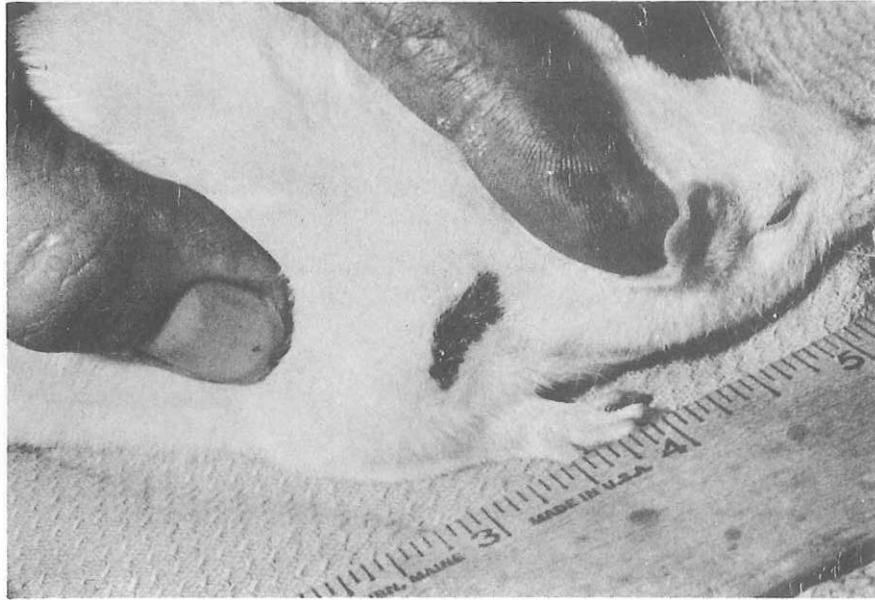

FIGURE 3

An advanced case showing trauma, scab formation and pyoderma

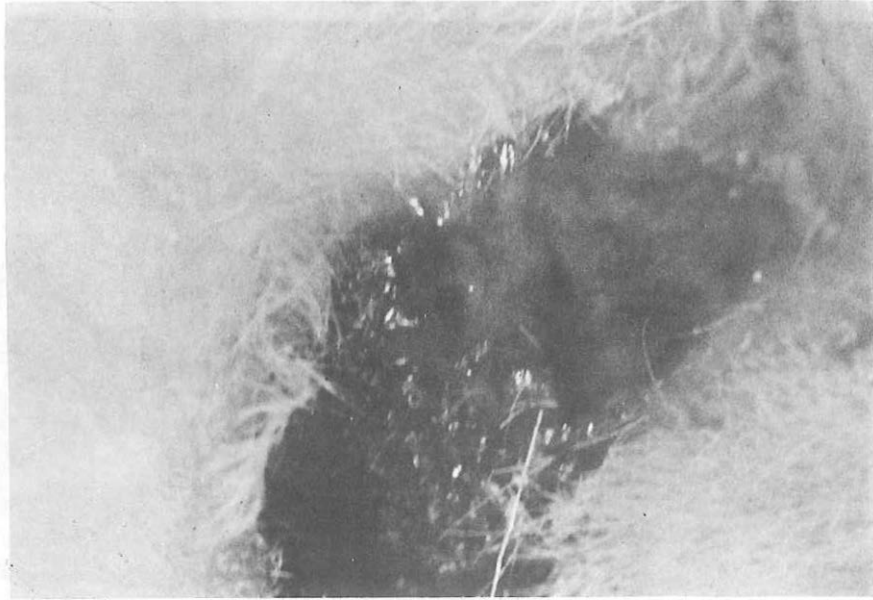


FIGURE 4

A case showing advanced pyoderma

FLOW CHART

Decrease in
work performance

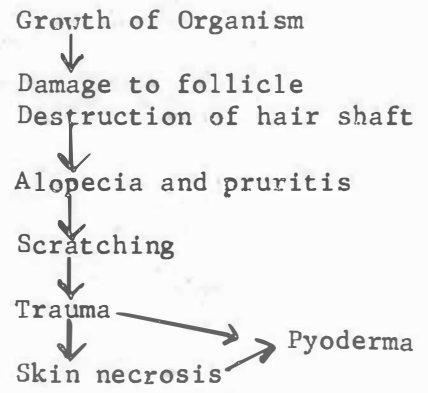


FIGURE 5

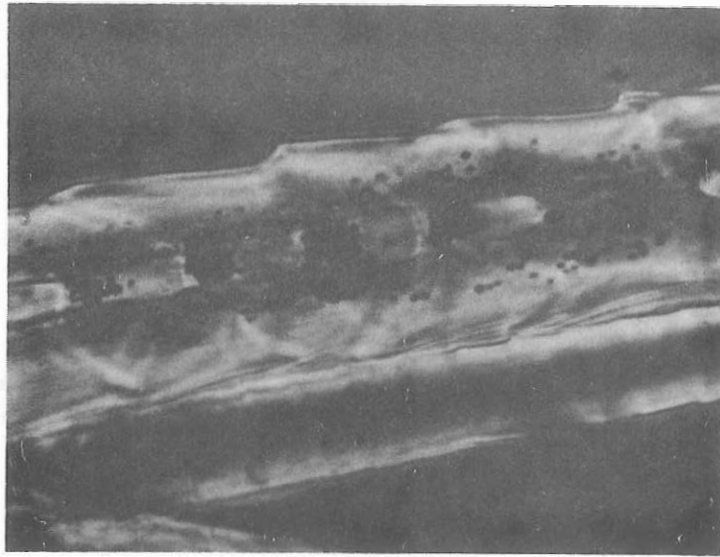


FIGURE 6

Photomicrograph (X430) of hair shaft of affected rat. Brown spots are thought to be spores of mycotic organism (endothrix).

REFERENCES

1. Cohrs, P. 1967. In Textbook of the Special Pathological Anatomy of Domestic Animals, p. 984. Pergamon Press, Oxford.
2. Huli, T. G. 1963. In Diseases Transmitted from Animals to Man, 5th ed, p. 490. Charles C. Thomas, Springfield.
3. Jobb, K. U. F. and Kennedy, P. C. 1970. In Pathology of Domestic Animals, 2nd ed., Vol. 2, p. 618. Academic Press, New York.
4. National Research Council. 1971. A report of the Committee on Laboratory Animal Disease - A Guide to Infectious Diseases of Mice and Rats, p. 28. National Academy of Science/National Research Council, Washington, D. C.
5. Pover, M. L. 1965. Ringworm (T. mentagraphytes) infection in a colony of albino Norway rats. Lab. Anim. Care 5(4): 264.