


Distribution of this document is unlimited

AD723449

# NAMRU-2

Human Vibrio Cholerae: A Histologic Review  
of 117 Cases in the Philippines



DDC  
RECEIVED  
MAY 21 1971  
REGULATED  
C

20050308110

NAMRU-2-TR-437  
March 1971

United States Naval  
Medical Research Unit No. Two  
Taipei, Taiwan

Reproduced by  
NATIONAL TECHNICAL  
INFORMATION SERVICE  
Springfield, Va. 22151

DISTRIBUTION STATEMENT A  
Approved for public release;  
Distribution unlimited

14

PATHOLOGY DEPARTMENT

Berton Timothy Schaeffer, B.S., M.D., Head

ACCESSION NO.	
CFSTI	WRITE SECTION <input checked="" type="checkbox"/>
DOC	DIFF SECTION <input type="checkbox"/>
UNANNOUNCED	<input type="checkbox"/>
JUSTIFICATION	
BY	
DISTRIBUTION/AVAILABILITY CODES	
DET.	AVAIL. CODE/SPECIAL
A	20

ADMINISTRATIVE INFORMATION

This study was supported in part by funds provided by the Bureau of Medicine and Surgery, Navy Department, for Work Unit MR 005, 09.01-0114A.

Distribution of this document is unlimited

R. H. WATTEN  
CAPT MC USN  
Commanding Officer

01180202001

UNCLASSIFIED

Security Classification

DOCUMENT CONTROL DATA - R & D

Security classification of title, body of abstract and indexing annotation must be entered when the overall report is classified

1. ORIGINATING ACTIVITY (Corporate author) U. S. Naval Medical Research Unit No. 2 Box 14, APO San Francisco 96263		2a. REPORT SECURITY CLASSIFICATION Unclassified	
2. REPORT TITLE Human <u>vibrio cholerae</u> : A histologic review of 117 cases in the Philippines			
4. DESCRIPTIVE NOTES (Type of report and inclusive dates) Technical Report			
3. AUTHOR(S) (First name, middle initial, last name) S. C. Sun, B. T. Schaeffer and V. M. Reyes			
6. REPORT DATE Marcy 1971		7a. TOTAL NO. OF PAGES 9	7b. NO. OF REFS 14
8a. CONTRACT OR GRANT NO. A. PROJECT NO. MR005.09.01-0114A.		8b. ORIGINATOR'S REPORT NUMBER(S) NAMRU-2-TR-437	
8c. OTHER REPORT NUMBER(S) (Any other numbers that may be assigned this report)			
10. DISTRIBUTION STATEMENT Distribution of this document is unlimited			
11. SUPPLEMENTARY NOTES Published in Southeast Asian J. Trop. Med. Pub. Hlth 2(1); 73-81, Mar. '71		12. SPONSORING MILITARY ACTIVITY Bureau of Medicine and Surgery Department of the Navy Washington, D. C. 20390	
13. ABSTRACT Analysis of 117 Asiatic cholera patients, of which 81 or 69% were infants and children, revealed a multiplicity of cholera-induced histopathology secondary to shock, electrolyte imbalance, and cholera toxins. In a majority of cases the proximate cause of death was ascribable to acute tubular nephrosis. Visceral haemorrhage was though a consequence of damage to capillary endothelium from cholera toxins. Hypokalemic cardiomyopathy, characterized by cytoplasmic vacuolation, hyalinization, and overcontraction of myofibrils, was a predominant feature. Focal inflammatory myocytolysis and an increase in Anitschkow myocytes constituted evidence of the toxicity of the vibrio involving the myocardium. Pulmonary congestion, and on occasion haemorrhage, interstitial pneumonia, and focal collapse were observed. A high incidence of fatty change of the liver in cholera victims of the younger age group suggested malnutrition might have been a predisposing factor which contributed to susceptibility and mortality.			

DD FORM 1473 (PAGE 1)

UNCLASSIFIED

Security Classification

**UNCLASSIFIED**  
Security Classification

14 KEY WORDS	LINK A		LINK B		LINK C	
	ROLE	WT	ROLE	WT	ROLE	WT
Human Vibrio Cholera Histological evidence of toxin effects Damage of Kidney, capillary walls and myocardium with appearance of Anitschkow myocytes						

DD FORM 1473 (BACK)  
1 NOV 66  
(PAGE 2)

**UNCLASSIFIED**  
Security Classification

---

Reprinted from  
**THE SOUTHEAST ASIAN JOURNAL  
OF TROPICAL MEDICINE AND PUBLIC HEALTH**

Vol. 2 No. 1 March 1971

**OFFICIAL PUBLICATION OF THE SEAMEO  
CENTRAL COORDINATING BOARD FOR  
TROPICAL MEDICINE AND PUBLIC HEALTH**

# HUMAN *VIBRIO CHOLERAE*: A HISTOLOGIC REVIEW OF 117 CASES IN THE PHILIPPINES†

S.C. SUN\*, B.T. SCHAEFFER\*\* and V.M. REYES\*\*\*

\*Medical Research Laboratory, Veterans General Hospital, \*\*Department of Pathology,  
U.S. Naval Medical Research Unit No. 2, Taipei, Taiwan and

\*\*\*San Lazaro Hospital, Manila, Republic of Philippines.

## INTRODUCTION

Perusal of the literature concerning human cholera discloses little precise information on histopathologic aspects of this disease. It remains conjecture that the cause of death is entirely attributable to either acute or prolonged shock (Phillips, 1964, 1965.) Little histologic evidence has been elicited to indicate whether cholera toxins affect organs besides the intestine and what relation this may have to the cause of death (Pollitzer, 1959).

The subject of this report is pathologic alterations in various organs and suggested patterns of occurrence of cholera toxin effects in 117 autopsies of cholera victims hospitalized at San Lazaro Hospital, Manila, Philippines, from 1967 to 1969.

## -MATERIALS AND METHODS

The age of the patients ranged from 4 months to 80 years. Eighty-one of the 117 cholera victims were infants and children (Table 1). One hundred eleven patients succumbed within two days of hospitalization (Table 2), and autopsies were performed within 2-12 hours. Rectal swabs for bacteriologic confirmation were obtained on all patients on admission and at postmortem.

† This study was supported in part by funds provided by the Bureau of Medicine and Surgery, Navy Department, for Work Unit MR005.09.01-0114A.

The opinions and assertions contained herein are those of the authors and are not to be construed as official or as reflecting the views of the Navy Department or the Naval Service at large.

All specimens were positive to Inaba and Ogawa agglutinogens. Tissue sections were preserved in 10% buffered formalin, forwarded to NAMRU-2, Taipei, Taiwan, and stained with the hematoxylin eosin, trichrome, periodic acid Schiff, Weigert fibrin and phosphotungstic acid techniques.

Table 1  
Age distribution of 117 Cholera patients  
autopsied San Lazaro Hospital, Manila,  
Philippines, 1967-1969.

Age (Years)	1967	1968	1969	Total
Under 1	0	2	5	7
1 - 4	4	23	38	65
5 - 14	5	9	5	19
15 - 24	2	2	1	5
25 - 34	1	0	3	4
35 - 44	3	2	1	6
45 over	2	4	5	11
Total	17	42	58	117

Table 2  
Days of hospitalization for 117 Cholera  
patients at San Lazaro Hospital, Manila,  
Philippines.

Age (Years)	Days of Hospitalization			
	Within 1 Day	1 - 2 Days	3 - 6 Days	Over 1 Week
Under 1	3	3	0	0
1 - 4	46	18	2	1
5 - 14	15	3	1	0
15 - 24	3	2	0	0
25 - 34	1	2	0	0
35 - 44	5	1	0	0
45 over	4	5	1	1
Total	77	34	4	2

NOT REPRODUCIBLE

SOUTHEAST ASIAN J. TROP. MED. PUB. HLTH.

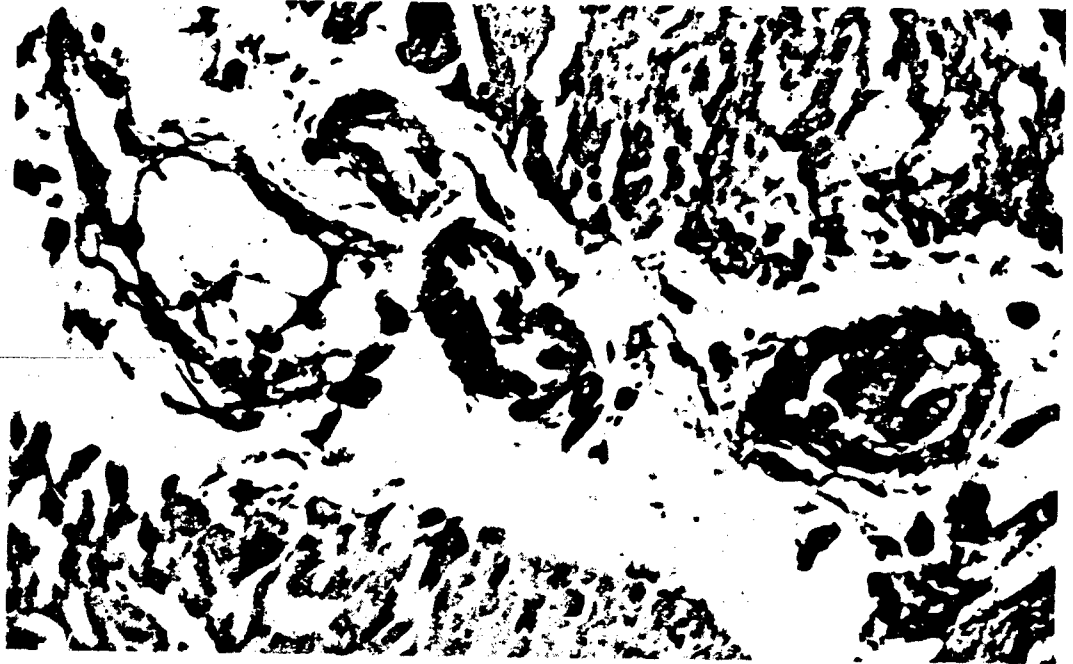


Fig. 1—Damage of endothelial cells demonstrated in small blood vessels in the small intestinal wall from a 35-year-old patient. H&E stain, X 400.

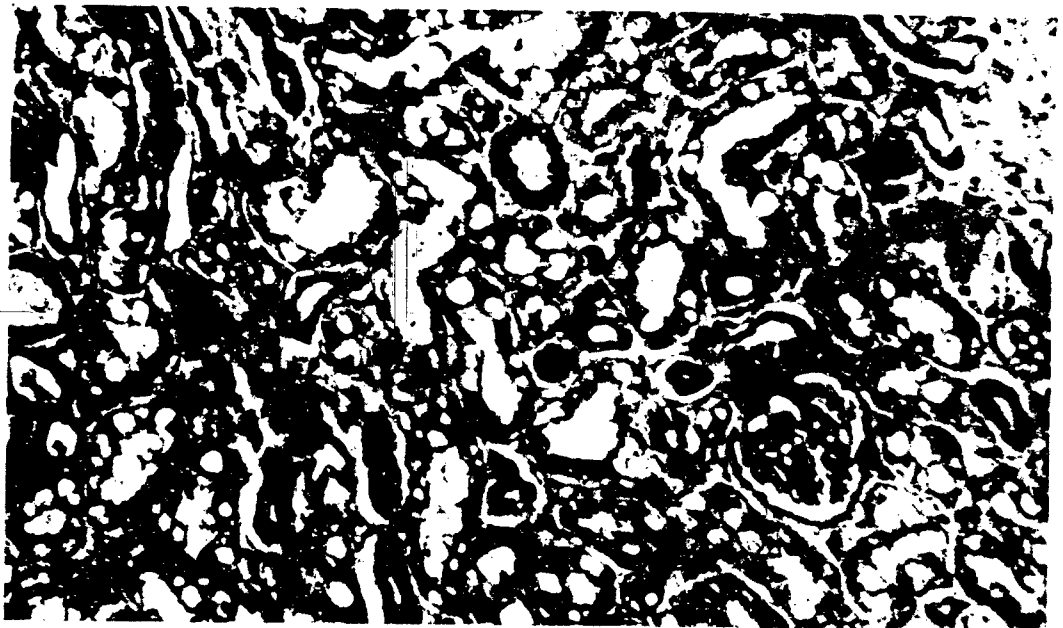


Fig. 2—Vacuolar degeneration of renal tubular cells in a 6-year-old child. H&E stain, X 400.

## RESULTS

A spectrum of histologic changes were observed. The most consistent finding was vascular dilatation and congestion of the viscera. Specifically, when autopsies were performed two to three hours post-mortem the mucosa of the small intestine was intact but oedema and transudate between the epithelium and the stroma of the lamina propria were noted. The lamina propria contained increased numbers of cells associated with striking congestion of submucosal blood vessels. When the time between death and autopsy was increased, epithelial denudation and extensive sloughing were present.

Variable degrees of smooth muscle degeneration were noted in the musculature of the small intestine, characterized by patchy hyper eosinophilia, muscle bundle disarray, and individual myofiber fusion with loss of cell borders. Nuclei were pale and vesicular; occasional others small and pyknotic. Small blood vessel walls were thickened and hyalinized with occasional exfoliation of cellular elements into the lumens (Fig. 1). No thrombi were present.

The renal changes varied considerably. Cortical ischemia was commonly seen in most cases of acute death. Glomerular tufts were somewhat hypercellular devoid of red blood cells, and exhibited swelling of endothelial cells and obliteration of the tubules showed early, granular, cloudy swelling with occasional disruption of the surface cell membranes. Eosinophilic hyaline droplets were often present in the cytoplasm. In some cases vacuolar degeneration of tubular cells was present (Fig. 2).

In other acute cases glomeruli were markedly hyperemic with the occasional presence of proteinaceous exudate and haemorrhage in widened Bowman's spaces. Acute tubular

nephrosis was generalized and extreme, characterized by cytoplasmic coagulation, nuclear pyknosis, and karyolysis. Distal and collecting tubules were plugged with exfoliated epithelial cell masses (Fig. 3). In a few cases haemoglobin and RBC casts were found within tubular lumens whose lining epithelium was essentially intact (Fig. 4). Inflammatory infiltration was seldom associated with these changes. Marked congestion of the medullary areas was seen consistently.

A variety of acute myocardial lesions were noted. Vacuolization and hyalinization of myocytes were the most frequent findings in young patients (Fig. 5). Vacuoles did not stain with the periodic acid Schiff technique. Myocardial fibers generally were shrunken and the cytoplasm rarefied. Cross striations were ill defined in some areas. Nuclei of these fibers were generally sparse or absent. Intercellular spaces were expanded with increased numbers of histiocytes and scant cellular infiltrates. In some cases muscle fibers exhibited focal hyper eosinophilia and hyalinization. Pronounced contraction of muscle fibers comprised another commonly encountered histologic feature and were observed as nodular masses on cross section (Fig. 6) and as shortened, scalloped myofibrils on longitudinal section. Coagulation necrosis was encountered in contracted myofiber masses with loss of cell boundaries and nuclei (Fig. 6). Foci of isolated muscle fiber dissolution with inflammatory cell infiltration were seen in one group of patients (Fig. 7). In five cases an increase in Anitschkow myocytes was present in areas adjacent to blood vessels (Fig. 8). Necrosis in multiple focal areas was observed in three young patients and in one elderly patient. Four patients exhibited haemorrhagic myocardial lesions.

In sections of lung patchy pneumonitis with or without atelectasis was the most



NOT REPRODUCIBLE

SOUTHEAST ASIAN J. TROP. MED. PUB. HLTH.

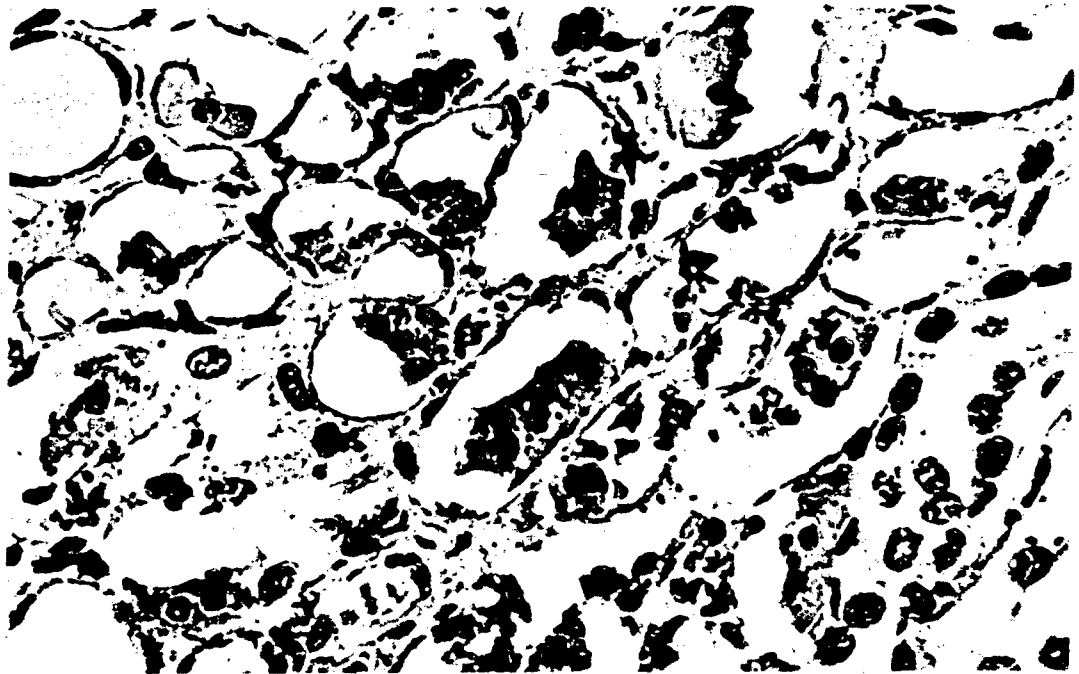


Fig. 3—Severe degree of acute renal tubular nephrosis in a 15-year-old child, showing coagulation necrosis and exfoliation of tubular cells. H&E stain, X 400.

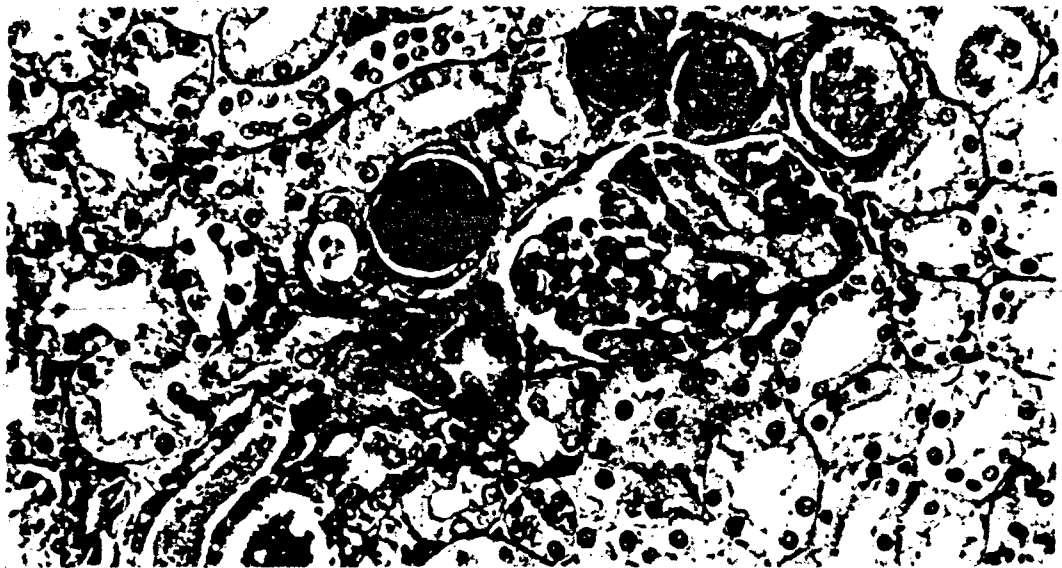


Fig. 4—Acute tubular nephrosis with demonstration of haemoglobin and RBC casts a 5-year-old child. H&E stain, X 250.

NOT REPRODUCIBLE

*V. cholerae* IN THE PHILIPPINES

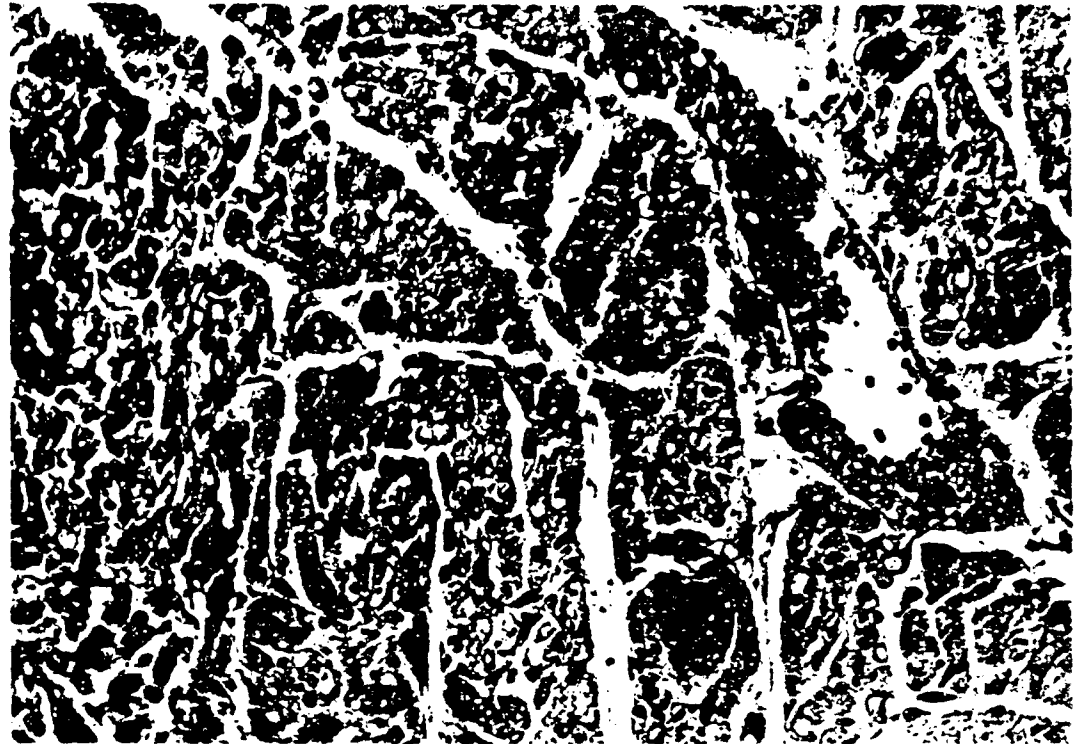


Fig. 5.—A representative microscopic field from the myocardium of a 5-year-old child showing vacuolation and hyalinization of the muscle fibers with terminal vasodilation in the interstitium, H&E stain, X 120.

commonly observed feature. Several cases had superimposed bronchial or lobar pneumonia. Diapedesis of red blood cells into alveoli had occurred in several cases. Appearance of hyaline membranes was rare. More severe cases were found where alveoli were filled with oedema fluid and red blood cells resembling hypostatic pneumonia.

Varying degrees of fatty change in the liver were noted in 54 cholera patients especially in the younger age groups. Early nutritional cirrhosis was found in 2 cases. Parasitism was not observed in the livers of the cases; however, increased degrees of lymphocytic infiltration in portal tracts with many eosinophils were commonly seen.

The malpighian corpuscles of the spleen were hyperplastic exhibiting a proliferation

of reticulum cells. Central hyalinization and frequently necrosis were present within the white pulp. Sinus congestion and increased cellularity were observed within the red pulp. Focal haemorrhage was present.

#### DISCUSSION

Of the 117 cholera patients, 111 who were autopsied had died within one to two days of hospitalization. There was generalized vasodilatation with blood stasis in most viscera and features of acute tubular nephrosis. The multiplicity of cellular changes in various organs consisting of loss of cellular integrity and cellular alterations in heart muscle and renal tubules suggests that cytotoxicity attributable to cholera toxins may be incriminated. Other factors that may be

NOT REPRODUCIBLE

SOUTHEAST ASIAN J. TROP. MED. PUB. HLTH.

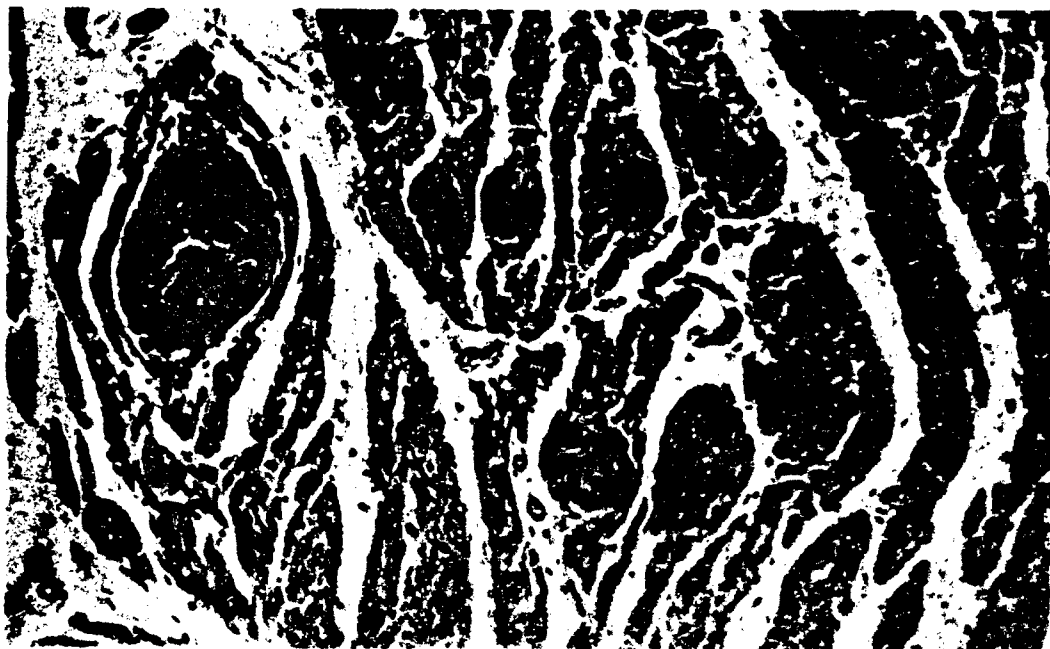


Fig. 6—Myocardium from a 4-year-old child, showing pronounced contraction of muscle fibers disposed as nodular masses with coagulation necrosis as seen on cross section. H&E stain, X 120.

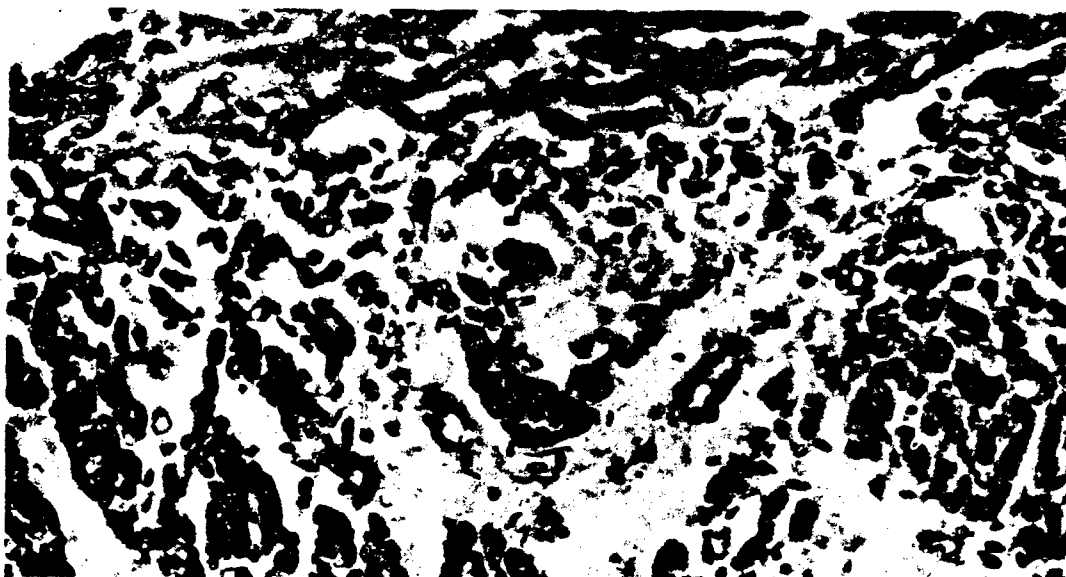


Fig. 7—Myocardium from a 4-year-old child showing a focus of muscle fiber dissolution with inflammatory cell infiltration. H&E stain, X 240.

NOT REPRODUCIBLE

*V. cholerae* IN THE PHILIPPINES



Fig. 8—Myocardium from a 1-year, 3-month-old child showing increase in Anitschkow myocytes in perivascular area. H&E stain, X 400.

implicated are hypovolemia, electrolyte imbalance especially potassium depletion.

The histologic features of the retained intact intestinal epithelium would tend to verify that the effect of cholera toxins on the function of the intestinal mucosa is responsible for the outflow of large amounts of fluid from the tissue (Elliott *et al.*, 1958). The damage sustained by the endothelium and muscularis of small vessels is attributable to the cholera toxins and is more striking in sections of the intestinal walls rather than in other viscera; whereas, the cholera toxins are presumed to be absorbed via the small blood vessels (Schaeffer *et al.*, 1970).

Renal histologic changes in cholera are believed secondary to haemoconcentration or

prolonged shock resulting in renal ischemia (Benyajati *et al.*, 1962). In this series the earliest renal change is manifested by cortical ischemia which coincides with the early clinical signs of oliguria experienced by cholera patients. As the condition progresses to shock, more profound tubular epithelial degeneration, nephrosis, and a variety of tubular casts are observed. This represents one feature of acute tubular nephrosis and coincides with clinically evident acute renal failure. The usual circumstance of depleted potassium stores reflected by vacuolar degeneration of renal tubular cells and possible cytotoxic effect to tubular epithelium by cholera toxins would tend to accelerate the process of acute tubular nephrosis (Schaeffer *et al.*, 1970. Benyajati *et al.*, 1962).

Few detailed descriptions exist concerning the histopathology of the heart in human cases. Since vibrio toxins possess multiple biochemical properties including a variety of proteolytic and tissue disintegrating enzymes and since pathogenesis is due to release of toxins into the blood stream from the infected site of intestinal mucosa (Pollitzer, 1959, Benyajati *et al.*, 1963, Vaughn-Williams and Dohadwalla, 1969), it is unlikely that cardiac muscle with high metabolic activity could escape effects of the toxins. Myocardial hypoxia, voluminous loss of tissue fluid and depletion of potassium also can contribute to the lesions observed in the myocardium. Hypokalemic cardiomyopathy progresses from vacuolation of myocytes to loss of myofibrils. Hyaline degeneration of skeletal muscle fibers and hypercontraction of myofibers in cardiac muscle have been demonstrated in potassium depletion (Achor and Smith, 1965, Malnar *et al.*, 1962). Hypokalemic cardiomyopathy was commonly observed in young age cholera patients. Faecal losses of potassium were higher in infants and children than in adults (Griffith *et al.*, 1967).

An increase in Anitschkow myocytes was observed in four cholera patients 1 to 2 years of age and in one patient 67 years of age. Goldstein *et al.*, have reported the dominant myocardial lesion as an increase in Anitschkow myocytes with lymphocytic infiltration, perhaps a direct effect of the cholera toxin, in 78% of cholera infected guinea pigs (Goldstein *et al.*, 1966). The cardiac lesions in the experimental animals, however, differ from those of human cholera infections. The specific feature of an increase in the number of Anitschkow myocytes has not been reported in human cholera. The Anitschkow myocyte is among the earliest of cells to appear in response to toxic influence upon the myocardium (Clawson, 1941, Gore and Saphir, 1948).

Malnutrition has long been invoked as a factor contributing to susceptibility of pa-

tients to cholera; however, scientific demonstration of such a causal relationship has seldom been made (Rosenberg *et al.*, 1965). Analysis of these 117 cholera patients reveals fatty change of the liver in nearly one-half the cholera patients. The percentage is especially high in age groups under one year and in 1- to 4-year-old patients. Fatty change in such young age groups is thought due principally to malnutrition.

In conclusion, despite a paucity of anatomic changes in the intestine, there is sufficient evidence of damage to numerous other organs. The variety of sites and the wide spectrum of histological changes reinforce the concept that cholera is a generalized disease wherein cytotoxicity to various tissues results as a consequence of disseminated cholera toxins, electrolyte disturbances, and hypovolemia.

#### SUMMARY

Analysis of 117 Asiatic cholera patients, of which 81 or 69% were infants and children, revealed a multiplicity of cholera-induced histopathology secondary to shock, electrolyte imbalance, and cholera toxins. In a majority of cases the proximate cause of death was ascribable to acute tubular nephrosis. Visceral haemorrhage was thought a consequence of damage to capillary endothelium from cholera toxins. Hypokalemic cardiomyopathy, characterized by cytoplasmic vacuolation, hyalinization, and overcontraction of myofibrils, was a predominant feature. Focal inflammatory myocytolysis and an increase in Anitschkow myocytes constituted evidence of the toxicity of the vibrio involving the myocardium. Pulmonary congestion, and on occasion haemorrhage, interstitial pneumonia, and focal collapse were observed. A high incidence of fatty change of the liver in cholera victims of the younger age group suggested malnutrition might have been a

predisposing factor which contributed to susceptibility and mortality.

#### REFERENCES

- ACHOR, R.W.P. and SMITH, L.A., (1955). Nutritional deficiency syndrome with diarrhea resulting in hypo-potassemia, Muscle degeneration and renal insufficiency: Report of case with recovery. *Proceedings of Staff Meetings of the Mayo Clinic*, 30 : 207.
- BENYAJATI, C., KEOPLUG, M., BEISEL, W.R., GANGAROSA, E.J., SPRINZ, H. and SITPRUA, V., (1962). Acute renal failure in Asiatic cholera: Clinicopathological correlation. *Proceedings of SEATO Conference on Cholera*, Dacca, East Pakistan. Bethesda, Md. National Institutes of Health, pp. 61-64.
- CLAWSON, B.J., (1941). Syphilitic heart disease, *Urol. and Cutan. Rev.*, 45 : 219.
- ELLIOTT, H.L., CHARLES, C.J., CARPENTER, R., SACK, B. and YARDLEY, J.H., (1968). Small bowel morphology in experimental canine cholera. A light and electron microscopic study. *Amer. J. Path.*, 52 : 15a.
- GOLDSTEIN, H.B., MERRILL, T.G. and SPRINZ, H., (1966). Experimental Cholera: Morphological evidence of cytotoxicity, *A.M. A. Arch. Path.*, 82 : 54.
- GORE, I. and SAPHIR, O., (1948). Myocarditis associated with acute and subacute glomerulonephritis, *Amer. Heart J.*, 35 : 390.
- GRIFFITH, L.S.C., FRESH, J.W., WATTEN, R.H. and VILLAROMAN, H.P., (1967). Electrolyte replacement in pediatric cholera. *Lancet*, 1 : 1197.
- MALNAR, Z., LARSEN, K. and SPARGO, B. (1962). Cardiac changes in potassium depleted rat. *A.M.A. Arch. Path.*, 74 : 339.
- PHILLIPS, R.A., (1965). Pathophysiology of Cholera. *Proceedings of the Cholera Research Symposium*, Honolulu, Hawaii, Public Health Service Publication, pp. 82-85.
- PHILLIPS, R.A., (1964). Water and electrolyte losses in cholera. *Fed. Proc.*, 23 : 705.
- POLLITZER, R., (1959). Biochemical properties of *V. Cholerae*. *Cholera W., H.O.*, Geneva, pp. 134-140.
- ROSENBERG, I.H., GREENOUGH, W.B. III. LINDENBAUM, J. and GORDON, R.S. JR., (1965). Nutritional studies in cholera: The influence of nutritional status on susceptibility to infection. *Proceedings of the Cholera Research Symposium*, Honolulu, Hawaii, Public Health Service Publication, pp. 134-140.
- SCHAEFFER, B.T., SUN, S.C. and WALKER, R.I., (1970). Localization of Cholera Toxins of Fluorescent Antibody Techniques. (In press).
- VAUGHN-WILLIAMS, E.H. and DOHADWALLA, A.N., (1969). Diarrhea and intestinal fluid accumulated in uninfected rabbit cross perfused with blood donor rabbits intra-intestinally infected with cholera. *Nature*, 222 : 258.