

AD 678251

TRANSLATION NO. 144

DATE: Sept 1968

Russian

DDC AVAILABILITY NOTICE

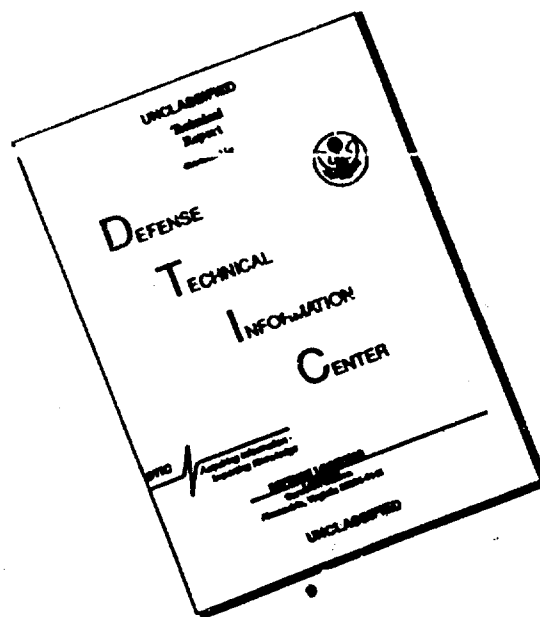
This document has been approved for public
release and sale; its distribution is
unlimited.

DEC 2 1968

DEPARTMENT OF THE ARMY
Fort Detrick
Frederick, Maryland

Reproduced by the
CLEARINGHOUSE
for Federal Scientific & Technical
Information Springfield Va 22151

DISCLAIMER NOTICE



THIS DOCUMENT IS BEST QUALITY AVAILABLE. THE COPY FURNISHED TO DTIC CONTAINED A SIGNIFICANT NUMBER OF PAGES WHICH DO NOT REPRODUCE LEGIBLY.

#144
cy1
Neuropathology and Psychiatry, 16(1); 30-36, 1947

Sergeeva, U. S. and Drigo, E. V.

Clinics of Japanese Encephalitis (From observations of the summer of 1946 on the Kuantung Peninsula)

Observations were conducted by us on the clinics of Japanese encephalitis in the wake of an epidemic, the patients of which were located in three hospitals. Ordinarily the patients were examined neurologically; particular attention was also devoted to the pulse, breathing, blood pressure and eyebottom. Most of the observations were from the first 2-3 days of infection, thus giving us a good picture of the dynamics of the clinical course of infection of this epidemic.

All the patients could be divided into two groups, those with severe courses upon entrance, and those with mild courses.

The severe cases entered at early periods, most of them had lethal infections.

In ten cases we were able to isolate the virus of Japanese encephalitis from the brain of the patients after death.

The clinical characteristics of this group of patients were the severe headaches, sudden increase of temperature. The temperature often attained 40 or higher in the first two days. The skin was hot and dry, covered with mosquito bites, sometimes covering the entire body, evidently, as a result of being bitten while sleeping.

The face and conjunctiva of the sclera were hyperaemic. Tongue dry, furred. Often there was vomiting. In all cases there was expressed rigidity of the occiput. Kernig symptoms were weak or absent.

An early appearance of the tension of the occipital muscle demands particular attention. At this time the breathing accelerates and is superficial, in some cases the rhythm goes to 55 per minute, the average

was 35-40. In severe cases the breathing becomes more superficial; the accessory muscles take part in the action. This indicates the incorporation of the respiratory nerve system into the pathological process.

The disruption of the cardio-vascular system is visible. The heart beat accelerates.

An object drawn across the skin of the patient gives a white dermographism. Characteristics of the pilomotor reflexes appear.

In the acute period of some of the patients there was a split of the pulse and temperature. A pulse of 80 with a temperature of 40; the average pulse was 90; the fastest being 140, the slowest was 50.

Analysis of the sphygmograph indicated that the infection starts with a fast pulse with a great amplitude, very strong beat wave and a clearly expressed diastolic increase. This pulse can be called *sympathic*. During a severe course the pulse later decreases by 3-4 times. This pulse can be called 'vagus'. The appearance of this type pulse is usually parallel with the symptoms of affection of the medulla oblongata.

In the first 2-3 days of infection the blood pressure does not fluctuate from normal, varying from 70 to 120 mm. The greatest blood pressure we observed was with a maximum of 160 mm and a minimum of 150, in a 20 year old patient. The lowest pressure was 70 mm as maximum and a 40 minimum.

We observed that during the decrease of the blood pressure the maximum drops faster than the minimum, coming to normal, or the maximum coming to the minimum, the latter in cases of death.

One of the early symptoms we noted was similar to the Horner

syndrome. We noted its one-sided appearance, indicating the affection of the visual innervation center. On the horizon of this appearance we noted the disruption of consciousness, deafness, starvation of the blood and brain from oxygen.

Along with the rigidity of the occiput and position of the head, we noted the variation of the muscle tone of the legs and arms. The legs are usually stre^Tched out and the hands tense and clenched. This condition progresses to the point where it is impossible to bend the legs or unclench the hands. There is what is known as an accoucher hand. In these cases, upon sectioning, there was softening of the optic nodes. (Note: The optic nodes referred to here are uncertain. Translator).

The increased muscle tone can affect one side of the body, arm or leg. In these cases the opposite side can have a hyperkinesis; it can be on the face muscles, in some cases there can be a contraction of the muscles of one half of the face.

As a result of the increased muscle tone of the face, there can be a characteristic trismus, it is impossible to open the mouth. There is oiliness of the face.

Hyperkinesis in the arms and legs can be observed in various groups of muscles, but most often in the wrists and fingers of the hands. They resemble stereotype of movements, or tremors which are observed during a post-epidemic-encephalitic Parkinsonism. Often the hyperkinesis can be scraping movements of the fingers, slight trembling of the hands, or acts of sorting fine objects. These symptoms indicate affection of the subcortical ganglions; in these cases, during sectioning, we found softening of the subcortical ganglion.

During Japanese encephalitis there is also affection of the white substance of the brain. There was either left- or rightsided hemiplegia.

Symptoms of the medulla oblongata include loss of voice (aphonia), difficulty in extending the tongue; further on there are disruptions of swallowing, full anarthria. The time of development of this symptom is 3 to 7-8 days. The quicker the symptoms of the medulla oblongata develop, the more unfavorable the prognosis is, and with a high temperature there is usually death; only in individual cases did patients with the above condition recover. Examinations during return of consciousness also give indications of affection of the brain stem.

During severe affection of the medulla oblongata the patients can die in the convalescent period. One of our patients died on the 17th day of illness with symptoms of affection of the medulla oblongata; in this case there was a clearly expressed Horner syndrome.

There was usually noted flexation, dysarthria and curving of the tongue of the patients. During examination, atrophy of one side of the tongue was noted and fibrillar jerking of the muscles, which indicates the nuclear affection of the XII pair of nerves. In one of the patients there were severe symptoms indicating affection of all the brain stem, including the subcortical ganglion, expressed by tension closing of the eyelids, hyperkinesis of the right wrist and fingers, nasality, inability to extend tongue, full anarthria with retension of the act of swallowing and with the presence of severe trophic disruptions and bed sores.

In cases of medium severity the pathological symptoms of the brain developed on the horizon of general deafness, expressed by meningeal appearances. In the patients there was a motive disturbance. They jumped from the bed; during examination they followed instructions with difficulty. The most common symptoms during this condition is perseveration.

In the clinics of similar conditions there also are characteristic vegetative symptoms, indicating the affection of the vegetative centers; they are one of the most reliable symptoms for the establishment of a clinical diagnosis. Included in this number, first of all, is the Horner syndrome, variations of breathing, pulse, appearance of a white dermographism and pilomotor reflexes; here also included are degrees and total deafness and disrupted consciousness.

Most often we encounter symptoms of affection of the frontal lobes, of the brain, in the form of grasping reflexes. Symptoms of affection of the brain stem are ordinarily expressed weakly. Symptoms of affection of the white substance of the brain can include increased tendonous and periosteal reflexes and in some cases, pathological reflexes.

The recovery period comes quickly after the temperature drop. However, some symptoms remain (variations of vision, disyness, headaches). There is variation of the taste sense on the back one third of the tongue, difficulty with extending the tongue and its inclination to one side, some aphonia, and sometimes, nasality (talking through the nose). In some cases there is fibrillar jerking of the tongue. There is trembling of the hands, even during attempts to write or handle food, etc.

The tonus is usually unvaried, but the rigidity of the occiput remains for a long period as one of the positive symptoms, even after the temperature drop.

Thus, in this group of patients the clinical symptoms indicated affection of the cortex of the brain and the white substance. We can separate the frontal symptoms from the cortex. With the temperature drop consciousness is regained, deafness disappears. During the acute period, in some cases, there are epileptic signs.

Symptoms of affection of the subcortical ganglions include an anemic face.

The cortex symptoms include deafness, variation of memory, quick faintness. In the recovery period the patients retain vegetative symptoms: perspiration, tachicardia, lability of the pulse, mixed dermographism, anisocoria and eye variations.

With the acute course we noted some cases where the symptoms developed slowly, starting with a subfebril temperature and general brain symptoms. The temperature rises to high figures. There was vomiting, rigidity of the occipital muscle, vegetative symptoms and general deafness. In such cases it is possible to diagnose encephalitis only in the course of observation.

However, during the development of such clinical symptoms, in some of the cases, there was an acute loss of weight for the patients, with the appearance of symptoms of the brain stem, stipulating the severe course of infection.

Analysis of blood and spinal fluid was conducted as a part of our work.

The morphology of the blood during our studies was not specific. Leukocytosis from 10 000 to 17 000; neutrophils in the formula were high (to 74-85%), shift to the left was seldom, lymphocytes increased, eosinophils in almost 100% of the cases were absent; monocytosis noted seldom, at the height of the illness.

In the first days of illness there was an increase of erythrocytes, and an accompanying increase of hemoglobin.

The blood chart of the recovering patient is very labile. An increase of the general quantity of the neutrophil group and bacilli

type in the stage of recovery serves as an indication of the appearance of some complication from the internal organs. The spinal fluid is transparent, and in some cases, slightly opalescent, with indications of low content of formal elements.

This epidemic of encephalitis was characterized by the small cytosis in the acute courses. The quantity of cells in 1 mm³ of material was 20-120. The quantity of albumen was very low, sometimes normal. We also noted a clear positive globuline ~~reaction~~ reaction (Pandy and Nonne-Apelt). The quantity of albumen in the spinal fluid was small, no more than 0.5 to 0.6 o/oo. The spinal fluid flowed with an increased pressure, in a stream, and only in some cases by droplets.

In the group with severe courses there was noted an increased intracranial pressure, if there was affection of the brain stem.

In the liquid there was little cytosis, decrease of albumen content during a positive globuline reaction. The earliest symptoms with these severe cases is the rigidity of the occipital muscles, an increased tone indicative of affection of the central brain.

In mildly severe cases the cytosis is increased, from 120 to 400 in 1 mm³. There were no severe clinical syndromes of the brain stem in these patients, usually characteristic of severe courses with lethal results.

The most atrophic for the virus of Japanese encephalitis are the subcortex ganglion, optical chiasm, central and medullary brain.

We cannot determine specific syndromes during this epidemic, such as Alperovich done during the Primorsk encephalitis.

The most frequent complication during this epidemic was the appearance of bedsores, indicating the disruption of the trophic system. They are usually present in cases with severe courses.

Complications of the internal organs included hemorrhagic cystitis. Ordinarily the patients complained of need to urinate. Sometimes the urine was bloody; with small quantities of albumen, in the sediment the field of vision was covered with erythrocytes. The urine disruptions last 7-8 days, very seldom longer. The cystitis usually appeared at the end of the high temperature period.

The patients also complained of subcostal pains; there usually was an enlargement of the kidney, with pain.

In some of the patients there were complaints of pain in the heart region, palpitation of the heart; the subfebrile temperatures remain for a long time. In two cases there were complications of the lower extremities, characteristic of thrombophlebitis.

Thus, in the epidemic period of Japanese encephalitis we should consider the quick start in the diagnosis of this disease- severe headaches, quick temperature rise, hyperemia of the face, depressed pulse, white dermographism, pilomotor reflex, in some cases the Horner syndrome, appearance of rigidity of the occipital and disruption of consciousness.

These are the starting and basic symptoms of Japanese encephalitis. The presence of them should require immediate hospitalization of the patients, and application of respective symptomatic and specific therapy.