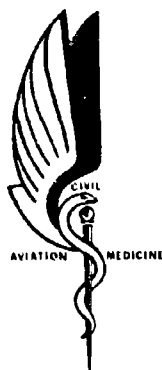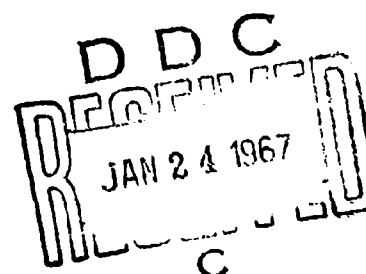


AD 645494



Problems in Aerial Application: A Comparison of the Acute Effects of Endrin and Carbon Tetrachloride on the Livers of Rats and of the Residual Effects One Month After Poisoning

July 1966



OFFICE OF AVIATION MEDICINE
FEDERAL AVIATION AGENCY

ARCHIVE COPY



PROBLEMS IN AERIAL APPLICATION:

A comparison of the acute effects of endrin and carbon tetrachloride on the
livers of rats and of the residual effects one month after poisoning

George Clark

Approved by



J. ROBERT DILLE, M.D.
CHIEF, CIVIL AEROMEDICAL INSTITUTE

Released by



P. V. SIEGEL, M.D.
FEDERAL AIR SURGEON

July 1966

FEDERAL AVIATION AGENCY
Office of Aviation Medicine

PROBLEMS IN AERIAL APPLICATION:

A comparison of the acute effects of endrin and carbon tetrachloride on the livers of rats and of the residual effects one month after poisoning

I. Introduction.

The halogenated hydrocarbons continue to be used as insecticides and many of these are aerially applied. As poisons, they constitute a hazard to those who handle them. The lack of precise information on the pathological changes induced by these compounds has seriously limited the formulation of other than very general rules for their use, has made it impossible to determine limits of exposure and has made treatment only symptomatic. In an early study it was found that there was (Clark, 1965), as stated by toxicologists, some liver damage. It was also found that cold acclimation (Clark, 1966) increased the amount of liver damage. Since the liver damage induced by carbon tetrachloride poisoning has been extensively studied, it was thought that a comparison of the effects on the liver of carbon tetrachloride and of endrin would serve to partially elucidate this problem.

II. Methods.

Forty-one male Charles River Rats, ranging in weight from 410-545 gm, were divided randomly into five groups. Two groups (A and B) of eight rats each were injected intraperitoneally once daily for three days with 3 mg/Kg of endrin dissolved in mineral oil. Group A was sacrificed on the day following the last injection of the poison while Group B was sacrificed one month later. Two Groups (C and D) of eight rats each were injected intraperitoneally once daily for three days with $\frac{1}{8}$ ml/Kg of CCl_4 dissolved in mineral oil. Group C was sacrificed on the day following the last injection of the poison and Group D one month later. At this time, Group E (nine untreated rats) was also sacrificed. No rats were lost in Groups C, D, and E, but in Group A, one animal was dead on the morning when the others were sacrificed and in Group B, one animal died on the second day after cessation

of treatment with endrin and one on the fourth day.

The animals were anesthetized with Nembutal and then decapitated. Portions of the liver were immediately removed and placed in 10% acetic formalin (Koenig et al, 1945). Blocks from each animal were embedded in paraffin and sectioned at 7 microns. Other blocks were frozen and sectioned at 10 microns. The following stains were used: Hematoxylin and Eosin, Powers' Marchi for fat (Powers, 1966), a modified Weil stain (Clark, 1966), and Cresyl violet acetate (Powers and Clark, 1955).

III. Results.

All of the animals treated with endrin lost weight during treatment (weight first day of treatment and first day after last dose) except one (#10) which inexplicably had a weight gain of 2 grams. All the others lost over 20 grams and four lost more than 50 grams—range +2 to -62 (Table 1). The three animals which died lost the most weight, 62-75 grams, but one animal which survived lost 62 grams (#12) and one 59 grams (#7). All the animals treated with carbon tetrachloride lost weight with a range of 13 to 38 grams. The control group mainly lost weight (+6 to -17 grams) during the same period.

The hematoxylin and eosin slides were of limited value but the results with the other slides will be described in some detail and are summarized in Table 1.

Cresyl violet acetate. Paraffin sections were stained with cresyl violet acetate which (Powers and Clark, 1955) is a specific for nucleic acid. Group A. In all of these there were differences apparent between the three regions of the lobule. In the perilobular areas the cytoplasmic RNA tended to be diffuse with no large clumps (Figure 1) while in the centrolobular areas the cyto-

plasmic RNA was confined to large clumps with the remainder of the cytoplasm unstained (Figure 2). The mediolobular regions were like the centrolobular. The damage was scaled on a range of 3 (Table 1). Those with RNA clumped throughout the lobule were recorded as 0, those with considerable dispersed RNA in the perilobular areas as 1 and those with marked amounts of dispersed RNA in the perilobular areas as 2.




FIGURE 1. Rat 5. Cresyl Violet Acetate. Central vein to left. Cytoplasmic RNA in large clumps. 700x




FIGURE 2. Rat 5. Cresyl Violet Acetate. Cytoplasmic RNA is diffuse with no large clumps. 700x

Group B. These were somewhat similar to Group A but differences between zones were less marked and two animals showed no differences. This group resembled the control group more than they resembled Group A.

Group C. The vacuoles in the centrolobular areas made these regions much lighter than in the remainder of the lobules. In this area clumped RNA was almost missing with cytoplasmic RNA very diffuse. In the remainder of the lobule, there was considerable diffuse RNA but clumped RNA was present in most cells.

Group D. There was considerable variation in

this group; in three there was little difference between perilobular and centrolobular areas while there were marked differences in one animal.

Group E (Control). In three animals no intralobular differences were present while in the remainder, the clumps of cytoplasmic RNA were larger in centrolobular areas than in perilobular areas.

Powers' Marchi. Frozen sections were stained with the modified Swank Davenport Marchi (Powers, 1966). Group A—In all of these there were fat-containing cells in the liver. These cells were most numerous in perilobular areas (Figure 3) while in the centrolobular areas fat-containing cells were found rarely. In one animal, the scanty fat was scattered, in another, the mediolobular area was free or virtually free of fat while there were both perilobular and centrolobular fat deposits; in another, there was fat in both perilobular and mediolobular areas while the centrolobular was almost free of fat. In contrast to Group C there was always some scattering of the fat containing cells and the fat was in smaller droplets than in Group C.




FIGURE 3. Rat 5. Powers' Marchi. Portal canal to left. The fat is in small droplets. The centrolobular areas were free of fat. 700x

Group B. The liver of one animal was free of fat and, in the others, the fat present was scattered. In two animals most of the fat present was in the von Kupffer cells. It is obvious that, in the month since the final dose of endrin, particularly all the damage had been repaired. In fact, there was very little, if any, difference (as revealed by fat content) between this group and the untreated control group.

Group C. As had been expected, the centrolobular areas were massively infiltrated with fat (Figure 4) and necrosis of cells in this area

was marked in three animals and present in all. In two animals there was marked necrosis with most of the fat in the mediolobular area.



FIGURE 4. Rat 18. Powers' Marchi. Central vein to left. The fat is predominately in large droplets and there are necrotic cells near lumen of central vein. 700x

Group D. The contrast between this group and Group C was marked. In the month since the final dose of carbon tetrachloride, much of the damage had been repaired. In fact, the livers of 5 of the 8 rats were virtually normal (as far as the fat stain revealed) and three of the five could be considered as normal. In two animals there was some fat both centrilobular and mediolobular. In none of the animals was there any perilobular fat.

Group E. The livers of two rats were free of fat while in the others there were occasional scattered cells containing fat.




FIGURE 5. Rat 5. Modified Weil. There is little differentiation and stain is quite uniform.

Modified Weil Stain. Paraffin sections were stained with the modified Weil stain (Figure 5) described in a previous study (Clark, 1966). Since the animals were not perfused and the

sinusoids contained varying amounts of blood, the method used in that report for assessing the staining intensity could not be used. Photomicrographs were taken at a magnification of 500 on 35 mm Kodalith film. In each case a representative area was chosen visually and the same exposure was used for all. The film was developed in diluted "Dektol" (1 part developer for 17 parts water) for 4 minutes at 24°C. Then 8 x 10 enlargements were made of these 35 mm negatives. Here again, the exposure was determined for one negative and the same exposure and developing time was used for all. Then the prints were arranged in rank order of the greyiness of the cytoplasm of the liver cells. This was done independently by three observers (Table 1). The rank orders for each group were summed and the means determined. The values were Group A-8.3, Group B-18.3, Group C-18.7, Group D-22.4, Group E-22.6. This indicates that whatever compound is stained by this method, presumably some substance containing a secondary or tertiary amine (Berube, Powers and Clark, 1965), the amount is markedly increased in acute poisoning with endrin. This substance is not markedly increased in poisoning with carbon tetrachloride. One month is sufficient for this material to decrease to normal amounts. Because of possible errors in the involved procedures used exact quantification was impossible. Statistical studies would be made if a microdensitometer were available. Especially interesting would be the acutely carbon tetrachloride poisoned animals (Group C) and the chronic endrin poisoned animals (Group B); the values found (18.7 and 18.3 respectively) were less than those found in Group D (one month after carbon tetrachloride poisoning) and in Group E (the controls) and may or may not be significantly different.

IV. Discussion.

The easy readability of the fat stain used (which was developed in our laboratory, Powers, 1966) materially aided the investigation. The changes seen in fat content of the liver after either carbon tetrachloride poisoning or after endrin poisoning seem completely reversible. It should be stressed that although no animals were lost in the three days of treatment, three were lost in the week following cessation of treatment. Thus, the level of the endrin was almost in the lethal range.

The meaning of the different distribution of fat in poisoning with endrin and carbon tetrachloride remains to be elucidated. Wachstein (1963) stated that "The distribution patterns of stainable lipids vary in various clinical and experimental conditions. On diets deficient in certain amino acids, particularly threonine, or in rats which are polyphagic due to hypothalamic lesions, fat droplets accumulate mainly in the cells of perilobular areas. In contrast, in choline deficiency, accumulation of lipids occurs predominantly in the central zone of the liver lobule. In toxic liver damage, stainable lipids occur likewise in central areas." However, he offered no explanation for the phenomenon.

The meaning of the changes in cytoplasmic RNA also remains to be elucidated. A tentative explanation would be that the heavily clumped RNA indicates a resting cell and that as the cell becomes more active there is a dispersion of the cytoplasmic RNA. If this is true, then the similar location (perilobular) of the fat laden cells and those with dispersed RNA would indicate that alterations in function as a result of endrin poisoning occur primarily in this perilobular area. However, there is no such localization seen with the Weil stain. Does this indicate that at least two widely different processes are seen in this poisoning? Anything further would be entirely speculative. Studies of the distribution of RNA have not been found to be very useful in the human (Farber, Koch-Weser, Szanto and Popper, 1961). The varying lengths of time before autopsy and the relatively poor fixation are undoubtedly the cause. In optimum cases the RNA was reported to be in the form of clumps while in the others the RNA was diffuse. The changes in RNA reported in this paper have apparently not been seen previously. It should be stressed that our hematoxylin and eosin slides were of limited value and that the changes seen were in those stained by Cresyl violet acetate. This is probably the reason why alterations such

as we report in this paper were not reported by Koch-Weser, Farber and Popper (1961).

There is a marked lack of correlation between the various stains and between the stains and the changes in weight (Table 1). Thus, rat #7 had little fat in the liver, marked alteration in RNA, perhaps even a decreased amount of the Weil stainable material and a large weight loss.

Toxicology texts routinely state that in poisoning with halogenated hydrocarbons liver damage occurs. Nevertheless, the amount of liver damage seen in our rats, which had quite massive doses of the poison, was really minimal and completely reversible. Our findings certainly do not suggest that altered liver function occurred in our animals.

Stains for reticular fibers were not made. Too often such stains are not particularly reliable and quantification of such data is usually of limited meaning. Recently, a new method for staining of reticular fibers was reported and it is planned to check this stain and determine if quantitative results are possible. If so, a separate report will be made. Autoradiographic studies of distribution of labeled endrin in the poisoned animals are planned. These will give some insight into the possible meanings of the alterations in liver we have reported. Also, histochemical blocking procedures will be used with the Weil stain in an effort to elucidate the nature of this material that increases in endrin and in dieldren (Clark, 1966) poisoning.

Our findings that liver damage in endrin poisoning is minimal and reversible do not mean that endrin and dieldren are not dangerous. They do indicate that the liver damage is not incapacitating and is not the cause of the deaths which did occur in our animals. Rather, our findings (Clark, 1965), (Clark, 1966, and this report) do indicate that, despite the paucity of damage we have seen, as yet, the primary action of these poisons is probably on the nervous system.

REFERENCES

1. BERUBE, G. R., POWERS, M. M., and CLARK, GEORGE: *Stain Techn.* 40: 235-238, 1965.
2. CLARK, GEORGE. In "Investigation of the effects of specific agricultural chemicals on histological tissue," Senior Investigator, L. B. Hinshaw. Report submitted 6-30-65, AM 64-6 (PIIARM-1) Phase 3, 1965.
3. CLARK, G. *OAM Report* #00-5, 1965.
4. FARDER, E., KOCH-WESER, D., SZANTO, P. B., and POPPER, H.: *Arch. Path.* 51: 300-408, 1951.
5. KOCH-WESER, D., FARDER, E. and POPPER, H.: *Arch. Path.* 51: 408-500, 1951.
6. KOENIG, H., GREAT, R. A. and WINDLE, W. F.: *Stain Techn.* 20: 13-22, 1945.
7. POWERS, M. M. and CLARK, GEORGE: *Stain Techn.* 30: 83-88, 1955.
8. POWERS, M. M. *Anat. Record.* 154: 604, 1966.
9. WACHSTEIN, M. In M. Rouiller. *The Liver: morphology, biochemistry, physiology.* Academic Press, New York. Vol. 1, p. 147, 1963.

TABLE 1

Group A Rat No.	Powers' Marchi	Cresyl Violet Acetate	Clark's Weil	Loss in Weight
1	3 PL CL	1	7 7 7	62
2	2 PL	1	10 10 10	30
3	2 PL ML	1	3 1 3	35
4	2 PL	2	5 6 5	18
5	2 PL	1	2 2 2	31
6	3 PL	1	6 5 6	31
7	1 S	2	29 27 20	59
8	2 PL	1	1 3 1	23
Group B				
10	0	1	27 19 25	+2
11	1 SA	1	10 21 20	31
12	1 S	1-0	21 17 21	62
13	1 A	0	8 9 8	21
15	1 S	1-0	34 34 34	32
16	1 S	1	4 4 4	54
Group C				
17	3 CL	2	0 6 0	22
18	3 CL	2	33 33 33	38
19	3 CLB	2	14 15 15	33
20	3 CLC 3ML	2	23 25 23	17
21	3 CLC 3ML	2	10
22	3 CL	22
23	3 CL	1	15 12 14	21
24	3 CL	16
Group D				
25	2 CL	0-1	22 18 22	13
26	1 CL (?)	1	20 22 18	15
27	2 CLS	0-1	35 35 35	17
28	1 S	0	24 20 24	21
29	1 S	0	12 14 12	16
30	0	0-1	30 32 31	23
31	2 CL ML	0-1	10 13 10	31
32	1 CL ML	1	25 28 26	33
Group E				
33				
34	0	0	18 24 19	+6
35		1-0	11 10 11	+6
36	1	1-0	32 26 32	1
37	1 S	0	17 23 17	1
38	2 S	0	31 31 30	4
39	1 S	0	28 29 28	16
40	1 S	0	13 11 13	17
41	0	0	26 30 27	2

Summary of histological studies. The amount of lipid present was estimated on a scale of 4: 0 - no fat, 1 - some fat, 2 - considerable fat, 3 - most cells fat laden. The Cresyl violet acetate stains were estimated on a scale of 3: 0 - all cytoplasmic RNA in heavy clumps, 1 - many cells with dispersed RNA, 2 - large areas of cells with dispersed RNA. The estimates of rank order of staining intensity by the three observers are given under the Weil stain. The loss in weight seen on the third day after the first dose of the poison is also given. Abbreviations: PL - perilobular, ML - mediolobular, CL - centrolobular, A - some for in von Kupffer cells, S - scattered, B - some CL necrosis, C - considerable CL necrosis.