

AD631922

①

MONITORING AGENCY DOCUMENT NO.

ASTIA DOCUMENT NO.

TITLE OF REPORT

»Toxicity changes in the central nervous system«

Oxygen deficiency and its influence on the central nervous system

NAME OF AUTHORS

Professor Dr. med. W. Scholz

Dr. med. J. W. Boellaard and Dr. med. Dr. rer. nat. H. Hager

NAME OF ORGANIZATION

Deutsche Forschungsanstalt für Psychiatrie, Max Planck-Institut

München, Germany

CLEARINGHOUSE
FOR FEDERAL SCIENTIFIC AND
TECHNICAL INFORMATION

Hardcopy	Microfiche		
\$17.40	\$1.00	178 pp	as

TECHNICAL (FINAL) REPORT

CONTRACT NO. AF 61 (514) -945

ARCHIVE COPY

PROCESSING COPY

Code 1

DATE OF REPORT

May 15 th, 1959

DDC
MAY 9 1966
E

»The research reported in this document has been sponsored by the AIR FORCE OFFICE OF SCIENTIFIC RESEARCH of the AIR RESEARCH AND DEVELOPMENT COMMAND, UNITED STATES AIR FORCE, through its European Office.«

MONITORING AGENCY DOCUMENT NO.

ASTIA DOCUMENT NO.

TITLE OF REPORT

"TOXICITY CHANGES IN THE CENTRAL NERVOUS SYSTEM."
OXYGEN DEFICIENCY AND ITS INFLUENCE ON THE CENTRAL NERVOUS SYSTEM.

NAME OF AUTHORS

Professor Dr.med. W. Scholz
Dr.med. J.W. Boellaard and Dr.med.Dr.rer.nat. H. Hager

NAME OF ORGANIZATION

Deutsche Forschungsanstalt für Psychiatrie, Max-Planck-Institut
München, Germany

TECHNICAL (FINAL) REPORT

CONTRACT NO. AF 61 (514) -945

DATE OF REPORT

May 15th, 1959

"The research reported in this document has been sponsored by the AIR FORCE OFFICE OF SCIENTIFIC RESEARCH of the AIR RESEARCH AND DEVELOPMENT COMMAND, UNITED STATES AIR FORCE, through its European Office."

A b s t r a c t .

Part I

The Morphologic Pattern of Oxygen Deficiency in the Human Brain.

43 cases of complete cerebral ischemia and of hypoxemia in the blood stream are microscopically investigated and the results compared as to the histology, topography and topistic pattern of the lesions. The differences in the clinical symptomatology of the two groups in regard to onset and development are considered. The histology of the lesions in the brain tissue does not differ essentially from that in local cerebral ischemia. Total ischemia, as a rule, causes mainly selective neuronal necrosis and incomplete tissue necrosis (softenings). The survival depends on the duration of the ischemia. The earliest reaction of microglia was observed after 18 hrs., of macroglia after about 64 hrs., and the newformation of fibrous astrocytes after 6 - 9 days. Selective neuronal necrosis alone forms only scanty sudanophilic products. Edema may elicit a moderate general fibrous gliosis without demonstrable relation to local loss of nerve structures. Selective neuronal necrosis is the predominant damage in hypoxemia. The exception is carbon monoxide poisoning, where focal lesions of vascular origin play an important role. Topographically, the cerebral cortex, Ammon's horn, thalamus, striatum and the cerebellar cortex are affected by the most intense changes in total cerebral ischemia. The severity of lesions diminishes generally towards the medulla oblongata. In contrast, states of severe hypoxemia in the newborn do not involve the cerebral and cerebellar cortex. The most characteristic changes occur in the globus pallidus, the corpora Luys, and the Ammon's horn. The thalamus and striatum may occasionally present focal lesions (status marmoratus). This clear distinction is not observed in later life, yet careful examination of cases of hypoxemia demonstrates even then the prevalence of damage to the basal ganglia, especially the globus pallidus. A special vulnerability of certain grey substances to oxygen deficiency is suspected. This assumption is supported by the topistic pattern of such lesions, which means their confinement to the area of a cortical lamina or

field or of an architectonic unit as e.g. the globus pallidus. They occur as a rule symmetrically. Such topistic patterns are rather numerous in states of oxygen deficiency. In total cerebral ischemia they are observed as laminar lesions in the cerebral and cerebellar cortex, as destruction of whole fields, i.g. in the Ammon's horn or of whole nuclei as the inferior olives. The most impressive feature of this pattern is the holotopistic combination - globus pallidus - corpus Luyssi in asphyxia or severe progressive anemia of the newborn, which is occasionally associated with the same type of lesion in the dentate nucleus. The role of a rather intensive gliosis without corresponding lesion of nerve tissue, located especially in the basal ganglia in cases of chronic anemia and their topistic pattern in the globus pallidus are described. The results are discussed with respect to cases in the literature, representing the familiar conditions of oxygen deficiency.

Part II

A) Electronoptic Studies on the Earliest Structural Changes of the Brain Caused by Hypoxidosis.

The effect of acute energetic insufficiency on the fine structure of nerve cells has been studied. In order to obtain knowledge concerning the normal nerve cell structures and to establish a basis for comparison, primary studies dealt with evaluation of the ultrastructures in the normal cerebral cortex of the Syrian hamster. The fixation of the brains was accomplished by perfusion. The hamsters were exposed to repeated nitrogen asphyxia to acutely lowered pressure, and to suitable dosages of potassium cyanide. The nerve cell changes, observed in the electronmicroscope, were predominantly located in the perikaryon. The mitochondriae became swollen, their inner membrane system disintegrated, the matrix disappeared and finally, vacuolar structures developed. The membrane bound profiles of the endoplasmic reticulum enlarged, the bordering membranes lost their connection and the Palade granula were rarefied. The alterations were essentially equal in hypoxemic and dysenzymatic hypoxidosis. The changes may be interpreted as being due to elevation of the intracellular osmotic pressure and to acute disturbance of the water metabolism. It was difficult to evaluate the findings in the nucleo-nucleolar system.

B) Studies on the Reversibility of Ultrastructural Hypoxidotic Changes in Ganglion Cells of Warm-Blooded Animals.

In order to study the reversibility of nerve cell changes caused by hypoxidosis, different experiments were carried out with the aim of inducing hypoxidotic damage under equally reproducible, fundamental conditions. Subsequently, the regression of the changes was to be studied at different time intervals in case of survival. Asphyxia secondary to administration of curare, succeeded by artificial respiration of the intubated animal or temporary occlusion of the airway followed by artificial respiration, did not prove successful. Then a series of tests was done, employing a standardized nitrogen asphyxia with subsequent killing of the animals at different time intervals. The evaluation of the results has not been completed as yet. So far they do not reveal anything conclusive as to the reversibility of fine-structural cellular changes caused by hypoxidosis of warm-blooded animals.

C) Methodic Examination to Evaluate the Possibility of Quantitative Cytologic Research on Anoxic Nerve Cells.

For the purpose of collecting detailed information concerning the physico-chemical condition of characteristically altered nerve cells (ischemic necrosis), a method was used which dealt with the microscopic interferometry of masses of biologic objects. The usual methods of optical determination of masses were scrutinized. Finally the formulas which are used in calculating the mass per square unit as measured by the path difference were revised. For experimental purposes, a machine was designed which photometrically measures the phase differences of screened out regions of the objects. Theoretical considerations lead to the introduction of a so-called two-wavelength method, the applicability of which, for the interferometric determination of masses in the microscopical range, was tested and interpreted. From the practical standpoint, a greater accuracy of measurement is to be required. This may be achieved by perfection of the measure system.

Table of Contents

Part I

The Morphologic Pattern of Oxygen Deficiency in the Human Brain.

Introduction

Material and Methods

Casuistics

Histologic Findings in the Brain Changes

Topographical Data Regarding Tissue Changes and Regional
Distinctions in Intensity

Topistic Pattern of Anoxic Lesions

Clinical Aspects

Discussion

Part II

A) Electronoptic Studies on the Earliest Structural Changes of the
Brain Caused by Hypoxidosis.

Material and Methods

Animals Experiments

Normal Findings

Findings after Hypoxemia and Dysenzymatic Hypoxidosis

Discussion

B) Studies on the Reversibility of Ultrastructural Hypoxidotic
Changes in Ganglion Cells of Warm-Blooded Animals.

Material and Methods

Results

C) Methodic Examination to Evaluate the Possibility of Quantitative
Cytologic Research on Anoxic Nerve Cells.

TOXICITY CHANGES IN THE CENTRAL NERVOUS SYSTEM.

OXYGEN DEFICIENCY AND ITS INFLUENCE ON THE CENTRAL NERVOUS SYSTEM.

Part I.

The Morphologic Pattern of Oxygen Deficiency in the Human Brain.

Prof. Dr.med. W. Scholz and Dr.med J.W. Boellaard

Introduction.

Considerable pathologico-anatomical research has been done concerning the influence of oxygen deficiency on the brain. A large part of the research work has been experimental. Initially these studies were carried out systematically on different animal species by A. MEYER and MEYER and BLUME, who produced hypoxia by carbon monoxide and asphyxia by narcosis. Later on more extensive studies were done in the school of F.BÜCHNER, especially so far as tests in the low pressure chamber are concerned (BÜCHNER and LUFT, ALTMANN and SCHUBOTHE among others). Fundamental experimental studies about anoxia caused by total cerebral is hemia have been done by WEINBERGER, GIBBON and GIBBON, and by GRESELL, among others. In the majority of studies a primary withdrawal of oxygen was accomplished by exterior manipulations by which the chain of cellular oxidation processes is interrupted. Here, we deal with a special case of anoxic or hypoxic hypoxidosis (STRUGHOLD) which has been compared with a nutritional hypoxidosis due to lack of glucose and a dysenzymatic hypoxidosis due to cyanogen. The effect of interruption of the reaction chain always produces the same picture: an end of life processes, cell death, and necrosis. These are the features which characterize the cerebral damage due to lack of oxygen.

It is more difficult, however, to understand the degree and topography of cerebral damage. The former is apparently determined by duration and completeness of anoxia and moreover by the speed of its onset. In evaluating the development of diffuse or of focal cerebral damage, it must be considered whether the oxygen withdrawal has affected the brain

alone, or the entire body. Likewise, what has been the damage to other organs, especially the heart, and whether, in case of survival, there is any retroaction on the brain from the circulatory system. A number of inconsistencies and irregularities which are encountered during the experiments, in particular morphologic changes that oftentimes only occur after repeated oxygen deficiency, may be explained by the complicated circumstances as outlined above. In cases of primary damage to the brain, certain cerebral regions are regularly affected by changes and this suggests that certain brain areas may be particularly vulnerable to anoxia. Also the effects of central regulatory disturbances of respiration and circulation on the brain are to be expected in anoxia.

In quite a number of clinical cases cerebral changes have been caused by lack of oxygen. At first, attention was drawn to the very regularly occurring symmetrical softening of the pallidum secondary to oxygen blockage of hemoglobin by carbon monoxide. Later were reported cases of temporary heart and respiratory arrest in narcosis and also the findings after survival from strangulation, asphyxia, atmospheric hypoxia and acute secondary anemia etc. These findings exhibit certain topographical patterns which are demonstrated with a certain regularity. Understandably, the demonstrable findings are not uniform because of the multifold interactions of effects and retroactions precipitated by the general oxygen deficiency. A circulatory collapse may cover a simultaneous hypoxemia and make its topographical pattern inrecognizable.

In experimental work, it is possible to control and eventually correct all factors and phases to a certain extent. In this paper, however, we deal only with research done on human beings and are thus compelled to chose a situation which resembles experimental conditions to a satisfactory extent. Therefore it may be expected that the best results are obtained in determination of topographical lesions, due to one single state of oxygen deficiency with a minimum of interfering processes. BÜCHNER (1957) differentiates between a pallidum type in acute hypoxemia and a striatum type in general oligemia, such as circulatory collapse or cases of temporary heart arrest. In the evaluation of our own studies and the results of other investigators, we have (SCHOLZ 1952) drawn attention to the differences between the cerebral pattern in hypoxemic and ischemic oxygen deficiencies. The main effect of the latter was observed in the

cerebral cortex with no particular involvement of the globus pallidus. In investigating a large number of human cases which have accumulated within a period of several decades, we are aware of the fact that we have to sacrifice the measurable conditions of the experiment for the advantage of direct observation of lesions with a more or less nebulous pathogenesis. Thus, at least an austere selection of cases had to be made in order to establish a comparable pathogenetic basis. Only a fraction of the cases of oxygen deficiency was selected. In consideration of the above listed differences in regard to the topography of cerebral manifestations, we adhered to a classification first, of hypoxemic oxygen deficiency in the circulating blood and second, of oligemic or ischemic oxygen deficiency. The problem of dysenzymatic hypoxidosis has not been made a subject of this study since we can experimentally produce the same type of cerebral reaction pattern, and no clinical cases are available. Other types of hypoxidosis, for instance, the glucose deficiency in insulin shock, are even less in accord with established experimental requirements and are moreover complicated with cerebropathological disturbances (general convulsions). Therefore, they offer little possibility for comparison in cerebral topography.

It is understandable that every type of acute hypoxemia effects the entire body regardless of whether it is caused by diminished oxygen pressure of the respiratory or alveolar air or whether by reduction of the oxygen carrier in the circulating blood. Even though the central nervous system is known to be the most sensitive organ of the body and suffers primary damage from hypoxia, additional factors may rapidly become effective secondary to a heart muscle and liver damage. Our own experimental studies revealed, that there were also effects upon the circulatory periphery, manifested by constriction and dilatation of the vessels. Hence, not every change in the brain can be attributed to the original hypoxemia. This especially holds true in respect to the frequently encountered focal damage which can only be explained by some action of the circulatory system. The cerebral circulatory system is capable of balancing a critical oxygen deficiency in the brain tissue for a certain period of time, provided that the hypoxemia is not overwhelming. However, the balancing mechanism cannot become effective in case of a circulatory arrest; then the oxygen deficiency exerts

immediately its full destructive action upon the tissue. Furthermore it has to be taken into account, that in ischemia we deal with a multiplicity of factors. We encounter a lack of glucose besides oxygen deficiency and a loss of irrigating function (OPTZ and SCHNEIDER) which is accompanied by an accumulation of metabolites in the tissue. If one deals with a prolonged general circulatory collapse or with a temporary heart arrest, one has to expect the same effects upon the whole body as in hypoxemia. This becomes important from the standpoint of survival and the cerebral changes developing in such a case. Other aspects have to be considered in cases of unsuccessful suicidal strangulation. Here, at least at the onset, one encounters an isolated cerebral total ischemia, which, aside from temporary asphyxia and additional incurring heart arrest, causes the development of cerebropathogenic changes seen in case of survival. DRESZER, in the experimental production of such cases demonstrated histologically that the disturbances of blood distribution in the peripheral areas can without preceding collapse, outlast the return of consciousness for quite some time. This disturbance can only be interpreted as due to a centrogenic reflex.

The oligemic and cerebro-ischemic conditions differ from the hypoxemic ones mainly by the rapid development of clinical symptoms and the development of morphologic manifestations. Hence, death is much more rapid and the number of patients which survive any length of time is rather small. There are only a few cases with symptoms of decerebration which have morphologic changes secondary to a long time survived cerebral ischemia.

In every case necrosis characterizes the histologic pattern of acute oxygen deficiency. The pathology of the cerebral circulatory system demonstrates the multifold morphologic pictures. They comprise different types, namely total tissue necrosis, tissue softening with subsequent cyst formation and elective parenchymal necrosis which develops in various severity from necrosis of single nerve cells to destruction of the whole nerve cell population of an area. It produces finally a gliofibrous sclerosis followed by more or less intensive shrinkage. The latter may quantitatively be of so minor degree that it is not demonstrable. It is assumed that the histologic process in total cerebral ischemia runs a course similar to local ischemia, which indicates that

the severity of tissue changes depends on the completeness and duration of circulatory arrest. The longer the duration in the development of critical hypoxemic conditions and in the interference of protective circulatory actions, the better is the possibility of less tissue damage in regard to elective parenchymal necrosis. However, the changes in cardiac circulation and angiospasm and stasis may also lead to the development of focal lesions which, as for instance, in carbon monoxide poisoning, oftentimes reach the state of malacia. As the central nervous system is not a simply and uniformly structured organ, it cannot be expected that a critical acute hypoxemia or total ischemia would effect it in a uniform manner. Besides the already mentioned focal changes which depend on the vascular supply, one encounters circumscribed lesions, the extent of which is not determined by the angio-architecture, but by the structure of the nervous system. Here, we deal with slight or total loss of nerve cells in certain layers of the cerebral and cerebellar cortex, in cytoarchitectural cortical regions and in several nuclear areas, in particular, globus pallidus, corpus luyisi, dentate nucleus and nucleus olivarius inferior. Eventually, a loss of the appertaining medullated fibers is associated. C. and O. VOGT designated the above cerebral changes as topistic brain damages in the development of which certain peculiarities of metabolism are believed to play an essential role. They determine the development and degree of tissue changes to a rather great extent and the question is raised, whether these cyto-architecturally characterized nerve elements possess a particular sensitivity to oxygen deficiency or even a specific pathoclisis in the sense of C. and O. VOGT. Topistic brain damages are not only found in states of generalized cerebral oxygen deficiency but are also seen in areas of local circulatory disturbance, provided that the damaged area is large enough and the damage of sufficient intensity. In regard to the formal pathogenesis of such manifestations we wish to refer to the reports of SCHOLZ (1952, 1957). Thus, most of the work done in our research deals with the topography of morphologic changes in certain brain centers and systems. From the qualitative histological standpoint, one phenomena remains enigmatical, namely, the extensive fiber gliosis in arrested cases which is not accompanied by a corresponding loss of nerve structures. This has also been observed by other investigators. The differences in intensity are

subject to much discussion and the question is raised, whether the glia is also damaged in the sense of a transitory reactive paralysis. Moreover, from the available data of numerous cases dealing with the onset, duration of oxygen deficiency and time of manifestation, several questions may be answered concerning development, sequence of regressive and reactive histological phenomena. The clinical data of our investigations must necessarily be limited since none of the investigated cases could be clinically observed by us and we had to refer to the data given by other clinicians. We were able to collect a great deal of valuable data regarding cause, development, duration and sequelae of cerebral oxygen deficiency as well as of other supplementary causes responsible for cerebral damage. Certain peculiarities in the course of illness, as for instance, prolonged progression despite only one single noxious effect to the brain, have posed other problems to be solved.

Material and Methods.

The German Research Institute for Psychiatry in Munich has furnished us with the necessary medical records for our investigations. From its collection of cases only such could be chosen in which there was definite evidence of a temporary cerebral oxygen deficiency. A large series of cases was excluded from our studies, namely, the ones which deal with interruption of circulation in extensive cerebral areas secondary to temporary occlusion of inflow and outflow as in tentorial herniation (PENFIELD et al.). Also excluded were cases with extensive circulatory disturbances as in generalized convulsions (SCHOLZ 1951). 43 cases were found suitable for our investigation and subjected to detailed review and evaluation¹⁾. One series of cases was selected in which, according to the clinical data, an oxygen deficiency in the circulating blood had to be assumed, such as secondary to diminution of oxygen pressure in the respiratory air, to occlusion of the respiratory ways, also to respiratory arrest (asphyxia) and to blockage of hemoglobin by carbon monoxide. Likewise included were cases of the

1) We are grateful to Prof. H. JACOB, Hamburg, who furnished us with a number of valuable cases. They are identified by the marking "Hamburg" which appears before the identification number. The cases from our institute have been marked "FA".

blood dyscrasias characterized by a rapidly progressive diminution of erythrocytes, which have the role of an oxygen carrier; for instance, icterus neonatorum and acute secondary anemias. We have not touched the problem which deals with the controversial pathogenesis of kern-icterus in icterus neonatorum nor with the questionable restitution in acute cases. We have chosen only older cases in which were exhibited uniform and clearly defined neuronal defects that could be compared with those secondary to birth asphyxia. In order to study the influence of chronic hypoxemia on the brain we evaluated cases with certain types of heart defect. We chose those types characterized by defective arterialization of blood due to communication between the right and left heart and in which the stenosis of the A. pulmonalis contributes an additional circulatory factor (Fallot's type). Severe chronic anemias were also investigated. The group of cases with hypoxemic oxygen deficiency was compared with another group in which there was total cerebral ischemia caused by temporary heart arrest or strangulation. Furthermore we have added two cases of poisoning due to an enzyme poison known for its non interference with the cellular oxidation processes. In both cases there were such severe attacks of general oxygen deficiency during the course of illness that they must be held responsible for the severe changes that took place in the brain.

Our material is incomplete in so far as we have no cases of total cerebral ischemia surviving more than 9 days. In acute hypoxemia we have essential cases with characteristic late changes, as in birth asphyxia and in morbus hemolyticus neonatorum, and are lacking cases with acute changes. It seems that the adult brain changes in some way its form of reaction. It has proven that it is rather difficult to provide the apt material for the study of the pattern of hypoxemia in adult brains. At all events, the composition globus pallidus - corpus Luysi which is found rather frequently in newborn, is no more met in later life.

In considering the given view points, the material was classified as follows:

- I. Oxygen Deficiency Produced by Cerebral Ischemia
 - a) Cardiac Arrest (6 cases)

- b) Survived Strangulation (8 cases)
- II. Oxygen Deficiency Produced by Hypoxemia
- a) Respiratory Arrest and Related Conditions
 - 1 Asphyxia at Birth (4 cases)
 - 2 Acute and Chronic Dyspnea, Respiratory Arrest (4 cases)
 - b) Atmospheric Hypoxidosis (2 cases)
 - c) Anemic Conditions
 - 1 Morbus Hemolyticus Neonatorum (Survived Kernicterus) (4 cases)
 - 2 Chronic Anemic Conditions (3 cases)
 - d) Defective Arterialization of the Blood with Circulatory Insufficiency (Congenital Malformation of Heart) (4 cases)
 - e) Survived Carbon Monoxide Poisoning (3 cases)
 - f) Severe States of Hypoxia during the Course of Poisoning with E 605 BAYER (2 cases)
- III. Complicated, not Clearly Defined Conditions of Oxygen Deficiency (3 cases)

The entire brain tissue was available for histological work-up. Large blocks from frontal, central and occipital regions and from symmetrical areas of the hippocampo-temporal region as well as the cerebellum including the dentate nucleus were taken. The basal ganglions, as a rule, were examined by symmetrical parts from several frontal sections. The examination of the mesencephalon and medulla oblongata was carried out at different levels, always including tissue from the nigra substance and the inferior olives. In all cases was used the celloidin imbedding technique. Staining was done by different methods: Nissl, hematoxylin-eosin, and van Gieson. In addition, in frozen sections, the myelin sheaths were stained according to the technique of Schröder, the glia fibers according to the method of Holzer and, if necessary, supplementary staining was done by the technique of Mallory. In acute cases the fat stain method by Romeis was employed. In a few cases the axis cylinders were stained by the Bielschowsky method.

Casuistics.

- I. Oxygen Deficiency Produced by Cerebral Ischemia.
- a) Cardiac Arrest.
 - 1.) Schre., F.A. 80/56, male, 36 years.

Asthma with severe attacks for several years, congestion of the lungs. Sudden collapse with cardiac arrest; intracardial injection, cardiac massage. Cardiac activity returned after some minutes, but cyanotic and unconscious, death 5 hrs. after onset of cardiac arrest.

Autopsy: Cerebral congestion, some subarachnoidal hemorrhages, no cerebral edema. No pulmonary embolism, as suspected.

Histology: Convincing changes of the nerve cells are present only in the cerebral cortex and the Ammon's horn. They consist partly in slight swelling with loss of the Nissl bodies, foamy structure of the plasm and darkening of the nuclear sap, partly in shrinkage with dark elongated nuclei; no eosinophilia. Here and there tendency to nuclear pyknosis of the oligoglia. In contrast to these findings may be observed a remarkably good preservation of neurons and glia cells in the cerebellar cortex basal ganglia extending to the medulla oblongata. No interstitial reaction.

Topography: Cerebral cortex, Ammon's horns.

Comment: As a reactive process is absent, it may be concluded from the contrast between the preserved nerve cells of the cerebellar cortex and of the basal ganglia to the changes of ganglia cells in the cerebral cortex and in the Ammon's horn that the state of the latter is due to an intravital regressive process. Although the uncharacteristic nerve cell changes have no convincing marks of necrosis, they may be related to the cardiac arrest, this is suggested because of their location in regions, where lesions are found after a stop of the cerebral circulation. This cannot be definitely decided whether the circulatory arrest or the time of manifestation (5 hrs.) was too short for the producing characteristic forms of cell necrosis.

2.) Pauk., F.A. 365/32, female, 33 years.

Schizophrenia, hospitalized for many years. General cachexia, sitophobia. Collapsed suddenly, was apparently dead for 20 min.: no pulse, no respirations. After application of several stimuli heart activity and respiration returned 20 min. later. Hypothermia, temperature remained on a level of about 20° C. Death 8 hrs. after cardiac arrest.

Autopsy: General atrophy. Congestion of the pial vessels, several subdural hemorrhages.

Histology: Severe neuronal changes from swelling to vacuolated plasm

dissolution, some pericellular incrustation, nuclear hyperchromatosis and pyknosis, partly resembling ischemic necrosis without eosinophilia combined with pyknosis of oligoglia and astroglia (Fig. 1). Nearly all nerve cells in the cerebral cortex and the Ammon's horn are involved; many of the Purkinje cells show necrosis with strong basophilia, whereas all nerve cells of the dentate nucleus demonstrate complete tigrolysis and extreme nuclear pyknosis. Severe alteration of the striatum is in contrast to relatively mild changes in the globus pallidus. Thalamus only partly involved. Changes gradually decreasing to the medulla oblongata. Swelling of the oligoglia in the cerebral white matter, amoeboidosis of astrocytes. Beginning cortical edema and edema of the cerebral white matter.

Topography: Cerebral cortex, Ammon's horns, striatum, cerebellar cortex, thalamus, inferior olives (?).

Comment: The clear cut picture of nerve cell necrosis, combined partly with regressive glial changes permit the changes to be considered as the effect of cerebral ischemia from cardiac arrest. The regressive state of astrocytes in some cortical regions indicates a local early stage of softening. But in general we deal apparently with a selective neuronal necrosis.

3.) Ko., F.A. 177/28, male, 60 years ¹⁾.

Carcinoma of the rectum. During operation in ether anesthesia cardiac arrest for 10 - 15 min., respiratory arrest for 25 - 30 min. Resuscitation after artificial respiration and heart massage. Nearly permanent generalized convulsions, unconsciousness. Death 15 hrs. after onset of the cardiac arrest.

Autopsy: Metastases within the liver.

Histology: Extended laminar pallor especially in lamina III of the cerebral cortex caused by ischemic nerve cell necrosis in all stages of development with and without pericellular incrustations; changes most pronounced in the depth of the sulci, relative preservation of the visual cortex. Laminar changes are here and there composed of a series of focal lesions within the same layer. Ammon's horns not available. Nearly all Purkinje cells and small cells within the

1) This case is published by G. Bodechtel, Z.Neur.117,366,1928, case 1

cerebellar molecular layer demonstrate necrosis. Striatum is severely involved with nerve cell necrosis, all neurons of the pallidum have also undergone necrosis. Within the thalamus (as far as available) disseminated nerve cell necrosis. No noticeable changes in the medulla oblongata. Oligoglia and some parts of the astroglia in the cerebral and cerebellar cortex show pyknosis. Slight progressive reaction of microglia within the white matter, edema of the central parts of the white matter.

Topography and scale of severity of lesions: Cerebral and cerebellar cortex, striatum, pallidum, thalamus (other parts of the basal ganglia are not available).

Comment: Severe regressive changes of oligoglia and astroglia, combined with ischemic nerve cell necrosis in some places of the cerebral and cerebellar cortex point to local softenings; most of the lesions, however, have the character of selective neuronal necrosis. A topistic pattern of the lesions becomes visible from the laminar changes and the relatively good preservation of the visual cortex. Beginning glial reaction within the white matter (15 hrs.).

4.) Lar., F.A. 290/56, male, 53 years.

Cardiac arrest during bronchoscopy in anesthesia. Cardiac massage, returning cardiac activity after 20 min. Death 4 days later.

Autopsy: Slight pressure conus at the cerebellar tonsils; borders between the cortex and white matter are not always quite distinct.

Histology: Extended selective neuronal necrosis throughout the whole cerebral and cerebellar cortex, including the cerebellar granular layer and the dentate nucleus (Figs. 2, 4). Cortical nerve cell necrosis is found frequently disseminated only or as laminar pallor (III or III and V), or locally involving the whole neuronal population, in some places reaching the state of softening (Fig. 3). Within the Ammon's horn only the granular layer remains. Nerve cell changes from simple swelling without nuclear changes to convincing necrosis (ischemic changes with nuclear destruction and eosinophilia). Nearly all thalamus, striatum, globus pallidus, and substantia nigra are involved in the same way. Within the preserved medulla oblongata the inferior olives present by means of serial control a topistic

lesion of their nerve cells extending over the whole nuclei (Figs. 5, 6). In many places the oligoglia are pyknotic; reaction of all other interstitial elements, except the mesenchymal cells of the vessel walls, which participate only in areas of beginning softening. Numerous fully developed cortical neuronophagies. Glial shrubs and diffuse glia proliferation in the cerebellar cortex also (Fig. 4), rod cells, with some containing fat droplets. Numerous progressive astrocytes, some of them with glial fibers (Fig. 7), local edema in the cerebral white matter with moderate myelin decay; in the cortex only symptoms of a slight alteration of cortical myelin fibers.

Topography and scale of severity of lesions: Cerebral cortex including Ammon's horn, cerebellar cortex, thalamus, striatum, substantia nigra, globus pallidus, inferior olives, cerebral white matter.

Comment: The histopathologic situation within the brain makes evident the ischemic effect of the cardiac arrest. In spite of its endurance for 20 min. the failure of mesenchymal reaction and the condition of the astrocytic glia demonstrate mainly a selective neuronal necrosis. Only some regions of the cortex are in an early state of softening. The time of 4 days was sufficient for the production of much neuronophagy, the formation of fatty products and even of some fibrous astrocytes, many of them of the protoplasmatic type. As neuronophagic reaction is only observed nerve cells with nuclear destruction, the simple swelling of nerve cells cannot be considered as a form of necrosis. A topistic pattern becomes visible because of laminar pallor. The neuronal necrosis, confined to the inferior olives, constitutes an example of a holotopistic lesion.

5.) Ba., F.A. 301/51, female, 42 years.

Compression of spinal roots C 6, C 7 by spondylosis deformans with osteochondrosis. Operation under local anesthesia by injection of novocain-suprarenin into the deep muscles of the neck. Nausea after about 8 min., vomiting, respiratory arrest, cyanosis and cardiac arrest. Thoracotomia, cardiac massage, intracardial injection. Returning of regular heart and respiratory activity 25 min. after cardiac arrest. Continued unconscious, transitory rigidity of all extremities. Death 6 days after the cardiac arrest.

Autopsy: No symptoms of elevated intracranial pressure, brainweight 1350 g; several small hemorrhages in the white matter of the cerebellum.

Histology: Mostly disseminated selective neuronal necrosis in the whole cerebral cortex; increased intensity with laminar pallor in the occipital cortex and the depth of the sulci in the central region. In the Ammon's horns only the granular layer remains. Nearly complete nerve cell loss of the thalamus with demyelination of the medial part (Fig. 8), disseminated loss of the small nerve cells in the striatum, locally changing; the Purkinje cells are homogenized, partly with involvement of the granular layer and the dentate nucleus. No convincing changes in globus pallidus, corpus Luysi, substantia nigra, medulla oblongata. Nerve cell changes from simple swelling without nuclear changes to pronounced necrosis (ischemic cell change with nuclear destruction and eosinophilia). Some destruction of the cortical myelinated fibers. Oligoglia as satellites of necrotic nerve cells are partly pyknotic. Considerable proliferation of astroglia and microglia, producing rod cells, macrophages containing fatty granules, astrocytes with increased plasma (Fig. 9) and, in some places (thalamus, Ammon's horns, white matter), also producing glial fibers (Fig. 10). No participation of the mesenchymal tissue of the vessels. No pronounced edema.

Topography and scale of severity of lesions: Thalamus, Ammon's horn, cerebral and cerebellar cortex, striatum.

Comment: This case is similar to case 4. There is no evidence of softening anywhere in spite of an respiratory and cardiac arrest of 25 min. duration. The lesion may be more severe in so far as the Ammon's horn is nearly completely involved, as the cerebellar granular layer participates with selective neuronal necrosis, and the myelinated fibers of the cortex demonstrate an extended destruction. The formation of neuronophagy remains in the background in favour of a diffuse proliferation of rod cells which contain fatty products. Astrocytic proliferation with plasmatic and some fibrous cells has fairly progressed, especially in the thalamus, Ammon's horn and the white matter of the hemispheres, without noticeable myelin loss. A topistic tendency appears only in the pronounced laminar lesions of the cortex and the preservation of the stratum granulosum of the

Ammon's horns. Globus pallidus, subthalamic region, nigra substance and medulla oblongata are remarkably well preserved.

6.) Dyr., F.A. 239/49, male, 13 months.

The child was transferred to the hospital with dyspepsia. One day he was found with the body outside the bed, his head, pressed through the staves of the bed, lying inside the bed, with the chin on the mattress. Incomplete strangulation with cyanosis, respiratory and cardiac arrest of about 10 min. duration. The child remained unconscious, had frequent generalized convulsions and died 9 days after the accident.

Autopsy: Brain weight 960 g. Moderate engorgement of the veins. Meninges slightly cloudy. The cortex shows patchy grey or grey-reddish discoloration with here and there a rather soft consistency. Otherwise no abnormalities. Some small perivascular hemorrhages.

Histology: Severe neuronal destruction within the whole cerebral cortex, partly as disseminated ischemic nerve cell necrosis, involving more than one half of the population, and partly as laminar or total pallor; in some places transition to local softening. In the Ammon's horn only the stratum granulosum is preserved. The thalamus has lost nearly all of its nerve cells in its dorsal and lateral region, the striatum nearly all of its small cells. In contrast to these severe changes, the cerebellar cortex is much less involved; only relatively few Purkinje cells are homogenized. Globus pallidus and corpus Luysi offer only little changes. Within the fairly well preserved medulla oblongata many of the nerve cells of the whole inferior olives show pericellular incrustation and neuronophagy, increasing in caudal direction. Of most of the necrotic nerve cells only scanty nuclear debris remains, the perikaryon is not demonstrable; in other places it shows a bright eosinophilia (Fig. 13). Microglial and macroglial reaction is fully developed in all places with severe lesions, i.g. in the whole cerebral cortex, thalamus, striatum, Ammon's horn. Rod cells, macrophages and some fat granular cells may be observed (Fig. 11). Large astrocytes with considerably enlarged nuclei and cell body are present (Fig. 12), some of them fiberbuilding in the Ammon's horn (Fig. 14). New formation of fibrous astrocytes is in the cerebral white matter also

(Fig. 15). The mesenchymal tissue is active only in such regions where softening has occurred. A few fatty transformation products, partly within rod cells and granular cells can be found in the cerebral cortex. The anoxic lesions are complicated by a developing purulent meningitis, causing glial reactions in the bordering nervous tissue of the endbrain, the cerebellum and the subependymal tissue. Both processes are well differentiated.

Topography and scale of severity of lesions: Cerebral cortex, Ammon's horn, striatum, thalamus, inferior olives, cerebellar cortex, globus pallidus, corpus Luysi.

Comment: Severity of lesions from disseminated and complete neuronal necrosis and in some places transitional conditions to softening. Cardiac arrest is here complicated with strangulation of an unknown duration and with the occurrence of numerous generalized convulsions after the accident. This may explain the remarkable severity of lesions in contrast to the preceding cases. The relatively great resistance of nerve cells with ischemic necrosis (plasma coagulation) to re-sorption may be observed in the Ammon's horn in the midst of an intensive diffuse astrocytic and microglial proliferation. After a manifestation time of 9 days the local stages of organization are locally remarkably different. It cannot be determined whether this depends upon an initial paralysis of the glial elements or whether convulsive lesions are superimposed. Except for the laminar predominance of the cortical lesions and the preservation of the stratum granulosum in the completely involved Ammon's horn, a topistic pattern becomes visible from the complete involvement of the inferior olives in an otherwise well preserved medulla oblongata.

b) Survived Strangulation.

7.) Höl., F.A. 4/52, male, 56 years.

Depressive reaction. Attempted suicide by hanging; was found unconscious 4 - 5 min. later and transferred to the hospital. Rattling respiration, regular pulse. Blood pressure 100/70 mm Hg. Generalized muscular rigidity, oscillating nystagmus. Nearly absent reflexes, on provocation short periods of spasticity. Death 18 hrs. after hanging.

Autopsy: Brain weight 1280 g. General hyperemia, no symptoms of intracranial pressure.

Histology: Within the whole cerebral cortex, decreasing from the frontal to the occipital lobe, and intensified in the insular cortex, is selective neuronal necrosis with numerous disseminated nerve cells in the condition of ischemic necrosis partly with eosinophilia of the plasm (Fig. 16). These changes are pronounced in lamina III and more intensive in the base of the sulci. Sommer's sector and the layer of the Purkinje cells are equally involved; likewise the lateral nucleus of the thalamus. Striatum, globus pallidus, midbrain and medulla oblongata morphologically intact. No regressive changes of any glia cells. Just beginning neuronophagy within field h_3 of the Ammon's horn.

Topography and scale of severity of lesions: Cerebral cortex, Ammon's horn, cerebellar cortex, thalamus.

8.) Küch., F.A. 122/31, male, 37 years.

Attempted suicide by hanging in the prison; was found unconscious after an unknown time of hanging and was transferred to the hospital. Enforced respiration, strong pulse, cyanosis of the face, cramped extremities, sometimes twitches. No spastic reflexes. Remained unconscious. Death 18 hrs. after hanging.

Autopsy: Bronchopneumonia, conjunctival hemorrhage.

Histology: Within the whole cerebral cortex is severe changes with nerve cell necrosis; in the frontal region nearly the whole population is involved, likewise in the temporal region and the Ammon's horn; the visual cortex is least affected with only disseminated ischemic nerve cell necrosis. Large areas of the Purkinje layer demonstrate typical homogenizing eosinophilic necrosis without convincing involvement of the granular layer. The thalamus participates with a moderately disseminated selective neuronal necrosis only, likewise the striatum, mainly its small cells, and the globus pallidus. Midbrain, especially nigra substance and medulla oblongata, show no changes. The cortical pyramidal cells demonstrate mainly swelling with tigrolysis and nuclear shrinkage and darkening; the typical condition of ischemic change is not (yet?) developed. Most of the oligoglia are pyknotic, especially in the frontal and temporal cortex. Even the astroglia nuclei demonstrate some hyperchromatosis.

Softening is possible developing in these places. In the cerebellar cortex beginning neuronophagy, reaction of the macroglia is visible. Topography and scale of severity of lesions: Cortex, Ammon's horn, cerebellar cortex, thalamus, striatum, globus pallidus.

Comment to cases 7 and 8: The duration of hanging (4 - 5 min.) is known in case 7 only; the time of survival is 18 hrs. in both cases. 4 - 5 min. arrest of the cerebral circulation were sufficient to produce a disseminated selective neuronal necrosis. From the much higher intensity and the greater extension of the lesions in case 8 (necrosis of all nerve cells in certain cortical regions with transition to softening, involvement of striatum and globus pallidus), one may conclude that the occlusion of the cerebral vascular system had lasted considerably longer than 4 - 5 min. In both cases the time of manifestation (18 hrs.) was sufficient for the production of beginning microglia proliferation. A topistic pattern is demonstrable in a partly laminar distribution of the disseminated nerve cell necrosis (lamina III and V in the cortex, Purkinje cell layer) and the sparing of the stratum granulosum of the Ammon's horn.

9.) Hem., F.A. 279/58, male, 22 years.

Congenital feeble-mindedness. Attempted suicide by hanging. Duration of hanging unknown. Was unconscious with decerebrated rigidity on admission to the hospital. No pupillar reaction, spastic reflexes, tongue bite. Regular respiratory activity. Decrease of muscular rigidity, remained unconscious. Death 35 hrs. after hanging.

Autopsy: Bronchopneumonia, general venous engorgement. Brain weight 1340 g. Pressure conus of the cerebellar tonsils; impression marks at the uncus. Sclerosis of the left Ammon's horn.

Histology: Both Ammon's horns demonstrate old scarred lesions in the field h_1 (Sommer's sector) as in epilepsy. Within the whole cerebral cortex intensive selective neuronal necrosis, in some places most of the cortical population is involved with ischemic nerve cell necrosis, in other regions a disseminated laminar loss (lamina III and V) is visible. On both sides the Ammon's horn is concerned with most of its remained neurons except the granular layer, likewise large areas of the thalamus and parts of the Purkinje cell layer. The striatum participates with single necrotic nerve cells. Much fully developed

neuronophagy is found in the cortex, (Fig. 17) the Ammon's horn and thalamus, single ones in the nigra substance. In some cortical regions are pyknotic changes of the oligoglia; the astrocytes show slight progressive change of their nuclei.

Topography and scale of severity of lesions: Cerebral cortex, Ammon's horn, thalamus, cerebellar cortex, striatum, nigra substance.

10.) Rau., F.A. 278/58, male, 28 years.

Attempted suicide by hanging during a period of depression. Duration of hanging unknown. Was transferred to the hospital unconscious, with Cheyne-Stokes breathing, cyanosis, regular pulse. Muscular rigidity in all limbs, spastic reflexes. By improvement of respiration and circulation decrease of muscular rigidity. Remained unconscious. Death 46 hrs. after hanging.

Autopsy: Bronchopneumonia, dilatation of the right heart, edema of the lungs. Brain weight 1360 g. Venous engorgement. Symptoms of slight intracranial pressure (cerebellar pressure conus).

Histology: Throughout the whole cerebral cortex is relatively mild disseminated selective neuronal necrosis with ischemic nerve cells (Fig. 18). Within the Ammon's horn of both sides nearly all nerve cells are involved, except the granular layer; the most intensive changes of this kind are found in the thalamus where most of the population of the nuclei are affected. The striatum demonstrates a great number of ischemic nerve cells, and the Purkinje cell layer also. The globus pallidus participates with part of its nerve cells. Fully developed neuronophagy is visible within the Ammon's horn (Fig. 19). Some glial shrubs are seen in the cerebellar cortex.

Topography and scale of severity of lesions: Thalamus, Ammon's horn, cerebral cortex, striatum, cerebellar cortex, globus pallidus.

Comment to cases 9 and 10: These cases differ from cases 7 and 8 by the greater length of time for the development of morphologic changes. It cannot be decided whether this is of significance in the production of the typical picture of the ischemic form of nerve cell necrosis since the time and completeness of occlusion of the cerebral vascular system are unfortunately not known in the cases 8 - 10. At all events the influence of time for the manifestation is shown by the glial reaction which is much more developed in

cases 9 and 10. But in spite of the greater length of time (46 hrs.) after hanging in case 10 the glial reaction is rather less developed than in case 9 (35 hrs.). This fact may point to a transient paralysis of the glia with the effective ischemia. In regard to the quality of the changes, both cases demonstrate similar conditions but a difference in the intensity and the location of the most severe lesions. A topistic pattern appears in the preference for lamina III and V of the cerebral cortex, in the Purkinje cell layer of the cerebellar cortex and the resistance of the stratum granulosum of the Ammon's horn.

11.) Krö., F.A.131/33, male, 36 years.

Attempted suicide by hanging, duration of hanging about 15 min. Was found unconscious with respiratory arrest and severe cyanosis. Remained unconscious with general muscular rigidity for about 36 hrs., was then delirious and restless. One epileptic fit occurred. Cerebrospinal fluid without special changes. No spastic reflexes, apparently motor aphasia. Death about 64 hrs. after hanging.

Autopsy: Venous engorgement of the brain and the organs. Brain swelling.

Histology: Generalized tigrolysis with foamy plasma transformation without pronounced nuclear changes in nearly all cortical nerve cells; relatively few characteristic ischemic forms, decreasing in number from the frontal to the occipital region. In contrast to the cortex, the whole population of extended areas of the thalamus (Fig. 20), the whole area h_3 and a few cells of the Sommer's sector of the Ammon's horn, demonstrate symmetrically the ischemic type of nerve cell necrosis; the Purkinje cells are concerned with disseminated necrosis. Striatum and globus pallidus show no convincing pathologic changes. Distinct edematous demyelination of the white matter of the uncus. All types of glial cells are proliferated mainly by neuronophagic reactions in h_3 and glial shrubs in the cerebellar molecular layer. Astrocytes have enlarged nuclei and plasm in the Bergmann layer of the cerebellar cortex also.

Topography and scale of severity of lesions: Ammon's horn, thalamus, cerebral and cerebellar cortex. No convincing changes in the striatum, globus pallidus, or down to the medulla oblongata.

12.) Lei., F.A. 245/41, female, 40 years.

Attempted suicide by hanging during a depressive psychosis; duration of hanging unknown. Appeared to be dead; resuscitation successful, but remained unconscious till death 3 days later.

Autopsy: Bronchopneumonia. Brain weight 1420 g, no macroscopic changes.

Histology: Pronounced laminar pallor (lamina III, III and V), sometimes extending over all layers (Fig. 21), is produced mainly from selective neuronal necrosis of the ischemic type with eosinophilia and is nearly equally distributed from the frontal to the occipital cerebral cortex. Both Ammon's horns are relatively slightly affected (h_1 and h_3). The thalamus has extended regions where the whole nerve cell population shows ischemic necrosis. The Purkinje cell layer participates almost completely in this process, whereas the granular layer appears intact. Within the striatum only a few small nerve cells are involved. Intensive interstitial reaction is met in all areas concerned. There is much neuronophagy and a diffuse micro- and macroglia proliferation in the Ammon's horn, thalamus, cerebral and cerebellar cortex (Fig. 22). A beginning proliferation of mesenchymal cells of the vessel walls seems only in a few areas of the occipital cortex. An edematous loosening of the tissue and pyknosis of the oligoglia are also present.

Topography and scale of severity of lesions: Cerebral cortex, thalamus, cerebellar cortex, Ammon's horn, striatum.

Comment to cases 11 and 12: Both of these cases differ in the intensity and extension of the lesions and their principal locations, but scarcely in the progression of the reaction. The type of the lesions corresponds to those of the above described 4 cases. On the whole, the brain of case 12 demonstrates a greater intensity of the lesions, surpassing a purely selective neuronal necrosis by transition to softening in some areas of the occipital cortex; furthermore the lesions are much more extended especially within the cerebral and cerebellar cortex, whereas vice versa the Ammon's horn is less concerned. The generalized swelling of the cortical pyramidal cells in case 11 can after a time for manifestation of 64 hrs. scarcely imply an expression of cell necrosis.

13.) Fed., F.A. 188/57, male, 63 years.

Attempted suicide by hanging during a depressive reaction. Duration

of hanging unknown; was found unconscious, transferred to the hospital. During the following days delirious, restless; some intervals of relative lucidity; became comatous and died 7 days after the strangulation.

Autopsy: Brain weight 1480 g. Moderate pressure conus of the cerebellar tonsils and impressions of the uncus. Several older arteriosclerotic cystic softenings in the basal ganglia and the neighboring centrum semiovale.

Histology: Moderate arteriosclerosis of the basal arteries, hyalinosis of intracerebral vessels, many of the small pial vessels show arteriosclerotic changes. The above mentioned cystic softenings are partly organized by collagenous mesenchymal tissue; small cortical old softenings of a rather great number are mostly covered by glial tissue. Only a few ischemic cells in the Ammon's horn, the cortex, and a few more in the lateral nuclei of the thalamus with scanty rod cell reaction and some neuronophagy can be reliably related to the cessation of the cerebral circulation by strangulation. No remarkable reaction of the astroglia. The remains of necrotic nerve cells within neuronophagic reactions have completely disappeared. Within the cortex and the white matter are multiple spots of loosening of the tissue by perivascular edema.

Topography and scale of severity of lesions: Thalamus, Ammon's horn, cerebral cortex.

Comment: The time of hanging and the completeness of the occlusion of the cerebral vessels were probably not sufficient to produce more severe lesions. The deleterious course may be related to a secondary edema favoured by the arteriosclerosis of the cerebral arterial system and its considerable consequences to the brain. The insignificance of the lesions has provoked only a modest reaction of the microglia and almost none in the astroglia cells.

14.) Bre., Hamburg 85a/50, 13 months ¹⁾.

Was found unconscious with respiratory arrest after strangulation with a bedgirdle. Remained unconscious after return of respiratory activity;

1) This case is reported and illustrated by H. Jacob, Handb.d.spez. path.Anat. Vol. XIII/1 B, p. 1719. Springer, Berlin, 1957. By kindness of Dr. Jacob we had the opportunity to investigate brain material and histologic slides.

had numerous convulsive twitches of the face and upper limbs. General muscular flaccidity. Death 8 days after strangulation .

Autopsy: of the brain: Swelling, general venous engorgement.

Histology: The brain changes are dominated by softenings which are most extended in the white matter of the cerebrum and the cerebellum; the grey substances participate in all parts of the cerebral cortex, in the Ammon's horn, mainly in field h_1 and h_2 , in the striatum, globus pallidus and nearly the whole cerebellar cortex, including the granular layer. In all these places is found a pronounced mesenchymal proliferation with gitter cells, containing fatty substances. In the bordering zones is proliferation of astrocytes with voluminous cell plasm. Beneath these softenings a selective neuronal necrosis can be observed in extended cortical regions and in many places of the thalamus but almost without interstitial reaction except for some neuronophagy in the dentate nucleus. A pronounced patchy edema (sometimes as linear demarkation zones of necroses) is found in the cerebral cortex.

Topography and scale of severity of lesions: Cerebral and cerebellar white matter, cerebellar cortex, cerebral cortex, Ammon's horn, striatum, globus pallidus, thalamus, dentate nucleus.

Comment: This case differs principally from the cases 7 - 13 by the severe lesions of the white matter. Because of the significant edema in the cerebral cortex and in the white matter, the supposition may be justified that we deal here with an additional effect of ischemia, the effect of a consecutive edema. With this presumption, the case fits into the series of the cases previously described. It is only remarkable because of the intensity and the local multiplicity of lesions. The severity of lesions may even point to an accompanying heart arrest of longer duration. It is hardly possible to explain the differences in the stages of interstitial reactions in many places by clinical facts as far as they are known.

II. Oxygen Deficiency Produced by Hypoxemia.

a) Respiratory Arrest and Related Conditions.

1 Asphyxia at Birth.

15.) Mol., F.A. 216/39, male, 13 months.

Asphyxia following precipitate labor; transferred to the pediatric

hospital on the 3rd day with restlessness, numbness, slight opisthotonus, muscular rigidity, still increasing during the first weeks. No mimic motility. Was several times in hospital. Developmental retardation. At the age of 13 months the child succumbed to pneumonia with measles.

Autopsy: Dilatation of the right heart. Hyperemia and swelling of the brain. Sclerosis of the Ammon's horn on both sides.

Histology: Highgrade holotopistic diminution of the nerve cell population, demyelination and intense fibrous gliosis of the globus pallidus are found in both hemispheres. The same conditions are met in the corpus Luysi, their lateral two thirds are especially involved (Fig. 23). Both Ammon's horns have lost nearly all nerve cells and myelin fibers, including the granular layer; a dense consecutive gliosis has developed. In the striatum only some loosely distributed fibrous astrocytes are visible. Periventricular zone of demyelination of the third ventricle. No changes are seen in the cerebral and cerebellar cortex, the thalamus, dentate nucleus, the midbrain and the medulla oblongata. Slight gliosis of the cerebral and cerebellar white matter and the optic tracts.

Topography and scale of severity of lesions: Globus pallidus, corpus Luysi, Ammon's horn, and - far apart - striatum.

16.) Wes., F.A. 10/43, female, 12 years.

Premature birth (7 1/2 months), followed by repeated cyanosis.

Application of oxygen. Development of general athetosis and mobile spasms; muscular rigidity. Spastic gait, could produce unarticulated sounds only, made herself understood by gestures. Died with bronchopneumonia at the age of 12 years.

Autopsy: No significant changes of the brain.

Histology: Marked symmetrical diminution of the nerve cell population. Demyelination and holotopistic isomorphic gliosis are demonstrated in the globus pallidus and corpus Luysi, most intensely in its dorsal and lateral regions (Fig. 24). Both Ammon's horns are involved with diffuse loss of nerve cells in the field h_3 and the stratum granulosum with many fibrous astrocytes. Whereas a mild patchy fibrous gliosis with a slight loss of nerve cells is observed in the thalamus and the nigra substance, only some loosely distributed fibrous astro-

cytes are seen in the striatum. A rather dense fibrous gliosis with many astrocytes, but without conspicuous changes in the nervous structures is present in the cerebral and cerebellar white matter, the optic tracts, the pes of the pons, the inferior olives and their hili, and less in the dentate nucleus; also most intensive subependymal gliosis. No convincing changes are in the cerebral and cerebellar cortex.

Topography and scale of severity of lesions: Globus pallidus, corpus Luysi, Ammon's horns, thalamus, nigra substance. (Gliosis only: inferior olives, pons, medulla oblongata, white matter including subependymal layer, optic tracts, striatum).

17.) Stro., F.A. 312/50, female, 37 years.

Delivery within the amnion, the opening of which was practiced ostensibly 2 1/2 hrs. later. Asphyxia of longer duration. 3 days after the birth, the child was completely motionless for some hours. Development of general athetosis with muscular rigidity, still increasing in the age of ten years, feeble-mindedness. Finally no longer able to walk, bizarre contracted bodily attitude. Had at no time convulsions. Died from general weakness at the age of 37 years.

Autopsy of the brain: Questionable atrophy of the frontal cortex, sclerosis of both Ammon's horns. No hydrocephalus.

Histology: Considerably diffuse loss of nerve cells, symmetrical holotopistic demyelination and isomorphic gliosis in the globus pallidus is present in both hemispheres and in the corpora Luysi, especially in their lateral parts (Figs. 25, 26). The nerve cells of the field h_1 and in one side of the field h_2 also have disappeared. Consecutive fibrous gliosis. Except for some perivascular gliosis and a few loosely distributed fibrous astrocytes, the striatum demonstrates no pathologic changes; no status marmoratus. Questionable diminution of the thalamic nerve cells; no convincing glial reactions. Many fibrous astrocytes within the inferior olives, but no diminution of the nerve cell population. Slight diffuse gliosis in the medulla oblongata. Pathological fibrous astrocytes are found in the cerebral and cerebellar white matter. Considerable subependymal gliosis and gliosis of the optic tracts. No convincing diminution of the nerve cell population of the cerebral and cerebellar cortex, no gliosis.

No demonstrably progressive process.

Topography and scale of severity of lesions: Globus pallidus, corpora Luysi, Ammon's horn (gliosis of the inferior olives, subependymal layer, optic tracts, white matter, medulla oblongata).

18.) Kel., F.A. 40/55, female, 66 years.

Since early childhood general chorea, athetosis with highgrade feeble-mindedness after a supposed meningitis; did not learn to speak. Lived always with her family as a stationary case of Little's disease until she was transferred to an insane hospital at the age of 64 years.

Athetosis and choreatic movements involved the muscles of the neck and the tongue especially. Was not able to speak, often choked while eating. Euphoric dementia. Died from general marasmus.

Autopsy: Highgrade atrophy of all organs. Mitral stenosis. Pneumonia. Brain weight 1085 g. The formalin fixed brain appears generally small without localized atrophy and with only a slight enlargement of the ventricles. Meninges not thickened, slight atheromatosis of the basal arteries.

Histology: Slight and not extended status marmoratus of the striatum and the thalamus, with corresponding patchy nerve cell loss and very slight gliosis. The number of nerve cells and myelin fibers of the globus pallidus and the corpus Luysi are greatly reduced; a consecutive isomorphic and holotopistic fibrous gliosis, poor in nuclei, is present (Fig. 27). Nearly all nerve cells of the Ammon's horns, including the stratum granulosum in both hemispheres are gone. Slight proliferation of fibrous astrocytes in the cerebral and cerebellar white matter. The cerebral and the cerebellar cortex, the dentate nucleus, nigra substance and inferior olives do not demonstrate convincing pathologic changes.

Topography and scale of severity of lesions: Globus pallidus, corpus Luysi, Ammon's horn, striatum, thalamus.

Comment to cases 15 - 18: In the cases 15 - 17 a reliable history states severe asphyxia at birth. From the conformity of the quality of the lesions (resulting of scarring after selective neuronal necrosis) and their location one may conclude that case 18 is also caused by an asphyxia at birth; all more so as there are no remains of a meningitis or of any other process which could explain the

lesions. The remarkable fact in the cases of oxygen deficiency to the brain of proven hypoxemia is the striking differences in the location of the lesions, mainly found in the basal ganglia with exception of the cerebral and cerebellar cortex, as compared to the findings in ischemic anoxia. There is a special pattern throughout all 4 cases: this is the holotopistic lesion of the globus pallidus and of the corpus Luysi. Frequently we find also a change in the extension of the lesions to the Ammon's horn in that as the stratum granulosum is severely damaged.

2 Acute and Chronic Dyspnea, Respiratory Arrest.

19.) Gro., Hamburg 7a/54, male, 9 months.

The child was transferred to the hospital because of sudden severe dyspnea in the course of a stomatitis. Diagnosis of the hospital: acute descending tracheobronchitis with latent spasmophilia. Repeated severe attacks of dyspnea with extreme cyanosis, tachycardia, emphysema of the skin and the lungs made a tracheotomy necessary. The child succumbed with high fever from respiratory paralysis at the 7th day.

Autopsy: Purulent tracheobronchitis, extended bronchopneumonia, moderate dilatation of the right heart.

Histology: All parts of the brain demonstrate a pronounced venous engorgement and a delicate loosening of the cortical tissue by edema.

Thereupon the cortical myelinated fibers show tortuosities and symptoms of dissolution. The cortical nerve cells have generally certain changes of their plasm but their nuclei are well preserved; thus it is not likely that the changes are an expression of cell necrosis as a direct effect of oxygen deficiency. Only a few single cortical pyramidal cells and a few in the fields h_1 and h_3 of the Ammon's horn demonstrate a distinct ischemic necrosis with eosinophilia and destruction of the nuclear structure (Fig. 28). Nowhere is there interstitial reaction. No pathologic changes within the cerebellum, striatum, thalamus, and nigra substance (midbrain and medulla oblongata were not available).

Topography and scale of severity of lesions: Ammon's horn, cerebral cortex.

20.) Mich., F.A. 234/37, female, 31 years.

Received an injection of Per-Abrodil BAYER, a contrast medium for X-rays, because of supposed pyelonephritis. The injection was followed by some eclamptic fits and respiratory arrest. Artificial respiration for 19 hrs., than cardiac arrest.

Autopsy: The brain demonstrated no gross changes.

Histology: Generalized venous engorgement, some subarachnoidal hemorrhages, diffusely propagated serofibrinous exudate around the intracerebral vessels. Most of the nerve cells of the cerebral cortex, including the Ammon's horn, show a dissolution of the plasm with shrinkage, or swelling and pyknosis of their nuclei, often pericellular incrustation. A large part of the glial nuclei are pyknotic. Typical ischemic necrosis with eosinophilia and characteristic nuclear changes are not encountered. Reactions are not observed. In contrast to the poor state of the cortical pyramidal cells which concerns mainly those of layer IIIa, the nerve cells of the striatum, the globus pallidus, the dentate nucleus, the nigra substance, the inferior olives and the cerebellum have a normal appearance.

Topography and scale of severity of lesions: Cerebral cortex, Ammon's horn.

Comment to cases 19 and 20: In case 19 the repeated attacks of severe dyspnea have apparently produced a necrosis of single nerve cells in different parts of the brain only. The pronounced difference in the state of the nerve cells in the cerebral cortex from those in other parts of the brain in case 20 does not allow them to be considered as post mortem changes. Since we deal with any one of the forms of necrosis it is absolutely uncertain whether this can be related to the respiratory arrest of 19 hrs. duration. Another cause seems to be more likely. The intravenous injection of Per-Abrodil was immediately followed by a cerebral reaction namely eclamptic fits and respiratory arrest - possibly the cerebral effect of some kind of embolism which would better explain the severity of the cortical lesions. By the complete absence of ischemic infarctions and the more or less diffuse distribution of the cortical nerve cells it is likely that the emboli are very small and numerous as in an embolism.

21.) Bro. I, Hamburg 77a/51, male, 2 months.

Made almost no movements with the limbs since birth. 3 weeks later

extreme abdominal respiration. Was transferred to the hospital with severe bronchopneumonia. Diagnosis: myatonia congenita. Besides a paralysis of the legs and arms a progressive paralysis of the intercostal muscles with phrenoplegia had developed.

Autopsy and histology of the spinal cord (Dr. H. Jacob): Typical changes of myatonia congenita.

Histology: See case 22.

22.) Bro. II, Hamburg 80a/51, male, 3 months.

(A younger brother of case 21). Was transferred to the hospital because of difficulties in sucking. Diagnosis: myatonia congenita. Paralysis of all limbs, the muscles of the abdominal wall and the intercostal muscles. Died from an infection which developed into bronchopneumonia.

Autopsy: Confirmed the clinical diagnosis myatonia congenita. Investigation of the brains of the cases 21 and 22 with regard to anoxic changes, produced by respiratory difficulties: The sclerotic changes in the anterior horns of the spinal cord (H. Jacob), a considerable increase of the fibrous glia within the medulla oblongata (hilus of the inferior olives, sensory decussation) and the pes of the pons without conspicuous loss of nerve fibers as well as the axonal reaction of a number of nerve cells in these places (including nucleus XII) may be related to the process of myatonia. Neither brain demonstrate any lesion which can be referred to the chronic oxygen deficiency produced by the prolonged difficulties of complete breathing.

b) Atmospheric Hypoxidosis.

23. Lind., F.A. 166/41, male, 28 years.

Lost the connection to the oxygen mask during an air raid over London 7500 m high; was observed lying in the bottom of the machine by the crew and found dead on landing.

Autopsy: Considerable engorgement of the intestines with hemorrhages in pancreas, stomach, ileum, and mesentery; marginal emphysema of the lungs, cyanosis of the face; no clotting of the blood in heart and vessels. In contrast to the engorgement of the organs, the brain appears anemic.

Histology: Some nerve cells of the striatum and the thalamus are slightly shrunken, stain slightly eosinophilic and very dark with basic aniline dyes; their nuclei show also shrinkage. A characteristic picture of necrosis, however, is nowhere developed.

24.) Sun., F.A. 332/56, male, 59 years.

Was 1940 member of a crew of a military airplane, when the oxygen supply became defective. Some of the crew died, patient was unconscious for a long time and was trepanned. Since thus he suffered from headache and had repeated epileptic fits. He lost occasionally the ability to speak or had difficulty in finding words. Suffered certain changes in his personality. Since 1947 chronic cholecystitis. Died 1956 from acute peritonitis after cholecystectomy.

Autopsy: Two trepanation holes of 1 cm in diameter, symmetrically situated in the frontoparietal region of the skull; hemosiderosis of the meninges at the left trepanation hole. Small peptic ulcer. Cholecystectomy. Old fracture by compression of the 11th thoracic vertebra. Free bile within the abdomen, peritonitis. Generalized moderate atherosclerosis. The walls of the cerebral vessels appear somewhat thickened, but without atheromas. Nowhere softenings. Frontal sections through the formalin fixed brain reveal no pathologic changes.

Histology: No definite pathological changes can be observed within the cerebral and cerebellar cortex, the Ammon's horn or the dentate nucleus. The striatum presents rather numerous fibrous astrocytes (Fig. 30) but no conspicuous loss of nerve cells. In the medial part of the globus pallidus are media calcification of larger vessels and rather numerous pericapillary and free calcified bodies; some of the latter may derive from necrotic neuronal structures. There is an insignificant reduction of the nerve cell population but a considerable increase of fibrous astrocytes (Fig. 31). The upper medial part of the globus pallidus is occupied by a small patch of demyelination (Fig. 29) and dense fibrous gliosis in local incidence to the calcium deposition. The thalamus is also involved with a slight rarefying of the nerve cell population and a reactive fibrous gliosis in its ventral nucleus. The corpus Luysi appears somewhat poor in nerve cells. A rather dense fibrous gliosis of the inferior olives and their hili is not combined with a convincing loss of nerve structures (Fig. 32).

The white matter participates with a slight increase of fibrous glial cells.

Topography and scale of severity of lesions: Thalamus, globus pallidus, corpus Luysi, striatum and inferior olives with gliosis only.

Comment to cases 23 and 24: From the morphologic view the time for manifestation of characteristic structural changes was supposedly too short in case 23. The pathogenetic conditions in case 24 may appear somewhat complicated. There are no arteriosclerotic changes of the intracerebral vessels and nowhere softenings. Comparing the character and the localization of the lesions with those of asphyxia at birth, their restriction to the basal ganglia is remarkable. As the slight neuronal loss and the gliosis surpass the region of vascular calcification by far, it may be permitted to suppose that the slight old changes in the thalamus, globus pallidus, striatum, corpus Luysi and the olives may be due to the atmospheric hypoxia at flight. It may also be considered that the slightly disseminated loss of nerve cells is so inconspicuous that it can be suggested only because of a reactive fibrous gliosis (see case 28).

c) Anemic Conditions.

1 Morbus Hemolyticus Neonatorum (Survived Kernicterus).

25.) Mit., F.A. 76/43, male, 3 1/2 weeks ¹⁾.

The infant developed jaundice with rapidly progressing anemia from the first day after birth. Increasing opisthotonus and generalized muscular rigidity which persisted till he died from pneumonia at the age of 3 1/2 weeks. Diagnosis: Icterus gravis.

Autopsy: The brain weighed 450 g and demonstrated the usual appearance at this age; no icteric discoloration of the nuclei, as found in kernicterus.

Histology: Symmetrical and nearly total loss of nerve cells and still progressive decay of myelin fibers occur in the globus pallidus and the corpus Luysi with extensive glial reactions (Fig. 33), consisting of rod cells, macrophages and increased astrocytic nuclei. Only moderate transformation to fatty products. Diffuse loss of nerve cells with

1) The cases 25 and 26 are published by Meriwether, Hager and Scholz: Archives of Neurol. & Psychiat. 73, 293-301, 1955

the same reaction of the glia is found in all fields of the Ammon's horn and the dentate nucleus, also single neuronophagy within the thalamus and the striatum. The medulla oblongata reveals a diffuse gliosis in its ventral part without demonstrable loss of nervous structures. Cerebral and cerebellar cortex appear normal, in the white matter a gliosis with many fibrous astrocytes is developing. Topography and scale of severity of lesions: Globus pallidus, corpus Luysi, Ammon's horn, dentate nucleus, striatum, thalamus.

26.) Roe., F.A. 49/43, male, 5 1/2 months.

The infant developed extreme jaundice with erythroblastosis and anemia within the first days after birth, followed by progressive muscular rigidity which persisted until the death at the age of 5 1/2 months.

Autopsy: Brain weight 510 g. Sclerosis of the Ammon's horn in both hemispheres.

Histology: Symmetrical and almost total loss of nerve cells with distinct demyelination are found in the globus pallidus and the corpus Luysi, with resulting consecutive intense holotopistic fibrous gliosis (Fig. 34). Nearly complete loss of nerve cells and intense fibrous gliosis occur in both Ammon's horns with only a small part of the field h_2 remaining. Likewise in the dentate nucleus is a considerable diminution of nerve cell population, with demyelination and consecutive fibrous gliosis (Fig. 35). A moderate status marmoratus has developed in the putamen and the thalamus demonstrates a partial nerve cell loss with consecutive fibrous gliosis in its ventrolateral and medial parts (Fig. 34). Besides these convincing destructions of nervous structures is an intense subependymal gliosis; gliosis of the optic tracts, of the ventral part of the medulla oblongata and of the cerebral and cerebellar white matter without conspicuous changes of neuronal structures is present. Cerebral and cerebellar cortex reveal no pathological status changes.

Topography and scale of severity of lesions: Globus pallidus and corpus Luysi (holotopistic), Ammon's horns, dentate nucleus, striatum, thalamus (subependymal layer, optic tracts, medulla oblongata, cerebral and cerebellar white matter with gliosis only).

27.) Büt., F.A. 189/58, male, 10 1/2 months.

7 days after birth the child was admitted at a pediatric clinic. He suffered from icterus gravis with erythroblastosis, 3% normoblasts, 16,4% bilirubin in the serum. Blood group A₁ Rh pos. (mother A₁ Rh neg.). In spite of blood exchange and two transfusions before disappearance of the jaundice, omprosthonus and increasing general muscular rigidity developed. As a case of Little's disease the child was transferred to an asylum and died there from pneumonia at the age of 10 1/2 months.

Autopsy: Besides a slight hydrocephalus internus the 710 g brain demonstrates no pathological findings.

Histology: In the lateral parts of the globus pallidus the nerve cell population is reduced to about 25%, the medial parts have practically lost all nerve cells. Demyelination and holotopistic fibrous gliosis is also found (Fig. 36). The corpora Luysi are similarly changed. In spite of the age of these changes, numerous products of dissolution - partly stainable with sudan and double refracting, nearly all stainable with hematoxylin - are seen everywhere equally distributed in the confines of these nuclei (Fig. 37). A tendency to accumulation around the vessels is not visible. The Ammon's horns are almost emptied of nerve cells and filled with fibrous glia. They present the same fatty dissolution products as the above mentioned nuclei (Fig. 38). The dentate nucleus has lost many nerve cells, especially in its dorsal part, and shows a slight loss of myelin fibers in the vlies and hilus; a corresponding gliosis is present. The thalamus exhibits small regions with a moderate loss of nerve cells and gliosis; in the striatum is a moderate perivascular gliosis only. Cerebral and cerebellar cortex, nigra substance reveal no pathological changes. There is a rather intensive diffuse fibrous gliosis in the medulla oblongata, especially in the subependymal layer, hilus and vlies of the inferior olives and the pyramidal tracts; no corresponding loss of nerve structures is present (Fig. 39, 40). In the cerebral white matter is only slight gliosis; here the myelin stain is not very dark, but there are no fatty products. Only few cortical radiated fibers are developed; in many places are the U-fibers not yet developed.

Topography and scale of severity of lesions: Globus pallidus, corpus Luysi, dentate nucleus, thalamus.

28.) Pet., F.A. 175/54, female, 8 years ¹⁾.

The child was born without complications after a normal pregnancy. After birth jaundice for 3 weeks. 4 months later involuntary athetoid movements of the limbs were observed which ceased during sleep. At the age of 9 months this state improved in so far as the movements discontinued from time to time. Athetosis increased with voluntary movements. Ostensibly no severe psychic changes, but the child did not learn to speak understandably. The child was transferred to the neurological hospital at the age of 8 years: the legs are crossed, hands and fingers in flexion, spasmus mobilis, muscular rigidity. The child was able to read and to do simple reckoning. Diagnosis: Encephalopathia posticterica infantum. The girl died 12 hrs. after a bulbotomy.

Autopsy: The formalin fixed brain weighed 950 g. Besides a fresh hemorrhagic incision of the medulla oblongata at the level of the left inferior olives, no pathologic findings.

Histology: One has the impression of a symmetrically diffuse thinning of the nerve cell population of the globus pallidus; especially the medial part appears nearly empty in some sections. This impression is supported by a conspicuous increase of glial nuclei and a rather poor stainability of the myelin structures. The condition of the material did not allow staining of glial fibers. However, there are found in the globus pallidus a rather large number of small calcified bodies, mostly of longish shape, but not connected with vessels (Fig. 41). As some calcified nerve cells can also be demonstrated, it can be taken for granted that the calcified bodies are derived from necrotic neuronal structures. The lateral third of the corpus Luysi shows diminution of nerve cells, but there are neither gliosis nor calcified particles. Otherwise no older pathologic changes can be observed in the brain which can be referred to the icterus gravis; cerebral and cerebellar cortex, Ammon's horn, striatum and thalamus show normal conditions.

Topography: Globus pallidus (and corpus Luysi?) of both hemispheres (holotopistic?).

Comment to cases 25 - 28: In 3 of these 4 cases a severe progressive anemia accompanied by icterus gravis was present in the first days of life. As reported, case 28 did not demonstrate definite neurologic

1) By courtesy of Professor Pentschew - Sofia

symptoms before the 4th month of life. All 4 cases present the same neuropathologic condition in so far as cerebral and cerebellar cortex do not participate in changes which can be referred to pathogenic conditions during the icterus gravis. All 4 cases are identical in regard to the holotopistic lesions of the globus pallidus and probably also of the corpus Luysi; in this respect only a variation in the intensity can be observed. The intensity may vary over a wide range as demonstrated in case 28 in which only the calcified remains of neuronal structures make the destruction of one part of the population absolutely certain. Thus these cases can be compared with cases 15 - 18 of birth asphyxia. Like these cases each of them differ from the others in regard to the injury in other nuclei and regions. In the cases of "encephalopathia posticterica infantum" the Ammon's horn seems to participate most frequently with severe lesions sparing often small parts of field h_2 only. The next most frequent lesions are of thalamus, striatum and dentate nucleus. All these lesions are symmetrically arranged in both hemispheres. Whereas the areas of dentate nucleus and Ammon's horn have a more or less topistic character, the changes in the thalamus and the striatum have focal appearance, pointing to a local circulatory disorder. As to the pathogenesis of the whole complex of lesions: not only the similarity to the changes from asphyxia permits the supposition that hypoxemia plays the decisive role. As we have learned from our own experience in acute cases of kernicterus and from the literature, bilirubin is resorbed by living glia cells but penetrates also into dead nerve cells which frequently demonstrate the characteristic feature of ischemic necrosis. The typical condition of selective neuronal necrosis in acute kernicterus parallels the selective neuronal loss in surviving cases of morbus hemolyticus with the clinical appearance of a Little syndrome.

2 Chronic Anemic Conditions.

29.) Müh., Hamburg 48a/53, female, 6 1/2 years.

The newborn infant suffered from severe dystrophy for more than one year; at the age of 13 months, the physical development was that of a 1 - 2 months old suckling. When she was transferred to the hospi-

tal at the age of 2 years, the retarded development of the extremely pale girl was related to a questionable premature birth. The investigation of the blood revealed 15% hemoglobin. The further development was very slow; the child learned to sit, took interest in her environment, but did not systematically play. She was permanently kept in bed and developed only a rudimentary speech. Otherwise no neurological symptoms. Except for a deviation of leucocytes and erythrocytes to the left, the sternal puncture did not reveal abnormalities. Fe and bilirubin in the serum were normal, likewise the bleeding time and the coagulation time. The cause of the anemia which persisted to the same degree throughout the whole life time could not be sufficiently explained. The child died suddenly and unexpectedly from an acute cardiac crisis at the age of 6 1/2 years.

Autopsy: Spotting of the muscle of the left heart with considerable dilatation of the ventricle. Patchy fatty degeneration of the liver, venous engorgement of the spleen, edema of the lungs. The brain presents some dysgenetic accessory shallow sulci on the convexity of the frontal and occipital lobes; otherwise no abnormalities.

Histology: The cortex is folded by the accessory sulci but demonstrates regular architectonic conditions. There is in general a marked periventricular gliosis and a moderate fibrous gliosis of the cerebral and cerebellar white matter including the optic tracts, without a conspicuous demyelination. A moderate number of progressive fibrous astrocytes can be observed in the striatum and the globus pallidus, without convincing diminution of their nerve cell population or of their myelinated structures. The corpus Luysi is similarly affected. The thalamus participates with two small foci of nerve cell loss with fibrous gliosis. There are no definite changes of the cerebral and cerebellar cortex nor of the Ammon's horns.

Topography: Thalamus, white matter of the cerebral and cerebellar hemispheres, striatum, globus pallidus.

30.) Schleim., F.A. 84/48, female, 7 years.

The infant, born without complications, weighed 3000 g. Normal development until the girl went to school. Then she suffered from increasing weakness, pains at the elbows and knees and became

strikingly pale. At the age of 7 years she was transferred to the hospital with fever, cough, abdominal pain, squinting and vomiting of blood. The girl weighed 20 kg. She appeared deathly pale. The values of hemoglobin varied between 22 and 15%, the number of erythrocytes between 0,81 and 1,2 millions at different times, white blood corpuscles (about 90% lymphocytes) increasing from 5500 to 27000 and falling to 1000. Diagnosis: micromyeloblastic leukemia. The child died from a purulent infection.

Autopsy: Dilatation of the right heart, nearly total fatty degeneration of the liver. Brain weight 1070 g. The colour of the brain is white as marble. Diagnosis of the pathologist: subchronic panmyelophthisis with myeloblastic reactions, anoxic insufficiency of the organs.

Histology: Besides a very recent decay of myelin fibers within extended regions of the medial and lateral thalamus, but without any destruction of nerve cells or gliosis reaction (Fig. 44), there is a tendency to fibrous gliosis of all parts of the brain, except in the cerebral and cerebellar cortex. The gliosis is most pronounced at all inner and outer surfaces. The gyral parts of the cerebral and cerebellar white matter are most affected (Fig. 45), but without a remarkable destruction of myelinated fibers. Striatum and globus pallidus contain a rather large number of diffusely spread fibrous astrocytes, but a convincing loss of neuronal structures cannot be observed. Likewise the medulla oblongata demonstrates a rather dense fibrous gliosis without demyelination or nerve cell diminution. Hilus and vliies of the dentate nucleus and the optic tracts present the same condition. Different parts of the brain show some glial nodules, related to the final sepsis.

Topography: Locally different, but generalized fibrous gliosis with exception of the cerebral and cerebellar cortex and the Ammon's horn, without conspicuous loss of nerve structures; pronounced development of fibrous astrocytes in the whole territory of striatum and globus pallidus.

31.) Hub., F.A. 142/41, male, 71 years.

The clinical notes are lost during the war.

Autopsy: revealed the typical findings of pernicious anemia without

changes of the spinal cord. Generalized atheromatosis of the aorta, hemosiderosis of liver and spleen. No remarkable arteriosclerosis of the cerebral vessels.

Histology: In the white matter and in the internal capsule are a rather large number of shell bleedings of different age, a part of which shows circular microglial reaction, another part demyelination only. Symmetrically in both globi pallidi are several small areas of very recent tissue destruction without any reaction (Fig. 48); a progressive calcification of the vessels is also present. But there is no absolute correspondence between the calcification and the tissue necrosis. Obviously the pallidum lesions are sublethal anoxic lesions to which the calcification of the vessels may have contributed. The predominant feature of this case is a generalized increase of the fibrous glia, prevalent in that tissue which contains many myelinated structures, but perceptible also in the grey substances, even in the cerebellar cortex where there are single fibers. It is remarkable that the cerebral and the cerebellar white matter do not demonstrate any demyelination except for the fresh perivascular patches of myelolysis with interstitial reaction. Also the nerve cell population does not show a conspicuous loss, although the increase of fibrous astrocytes in the striatum approaches the condition of Huntington's chorea (Fig. 49). Possibly as a consequence of its higher content of myelinated tracts, the globus pallidus in its whole extent shows a rather high grade fibrous gliosis (Figs. 50, 51). Even in the third layer of the cerebral cortex and still more in the deeper layers, are pathologic fibrous astrocytes with processes which contain bundles of fibrils (Fig. 52). A pronounced gliosis without diminution of nerve cells is found in the inferior olives (Fig. 53) and the dentate nucleus; here are the myelinated structures especially concerned (compare Fig. 40). The same conditions of gliosis are visible in the thalamus and field h_3 of the Ammon's horn. A special preference in the topography of the lesions cannot be set up; but the intensification of the development of fibrous astrocytes in the whole territory of the striatum, in the globus pallidus, and even in the cortex, should be noticed.

Comment to cases 29 - 31: Apart from recent changes in case 30 (beginning encephalitis from general sepsis) and in case 31 (small foci of demyelination deriving from local disturbances of barrier function

as shell bleeding and sublethal anoxic foci in the globus pallidus), all three cases show a general trend of morphologic changes related to the chronic anemia. They consist of a diffuse proliferation of the fibrous glia without a convincing loss of nerve structures to explain the gliosis. Only the thalamus in case 29 presents a small glial focus with a distinct perivascular loss of nerve cells. The diffusely spread and perivascularly pronounced fibrous gliosis is most strikingly developed in the white matter and in the inner and outer surfaces of the brain, including the optic tracts. But also grey nuclei as the striatum, the globus pallidus, the thalamus and inferior olives participate in the gliosis with proliferative modifications of the fibrous astrocytes. In the striatum of cases 30 and 31 this proliferation is so marked that the glious condition resembles that in Huntington's chorea. The remarkable fact in all three cases is the inconspicuous loss of nerve structures (whenever present), in spite of the high degree of gliosis and the bilateral gliosis of the globus pallidus, visible to the naked eye in Holzer preparations (Figs. 42, 43, 45 - 47, 49 - 53).

d) Defective Arterialization of the Blood with Circulatory Insufficiency (Congenital Malformation of Heart).

32.) Her., F.A. 315/35, male, 18 years ¹⁾.

The patient was born in the 8th month of pregnancy as second of twins; he was delivered with blue face and snoring respirations. No acute asphyxia is mentioned. Considerably retarded bodily and mental development, breathing always snoring, general cyanosis, tendency to asthmatic attacks; walking and ordinary speaking not before the age of 6 years. At the age of 18 years the patient showed a bodily development of a 11 - 12 years old boy. For many years he lived in an asylum. As he was not skilful with his hands, he was unable to do any wicker work; his gait was faltering, often reeling, the limbs showed a slight athetoid restlessness with a slight muscular rigidity. Auscultation revealed a long loud systolic murmur over all ostia of the heart. Diagnosis: chronic cyanosis from vitium cordis. At the age of 18 years he acquired a septic infection and died within two days.

1) Published by W. Scholz, Z.Neur. 171, 426, 1941

Autopsy: Subacute endocarditis followed by pyemia and many abscesses in the organ. Malformation of the heart (Fallot's tetrad) with pulmonary stenosis, large defect in the septum of the atrium, open foramen ovale, hypertrophy of the right ventricle, closed ductus Botalli. Pronounced cyanosis of the limbs. The brain weighed 1070 g and presented a considerable engorgement of the blood vessels; otherwise no changes.

Histology: Besides the irregularly distributed miliary abscesses, related to the terminal pyemia, there are symmetrically arranged old changes in the basal ganglia of both hemispheres. They consist in an insignificant demyelination and a marked diffuse numerical diminution of the nerve cell in the region of the globus pallidus and the corpus luyysi, with a corresponding dense isomorphic fibrous gliosis (Figs. 54 - 56). Likewise the dentate nucleus in both cerebellar hemispheres is affected (Fig. 57). All these changes, which bear a holotopistic character, concern the whole territory of these nuclei and do not overstep their frontiers. The thalamus participates with patchy incomplete loss of nerve cells (some calcified ones are remaining) and a local increase of fibrous glia cells. A moderate development of fibrous astrocytes is observed also in the striatum, but without a convincing loss of nerve structures. Hilus and vliies of the inferior olives show a distinct demyelination, causing a dense local gliosis. For the rest, all inner and outer surfaces of the brain, including the optic tracts, demonstrate more or less thick layers of gliosis. The white matter of the cerebral and cerebellar hemispheres present a slight increase of fibrous glia without demyelination, whereas the cortices and both Ammon's horns do not present pathologic changes.

Topography and scale of severity of lesions: Globus pallidus, corpus luyysi, dentate nucleus, thalamus, hilus and vliies of the inferior olives with loss of nerve structures (cerebral surfaces, optic tracts, striatum, white matter with gliosis only).

33.) Ren., Hamburg 60a/53, male, 4 1/2 years.

The mother had normal pregnancy and delivery. During the first year of life, the child appeared healthy. With the first attempts to walk he developed cyanosis and increased dyspnea (a certain dyspnea had always been present). The infant became strikingly sparing of motion. At the age of 4 1/2 years, admission to the hospital because of

angina pneumonia and meningeal irritation. There were found an empyema of the pleura and loud systolic and diastolic murmurs. The child was deeply cyanotic and dyspnoic and had some convulsions. Gangrene of both legs developed; the boy died 10 days after admission. Blood count: erythrocytes 5,5; hemoglobin 110; leucocytes 18600. Cerebrospinal fluid: 40/3 lymphocytes.

Autopsy: Malformation of the heart (Fallot's tetrad), pulmonal stenosis, stenosis also of the pulmonal cornu, defect of the atrio-ventricular septum, considerable hypertrophy of the right heart, less of the left ventricle, transposition of the aorta to the right side. High degree of general circulatory engorgement. Thrombosis of both iliac arteries, chronic purulent meningitis, swelling and engorgement of the brain with a rather recent walnut size hemorrhagic softening in the right frontal lobe.

Histology: Enormous venous engorgement of the brain, partial thrombosis of the vertebral arteries. Some ventricular diverticles of the inferior horn in the region of the uncus (malformation?). In the same region are two old cysts, containing some vessels. A few rod cells are diffusely spread in the cerebral cortex, which does not show convincing nerve cell depopulation. Slight hypertrophy of the astrocytic nuclei and also generally distributed a slight increase of endothelial cells of the intracerebral capillaries. No definite changes in the globus pallidus and corpus Luysi. Slight but distinct increase of fibrous glia in the cerebral and cerebellar white matter.

34.) Berg., F.A. 139/47, female, 15 weeks.

The infant was born under normal conditions, weighed 5300 g. She was asthmatic when drinking and was transferred to the hospital because of intestinal disturbances at the age of 3 months. On admission the weight was 3800 g; tachycardia, slight cyanosis. A bronchopneumonia developed with increasing cyanosis, difficult breathing and several circulatory collapses. The child died 12 days after admission.

Autopsy: Bronchopneumonia. Congenital vitium cordis: persisting vena pulmonalis commun., abnormal flow into the vena anonyma sin.. Considerable dilatation of the right atrium. Hypertrophy of the right ventricle; foramen ovale half open. Fatty degeneration of heart muscle and liver. Swelling of the brain (535 g).

Histology: Some nerve cells of the cerebral cortex, of the basal ganglia and also a few Purkinje cells suggest necrosis. The subependymal layers of the ventricles, the cerebral and the cerebellar white matter, and the myelinated structures of the globus pallidus contain considerably more glial fibers than usually found at this age. No definite nerve cell loss and no demyelination of the cerebral and cerebellar cortex nor of the striatum, globus pallidus, corpus Luysi and the Ammon's horn.

35.) Schu., Hamburg 6a/53, female, 4 1/2 months.

The premature born infant weighed 2000 g and had slight cyanosis of the lips, feet and hands. Systolic murmur. Generalized cyanosis and findings at the heart remained constant, blood count and hemoglobin varying between 4,59 and 3,52 erythrocytes and 155 and 86 hemoglobin. Regular development to a weight of 2540 g at the age of 4 months; than increasing cyanosis, especially when drinking. Rapid deterioration with infectious pharyngitis. The child died from severe respiratory and circulatory disturbances.

Autopsy: Complete obliteration of the arterial ostium of the left ventricle of the heart; the aorta coming from the right ventricle. Aside from the aorta a pulmonary artery with a considerably thin wall is situated. Subaortal defect of the ventricular septum; nearly complete obliteration of the ductus Botalli.

Histology: (incomplete brain material) High degree of capillary ectasia and engorgement. Some nerve cells in the dentate nucleus and some Purkinje cells suggest recent necrosis; otherwise no conspicuous morphologic changes. No convincing numeric diminution of nerve structures, especially in the basal ganglia including globus pallidus. The glia fibers failed to stain.

Comment to cases 32 - 35: There is a fundamental contrast between the findings in case 32 and in those of the three cases that follow. Whereas case 32 in its morphologic findings can be compared with the cases of birth asphyxia and those of morbus hemolyticus, case 33 has (besides a malformation in the temporal lobe, which concerns the ventricular system) some fresh and older softenings which point to temporarily entering circulatory incidents, possibly to repeated embolism. The increased periventricular and perivascular gliosis,

found in case 34, might be referred to conditions as met in cases of chronic anemia. Acute nerve cell changes as in case 33 - 35 which are suspected of necrosis, are obviously due to final decompensation of the unstable circulatory condition. Only case 32 presents definite lesions pointing to a direct effect of a hypoxemia which occurred long ago. All cases were apparently adapted. In case 32 it may be considered whether a moderate birth asphyxia, under ordinary conditions remaining below threshold, combined with the defective arterialization of the blood, resulting from the malformation of heart will have caused a dangerous degree of hypoxemia which produced the special pattern of the brain changes. In this pattern indeed circulatory effects are not completely missed. In all cases, a probable compensatory slight vascular hypertrophy, which consists in an increase of the endothelial cells of the small intracerebral vessels, is present. The common pattern of cases 32 - 34 is a definite increase of fibrillary glia in the cerebral and cerebellar white matter, in other myelinated structures and in the inner and outer surfaces of the brain.

e) Survived Carbon Monoxide Poisoning.

36.) Eh., F.A. 150/49, male, 56 years.

In 1917, during the first world war, the 24 year old patient was buried by a mine explosion. No external injuries; was transferred to a field hospital complaining of numbness. To questions he only repeated his name, was unclear, sometimes obstinate, even negativistic, restless and disorientated. After some weeks he became apathic, depressed, took no interest in his environment, and showed only slow a returning of incomplete orientation. Obviously had great difficulties in thinking, made a distracted impression, grimaced. Neurologic investigation revealed unequal size of the pupils, slight paresis of the right nervus XII and bad articulation in speaking. 1/2 year later he was able to do simple gardening. For the next 30 years he remained in an intellectually defective state, presenting some traits which resembled schizophrenia. For a certain time he was employed as farm worker. When he was readmitted to a mental hospital in 1948, a high degree of dementia, uncertainty and stiffness of gait were noticed. He became increasingly dull and stiff and died in 1949.

Autopsy: Recent pneumonia. Slight arteriosclerosis of the large brain arteries. Some gyri of the occipital lobe demonstrate état vermoulu. In both hemispheres is a slight degree of symmetrical granular atrophy of the occipital cortex. Old circumscribed softenings occur in both globi pallidi, on the right including especially the lateral part, on the left nearly the whole area. Both Ammon's horns were atrophic and of firm consistency. On section, the white matter below the cortical état vermoulu of the occipital lobes is partially sunken in wavelike formation. The ventricular system is considerably enlarged. A number of lobules of the cerebellum appear shrunken, especially in the regions near the hemispheric white matter. The consistency of the tissue is remarkably soft in the region of the dorsal putamen and the internal capsule of the right hemisphere.

Histology: Some occipital and temporal gyri demonstrate superficial defects on the surface and these are only partially covered by glial tissue. They are evidently of traumatic origin. Below some of these cortical contusional lesions are small areas in the white matter with spongy or cystic appearance. Otherwise a great number of small foci of incomplete nerve cell loss and mostly covered with glial or connective tissue, is found in all cortical layers. These small foci are distributed over the whole cortex of both hemispheres, but are most densely packed in the regions with granular atrophy in the occipital lobes. They are numerous also in the basal temporal cortex and the uncus, including both Ammon's horns. The lesions of the latter show no topistic pattern. The cerebellar cortex is likewise affected. Some lobules are sclerotic, others appear spongy. Obviously, all these cerebral and cerebellar focal lesions are of circulatory origin. They are partially related to thrombotic and recanalized pial arteries. In both hemispheres the globus pallidus participates also partly with focal lesions, filled with connective and glious tissue. Besides these focal defects are found a diffuse reduction of the nerve cell population of the whole territory of the globus pallidus with a conspicuous demyelination (Fig. 58) and a corresponding gliosis. The only recent lesion is an extended softening which includes the dorsal half of the right putamen and part of the neighboring internal capsule. Reactive processes are not yet present. These facts may be

related to a marked arteriosclerosis of the peripheral branches of the brain arteries.

Topography of the old scarred lesions: Cerebral and cerebellar cortex including Ammon's horn, globus pallidus. Symmetrically and of a topistic pattern in the globus pallidus only.

37.) El., F.A. 221/38, male, 53 years¹⁾.

During the first world war, the 30 year old E. was removed unconscious from a mine tunnel when he had tried to save some comrades. Awakened after 10 days, he developed a psychosis with the character of an amentia which gradually changed to a schizophrenia. Initial symptoms pointing to an optic agnosia disappeared completely later on under a catatonic symptomatology with hallucinations, unsystematic delusions etc. He died hospitalized for tuberculosis at the age of 53 years.

Autopsy: The formalin fixed brain weighed 950 g only. Both occipital lobes are considerably shrunken from symmetrically extended cortical changes of the convexity, reaching to the left temporal lobe. Likewise both frontal lobes show such lesions, expanding from the lower parts of the convexity to the orbital region. On frontal section the lesions change from ulegyria to cystic formations in which not only the cortex but the white matter also participates. The whole ventricular system is considerably enlarged. The Ammon's horns are shrunken in both hemispheres. No convincing changes of the basal ganglia, cerebellum, and mesencephalon.

Histology: The above mentioned cortical regions demonstrate the pattern of extended old circulatory disturbances, in part as cystic formations following cortical and subcortical softenings, also as small foci which are covered by glious tissue, and finally as laminar changes, often with complete loss of nerve cells. Beneath the cortical changes, the white matter shows cyst formations and extended simple demyelination. In no place are found superficial cortical tissue defects, pointing to traumatic lesions. In Sommer's sector of the Ammon's horns is a nerve cell loss. The histologic cortical changes surpass in general the grossly changed regions, observed at autopsy.

1) This case is published by Roeder-Kutsch and Scholz-Wölfing, Z.Neur. 173, 702, 1941

The right cerebellum participates with lobular atrophy. The cerebral vascular system reveals no organic changes e.g. arteriosclerosis or remains of former thrombosis. In regard to the pathogenic factors, it is of considerable significance that both globi pallidi demonstrate symmetrically arranged multiple scarred foci (Fig. 59), accompanied by a diffuse numeric reduction of nerve cells in the whole area of the globus pallidus (Fig. 60) which points to mine gas (carbon monoxide) poisoning. Besides these more or less focal or circumscribed lesions, the cerebral and cerebellar white matter demonstrate a subependymal gliosis and a tendency to a moderately diffuse pronounced perivascular fibrous gliosis with here and there a slight perivascular demyelination. Thalamus, striatum, mesencephalon and medulla oblongata present no definite lesions, except for a fibrous gliosis of the olives.

Topography: The lesions of the cerebral cortex and white matter, including the Ammon's horns, and of the globus pallidus are all symmetrically arranged. The cerebellar changes are apparently unilateral. Topistic patterns appear as laminar cortical changes, as nerve cell loss on Sommer's sector and field h_3 of the Ammon's horn, as symmetrical softenings of the globus pallidus, and perhaps as symmetrical exemption of the visual cortex from the severe changes of the neighboring cortex.

38.) Jor., F.A. 25/41, male, 42 years.

During the war in military service, J. was for years a habitual drunkard and smoker. After an alcoholic excess and a dispute with his wife, he was found 7 hrs. later unconscious in the kitchen, with the gas bracket open. After transfer to a military hospital consciousness returned gradually the next day. Complete amnesia. Neurologic investigation: only a slight hanging of the right angle of the mouth. He was kept in hospital for 18 days. 3 1/2 months later suicide with lighting gas.

Autopsy: Dilatation of the heart with hypertrophy of the left atrium and the right ventricle; healed endocarditis of the mitralis. Brain weight 1440 g. Considerable injection of the pial and intracerebral vessels with bright red blood. No definite arteriosclerosis of the large brain arteries. On frontal section an extended recent softening

of the white matter of the right frontal lobe becomes visible; it includes part of the cortex and extends nearly to the ventricular system from the outer surface of the caudate nucleus to the origin of the thalamus. The right occipital lobe shows a similar, but apparently older extended softening, which spars the cortex. Otherwise no definite changes.

Histology: The above mentioned softenings of the white matter appear as demarkated infarctions. They demonstrate a fully developed process of organization, are filled with fat granular cells and abundantly growing connective and glious tissue. Nevertheless cyst formation is beginning. The cortex is completely involved in the occipital softening which is somewhat more progressed in organization. No vascular thrombosis is observed, to explain the infarctions. Distinct from these infarctions are seen several small foci of necrosis in the same state of organization symmetrically in the globi pallidi of both hemispheres. Besides these small softenings, the whole area of the globus pallidus is diffusely covered with numerous progressive fibrous astrocytes (Fig. 61), but a diffuse numeric reduction of its nerve cells cannot convincingly be observed. The striatum also demonstrate a diffusely spread increase of fibrous astrocytes without diminution of its nerve cell population. Only in the thalamus are found scanty foci of nerve cell loss with corresponding gliosis. Aside from these changes is a tendency to a diffuse increase of fibrous glia in the whole cerebral and cerebellar white matter as well as in the pons and the medulla oblongata. A subependymal gliosis is marked. Ammon's horns, cerebellar cortex, nigra substance, dentate nucleus and inferior olives are not convincingly affected.

Topography: Cerebral cortex and white matter of the right hemisphere, globus pallidus symmetrically, and thalamus with neuronal destruction. Striatum, corpus Luysi, cerebral and cerebellar white matter, pons and medulla oblongata with gliosis only. A topistic pattern appears only in the symmetry of the lesions of the globus pallidus.

f) Severe States of Hypoxia During the Course of Poisoning by
E 605 BAYER (Diaethyl-P-nitrophenyl-thiophosphat).

39.) Bles., Hamburg 27a/55, male, 20 years.

After a conflict he attempted suicide together with a young girl by the plant protection drug E 605 BAYER. Short after being found, both became unconscious and were transferred to a hospital within half an hour; the girl died on the way. An edema of the lungs with severe cyanosis and Cheyne-Stokes respiration developed quickly; intubation was necessary. One hour later for about 90 min. no spontaneous movements of respiration, tachycardia, blood pressure 200/110 mm Hg. Numerous tonic-clonic convulsions, extreme cyanosis, total areflexia with some muscular rigidity. Cheyne-Stokes respiration persisted for the first 24 hrs., then the convulsions decreased in number, transient athetotic movements were observed, respiration became regular, consciousness returned gradually. On the third day, B. recognized his mother; retrograde amnesia, became restless and aggressive. Permanent salivation and insatiable thirst. Transfer to a psychiatric clinic proved necessary for the next 6 months, leftside spastic reflexes, disorder in the coordination of movements were stated; slowness of all impulses and affective incontinentia are mentioned later on in contrast to a silly pueril behaviour in the beginning. Patient died nearly two years after the poisoning from an unknown cause.

Histology: In no area of the cerebral and cerebellar cortex can be observed a numeric reduction of nerve cells nor a definite gliosis reaction. The white matter of the occipital lobes demonstrates a slight diminution of myelin fibers and a definite fibrous gliosis of moderate density (Fig. 62). Sommer's sector, field h_3 and the stratum granulosum of one of the Ammon's horns have lost nearly all their nerve cells; in their place a dense fibrous gliosis is found. Both thalami have the most extended change; as effect of a former selective neuronal necrosis a thinning of high degree of the nerve cell population can be observed from the frontal begin to the pulvinar. A corresponding patchy, often confluent reactive gliosis, consisting of great fibrous astrocytes has developed. The globus pallidus presents a calcification of the muscular layer of its arteries; but otherwise no changes.

Topography: Thalamus bilateral, Ammon's horn unilateral, white matter of the occipital lobes bilateral.

40.) Gral., F.A. 35/56, male, 20 years.

The birth of the patient was complicated and of long duration. In his 17th year he developed epileptic symptoms as absent mindedness, convulsions and dreamy states, personality changes followed. Polycythemia. At the age of 20 years he committed suicide by means of the plant protection drug E 605 BAYER. Afterwards he lived for 15 - 20 hrs., and died from edema of the lungs.

Autopsy: Brain weight 1570 g. Both gyri uncinati present tentorial impresses. As cause of the epilepsy can be observed a rather extended region of gyral shrinkage at the medial and basal surfaces of the right occipital lobe. The right Ammon's horn is shrunken and of firm consistency.

Histology: The shrunken occipital gyri present mostly the pattern of ulegyria with a changing degree of nerve cell loss and fibrous gliosis. In only a few places has the connective tissue become organized. The right Ammon's horn, mainly field h_2 and h_3 demonstrates a marked numeric reduction of the nerve cells. Recent changes consist of a generalized intense venous congestion, followed by serum- and erythrodiapedesis in irregularly distributed regions of the cerebral and cerebellar cortex. A large number of pyramidal nerve cells is swollen, but they do not show definite marks of necrosis. The nerve cells of the globus pallidus and of the corpus Luysi are in general shrunken and present dark stained nuclei with plasm tigrölysis, but no bright eosinophilia. The typical picture of ischemic necrosis is nowhere developed.

Topography of the recent lesions: Cerebral cortex, globus pallidus.

Comment to cases 39 - 40: It may appear somewhat artificial to put these two cases in a series of general oxygen deficiency of the brain, all the more as we don't deal with enzym poisons related to the oxydation process of cell metabolism. But there are in both cases intermediate factors pointing to hypoxemia as pathogenic factors: in the first place the severe edema of the lungs in case 39 which made intubation necessary, moreover causing Cheyne-Stokes respiration and arrest of respiratory movements for 1 1/2 hrs. The patchy character of the thalamic lesions and the unilateral severe lesion of the Ammon's horn in case 39 point to circulatory pathogenic factors, related to hypoxemia; the gliosis of the occipital white matter may possibly be the result of hemodynamic edema. The old

scarred lesions of the right occipital lobe in case 40 may be related to a birth trauma as cause of the epileptic development, the unilateral sclerosis of the Ammon's horn possibly as convulsive lesions. As the fully developed feature of ischemic nerve cell necrosis is not met, the recent changes of the nerve cells cannot be definitely determined. But it is likely that we deal with transient states to typical changes as far as the nerve cells of the globus pallidus are concerned. It is remarkable that in both cases there is no local coincidence of venous diapedesis and nerve cell changes; it is therefore not likely that the nerve cell changes are dependent on a transsudation only.

III. Complicated, not Clearly Defined Conditions of Oxygen Deficiency.

41.) Gün., F.A. 40/34, female, 23 years.

The prostitute was murdered; a bullet penetrated the thorax and injured the left inferior pulmonary vein and left inferior lobe of the lung. The thorax was opened by the surgeon in pressure chamber and the ruptured vein sutured. General convulsions and other not exactly defined cerebral symptoms occurred. She remained unconscious from the injury until she died 2 days later. An air embolism was suspected.

Autopsy: of the brain revealed no special findings.

Histology: The extended but relatively mild lesions are to be characterized as selective neuronal necrosis which in no area reaches the state of softening. Single nerve cells in the state of ischemic necrosis are distributed all over the cerebral cortex. In some places these damaged nerve cells are very close together, forming small foci of paling or also laminar pallor. In both Ammon's horns the Sommer's sector is affected. The medial parts of both thalami and the anterior part of the caudate nucleus present some small foci of pallor. In the cerebellar cortex is a disseminated homogenization of the Purkinje cells. The glia cells do not show regressive changes anywhere. Reactive processes are just beginning with some rod cells in the cerebral cortex and with single neuronophagy of necrotic Purkinje cells. In the lesion of ischemic necrosis, the neurofibrils are still rather well preserved in the dendrites although already broken down in the perikaryon.

Topography and scale of severity of lesions: Cerebral cortex, in-

cluding Ammon's horn, thalamus, striatum, cerebellar cortex.

Comment: Two, or perhaps three pathogenic factors have to be considered: sudden secondary anemia from a fall of systemic blood pressure, and the clinically supposed air embolism. Morphologic changes point to a circulatory disturbance in the pathogenesis because of the focal character of some lesions. On the whole, the neuropathologic pattern resembles all cases of air embolism which survived a sufficient length of time. Topistic patterns appear in laminar changes, the affected Sommer's sector and in the restriction of cerebellar changes to the Purkinje cells.

42.) Lan., F.A. 346/36, male, 49 years.

Because of a carcinoma, resection of the larynx in 1932. 1936 recurrence of the carcinoma, causing great difficulties in swallowing and increasing hardening of the region of the left sternocleidomastoideus and of the bottom of the mouth. A perforation developed with an opening of 1 1/2 cm in diameter, close to the left side of the trachea. 1 day before death a profuse hemorrhage escaped from this opening.

Autopsy: Large communication between oesophagus and trachea; voluminous necrotic hole on leftside beneath the trachea in which the left carotid artery is destroyed. From this destruction the profuse hemorrhage took its origin. The proximal and distal stumps of artery are thrombosed. Small thrombi are found also in the right carotid artery and the left Sylvian artery. The 1665 g fresh brain shows thrombosis of pial veins of the left frontal lobe and of the surface of the adjacent temporal lobe. On frontal section, the brain substance is strikingly anemic. In some places, however, i.g. in the frontoparietal and cingular region is a reddish-blue discoloration.

Histology: The cortical changes are very extended and severe. They vary from fresh selective neuronal necrosis to recent softenings with an edematous zone of demarkation. Nearly symmetrical softenings can be observed in both occipital lobes, whereas disseminated and laminar nerve cell necrosis, often extending over all cortical layers, dominates the frontal and parietal cortex. Most nerve cells of Sommer's sector in both Ammon's horns present the type of complete ischemic necrosis. In the cerebral cortex are a great number of transitional nerve cell changes with some pericellular incrustations. In the basal

ganglia, it is mainly the thalamus which contains a great number of demarkated foci of necrosis (Fig. 63). Striatum, globus pallidus, and corpus Luysi are also not free of disseminated necrotic nerve cells. The nigra substance participates with rather many of its nerve cells. Non characteristic nerve cell changes are seen in the pons and the motor cells of the medulla oblongata. The cerebellar cortex presents only few necrotic Purkinje cells, likewise the dentate nucleus. Except for a few elongated microglia nuclei in the cerebral cortex, a reactive glial or mesenchymal proliferation has not yet made its appearance.

Topography: Cerebral cortex, including Ammon's horn, thalamus, striatum, globus pallidus, nigra substance, cerebellum.

Comment: There are two pathogenic factors in competition: one an acute secondary cerebral anemia from the profuse hemorrhage of the left internal carotid artery and second an anemia from the interruption of the circulation in this artery, because of partial thrombosis of the right carotid artery and extended thrombosis of pial veins. Practically it seems impossible to separate the effect of both factors; probably they accentuate one another. Because of the great extension of the lesions and the existence of infarctious softenings, the morphologic situation points to a circulatory disturbance in rather proximal parts of the cerebral arteries. It is difficult to draw conclusions about the topistic pattern of some of the lesions (laminar lesions, changes in the Ammon's horn). It is true, that the participation of the regions with bloodflow from the posterior cerebral arteries (cerebellum, Ammon's horn, posterior lobe, nigra substance) might suggest the influence of a factor which concerns the whole brain, as in this case is secondary anemia.

43.) Zweck., F.A. 301/35, female, 48 years.

Because of symptoms of Basedow's disease, a strumectomy under avertin-anesthesia with ether was done. During operation respiration and heart activity were regular; some hours later the still unconscious patient developed cyanosis, slow respiration. After administration of stimulating drugs slight improvement of pulse and respiration, but soon severe cyanosis and shallow respirations returned. Pulse regular; carbon dioxide and oxygen were given, cyanosis and respiration im-

proved. One hour later gradually increasing circulatory failure; death 16 - 18 hrs. after operation without returning of consciousness.

Autopsy: Terminal edema of the lungs, old pleural adhesions. In the white matter of the right hemisphere are extended fresh hemorrhagic cortical infarctions combined with hyperemia and small bleedings. The hemorrhagic infarctions are found exclusively in the depth of the sulci, especially in the right parietal lobe and the left temporal lobe.

Histology: Extreme dilatation of meningeal and intracerebral vessels including the capillary system. In the cerebral cortex, including also the frontal and occipital lobe, numerous small softenings are distributed over far more extended regions than macroscopically expected. Nearly all of them are demarkated by thin zones of edema (Fig. 64). The thalamus of the right side also contains a small softening. Beneath these softenings are numerous small foci of neuronal necrosis only. The occipital cortex of one side, Ammon's horn, striatum and globus pallidus, which are less involved, demonstrate a diffuse distribution of a great number of single ischemic necrotic nerve cells. In the cerebellum is an irregularly distributed moderate number of homogenized Purkinje cells. Oligoglia and astroglia are regressive in the recent softenings. Otherwise is a just perceptible progressive transformation of microglia and astroglia. Towards the midbrain the changes are obviously diminishing. There is a loosening of the periventricular tissue zone from edema.

Topography: Cerebral cortex, thalamus, Ammon's horn, striatum, globus pallidus, cerebellar cortex.

Comment: The pathogenic situation cannot be clearly defined. The whole realm of changes is remarkably different from those of cardiac arrest and strangulation. The first impression is that of a venous thrombosis, especially because of the multiplicity of small partly hemorrhagic cortical softenings points to this origin, but thrombosis of the venous outflow cannot be stated. It is likely that a circulatory collapse from paralysis of the peripheral vessels happened in combination with other pathogenic factors. The state of development of the morphologic changes points to their origin during or shortly after operation.

Histologic Findings in the Brain Changes.

Total cerebral ischemia can only manifest itself in the tissue if the duration is not long enough to kill the individual, and if the period of survival is of sufficient duration to produce structural changes. The duration in cerebral ischemia must comprise a very short period of time. In our material it constituted a minimum of 5 min. and a maximum of 25 min. Because of the limited time interval, it is not expected that the most severe types of tissue necrosis occur in incidences of total cerebral ischemia, as for instance, the type of total necrosis, which also destroys connective tissue. However, the stage of malacia was encountered several times. The periods of survival in the series of total cerebral ischemia in which structural changes could develop were likewise rather limited; they range from 5 hrs. up to 9 days. The terminal stages of cicatrization could not therefore be demonstrated at all. From a consideration of the acute findings and a comparison with local circulatory effects one may draw conclusions as to what the course of further development might have been.

As expected, fundamental qualitative differences in histological findings could not be elicited in respect to focal circulatory effects. On the other hand, we received certain information about the formal and periodical development of regressive and reactive processes in those cases where the duration of oxygen deficiency and manifestation time could be determined with sufficient accuracy. Cases with heart arrest and a few strangulation cases were reviewed for this information. In the attached tables are listed both categories of cases in the sequence of the elaborated manifestation time. This must, like the duration of oxygen deficiency, exhibit a basal line in regard to the development of morphologic changes. The manifestation time ranges from 5 hrs. up to 9 days in cases of heart arrest and from 18 hrs. up to 8 days in cases of strangulation. Whereas the duration of heart arrest varies between a few minutes and 25 min., the duration of hanging in strangulation is reported as 4 - 5 min. and 15 min. in only two cases. One can say immediately, that there were structural changes of various degrees of severity in all cases of both categories. They fluctuate

between nerve cell changes not yet identified as necrotic stage, necrosis of single nerve cells or nerve cell groups within a morphologically intact nerve cell population and selective necrosis of all nerve cells in circumscribed regions. Tissue softening must be assumed in very acutely occurring yet reactionless alterations if, besides the nerve cells in circumscribed areas, the astroglia shows definite signs of disintegration. Even in cases with the shortest duration of ischemia, a few minutes only, and a manifestation time of 5 hrs. (case 1) regressive changes in a number of nerve cells in the cerebral cortex and field h_3 of the Ammon's horn could be demonstrated. However, they do not exhibit the definite signs of cellular death. Even though in the above case it cannot be decided whether the duration of ischemia or the manifestation time were of sufficient length to create typical necrosis, the strangulation case 7 with hanging time of 4 - 5 min. only and a manifestation time of 18 hrs. shows that such a short period of ischemic leads to the formation of actual nerve cell necrosis, that is, in the sense of an extensive elective parenchymal necrosis, presenting a typical ischemic pattern of necrosis (Fig. 16). There is a possibility that the duration of ischemia, in case 1, was sufficiently long in order to produce irreversible changes but that the five-hour manifestation time did not suffice for the development of demonstrable necrosis. In case 2 with heart arrest of 20 min. duration, definite necrosis can be demonstrated with a manifestation time of 8 hrs. (Fig. 1). Here the predominant features are the very fulminating progressive disintegration processes in nerve cells (swelling and vacuolization with loss of contour; extreme shrinkage along with structural break-down of the nucleus; incrustation). There is no evidence of any development of typical ischemic types of necrosis with all its features. Especially the plasma eosinophilia is missing. This rapid onset of cellular disintegration locally involves the oligo- and astroglia. The changes in this early stage are characterized by softening, at least in circumscribed areas, and deserve attention because of the recently employed undercooling for therapeutic purposes. It was found, for example, that the body temperature of the female patient had not risen above the level of 20° C in the interval between heart arrest and death. If this produced a slowing of the enzymatic processes of autolysis, one should be able to find

the characteristic histologic reaction complex of tissue softening in extensive cortical areas after a prolonged manifestation time as in case 4 (cardiac arrest of 20 min., time for manifestation 4 days). This was true, since the transition from laminar selective neuronal necrosis to malacia, associated with reactive processes of the connective tissue, is clearly demonstrable (Fig. 3). If there is evidence of transition into regional malacia after 25 - 30 min. of respiratory arrest associated with 10 - 15 min. of cardiac arrest in case 3, and after 10 min. of cardiac arrest in case 6, while malacia is entirely missing after cardiac arrest of 25 min. in case 5, then it is deemed possible that there was a residual circulation over a certain period of time in the last case mentioned. In other words, the cerebral ischemia was not complete during the entire period of 25 min. In cases of strangulation one presumably has to consider only regionally effective residual circulation which depends on the application of the strangulating device (H. JACOB). Therefore, it is not always possible to correlate the duration of effect of cerebral circulatory arrest with the manifestation time and with the degree of severity in histologic changes. Eventually other factors, as the episodic occurrence of generalized convulsions, have to be taken into account, because they may produce the same type of changes.

If focal or infarct features are missing in circulatory anoxia, fully developed ischemic nerve cell necrosis has always been the most reliable and most frequent structural characteristic in proof of etiology. As long as regional differences do not give any clue, and reactions in the interstitial tissue do not occur, it is often impossible to exclude a postmortal autolysis in cases of intravital necrosis with suspicious nerve cell changes - especially swellings including signs of liquefaction and cell shrinkage. The not absolutely specific picture of ischemic nerve cell necrosis varies to a certain extent. We have seen such a picture presenting all features in ubiquitous distribution in the brain of a lethally injured man who was exhumed 4 weeks after burial; just this distribution makes them easily recognizable as post mortem changes. The classic form of ischemic nerve cell necrosis in Nissl preparations (SPIELMEYER 1922) was found in our cases of cerebral circulatory arrest most frequently in regions of elective parenchymal necrosis. The plasma eosinophilia demonstrated this

ischemic necrosis of nerve cells even in regions of malacia where the nerve cell plasma remains refractory to staining with basic aniline dyes.

The studied cases did not disclose any further information in regard to the problem of causative conditions and to the developmental stages of this important type of ischemic nerve cell necrosis. In accord with experiences of others the less characteristic processes in nerve cells, as rapid disintegration and liquefaction, seem to occur more often in sudden and complete circulatory anoxia than the typical ischemic type of necrosis. The latter, by way of comparison, remains visible in the tissue for a longer period of time. In case 6, ischemic necrosis was still present in typical form in the Ammon's horn together with a very intensive glia reaction, on the 9th day after the incurred damage (Fig. 13). We found ischemic necrosis more often in strangulation than in heart arrest, where there are more frequent transitions into regional malacia (4 times in 6 cases). This speaks in favor of a more complete circulatory anoxia than in strangulations of which only 2 cases from 8 presented transitions into local malacia. It could also indicate a persistent residual circulation causing a delayed onset and a milder type of tissue damage.

Our cases of hypoxemia give less detailed information concerning acute tissue changes. Ischemic nerve cell necrosis with yellow colour are well known in kernicterus. We found ischemic nerve cell necrosis and other milder nerve cell changes in the Ammon's horn in only one case (19). This was a case of extremely severe dyspnea lasting several days and which necessitated a tracheotomy (Fig. 19). One case of respiratory arrest, due to intravenous injection received artificial respiration for 19 hrs. (20). The brain revealed a very fulminant noncharacteristic type of nerve cell disintegration, disseminated over large areas of the cerebral cortex, produced in all probability by some type of embolism that had already caused the respiratory arrest. An intensification of changes especially in the cortical lamina III without distinct signs of malacia could, in accordance with case 41 (rupture of the left inferior pulmonary vein), be interpreted as air embolism. In one case of acute atmospheric hypoxia (23), the survival time was deemed too short for the development of distinct nerve cell necrosis.

The cases with prolonged survival are of interest from the standpoint of initiating reactive processes which in particular concern the removal of devitalized tissue, the conversion of the latter into absorptive substance and the closure of defects. The importance lies in the fact that this resembles experimental conditions, since the degree of severity, duration of effect and manifestation time are reliably well known. It is noteworthy that the onset of neurophagocytic reactions, which conceivably are only possible within the scope of selective neuronal necrosis, could be observed in field h_3 of the Ammon's horn after a period of 18 hrs. in a strangulation case (7) with a hanging period of 4 - 5 min. Strangulation case 8 with the same manifestation time but an unknown hanging time, showed very fulminant disintegration signs in the cortical nerve cells and even regional malacia but the above mentioned neuronophagic reactions were only seen sporadically about Purkinje cells of the distinctly less damaged cerebellum. These cases indicate that the interstitial elements react at various speeds and with variable intensity within the same manifestation time and in the apparently same degree of tissue damage, namely, a selective neuronal necrosis. This also means that the interstitial elements may be damaged in a way which does not manifest itself morphologically but which causes a temporary suppression of reactivity. Therefore, in cases with an unknown duration of the oxygen deficiency, the absolute manifestation time for structural changes can be estimated within certain limits from the stage of reaction. If the manifestation time is known, certain conclusions may be drawn concerning the severity and duration of oxygen deficiency. Some differences in the developmental speed of reactive processes, which are usually present to a variable degree in all cases of circulatory oxygen deficiency of longer manifestation periods than 18 hrs., are probably explainable this way. Hence, we find for instance, that neuronophagic reactions in strangulation case 9 with a 35-hour manifestation time (Fig. 17) are further advanced than in case 10 with 46-hour manifestation time (Figs. 18, 19). The changes found in the first case are more disseminated and of less intensity. In all cases with a manifestation time of over 64 hrs. the reactive processes are of such an impressive nature that the less impressive process of cell necrosis appears to

be rather inconspicuous. As can be understood, all types of transitional stages are encountered corresponding to the speed of reactions. In general, the microglia is the first element to show reaction in our cases. Unmistakable proliferative features associated with an increase in cytoplasmic volume are found in the astroglia not earlier than after a lapse of 64 hrs. (case 11). The first appearance of glia fibers can be demonstrated in acute total circulatory ischemia in areas of selective neuronal necrosis after a lapse of 4 days (case 4, Fig. 7). After 6 days (case 5, Fig. 10), large pathologic types of fiber forming astrocytes are seen in adults. After 9 days a new formation of fibrous astrocytes is seen in a 13-months old child (case 6, Fig. 14). With a manifestation time of 4 days (case 4) sparse sudanophile droplets originally occur in rod cells of the cortex whereas after 6 days (case 5) they are seen there in abundance within the glia macrophages of the thalamus. In how far the appearance and quality of sudanophile metabolites depend on the simultaneous decomposition of myelin structures in the region of selective nerve cell necrosis, could not be definitely determined. It is remarkable that in case 6, 9 days after a total ischemic period, the grey matter is almost alone involved with relatively little disintegration of medullated fibers and only a moderate amount of sudanophilic substance was visible in the cortex while it was entirely missing in the relatively sparse medullated field h_3 (terminal layer) of the Ammon's horn, despite the presence of numerous necrotic nerve cells and intensive reaction of the microglia. Clear evidence that the quantity and early occurrence of sudanophilic substance depends largely on the material composition of decomposed structures, could be shown in strangulation case 14, in which the white matter was predominantly affected. Here after a manifestation time of only 8 days we find in the white matter a large amount of sudanophilic substance of which the quantity explains the early occurrence of numerous fat granule cells. Study of the cases 4 - 6 confirms the usual finding that a relatively small amount of sudanophilic substance is present in regions of solely elective parenchymal necrosis, even if all nerve cells in a cortical area are necrotic, provided that the corresponding myelin containing structures are essentially preserved. Medullated fibers of the grey matter exhibit widespread disintegration

features especially in cases accompanied by regional edema. Such edema was ordinarily considered the reason for an incidental concomitant demyelination in the white matter (case 4). We then see an increase in sudanophilic products. Hence, only a small number of fat granule cells can be demonstrated even in highly advanced stages of solely cortical selective parenchymal necrosis. In case 6 with the longest manifestation time (Fig. 12) an active defect covering protoplasmatic macroglia proliferation had already appeared on the 9th day. The macroglia revealed such pronounced features of large chromatin rich nuclei and large asteroid cytoplasm, that the microglia reactions stood in the background in the Nissl stained preparations. It seems that a massive fiber production, as is known in the terminal stages of elective parenchymal necrosis, develops quite some time later.

Of interest are certain deviations from this type of a short reaction time that we had a chance to see in case 27 after survival from icterus neonatorum with severe anemia. Symptomatology and course of illness as well as comparison with other analogous cases (25, 26, Figs. 33 - 35) do not leave any doubt as to the fact that changes in the globus pallidus, corpus Luysi and Ammon's horn have already developed within the first days of life. In spite of this, the involved areas were still found to be covered with hematoxylinophilic and sudanophilic substances after 10 1/2 months. Moreover, there was no evidence of its eventual removal since there was no accumulation of such substance around the vessels. This retardation did not concern the macroglia reaction for we could demonstrate a fairly distinct fiber gliosis in the affected areas (Figs. 37, 38). If the occurrence of similar processes in cases of leucodystrophia are to be explained as constitutional enzymopathy, then the causes for this abnormal finding in case 27 are still in the dark. It is considered quite an unusual event in a milieu of anoxic damage of nerve tissue and of kernicterus.

Contrary to transient microglia reactions, the fiber gliosis, as a rule, is the consequence of loss of regional tissue. But it is not always possible to prove such a connection due to the fact that a local defect may not at times be demonstrable at all. Therefore SCHOLZ (1949, 1955) focused attention upon functional tissue mechanisms, which

are considered specific stimuli for the fiber formation of astrocytic glia, such as in external and internal gliosis (Chaslin's marginal gliosis, periventricular and perivascular gliosis) and in that type of massive gliosis which occurs secondary to inflammatory processes without corresponding tissue destruction. In our cases of hypoxemia with long survival periods we could see dense gliosis in the globus pallidus, corpus luyysi and in the Ammon's horn. This gliosis is explained as a phenomenon of defect closure because of the corresponding nerve cell and fiber loss (cases of birth asphyxia, 15 - 18, and cases of survived icterus neonatorum, 26 - 28; Figs. 23-27, 33, 34, 36). A related loss of nerve cells and fibers is however missing in some types of gliosis of the grey and white matter, as in external and internal superficial layers, in the tractus opticus and at times also in the inferior olive and nucleus dentatus. One may encounter fiber bundles forming astrocytes in the grey matter where they are normally missing. Such apparently primary types of gliosis are seen in all of our three cases of chronic anemia (cases 29 - 31, Figs. 42, 43, 45 - 47, 49 - 53). A lesser degree of gliosis in the white matter of cerebral and cerebellar hemispheres, significant subependymal gliosis as well as gliosis of the tractus opticus and medulla oblongata are also found in cases of birth asphyxia and icterus neonatorum besides defect gliosis in the basal ganglia (Figs. 23, 24, 39, 40). In two of the above cases the ventral layers of the medulla oblongata were found to be especially affected (Fig. 40). Even in case 24, in which the atmospheric hypoxidosis was survived, an advanced degree of this common type of gliosis was demonstrable (Figs. 30 - 32). In spite of the realized imperfection of our histologic methods and the difficulty in observing minor diffuse defects in areas of densely arranged medullated nerve fibers it is, considering the comparatively large number of cases, very unlikely that a loss of neuronal structures would always fail to be demonstrable. Perivascular zones of thick gliosis in the medullary substance and the frequently impressive form of superficial gliosis in the region of the basis cerebri including the tractus opticus and, especially the thick periventricular masses of glia fibers indicate that functional tissue mechanisms are involved in its development. Only speculations are possible in regard

to the causes of other apparently functional gliosis, as for instance, in the striatum. In birth asphyxia and especially in cases of icterus neonatorum with icterus gravis, the effect of transsudative processes (kernicterus) must be considered coexistent causing the brain volume to increase over a certain period of time. Also, it produces tension in the tissue structures and like a form of indurating edema stimulates the proliferation of interstitial tissue. In chronic anemia are such conjectures more firmly established. The development of fibrous astrocytes in grey substances where they are normally not demonstrable at all, as for instance, in the middle layers of the cortex and in the striatum (cases 29 - 31, Figs. 46, 49, 52) raises the question whether a decreased supply of oxygen may directly stimulate the astroglia and may cause fibrous glia cells to appear all over. Our cases offer no data for a comparison with the terminal stages after total cerebral ischemia. Therefore it is impossible to determine, whether there are any variations in the development of common gliosis as regards cases of hypoxemia. In total cerebral ischemia mechanical tissue factors are the basis in the development of a gliosis apparently caused by rather prolonged congestions and, in several cases, also by proven cerebral edema causing volume changes of longer duration. In case 6 an increase of fibrous astrocytes in the white matter of the cerebral hemispheres was already clearly visible after a period of 9 days (Fig. 15).

Although observations on the quality of tissue changes in general circulatory ischemia of the brain did not disclose fundamentally new aspects concerning local ischemia it was possible, however, to obtain more precise data concerning the chronological course of single processes. Limited survival periods of the affected individuals provided a limited observation time. The equal type of effect which was always encountered in general ischemia of limited duration and in transitory local ischemia justifies the assumption that there are basically no variations to be expected in the further course of development, until the terminal stage is finally reached. The main efforts made in pathologico-anatomical research of general circulatory oxygen deficiency are not sought in the histology of structural damage, but in the topography of tissue changes. To a yet higher degree the same applies to

cerebral tissue damage caused by hypoxemia of extremely different etiology.

Topographical Data Regarding Tissue Changes and Regional Distinctions in Intensity.

In a tabular compilation of data regarding the topography of brain changes and their regional variations in intensity (Table II), some aspects had to be sacrificed to the individuality of the single case. As cases without definite pathologic findings are useless, cases 21 and 22 with respiratory arrest in myatonia, case 23 with immediate death from atmospheric hypoxidosis and case 35 with malformation of heart had to be omitted. In order to evaluate only cases which exhibit oxygen deficiency affecting the entire brain, cases 42 and 43 had to be eliminated, since extensive ischemic infarctions followed gross circulatory disturbance in regions of single large cerebral arteries. From 43 investigated cases only 37 could be used for general statistical evaluation as far as topographical aspects are concerned. It seems contradictory that we include the cases 20 and 41 in this series, because embolic features have probably played a major role in the development of the brain lesions. But ischemic infarctions are entirely missing in these cases and since rather diffuse and at times even topistical changes dominate the picture, it is assumed that numerous, equally distributed microemboli produced conditions similar to general cerebral oxygen deficiency. We also included in the topographico-statistical evaluation, cases, in which there was marked diffuse and regional fibrous gliosis without corresponding neuronal loss, as in asphyxia neonatorum and icterus neonatorum, besides the topistic neuronal loss in the globus pallidus, corpus Luysi and Ammon's horn.

Considering the above mentioned limitations it becomes obvious that the grey matter of the brain was affected in each of the remaining 37 cases whereas the white substance of the cerebral and cerebellar hemispheres presented changes in only 29 of the 37 cases. In only 13 cases did these changes constitute a demonstrable decomposition or loss of medullated fibers. Among these 13 cases are 6 which had ex-

tensive cortical malacia with affection of the white matter; namely, there is one strangulation case (14), 2 cases with acute decompensation in adapted heart malformation (33, 34) and 3 cases of survival from CO-poisoning (36 - 38) of which one case (36) is complicated by severe arteriosclerotic changes. Among the remaining 7 cases, acute perivascular edematous disintegration was present in 4 incidences while a lesser degree of diffuse decomposition of medullated fibers, probably as a result of general cerebral edema, was encountered in 3 cases. In 16 other cases was a more or less developed fiber gliosis but more significantly pronounced in the superficial regions of the brain without definitely detectable loss of nerve fiber structures. We have focused attention upon this type of gliosis and its possible pathogenesis in the previous section of the paper. The proportion of affected grey matter to white matter was 3:1 in regard to directly demonstrable loss of nerve structures following general cerebral oxygen deficiency. If such sequelae as edema and cortical malacia were not included, the proportional difference would be a quite larger one.

The Ammon's horn was found to be the most frequently affected area in the grey matter in regard to the pathogenetic basic situation. Lesions in the Ammon's horn occurred in 29 out of 37 cases with bilateral neuronal loss in 26 incidences, of which were 9 symmetrical in type. They all presented the features of selective neuronal necrosis. Second in frequency of lesions was the thalamus which showed neuronal loss in 26 cases, in 2 of which was an associated fiber gliosis. Next in numerical order were the cerebral cortex, striatum, globus pallidus and cerebellar cortex. We avoided the discussion of further regional alterations of relatively minor frequency since they must be of doubtful statistical value within the scope and type of this investigation .

Even if the brain lesions are of significant intensity and are widespread, the degree of change generally diminishes with fair rapidity towards the regions of mesencephalon and medulla oblongata. Apart from the inferior olives, in none of the cases is there definite necrosis or nerve cell loss in these areas. However, a marked fiber gliosis could often be seen. To a low extent are the vegetative diencephalic nuclei subject to hypoxic damage in spite of their proximity to the favoured areas for grey matter lesions and the often intensive

ventricle wall gliosis. Neither in the nucleus paraventricularis nor in the nucleus supraopticus are observed acute changes or neuronal loss comparable to the findings in the adjacent thalamic region, globus pallidus etc. It is worth mentioning, however, that there is a relative frequency in the involvement of the nucleus dentatus and inferior olive (both in case 11) so far as neuronal necrosis or loss is concerned. That will be discussed together with the topistic changes. The plain gliosis developing in the white matter and superficial regions as well in areas of grey matter, not associated with loss of nerve structures, has been already mentioned; it can be demonstrated best in its late stages. Regions which proved to be rather resistant to anoxic damage were comparatively often involved by such gliosis, namely, the pons in 5 and the medulla oblongata in 7 incidences (cases: 17, 18, 24 - 26, 30 - 32). In each case the primary features were hypoxemia. But it is likely that it may be produced by transient ischemia too.

In spite of the obvious variations in topographical findings of each individual case, the evaluation of the absolute figures, obtained from all the material, does in no way exhibit a characteristic statistical picture. The situation is different as soon as one considers a group of cases showing a comparatively constant topographical pattern which reveals systemlike characteristics and moreover allows a sound judgement concerning the neuronal loss. This concerns the cases 15 - 18, 25 - 28, and 32, with topistic neuronal loss in the globus pallidus, corpus Luysi and Ammon's horn. They all exhibit a truly primary state of hypoxemia, namely, asphyxia neonatorum and erythroblastosis associated with severe progressive anemia in the newborn. It appears logical to compare the just mentioned cases with cases 1 - 14 which show transitory ischemic oxygen deficiency. In so doing one encounters a rather striking polarity. In the ischemic group the cerebral cortex and Ammon's horn are always severely affected. With 2 exceptions the same applies to the cerebellar cortex. Among the basal ganglia, the thalamus and striatum alone show changes with fair regularity. In only one half of the cases does the globus pallidus seem to be involved with a rather mild type of injury which without exception is part of the widespread acute and heavy destruction in

adjacent areas as outlined above. In none of the cases did the globus pallidus exhibit a preferential position among the damaged areas while the severity of changes were always found to be of a rather light degree.

Quite a different situation is observed in the hypoxemic group of the first mentioned 9 cases. In these, the globus pallidus and corpus Luysi show by far the most severe and extensive neuronal loss (Figs. 23 - 25, 27, 33, 34, 36, 54, 55) while there are generally no lesions in the entire cerebral and cerebellar cortex. If they are found to be affected, it is of such a slight nature that a definite defect is not demonstrable in the terminal stage at all. In all cases except one, the Ammon's horn is involved with the same severe alterations (Fig. 38). A more distant area of nuclei is often affected, the nucleus dentatus, where a rather significant loss of nerve cells could be shown (in 5 out of 9 cases; Figs. 26, 32). In the globus pallidus and corpus Luysi the nerve cell population has in all cases been reduced to a fraction of the original number (Figs. 26, 41, 56). The medullated fibers have been diminished in various degrees, while in all cases a more or less dense fiber gliosis is demonstrable. These changes attain characteristic features because of the clear evidence of topistic signs in the extension of lesions and by the absolutely symmetrical pattern of involvement. Histologically there is no doubt but that we deal with progressive or terminal stages of selective neuronal necrosis as is evident from the findings in the relatively acute cases 25 and 27. Even though lesions are always constant in the globus pallidus and corpus Luysi, changes are also seen in other regions of the basal ganglia. In 6 out of 9 cases (cases 16, 18, 25 - 27) the thalamus is affected. In 8 cases the striatum shows some change which, however, is confined to nerve structures in only 4 incidences (cases 15, 18, 25, 26). The other 4 cases reveal fibrous astrocytes without definite evidence of neuronal defects. Finally, the inferior olive is affected in 3 incidences (cases 16, 17, 32), in 2 of which with simple gliosis. In one single case (case 16) is the substantia nigra involved.

The lesions in the thalamus and striatum - often exhibiting features of status marmoratus and thereby demonstrating a vascular pattern -

differ from those in globus pallidus, corpus Luysi, Ammon's horn, nucleus dentatus and inferior olives chiefly by secondary vascular reactions occurring from a certain degree of hypoxemia. The topistic combination "globus pallidus - corpus Luysi - Ammon's horn" characterizes the striking pattern of this topographical picture. It should be mentioned that this topographical type is not seen in the listed test cases only. This type (with the exception of the corpus Luysi) is also evident in the symmetrical involvement of the globus pallidus and Ammon's horn in other forms of acute hypoxia, especially in CO-poisoning. The picture presented in such cases differs not only by more severe tissue lesions but also by frequent and extensive involvement of cerebral and cerebellar cortex and white matter. In agreement with numerous cases reported in literature we have also found in our 3 cases of survived mine gas or CO poisoning, multiple foci of malacia or its residuals in the globus pallidus besides laminar changes, malacia or cystic lesions in the cerebral and cerebellar cortex as well as in the adjacent white matter. It seems that the entire circulatory system becomes more directly affected by not quite measurable concomitant conditions. That means, a general disturbance of the cardiac circulation exerts a retroaction upon the brain for which we have evidence from autopsy findings which disclose bleeding and hemorrhagic malacia. Therefore, we encounter an essential variation in the topography of lesions. The importance of speed in the development of acute severe hypoxemia with regard to the morphological aspect of brain lesions is known, also the analogous concurrence of symmetrical malacia in the globus pallidus in cases of acute secondary anemia. The complexity encountered in pathogenetic features of lighting gas poisoning becomes evident if one considers the cases with an apparent recovery of short duration and following rapid decerebration which manifest themselves in extensive and progressive disintegration of the white matter of the cerebral hemispheres (H.JACOB). Perhaps we deal here with secondarily developed pathogenetic features which presumably do not depend only upon the preceding hypoxemia but also upon other factors since they are not known to exist in ordinary cases of hypoxemia.

The uniformity with which the topographical pattern presents itself

in the cases of hypoxemic conditions of newborn could never be demonstrated in any of the other hypoxic cases. In particular the topistic type of changes seems to loose evidence with the development of malacia in the globus pallidus. This, indeed, does not absolutely apply to the focal softenings in the globus pallidus in so far as diffuse alterations over its entire territory could be demonstrated in our 3 cases with CO-poisoning (cases 36 - 38). These changes do not appear as marked neuronal loss but in the form of moderately diffuse fiber gliosis with progressive fibrous astrocytes. They are pronounced in the globus pallidus but not limited to it, for the white matter of the hemispheres and the neighboring grey nuclei are also involved although to a lesser degree.

In this connection exists a certain similarity with the topographical findings in case 24 which survived atmospheric hypoxidosis and showed foci of demyelination in the medial tip of the globus pallidus associated with diffuse gliosis of this ganglion. Also present are selective gliosis of the inferior olive and disseminated foci of fibrous astrocytes in the corpus striatum (Figs. 29 - 32). Even in 3 cases (29 - 31) of severe chronic anemia the globus pallidus shows a distinct tendency to develop gliosis. With a specific glia fiber stain, it is already visible to the naked eye (Fig. 50) and microscopically presents either an accumulation of pathological forms of fibrous astrocytes or isomorphous gliosis (Fig. 51). In addition to this, some cases disclose a specially intensive gliosis in the inferior olives and nuclei dentati. The corpus striatum often reveals fibrous astrocytes which are not found there ordinarily. The globus pallidus, however, is most consistently affected and with a particular degree of intensity. Of no importance is the acute disseminated cell necrosis in the globus pallidus of two supplementary cases with secondary anemia complicated by extensive thrombosis (42) and circulatory collapse. In these instances cell necrosis of the globus pallidus is considered part of the severe and very widespread cerebral damage and in comparison ranks secondarily. The same applies to alterations in the nucleus dentatus of the two above cases. Certain deviations in the pattern of manifestation along with a not clearly defined origin of the hypoxemic situation do not upset the basic features of polarity

encountered in topographical changes in circulatory and hypoxemic cerebral oxygen deficiency. Aside from similar findings in case reports in the literature, our 9 pediatric cases with a distinctly primary hypoxemic situation (asphyxia, progressive hemolytic anemia) reveal an established consistency in the morphologic pattern which cannot be considered incidental. The existence of a specific vulnerability of certain brain centers (globus pallidus, Ammon's horn, corpus Luysi, nucleus dentatus, inferior olives) is supported by the topistic type of findings in which the extension of a lesions is finally determined by architectonic structures.

Topistic Pattern of Anoxic Lesions.

The frequency of topistic tissue lesions in anoxia of the brain warrants a separate discussion (C. and O. VOGT). This type of lesion is confined to regions of uniform cyto-architectural build (thus imitating systemic diseases) or at least accentuating such features. The frequency with which they occur raises the question of a possible specific vulnerability of such topistic units to oxygen deficiency. Therefore, they become of significant practical importance in the determination of the oxygen deficiency pathogenesis of brain lesions from the aspect of morphologic pathology. Topistic brain lesions are, of course, not only found after states of oxygen deficiency. They also occur, for instance, in intoxications from quinine derivates (R.RICHTER 1949), but are then generally manifested in other nuclear regions. They do not depend, of course, on a general cerebral anoxia, but occur almost as often in regionally limited areas of cerebral ischemia following transient local circulatory disturbances. The attempt to explain such topistic phenomena by peculiarities in the vascularization of topistic units (UCHIMURA, HILLER etc.) cannot be considered successful. The apparent contradiction that a vascular conditioned lesion may exhibit the form of a systemic defect vanishes if one considers the size of the region of actual circulatory disturbance. These regions must be large enough to surround the topistic units either entirely or at least to an extent that gives the topistic lesions a chance to manifest itself (SCHOLZ 1952, 1957).

The following are the most frequently encountered topistic lesions which are demonstrable in our material of total cerebral oxygen deficiency: laminar changes in cerebral and cerebellar cortex; damages in certain cytoarchitectonic cortical regions, seen best in the Ammon's horn; neuronal loss limited to specific nuclear regions, i.g. globus pallidus, corpus Luysi, nucleus dentatus and inferior olives. It is understandable that such topistic patterns are confined to a limited degree of tissue damage. Within an extensive region of malacia, topistic patterns have no chance to manifest themselves at all. Nevertheless, one either encounters topistic malacia as laminar phenomena in the cerebral cortex or malacia in cytoarchitectural fields, i.g. in the area striata and the fields of the Ammon's horn. Also known is the preferential occurrence of focal damage or softening within topistic units, i.g. symmetrical lesions in the globus pallidus in CO-poisoning. Real topistic patterns can develop within larger areas of ischemia only if the degree of tissue lesion remains within the scope of selective neuronal necrosis. At times the topistic tendency is only recognized by the fact that small areas of nerve cell loss are arranged in form of rows in the 3rd cortical layer and that they eventually become confluent and exhibit the pattern of a continuous laminar lesion. Similar processes are also seen within the Sommer's sector of the Ammon's horn. As a rule, topistic patterns occur primarily as continuous laminar lesions in the cerebral cortex which can often be demonstrated in several gyri.

The topistic pattern is easily discerned in so-called laminar or field pallor (Ammon's horn) in recent and yet reactionless changes of sufficient intensity occurring in regions of rather densely packed nerve cells. In order to identify the topistic pattern in areas of loosely arranged nerve cells, as in the Purkinje cell layer or in the globus pallidus, more scrutiny is required. In such regions the fiber gliosis, which frequently develops, becomes in the late stages of the process a strikingly evident indicator for determining the extent of the damage present. The recognition of the topistic characteristics of tissue damage depends on the evidence of accentuation within the area of one or more topistic units. In the event of local circulatory damage it is not necessary that the units concerned be entirely af-

fect. This depends in each case on the extent to which the topistic unit was included in the area of circulatory disturbance.

The most convincing case of topistic damage is in the so-called holotopistic form. The criteria for this type of damage are lesions uniformly disseminated within the whole area of a topistic unit and their absence in the adjacent brain tissue. These criteria are fulfilled in our hypoxemic cases 15 - 18, 25 - 27, and 32, dealing with asphyxia neonatorum and erythroblastotic progressive anemia in which occur nerve cell loss, demyelination and succeeding gliosis in the globus pallidus. However, it is impossible to speak of topistic damage if certain architectonic units only share in severe overall cerebral damage without exhibiting a special intensification. In case of total cerebral anoxia another criterion has to be considered. This concerns the symmetry of topistic damage in both hemispheres of the brain and in the unpaired brain stem. It is relatively simple to prove symmetrical involvement in some of the areas, as in inferior olives. The same applies to distinctly circumscribed topistic units such as the basal ganglia and Ammon's horn. The demonstration of symmetrical involvement in laminar changes proves technically rather difficult if one aims at the localization of lesions in identical cortical regions. This would necessitate serial sections of both hemispheres. In our work-up, serial sections were only used to prove holotopistic damage in the inferior olives. With regard to the basal ganglia we have limited serial sections to the determination of identical affected areas in different frontal levels.

Topistic features are also apparent in connection with architectonic units that are spared within heavily damaged surroundings as is not unusual in the visual cortex. Such topistic features, however, are not explained by vulnerability but have the opposite character of a special resistance. Examples fulfilling all above mentioned criteria of a constant topistic pattern in anoxia are to be found in a number of our cases.

Prior to the discussion of pertinent data listed in table III we wish to draw attention to the fact that the statistical results in the section on topography of changes are only regarded as pointers to the

areas where topistic lesions may be found. A review shows that the most frequently affected Ammon's horn represents a region which, among all studied localities, reveals the highest tendency to develop topistic lesions. The strikingly high incidence of topistic affection of the globus pallidus, exceeding by far that of the cerebral and cerebellar cortex, is undoubtedly dependant upon the selection of material and in particular upon the inclusion of a relatively large number of hypoxemic cases. The insignificance of the thalamus may be ascribed to the not easily determined topistic nature of its lesions. It is believed that there are definite regional distinctions in the thalamus in regard to the acute changes of total cerebral ischemia. We were not fortunate enough, however, to be able to demonstrate them in certain nuclear areas. The scars that we have seen were all of focal character. According to table II, we find that the corpus striatum and thalamus are quite frequently and often in toto included in the acute brain damage of total cerebral ischemia. This should, however, not justify us to more than the assumption of a general tendency to become affected as is also true of the cerebral and cerebellar cortex. In hypoxemic states we have only seen focal glia scars (status marmoratus) or the development of a rather mild gliosis as general involvement of the entire striatum without evidence of neuronal loss. Since this general striatal gliosis often occurs simultaneously with elective gliosis of the inferior olives and nucleus dentatus - a cortical affection is missing as a rule - they must likewise be regarded as topistic phenomena.

The comparatively frequent involvement of the Ammon's horn warrants a study of the question as to whether there might be a vulnerability in its individual cytoarchitectonic fields. For this purpose we used VOGT's three main fields h_1 - h_3 (Sommer's sector; resistant band; end leaf and stratum granulosum of fascia dentata) which appear architecturally different even to the inexperienced observer. A comparison of the affected fields in the studied cases resulted in the belief that the variations in frequency of involvement are not as great as might be expected from the findings in epileptics. The field h_2 , claimed as resistant, was affected 12 times among 22 lesions while field h_1 was involved 19 times. Field h_3 , which is also involved in

convulsive lesions, ranks close to field h_1 . The least often damaged was the stratum granulosum of the fascia dentata which was affected in 7 cases only. It was entirely free of changes in 6 cases revealing complete atrophy of the fields $h_1 - h_3$. This absence of similarity in behavior becomes of special interest when related to hypoxemic and ischemic oxygen deficiency states. The degree of vulnerability remains in the same sequence: h_1 , h_3 , h_2 and stratum granulosum. However, the proportion changes. The most pronounced injury to the Ammon's horn and especially the involvement of the stratum granulosum is attributed to states of hypoxemia in 6 incidences.

The characteristic change in our cases of asphyxia and hemolytic anemia was the holotopistic type of lesion in the globus pallidus combined with the same kind of affection in the corpus Luysi. Our previous assumption (SCHOLZ 1941) that the structural alterations in the corpus Luysi in hypoxemia are only secondary to the damage in the globus pallidus, can no longer be sustained. We could demonstrate sudanophilic decomposition products of the same age in the corpus Luysi as in the globus pallidus as well as in the fiber systems which originate from the corpus Luysi (case 27 of our series, icterus neonatorum). Therefore, the changes in the corpus Luysi are the result of the same direct hypoxemic effect as elicited in the globus pallidus and Ammon's horn. This belief is supported by the finding of early nerve cell loss in the globus pallidus in case 25 of icterus neonatorum with a survival period of 3 1/2 weeks only. In the hypoxemic triad globus pallidus, corpus Luysi, the Ammon's horn is damaged relatively often (in 4 out of 9 cases). The nucleus dentatus sometimes joins in the pattern of topistic lesion (25 - 27, 32).

Attention must now be turned upon the fact that the reported, strikingly similar topistic findings in our cases have always been developed during early childhood. There is not a single case known to us which exhibited equally sharp topistic features originating later in life. It is true that a similar topistic tendency is generally encountered in CO-poisoning; we find it also in our 3 cases with symmetrically localized malacia in the globus pallidus as well as the less often occurring topistic manifestations in the Ammon's horn. However, one usually does not observe a clearly defined topistic combination. Consequently the question

is raised whether the brain of the newborn possesses a particular tendency to develop uncomplicated topistic lesions in spite of the known tolerance to oxygen deficiency. Such topistic lesions could possibly result from the low propensity to precipitate vascular reactions and disturbances in the cardiac circulation. Yet, focal changes are seen in the adjacent thalamus and striatum also in such cases (18 and 26). In our three cases of CO-poisoning in adults (36 - 39) we could prove that the focal lesions in the globus pallidus were accompanied by a diffusely discrete neuronal loss all over the nucleus or at least by a significant production of pathologic types of fiber forming astrocytes. Hence, one can recognize a holotopistic tendency in the pallidum also in cases of CO-poisoning in adults. A similar conclusion applies to a case of atmospheric hypoxidosis (24) with long survival period, in which there is a small area of demyelination with glia formation at the medial tip of the pallidum and abundant pathologic fibrous astrocytes within the whole nucleus. Striatum and inferior olives are also included in this topistic glia proliferation without convincing proof of any neuronal loss. In a comparison with three cases of severe chronic anemia (29 - 31) it is more difficult to separate definite topistic findings from a general fiber gliosis which was chiefly present in the white matter, since the gliosis was not accompanied by conclusive loss of nerve structures. It is of interest that the striatum contained a remarkable number of fibrous astrocytes which are normally not seen there. They were also present in the globus pallidus but in larger numbers. Such a type of striking fiber gliosis without neuronal loss was likewise demonstrable in the inferior olives in 5 cases of hypoxemia. These were two cases of asphyxia neonatorum (16, 17), one of survival from atmospheric hypoxidosis (24), one after CO-poisoning (37) and one of Fallot's heart malformation (32), in which case, however, an asphyxia neonatorum has to be drawn in consideration.

On the other hand, holotopistic nerve cell necroses in the olives could only be observed in cases of total cerebral ischemia. In the cases 4 - 6 with heart arrest of 20 or 10 min., the olives had lost almost all the nerve cells throughout their entire length, while the medulla oblongata was otherwise not affected. A topistic type of

partial loss of olive cells plays a certain role in cerebral circulatory pathology. According to H. JAKOB, who has studied the olives in cases of Wernicke's disease, the loss of their cells occurs by circulatory disturbances in the region of small olive arteries. The essential feature is the elective damage to the olives since other nerve structures, which lie within the area of disturbance, remain intact. Therefore, we have sufficient evidence to conclude that the inferior olives belong to those topistic units which are particularly vulnerable in hemodynamic oxygen deficiency. Included also in the frequent topistic findings of total cerebral ischemia are the changes in the third layer to a lesser extent, those in the fifth layer of the cerebral cortex and in the layer of Purkinje cells in the cerebellum.

A remarkable characteristic is the relative resistance of the cerebral and cerebellar cortex to hypoxemic conditions in infancy. They are, of course, affected with great regularity in the event of total ischemia. In our series of cases we have seen topistic patterns in the form of laminar lesions in the cerebral cortex in 7 out of 14 cases (3 - 7, 9, 12) and in the cerebellar cortex in 8 among 14 cases (3, 6 - 12). The globus pallidus and corpus Luysi, on the other hand, do not reveal any topistic changes whatsoever. Doubtful topistic damage to the nucleus dentatus along with numerous focal lesions in the cortex and white matter of the cerebellum have been recorded only once in cerebral ischemia (14). Topistic lesions in the fields of the Ammon's horn were seen in 10 among 14 cases of total cerebral ischemia. The same frequency of involvement was found in cases of primary hypoxemia in early infancy, namely, in 7 among 9 cases (15 - 18, 25 - 27). The distinction between the injuries in pathogenetically different oxygen deficiency is demonstrated by the fact that the Ammon's horn exhibits an additional topistic lesion under hypoxemic conditions, because of the involvement of the entire stratum granulosum in 6 out of 9 cases (15, 16, 18, 25 - 27), whereas the latter is entirely spared in all cases of total cerebral ischemia. We do not feel that the different types of oxygen deficiency should be regarded as the only reason if we take in account that we deal with brains of newborn in one instance and with those of adults in the other.

There are certain findings in the nucleus dentatus and inferior

olives which should be mentioned briefly. Only symmetrical structural loss and gliosis in nerve cell grey matter have so far been regarded as criteria for topistic changes. Even though the grey matter regions of these nuclei were found intact, it is not unusual to observe gliosis and symmetrical demyelination in their hilus and vllies. The origin can not be clarified at the present time. The presence of this gliosis might be interpreted as the result of an intensified activity of generalized gliosis in the surrounding tissues, for instance, the medulla oblongata. However, this does not always reflect the true situation as the partial demyelination shows.

We have already indicated that no attempt has been made to characterize the frequent changes in striatum and thalamus as topistic in nature. This would be comparatively easy in the striatum if one remembers its uniform architecture. In the thalamus the different nuclear regions must be considered individually - just as the architectonic fields of the cerebral cortex - and this would have required a technical work-up of unsurmountable difficulty. In cases which show a distinct dependence of the lesions on the vascular system, as status marmoratus in the thalamus and striatum, the question is obviously whether this preferential and exclusive localization may have a topistic significance. Such cases, however, were not included in the topistic patterns. This also applies to case 6 with heart arrest in which there was loss of only the small cells of the striatum but extensive damage to the entire brain. It was, however, our opinion that those cases should be drawn in consideration which revealed in all examined parts of the striatum symmetrical and equal distribution of pathologic forms of fiber forming glia cells - not normally found in the striatum - although there was no demonstrable neuronal loss. These conditions were fulfilled without exception in a series of cases of hypoxemic oxygen deficiency and are listed as follows: case 24 (survived atmospheric hypoxidosis); cases 29 - 31 (chronic anemia); case 32 (Fallot's tetrad); case 38 (survived CO-intoxication).

Thalamic lesions, because of their general dissemination in each single nucleus, could only be given consideration in two cases. In strangulation case 10 the damage to the thalamus should not be regarded as anything in particular in view of the extent of damage to the entire

grey matter of the brain. In case 39, with poisoning secondary to F 605 BAYER and a survival period of 1 1/2 years, a significant decrease in nerve cell population (in all examined frontal sections) was limited to symmetrical regions of the whole thalamus and unilaterally to one Ammon's horn. This might be regarded as a topistic pattern. However, the pathogenetic features were found to be rather complicated and objections could be made as to their correlation with oxygen deficiency even though a severe hypoxemia (respiratory arrest) was undoubtedly present. The general tendency of the thalamus to respond to any type of oxygen deficiency with neuronal loss may be concluded from the unusual frequency with which it is involved in corresponding brain lesions.

There is another topistic feature which should be discussed briefly. It is not characterized by an increased vulnerability, but by distinct resistance to oxygen deficiency. This topistic feature is encountered in large areas of regional circulatory disturbances of the brain secondary to a series of convulsions where one field of the cerebral cortex is repeatedly excluded from involvement, namely the visual cortex which lies surrounded by severely damaged tissue. This, in general, corresponds to the peculiarities encountered in the previously discussed subject which dealt with sparing of the stratum granulosum in an otherwise totally damaged Ammon's horn. The visual cortex was found to be relatively intact in only two cases of hemodynamic oxygen deficiency, namely in case 3 with heart arrest and in case 7 which dealt with strangulation. We believe that this resistance might be explained by the better venous drainage in the internal cerebral veins. In case of general cerebral circulatory arrest, however, this does not seem to be a very convincing argument. The distinct limitation of these processes to cytoarchitectonic units constitutes a factor which always characterizes them as being dependent on neuronal elements and thus must be interpreted as a genuine topistic feature.

Clinical Aspects.

The clinical evaluation of the anatomically studied material proves to be rather limited since we did not see any of the patients during their lifetime and thus, we had to depend exclusively on incomplete reports in clinical records. However, it seems possible to identify general

clinical findings in the groups of total cerebral ischemia and infantile hypoxemia. They can be distinguished from each other in the same manner as the anatomical findings can be differentiated. In total cerebral ischemia there was clinically no basic difference encountered in the nervous symptoms secondary to heart arrest or to strangulation. In only 2 out of 6 cases did heart arrest occur during inhalation narcosis (3, 4). In a third case, respiratory arrest was followed by heart arrest 8 min. after injection of novocain-suprarenin solution into the deep neck muscles. The clinical course and the intensity and extent of brain lesions in cases with survival rates ranging from 15 hrs. to 4 days did not present convincing distinctions compared with cases of heart arrest of different etiology. In two cases a sudden circulatory collapse had caused the heart arrest (1 and 2). In another case a preceding strangulation was reported as cause of the heart standstill (6). In cases dealing with heart arrest, the shortest survival periods after circulatory collapse were 5 and 18 hrs. The survival periods after heart arrest due to narcosis ranged half way between 15 hrs. and 6 days. Case 1 with the shortest period - a few minutes only - of heart arrest (in circulatory collapse) showed the shortest survival time of only 5 hrs. The nerve cell changes in this case, even though not clearly demonstrable, were, contrary to all other cases, limited to the cerebral cortex and Ammon's horn. The most serious condition was seen in a case (2) of apparent death, in which there was simultaneous circulatory collapse and heart arrest followed by hypothermia of 20° C. In this case it is especially interesting to note that the vegetative nuclei of the diencephalon, found in all other studies to be very resistant to damage, were affected by extensive decomposition of their nerve cells. Also involved were the nerve cells of the substantia reticularis in the otherwise well preserved medulla oblongata. Recurrence of heart function was not followed by a return of consciousness in any of the studied cases of heart arrest. There were numerous attacks of general convulsions in two cases (3, 6). In one case (5) a transient decerebrate rigidity was observed. In these last three cases, cardiac arrest was preceded by respiratory arrest which, however, was not clearly incriminated in regard to either the clinical nor histologic picture.

Of 8 cases of strangulation, profound unconsciousness cleared up in two incidences with survival periods of 2 1/2 and 7 days (11, 13); full consciousness was, however, not regained. In one of the cases the strangulation time was reported to be 15 min. In 5 of 6 cases more detailed data was available concerning neurologic findings. The following was observed: primarily, a general muscular rigidity was seen, associated partly with spastic reflexes and partly with absent reflexes. This condition returned to normal after a survival period of 24 hrs. (7 - 11). The mentioned symptoms were also encountered in one case with only 4 - 5 min. of strangulation and 18 hrs. of survival (7). Both the strangulation time and survival period were the shortest ones reported.

The decerebrate rigidity, in all cases of total ischemia, is consistent with the anatomical findings of a rather extensive destruction of nerve cells in the cerebral cortex. Concerning the basal ganglia, the thalamus is almost regularly involved with severe nerve cell loss (2 - 14). The striatum is less often affected and, as a rule, exhibits less intensive nerve cell loss (2 - 6, 8 - 10, 12, 14). The severity and extent of anatomical changes fulfill all the postulates necessary to explain the development of a cortical symptomatology rather than an extrapyramidal one. The tendency of the decerebrate rigidity to return to normal causes us to believe that its development should not be explained by morphologic features alone, despite the presence of severe histologic changes. No correlation can be established as to the sequence of events with regard to the formation of cerebral edema and swelling that was often fully developed at a time, when the decerebrate rigidity was in regression.

In contrast to total cerebral ischemia which is characterized by a rapid development of symptoms and their regression, a less stormy onset of cerebral symptomatology is found in a series of cases with critical hypoxemia of other etiology. Thus a distinct progressive development is often seen in perinatal forms of critical hypoxemia while complete unconsciousness did not often occur. With regard to asphyxia neonatorum, only such cases of hypoxemia are considered, in which there was no apparent death following circulatory arrest. In

most of these cases definite cyanosis was observed. The brain lesions, the neurologic symptomatology and the course of disease in the different types of asphyxia may be compared to those in progressive severe anemia in icterus neonatorum. In both groups the pathogenetic primary situation is hypoxemia. In contrast to the decerebrate rigidity in total cerebral ischemia severe hypoxemia of the newborn presents the following symptoms: apathy and sleepiness succeeded by more marked drowsiness and loss of consciousness; striking extrapyramidal symptomatology as opisthotonus, muscular rigidity, athetosis and spasmus mobilis. A retarded development of posture and movement as in status marmoratus becomes evident in later stages of infantile growth. There is as yet no answer to the question whether, in case of sufficiently long survival, the impression of dementia is evoked and intensified by loss of extrapyramidal functions (deficient automatism of originally voluntary functions), especially if the development of speech is also hampered. There is a retarded development of speech which can neither be regarded as a restriction of speech from chorea or athetosis, nor as a motor-aphasia because of the lack of corresponding cortical findings. Such retarded development of speech was present in at least 2 out of 4 cases of perinatal hypoxemia, which had reached an adequate age (18, 28). Also to this category belongs case 32 (Fallot's tetrad, asphyxia at birth) and possibly case 29 which presented a most severe chronic anemia from early childhood associated with symmetrical gliosis in the globus pallidus. In two other cases of asphyxia neonatorum (16, 17) the generalized athetosis is believed to play an essential role in the severe disturbance of speech.

In all cases of hypoxemia of the newborn, the anatomical findings are confined to the basal ganglia by exclusive localization of definite neuronal loss with subsequent gliosis. In each of these cases the globus pallidus and corpus Luysi demonstrate holotopistic changes. Also not infrequently affected are the thalamus and striatum with focal losses manifested, for instance, as status marmoratus. In none of the cases were there cortical lesions which would convincingly explain the retarded development of speech by focal aphasia or by a high degree of dementia. In this connection we wish to draw attention to some interesting observations concerning the almost regular formation of distinctly diffuse fiber gliosis in the white matter of cerebral and cere-

bellar hemispheres without corresponding loss of myelinated nerve fibers. This was reported by A. MEYER (1937) as a frequent finding in mental defectives. Such fiber gliosis could not be adequately explained as a secondary effect of a loss of cortical nerve cells in our cases and in those reported by A. MEYER. The same comes true for the enormous gliosis seen in regions of the ventricular walls and basal cerebral surfaces including the tractus opticus. This type of gliosis is not believed to be of great importance for the manifestation of mental defects because it is pronounced in each one of two cases with panmyelophthisis and pernicious anemia (30, 31) with no indication of related psychic disturbances. Gliosis was also present to a moderate extent in one case of survived atmospheric hypoxidosis (24) associated with changes in the pallidum and thalamus. In this case certain alterations in personality and episodically occurring difficulties in speech were also encountered.

A brief discussion of case 32 is warranted since it demonstrates retarded body and mental development, mild extrapyramidal symptoms and brain lesions which are typical of perinatal hypoxemia. These lesions were holotopistic changes in corpus pallidum, corpus Luysi and nucleus dentatus as well as gliosis of white substance and were previously believed due to chronic hypoxemia following congenital malformation of heart (Fallot's tetrad; SCHOLZ 1941). As we are lacking confirmation of this concept from corresponding observations in our other cases (33 - 35), we accept the opinion of ERBSLÖH that these characteristic findings are developed at time of birth. Despite the easy delivery, this newborn (32) was cyanotic at birth. Thus one has to consider the possibility that the uterine adaptation was decompensated at the onset of respiration causing the cerebral effect of severe hypoxemia.

We are aware of the fact that the neurologic symptomatology of the newborn cannot be compared, in each respect, with that of adults, since the cerebral cortex of the newborn does not exert any influence upon the other parts of the CNS. Thus prerequisites for some symptoms are not yet present. The delayed appearance of oxygen deficiency in icterus neonatorum and also the repeated attacks of asphyxia in the newborn help to explain the fact that clinical symptoms and anatomical

lesions do not immediately occur in full severity, in contrast to cases of total cerebral ischemia. There is in the early stage a certain progression of the clinical and pathoanatomical process and understandably a life endangering situation is not created as is encountered in total cerebral ischemia with its subsequent development of extensive cerebral damage. The latter is seldom compatible with a prolonged period of survival. According to H. JACOB (1957), an all-or-nothing rule seems to be the essential feature in all cases of strangulation. At any rate, there are only a few known cases which combine a long survival time with extensive cerebral damage. It is remarkable that one of our cases of asphyxia (17; birth in amniotic sac) reached the age of 37 years, and revealed a progression of severe extrapyramidal symptomatology even during the last years of life. However, there were no signs of a progressive cerebral process.

The permanent clinical sequelae encountered in adults in our cases of severe acute hypoxemia can hardly be compared with the sequelae in the newborn. The symptomatology in cases of survived CO-poisoning markedly deviates from that encountered in the above cases as can be understood from the severity, extent and topography of the cerebral changes. In two cases which survived hypoxemia for many years, no neurologic symptomatology was found at all, although there were quite extensive brain lesions in both cerebral and cerebellar hemispheres and in symmetrical areas of the globus pallidus. One of these cases ran the course of schizophrenia (37) and the other one presented an organic dementia associated with schizophrenic features (36). In case 24 with less pronounced brain lesions from atmospheric hypoxidosis (gliosis of hemispheres and small lesion in the globus pallidus) were observed personality changes, but aside from episodes of aphasia and several epileptic seizures no significant neurological symptoms. Similar findings were present in case 39 which revealed very severe respiratory embarrassment in the acute stage of poisoning (E 605), (edema of the lungs, Cheyne-Stokes syndrome, respiratory arrest with very severe cyanosis). These were followed by spastic and ataxic symptoms, also finally by personality changes (spontaneity, affective incontinentia, puerilism). In this case were observed a marked degree of gliosis and minimal loss of myelinated fibers in the white matter and significant diminution of nerve cells in both thalami, whereas the globus pallidus was found to be affected

by rather marked vascular calcification.

In case 29 (a child) of the series of cases with severe chronic anemia, was seen a significant retardation of physical and mental development. The associated, apparently pronounced dementia may, however, be correlated with a light degree of gyral malformation. It remains uncertain as to how much one should attribute the incomplete development of motor activity (inability to walk) to the rather significant focal loss in the thalamus and the presence of diffuse gliosis. There were no neurologic findings in case 30 in which the onset of anemia occurred at age of 6 years, despite the demonstrably more extensive and intense diffuse gliosis. The medical records of case 31 were lost during the war which is indeed a pity, because in this case of pernicious anemia we observed the highest degree of generalized gliosis in a pronounced symmetrical involvement of the globus pallidus and corpus striatum. Since this patient was cared for on the medical ward and since there was no evidence of spinal cord lesions at any time, it is assumed that no prolonged psychic anomalies or gross neurologic findings were present during the entire course of illness. During the last phase of this patient's life, multiple small foci of perivascular demyelination associated with a nodular glial reaction developed in the brain, independently of the above mentioned fiber gliosis, but without correlation to fresh anoxic lesions in connection with calcified vessels in the globus pallidus.

Effective adaptation mechanisms seem to play a role in cases of chronic hypoxemia due to malformation of heart and in cases of severe chronic anemia. There was no significant loss of nerve structures due to oxygen deficiency in cases with perfect development of the brain; hence, we are lacking an absolute symptomatology referable to the CNS. As can be understood, the equilibrium of function is rather unstable and there are greater potentialities for decompensation. The regularity with which one observed quite extensive diffuse gliosis in the aforementioned cases, as well as in cases of acute hypoxemia, should encourage us to study even minimal deviations from normal nervous functions, which may be precipitated by chronic oxygen deficiency or decompensation.

Tab. I

Autopsy Findings and Histology

No.	Name	Age	Pathogen.	Situat.	Dura- tion	Sur- vival	Cranial press.	Congest.	Hemorrhag.	Edema	Anemia	Sel.neur.necros.	Softening	Neuronophagy	Macroglia	Fibr. glia	Mesenchym.react.	Sudanophil.prod.	White matter	Complication
1	Schre	36y	Cardiac arrest		5 mi?	5 h	-	+	-	-	-	+	-	-	-	-	-	-	-	-
2	Pauk	33y	"	"	20 mi	8 "	+	+	-	-	-	+	+	-	-	-	-	-	+	-
3	Ko	60y	"	"	10-15mi	15 "	?	+	-	-	-	+	+	-	-	-	-	-	+	-
4	Lar	53y	"	"	20 mi	4 d	-	-	-	-	-	+	+	+	+	?	+	+	-	-
5	Ba	42y	"	"	25 "	6 "	-	+	+	-	-	+	-	+	+	+	-	+	+	-
6	Dyr	13mo	"	"	10 "	9 "	-	+	+	-	-	+	+	+	+	+	-	+	-	-
7	Höl	56y	Strangulation		4-5mi	18 h	-	+	-	-	-	+	-	+	-	-	-	-	-	-
8	Küch	37y	"	"	?	18 h	-	+	-	-	-	+	?	-	-	-	-	-	-	-
9	Hem	22y	"	"	?	35 "	+	+	-	-	-	+	-	+	-	-	-	-	-	-
10	Rau	28y	"	"	?	46 "	-	+	-	-	-	+	-	+	+	-	-	-	-	-
11	Krö	36y	"	"	15 mi	64 "	+	+	-	-	-	+	-	+	+	?	-	-	-	-
12	Lei	40y	"	"	?	3 d	-	+	-	-	-	+	+	+	+	-	+	+	+	-
13	Fed	63y	"	"	?	7 "	+	-	-	-	-	+	+	+	+	+	+	+	+	arteriosclerot.softenings
14	Bre	13mo	"	"	?	8 "	+	+	-	-	-	+	+	+	+	+	+	+	+	-
15	Mol	13mo	Asphyxia at birth		-	-	-	-	-	-	-	+	-	-	+	+	-	-	-	gl
16	Wes	12y	"	"	-	-	-	-	-	-	-	+	-	-	+	+	-	-	-	gl
17	Stro	37y	"	"	-	-	-	-	-	-	-	+	-	-	+	+	-	-	-	gl
18	Kel	66y	"	"	-	-	-	-	-	-	-	+	-	-	+	+	-	-	-	gl

No. Name	Age	Pathogen. Situat.	Dura- tion	Sur- vival	Cranial press.	Congest.	Hemorrhag.	Edema	Anemia	Sel. neur. necros.	Softening	Neuronophagy	Macroglia	Fibr. glia	Mesenchym. react.	Sudanophil. prod.	White matter	Complication
19	Gro	9mo	Dyspnea, cyanosis	sev. d 7 d	-	+	-	+	-	+	-	-	-	-	-	-	-	-
20	Mich	3ly	Respir. arrest after inject	19 h 19 h	-	+	+	-	-	+	+	-	-	-	-	-	-	Embolism
21	Bro I	2mo	Myatonia congen., respir. failure	sev. d -	-	-	-	-	-	-	-	-	-	-	-	-	-	-
22	Bro II	3mo	" "	" "	-	-	-	-	-	-	-	-	-	-	-	-	-	-
23	Lind	28y	Atmospher. hypoxidos.	2 h?	-	-	-	-	+	-	-	-	-	-	-	-	-	-
24	Sun	59y	" "	? h 16 y	-	-	-	-	-	+	-	-	+	+	-	-	gl	-
25	Mit	3 1/2w	Hemolyt. icterus	- 3 1/2w	-	-	-	-	-	+	-	+	+	+	-	+	gl	No icter. discoloration
26	Roe	5 1/2mo	" "	sev. d. 5 1/2mo	-	-	-	-	-	+	-	-	+	+	-	-	gl	-
27	Büt	11mo	" "	sev. d. 11 mo	-	-	-	-	-	+	-	-	+	+	-	+	gl	-
28	Pet	8y	" "	3 w 8 y	-	-	-	-	-	+	-	-	+	+	-	-	gl	-
29	Müh	6 1/2y	Severe anemia	6 y 6 "	-	-	-	-	-	+	-	-	+	+	-	-	gl	-
30	Schlehm	7y	Pann., elophtisis	1 y 1 "	-	-	-	-	+	-	-	-	+	+	-	-	gl	-
31	Hub	71y	Pernic. Anemia	sev. y. -	-	-	+	-	+	+	-	-	+	+	-	-	gl	Demyelinat. No comb. degen.
32	Her	18y	Malformat. of heart	18 y -	-	+	-	-	-	+	-	-	+	+	-	-	gl	Birth asphyxia, purul. enceph.
33	Ren	4 1/2y	" "	4 1/2y -	-	+	+	+	-	-?	+	-	+	+	+	-	gl	Purul. meningitis
34	Perg	15w	" "	15 w -	+	+	-	+	-	-?	-	-	+	+	-	-	gl	-

old

No. Name	Age	Pathogen. Situat.	Dura-tion	Sur-vival	Cranial press.	Congest.	Hemorrhag.	Edema	Anemia	Sel.neur.necros.	Softening	Neuronophagy	Macroglia	Fibr. glia	Mesenchym.react.	Sudanophil.prod.	White matter	Complication
35	Schu 4	1/2mo Malformat.of heart	4 1/2mo	-	-	+	-	-	-	-?	-	-	+	?	-	-	?	
36	Eh	56y Mine gas poisoning	?	32 y	-	-	-	-	-	+	+	-	+	+	+	-	gl	Cyst format.,demyelinat. cortical scars
37	E1	53" " "	hours	23 "	-	-	-	-	-	+	+	-	+	+	+	-	gl	Cyst format.,demyelinat. cortical scars
38	Jor	42" Lighting gas poison.	7 h 3	1/2mo	-	+	+	+	-	+	+	-	+	+	+	+	gl	
39	Bles	20" Poison.with E 605, severe anoxia	24 "	2 y	-	-	-	-	-	+	-	-	+	+	-	-	gl	
40	Gral	20" " "	-	15- 20 h	+	-	-	+	-	-	-	-	-	-	-	-	gl	Birth trauma, epilepsy, Ammon's horn sclerosis
41	Jün	23" Injured pulmon.vein	-	2 d	-	-	-	-	-	+	-	+	-	-	-	-	-	
42	Lan	49" Arter.& ven.thrombos.-	-	1 "	-	-	-	+	+	+	+	-	-	-	-	-	-	
43	Zweck	48" Circul.collapse post operat.	-	18 h	-	+	+	+	-	+	+	-	-	-	-	-	-	

+ = definite neuronal lesion or loss

gl = gliosis without related neuronal loss

? = dubious finding

Tab. II

Topography and Severity of Lesions

No.	Cerebral cortex	Ammon's horn	Thalamus	Striatum	Globus pallid.	Corpus Luysi	Nigra substance	Cerebellar cortex	Dentate nucleus	Pons	Medulla oblongat.	Inferior olives	Hemisph. white matter	Periventric.& basal gliosis	Bilateral	Symmetrical
1	+	2+	-	-	-	-	-	-	-	-	-	-	-	-	+	-
2	4+	4+	+	3+	+	+	-	2+	4+	-	-	-	ed	-	+	-
3	4+	∅	2+	3+	3+	∅	∅	3+	-	-	-	-	ed	-	+	-
4	4+	4+	4+	3+	2+	-	2+	4+	+	-	-	4+	ed	-	+	+
5	3+	4+	4+	3+	-	-	-	3+	+	-	-	-	ed	-	+	-
6	4+	4+	3+	3+	+	-	-	+	-	-	-	4+	gl	-	+	+
7	3+	3+	2+	-	-	-	-	2+	-	-	-	-	-	-	+	-
8	4+	3+	2+	2+	+	-	-	3+	-	-	-	3+	-	-	+	+
9	3+	3+	3+	+	-	-	+	2+	-	-	-	-	-	-	+	-
10	2+	3+	3+	2+	+	-	-	2+	-	-	-	+	-	-	+	-
11	2+	3+	3+	-	-	-	-	2+	-	-	-	-	-	-	+	-
12	4+	2+	3+	+	-	-	-	3+	-	-	-	-	ed	-	+	-
13	+	+	2+	-	-	-	-	-	-	-	-	-	ed	-	+	-
14	3+	2+	+	+	+	-	-	2+	+	-	-	-	4+	-	+	-
15	-	3+	-	+	3+	3+	-	-	-	-	-	-	gl	gl	+	+
16	-	2+	+	gl	3+	3+	+	-	gl	gl	gl	2gl	gl	2gl	+	+
17	-	2+	-	gl	3+	3+	-	-	-	gl	gl	2gl	gl	2gl	+	+
18	-	3+	2+	2+	3+	3+	-	-	-	-	-	-	gl	gl	+	+
19	+	+	-	-	-	-	-	-	-	-	-	-	ed	-	+	-
20	4+	3+	-	-	-	-	-	-	-	-	-	-	ed	-	+	-
23	-	-	+	+	-	-	-	-	-	-	-	-	-	-	-	-
24	-	-	+	gl	2gl*	gl	-	-	-	-	gl	2gl	gl	gl	+	+
25	-	3+	+	+	3+	3+	-	-	2+	-	gl	-	gl	-	+	+
26	-	3+	+	+	3+	3+	-	-	2+	-	gl	-	gl	2gl	+	+
27	-	3+	+	gl	3+	3+	-	-	+	-	+	-	gl	gl	+	+
28	-	-	-	-	2+	+	-	-	-	-	-	-	-	-	+	+
29	-	-	+	gl	gl	gl	-	-	-	-	-	-	gl	2gl	+	+
30	-	-	gl	2gl	3gl	-	-	-	2gl*	gl	2gl	2gl*	2gl	3gl	+	+

No.	Cerebral cortex	Ammon's horn	Thalamus	Striatum	Globus pallid.	Corpus Luysi	Nigra substance	Cerebellar cortex	Dentate nucleus	Pons	Medulla oblongat.	Inferior olives	Hemisph. white matter	Periventric. & basal gliosis	Bilateral	Symmetrical
31	2gl	gl	2gl	2gl	2gl	2gl	gl	gl	2gl*	gl	gl	2gl*	2gl	2gl	+	+
32	-	-	+	gl	3+	3+	-	-	2+	gl	2gl	2gl*	gl	2gl	+	+
33	3+	-	+	-	-	-	-	+	-	-	-	-	(3+)	-	+	-
34	+?	-	-	-	gl	-	-	+?	-	-	-	-	+?	gl	+	-
35	-	-	-	-	-	-	-	+?	+?	-	-	-	-	-	+	-
36	3+	3+	+	+	3+	+	-	3+	-	-	-	-	2gl	gl	+	+
37	4+	2+	-	-	3+	-	-	2+	-	-	-	gl	2+	2gl	+	+
38	3+	-	+	-	2+	-	-	-	-	-	-	-	3+	2gl	+	+
39	-	3+	3+	-	-	-	-	-	-	-	-	-	gl	gl	+	+
40	2+	(+)	-	-	2+	-	-	-	-	-	-	-	ed	-	+	-
41	3+	2+	2+	2+	-	-	-	2+	-	-	-	-	-	-	+	-
42	4+	3+	3+	+	+	+	+	+	+	+	+	+	+	-	+	-
43	4+	+	2+	+	+	-	-	+	-	-	-	-	2+	-	+	-

+ = definite neuronal lesion or loss

2 - 4 = intensity of lesions

gl = gliosis without related neuronal loss

gl* = gliosis with thinning of myelinated structures

ed = edema

? = dubious finding

() = preexistent lesion

∅ = not available

Tab. III
Topistic Patterns

No.	Cerebral cortic. laminae	Cerebellar cortic. laminae	Fields of the Ammon's horn			Stratum granul.	Striatum	Globus pallid.	Corpus Luysi	Nigra substance	Dentate nucleus	Inferior olives
			h ₁	h ₂	h ₃							
3	+	+										
4	+	+	+	+	+							+ho
5	+	+	+	+	+							
6	+	+	+	+	+							+ho
7	+	+	+		+							
8		+	+	+	+							
9	+	+	+	+	+							
10		+	+	+	+							
11		+	+		+							
12	+	+	+		+							
14			+	+								
15			+	+	+	+		+ho	+ho			
16					+	+		+ho	+ho	gl	gl	gl
17			+	+				+ho	+ho			gl
18			+	+	+	+	sm	+ho	+ho			
24							gl	gl*				gl
25			+	+	+	+		+ho	+ho		+ho	
26			+		+	+		+ho	+ho			
27			+	+	+	+		+ho	+ho		+	
28								+ho				
29							gl	gl				
30							gl	gl				
31	gl				gl		gl	gl				

No.	Cerebral cortic. laminae	Cerebellar cortic. laminae	Fields of the Ammon's horn	Stratum granul.	Striatum	Globus pallid.	Corpus Luysi	Nigra substance	Dentate nucleus	Inferior olives
			h ₁ h ₂ h ₃							
32					gl	+ho	+ho		+ho	gl*
36						+				
37	+		+			+				gl
38					gl	+				
41	+	+	+							

ho = holotopistic lesions

gl = gliosis without related neuronal loss

gl* = gliosis with thinning of myelinated structures

sm = status marmoratus

Discussion.

The chief interest in regard to the pathology of cerebral oxygen deficiency is naturally focused upon changes in nerve cells. They all develop a number of minor nonspecific changes upon approach of a critical threshold of oxygen deficiency. If the critical threshold is exceeded all of the nerve cells develop necrosis of various types. Under excellent experimental conditions a fairly reliable correlation of the different changes with the degree of oxygen deficiency and its duration is possible. Since the excellent conditions of experiments are rarely encountered in man, one necessarily has to rely upon the presence of tissue changes to prove antecedent critical oxygen deficiency. Among all the possible types of necrosis are the ischemic nerve cell changes, described by SPIELMEYER in 1922. They occur also in the form of a homogenizing necrosis, particularly in Purkinje and olivary cells. The relationship of ischemic nerve cells to oxygen deficiency has been recognized by their presence within acute focal lesion of vascular origin where they are demonstrated with great regularity in different phases. The principal features encountered are a shrunken dark or chromatin poor nucleus which undergoes a structural decomposition and shows an irregular contour. The plasma is almost completely refractory to staining with basic aniline dyes. It stains with eosin instead and shows moreover an altered refraction to light. In either a slight swelling or a shrinkage of the nerve cell the contour remains usually intact. This type of necrosis constitutes the prevailing phenomenon that is seen many thousand times in acute circulatory damage. Such a regularity makes it possible to interpret the change as a pathologic process in general cerebral oxygen deficiency. Also the relationship is well known and acknowledged in neuropathology.

The specificity inherent in ischemic nerve cell necrosis is not absolute. It may be replaced by other types of dissolution or it may occur with other forms of necrosis as has been determined many years ago (NEUBÜRGER 1925, BODECHTEL 1930). However, the observations of KROGH (1952), who investigated the ischemic spinal cord of rabbits, fail to meet the subject. Nevertheless, oxygen deficiency may be re-

garded as the cause of ischemic type of necrosis whenever found, whether as selective neuronal necrosis or malacia (A. MEYER 1958, KÖRNYEY 1955, SCHOLZ 1957, among others). No reports have come to our attention, which claim that this type of nerve cell necrosis appears in other disease processes.

It cannot be denied that such a nerve cell change may, as an exception, of course, develop in a cadaver as has been pointed out by CAMERER (1943). We ourselves had an opportunity to see a case with the typical picture and plasma eosinophilia in a healthy male individual who was killed in an accident during winter and the body exhumed 4 weeks later. But this picture differs remarkably in its topography from pathologic cases, since the same changes were found in all the nerve cells from the cortex down to the spinal cord.

In the present studies we have drawn attention to the importance of this type of necrosis since it is considered an unequivocal indicator of the action of antecedent hypoxia. We have observed this necrosis in typical form in 11 incidences among 14 cases of total cerebral ischemia (cardiac arrest and strangulation). This necrosis was atypical in one case and sporadic among numerous other types of disintegration in a second. In another case, the duration of ischemia and manifestation time were too short to produce cell necrosis.

The reported time needed for complete development of such necrosis varies in the literature. Swelling has been described after 1 - 2 hrs. of survival (MÜLLER 1930, WINDLE et al. 1944). Distinct characteristics of ischemic necrosis were found by NEUBÜRGER (1928) after a period of 2 - 3 hrs. MÜLLER (1930) believes that the average time for the production of typical forms is 14 - 15 hrs. It is assumed, however, that a much shorter period would suffice for survival.

An outstanding observation is reported by H. JACOB (1951) who demonstrated typical ischemic nerve cells in the Ammon's horn of hanged individuals who died during strangulation. In one of our cases (1) with a relatively short duration of heart arrest, 5 min., there were no typical changes seen after a lapse of 5 hrs. However, in a heart arrest of 20 min. duration followed by a survival time of 8 hrs., an inverse ratio existed between the duration of oxygen deficiency and

the duration of manifestation time also possibly the type of manifestation. In this case, acute types of liquefaction were prevalent. It is possible that the autolytic processes in the cell, particularly in severe anoxic tissue damage, cause nonspecific types of liquefaction. In such cases no neuronophagia can develop because of damage to glia. They occur in elective parenchymal necrosis only. In this connection we wish to draw attention to the fact that the ischemic type necrosis remains demonstrable in the tissues for rather long periods of time, presumably due to coagulation of cell plasma. In the form of calcification it may persist for years (case 28).

The question is raised whether nerve cells have a potentiality to survive after only one injury from oxygen deficiency with subsequent changes. From the morphologic standpoint the all-or-nothing rule is followed. However, in the peripheral areas of old circulatory scars or in old diffuse pallidum hypoxemic lesions one encounters nerve cells which appear atrophied because of a demonstrable reduction of plasmatic and nuclear volume. I have called them secondary "Kümmersformen" (nerve cells of reduced size, SCHOLTZ, 1957). They play a secondary role among the different types of oxygen deficiency changes and are pathogenetically of no great importance. Perhaps some of the findings of WINDLE, BECKER and WEIL (1944), which deal with observations on asphyxiated guinea-pig embryos, become understandable if the above interpretation is given consideration. The authors report cortical atrophy without significant glia reaction after 8 and a half days and complete volume reduction of the brain without disturbance of body growth after 6 weeks.

The degree of damage in a recent anoxic tissue still without reaction is estimated by the number of nerve cells affected. The mildest type is found in disseminated selective neuronal necrosis (case 10). This is followed by selective necrosis of all nerve cells within a certain area (case 7). In such conditions all categories of glia cells may be found intact. The oligoglia, however, frequently show nuclear pyknosis and plasmatic swelling. Only when the astroglia begin to manifest distinct signs of regression or decomposition (nuclear pyknosis, clasmatodendrosis; case 2), can one expect the tissues to undergo at least a partial softening, the organization of which is partly ac-

complished by mesenchymal structures (Fig. 3). The infarction type of softening and total necrosis of tissues, which in cases of general oxygen deficiency have to be considered as a secondary circulatory effect, are detected after a period of 18 - 24 hrs. by the edematous lines of demarcation (Figs. 63, 64). At this time one also encounters the first glial reaction in selective neuronal necrosis. In approximate agreement with MÜLLER (1930) who reported the first signs of microglial reaction after a lapse of 22 hrs., we observed the onset of neuronophagocytic reaction at 18 hrs. in one case of strangulation, with a hanging time of 4 - 5 min. (case 7). As described in the chapter of "Histologic Findings in the Brain Changes", the onset of neuronophagocytic processes is limited and falls within a certain time interval (about 48 hrs.), being the longest period observed. However, ischemic nerve cells were not being removed after 64 hrs. (case 11) nor even 9 days (case 6). We are inclined to believe that such differences in the reaction of microglia are caused by an associated anoxic damage (inhibition) which is not morphologically traceable. On the other hand, the ischemic nerve cell seems to offer a material (plasma coagulation) which is not easily absorbed and exerts only a moderate stimulation upon the microglia. This may be concluded also from the small number of microglia cells involved. A temporary proliferation of microglia without phagocytic action, seen in inflammatory processes, and interpreted by WINDLE et al. (1944) as a false alarm, could never be demonstrated by us in cases of hypoxemia.

At this degree of necrosis, progressive forms of the astroglia range behind the reaction of the microglia. Only sparse data are available in the literature, concerning the glia in this respect. MÜLLER observed an increase of glia fibers in the cerebellar cortex after a period of 16 days. We have seen a demonstrable increase of plasma and nuclear volume after 64 hrs. (case 11). A questionable progression of fiber forming astrocytes was observed after 4 days (case 4); a definite one after 6 days (case 5). New formation of fiber forming astrocytes was evident in a 13-months-old child after a period of 9 days (case 6). In that case there was also a growth of plasmatic astrocytes containing chromatin rich nuclei and voluminous plasma.

The transformation of metabolites into sudanophilic substances in cases of softening is well known but little dependable knowledge is available in regard to selective neuronal necrosis in connection with hypoxic states of the brain. It seems that the disintegration of nerve cells alone causes the production of only small amounts of sudanophilic substances. A mobile "Abbau", namely a significant formation of fat granular cells is infrequently encountered, even if all nerve cells in a certain region disintegrate. This is clearly indicated in 9-day-old cortical lesions in one of our cases (case 6). In sufficiently advanced cases are found fat droplets in neuronophagocytic microglia cells or within the substituting, diffuse proliferation of rod cells. SAGEL (1921) has illustrated fat droplets in glia shrubs of the cerebellar cortex, and SCHOLZ (1951) within a diffuse rod cell proliferation in the Ammon's horn. Later, resorption seems to proceed rather slowly and there is doubt as to whether removal of fat to the Virchow-Robin's space is accomplished regularly by means of mobile granular cells. In any case, one rarely succeeds in apprehending a glia shrub of the cerebellar cortex in the process of dissolving into disseminated granular cells (KÖRNYEY 1955, Fig. 56). As mentioned in the chapter dealing with histology, the development of sudanophilic substances depends chiefly upon the quantity of the waste products and presumably also upon the diversity in the composition of the latter. At any rate, the nerve cells alone produce comparatively little waste material as is evident when one considers their proportionally greater number among the various structures of the grey matter. The situation changes if edema is added because of anoxic disturbances of capillary permeability, since this attacks by preference the myelin containing structures or again profound tissue damage occurs from a long duration and high degree of anoxia secondary to circulatory disturbances. In the case of a large accumulation of waste products the need for removing cells is soon met by the mobilization of local microglia, mesodermal macrophages and granular cells, even though the transformation into sudanophilic substances had not as yet been completed so far. All kinds of reparative processes could be demonstrated on the 8th day in case 14 of our series (strangulation), which revealed every degree of anoxic tissue dis-

integration, and in which a venous stasis had caused an extensive edema in the white matter followed by softening. In case 6 (heart arrest and strangulation), however, with elective parenchymal necrosis without significant decomposition of myelinated fibers, only traces of sudanophilic substances were noted along with a plain glial reaction. It is unusual to see a delayed removal of sudanophilic waste products in a case of anoxic tissue damage but this could be demonstrated in the globus pallidus, corpus Luysi and Ammon's horn in a 10 1/2-months-old child, who suffered from posticteric encephalopathy due to kernicterus.

We have not been able to observe cases with total cerebral ischemia which had longer survival rates. With the exception of a few completely recovered cases, the ischemia ends in extensive laminar and nuclear loss of nerve cells in band-like cortical softening and in more or less pronounced focal phenomena of varied degree, according to the extent of the accompanying local circulatory disturbances. Loss of myelinated fibers or softening of white matter due to associated edema and secondary degeneration complete the picture. In the literature are cited a few cases which had advanced brain changes secondary to cerebral ischemia of a definite duration, followed by a decerebrate symptomatology. They are in contrast to the recently published cases because of the severity of the changes and not so much by their more defined extent and topography. In this respect we wish to mention the case reported by STEEGMANN (1939) with a survival time of 17 months after narcosis with complications, the case of ZEMAN and YOUNGUE (1957) with asphyxia and collapse yet a survival period of 18 months, and finally the case of MATTYUS (1959) with severe circulatory collapse during an attack of asthma and a year's duration of illness. During such a prolonged course of disease there is always a possibility that acutely occurring structural changes are superimposed upon old lesions from incidental episodes as general convulsions, respiratory distress and circulatory disturbances. Thus, altogether these may cause a progression of cerebral symptoms in such weak patients even late in the course of illness.

Attention should be paid to the late histologic sequelae which are

dealt with in the pathology of cerebral oxygen deficiency. They have also been repeatedly mentioned in the pathology of cerebral palsy (BENDA 1952 among others) and early acquired dementia (A.MEYER 1937). These sequelae are to be found in the formation of a rather significant fiber gliosis in the white matter, especially in the region of the basal cerebral surface including tractus opticus, in the ventricular walls, and perivascular tissue, as well as in certain grey nuclei especially the inferior olives and nucleus dentatus. In many cases there is no evidence for the apparent loss of nerve structures. However, a minor degree of parenchymal loss in the white matter or in regions of densely populated grey matter, may escape detection. In considering the extent of gliosis this may not hold true in every case. The gliosis has been frequently identified as edematous damage. But considering the thick fiber layers which give particular preference to the cerebral surface, it is our opinion that there are still other causes effective. According to studies of BRAND (1941) the astrocytic glia are regarded as structural elements which provide for the cohesion of the brain substances and which generally respond to mechanical stimuli from the tissues. The astrocytes fill defects and adhere to certain physical rules of growth especially in regard to tensile load. This tendency of growth is also observed along normal lines and is prominent in cases with repeated but brief episodes of fluctuation of the cerebral volume, as for instance in epileptic seizures (marginal and perivascular gliosis of Chaslin) or in cases of prolonged increase in volume due to inflammatory edema (SCHOLZ 1955). We could also demonstrate in our cases congestion and disturbance of permeability of prolonged duration with succeeding edema. That occur secondary to acute ischemic or hypoxemic conditions. Changes in the tensile state of the tissues are the basis for the mechanical factors in the development of such a type of fiber gliosis. Posticteric encephalopathy, which follows secondary to kernicterus along with proven disturbances in permeability (bilirubin in the tissue), represents a good example of the marked production of gliosis in ventricular walls, olivary bodies and other nuclei without evidence of an accompanying structural loss. The same findings are encountered in late stages of asphyxia neonatorum.

Even though one assumes that part of the fiber gliosis develops from an undetectable loss of parenchymal tissue, and another part from mechanical tissue factors, there is a residual growth which remains unexplained. The latter becomes particularly obvious in cases of chronic anemia in which, apart from gliosis of the white matter, there are fiber forming astrocytes within the grey matter of the striatum, thalamus, globus pallidus and even in the cerebral cortex without indication of a volume reduction or loss of structures (case 31). We are unable to give a reasonable clinical explanation for the gliosis which is demonstrable in the Figs. 43, 46, 47, 49 - 53. The same applies to one case of survived atmospheric hypoxidosis. Whether or not a primary stimulation of astrocytic glia is caused by transient or chronic oxygen deficiency remains so far a hypothetic speculation. Nevertheless, the regularly observed gliosis of the white matter in infantile hypoxemia may speak in favour of the above. This supposition is also supported by the predilection for increased fiber gliosis in regions known to be rather sensitive to oxygen deficiency, such as the inferior olives and nucleus dentatus where neither cell nor fiber loss can be detected in either one of them. Changes in the olives as seen in Figs. 5 and 6 must, in case of survival, naturally lead to a marked fiber gliosis. It remains unknown, however, why such a dense gliosis had developed in the Figs. 32 and 53. Contrary findings are encountered in the pallidum - subthalamicus - Ammon's horn gliosis in the cases of hypoxemia of the newborn as compared to the pallidum gliosis in pernicious anemia (Fig. 50).

Thus we have arrived at the topography of cerebral changes which cannot be separated from their topistical characteristics.

Published reports of secondary cerebral damage are those of anesthesia incidents, controlled heart and respiratory arrest, circulatory collapse, atmospheric and other types of hypoxidosis, CO-poisoning, enzymatic poisons and hypoglycemia. In such cases we have to consider a diminution of the oxygen available, an interruption of oxidative processes by enzymatic inhibition or nutritional deficiency. A simple statistical evaluation of these numerous published reports dealing with secondary cerebral damage would probably end with a result similar to that which we obtained in our own cases.

The grey matter would be described as the favored site of injury with demonstrably intensified action in the cerebral cortex including Ammon's horn, striatum, thalamus and probably cerebellar cortex. At times, presumably, one would learn that globus pallidus (CO, cyanide, CS₂) and corpus Luysi (asphyxia in newborn) were strikingly affected. On the other hand there would be a rapid decrease of changes in the direction of mesencephalon, medulla oblongata and spinal cord and a tendency to spare the vegetative nuclei of the diencephalon. Therefore we have classified our cases into primary ischemic and primary hypoxemic cerebral oxygen deficiencies, as explained in the introduction to this paper. It is our impression that while there may be an overlapping in regard to their cerebral types of manifestation, there are differences between both which cannot be plausibly explained. In order to have a basis for our personal interpretations we confronted two groups of cases regarding the topography of cerebral lesions. One of the groups comprises 14 cases with acute total cerebral ischemia. The second one is made up of 9 cases of survived asphyxia neonatorum and hemolytic icterus neonatorum with kernicterus offering a pallidum - corpus Luysi - Ammon's horn syndrome. The studies disclosed that, by a sudden onset of total cerebral ischemia, the cerebral cortex and also the cerebellar cortex, Ammon's horn, striatum and thalamus were affected with great regularity, whereas the globus pallidus was not significantly affected. In contradiction is the group of 9 cases where the lack of oxygen does not become so rapidly effective and the above mentioned combination of pallidus - corpus Luysi - Ammon's horn is in the foreground indeed. Striatum and thalamus are not always excluded. We also noted loss of nerve structures or the growth of simple gliosis in several nuclear regions, as inferior olives and nucleus dentatus, which have already been mentioned in ischemic conditions. Cerebral and cerebellar cortex were usually not affected. This in itself demonstrates the polar nature in the differences of topography that cannot be disregarded, even though there are certain mutual features regarding the involvement of the basal ganglia.

Early acquired damage of the pallidus and corpus Luysi is not too rare. HALLERVORDEN and MEYER (1956) observed 12 cases in which 8 cases of longer survival revealed an almost pure form of pallidum - corpus Luysi -

injury with a relatively minor loss of mental capacity. All of these cases showed complications at birth and asphyxia. Somewhat similar cases are reported by SCHARAPOW and TSCHERNOMORDIK (1928) and PAPEZ, HERTZMAN and RUNDLES (1939) who deal with asphyxia neonatorum in a child 6 1/2 years of age and with a precipitate delivery in a 35-year-old female, respectively. Additional cases of not entirely clear pathogenesis are reported by KREYENBERG (1931), de LANGE (1939) and INOSE (1941). Adding our 5 cases we accumulate at least 22 cases with entirely analogous findings in which asphyxia neonatorum played an essential role. The cases von van BOGAERT (1946) showing a familial progressive pattern probably do not fall into this category. Controversial opinion may be aroused by the fact that we have added 4 cases of posticteric encephalopathy to the 5 cases with asphyxia neonatorum. Morphologically they all disclose absolutely uniform findings similar to the cases of posticteric encephalopathy published by SOEKEN (1957) and the ones recently reviewed by HAYMAKER et al. (1959). In all of our cases a morbus hemolyticus neonatorum and progressive anemia were present. MERIWETHER, HAGER and SCHOLZ (1955), in contrast to DEREYMAEKER (1949), claimed that hypoxemia is the effective factor responsible for the final conditions encountered. Recently, HAYMAKER, MARGOLES, PENTSCHEW, JACOB, LINDENBERG, SAENZ-ARROYO, STOCHDORPH and STOWENS investigated the genesis of kernicterus in a study of a great many cases. Even though it has been determined in the meantime, that, in a large number of cases, the anemia has not been caused by blood incompatibility, the authors in agreement with H. JACOB (1948) demonstrated in acute cases of kernicterus that, in contrast to the glia, the devitalized nerve cells are the only cells to take up bilirubin. Therefore, we deal with a form of supravital staining in which the areas of nerve cell necrosis extend at times beyond the regions of the yellow staining. Since we cannot assume that all aforementioned cases (pallidum - corpus Luysi - Ammon's horn syndrome with a history of precipitate birth, severe asphyxia, birth in the amniotic sac etc.) have been unrecognized cases of kernicterus, one may join the opinion of ERBSLÖH (1958) who concluded that hypoxidosis which occurs in many ways during the course of delivery, constitutes the causative factor in the formal pathogenesis of the permanent

cerebral changes of kernicterus. This theory is supported by findings of WINDLE, who, according to a discussion delivered by CAMERMEYER (1957), observed changes in an asphyxiated mature monkey which were topographically similar to those seen in kernicterus. HAYMAKER et al. (1959) introduced functional liver damage as a form of an intermediary link. It has yet to be proven whether there is a necessity for its introduction and how it manifests itself. Thus we believe that hypoxemic tissue damage plays a major role in the findings of post-icteric encephalopathy as reported in the literature by PENTSCHEW (1949), SOEKEN (1957), HAYMAKER et al. (1959). Moreover, the importance of asphyxia in the development of cerebral injury may be inferred from a statistical review of 500 cases reported by SCHREIBER (1938). He was able to demonstrate the presence of a striking degree of apnea in the perinatal history in not less than 70% of the cases, and believes that the duration of apnea is in direct proportion to the severity of neurologic symptoms. He emphasizes that cases of premature and precipitate birth are particularly endangered. This seems to be a broad basis for simple anoxic tissue changes and also for cases with kernicterus besides the existence of erythroblastosis.

The findings in CO-poisoning suggested that the globus pallidus is a nucleus which shows a marked sensitivity to oxygen deficiency. Some people argue the point that the globus pallidus holds a special position among all nuclei. This is understandable when one considers the multiplicity of changes and of factors that become effective during the course of poisoning. However, the question must be raised, why just this small part of the brain is symmetrically affected with such regularity in comparison to the total mass of the brain tissue. Corresponding changes could also be found in some of our cases (36 - 38). With such aspects in mind, A. MEYER (1926) began his experimental work with carbon monoxide. He continued his studies in the field of cyanide (1933) and anesthetic asphyxia (with the cooperation of BLUME, 1934). Even though the cerebral changes followed a vascular distribution in most of the cases, the involvement of the globus pallidus by elective symmetrical damage was of strikingly high incidence. In the opinion of the author such changes are bound to occur with exceptional frequency "in case of disturbed external and internal respiration" and in the

almost entire absence of circulatory lesions. Other experimental studies dealing with oxygen deficiency due to hemoglobin factors or the use of the low pressure chamber and the diminution of oxygen in the respired air, are subjects of this discussion. These tests revealed that cerebral changes usually occurred only after repeated severe asphyxia which always ranged within values endangering the life of the test animals. This signifies an intricate combination of factors as also indicated by the brain findings. There appears to be a thin line between a hypoxemia causing special lesion and transient heart arrest or circulatory collapse. Some of the latter findings closely resemble the markedly extensive changes seen in cases of cerebral ischemia. This does not mean, however, that the aforementioned narrow boundary would not be present, although seemingly difficult to broaden. This can best be demonstrated in two cases reported by TITRUD and HAYMAKER (1947) in which atmospheric hypoxidosis was survived by 40 hrs. in one case and 21 days in the second. The first case with general convulsions and early decerebrate rigidity revealed a histologic picture which we have seen in total cerebral ischemia. The second case presented symptoms of partial remission and an apparently delayed development of spastic symptoms. Aside from cortical and cerebellar changes there was observed a severe involvement of the basal ganglia. A partial softening was found in symmetrically arranged circumscribed areas within the globus pallidus. In one of our two cases of atmospheric hypoxidosis (23) death ensued immediately without development of definite changes. The other case (24) with many years of survival and rather inconspicuous cerebral symptoms developed distinct cerebral lesions involving thalamus and globus pallidus which will be considered later. The numerous cases of symmetrical malacia of the globus pallidus in acute CO-poisoning reported in the literature will not be extensively discussed. We wish to mention only that included were cases which revealed a total damage to the pallidum (GROSSPERRIN 1931). We intend to draw attention solely to the reports of pallidum changes in other types of hypoxemia. Such reports in hypoxemia due to secondary anemia from severe internal bleeding have been published by STAEMMLER (1923), PULCHER (1932), E.SCHERER (1934), OVERHOF (1933), ULBRICHT (1948) and PLAMBECK (1950).

The last two authors also described findings pertaining to striatum, cortex, Ammon's horn and cerebellum. Heart and respiratory arrest were concomitant features in the cases of ULBRICHT. Symmetrical pallidum softening was observed by BALO (1941) in 5 cases of bleeding peptic ulcers. Another case belongs into this category. A 11-year-old girl presented symmetrical pallidum softening as a sequel of a hemorrhagic diathesis with severe initial bleeding that happened 3 weeks after an A-bomb explosion (SHIRAKI, UCHIMURA et al. 1956). It seems logical in acute hemorrhage to accuse the minimal oxygen capacity of the remaining blood volume of being the cause of the cerebral changes, even though the latter may be avoided by merely replacing the lost blood with some indifferent fluid. However, we believe that the critical level of hypoxemia is not being reached because of improved circulatory conditions. ABBOTT and COURVILLE (1938) reported on a case of respiratory arrest during anesthesia which was followed by partial bilateral pallidum necrosis without cortical changes. In the case of GRUNER (1952), strikingly severe damage to the globus pallidus, putamen and thalamus along with minor cortical changes were observed secondary to prolonged respiratory arrest at the end of anesthesia. Among 12 cases with paralytic respiratory distress in poliomyelitis, as reported by ALAJOUANINE, BERTRAND et al. (1952), only one was found to have a pallidum demyelination. STEEGMANN and DAVIS (1950) on the other hand did not see that the basal ganglia were involved in preference to cerebral cortex and Ammon's horn in cases of appropriately similar respiratory distress. N. MALAMUD and HAYMAKER (1947) report on extensive symmetrical softening of striatum and pallidum with elective necrosis of the substantia nigra, also cerebral and cerebellar cortical lesions as well as changes in the Ammon's horn secondary to severe head injury. A preceding surgical amputation of one arm presumably played a role in the development of the cerebral lesions, since artificial respiration was necessary during the anesthesia while convulsions and decerebrate rigidity subsequently occurred. A different aspect is offered in one case of JERVIS and JOYCE (1948) who report changes in the basal ganglia and especially in the outer portion of the pallidum following barbiturate and opiate intoxication. Reports on symmetrical pallidum necrosis were given later by GONZALES, VAUCE, HELPERN and UMBERGER in 1954. NEUMANN (1951) published a case of barbiturate poisoning (with

a survival of 6 months) in which the principal lesions were localized in the cerebral and cerebellar cortex, Ammon's horn and nucleus caudatus. Symmetrical gliosis was found in both globi pallidi. The findings encountered in barbiturate poisoning are similar to those mentioned in hypoxemia, at least with regard to topography and lesions, even though no definite conclusions may be drawn on the occurrence of hypoxidosis in the course of illness. No clear relationship is established in cases of symmetrical pallidum necrosis due to acute morphin intoxication, as reported by WEIMANN and MAHRENHOLTZ in 1928. Such obscure pathogenesis induced ERBSLÖH (1958) to make the generally preexistent vascular calcium deposits and pseudocalcifications in the globus pallidus responsible for the localization of lesions there. Such an explanation had been previously mentioned in secondary anemia by STAEMMLER (1923) and E. SCHERER (1934). As a matter of fact, a coincidence of both types of changes is not considered rare. This raises the question as to whether preexistent vascular calcification potentially favors the development of hypoxemic tissue damage. On the other hand one should not overlook the fact that calcium deposits in the globus pallidus are a very common finding in the vast majority of human brains without evidence of cerebral changes, although this calcification is often more intensive than in cases which show cerebral lesions. Frequently, the cerebral changes are not limited to regions of the vascular calcification. It is also known that the deposition of calcium may occur secondarily in regions with a decreased blood flow. SCHMINCKE (1920) believed that they may be precipitated by a decrease in CO_2 content, that is a decreased tissue respiration. The deposition of pseudo-calcium into mesenchymal structures may happen within a surprisingly short period of time, as has been pointed out by DÜRCK. Another striking feature is the fact that concretions remain without evidence of any significant progression in areas of old necrosis. Reliable demonstration of preexisting vascular calcification becomes possible only in areas of rather acute necrosis. It may happen that the pallidum in intercurrent hypoxemia is predisposed to a regional preference for necrosis because of preexistent calcification as stated by ERBSLÖH. However, one cannot admit a general significance for an increased vulnerability since there is only slight interference with circulation and metabolism. This leaves us with the often stated

question as to whether or not the predilective deposition of calcium and the sensitivity to oxygen deficiency of this nucleus should be attributed to the same causative factors.

In relation to the problem of vulnerability should be mentioned the experiments performed by R. RICHTER (1945). He was able to produce elective symmetrical lesions in pallidum and substantia nigra of monkeys which were kept in a carbon disulfide atmosphere for many months. Thus, we find a topographic pattern which largely corresponds to hypoxemia especially in regard to our findings in the newborn. RICHTER raises the question as to whether the topography can be correlated with the hypoxia problem and whether hypoxidosis in his cases cannot be understood as an effect upon the co-enzymes of tissue respiration. PENTSCHEW (1958) mentioned the possibility of the existence of an intermediary link in the form of liver damage, reasoning that there are histologic similarities with Wilson's disease. However, other arguments are lacking in this respect.

In this connection, attention should be drawn to the symmetrical pallidum changes which are due to manganese and which have been described by ASHIZAWA (1927), STADLER (1936) and PARNITZKE and PEIFFER (1954). Here we ordinarily encounter a demonstrable loss of nerve cells only in the pallidum, but exceptionally impressive in its interior part and followed by a moderate fiber gliosis. The latter closely resembles the old pallidum lesions seen in cases of asphyxia neonatorum. They are connected clinically in the development of progressive rigidity and athetosis. In this respect it seems reasonable to search for an eventual relationship to oxygen pathology which, of course, could hardly be expected to have the nature of a lack of oxygen but might be a dysenzymatic hypoxidosis, considering the findings of A. MEYER who worked with cyanide, and R. RICHTER who employed CS₂. Such an interpretation was given by STADLER as early as 1936. The reason the disease progresses is because of the deposit of manganese oxide in the chorioid plexus - at least in the case of PARNITZKE and PEIFFER (1954). This patient had long been removed from exposure to the poison.

The holotopistic type of nerve cell depopulation, demyelination

and gliosis in the combination globus pallidus - corpus Luysi - Ammon's horn occurs only in the brains of the newborn. This type of combination probably depends during this period of life upon the stage of development of the brain, for which the maturation of the medullary sheaths is considered a morphologic indicator. At this time the medullary maturation is ordinarily most advanced in the phylogenetically old parts. Their vulnerability in hypoxemia seems to be definitely proven. In later periods of life the red zone of the substantia nigra sometimes takes the place of the corpus Luysi. The nigra substance is often mentioned in connection with the globus pallidus and also in increasing frequency, the putamen and nucleus caudatus. The Ammon's horn shows a decrease in sensitivity, the changes being less extensive, but still demonstrating a topistic pattern with a preferred loss of nerve cells in field h_1 and h_3 . In these cases the correlation between pallidum lesions and hypoxemic conditions becomes less impressive. As a rule, the lesions within the globus pallidus are focal. In addition, other parts of the brain appear damaged. The origin of these changes is sought in circulatory effects upon the brain, displacement of brain within the skull from edema and in changes of other body organs. The absolute number of pallidum lesions, especially in CO-poisoning (the frequency would probably show a significant increase if microscopic study were always performed), their symmetrical manifestation in other types of hypoxemia and finally the more or less topistic development in experimental intoxication with cyanide forcibly demonstrate the vulnerability of this nucleus to a lack of oxygen and to a defective oxygen utilization in cellular metabolism. The pallidum is also affected by chronic CS₂ and manganese intoxication in which the lesions are limited to the nuclear area. This also indicates that a dysenzymatic disturbance of the cellular oxidation plays an essential role. Probably correlated with the rapidity of the onset of effect and the structure of the nucleus, there seems to be a borderline, at which this particular vulnerability ceases to exist. This threshold lies within the period of the abruptly occurring anoxia in total cerebral ischemia.

There are numerous cases reported in the literature in which we have not found any evidence of preferential involvement of the globus

pallidus. These cases comprise conditions such as anoxic cerebral damage due to anesthesia with heart arrest or respiratory and heart arrest (BODECHTEL 1928, COURVILLE 1938, NEUBUERGER 1954, A. MEYER 1956 and others), also sudden circulatory arrest due to other causes, for instance, pulmonary embolism (WUSTMANN and HALLERVORDEN 1935, NYSTRÖM 1930) and sudden circulatory collapse (MATTYUS 1959). The absence of globus pallidus vulnerability was observed also in experimental circulatory arrest (WEINBERGER, GIBBON and GIBBON 1940, GRENNELL 1946, GILDEA and COBB 1930) and histamine shock (MEESSEN 1944). Similar findings occurred in our cases of cardiac or respiratory and cardiac arrest and after strangulation which showed that the cerebral cortex including Ammon's horn, thalamus, striatum and cerebellar cortex are preferentially affected. The globus pallidus was not spared but was more or less in a second rank compared to the general damage in the grey matter.

The same observations apply to cases 41 - 43. In case 41, secondary anemia and air embolism share equally as the causative factors. In the cases 42 - 43 multiple anemic infarcts play the major role which makes it impossible to coordinate them to any topographic pattern. In addition, we have seen involvement of the nucleus dentatus combined with damage to the cerebellum in 4 cases of cerebral ischemia. Cerebellar damage is missing in 4 cases of posticteric encephalopathy or asphyxia neonatorum where the nucleus dentatus was found to be affected. Definite evidence of acute loss of nerve cells in the inferior olives was encountered in 4 cases with total cerebral ischemia, once, in disseminated form and 3 times in total depopulation of the entire nucleus. The holotopistic nature of the lesions was demonstrated by serial sections in case 4 (Figs. 5, 6). The general sensitivity of the olives to oxygen deficiency can also be observed in circulatory disturbances since they occur in cases of Wernicke's encephalopathy. In such incidences they show, as a rule, an extensive, sectorlike nerve cell loss (H. JAKOB 1955). In cases of hypoxemia or anemia the olivary changes are of the gliosis type without corresponding loss of parenchymal tissue (Figs. 32, 53).

Changes in the nucleus dentatus and inferior olives, secondary to total cerebral ischemia or to hypoxemia are often mentioned in the

literature. A distinct relation does not seem possible. It should be mentioned, however, that they frequently appear after a series of convulsions and that the lesions in the nucleus dentatus are usually associated with changes in the cerebellar cortex. All arguments with regard to their development by tentorial herniation (PENFIELD and JASPER 1954) and the role which temporary occlusion of the posterior channels plays in out- and inflow of the blood (LINDENBERG 1957, PIA 1957, SCHOLZ 1959) apply to other local and frequently topistic manifestations occurring in the hippocampus region, the thalamus, striatum, occipital cortical regions and cerebellar cortex in types of local cerebral ischemia with subsequent cerebral edema. Strikingly, the globus pallidus is not one of the affected areas.

It seems that the pallidum is preferentially involved if cerebral circulation remains intact and oxygen may be utilized from the circulating blood for some period of time. The conditions for their experimental reproduction and for holotopistic occurrence in adults may be established if the inhibition of the cellular oxidation by enzyme poisons takes place intermittently or very slowly.

The problem as to the circumstances under which hypoxemia may produce irreversible cerebral changes has been investigated in additional related cases. No definite findings were elicited in two cases of small infants (21, 22) with progressive respiratory distress in congenital myatony. However, there was a 9-month-old infant who suffered such severe attacks of dyspnea from tracheobronchitis and latent spasmophilia, that a tracheotomy was necessary (19). In this case single nerve cells in the cerebral cortex and field h_1 and h_3 of the Ammon's horn revealed a typical ischemic cell necrosis as an effect of hypoxemia. The globus pallidus appeared to be free of lesions. Two cases of suicidal E-605 poisoning belong in the same category. One of them (40) expired after severe edema of the lungs. Only doubtful nerve cell changes were seen in cortex; besides old cerebral changes which were due to birth trauma, and which also were believed to be the cause of the existing epilepsy, since there was a typical sclerosis of the Ammon's horn. The first case (39), with a protracted course, suffered a number of severe respiratory and circulatory disturbances, namely severe cyanosis, respiratory arrest of 90 min., Cheyne-Stokes

syndrome for 24 hrs. and several episodes of generalized convulsions. Complete unilateral damage to the Ammon's horn and rather extensive nerve cell loss in both thalami occurred as a consequence.

There were also two cases of atmospheric hypoxidosis in one of which (23) the survival period was too short for the production of morphologically demonstrable abnormalities. Only the thalamus and striatum presented nerve cell changes of doubtful significance. The second case (24) is of interest since the acute stage was survived for 16 years without evidence of definite cerebral symptoms. Obvious nerve cell loss was observed only in the thalamus and distinct demyelination in the tip of the globus pallidus. The parenchymal loss was associated with the development of marked fiber gliosis in regions of the thalamus and globus pallidus. The fiber gliosis in the globus pallidus, also in striatum, white matter of hemispheres including ventricular walls and especially medulla oblongata and inferior olives far exceeded the parenchymal loss. This type of gliosis has been discussed in the section dealing with histology of oxygen deficiency damage.

In contrast, 3 of our cases of CO-poisoning (36 - 38) show rather severe damages, in regions of old scars in two cases and in one about 3 months after poisoning. The most pronounced changes were the symmetrical lesions in the globus pallidus in all 3 cases besides injury to the cerebral cortex and the white matter. The lesions of the globus pallidus were not only of the focal type but also consisted of a diffuse gliosis of the entire nuclear area not limited to the neighborhood of the small foci. Figs. 58 and 59 disclose that the pallidum lesions affect the entire nucleus with a loss of medullary fibers. The lesion is demonstrable in a Nissl preparation as a thinning out of the nerve cells, followed by a reactive gliosis. Not everything which appears unaltered to the naked eye really proves to be normal on close inspection. Thus, the topistic tendency of the pallidum changes, although of varied intensity, becomes evident even in a mild degree of damage. It may likewise be manifested by only a productive reaction of fiber forming astrocytes without demonstrable loss of nerve structure (Fig. 61). The importance of this observations has already been discussed in the section dealing with histologic changes.

Finally it was of interest to learn how the brain would react if exposed to chronic hypoxemia, created by poor arterialization of the blood from an arteriovenous shunt or by the diminution of oxygen carriers in the blood. The investigation of cases with malformation of heart and cyanosis was disappointing except for case 32 in which a complication of perinatal asphyxia could not be ruled out. It becomes obvious that there is good adaptation to poorly arterialized blood and altered circulatory conditions, as long as respiration and circulation are not subject to undue stress. The pallidum - corpus Luysi - Ammon's horn changes, as found in case 32, remained a rarity considering the extensive studies done in regard to malformation of heart by MEESEN and STOCHDORPH (1952). Aside from compensatory productive alterations in the brain vessels, massive changes were observed only in cases of decompensation as shown by the softening due to arterial thrombosis in case 33, and by the old damage in case 34. The last case (35) did not show any noteworthy cerebral lesions.

In chronic anemia the situation is quite different. Of three cases, two were 6 1/2- and 7-year-old girls with an extremely low hemoglobin content, fluctuating between 15 and 22 per cent. The first case presented the general features of poor development as indicated by dementia and defective development of speech associated with a few slight developmental malformations of the cerebral gyri. The severe anemia, the cause of which had never been discovered, persisted throughout her entire life. Apart from two small lesions in the thalamus, covered with glial proliferation, no loss of nerve structures was seen anywhere. In the second case, a subchronic panmyelophthisis had developed at the age of 6 years with evidence of a myeloplastic reaction, the number of erythrocytes fluctuating between values of 0.81 and 1.2 million. The mutual features of both cases were a rather extensive and dense fiber gliosis without corresponding loss of parenchyma. In both cases most of the grey and white matter were affected in this way with exception of the cerebral and cerebellar cortex. The gliosis was of marked intensity in the globus pallidus, the ventricular walls and in the tractus opticus (Figs. 42, 43, 45, 46, 47). An acute distinction of medullary fibers in the thalamus of the second case was not associated with a corresponding loss of nerve cells nor with any

glial reaction (Fig. 44). The disintegration of the medullated fibers must have developed during the very last phase of life and, thus, cannot be regarded as the direct effect of chronic oxygen deficiency.

This type of gliosis was even more pronounced in the third case, pernicious anemia, in which subacute combined degeneration of the cord was absent. Several authors have investigated the cerebral changes in pernicious anemia (FERRARO, ARIETI and ENGLISH 1945). The results were reviewed by ERBSLÖH (1958). A differentiation was made between ring bleedings and demyelination which was coordinated with changes that occur in subacute combined degeneration of the cord. Only the first named lesions could be demonstrated in our case, affecting essentially the white substance. They certainly cannot be considered an effect of chronic oxygen deficiency but may be attributed to vitamin B₁₂ deficiency. Furthermore, a number of small and acutely developed foci of tissue destruction were symmetrically distributed in both globi pallidi. The lesions had apparently developed sublethally, secondary to tissue anoxia and to a contributory effect of the markedly calcified local vessels. The previously mentioned gliosis was rather extensive in this case, and connects it with the other two cases. Many fiber forming astrocytes were also observed in the cerebral cortex where no nerve cell loss could be detected (Fig. 52). The same findings were encountered in the thalamus and striatum. Symmetrical gliosis of the globus pallidus is even visible to the naked eye in Holzer preparations (Fig. 50) and can be verified microscopically (Fig. 48). A severe development of gliosis is also present in the white substance, the ventricular walls, the medulla oblongata and the inferior olives.

With the exception of case 29, none of the cases with chronic anemia disclosed a loss of nerve cells that could be related to a hemoglobin deficiency or to a reduced number of erythrocytes. Most significantly, we did not observe any important hemorrhages. According to the studies of ERBSLÖH (1958), who refers to reports in the literature, critical states of hypoxemia in cases of severe anemia may be expected only if intermittent complications arise as in case 31 which shows symmetrical focal destruction within the globus pallidus. Special attention should

be drawn to the occurrence of primary diffuse gliosis since an adequate basis for its development, namely general cerebral edema or mechanical tissue factors, is absent. The marked and uniform involvement of the grey matter, namely the pallidum, striatum and also the cerebral cortex, the latter being affected only in the case of pernicious anemia, must be considered unusual. Such diffuse proliferation of glia fibers has already been referred to by other investigators (WOHLWILL 1921, WEIMANN 1924, among others). If this gliosis is especially pronounced in pernicious anemia, unusual conditions of metabolism may be held responsible, such as, a disturbance of internal respiration of the entire brain associated with diminished utilization of sugar and oxygen (SCHEINBERG 1951, BERNSMEIER 1953). The findings in the first two cases indicate, however, that the same phenomena also occur in simple chronic anemia, although less severe.

In regard to the above all the characteristics of chronic anemia are met in the other forms of hypoxemia placed in this group. The resistance of the nerve structures is remarkable. In acute respiratory distress, loss of nerve tissue is only seen in situations endangering life. In one case with long survival from atmospheric hypoxidosis, the loss of nerve structures in thalamus and pallidum was of a relatively minor degree. Most conspicuous was the severe gliosis in the globus pallidus, corpora striata and inferior olives which was not accompanied by loss of nerve structures. The focal nature of the lesions in CO-poisoning is used as an argument against a direct sensitivity of the globus pallidus to oxygen deficiency. The interconnection with circulatory mechanisms can hardly be denied. Studies of our cases revealed that the focal loss was associated with a diffuse damage to the pallidum which, in two cases, resulted in slight demyelination and disseminated nerve cell loss followed by gliosis. The third case (38) which presented only microscopically visible small areas of softening in the globus pallidus, showed the development of considerable diffuse gliosis over the entire area without demonstrable nerve cell loss (Fig. 61). Understandably, these changes are more easily found if they have reached a certain age. Then we often see also vascular calcifications which are deemed chiefly of secondary origin and of no importance in regard to the involvement of the globus pallidus in tissue

changes. At any rate, these findings favor the theory that we deal with topistic lesions of the globus pallidus also in CO-poisoning.

We are almost convinced that in a certain number of cases the gliosis of the white matter is caused by edematous conditions and is due to mechanical tissue factors. If, however, it is admitted that primary fiber gliosis can be attributed to subcritical oxygen deficiency, as seen in cases of chronic anemia, then the gliosis encountered in the pallidum, putamen, inferior olives and presumably also in the cerebral cortex should be regarded as a hypoxic effect. We are familiar with neuronal lesions in the same locations, occurring with a topistic pattern in the inferior olives in total cerebral ischemia. Consequently a primary gliosis has to be regarded as an effect of a minimum degree of oxygen deficiency upon the nerve tissue.

In general the gliosis is most pronounced in the white matter and in richly medullated grey substances, where they appear in late stages as isomorphic gliosis. In grey substances poor in medullated fibers there occurs a simple increase of fibrous astrocytes. Most impressive is their appearance in isolated nuclei as in the inferior olives and nucleus dentatus. While total loss of nerve cells within the olives has been found preferentially in cerebral ischemia, simple gliosis often associated with a more intensive involvement of the hilar recessus, was seen mainly in hypoxemia. This applies even more strongly to the simple gliosis of the pallidum and striatum. Whereas the latter can only be identified by microscopical examination, the former may be verified with the naked eye in selectively stained preparations.

These observations seem to confirm the sensitivity of the globus pallidus to oxygen deficiency. Neither angioarchitectural peculiarities nor other localizing factors, as for instance the formation of vascular concretions (pseudocalcification) can be held responsible. All the findings point to a specially substantial organization of this nucleus and thus represent topistic manifestations. They are also seen with other changes which are partly holotopistic or topistic and partly focal or circulatory in nature. The globus pallidus, however, always exhibits the most intensive alterations in primary hypoxemia.

It cannot be denied, that complications may intervene in the course of long survived hypoxemic states or that they are covered by cerebral ischemia at the very onset. This leads, of course, to rather obscure anatomical findings. Such cases of long survival are hardly fit for a pathogenetic analysis. In our opinion it was, therefore, preferable to investigate acute cases which present a clear situation. Total cerebral ischemia offered this possibility. We did not have own acute cases of primary hypoxemia in the newborn. This gap may be closed by the fact that the older changes are of the same type. In adults who obviously develop an increased resistance to hypoxemic conditions, the findings were always meager, except in cases of CO-poisoning. We therefore had to refer chiefly to cases reported in the literature. In addition we used observations from the experimental pathology of cyanide and CS₂ and considered also the elective pallidum changes as found in manganese intoxication. These investigations revealed the significantly greater sensitivity of the basal ganglia, with preference for the globus pallidus and at times also for the substantia nigra, compared to other parts of the brain. It may be assumed that this sensitivity is caused by a special organization of these nuclei. In contradiction, cases of cerebral ischemia in general show varied degrees of regional sensitivity which diminishes in this order, namely from the cerebral and cerebellar cortex including Ammon's horn down towards the medulla oblongata although certain nuclear areas, as the inferior olives are often exempt. These differences seem generally to be caused by the speed with which hypoxia takes place, the slower hypoxemia giving the brain a possibility for a larger variety and differentiation of lesions. It should, however, be noted that cerebral ischemia may be manifested also topistically in the form of laminar nerve cell loss, depopulation of single fields in the Ammon's horn, laminar changes in the cerebellar cortex and nerve cell necrosis of the inferior olives. These features are likewise encountered in regions of local circulatory disturbance.

References.

- Abbott, C.N. and B. Courville: Degeneration of the globus pallidus after nitrous oxide anesthesia. Bull. Los Angeles Neurol. Soc. 3, 46, 1938
- Alajouanine, T., I. Bertrand, P. Castaigne, J. Gruner and J. Pecker: Etude des lésions cérébrales de l'anoxie au cours des paralysies respiratoires. Rev.Neurol. 86, 3, 1952
- Altmann, H.-W. and H. Schuboth: Funktionelle und organische Schädigungen des Zentralnervensystems der Katze im Unterdruckexperiment. Beitr.path.Anat. 107, 3, 1942
- Ashizawa, R.: Über einen Sektionsfall von chronischer Manganvergiftung. Jap.J.med.Sci. 1, 173, 1927
- Balb, J.v.: Die neurogene Theorie des peptischen Magen- und Duodenalgeschwürs. Dtsch.med.Wschr. 1941, p. 419
- Benda, C.E.: Structural cerebral histopathology of mental deficiencies. Proc.Ist Intern.Congr.Neuropath. Rom, 1952
- Bernsmeier, A.: Die Messung der Hirnaurchblutung bei inneren Erkrankungen. V.Congr.Neurol.Int., Lissabon, 1953
- Bodechtel, G.: Befunde am Zentralnervensystem bei Spätnarkosetodesfällen. Z.Neur. 117, 366, 1928
- Bodechtel, G.: Gehirnveränderungen bei Herzkrankheiten. Z.Neur. 140, 657, 1932
- Bodechtel, G.: Zur Bedeutung des vasalen Faktors beim Hirntrauma. Dtsch.Z.f.Nervenheilk. 140, 286, 1936
- Bodechtel, G. and G. Müller: Die geweblichen Veränderungen bei der experimentellen Gehirnembolie. Z.Neur. 124, 764, 1930
- Bogaert, L. van: Aspects cliniques et pathologiques des atrophies pallidales et pallido-luysennes progressives. J.Neurol, Neurosurg.Psychiat. 9, 125, 1946
- Bogaert, L.van: Aspect histologique d'une séquelle tardive de l'ictère nucléaire. Ann.Paediatr. 168, 57, 1947
- Bogaert, L.van, M.J. Dallemagne and R. Wégria: Recherches sur le besoin d'oxygène chronique et aigu chez Macacus Rhesus. Arch.Intern. de Méd. expér. XIII, 335, 1938
- Brand, E.: Zur Morphogenese pathologischer Gliafaserstrukturen mit besonderer Berücksichtigung gewebsmechanischer Momente. Z.Neur. 173, 178, 1941

- Büchner, F.: Die Pathologie der cellulären und geweblichen Oxydationen. Die Hypoxydosen. Handb.d.allg.Patnol. IV/2, p. 569, Springer, Heidelberg, 1957
- Büchner, F. and U.C. Luft: Hypoxämische Veränderungen des Zentralnervensystems. Beitr.path.Anat. 96, 549, 1936
- Camerer, J.: Untersuchungen über die postmortalen Veränderungen am Zentralnervensystem, besonders an den Ganglienzellen. Z.Neur. 176, 596, 1935
- Cammermeyer, J.: Symposium on encephalomyelopathies of infancy and childhood. Discussion. Atlantic City, June 1957. J.Neuropath. & exper.Neurol. 18, 140, 1959
- Courville, C.B.: The pathogenesis of necrosis of the cerebral grey matter following nitrous oxide-oxygen anesthesia. Ann.Surg. 107, 371, 1938
- Courville, C.B.: Antenatal and paranatal circulatory disorders as a cause of cerebral damage in early life. J. Neuropath. & exper. Neurol. 18, 115, 1959
- Dereymaeker, A.: L'ictère nucléaire du nouveau-né. Edition Arscia, Brüssel, 1949
- Dreszer, R.: Troubles de la dislocation du sang dans le cerveau occasionnes par des barrages mecaniques experimentaux des vaisseaux. Nowin Psychiatricznych 1, 1938
- Dürck, H.: Über die Verkalkung von Hirngefäßen bei der akuten Encephalitis lethargica. Z.Neur. 72, 175, 1921
- Erbslöh, F.: Das Zentralnervensystem bei Krankheiten des Herzens und der Lungen. I. Die Hirnveränderungen beim Herzstillstand und bei der akuten Herz- und Kreislaufinsuffizienz. Handb.d.spez. pathol.Anat.u.Histol. XIII/2 B, p.1330, Springer, Heidelberg, 1958
- Erbslöh, F.: Das Zentralnervensystem bei Krankheiten des Herzens und der Lunge. IV. Hirnveränderungen bei den mit Blausucht einhergehenden kardio-pulmonalen Erkrankungen. Handb.d.spez.pathol. Anat.u.Histol. XIII/2 B, p.1353, Springer, Heidelberg, 1958
- Erbslöh, F.: Das Zentralnervensystem bei Krankheiten des Blutes. IV. Veränderungen des Zentralnervensystems bei Anämien. Handb. d.spez.pathol.Anat.u.Histol. XIII/2 B, p.1492. Springer, Heidelberg, 1958

- Erbslöh, F.: Kernikterus (Hirnveränderungen beim Morbus haemolyticus neonatorum). Handb.d.spez.pathol.Anat.u.Histol. XIII/2 B, p. 1602, Springer, Heidelberg, 1958
- Erbslöh, F. and H. Bochnik: Symmetrische Pseudokalk- und Kalkablagerungen im Gehirn. Sogenannte "idiopathische nicht-arteriosklerotische intracerebrale Gefäßverkalkungen" (Fahr). Handb.d.spez.pathol.Anat.u.Histol. XIII/2 B, p. 1769, Springer, Heidelberg, 1958
- Eros, G. and G. Priestman: Cerebral vascular changes in carbon monoxide poisoning. J.Neuropath. & exper.Neurol. 1, 158, 1942
- Ferraro, A., S. Arieti and W.H. English: Cerebral changes in the course of pernicious anemia. J.Neuropath. & exper.Neurol. 4, 217, 1945
- Gavallér, B.v.: Funktionelle und organische Schädigungen des Zentralnervensystems des Kaninchens nach wiederholter Entblutungsanämie. Beitr.path.Anat. 109, 367, 1944
- Gildea, E.F. and S. Cobb: The effects of anemia on the cerebral cortex of the cat. Arch.of Neurol. & Psych. 23, 876, 1930
- Gonzales, T.A., M. Vauce, M. Helpern and C.J. Umberger: Legal medicine pathology and toxicology. 2nd Ed. Appleton Century Co., New York 1954
- Greenfield, J.G.: The histology of cerebral oedema associated with intracranial tumors (with special reference to changes in the nerve fibers of the centrum ovale). Brain 62, 129, 1939
- Grenell, R.G.: Central nervous system resistance. The effects of temporary arrest of cerebral circulation for periods of two to ten minutes. J.Neuropath. & exper.Neurol. 5, 131, 1946
- Grenell, R.G. and H. Kabat: Central nervous system resistance. II. Lack of correlation between vascularity and resistance to circulatory arrest in hypothalamic nuclei. J.Neuropath. & exper.Neurol. 6, 34, 1947
- Grossperrin, R.D.: Les manifestations hypertoniques consécutives à l'asphyxie oxycarbonée aiguë. Thèse, Facult.de Médecine de Paris, 1931
- Gruner, J.E.: Discussion on the vascular diseases. Proc. Ist Intern. Congr.Neuropath. Rom, 1952
- Hallervorden, J. and J.-E.Meyer: Cerebrale Kinderlähmung (Früherworbene körperliche und geistige Defektzustände). Handb.d.spez.pathol.Anat.u.Histol. XIII/4, p. 194, Springer, Heidelberg, 1956

- Haymaker, W. and C. Davison: Fatalities resulting from exposure to simulated high altitudes in decompression chambers. *J.Neuropath. & exper.Neurol.* 9, 29, 1950
- Haymaker, W. and H. Strughold: Atmospheric hypoxidosis. *Handb.d.spez. pathol.Anat.u.Histol.* XIII/1 B, p. 1673, Springer, Heidelberg, 1957
- Haymaker, W., C. Margoles, A. Pentschew, H. Jacob, R. Lindenberg, L. Saenz-Arroyo, O. Stochdorph and D. Stowens: The role of erythroblastosis and kernicterus in general in cerebral palsy. Edit. by C.A. Swinyard, C.C. Thomas, Springfield/ Ill., 1959/60
- Hiller, F.: Über die krankhaften Veränderungen im Zentralnervensystem nach Kohlenoxydvergiftung. *Z.Neur.* 93, 594, 1924
- Hiller, F.: Die Zirkulationsstörungen des Rückenmarks und Gehirns. *Handb.d.Neurologie v. Bumke-Foerster*, XI, p. 178, Springer, Berlin, 1936
- Inose, T.: Athetose bei der symmetrischen pallidären Gliose. *Psychiat. et Neurolog.Japon.* 45, 23, 1941
- Jacob, H.: Über die diffuse Markdestruktion im Gefolge eines Hirnödems. *Z.Neur.* 168, 382, 1940
- Jacob, H.: Über die Hirnschäden bei Icterus neonatorum gravis (Kernicterus). *Arch.f.Psych.* 180, 1, 1948
- Jacob, H.: Strangulation. *Handb.d.spez.pathol.Anat.u.Histol.* XIII/1 B, p. 1712, Springer, Heidelberg, 1957
- Jacob, H. and W. Pyrkosch: Frühe Hirnschäden bei Strangtod und in der Agonie. *Arch.f.Psych.* 187, 177, 1951
- Jacob, H.: Zur Frage systemartiger Veränderungen der unteren Olive bei Kreislaufstörungen. *Arch.f.Psych.* 186, 535, 1951
- Jacob, H.: Zur Analyse konsekutiver Olivenschäden bei vasculär bedingten Kleinhirndefekten. *Arch.f.Psych.* 193, 583, 1955
- Jervis, G.A. and F.T. Joyce: Barbiturate-opiate intoxication with necrosis of the basal ganglions of the brain. *Arch.of Pathol.* 45, 319, 1948
- Környey, S.: Histopathologie und klinische Symptomatologie der anoxisch-vasalen Hirnschädigungen. *Akademiai Kiado, Budapest*, 1955
- Kreyenberg, G.: Status dysmyelinisatus des Pallidum bei congenitaler bilateraler Athetose. *Z.Neur.* 132, 806, 1931

- Krogh, E.: Discussions on the vascular diseases. Proc. Ist Intern. Congr. Neuropath. Rom, 1952
- Lange, C. de: Angeborene Systemerkrankung des Zentralnervensystems. Ann. paediatr. (Basel) 152, 309, 1939
- Lewis, R.B. and W. Haymaker: High altitude hypoxia. Autopsy observations in 75 fatal cases and an analysis of the causes of the hypoxia. Air Univers. School of Aviation Medic. Proj. No. 513, Report No. 1
- Lindenberg, R.: Compression of brain arteries as pathogenetic factor for tissue necroses and their areas of predilection. J. Neuropath. & exper. Neurol. 14, 223, 1955
- Lindenberg, R.: Die Gefäßversorgung und ihre Bedeutung für Art und Ort von kreislaufbedingten Gewebsschäden und Gefäßprozessen. Handb. d. spez. path. Anat. u. Histol. XIII/1 B, p. 1071, Springer, Heidelberg, 1957
- Malamud, N.: Sequelae of perinatal trauma. J. Neuropath. & exper. Neurol. 18, 141, 1959
- Malamud, N. and W. Haymaker: Cranial trauma and extrapyramidal involvement: cerebral changes simulating those of anoxia. J. Neuropath. & exper. Neurol. 6, 217, 1947
- Máttyus, A.: Über anoxische Gehirnveränderungen bei Asthma bronchiale. Arch. f. Psych. 199, 172, 1959
- Meessen, H.: Veränderungen am Zentralnervensystem des Hundes nach Histaminkollaps. Beitr. path. Anat. 109, 352, 1944
- Meessen, H. and O. Stochdorph: Gehirnbefunde bei Morbus coeruleus. Proc. Ist Intern. Congr. Neuropath. Rom, 1952
- Meriwether, L.S., H. Hager and W. Scholz: Kernicterus. A.M.A. Arch. of Neurol. 73, 293, 1955
- Meyer, A.: Über die Wirkung der Kohlenoxydvergiftung auf das Zentralnervensystem. Z. Neur. 100, 201, 1926
- Meyer, A.: Experimentelle Vergiftungsstudien I, II. Z. Neur. 139, 420, 1932
- Meyer, A.: Experimentelle Vergiftungsstudien III. Gehirnveränderungen bei experimenteller Blausäurevergiftung. Z. Neur. 143, 333, 1933
- Meyer, A.: On some problems of histological diagnosis and interpretation of circulatory disturbances in the brain. J. Ment. Sci. January 1938, p. 1

- Meyer, A.: Neuropathological aspects of anoxia. Proc.Roy.Soc.Medic. 49, 619, 1956
- Meyer, A.: Anoxias, intoxications and metabolic disorders. In: Neuropathology by Greenfield, Blackwood, Meyer, McMenemey, Norman. Edward Arnold, London, 1958
- Meyer, A. and I.C. Cook: Diffuse white matter gliosis in mental defectives. J.Ment.Sci. 1937, p. 1
- Meyer, A. and W. Blume: Experimentelle Vergiftungsstudien IV. Folgeerscheinungen der Narkose am Zentralnervensystem. Z.Neur. 149, 678, 1934
- Morrison, L.R.: Histopathologic effects of anoxia on the central nervous system. Arch. of Neurol. & Psychiat. 55, 1, 1946
- Müller, G.: Zur Frage der Altersbestimmung histologischer Veränderungen im menschlichen Gehirn unter Berücksichtigung der örtlichen Verteilung. Z.Neur. 124, 1, 1930
- Neubuerger, K.: Über cerebrale Fett- und Luftembolie. Z.Neur. 95, 278, 1925
- Neubuerger, K.: Akute Ammonshornveränderungen nach frischen Hirnschußverletzungen. Krankheitsforsch. 7, 219, 1928
- Neubuerger, K.: Lesions of the human brain following circulatory arrest. J.Neuropath. & exper.Neurol. 13, 144, 1954
- Neumann, M.A.: Encephalopathy following barbiturate intoxication. J. Neuropath. & clinic.Neurol. 1, 145, 1951
- Nyström, G.: Experiences with Trendelenburg operation for pulmonary embolism. Ann.Surg. 92, 498, 1930
- Opitz, E. and M. Schneider: Über die Sauerstoffversorgung des Gehirns und den Mechanismus von Mangelwirkungen. Erg.d.Physiol. 46, 125, 1950
- Overhof, K.: Über das Vorkommen symmetrischer Gehirnerweichungsherde bei sekundärer Blutarmut. Virchow's Arch. 287, 784, 1933
- Papez, J.W., J. Hertzman and R.W. Rundles: Athetosis and pallidal deficiency. Arch. of Neurol. 40, 789, 1939
- Parnitzke, K.H. and J. Peiffer: Zur Klinik und pathologischen Anatomie der chronischen Braunsteinvergiftung. Arch.f.Psych. 192, 405, 1954
- Peiffer, J.: Zur Pathogenese der zentralnervösen Störungen bei der chronischen Manganvergiftung. Arch.f.Gewerbepath. und Gewerbehyg. 14, 408, 1956

- Penfield W. and H. Jasper: Epilepsy and the functional anatomy of the human brain. Little, Brown & Co, Boston, 1954
- Pentschew, A.: Beziehungen zwischen Gehirn und Leber bei Encephalopathia posticterica infantum im Lichte neuerer Forschungsergebnisse. *Nervenarzt* 20, 220, 1949
- Pentschew, A.: Intoxikationen. *Handb.d.spez.pathol.Anat.u.Histol.* XIII/2 B, p. 1907, Springer, Heidelberg, 1958
- Pia, H.W.: Die Schädigungen des Hirnstammes bei den raumfordernden Prozessen des Gehirns. *Acta Neurochirg. Suppl. IV*, Springer, Wien, 1957
- Plambeck, H.: Veränderungen des menschlichen Gehirns bei chronischem und akutem allgemeinem Sauerstoffmangel. *Beitr.path.Anat.* 111, 77, 1950
- Pulcher, J.: Über akute lymphatische Leukämie an Hand von 3 Sektionsfällen. *Inaug.Diss.* Erlangen 1932
- Richter, R.: Degeneration of the basal ganglia in monkeys from chronic carbon disulfide poisoning. *J.Neuropath. & exper.Neurol.* 4, 324, 1945
- Richter, R.: The effect of certain quinoline compounds upon the nervous system of monkeys. *J.Neuropath. & exper.Neurol.* 8, 155, 1949
- Roeder-Kutsch, T. and J. Scholz-Wölfling: Schizophrenes Siechtum auf der Grundlage ausgedehnter Hirnveränderungen nach Kohlenoxydvergiftung. *Z.Neur.* 173, 702, 1941
- Sagel, W.: Zur histologischen Analyse des Gliastrauchwerkes der Kleinhirnrinde. *Z.Neur.* 71, 278, 1921
- Scharapow, B.I. and P.M. Tschernomordik: Zur Pathologie der Stammganglien. *J.f.Psychol. u. Neurol.* 35, 279, 1928
- Scheinberg, P.: Cerebral blood flow and metabolism in pernicious anemia. *Blood* 6, 213, 1951
- Scherer, E.: Symmetrische Erweichungsherde im Globus pallidus bei sekundärer Anämie. *Z.Neur.* 150, 632, 1934
- Schmidt, I.G. and L.H. Schmidt: Neurotoxicity of 8-Aminoquinolines. I. *J.Neuropath. & exper.Neurol.* 7, 368, 1948
- Schmidt, I.G. and L.H. Schmidt: Neurotoxicity of the 8-Aminoquinolines. III. *J.Neuropath. & exper.Neurol.* 10, 231, 1951
- Schmincke, A.: Encephalitis interstitialis Virchows mit Gliose und Verkalkung. *Z.Neur.* 60, 302, 1920

- Scholz, W.: Über den Einfluß chronischen Sauerstoffmangels auf das menschliche Gehirn. Z.Neur. 171, 426, 1941
- Scholz, W.: Histologische und topische Veränderungen und Vulnerabilitätsverhältnisse im menschlichen Gehirn bei Sauerstoffmangel, Ödem und plasmatischen Infiltrationen. Arch.f.Psych. 181, 621, 1949
- Scholz, W.: Die Krampfschädigungen des Gehirns. Springer, Heidelberg, 1951
- Scholz, W.: An nervöse Systeme gebundene (topistische) Kreislaufschäden. Handb.d.spez.path.Anat.u.Histol. XIII/1, p. 1326, Springer, Heidelberg, 1957
- Scholz, W.: Die nicht zur Erweichung führenden unvollständigen Gewebnekrosen (elektive Parenchymnekrosen). Handb.d.spez.path.Anat.u.Histol. XIII/1, p. 1284, Springer, Heidelberg, 1957
- Scholz, W.: Für die allgemeine Histopathologie degenerativer Prozesse bedeutsame morphologische, histochemische und strukturphysiologische Daten. Handb.d.spez.path.Anat.u.Histol. XIII/1, p.42 Springer, Heidelberg, 1957
- Scholz, W.: The contribution of patho-anatomical research to the problem of epilepsy. Epilepsia 1, 36, 1959
- Scholz, W. and H. Schmidt: Cerebrale Durchblutungsstörungen bei Hypoxämie (Asphyxie). Arch.f.Psych. 189, 231, 1952
- Schreiber, F.: Apnea of the newborn and associated cerebral injury. A clinical and statistical study. J.A.M.A. 111, 1263, 1938
- Shiraki, H., Y.Uchimura, S. Matsuoka, M. Mikaye, S. Takeya, C. Tamagawa, K. Koyano, S. Amano, M. Araki, W.W. Ayres and W. Haymaker: Effects of atomic radiation on the brain in man. Ann.Meet.Amer. Assoc.Neuropath. Atlantic City, 1956
- Soeken, G.: Kernicterus und Morbus haemolyticus neonatorum. F. Enke, Stuttgart, 1957
- Spielmeyer, W.: Histopathologie des Nervensystems. Springer, Berlin, 1922
- Stadler, H.: Zur Histopathologie des Gehirns bei Manganvergiftung. Z.Neur. 154, 62, 1936
- Staemmler, M.: Beitrag zur Kenntnis der Verkalkungen des Gehirns. Beitr.path.Anat. 71, 503, 1923
- Stegmann, A.T.: Encephalopathy following anaesthesia. Arch. of Neurol. 41, 955, 1939

- Steegmann, A.T.: Clinical aspects of cerebral anoxia in man.
Neurology 1, 261, 1951
- Steegmann, A.T. and Davis H.V.: Anoxic encephalopathy following poliomyelitis. Arch. of Neurol. & Psychiat. 63, 774, 1950
- Strughold, H.: Hypoxydose. Klin.Wschr. 1944, p. 221
- Titrud, L.A. and W. Haymaker: Cerebral anoxia from high altitude asphyxiation. Arch. of Neurol. & Psychiat. 57, 397, 1947
- Uchimura, Y.: Über die Gefäßversorgung des Ammonshornes. Z.Neur. 112, 1, 1928
- Uchimura, Y.: Über die Blutversorgung der Kleinhirnrinde und ihre Bedeutung für die Pathologie des Kleinhirns. Z.Neur. 120, 774, 1929
- Ulbricht, J.: Die Folgen des Anämie-bedingten Sauerstoffmangels im Großhirn. Beitr.path.Anat. 110, 147, 1948
- Vogt, C. and O.: Zur Lehre der Erkrankungen des striären Systems. J. Psychol. u. Neurol. 25, 631, 1920
- Vogt, C. and O.: Morphologische Gestaltungen unter normalen und pathogenen Bedingungen. J. Psychol. u. Neurol. 50, 3, 1942
- Weimann, W.: Großhirnveränderungen bei Anämie usw. Z.Neur. 92, 433, 1924
- Weimann, W. and v. Mahrenholtz: Doppelseitige Linsenkernerweichung nach akuter Morphinumvergiftung. Dtsch.Z.gerichtl.Med. 12, 297, 1928
- Weinberger, L.M., M.H. Gibbon and J.H. Gibbon: Temporary arrest of the circulation to the central nervous system. II. Pathologic effects. Arch. of Neurol. & Psychiat. 43, 961, 1940
- Windle, W.F., R.F. Becker and A. Weil: Alterations in brain structure after asphyxiation at birth. An experimental study in the guinea pig. J. Neuropath. & exper.Neurol. 3, 224, 1944
- Wohlwill, F.: Zum Kapitel der pathologisch-anatomischen Veränderungen des Gehirns und Rückenmarks bei perniziöser Anämie und verwandten Affektionen. D.Z.f.Nervenheilk. 68/69, 1921
- Wustmann, O. and J. Hallervorden: Beobachtungen bei Trendelenburgschen Embolieoperationen. Dtsch.Z.Chir. 245, 472, 1935
- Zeman, W. and E. Youngue: Decortication as a result of widespread circulatory and anoxic damage. J.Neuropath. & exper.Neurol. 16, 492, 1957

Figures.

- Fig. 1 Case 2. Shrinkage and swelling of cortical nerve cells with distinct marks of dissolution; pyknosis of all glial nuclei (8 hrs. after cardiac arrest). Nissl stain.
- Fig. 2 Case 4. Laminar pallor of the cortex, most pronounced in lamina III and in the depth of the sulci. Nissl stain.
- Fig. 3 Case 4. Beginning vascular reaction in cortical lamina III, indicating transition into softening (4 days after cardiac arrest). Nissl stain.
- Fig. 4 Case 4. Homogenizing necrosis of Purkinje cells and pyknosis of the granular cells. Beginning neuronophagy and shrunken formation. Pure selective neuronal necrosis. Nissl stain.
- Fig. 5 Case 4. Holotopistic involvement of the inferior olives with numerous neuronophagies. Nissl stain.
- Fig. 6 Case 4. Part of Fig. 5, higher magnification. Ischemic necrosis of the nerve cells of the inferior olives, many of which showing neuronophagic reaction. Nissl stain.
- Fig. 7 Case 4. Progressive fibrous astrocytes in field h_3 of the Ammon's horn. Holzer stain.
- Fig. 8 Case 5. Basal ganglia. Demyelination of the nucleus medialis thalami and some smaller areas of demyelination with corresponding loss of nerve cells. Schroeder myelin stain.
- Fig. 9 Case 5. State of organization in cortical lamina II (6 days after cardiac arrest). Almost complete nerve cell loss with glious reaction only. Nissl stain.
- Fig. 10 Case 5. Proliferating fibrous astrocytes in the Ammon's horn. Holzer stain.
- Fig. 11 Case 6. Almost complete nerve cell loss in the cortex; consecutive rod cell proliferation, some progressive changes of astrocytes, pyknosis of oligoglial nuclei (9 days after cardiac arrest). Nissl stain.
- Fig. 12 Case 6. Complete nerve cell loss in the cortex; pure glious reaction with formation of rod cells and large protoplasmatic astrocytes (9 days after cardiac arrest). Nissl stain.

- Fig. 13 Case 6. Transition from disseminated to neuronal necrosis of the whole nerve cell population in the Ammon's horn. A large number of nerve cells are well preserved (in the upper part of the figure), but most of them have disappeared (lower part of the figure) or demonstrate change of the ischemic necrosis (x) (9 days!), in spite of considerable macro-microglial reaction. Hematoxylin eosin stain.
- Fig. 14 Case 6. New formation of fibrous astrocytes in the Ammon's horn. Holzer stain.
- Fig. 15 Case 6. New formation of fibrous astrocytes in the cerebral white matter. Holzer stain.
- Fig. 16 Case 7. Numerous nerve cells in the state of distinct ischemic necrosis in the cortical lamina III. Only one (x) nerve cell demonstrates beginning neuronophagy (18 hrs. after hanging). Some nerve cells show less severe changes, recovery of which seems possible. No changes of glious cells. Nissl stain.
- Fig. 17 Case 9. Disseminated ischemic nerve cell necrosis, partly with progressed neuronophagic reaction (35 hrs. after hanging) in the cerebral cortex. Nissl stain.
- Fig. 18 Case 10. Rather mild degree of disseminated ischemic nerve cell necrosis in the cortex, but without distinct glious reaction (46 hrs. after hanging). Nissl stain.
- Fig. 19 Case 10. Most of the nerve cells show distinct ischemic necrosis, only a few neuronophagies. Nissl stain.
- Fig. 20 Case 11. A small group of nerve cells with ischemic necrosis in the thalamus; no distinct glious reaction (64 hrs. after hanging).
- Fig. 21 Case 12. Laminar pallor, locally extending on the whole cortex of the occipital lobe. Nissl stain.
- Fig. 22 Case 12. Complete loss of Purkinje cells with pronounced development of glial shrubs (3 days after hanging). No severe alteration of the granular layer. Proliferation of the Bergmann layer. Nissl stain.
- Fig. 23 Case 15. Holotopistic demyelination of the globus pallidus and the corpus Luysi. Demyelination of a periventricular zone. Frozen section, Schroeder stain.

- Fig. 24 Case 16. Holotopistic fibrous gliosis of the globus pallidus and the corpus Luysi. Subependymal gliosis. Holzer stain.
- Fig. 25 Case 17. Holotopistic nerve cell loss and demyelination of the globus pallidus and the corpus Luysi, a demonstrating the increase of glious cells in both nuclei (Nissl stain), b shows their demyelination (Schroeder stain).
- Fig. 26 Case 17. Considerable loss of nerve cells and consecutive gliosis in the globus pallidus. Nissl stain.
- Fig. 27 Case 18. Holotopistic fibrous gliosis (a) and demyelination of the globus pallidus and the corpus Luysi (b). Holzer and Schroeder stain.
- Fig. 28 Case 19. Ischemic necrosis of a few nerve cells in the Ammon's horn. Nissl stain.
- Fig. 29 Case 24. Small patches of demyelination on the top and in the neighboring tissue of the globus pallidus. Schroeder stain.
- Fig. 30 Case 24. Development of fibrous astrocytes in the putamen without conspicuous loss of nerve cells. Holzer stain.
- Fig. 31 Case 24. Rather intensive fibrous gliosis of the globus pallidus. x = nerve cells. Holzer stain.
- Fig. 32 Case 24. Dense gliosis of the nerve cell ribbon of the inferior olives, but without convincing loss of nerve structures. Holzer stain.
- Fig. 33 Case 25. Coronal section through the basal ganglia. Holotopistic loss of nerve cells of the globus pallidus and the corpus Luysi with consecutive cellular gliosis (3 1/2 weeks!). Nissl stain.
- Fig. 34 Case 26. Holotopistic fibrous gliosis of the globus pallidus and the corpus Luysi. Patchy fibrous gliosis in the putamen and thalamus, deriving from a status marmoratus. Holzer stain.
- Fig. 35 Case 26. Demyelination of the lateral part of the dentate nucleus. Schroeder stain.
- Fig. 36 Case 27. Holotopistic demyelination (a) and fibrous gliosis (b) of the globus pallidus and the corpus Luysi. A small perivascular plaque fibromyelinique in the medial nucleus of the thalamus. Schroeder and Holzer stain.
- Fig. 37 Case 27. Many sudanophilic products, most of them situated intracellularly, are rather diffusely distributed all over the area of the globus pallidus (10 1/2 months after the acute state). Romeis stain.

- Fig. 38 Case 27. Gliosis (a) and transport retardation (b) in the Ammon's horn (same condition as found in the globus pallidus in Figs. 36 and 37). Holzer and Romeis stain.
- Fig. 39 Case 27. No convincing diminution of the nerve cell population in the medulla oblongata. Nissl stain.
- Fig. 40 Case 27. In contrast to the Nissl preparation (Fig. 38a), the Holzer stain presents a rather intensive fibrous gliosis of the medulla oblongata with preference of the subependymal layer, the pyramidal tracts and the myelin fiber system of the inferior olives.
- Fig. 41 Case 28. Diminution of nerve cells and cellular gliosis, multiple calcified bodies, deriving from necrotic nerve cells and nerve fibers in the globus pallidus. Nissl stain.
- Fig. 42 Case 29. Slight generalized fibrous gliosis with preference of the subependymal layers, perivascular tissue, the optic tracts, the external capsule and the globus pallidus. Holzer stain.
- Fig. 43 Case 29. Moderate fibrous gliosis of the globus pallidus. Holzer stain.
- Fig. 44 Case 30. Fresh myelin destruction in the medial and lateral nuclei of the thalamus and the medial part of the nigra substance (unilateral). Schroeder stain.
- Fig. 45 Case 30. Rather dense fibrous gliosis in the cerebral white matter, but without significant demyelination. Holzer stain.
- Fig. 46 Case 30. Proliferation of fibrous astrocytes in the putamen; no corresponding loss of nerve structures. Holzer stain.
- Fig. 47 Case 30. Rather dense fibrous gliosis of the globus pallidus; at least two nerve cells can be made out (x). Holzer stain.
- Fig. 48 Case 31. Three very recent small patches of demyelination in the globus pallidus, still without any interstitial reaction. van Gieson stain.
- Fig. 49 Case 31. Development of numerous fibrous astrocytes in the putamen; no loss of nerve structures. Holzer stain.
- Fig. 50 Case 31. Moderate holotopistic fibrous gliosis of the globus pallidus (bilateral). Holzer stain.

- Fig. 51 Case 31. Progressive forms of fibrous astrocytes in the globus pallidus (further differentiated detail of Fig. 49). Holzer stain.
- Fig. 52 Case 31. Development of many fibrous astrocytes in the insular cortex; no convincing loss of nerve structures. Holzer stain.
- Fig. 53 Case 31. Severe subependymal gliosis and dense gliosis of the peri- and intraolivary fiber system without a marked demyelination. Holzer stain (compare Fig. 39).
- Fig. 54 Case 32. Topistic fibrous gliosis in the globus pallidus with considerable loss of nerve cells, but without conspicuous demyelination. Slight gliosis in the thalamus. Holzer stain.
- Fig. 55 Case 32. Holotopistic fibrous gliosis of the corpus Luysi. Holzer stain.
- Fig. 56 Case 32. Considerable thinning-out of the nerve cell population and cellular gliosis of the globus pallidus. Nissl stain.
- Fig. 57 Case 32. Marked loss of nerve cells and gliosis of the dentate nucleus. Nissl stain.
- Fig. 58 Case 36. Bow-shaped softening in the medial part of the globus pallidus, parts of which are filled with mesenchymal tissue; the diffuse demyelination is more pronounced in the dorsal part than in the ventral part (32 years survived mine gas poisoning). van Gieson stain.
- Fig. 59 Case 37. Multiple, irregularly shaped foci of demyelination of the globus pallidus (bilateral) (23 years survived mine gas poisoning). Schroeder stain.
- Fig. 60 Case 37. Irregular, diffuse reduction of nerve cell and reactive gliosis in the globus pallidus, outside of the foci of demyelination. Nissl stain.
- Fig. 61 Case 38. Diffuse development of progressive fibrous astrocytes in the area of both globi pallidi (3 1/2 months survived lighting gas poisoning). Mallory stain.
- Fig. 62 Case 39. Diffuse fibrous gliosis in the white matter of both occipital lobes. Holzer stain.
- Fig. 63 Case 42. Multiple demarkated foci of necrosis in the thalamus, internal and external capsule and the base of the caudate nucleus. van Gieson stain.
- Fig. 64 Case 42. Multiple cortical and subcortical demarkated infarctions in the occipital lobe. Hematoxylin eosin stain.

ASTIA NO:

Contract No: AF 61(514)-945

United States Air Force, Air Research and Development Command, European Office, Brussels, Belgium
Technical (Final) Report

TOXICITY CHANGES IN THE CENTRAL NERVOUS SYSTEM

OXYGEN DEFICIENCY AND ITS INFLUENCE ON THE CENTRAL NERVOUS SYSTEM, by W. Scholz, J.W. Boellaard, H. Hager

date: May 15th, 1959

Organization: Deutsche Forschungsanstalt für Psychiatrie, Max-Planck-Institut, München / Germany

Abstract: 43 cases of complete cerebral ischemia and of hypoxemia are microscopically investigated and the results compared as to the histology, topography and topistic pattern of the lesions. Whereas in ischemia

ASTIA NO:

Contract No: AF 61(514)-945

United States Air Force, Air Research and Development Command, European Office, Brussels, Belgium
Technical (Final) Report

TOXICITY CHANGES IN THE CENTRAL NERVOUS SYSTEM

OXYGEN DEFICIENCY AND ITS INFLUENCE ON THE CENTRAL NERVOUS SYSTEM, by W. Scholz, J.W. Boellaard, H. Hager

date: May 15th, 1959

Organization: Deutsche Forschungsanstalt für Psychiatrie, Max-Planck-Institut, München / Germany

Abstract: 43 cases of complete cerebral ischemia and of hypoxemia are microscopically investigated and the results compared as to the histology, topography and topistic pattern of the lesions. Whereas in ischemia

ASTIA NO:

Contract No: AF 61(514)-945

United States Air Force, Air Research and Development Command, European Office, Brussels, Belgium
Technical (Final) Report

TOXICITY CHANGES IN THE CENTRAL NERVOUS SYSTEM

OXYGEN DEFICIENCY AND ITS INFLUENCE ON THE CENTRAL NERVOUS SYSTEM, by W. Scholz, J.W. Boellaard, H. Hager

date: May 15th, 1959

Organization: Deutsche Forschungsanstalt für Psychiatrie, Max-Planck-Institut, München / Germany

Abstract: 43 cases of complete cerebral ischemia and of hypoxemia are microscopically investigated and the results compared as to the histology, topography and topistic pattern of the lesions. Whereas in ischemia

ASTIA NO:

Contract No: AF 61(514)-945

United States Air Force, Air Research and Development Command, European Office, Brussels, Belgium
Technical (Final) Report

TOXICITY CHANGES IN THE CENTRAL NERVOUS SYSTEM

OXYGEN DEFICIENCY AND ITS INFLUENCE ON THE CENTRAL NERVOUS SYSTEM, by W. Scholz, J.W. Boellaard, H. Hager

date: May 15th, 1959

Organization: Deutsche Forschungsanstalt für Psychiatrie, Max-Planck-Institute, München / Germany

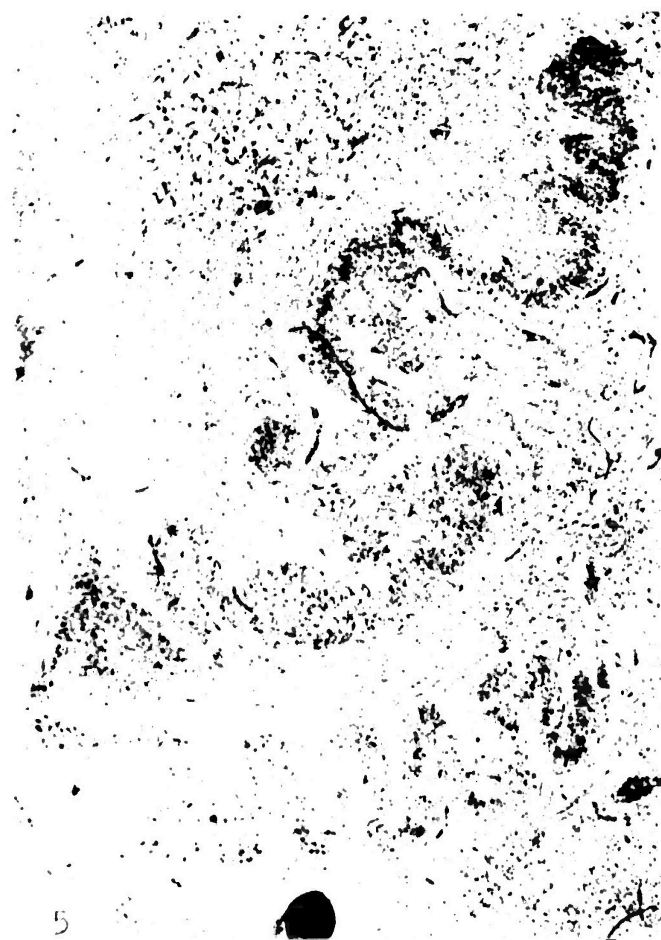
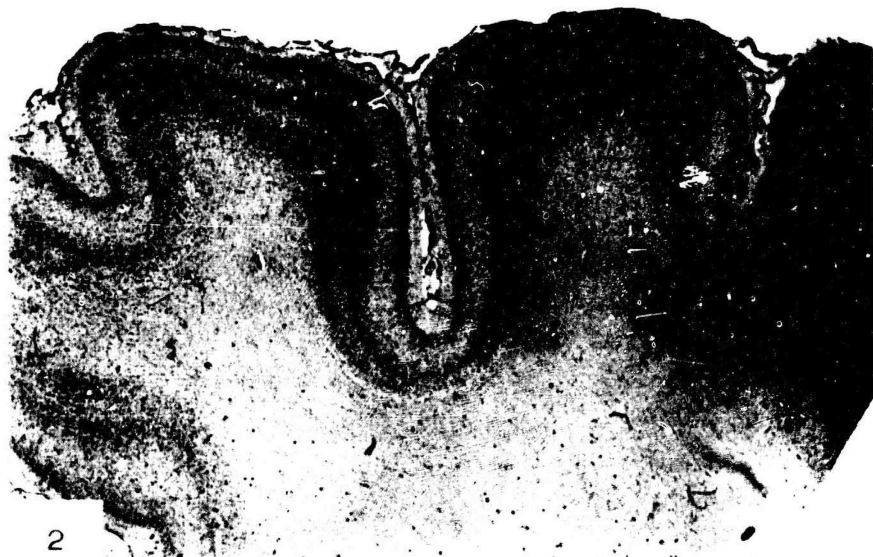
Abstract: 43 cases of complete cerebral ischemia and of hypoxemia are microscopically investigated and the results compared as to the histology, topography and topistic pattern of the lesions. Whereas in ischemia

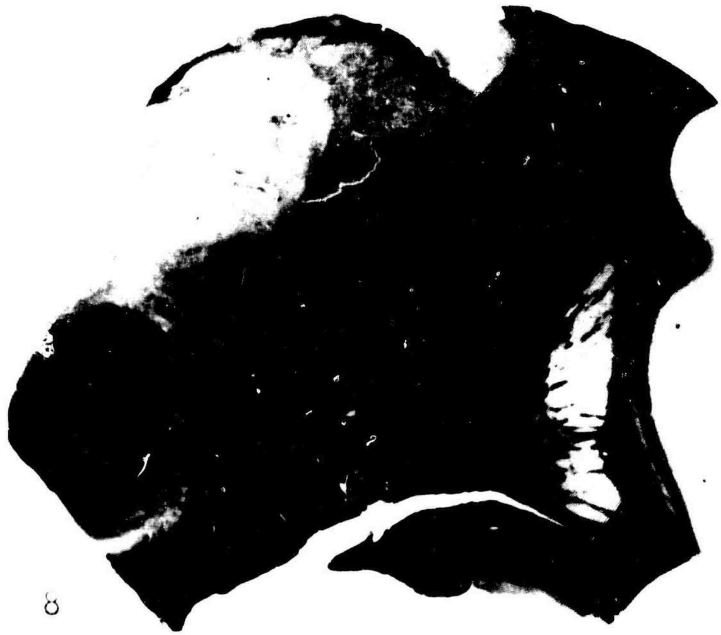


the lesions are localized in the cerebral and cerebellar cortex; the basal ganglia are the preferred site in hypoxemia. The effect of acute energetic insufficiency on the fine structures of nerve cells and its reversibility has been studied.

the lesions are localized in the cerebral and cerebellar cortex; the basal ganglia are the preferred site in hypoxemia. The effect of acute energetic insufficiency on the fine structures of nerve cells and its reversibility has been studied.

the lesions are localized in the cerebral and cerebellar cortex; the basal ganglia are the preferred site in hypoxemia. The effect of acute energetic insufficiency on the fine structures of nerve cells and its reversibility has been studied.

the lesions are localized in the cerebral and cerebellar cortex; the basal ganglia are the preferred site in hypoxemia. The effect of acute energetic insufficiency on the fine structures of nerve cells and its reversibility has been studied.



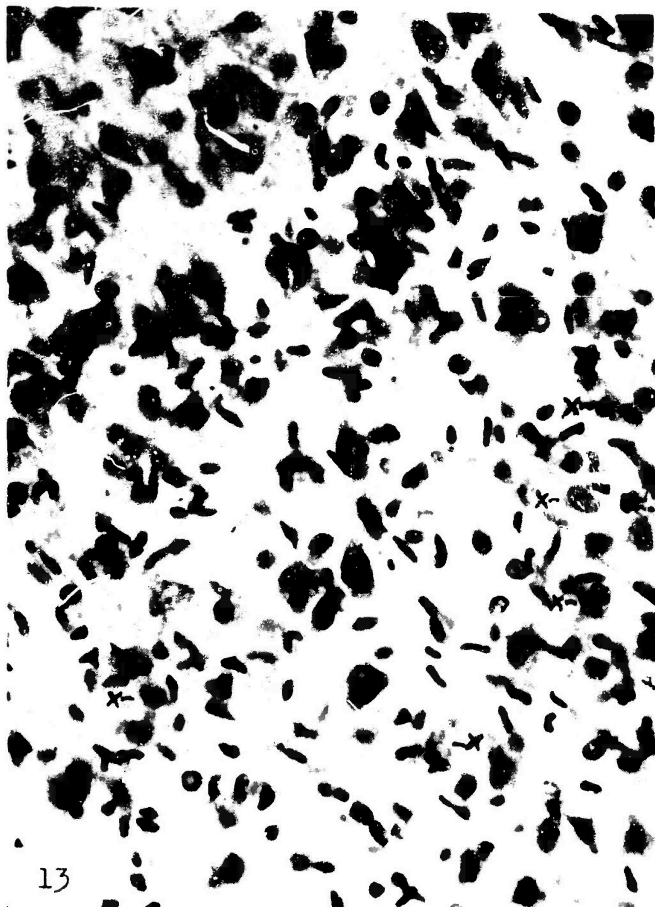





11




12



13



14



15



| 16



17

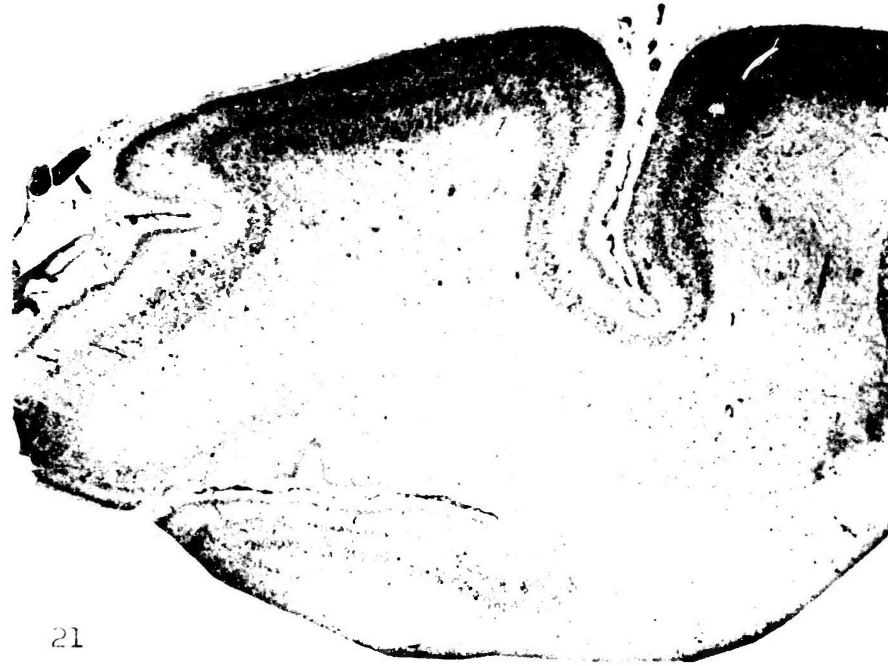


18



19

20



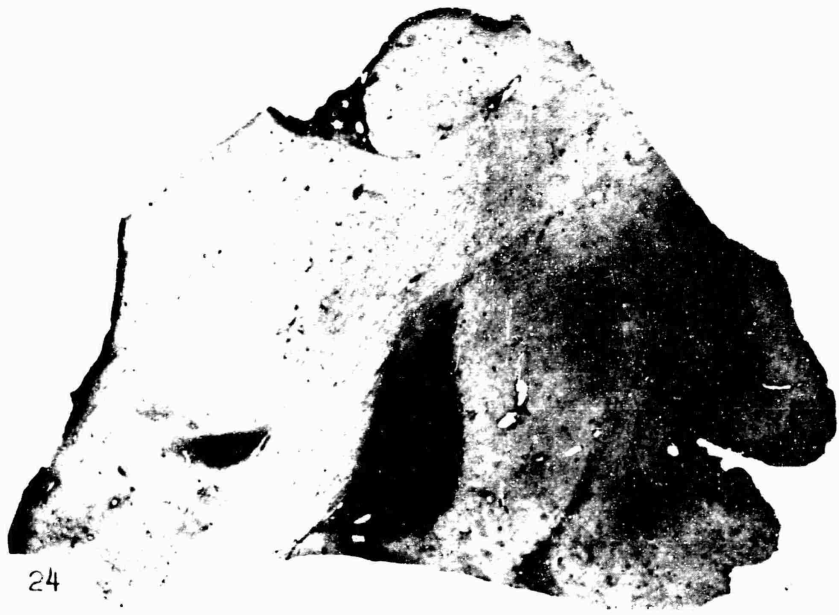
21




22



23



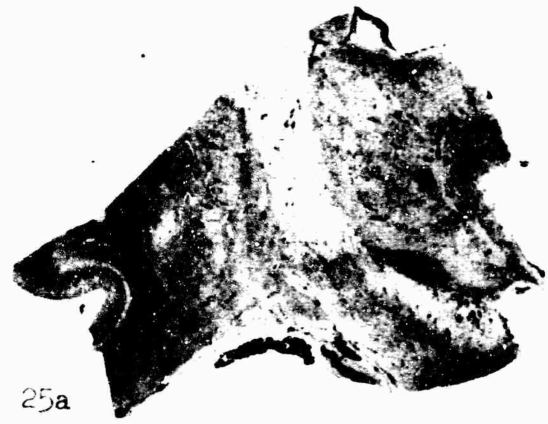24



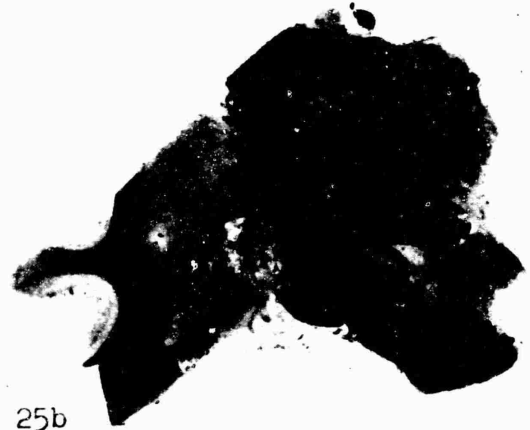26



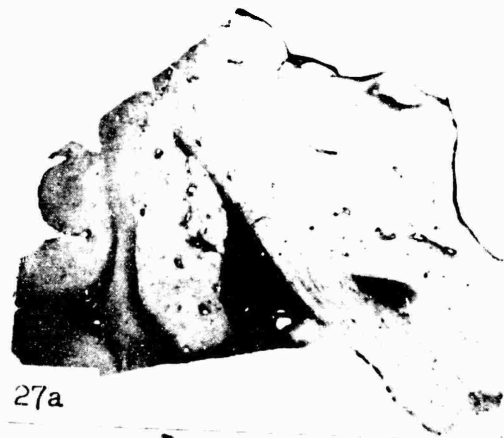28



25a



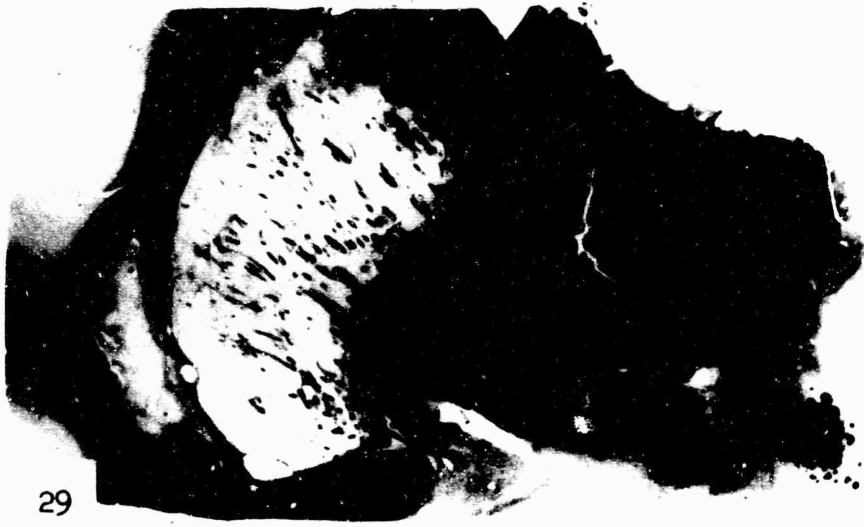25b




27a



27b



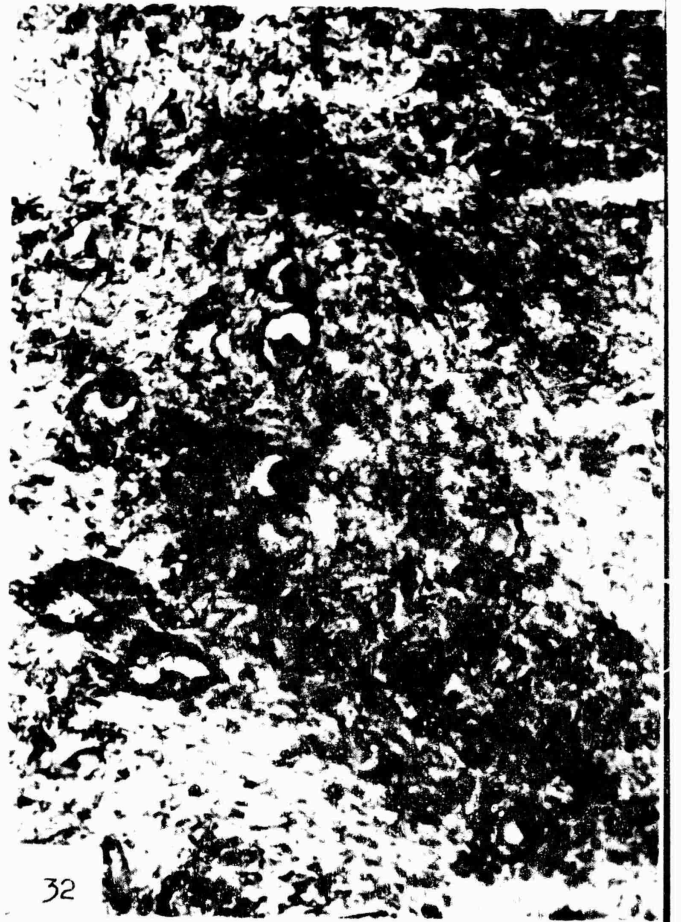29



30



31



32



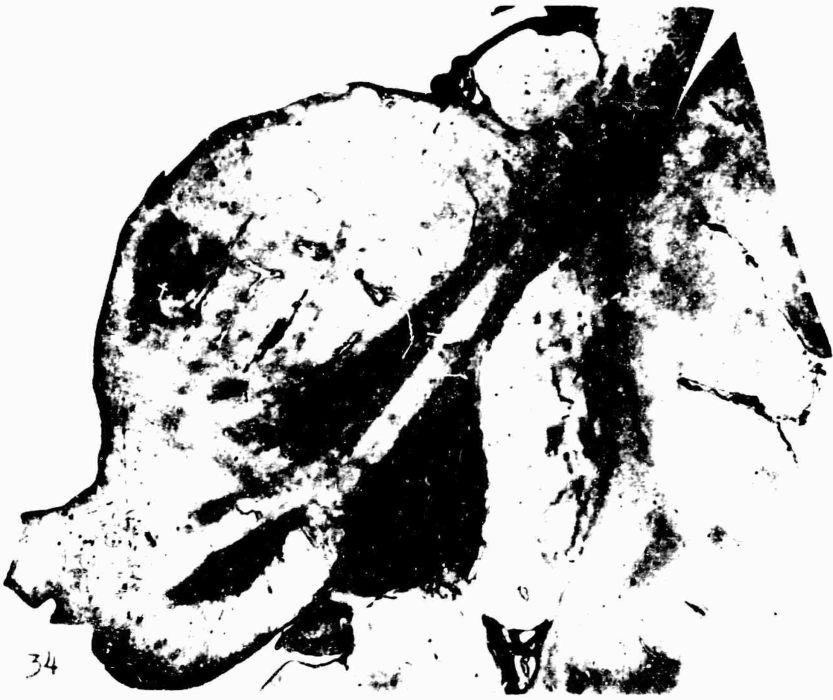33



34



35



34



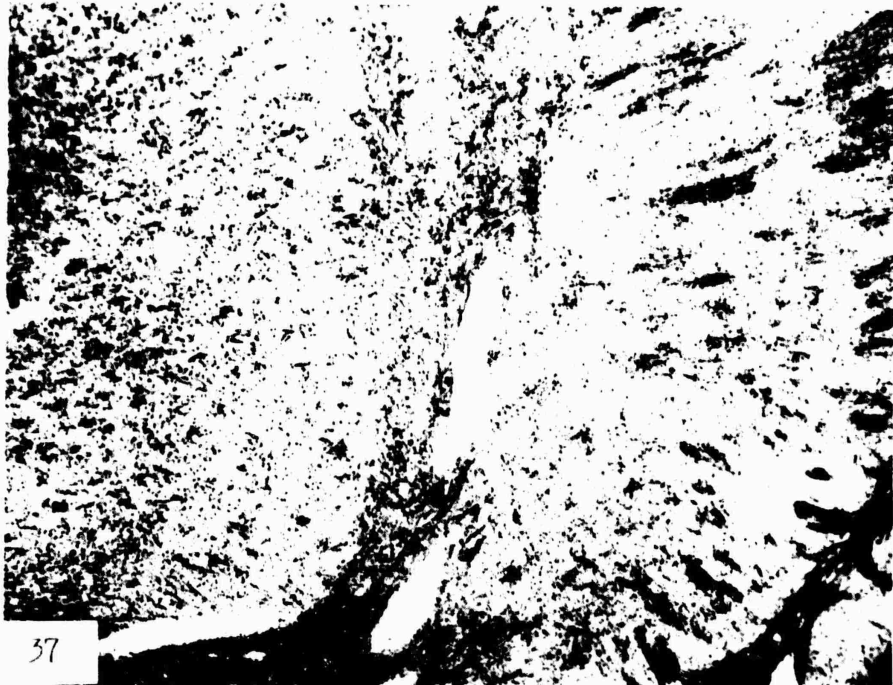36a



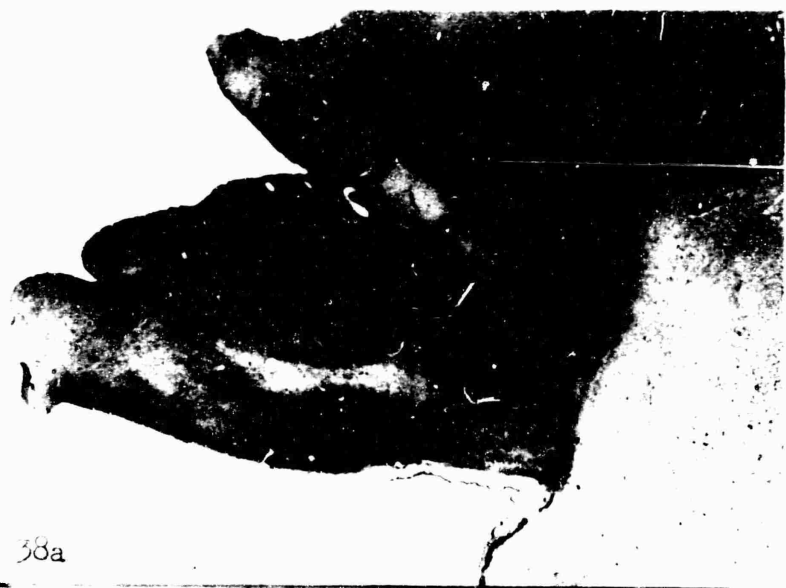35



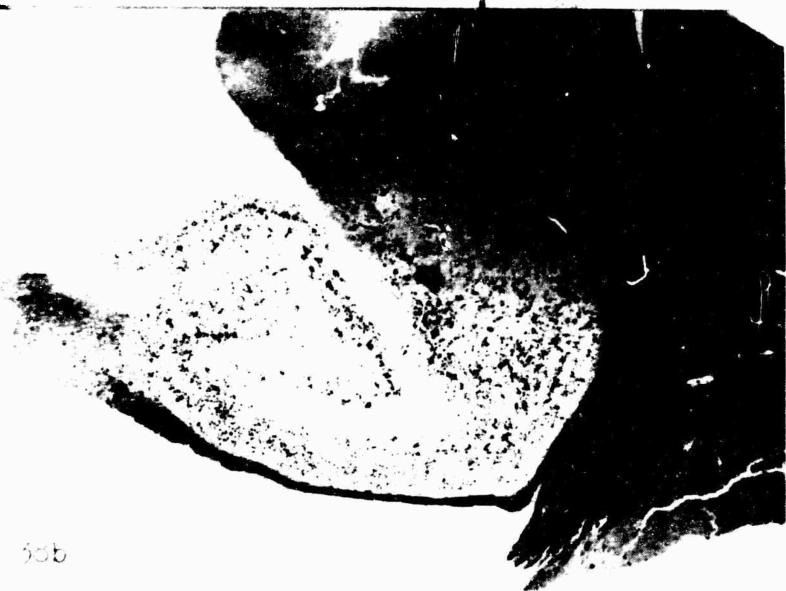36b



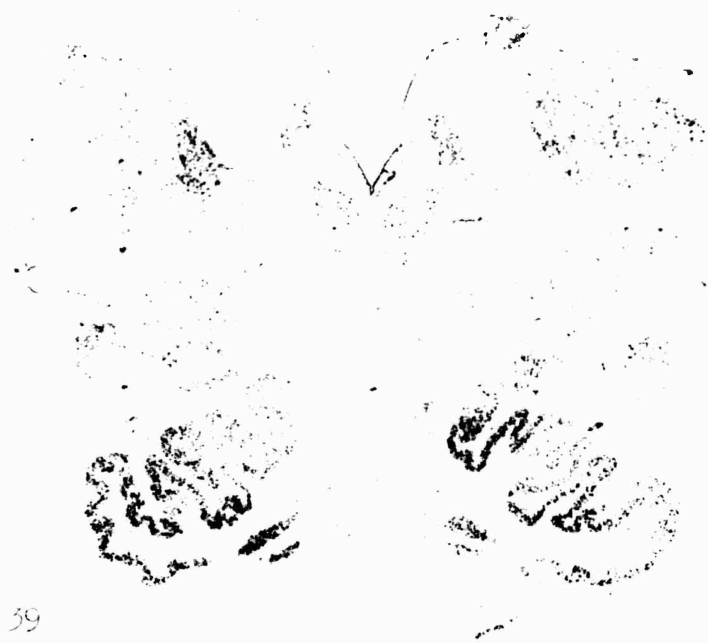
37



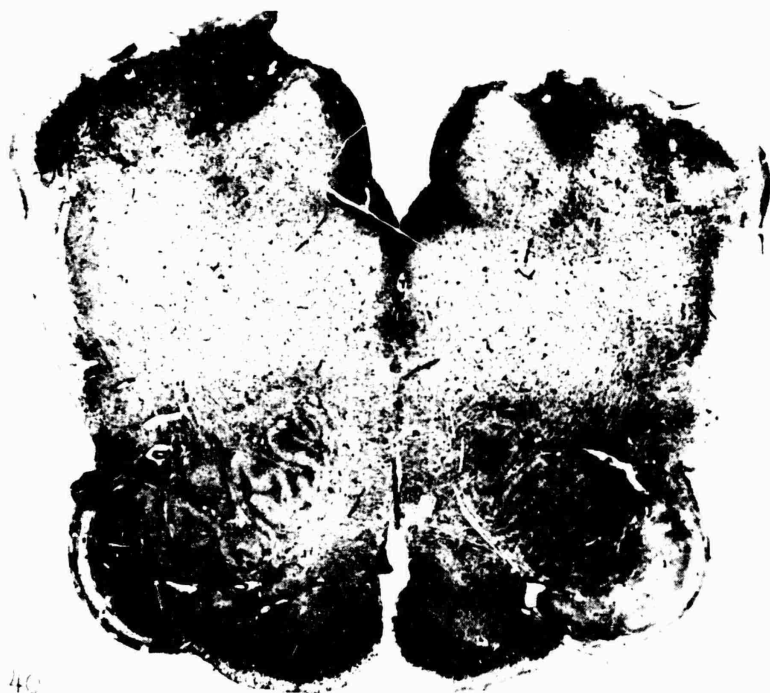38a




38b



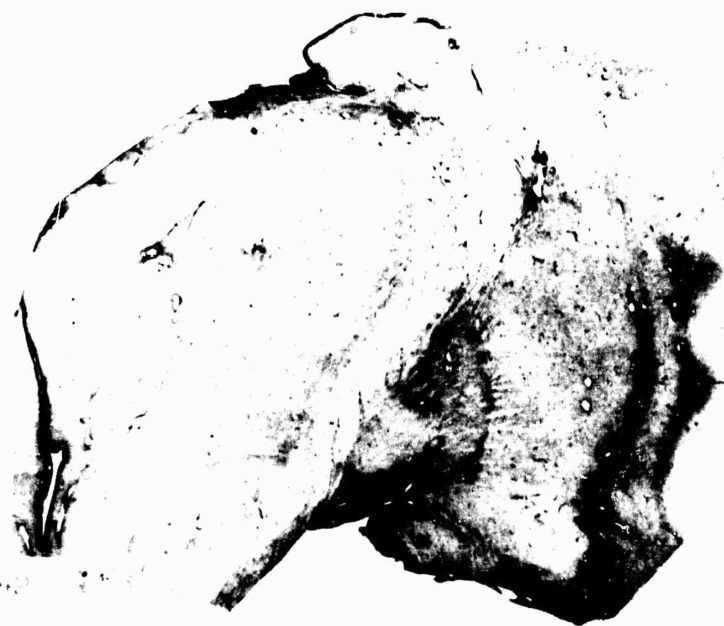39



40




41



43

44

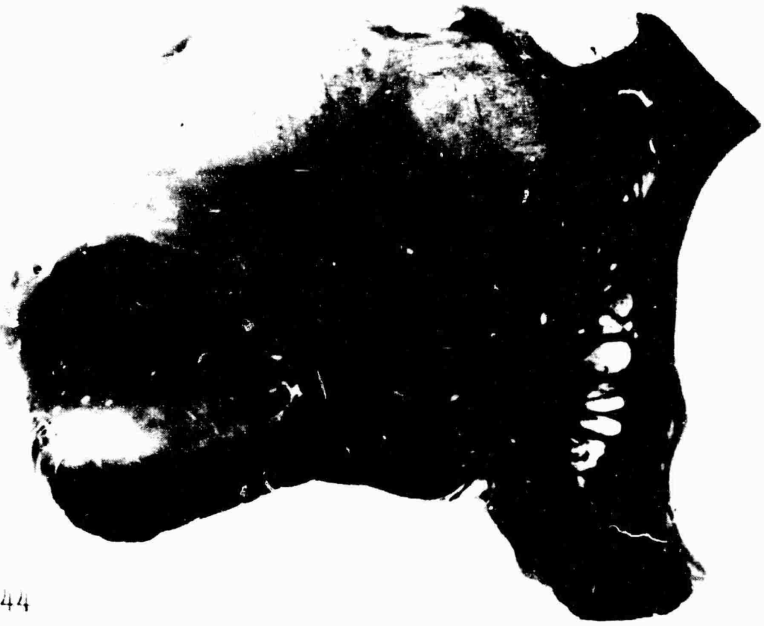46



43



47



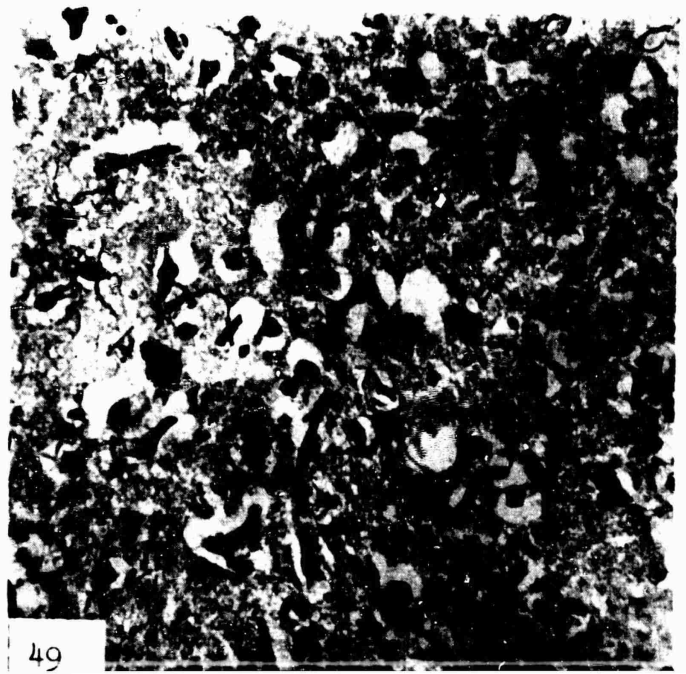
44



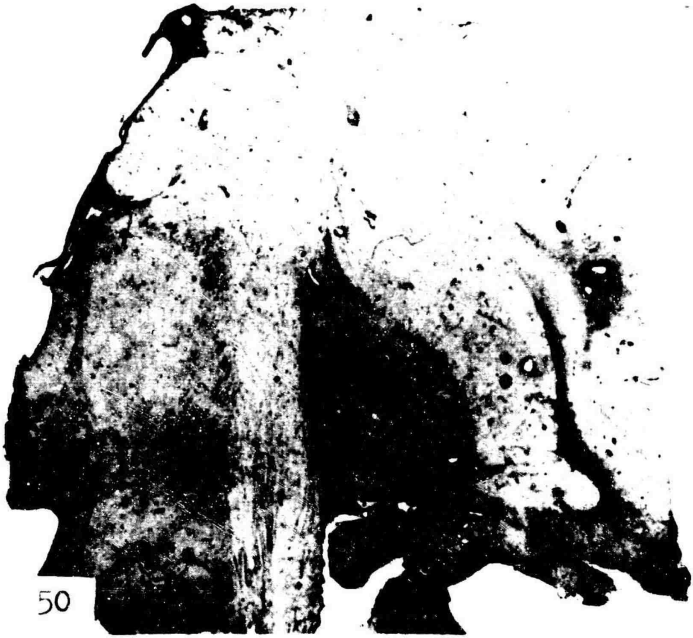48



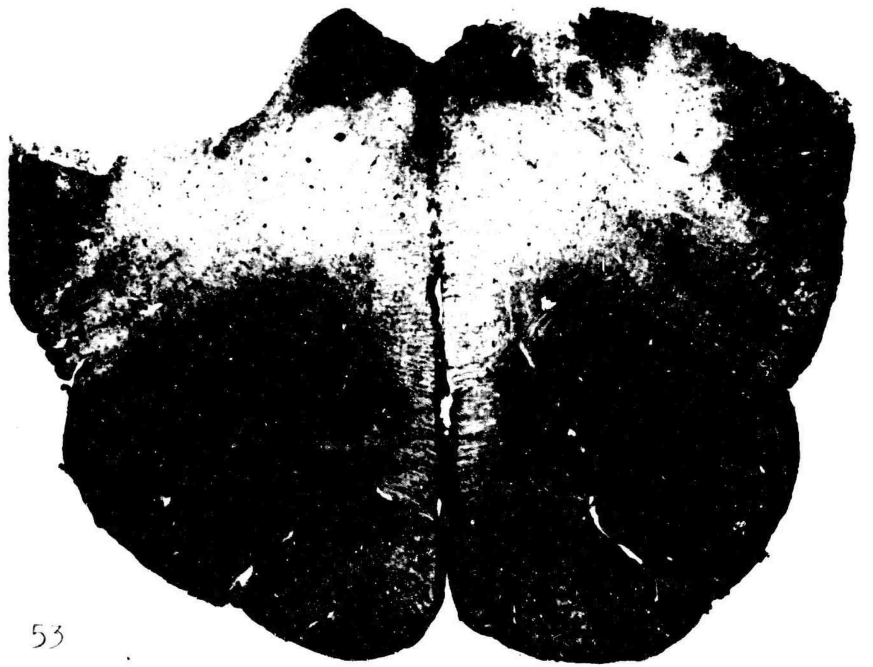46




49



50




53



51




54




52



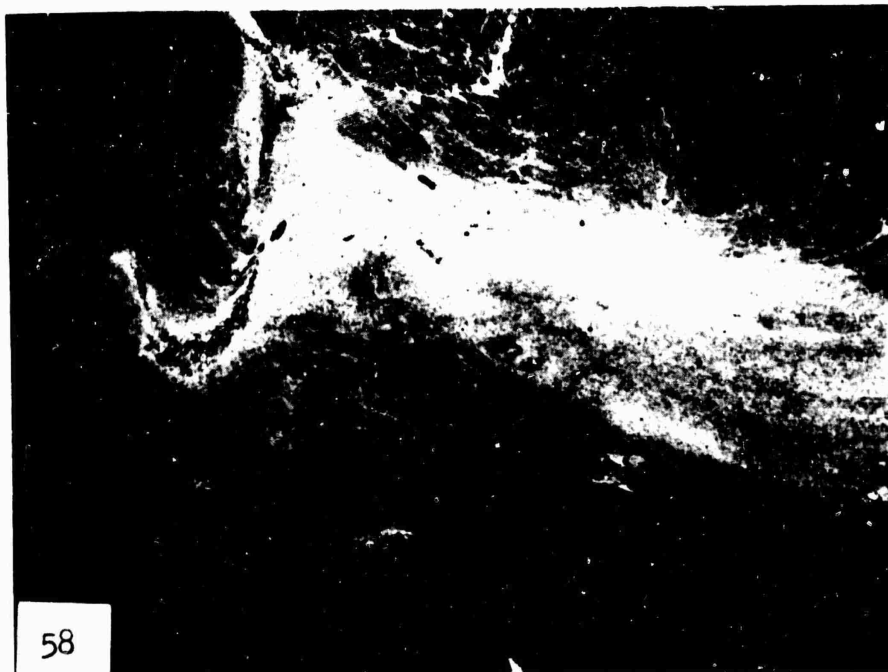
55



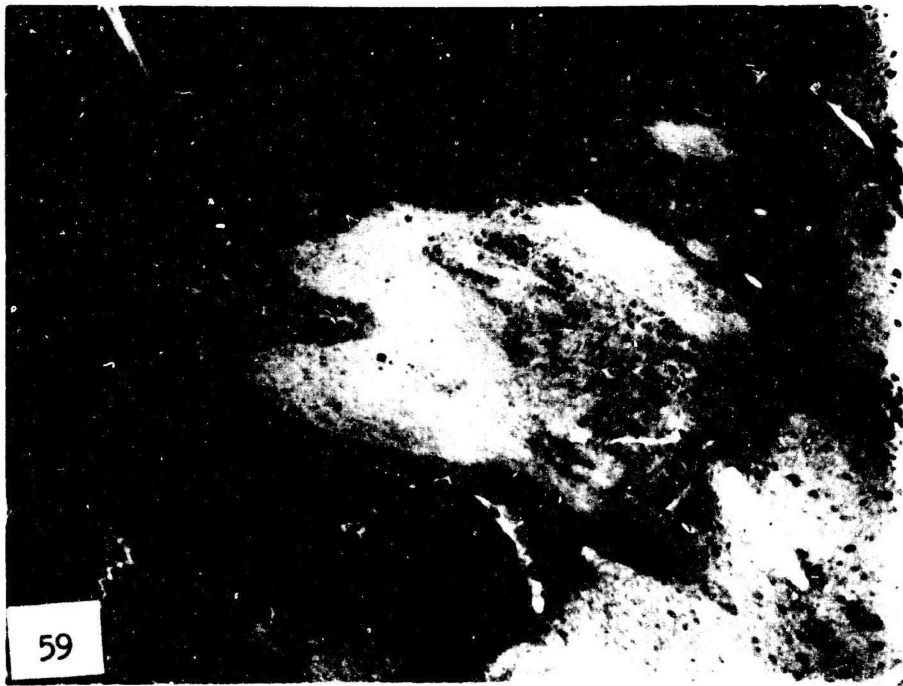56



57




58



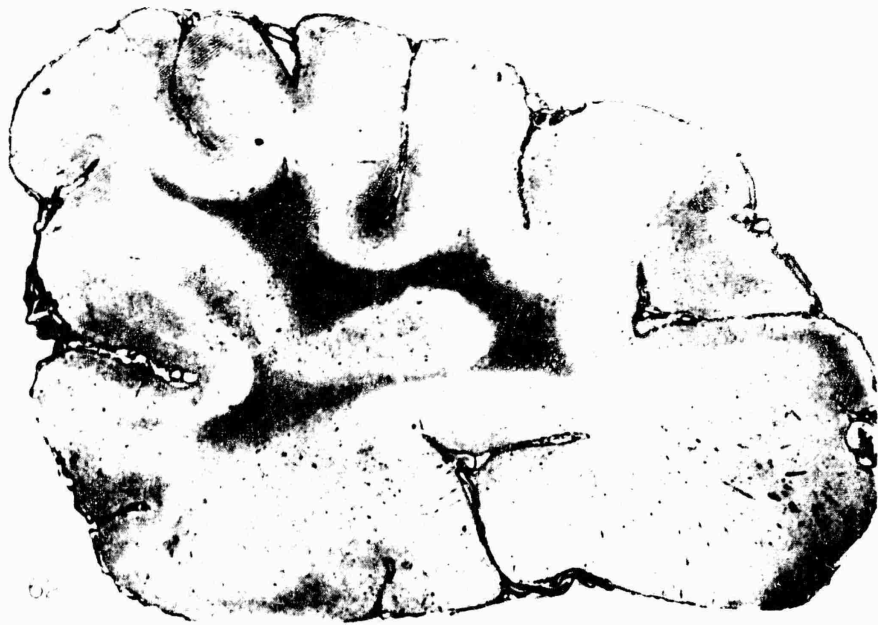59



60



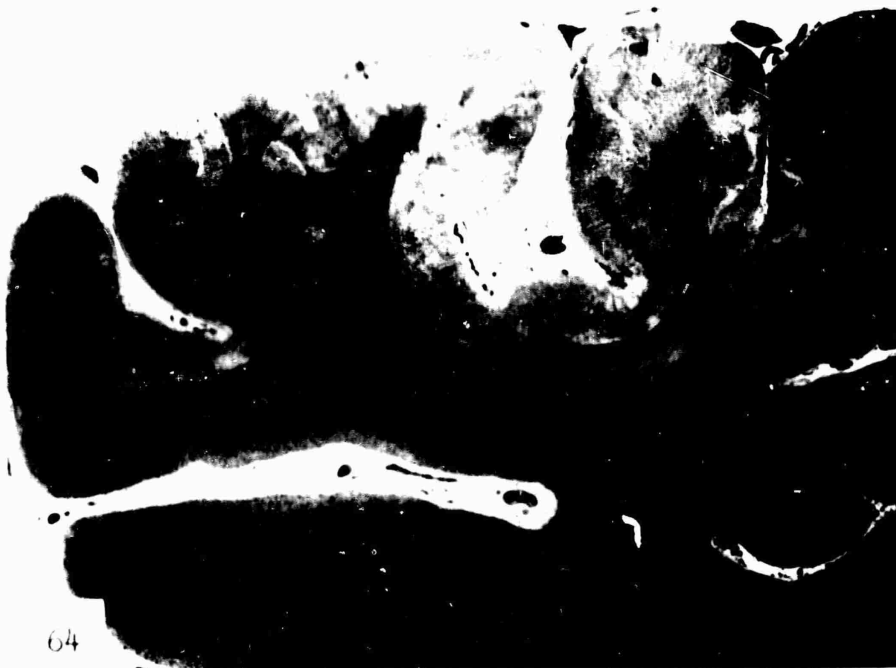61



62



63



64

TOXICITY CHANGES IN THE CENTRAL NERVOUS SYSTEM

OXYGEN DEFICIENCY AND ITS INFLUENCE ON THE CENTRAL NERVOUS SYSTEM

PART II

by Professor Dr.med. W. Scholz and Dr.rer.nat.Dr.med.H. Hager

A) Electronoptic Studies on the Earliest Structural Changes of the Brain Caused by Hypoxidosis.

In the beginning of medical research on hypoxidosis, the experimental work dealt chiefly with the pathophysiologic reactions of men and test animals under hypoxic conditions. Not until recently have studies on the morphologic effect of acute oxygen deficiency been added. Experimental work on the changes in the central nervous system, as a result of acute atmospheric hypoxia has been performed by BÜCHNER and LUFT (1936), ROITER (1938), THORNER and LEWY (1940) and ALTMANN and SCHUBOTHE (1942). In these investigations, attention was primarily focused upon permanent damage or late sequelae. The types of change and their localization were explored. Nerve cell necrosis was the predominant damage in the central nervous system in acute hypoxia. Cell necrosis indicates the irreversibility of catabiotic processes. It is impossible to draw conclusions between these processes and the structural changes. It was thought that electron microscopical investigations in hypoxidosis might provide new information, concerning the pathological changes which are beyond the limitations of light microscopy. It was soon apparent that under suitable conditions structural alterations of peculiar type could be evoked in the cell organelles. Some of these alterations were reversible. Under various experimental conditions, BERNHARD, GANSLER and ROUILLER and POCHE have carried out investigations on the cell elements of liver, kidney as well as of the heart muscle. MÖLBERT, MÖLBERT and GUERRITORE studied the fine-structural changes in liver and heart-muscle cells caused by hypoxemic and dysenzymatic hypoxidosis. STRUGHOLD introduced the term hypoxidosis as signifying the biologic effect of oxygen deficiency. Hypoxidosis

develops if there is a disproportion between the supply and needs of the cell in any of the substances which take part in the biologic oxidation. If one modifies STRUGHOLD's classification, three types may be differentiated: 1. Oxygen deficiency hypoxidosis, 2. Nutritional deficiency hypoxidosis, 3. Enzyme deficiency hypoxidosis. It was the problem of this investigation, to induce oxygen deficiency hypoxidosis and to determine the effect of acute energetic insufficiency, on the fine structures of the nerve cell. In order to obtain knowledge of the normal structures, and to establish a basis for comparison, parallel examinations of the central nervous system in normal animals were made using the same technique.

Material and Methods.

The danger of errors, caused by fixation artefacts, is especially great in the central nervous system. As is known, osmic acid penetrates the tissue blocks very slowly, so that in the centers of the tissue blocks, taken from living material, there results a form of change which is difficult to distinguish from changes, caused by intravital hypoxidosis. The preliminary studies on material fixed after biopsy were not only difficult and time consuming but they were unreliable. A special method elaborated by us proved to be more reliable for this study.

The Syrian hamster was chosen as test animal because of his physical resistance and easy availability. A standard fixation mixture of 1 per cent OsO_4 , buffered at p_H 7.2 with veronal acetate buffer, as described by PALADE, was used on the living, ether narcotized animal, for the purpose of fixing the brain by perfusion. After a quick operative exposure of the heart, the fixing solution was injected while the arterial system to the distal portion of the body was partially blocked (method: open thorax, open the left ventricle, introduce a button tubule in the ascending aorta, pinch off the descending aorta. The time: for opening the thorax and the ventricle 40 to 60 sec.; 30 to 50 sec. interval before the start of the irrigation). After completion of the perfusion, the skull was removed and tissue blocks were obtained from the rostral, middle and caudal regions of the mediodorsal cortex. Portions of the cerebellum and upper cervical spinal cord segments were not taken and examined routinely. These parts were usually poorly fixed. The tissue

blocks to be embedded were refixed for 2 - 4 hrs. in cooled buffered 1 per cent osmiumtetroxide solution. After washing in distilled water and dehydration, the tissue samples were infiltrated with a mixture of destabilized butyl- and methylmetacrylate (9:1), to which 1% benzoylperoxide is added. The polymerization of the mixture was achieved in gelatine capsules which were placed in an oven at 55° C for about 12 hrs. Under microscopic control, pyramids were trimmed in suitable areas of the block. The ultrathin tissue was cut on two ultramicrotomes (PORTER-BLUM and LEITZ), using glass knives. Sections were placed on coppermesh grids which were prepared with formvar foils. The electronoptic examination was done with two different instruments⁺) (ZEISS EM 8, ray voltage 50 KV, and SIEMENS Ü 100, ray voltage 60 KV).

Animal Experiments.

For the purpose of gross orientation regarding the patho-physiologic response of the animals after were subjected to CO-poisoning a small series of tests was then carried out at low atmospheric pressure, employing a special steel chamber with observation window. The pressure in the chamber was recorded by a mercury manometer, the evacuation being achieved by a metal water jet pump. The Syrian hamsters, in the acute low pressure test, revealed a poor adaptability to altitude. The animals rapidly became restless, developed disturbances of equilibrium, staggering and tumbling as they tried to move about. Upon approach of the critical threshold, the mobility was decreased, whereas the respiratory rate was definitely elevated. Subsequently, paresis of the legs developed. Gasping respiration and severe paresis occurred at a barometer reading of 438.0 mm. A large number of the animals died. The animals which survived were quickly removed from the chamber. Their brains were fixed in the above described manner. Survey studies with oxygen-nitrogen mixtures were also carried out. The oxygen and nitrogen were admitted to a water filled glass balloon of 60 liter capacity, using gas meter devices. In this balloon a mixing took place. The gas mixture was finally replaced by water and subsequently, via a gas meter, admitted into a container, which harbored the test animal. It could be demonstrated that a mixture of about 3 parts oxygen

+) Instruments of the 2nd Institute of Physics, University of Munich

and 97 parts nitrogen evokes symptoms which approximately correspond to the reactions elicited within the critical low pressure range. The time of gas flow varied from 30 to 60 min. The mode of procedure rendered it difficult to reproduce the exact oxygen-nitrogen mixture and to obtain adequate reactions of the animals. Therefore this method was not again employed. Exposing the animals to a pure nitrogen atmosphere was found to be more suitable for the purpose of producing peracute asphyxia. The animals, after 30 - 60 sec. in nitrogen, developed severe respiratory disturbances by gasping respiration. The animals were brought back into the air and the asphyxia was then repeated. Within a maximum period of 15 min., 10 - 12 severe attacks of asphyxia were induced. The brains of the animals were fixed in the manner outlined above.

In order to produce a dysenzymatic hypoxidosis, potassium cyanide was used. The CN-ion retards the action of the cell cytochromoxidase and thus interferes with the electron transport to molecular oxygen which, therefore, cannot combine with ionized hydrogen to form water. By means of cyanide poisoning, it is possible to eliminate approximately 90% of cell respiration. Preliminary studies were necessary to determine the adequate quantities of substance and the method to be employed. The smallest dosages of potassium cyanide which evoked more or less severe symptoms of poisoning were determined. A dosage from 0.1 mgm to 0.07 mgm KCN in aqueous solution proved to be suitable. The solution was injected subcutaneously into the dorsal region of the pelvic area of the animals. After 10-20 min. a mild paralysis developed which finally lead to a more or less deep comatose state. 0.07 mgm proved to be the optimal dosage for our experiments. The brains of the animals were fixed in intervals of 20 - 60 min. after injection. An experiment was made using 2,4-dinitrophenol which is supposed to cause a so-called uncoupling of respiration and phosphorylation. The effect varied in each animal because of the strong cerebral influence exerted on the cerebral blood flow; this was interpreted as vasoconstriction. Therefore the tests were discontinued.

Under the same technical conditions, the fine structures of the nerve cells of the cortex were studied in control animals.

Normal Findings.

The normal ultrastructure of cortex nerve cells of the Syrian hamster.

With the electronmicroscope, a number of submicroscopic structures are identified in the nerve cells of the cortex of mammals (Fig. 1, 2). Embedded in the cytoplasm are found numerous large, more or less oval, elongated profiles which represent sections of mitochondriae (Fig. 1, 2, 3, 4). These are encased in a double membrane which exhibits two dark well contrasting layers with a poorly contrasting zone lying inbetween (Fig. 4). The inner space of these small organelles is filled with a system of transversely arranged, parallel, double membranes which are of the same dimensions as the outer membrane. These inner membranes are embedded in a homogeneous ground substance. The submicroscopic basis of the Nissl substance are the structures belonging to the endoplasmic reticulum of the American authors (ergastoplasm) (Fig. 3). Considering three dimensions, we deal with a system of cavities which may be compared with the pores of a sponge. This system is composed of membranes which separate communicating tubules, vacuoles, trabeculae and plates. Exterior to the inner spaces of the endoplasmic reticulum, namely in the ground cytoplasm are found osmophile, dark and obviously compact granules (Fig. 3). The latter are attached to the membranes of the endoplasmic reticulum, either diffusely or packed in clusters, and partially in a pearl-string-like arrangement. These dense osmophile granules were also carefully studied in nerve cells by PALAY and PALADE (1955). The studies revealed that the granular component may be regarded as the substrate of the basophilia of the nerve cell protoplasm. These granules represent the essential portion of ribonucleotide substance of the microsomic fraction which is separable by centrifuging the cell homogenates. The so-called Golgi zone is characterized by a fine double membrane system, free of granules. Several of these membranes are often packed together and have close contact to other larger, membrane bordered vacuolar spaces. Furthermore, the nerve cell cytoplasm contains strongly osmophile corpuscles of dense homogeneous substance, which do not quite attain the size of mitochondriae (Fig. 2). They sometimes contain small light vacuoles. Also, there are equally large bodies, filled with a moderately osmophile, somewhat loosely arranged substance, confined in a singly-layer membrane. Such inclusion bodies in the ground substance

are called lipochondriae or liposomae, because of their osmophilia. The osmophile parts of the nucleoplasm (Fig. 1, 2) inside the nerve cell nucleus, are loosely distributed in a flaky manner. A denser accumulation of substance is occasionally found on the nuclear membrane. The nucleole (Fig. 1, 2) is composed of granular, deeply osmophile, partially thread-like aggregated, densely packed substance, usually containing a few light irregularly bordered vacuoles. Often, there are loose, weaker osmophile substances affixed to the nucleus representing the paranuclear corpuscle.

Findings after Hypoxemia and Dysenzymatic Hypoxidosis.

1. Observations from repeated peracute asphyxia by pure nitrogen.

The brains of the animals were fixed immediately after the repeatedly induced nitrogen asphyxia which lasted 12 - 15 min. each. A considerable portion of the cerebrocortical nerve cells revealed remarkable changes. In the area of the perikaryon, fine-structural changes, corresponding to the arrangement within the Nissl substance, were found (Fig. 5, 6). The membrane systems were separated, and frequently the inner spaces of the endoplasmic reticulum were expanded to large vacuoles. The more severely altered cells showed a breakdown of the continuity of the membrane systems. The granules named after PALADE, were clumped and often severely rarefied. These alterations were most marked in the peripheral zones of the perikaryon, close to the cell membrane. In the vicinity of the nuclear membrane as well as in the nuclear folds, the endoplasmic reticulum was, as a rule, better preserved (Fig. 5). The entire perikaryon appeared to be swollen and thus enlarged. Pronounced changes were also detected in the mitochondriae. Different kinds of mitochondrial damage were observed (Fig. 6, 7). The mildest form consisted in vacuolization of the matrix and clubbing of the inner membranes. More intensive changes manifested themselves in complete disorganization of the inner membranes which became fragmented. In this stage, the matrix usually appeared grossly loosened or disappeared almost completely. On the other hand there were mitochondriae which showed an increased swelling. In areas of the inner membranes, there were additional fragments which were attached to the outer membrane and which projected stump-like into the interior. Finally, fairly large vacuoles seemed to have developed from the swollen mitochondriae. These elements were bordered by the intact

outer membrane and appeared almost empty. The increase of volume was significant. The nuclear contents and the nuclear membrane did not show such profound changes. The nuclear substance frequently lay at the periphery. Often, one observed clumping or the osmophile parts of the nucleoplasm forming masses or denser clots.

2. Findings after acute low pressure tests.

The critical level of the lowered atmospheric pressure apparently lies rather low for the Syrian hamster. The few animals which survived the lowering of the pressure to values of 420 mm, exhibited changes in numerous cells of the cortex. These changes closely resembled the ones, observed after repeated nitrogen asphyxia. The alterations of the endoplasmic reticulum showed the same characteristics and were equally present in many cells (Fig. 8, 9, 10). Occasionally, only the above described small-vacuolar changes of mitochondriae were found in the more severely altered cells (Fig. 9). To some extent, the nerve cell nuclei demonstrated finely distributed or densely clumped chromatin substance. The strongly osmophile liposomes (lipochondriae) which are usually seen in the cytoplasm of the nerve cells, did not reveal any changes.

3. Findings after potassium cyanide poisoning.

All animals that survived the injection of 0,7 mgm of potassium cyanide by 15 - 40 min., usually developed severe symptoms such as paresis, coma and tonic convulsions after a period of 15 min. The nerve cells of the cerebral cortex were altered in each animal. These alterations basically revealed the same features as described above, after nitrogen asphyxia and after low pressure experiments (Fig. 11, 12, 13, 14). The findings in the endoplasmic reticulum and in the peripheral zones of the perikaryae, were rather significant. Within the folds of the nuclear membrane the structures were better preserved. The mitochondriae were partially vacuolized. To some extent significant swellings occurred within the matrix. The inner membranes were destroyed. The nucleus rather frequently showed pyknosis of the nuclear substance as a result of a large clumping. The nucleolus was sometimes found to be located either at the nuclear membrane or in its vicinity (Fig. 15).

Rarely, the nucleus associated body established a link from the nucleolus to the nuclear membrane. An unequivocal increase of microbodies, which are rounded corpuscles of denser osmophile substance that ROUILLER and BERNHARD believed to be the first stage of mitochondriae, was not often found in the perikaryon of damaged nerve cells.

Discussion.

The work reported here was concerned with the changes of ultrastructure of nerve cells in the cerebral cortex of animals subjected to experimentally induced hypoxidosis of varied type. It is obvious, that the changes are to be considered as direct or indirect sequelae of an acute energetic insufficiency of the cell. The fine-structural changes consist of a progressive expansion of the inner spaces of the endoplasmic reticulum to large vacuoles, with the process originating at the periphery and proceeding to the central parts of the perikaryon. Also, changes of the inner structures and intense swelling of the mitochondriae occur. It is believed that the endoplasmic reticulum assists in the intracellular circulation of many different substances (PALADE). In this system, which is bordered by membranes, the cytoplasm is divided into two phases. The fine-structural changes, caused by acute hypoxidosis of the nerve cells, are best interpreted as a disturbance of the water exchange of the cell, resulting in an intraplasmatic accumulation of water. The endoplasmic reticulum behaves *in situ* as well as *in vitro* like an osmometer that responds sensitively to alterations of osmotic pressure and water displacement. It is known that the difference in the osmotic pressure between the interior of the cell and the extracellular space demands continuous consumption of energy. The activity of the terminal respiratory enzyme is altered under hypoxidotic conditions, either by withdrawal of the substrate (oxygen) causing oxygen deficiency as in nitrogen atmosphere and in the low pressure experiment or by retardation of the activity of the cytochromoxydase system by the CN-ion. Each situation reveals a rapid diminution of energy production. As to the disturbance of the water exchange, the increase of the intracellular osmotic pressure is to be considered an important factor. The rapid elevation of the latter in the cytoplasm under hypoxidotic conditions has been demonstrated with

physiological methods (BATTAGLIA et al. 1958), and was verified by experimental studies. One may assume, that such an increase of hyperosmosis is caused by an increase of the intracellular concentration of osmotically active particles. This may be due mainly to the limitation of final oxidation of the metabolites. Therefore, an accumulation of acid, low-molecular metabolites occurs under hypoxic conditions since, to a certain extent, an anaerobic glycolysis takes place in the brain. This was proven by THORN et al. (1958), who observed a rapid elevation of the lactic acid concentration in the brain under hypoxic conditions. The strong reduction of the so-called Palade granules, as demonstrated by us, points to a process of rapid depolymerization of the plasma ribonucleotides. After suppression of the cellular reactions supplying energy, it could frequently be demonstrated according to ALTMANN that a very rapid diminution of the cellular basophilia develops. DUSPIVA and NOLTENIUS (1957) pointed out that an energetic insufficiency of the cells induces a disturbance of the water excretion. This is impressively demonstrated by the pulsating vacuole of protozoae. Hydrocyanic acid poisoning rapidly diminished the pulsation and thus the water excretion from the cytoplasm. The reduction of free energy produced in the cell causes separation of fluid from the cytoplasm. According to BÜCHNER, this process leads as microscopically demonstrable to vacuolization within the parenchymal cells of the liver which are localized in the center of the lobules. Likewise the heart muscle fibers exhibit cell edema and decomposition of the fibrillar structures. BÜCHNER reports cases in which OPITZ applied a cuff to the neck of rabbits and thus interrupted the blood flow of the brain for 40 min. 20 min. later the animals were killed. Changes in the nerve cells were recognizable and interpreted as severe acute cytoplasmatic edema. MÖLBERT and GUERRITORE (1957), and MÖLBERT (1957) electron-optimally demonstrated a progressive development of large vacuoles originating from enlarging internal spaces of the endoplasmic reticulum of parenchymal liver cells under conditions of hypoxemia and dysenzymatic hypoxidosis. This was interpreted as a disturbance of the cellular water exchange and due to a rise in the intercellular osmotic pressure.

Especially in cyanide poisoning of animals have we frequently found a

peripheral position of the nucleolus and the paranucleolar chromatine. The granular endoplasmic reticulum was, as a rule, better preserved around the nucleus. Agreeing with the presumption of CASPERSSON, MÖLBERT interpreted similar findings as an increased activity of the nucleus associated body and also as a sign of the formation of the new plasma ribonucleotides. We cannot definitely decide whether our observations on nerve cells point toward such activity of the nucleus associated body.

The first stages of mitochondrial damage are mild vacuolizations of the internal mitochondrial area with simultaneously existing, far advanced alterations of the ergastoplasm. In advanced stages, severe changes or, as often called, transformations of the mitochondriae to vacuolar bodies occur. They are followed by disorganization of the inner membrane system, loosening of the structures and finally disappearance of the matrix. The increase of volume is considerable. Whether the first development of vacuoles is predominantly taking place within the osmophobe layers of the inner membranes, as observed in isolated mitochondriae by LEVER and CHAPPELL, cannot be determined accurately. The final products are vacuoles which are either empty or filled with residual matrix. Based on several observations, it is assumed, that the mitochondrial changes are reversible, as long as the external membrane remains intact (GANSLER and ROUILLER, MÖLBERT). The density of the matrix is observed to increase again, while the internal membranes are regenerating. The so-called bulbous transformation of the mitochondriae in acute hypoxidosis of the liver and heart was observed by MÖLBERT (1957), MÖLBERT and GUERRITORE (1957). A uniform type of transformation of mitochondriae secondary to hypoxidosis was seen in the following instances: if fixation was not done within a very short time (RHODIN 1954, ZETTERQUIST 1956); in agony (observations of the heart by MILLER 1958); in ventricular arrest after overdose of digitalis glycosides (LINDNER 1957); and in ischemia of the skeletal musculature (MOORE, RUSKA and COPENHAVER 1956). These typical changes of the mitochondriae were also encountered in other organs, namely, after thyroxin action on the liver (SCHULZ et al. 1956), after phosphorus poisoning of the heart muscle (POCHE 1958) and after acute severe starvation in liver and kidney (GANSLER and ROUILLER 1956). The changes

of the mitochondriae may be of essential importance in regard to the energy providing processes of the cell. Biochemically seen, the mitochondrion presents itself as a multi-enzymatic system, which is encased by membranes. The respirations as well as the production of energy are effects of these organellae (LINDBERG and ERNSTER 1954). They contain the different enzymes for the respiration and for the oxidative phosphorylation, partial links of the citric acid cycle.

The fine structure of the mitochondriae possibly represents the basis for a certain arrangement of the enzymes, corresponding to the sequence of the reaction chains. Topographically, there is still little known about the arrangement of the enzymes within the mitochondriae. Some studies on this subject have been done by BARNETT and PALADE 1957. ALTMANN (1955) attempted to explain the mitochondrial changes in hypoxidosiis by the decoupling of respiration and phosphorylation. After the consumption of the energy binding phosphate compounds, which are produced in the mitochondriae, changes should be expected primarily in these organellae (MILLER 1958). The fine-structural alterations are supposed to be secondary to the mitochondrial damage. In contrast to that, we have found especially in KCN-poisoning only minor changes of the mitochondriae along with profound changes of the endoplasmic reticulum. DUSPIVA and FRANKEN (1957), DUSPIVA and NOLTENIUS (1957), have biochemically studied the liver tissue in which MÖLBERT and GUERRITORE had observed severe mitochondrial changes due to experimental hypoxidosiis. They could demonstrate neither an alteration of balance within the pyridin-nucleotide system, which plays a role in the hydrogen transport, nor a significant change of the adenosin-polyphosphate fractions.

Liver cells are capable of forming adenosin-triphosphoric acid (ATP) anaerobically, provided there is a good supply of carbohydrates; in consequence the concentration does not decrease initially. The glycolysis in the brain tissues, however, is not capable of maintaining the ATP-concentration under hypoxic conditions (THORN, SCHOLL, PFLEIDERER and MUELDENER 1958). So far, no coordinated investigation has been done in regard to the changes of the fine structures of mitochondriae, nor to the alterations of enzymes, energy-enriched phosphates and metabolites.

Therefore, the direct factors causing mitochondrial swelling under hypoxic conditions, are not exactly known. Our observations, concerning the initial damage to mitochondriae of nerve cells associated with cytoplasmatic hydrops, may indicate that the changes are caused by a hypotonic, exogen osmosis (ALTMANN 1955). These changes are hardly distinguishable from advanced stages of transformation which primarily develop after the energetic principle (MILLER 1958). It was determined that hypoxidosis in situ evokes a rapid, linear decrease of the phosphorylation capacity of mitochondriae (LEON, COOK and HAMMON). Alterations of the fine structures may significantly disturb such chain reactions which are involved in the energy developing processes, however, without significant disturbance of the biochemically determinable total amount of cell enzymes.

Finally, shall be discussed the fact that the different types of hypoxidosis, namely the hypoxemic and dysenzymatic ones, evoke a uniform fine-structural change in the nerve cell. MÖLBERT arrived at the same conclusions in her experimental electronoptic studies on the liver cell. Light microscopic studies of the actions of different enzyme poisons, carried out on kidneys of warm- and cold-blooded animals, did not reveal any differences in the structural patterns (RANDERATH and LUTZ 1955, KNAUFF and SCHRAMM 1956). The conception that uniform structural changes of the nerve cells are due to different types of hypoxidosis, despite the noxious agents acting in different phases of the intracellular metabolism, is contrary to BECKER's assumption. He based his findings on the light microscopy which indicate that a blockage of the respiratory enzyme could be differentiated from oxygen deficiency, in regard to the morphologic effect.

B) Studies on the Reversibility of Ultrastructural Hypoxidotic

Changes in Ganglion Cells of Warm-Blooded Animals.

In the first part of these electronoptic studies, changes were demonstrated in the perikaryon and nucleus of nerve cells of mammals under experimentally induced hypoxidotic conditions. Interpretation of the changes was also attempted. The studies, described below, were developed for the purpose of examining the reversibility of the ultrastructural hypoxidotic changes of nerve cells of the cerebral cortex.

Experimental work on parenchymal cells of other organs (kidney, liver) revealed that the fine-structural changes, which result after hypoxemic and dysenzymatic hypoxidosis due to carbon tetrachloride poisoning or starvation, are partially reversible (MÖLBERT and GUERRITORE 1957, BERNHARD 1957, GANSLER and ROUILLER 1956). A restoration of the injured mitochondriae appears to be possible, as long as we find preserved external membrane and remnants of the internal membrane inside the vacuolarly swollen organellae. The density of the matrix may increase again with the formation of inner membranes, which develop from remnants of the original inner trabeculae or from tubular and finely spun structures within the matrix. The pronounced transformation of mitochondriae in liver cells, which could be seen in rats after several days of starvation (GANSLER and ROUILLER 1956), diminished after feeding for 24 hours. The vacuolar alteration of liver cell ergastoplasm seems to be likewise reversible (MÖLBERT and GUERRITORE 1957). In individual research on the nervous system, an attempt should be made to establish a uniform basis of test procedures, which regularly reproduce the changes in all or most of cerebrocortical nerve cells. The reversibility of these changes should then be observed at varying intervals of time.

Material and Methods.

The Syrian hamster was used for the tests. Their weight ranged from 40 - 60 grams. In the first series of experiments, the possibility of a temporary respiratory arrest, after administration of curare, was ex-

plored. In order to enable an easy calculation of the dosage, d-tubocurarinchloride was diluted 1:10; 0,1 to 1 unit was injected intraperitoneally. The effect was rather unequal in animals of equal weight. Some animals showed a persistent respiratory arrest, others were not affected at all. In cases of respiratory arrest, the animal could not, as a rule, be saved. In order to have the animals survive for some given time after asphyxia due to respiratory arrest, an apparatus was designed to furnish artificial respiration to the animals. It consisted chiefly of 2 cylinders and 2 pistons (5,0 cc syringes). The pistons were moved to and fro at regular speed by means of an electro-motor which transmitted its action by a system of rods. The atmospheric air was sucked in by valves and transferred to the lungs of the test animal through a tracheal tube. By shifting the valve, air was sucked out and expelled by the second piston. The respiratory rate and respiration volume of the respirator were changeable. In order to insert the tracheal tube, the animals were anesthetized with ether. The trachea was opened below the thyroid gland, a small tube was inserted and kept in place by a ligature. By means of this respirator, artificial respiration could be applied after the curare induced respiratory arrest. The animals thus survived the curare effect. However, the loss and restoration of functions could not be observed and controlled because of the general paralysis of the animals. An EEG-machine was not available. After a prolonged artificial respiration there were frequent incidences of tension pneumothorax and obstruction of the tracheal tube by blood and secretions.

As the administration of curare proved unsuitable for the purpose of establishing a basis of test procedures, an attempt was made to produce asphyxia by temporary occlusion of the respiratory tract. To accomplish this, a tracheal tube was inserted in the animals. After the animals had recovered for 30 min., they were slightly anesthetized with ether, following which the external part of the tracheal tube was closed. After a few short respirations, restored normal respiratory movements were followed by arrest. About 2 min. later a gasping respiration ensued, lasting 1/2 to 1 min. Finally a free respiratory movement was established but spontaneous breathing

did not recur. Following the asphyxia, the animals were given artificial respiration in the respirator until spontaneous breathing returned within a few minutes. A respiratory arrest of 2 1/2 min. proved most satisfactory, as asphyxia of 3 min. or longer was usually followed by cardiac arrest. We originally had planned to employ a standardized asphyxia of 2 1/2 min. in a large series of tests, in which the animals would survive for different periods of time. However, the electronoptic controls revealed that after an asphyxia of 2 1/2 min. duration, the fine-structural changes in the nerve cells of the cerebral cortex could not be regularly reproduced. Asphyxia of longer duration was complicated by cardiac arrest from which survival seldom occurred. As these technically rather difficult experiments did not show regularly reproducible results, we resorted to the performance of repeated nitrogen induced asphyxia, which had already proved useful in the creation of hypoxidotic changes in nerve cells. The experimental procedure was as follows: 2 animals were placed in a socket piece of a glass tube. The ends of the latter could be tightly closed and were equipped with feeding tubes. For 60 sec. pure nitrogen was flooded through the tube. The animals were then immediately removed from the tube for 1/2 min. This procedure was repeated 10 times. The animals were finally killed at different time intervals after completion of the experiments, namely after survival rates ranging from 2 1/2 min. to 1 hour and 40 min. One third of the animals were lost during the experiments. The described test procedures were maintained throughout the entire experimental series. The animals exhibited rather different reactions. In some animals, the corneal reflex was still present at the end of the tests. In others, it returned as late as 8 min. after the experiment (average 2 - 3 min.). 3 - 17 min. after completion of the experiments, the animals began to arise and walked about some time later. In 20 - 25 min., the animals seemed to have completely recovered. The fixation was done by perfusion in the manner as outlined in part A).

Results.

A review of the electronoptically studied test material indicated the impossibility of judging the different chronologic and formal features of regeneration which ensue after acute hypoxidotic changes of the

nervous system. Although it was observed that following the series of asphyxiae not all of the nerve cells in the cortex presented equally severe and uniform changes. Studies on the reversibility of hypoxic changes in the brain are subject to a number of uncertain factors in contrast to experiments carried out on other organs (i.g. liver). OPITZ and SCHNEIDER have pointed out that during hypoxidotic disorders of cerebral metabolism certain regulatory mechanisms come into activity. These mechanisms are supposed to maintain an uninterrupted supply to the brain. From this point of view, the brain holds an exceptional position among the other organs. Increase of CO_2 -concentration and decrease of oxygen pressure in the blood augment the cerebral blood flow while it is diminished in other organs. Under experimental conditions it is easier to regularly produce changes in liver, heart and kidney than in the brain. We were thus compelled to resort to the method of repeatedly induced asphyxia for the purpose of producing fine-structural damage. In the past, similar difficulties were encountered in experiments carried out by investigators who tried to reproduce microscopically demonstrable damage to the central nervous system (ALTMANN and SCHUBOTHE, BÜCHNER and LUFT). Since the central nervous system behaves exceptionally with respect to regulating mechanisms, the difficulty in establishing uniform experimental conditions may be explained. In part I the findings were demonstrated in human beings. Difference in topography and in severity of cerebral changes occurred in human cases of hemodynamic and hypoxemic oxygen insufficiency. Considering the above and also the report of A. MEYER and BLUME, who experimentally produced respiratory arrest in cats, one should assume that also in animals the nerve cell changes due to asphyxia are not preferentially localized in the cerebral cortex. If there should be a preferential involvement of the basal ganglions, these regions of the brain should also be experimentally investigated. However, it is difficult to fix adequately the basal ganglions of the hamster by the method of perfusion with osmic acid. The entire evaluation of the experiments carried out thus far cannot be completed at this writing, because there was limited access to electronoptical machines. So far we have arrived at the conclusion as previously stated that it is impossible to study the problem of

the reversibility of fine-structural changes in nerve cells by methods, which induce respiratory arrest with curare or which employ asphyxia and subsequent artificial respiration. There is only one way of approaching this problem, namely, the practice of inducing a large number of repeated asphyxiae within a short period of time, as done in part A) of this investigation. Even under these conditions, the reactions of the animals varied. The use of potassium cyanide in sub-acute dosages would seem to be more suitable. By this method, the clinical pictures obtained are regularly reproduced and are, of course, reversible, and the electronoptic findings are more generalized. For this reason one may expect a better possibility for electronoptic studies pertaining to the reversibility of the nerve cell changes. We have planned to conduct a test series in animals which survive for different periods of time. The experiments should be of particular interest if it is possible to correlate the onset of the fine-structural changes and their regression with the duration of paralysis and period of resuscitation. From such experiments, correlations may be found between the beginning of the structural changes and the cessation of functions or between the return of functions and the restoration of the fine structures. For the reasons outlined above, such physiologic studies were hitherto done successfully only under ischemic conditions, on the spinal cord under control of the functions, and on the cerebral cortex under control by electric activity. The combination of patho-physiologic studies of functions and electronoptic observations still poses a problem with a multiplicity of difficulties as far as methods are concerned.

C) Methodic Examinations to Evaluate the Possibility of Quantitative
Cytologic Research on Anoxic Nerve cells.

The purpose of these studies was, to obtain detailed knowledge concerning the physico-chemical condition of nerve cells which appeared to be altered, as microscopically demonstrable. In particular, we thought it possible to obtain information about the rather characteristic features of this type of cell necrosis which is generally known as ischemic nerve cell necrosis.

At the present time, the following physico-optical methods are available in the field of quantitative cytology: quantitative microabsorption measurements using visible and ultraviolet light, x-ray-microradiography and finally interference microscopy. During the time of our experimental work, we evaluated the possibilities of employing the interference microscope. We had an instrument available (BAKER) which operated on the principle of the so-called Sénarmont-compensation. In the field of quantitative cytologic research, the evaluation of the results, obtained by interference-microscopical measurements, depends upon the determination of the dry mass per square unit. So far, research has been done mostly on single, isolated, fresh or fixed biologic objects. The applicability of this procedure, for our objects, which comprised cells and cell parts in fixed tissue sections, was to be tested. In order to determine the mass per square unit from the measured path difference of light calculations had to be found which could be revised on the basis of previous studies. The formula contains the following elements: the path difference which is reported as value of the angle measured; the refractive indices of the embedding materials; the wave length of the monochromatic light which is used for the procedure of measuring; the constant of the specific refraction increment. In order to eliminate the thickness of the object, which was not directly determinable, two arrangements of the equation are necessary. Biologists have so far experimented with chiefly two embedding substances. In order to measure the different objects only once, the thickness must appear as a variable. Thus more precise results may be obtained by the determination of mean values if measurements are taken from a large number of objects. We have used simple test objects (isolated flat epithelial cells and quartz plates

which are defined optically) in a large series of these in order to trace the source of error in the method and to check the accuracy of measurements. The optical path difference was primarily measured by visual observation. Finally, objects were studied which were embedded in two different embedding substances. The mean error of measurements was determined by Gauss' rule of error propagation. It could be demonstrated that many errors resulted. Errors in visual measurements were especially due to lack of homogeneity of the objects. By employing a halfshade eyepiece, better results were obtained. However, exact measurements were again severely interfered with by lack of homogeneity of objects. An improved experimental procedure was developed. As light source, a stabilized high pressure mercury lamp was used. Different wave length, such as the green, yellow and blue mercury line, were filtered out by an appropriate combination of filters. Originally, the test were carried out with an improvised photometer. Later in the studies, we used a so-called photo-multiplier, an amplifier and a reflecting galvanometer to determine the maximum and minimum of intensity. For adjustment purposes, we have used a tubal topping with interchangeable diaphragms and centered ground glass disks. It is obvious that the use of two embedding substances is a source of errors. Therefore we looked for methods by which measurements could be made in rapid succession in an identical region of the object and with only one embedding substance employed. We also considered the fact that the refractive index of a substance is dependent on the wave length of the used light. The formulae of this method have been previously reported (HAGER and PEHLAND 1958). A theoretical study of the limits of the so-called two-wave-length method revealed, that the smallest measurable masses are within ranges that would require a great improvement in the accuracy of measurement. MITCHISON, PASSANO and SMITH have reported on the subject and referred to a possible solution of the problem. Their method consists in alternately interposing two openings in the path of rays. The openings are arranged in one of the diameters of a rotating disk. One of the openings is equipped with a quarter wave plate, the other one is empty. With the disk rapidly rotating, the intensities entering the two openings are measured by a photo-multiplier. There are two curves appearing on the screen of an oscillograph. By adjusting the

analyzer, the curves are rendered congruent. The accuracy of the readings is supposedly increased from 10 to 20 times compared with those taken visually. We soon expect to design such a machine. The refraction indices of the embedding materials are determined by means of a spectrometer. The interference microscopy, used in quantitative cytologic research, has remained in a developmental stage in the recent past. As we deal with a comparatively new method, a series of research experiments will be necessary to successfully employ this method in the future.

R e f e r e n c e s

PART II/A and B

- Altmann, H.W.: Allgemeine morphologische Pathologie des Cytoplasmas.
Die Pathobiosen. In: Handb.d.allg.Pathol. Bd. 2/1, p.419,
Springer, Berlin, 1955
- Altmann, H.W. and H. Schubothe: Funktionelle und organische Schädigungen
des Zentralnervensystems der Katze im Unterdruckexperiment. Beitr.
pathol.Anat. 107, 3, 1942
- Barnett, R.J. and G.E. Palade: Histochemical demonstration of the sites
of activity of dehydrogenase systems with the electron microscope.
J.Biophys. & Biochem.Cytol. 3, 577, 1957
- Battaglia, F.C., G. Meschia, A. Hellegers and D.H. Barron: The effects of
acute hypoxia on the osmotic pressure of the plasma. Quart.J.Exper.
Physiol. 43, 197, 1958
- Becker, V.: Geweblich gebundener Sauerstoffmangel (Histotoxisch bedingte
Hypoxydose). Klin.Wschr. 1954, p.577
- Bernhard, W.: Die Anwendung des Elektronenmikroskopes zum Studium cellular-
pathologischer Vorgänge. Klin.Wschr. 1957, p.251
- Büchner, F.: Die Pathologie der zellulären und geweblichen Oxydationen.
Handb.d.allg.Pathol. Bd. 4/2, p.569, Springer, Berlin, 1957
- Büchner, F. and U.C. Luft: Hypoxämische Veränderungen des Zentralnerven-
systems. Beitr.pathol.Anat. 96, 549, 1936
- Caspersson, T.: Cell growth and cell function. W.W. Norton Comp.Inc.,
New York, 1950
- Duspiva, F. and F.H. Franken: Untersuchungen über den Stoffwechsel bei
akuter Hypoxie. I. Beitr.pathol.Anat. 118, 38, 1957
- Duspiva, F. and H. Noltenius: Untersuchungen über den Stoffwechsel bei
akuter Hypoxie. II. Beitr.pathol.Anat. 118, 52, 1957
- Gansler, H. and Ch. Rouiller: Modifications physiologiques et patho-
logiques du chondriome. Schweiz.Z.f.allg.Pathol. 19, 218, 1956
- Knauff, H.G. and W. Schramm: Zur Frage morphologischer Äquivalentbilder
der histotoxischen Hypoxydose. Frankf.Z.f.Pathol. 67, 308, 1956

- Leon, H.A., S.F. Cook and J.P. Hannon: Adenosintri-phosphatase activity of rat liver mitochondria following in situ anoxia. *Exper. Cell Res.* 14, 231, 1958
- Lever, J.D. and J.B. Chappell: Mitochondria isolated from rat brown adipose tissue and liver. *J. Biophys. & Biochem. Cytol.* 4, 287, 1958
- Lindberg, O. and L. Ernster: Chemistry and physiology of mitochondria and microsomes. In: *Protoplasmatologia, Handb.d. Protoplasmaforschung*, 3/A4, Springer, Wien, 1954
- Lindner, E.: Die submikroskopische Morphologie des Herzmuskels. *Z. Zellforsch.* 45, 702, 1957
- Meyer, A. and W. Blume: Experimentelle Vergiftungsstudien. IV. Folgeerscheinungen der Narkose am Zentralnervensystem. Histopathologischer Teil. *Z. Neur.* 149, 678, 1934
- Miller, F.: Orthologie und Pathologie der Zelle im elektronenmikroskopischen Bild. *Verh.d.Dtsch.Ges.f.Pathol.* 42. Tagg., Wien, April 1958
- Mölbert, E.: Das elektronenmikroskopische Bild der Leberparenchymzelle nach histotoxischer Hypoxydose. *Beitr.pathol.Anat.* 118, 203, 1957
- Mölbert, E.: Die Herzmuskelzelle nach akuter Oxydationshemmung im elektronenmikroskopischen Bild. *Beitr.pathol.Anat.* 118, 421, 1957
- Mölbert, E. and D. Guerritore: Elektronenmikroskopische Untersuchungen am Leberparenchym bei akuter Hypoxie. *Beitr.pathol.Anat.* 117, 32, 1957
- Moore, D.H., H. Ruska and W.M. Copenhaver: Electron microscopic and histochemical observations of muscle degeneration after Tourniquet. *J. Biophys. & Biochem. Cytol.* 2, 755, 1956
- Opitz, E.: cit. by Büchner, 1957
- Opitz, E. and M. Schneider: Über die Sauerstoffversorgung des Gehirns und den Mechanismus von Mangelwirkungen. *Ergeb.d. Physiol., biol. Chem. u. exper. Pharmakol.* 46, 125, 1950
- Palade, G.E.: Studies on the endoplasmic reticulum. II. Simple dispositions in situ. *J. Biophys. & Biochem. Cytol.* 1, 567, 1955
- Palade, G.E.: A small particulate component of the cytoplasm. *J. Biophys. & Biochem. Cytol.* 1, 59, 1955

- Palade, G.E.: An electron microscope study of the mitochondrial structure. J.Histochem.Cytochem. 1,188,1953
- Palade, G.E.: A study of fixation for electron microscopy. J.Exper.Med. 95,285,1952
- Palay, S.L. and G.E. Palade: The fine structure of neurons. J.Biophys. & Biochem.Cytol. 1,69,1955
- Poche, R.: Submikroskopische Beiträge zur Pathologie der Herzmuskelzelle bei Phosphorvergiftung, Hypertrophie, Atrophie und Kaliummangel. Virchows Arch. 331,165,1958
- Randerath, E. and P. Lutz: Histologische Befunde der Niere von Salamandra maculosa nach intraperitonealer Injektion fermenthemmender Substanzen. Frankf.Z.f.Pathol. 67,38,1955
- Rhodin, J.: Correlation of ultrastructural organization and function in normal and experimentally changed proximal convoluted tubule cells of the mouse kidney. Karolinska Inst. Stockholm, 1954
- Rotter, W.: Über hypoxämische Veränderungen des Zentralnervensystems unter Sauerstoffatmung bei normalem Luftdruck. Beitr.pathol.Anat.101, 23,1938
- Rouiller, C. and W. Bernhard: Microbodies and the problem of mitochondrial regeneration in liver cells. J.Biophys. & Biochem.Cytol.2,355,1956
- Schulz, H., L.Löw, L. Ernster and F.S. Sjöstrand: Elektronenmikroskopische Studien an Leberschnitten von thyroxinbehandelten Ratten. Electron Microscopy Proc.Stockholm Conf. 1956, p. 134
- Strughold, H.: Hypoxydose. Klin.Wschr. 1944, p.221
- Thorn, W., H.Scholl, G. Pfliegerer and B. Muedener: Stoffwechselforgänge im Gehirn bei normaler und herabgesetzter Körpertemperatur unter ischämischer und anoxischer Belastung. J.Neurochem. 2,150,1958
- Thorner, M.W. and F.H. Lewy: The effects of repeated anoxia on the brain. J.Amer.Med.Assoc.115,1595, 1940
- Zetterquist, H.: The ultrastructural organization of the columnar absorbing cells of the mouse jejunum. An electronmicroscopic study including some experiments regarding the problem of fixation and an investigation of vitamin A deficiency. Thesis Stockholm, 1956

R e f e r e n c e s

PART II/C

- Hager, H. and H. Pehland: Interferenzmikroskopische Massenbestimmungen an biologischen Objekten mit einer Zweiwellenlängenmethode. Naturwissensch. 45, 370/71, 1958
- Mitchison, J.M., L.M. Passano and F.H. Smith: An integration method for the interference microscope. M.Microsc.Sci. 97,287,1956
- Pehland, H. and H. Hager: Zur Theorie der interferenzmikroskopischen Trockengewichtsbestimmung an biologischen Objekten. Z.f.wissensch. Mikroskop. (im Druck)

Figures.

- Fig. 1 Normal nerve cell from the cerebral cortex. MI = mitochondria, E = endoplasma reticulum, P = Palade granula, N = nucleus, NM = membrane of the nucleus, NL = nucleolus.
Magnification 21600:1
- Fig. 2 Normal nerve cell of the cerebral cortex. N = nucleus, NM = membrane of the nucleus, NL = nucleolus, MI = mitochondria, E = endoplasma reticulum, P = Palade granula, L = liposome.
Magnification 21600:1
- Fig. 3 Endoplasma reticulum (E) in a Purkinje cell of the cerebellar cortex. P = Palade granula, MI = mitochondrion.
Magnification 90000:1
- Fig. 4 Ultrastructure of mitochondria in neurons of the cerebellar cortex.
Magnification 90000:1
- Fig. 5 Nerve cell of the cerebral cortex after repeated nitrogen asphyxiation. Changes in the mitochondria and in the endoplasma reticulum. N = nucleus, NL = nucleolus, PE = perikaryon.
Magnification 4800:1
- Fig. 6 Nerve cell of the cerebral cortex after repeated nitrogen asphyxiation. Changes in the mitochondria (MI) and in the endoplasma reticulum (E); rarefication of the Palade granula (P). N = nucleus.
Magnification 21600:1
- Fig. 7 Nerve cell of the cerebral cortex after repeated nitrogen asphyxiation. Changes in the mitochondria (MI); rarefication of the Palade granula (P). N = nucleus, NL = nucleolus, NM = membrane of the nucleus.
Magnification 21600:1
- Fig. 8 Nerve cell of the cerebral cortex after acute depression experiment. Changes in the perikaryon.
Magnification 4800:1

- Fig. 9 Nerve cell of the cerebral cortex after acute depression experiment. Small vacuoles in mitochondria (MI); rarefication of Palade granula (P). N = nucleus, NM = membrane of the nucleus, GZ = Golgi zone.
Magnification 21600:1
- Fig. 10 Nerve cell of the cerebral cortex after acute depression experiment. Changes in mitochondria (MI), in endoplasma reticulum (E); rarefication of Palade granula (P). N = nucleus.
Magnification 21600:1
- Fig. 11 Nerve cell of the cerebral cortex after potassium cyanide poisoning. Disappearance of the endoplasma reticulum; rarefication of Palade granula (P). PE = perikaryon, N = nucleus.
Magnification 4800:1
- Fig. 12 Nerve cell of the cerebral cortex after potassium cyanide poisoning. Rarefication of Palade granula (P); mitochondria (MI) are relatively intact. N = nucleus, NM = nuclear membrane.
Magnification 21600:1
- Fig. 13 Nerve cell of the cerebral cortex after potassium cyanide poisoning. Pronounced changes in mitochondria (MI); endoplasma reticulum and Palade granula near the nucleus (N) are better preserved.
Magnification 4800:1
- Fig. 14 Nerve cell of the cerebral cortex after potassium cyanide poisoning. Changes in mitochondria (MI), discontinuity of membranes of the endoplasma reticulum (E). NM = membrane of the nucleus, N = nucleus.
Magnification 21600:1
- Fig. 15 Nerve cell of the cerebral cortex after potassium cyanide poisoning. NM = membrane of the nucleus, NL = nucleolus, A = nucleolus associated chromatin.
Magnification 4800:1
- Fig. 16 Nerve cell of the cerebral cortex after potassium cyanide poisoning. NM = membrane of the nucleus, NL = nucleolus, A = nucleolus associated chromatin.
Magnification 21600:1

