

AD630655

AEROMEDICAL REVIEWS

ENDOPARASITES OF LABORATORY ANIMALS

Review 1-66

CLEARINGHOUSE FOR FEDERAL SCIENTIFIC AND TECHNICAL INFORMATION			
Hardcopy	Microfiche		
\$ 3.00	\$ 0.75	65 pp	as
ARCHIVE COPY			

Code 1

USAF School of Aerospace Medicine
Aerospace Medical Division (AFSC)
Brooks Air Force Base, Texas

DDC
REFLECTED
APR 12 1966
REFLECTED
C

ENDOPARASITES OF LABORATORY ANIMALS

ROBERT R. ESTES, Staff Sergeant, USAF
JAMES C. BROWN, Captain, VC, USAF

Review 1-66

USAF School of Aerospace Medicine
Aerospace Medical Division (AFSC)
Brooks Air Force Base, Texas

January 1966

PREFACE

This study is a compilation of many of the ova or larvae of parasites encountered in laboratory animals. In the interest of brevity, the parasites are separated according to similar hosts rather than species of animal. Realizing that this collection is by no means complete, we feel that it is necessary to provide researchers with some method of identifying parasites of the laboratory animals most commonly used. At the present time a variety of texts must be consulted to identify many parasite ova infrequently observed. We believe this review will prove valuable as a training aid for new laboratory and veterinary technicians as well as for research veterinarians.

More research was involved and fewer references were available on primate parasitology; therefore, more emphasis was placed on this section. Although most of the illustrations in this section are drawings, the list is more complete than the listing of other hosts. More specimens were available from dogs, thus enabling us to obtain photomicrographs on most of these parasites. This review is divided into four categories: primates, canines and felines, rodents and rabbits, and poultry. Much remains to be done in this field of endeavor, and it is the hope of the authors that this review will stimulate the desire for a more complete manual.

Photographs of the ova are magnified 500 times and the drawings are made approximately to the same scale. The section on protozoans of primates, however, is drawn at about 1,000 times magnification since much detail would be obscured at a lower magnification. The size of the parasite is listed with each picture.

The authors express their gratitude to Orville V. Anderson for his superb photomicrography and to Melvan D. Jordan, who completed the collection with drawings. All illustrations are originals and much effort was made to demonstrate the more pertinent features.

CONTENTS

	<i>Page</i>
I. Parasites of subhuman primates	1
Nematodes	1
Cestodes	1
Trematodes	17
Protozoans	17
II. Parasites of canines and felines	30
Nematodes	30
Cestodes	38
Trematodes	39
Protozoans (sporozoa)	41
Blood microfilariae	45
III. Parasites of rodents and rabbits	47
Nematodes	47
Cestodes	52
Protozoans (sporozoa)	55
IV. Parasites of poultry	56
Nematodes	56
Protozoans (sporozoa)	58

LIST OF ILLUSTRATIONS

Ancylostoma caninum (canine and feline)
Ancylostoma duodenale (primate)
Ascaridia galli
Ascaris lumbricoides
Aspicularis tetraptera
Balantidium coli
Bertiella spp.
Capillaria aerophila (canine and feline)
Capillaria hepatica (primates)
Capillaria hepatica (rodents)
Capillaria spp. (poultry)
Chilomastix mesnili
Dientamoeba fragilis
Dipetalonema reconditum
Diphyllobothrium mansonoides
Dipylidium caninum
Dirofilaria immitis
Echinococcus granulosus
Eimeria canis (canine)
Eimeria spp. (rodents)
Eimeria spp. (poultry)
Embadoemonas intestinalis
Endolimax nana
Entamoeba coli
Entamoeba histolytica
Entamoeba polecki
Enterobius vermicularis
Enteromonas hominis
Fasciola hepatica
Giardia lamblia
Gnathotoma spp.
Gongylonema spp. (primates)
Gongylonema spp. (rodents)
Heterakis gallinae (poultry)
Heterakis spumosa (rodents)
Hymenolepis diminuta (primates)
Hymenolepis diminuta (rodents)

Hymenolepis nana (primates)
Hymenolepis nana (rodents)
Iodamoeba buetschlii
Isospora bigemina
Isospora felis
Isospora rivolta
Metastrongylus spp.
Multiceps multiceps
Necator americanus
Oezophagostomum apistomum
Passalurus ambiguus
Physaloptera caucasica (primates)
Physaloptera spp. (canine and feline)
Railiistina spp.
Spirocerca lupi
Streptopharonus armatus
Strongyloides intestinalis (primates)
Strongyloides spp. (rodents)
Strongyloides stercoralis (canine and feline)
Syphacia obvelata (primate)
Syphacia obvelata (rodents)
Taenia spp. (primates)
Taenia spp. (canine and feline)
Taenia spp. (rodents)
Ternidens diminuta
Toxascaris leonina
Toxocara spp.
Trichomonas hominis
Trichostrongylus spp.
Trichuris spp. (rodents)
Trichuris trichiura (primates)
Trichuris vulpis (canine and feline)
Trogloidyrella abressarti
Watsonius watsoni

ENDOPARASITES OF LABORATORY ANIMALS

We are concerned with the control of disease in the laboratory animals most commonly used in scientific studies. Even in the cleanest and best-maintained laboratory, vigilance is required to protect the animals from infection by parasites. By early recognition of the parasite, disease may be more quickly exterminated. The monkey, dog, cat, rabbit, rodent, turkey, and chicken are perhaps the animals most frequently employed in medical studies. Although parasitism often does not present clinical symptoms or apparent health problems for laboratory animals in their normal environment, it may cause complications during the stresses of experimentation. It is for this reason that parasites must be identified and eliminated.

I. PARASITES OF SUBHUMAN PRIMATES

Most of the parasites that infect man also infect the monkey. Others are peculiar to the species. Those most often encountered are the amebas, *Strongyloides intestinalis*, whipworm, *Bertiella studeri*, *Streptopharagus armatus*, *Oesophagostomum apiostomum*, and *Physaloptera caucasica*. This section describes the ova and cysts of endoparasites that most often cause disease in the monkey.

Although the majority of endoparasites of primates seem to be commensals, it is important to identify them since their presence in large numbers could cause an intestinal disturbance.

Nematodes

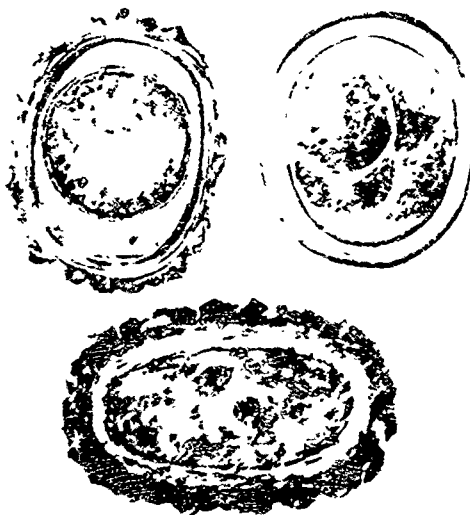
Ancylostoma duodenale (Old World hookworm)

The ova of *A. duodenale* measure 60 by 40 μ and are usually discharged in the 2- to 8-cell stage. They may occasionally contain first-stage larvae, but only in constipated stools. (See drawing of ova at top of page 2.)



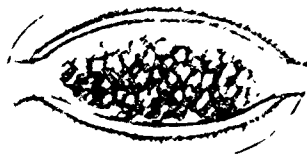Ascaris lumbricoides (giant intestinal roundworm)

The ova of *A. lumbricoides* appear in various forms. The fertilized ova measure 45 to 75 by 35 to 50 μ . They may or may not possess the thick outer albuminous coat. The unfertilized eggs measure 88 to 94 by 44 μ . They also may or may not possess the outer coat.




Capillaria hepatica (capillary liver worm)

The ova of *C. hepatica* measure 51 to 67 by 30 to 35 μ . They resemble ova of *Trichuris trichiura* but are larger and more ovoid, and have a distinctly pitted shell.



Enterobius vermicularis (pinworm)

The ova of *E. vermicularis* measure 55 by 30 μ . These eggs are fully embryonated when deposited and are flattened on one side. The hyaline shell is relatively thick.



Gnathostoma spp.

The ova of *Gnathostoma* spp. measure 65 to 70 by 38 to 40 μ . The ovoid eggs are transparent, have a pitted shell, and have a mucoid plug at one end. They are unembryonated when laid.



Gongylonema spp. (scutate threadworm)

The ova of *Gongylonema* spp. measure 50 to 70 by 25 to 37 μ . They are thick-shelled, broadly ovoid, and fully embryonated when passed in the feces.



Metastrongylus spp.

The ova of *Metastrongylus* sp. measure 51 to 54 by 33 to 36 μ . They are thick-shelled, hyaline eggs and are fully embryonated when passed in the feces.



Necator americanus (tropical hookworm)

The ova of *N. americanus* measure 64 to 76 by 36 to 40 μ . They resemble those of *A. duodenale* but are somewhat narrower and longer.



Oesophagostomum apistomum

The ova of *O. apistomum* measure 60 to 63 by 27 to 40 μ . They are morphologically similar to the hookworm ova.



Physaloptera caucasica

The ova of *P. caucasica* measure 44 to 65 by 32 to 45 μ . They have a smooth, thick, ovoid shell and are fully embryonated when laid.



Streptopharagus armatus

The ova of *S. armatus* measure approximately 60 by 35 μ . They are ovoid, thick-shelled, and embryonated when laid.



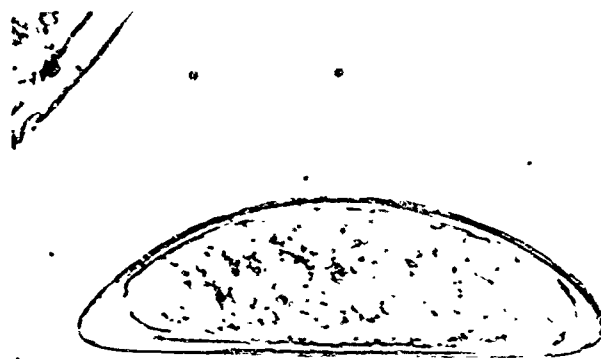
Strongyloides intestinalis (threadworm)

The ova of *S. intestinalis* measure 50 by 32 μ and are fully embryonated when laid.




Syphacia obvelata

The ova of *S. obvelata* measure 125 by 40 μ . They are unembryonated eggs similar to *E. vermicularis* but considerably larger.




Ternidens diminuta

The ova of *T. diminuta* measure 84 by 51 μ and resemble the hookworm ova but are noticeably larger. They are more often seen in the 8-cell stage.



Trichostrongylus spp.

The ova of *Trichostrongylus* spp. measure 45 to 100 μ . They resemble hookworm ova but are much larger and more elongated.



Trichuris trichiura (whipworm)

The ova of *T. trichiura* measure 50 by 22 μ . They are barrel-shaped with a triple shell and have a mucoid plug at each end. The outer shell has a brown color.



C

Cestodes

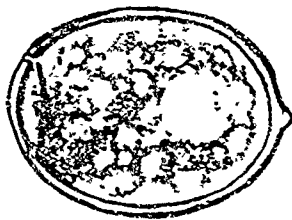Bertiella spp.

The ova of *Bertiella* spp. measure 45 to 46 by 49 to 50 μ . They are spherical and have a rough, irregular outer shell. The oncosphere shows a protrusion on one side.



Diphyllbothrium mansonoides

The ova of *D. mansonoides* measure 58 to 76 by 40 to 51 μ . They are broadly ovoid and moderately thick-shelled, and contain immature embryos when passed in the feces. They are yellowish in color and possess an operculum.




Echinococcus granulosus (hydatid worm)

The ova of *E. granulosus* measure 31 to 36 μ . They are morphologically indistinguishable from *Taenia* spp. or *Multiceps multiceps*.



Hymenoclepis diminuta (rat tapeworm)

The ova of *H. diminuta* measure 60 to 79 by 72 to 86 μ . They are subspherical and have a slightly yellowish, transparent shell and an inner membrane around the oncosphere. There are two polar thickenings but no filaments. The six hooklets within the oncosphere are arranged in a fan-shaped pattern.



Hymenolepis nana (dwarf tapeworm)

The ova of *H. nana* measure 30 to 47 μ in diameter. These almost spherical, hyaline eggs contain an oncosphere enclosed in an inner envelope with two polar thickenings. To these thickenings are attached four to eight filaments. The oncosphere contains three pairs of hooklets.



Multiceps multiceps ("gid worm")

The ova of *M. multiceps* measure 31 to 36 μ . They are morphologically indistinguishable from *Taenia* spp.



Raillietina spp.

The ova of *Raillietina* spp. measure 57 by 21 μ . The ellipsoidal eggs contain six conspicuously large hooklets.



Taenia spp.


The ova of *Taenia* spp. measure 31 to 43 μ . They are spherical to subspherical and are brownish in color. The shell is thick, shows radial striations, and is sometimes surrounded by a thin hyaline membrane. The fully developed embryo (oncosphere) usually contains three pairs of hooklets.



Trematodes

Watsonius watsoni

The ova of *W. watsoni* are rather large, measuring 122 to 130 by 75 to 80 μ . They are ovoid, operculated, and light yellow in color. They are immature when laid.



Protozoans

Dientamoeba fragilis

Trophozoites of *D. fragilis* measure 7 to 12 μ . Pseudopods are hyaline, and motility is progressive and rapid. The characteristic feature of this organism is its high percentage (sometimes 80%) of binucleate forms.

No cyst stage of *D. fragilis* has been reported.



Endolimax nana

Trophozoites of *E. nana* measure 5 to 12 μ . Pseudopods are blunt and hyaline, and movement is sluggish. The cytoplasm may contain food vacuoles with ingested bacteria. The nucleus is characterized by a rather large karyosome.

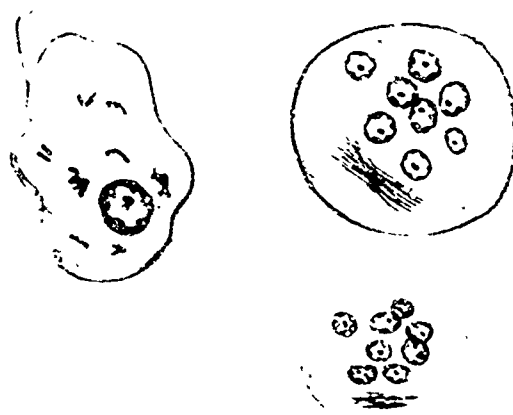
Cysts of *E. nana* measure 5 to 14 μ and are often ovoid. They have one to four nuclei, each containing a large karyosome. Very little chromatin granulation is present.



Entamoeba coli

Trophozoites of *E. coli* measure 15 to 50 μ in diameter. Their movement is more sluggish than *Entamoeba histolytica*, and ingested red blood cells will not be seen.

Cysts of *E. coli* measure 15 to 20 μ . They contain one to eight nuclei with an eccentrically located karyosome. Chromatin granules are unevenly distributed and the chromatoidal bar, when present, appears splintered on the ends.



Entamoeba histolytica

Trophozoites of *E. histolytica* measure 15 to 60 μ . In fresh stools their movement is directional and rapid. Ingested red blood cells are often seen.

Cysts of *E. histolytica* vary in size. Small race measures 5 to 10 μ ; large race, 10 to 20 μ . They contain one to four nuclei with a centrally located karyosome. The chromatin granules are evenly distributed around the periphery of the nucleus. Chromatoidal bars, when present, have rounded ends.



Entamoeba polecki

Trophozoites of *E. polecki* measure 10 to 12 μ and resemble those of *E. histolytica*. Their movement, however, is less directional.

Cysts of *E. polecki* measure 5 to 11 μ and are characterized by a single nucleus. The karyosome is usually large and centrally located and may be spherical or consist of a group of small granules. The chromatoidal bars frequently are angular or pointed on the ends.



Iodamoeba buetschlii

Trophozoites of *I. buetschlii* measure 9 to 14 μ . Their movement is sluggish, and they may contain ingested bacteria but no red blood cells.


Cysts of *I. buetschlii* measure 6 to 16 μ . They usually contain one nucleus with an irregular karyosome often quite eccentrically located. The outstanding characteristic of this cyst is the presence of a large glycogen vacuole. When stained with iodine, this vacuole appears as a dark brown mass, although it is readily visible as a refractile body in unstained cysts.



Chilomastix mesnili

Trophozoites of *C. mesnili* measure 10 to 20 μ in length and are elongated with a tapered posterior end. There are three anterior flagella which provide a directional movement. There is a single anterior positioned nucleus bordered by a cytostomal fibril curved to resemble a shepherd's hook.

Cysts of *C. mesnili* measure 6 to 10 μ and have a characteristic lemon shape owing to a nipplelike protuberance at the anterior pole. They have a single nucleus and a curved cytostomal fibril.



Embecdomonas intestinalis (*Retortamonas intestinalis*)

Trophozoites of *E. intestinalis* measure 4 to 10 μ and are ovoid or tear-shaped. There are a single nucleus, two anterior flagella, and a cytostome running about half the length of the body.

Cysts of *E. intestinalis* are very small, measuring 4 to 7 μ long, and are pea-shaped. There is a single nucleus near which is located two fibrils that resemble a bird's beak.



Enteromonas hominis

The trophozoites of *E. hominis* measure 4 to 10 μ in length. They are broadly ovoid and possess three anterior flagella which provide it with a rapid, jerky movement and a fourth flagellum directed posteriorly. They have a single nucleus

Cysts of *E. hominis* measure 6 to 8 μ in length and are ellipsoid in shape. They usually possess two nuclei but may have four.

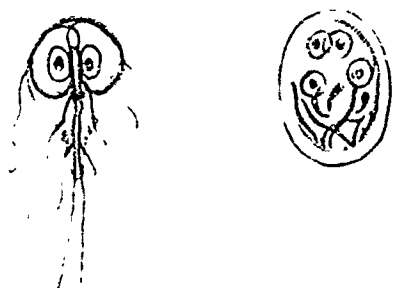
Fig.



Giardia lamblia

Trophozoites of *G. lamblia* measure 9 to 21 by 5 to 15 μ and are the most easily recognized of the intestinal protozoa. They are bilaterally symmetrical, contain two nuclei, and have four pairs of flagella.

Cysts of *G. lamblia* measure 8 to 14 by 7 to 10 μ . They are ovoid and contain four nuclei. Four median bodies are usually present as well as a number of intracytoplasmic flagellar structures.



Trichomonas hominis

Trophozoites of *T. hominis* measure 7 to 15 μ . They have a rapid, jerky, nondirectional movement. There is a single nucleus with a small karyosome. This trophozoite possesses a thin, curved rod called the costa to which is attached an undulating membrane. An axostyle runs the length of the body and protrudes past the posterior end.

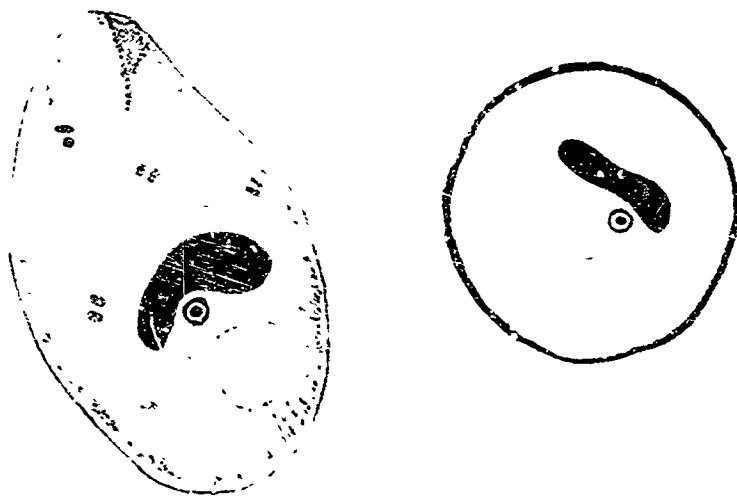
No cyst stage of *T. hominis* has been reported.



Balantidium coli


Trophozoites of *B. coli* average 50 to 100 by 40 to 70 μ , although they have been reported as much as 200 μ in length. They are ovoid and contain a cytostome near the anterior end. They are covered with cilia and contain a macronucleus which may be ellipsoid, spherical, curved, or kidney-shaped. There is also a small, spherical micronucleus.

Cysts of *B. coli* are spherical and measure 50 to 75 μ in diameter. They have a thick, refractile wall and both a macronucleus and a micronucleus. The organism of newly encysted specimens may still contain the cilia, and it may be seen slowly rotating.



Troglodytella abressarti

The seeldom reported trophozoites of *T. abressarti* are very large, measuring 126 to 87 by 174 to 145 μ . A group of cilia protrudes from the anterior aspect, and several rows of cilia are located throughout the body.



II. PARASITES OF CANINES AND FELINES

The more common endoparasites of dogs and cats are shown in the photomicrographs of this section. Frequently encountered are the whipworm, hookworm, and the coccidia (*Eimeria* spp. and *Isospora* spp.). In addition, the differential characteristics of heartworm (*Dirofilaria immitis*) and the subcutaneous worm (*Dipetalonema reconditum*) are given at the end of the section.

Nematodes

Ancylostoma caninum (hookworm)

The ova of *A. caninum* measure 75 to 85 by 50 to 55 μ . These hookworm ova of dogs and cats are deposited in the early stages of segmentation.

Capillaria aerophila (lungworm)

The ova of *C. aerophila* measure 60 to 75 by 32 to 38 μ . They are similar to *Trichuris vulpis* except that they are smaller and more ovoid, and have a distinctly pitted shell. One of the mucous plugs is often off-center.



Physaloptera spp.

The ova of *Physaloptera* spp. measure 42 to 56 by 30 to 40 μ . They have a smooth, thick, hyaline shell and are fully embryonated when deposited in the feces.



Spirocerca lupi (esophageal worm)

The ova of *S. lupi* measure 30 to 35 by 10 to 15 μ . They are elongated, thick-shelled, and fully embryonated when deposited in the feces.

Strongyloides stercoralis (threadworm)

The rhabditiform larvae of *S. stercoralis* usually hatch before being passed in the feces, and eggs are rarely seen in the stool. The rhabditiform larvae measure 0.6 to 0.8 mm. in length by 40 to 50 μ in width (male), and about 1 mm. in length by 50 to 75 μ in width (female). The main characteristic used to distinguish larvae of *S. stercoralis* from hookworm larvae is the relatively short buccal cavity of *S. stercoralis*.



Toxascaris leonina (ascarid)

The ova of *T. leonina* measure 75 to 75 by 65 to 75 μ . They are ovoid to spherical and possess a smooth, thick shell. They are deposited in the single-cell stage but rapidly develop to the 2-cell stage.

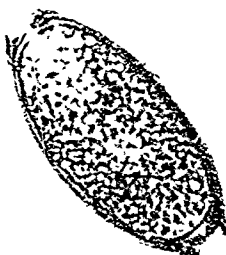Toxocara spp. (ascarid)

The ova of *Toxocara* spp. measure 75 to 85 μ . They are subglobular in shape and possess a thick, brownish shell. The shell is distinctly pitted, and the egg is unembryonated when deposited in the feces.



Trichuris vulpis (whipworm)


The ova of *T. vulpis* measure 70 to 90 by 35 to 40 μ . They are barrel-shaped with a triple shell, have a mucoid plug at each end, and are brownish in color.



Cestodes

Dipylidium caninum

Ova of *D. caninum* measure 30 to 40 μ in diameter. They are spherical and thin-shelled. They are usually seen enclosed in packets ranging from 8 to 15 eggs per packet.



Taenia spp.

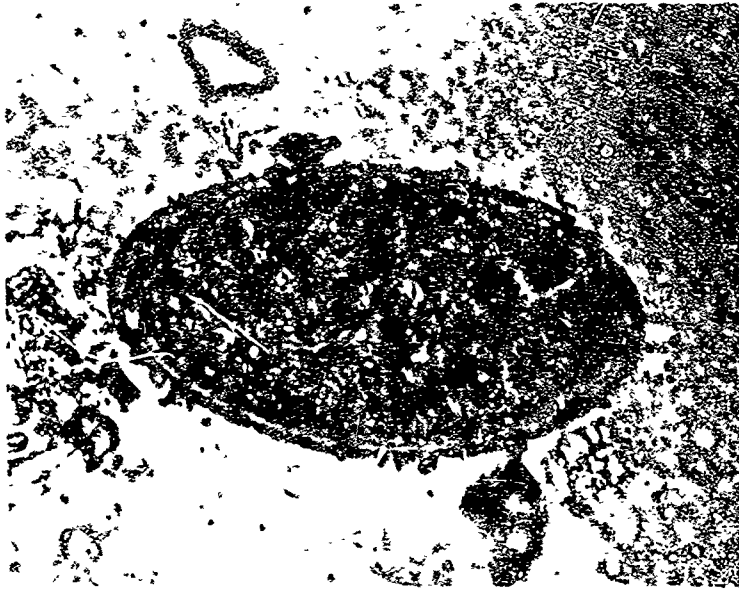
The ova of *Taenia* spp. measure 31 to 43 μ . They are spherical to subspherical and are brownish in color. The shell is thick, shows radial striations, and sometimes is surrounded by a thin, hyaline membrane. The fully developed embryo usually contains three pairs of hooklets.



Trematodes

Fasciola hepatica

The ova of *F. hepatica* measure 130 to 150 by 63 to 90 μ . They are large, ovoid eggs with an operculum and are laid in the immature stage.



Protozoans (sporozoa)

Eimeria canis

Oocysts of *E. canis* measure 20 to 45 by 10 to 30 μ . They have a rough shell with a micropyle at one end and are brownish in color.

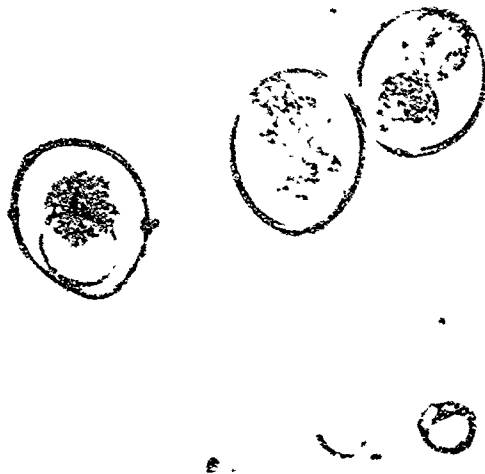

Isospora bigemina

Oocysts of *I. bigemina* measure 10 to 14 by 7.5 to 9.5 μ (small race) and 18 to 20 by 14 to 16 μ (large race). They are often sporulated when passed in the feces. They possess two sporocysts, each of which contains four sporozoites.

Isospora felis

Oocysts of *I. felis* measure 40 to 48 by 25 to 38 μ . They are egg-shaped and usually unsporulated when passed in the feces.



Isospora rivolta

Oocysts of *I. rivolta* measure 20 to 25 by 15 to 20 μ . They are egg-shaped and are usually unsporulated when passed in the feces.




Blood microfilariae


Dipetalonema reconditum (subcutaneous worm) and
Dirofilaria immitis (heartworm)

Microfilariae of *D. reconditum* and *D. immitis* are released into the bloodstream and may be detected there with the use of simple concentration technics. The two microfilariae are extremely difficult to differentiate, and all characteristics must be taken into consideration. *D. reconditum* is not known to present a problem to the animal, but *D. immitis* may seriously alter the ability of the animal to withstand the stresses of research studies, thus affecting experimental results.

Dipetalonema reconditum



Dirofilaria immitis



Differentiation of D. immitis and D. reconditum when using the modified Knott method of concentration

	<i>D. reconditum</i>	<i>D. immitis</i>
Average length (range)*	270 (258-292)	314 (286-340)
Average width (range)	5.2 (4.7-5.8)	6.8 (6.1-7.2)
Anterior extremity	Parallel sides	Tapered
Tail	Button-hooked	Mostly straight
Straightness	Crescent, wavy	Straight
Number	Usually low	Usually high

*All measurements are in microns.

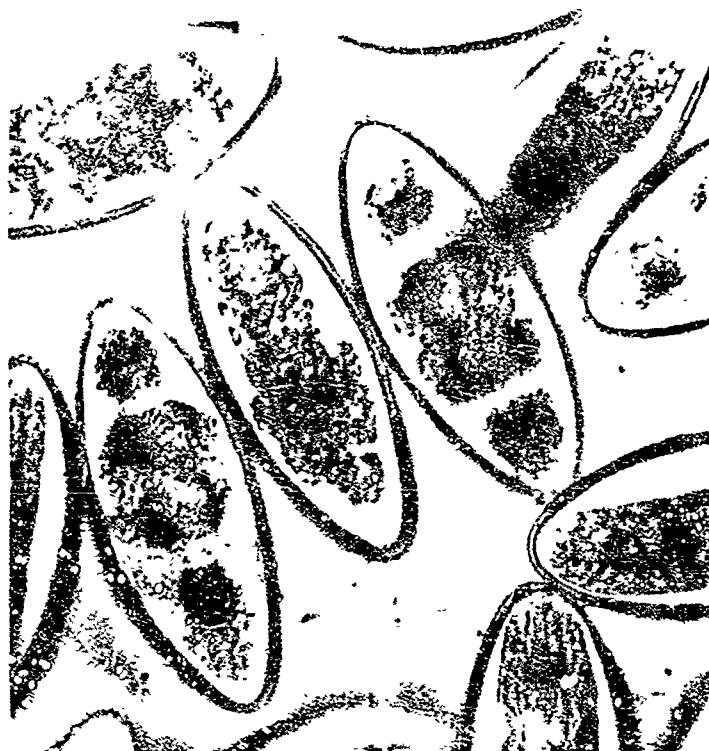III. PARASITES OF RODENTS AND RABBITS

Rodents and rabbits do not normally harbor a large variety of parasites. Common in rats and mice is *Hymenolepis nana*, which is of extreme importance because it can be transmitted to man. The most commonly encountered parasites of rabbits are members of the genus *Eimeria*, the causative agents of hepatic and intestinal coccidiosis. Pinworms are not uncommon in both rodents and rabbits.

Nematodes

Aspicularis tetraptera

The ova of *A. tetraptera* measure 90 by 39 μ . They are thin-shelled, barrel-shaped, and unembryonated when deposited in the feces.



Capillaria hepatica

The ova of *C. hepatica* measure 51 to 67 by 30 to 35 μ . They resemble ova of *T. trichiura* but are larger and more ovoid, and have a distinctly pitted shell.




Gongylonema spp. (scutate threadworm)

The ova of *Gongylonema* spp. measure 50 to 70 by 25 to 37 μ . They are thick-shelled, broadly ovoid, and fully embryonated when laid. The larvae are coiled within the egg.



Heterakis spumosa

The ova of *H. spumosa* measure 65 by 55 μ . They are thick-shelled and corticated.



Passalurus ambiguus (rabbit pinworm)

The ova of *P. ambiguus* measure 100 by 43 μ . They resemble the other pinworm ova in that they are flat on one side.



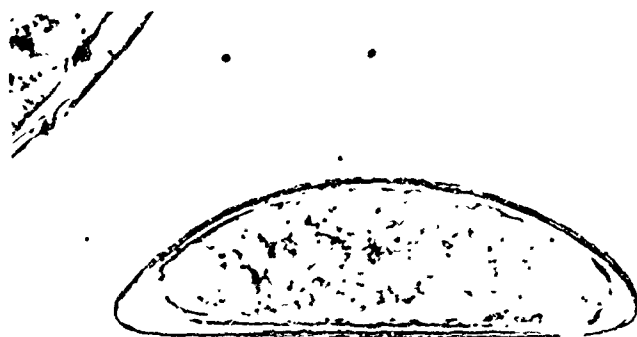
Strongyloides spp. (threadworm)

The ova of *Strongyloides* spp. measure 50 by 32 μ . The ova are fully embryonated when laid.



Syphacia obvelata

The ova of *S. obvelata* measure 125 by 40 μ . They are unembryonated when laid, have a relatively thick, hyaline shell, and are flattened on one side.



Trichuris spp.

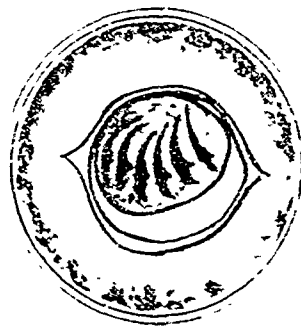
The ova of *Trichuris* spp. measure 50 by 22 μ . They are barrel-shaped and have a triple shell; the outer shell has a brownish color. There is a mucoid plug at each end.



Cestodes

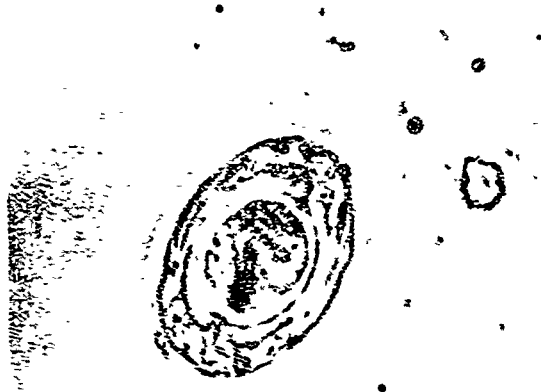Hymenolepis diminuta (rat tapeworm)

The ova of *H. diminuta* measure 60 to 79 by 72 to 86 μ . They are subspherical and have a slightly yellowish, transparent shell and an inner membrane around the oncosphere. There are two polar thickenings but no filaments. The six hooklets within the oncosphere are arranged in a fan-shaped pattern.



Hymenolepis nana (dwarf tapeworm)

The ova of *H. nana* measure 30 to 47 μ in diameter. These almost spherical, hyaline eggs contain an oncosphere enclosed in an inner envelope with two polar thickenings. To these thickenings are attached four to eight filaments. The oncosphere contains three pairs of hooklets.



Taenia spp.

The ova of *Taenia* spp. measure 31 to 43 μ . They are spherical to subspherical and brownish in color. The shell is thick, shows radial striations, and is sometimes surrounded by a thin, hyaline membrane. The fully developed embryo (oncosphere) usually contains three pairs of hooklets.



Protozoans (sporozoa)

Eimeria spp.

Oocysts of the different species of *Eimeria* spp. range from 10 to 30 μ in length. They are spherical to ovoid and possess an operculum at one end. When sporulated, they contain four sporocysts, each of which contains two sporozoites.




IV. PARASITES OF POULTRY

Parasites of poultry are usually self-eradicating and seldom cause a problem in birds housed on wire floors. Some are of importance, however, and the more common ones are included in this section to aid in their identification.

Nematodes

Ascaridia galli

The ova of *A. galli* measure 75 to 80 by 45 to 50 μ . They are thick-shelled and ellipsoidal in contour. They are deposited in the single-cell stage.



Capillaria spp.

The ova of the different species of *Capillaria* range in size from 45 to 64 μ in length by 21 to 28 μ wide. They resemble the ova of whipworm found in other animals in that they are thick-shelled and barrel-shaped, and have mucoid plugs at both ends.



Heterakis gallinae (cecal worm)


The ova of *H. gallinae* measure 65 to 70 by 38 to 48 μ . They are thick-shelled and ellipsoidal in contour, and are deposited in the single-cell stage.



Protozoans (sporozoa)

Eimeria spp.

Because there are many species of *Eimeria* found in poultry, size will not be discussed. These oocysts are similar in morphology to the other coccidia and may be reported as *Eimeria* spp.



BIBLIOGRAPHY

1. Benbrook, E. A., and M. W. Sloss. Veterinary clinical parasitology. Ames, Iowa: Iowa State University Press, 1961
2. Craig, C. F., and E. C. Faust. Clinical parasitology. Philadelphia: Lea and Febiger, 1957.
3. Markell, E. K., and M. Voge. Diagnostic medical parasitology. Philadelphia: W. B. Saunders, 1958.
4. Morgan, B. B., and P. A. Hawkins. Veterinary helminthology. Minneapolis, Minn.: Burgess, 1949.
5. Ruch T. C. Diseases of laboratory primates. Philadelphia: W. B. Saunders, 1959.
6. Spencer, F. M., and L. S. Monroe. The color atlas of intestinal parasites. Springfield, Ill.: Charles C Thomas, 1961.
7. York, W, and P. A. Maplestone. Nematode parasites of vertebrates. New York: Hafner, 1962.
8. AFM 160-48, Laboratory procedures in parasitology, 1 Oct. 1960.