

AD620401

1

THE ABSENCE OF MICROORGANISMS
IN INFLAMED GINGIVAE

CLEARING HOUSE
FOR FEDERAL GOVERNMENT
TECHNICAL INFORMATION
hardcopy \$2.00 \$0.50 30 edj
PROGRAMS

ARCHIVE COPY

by

Dale F. P. Rank, B.S., D.D.S.

The Ohio State University

1965

SEP 15 1985
SERIALS ACQUISITION
FISIA II

1

RANK, DALE F. P.

MED

THE ABSENCE OF MICROORGANISMS IN INFLAMED GINGIVAE

1965, The Ohio State University

Contract No AF 33(608)-1695

3 cys recd: 1-DDC, 1-AU, 1-Hq USAF

**THE ABSENCE OF MICROORGANISMS
IN INFLAMED GINGIVAE**

A Thesis

**Presented in Partial Fulfillment of the Requirements
for the Degree of Master of Science**

by

**Dale F. P. Rank, B.S., D.D.S.
The Ohio State University
1965**

Approved by

**Adviser
College of Dentistry**

ACKNOWLEDGMENT

The author wishes to express his sincere appreciation to Dr. Charles W. Conroy for his guidance and advice throughout this study.

The assistance of Mrs. Frances B. Dombek, Mr. Dorrance T. Kelly, and Mr. Charles C. Durbin in sectioning and staining tissues was greatly appreciated.

Acknowledgment is also made to the United States Air Force who made this study possible.

TABLE OF CONTENTS

	Page
Introduction.....	1
Literature Review.....	2
Materials and Methods.....	5
Results.....	8
Discussion.....	12
Summary and Conclusions.....	16
References.....	17
Illustrations.....	20

INTRODUCTION

The role that microorganisms play in gingival inflammation and consequently in periodontal disease, remains undetermined. Microorganisms are consistently present within the oral cavity, the clinically healthy gingival sulcus, and periodontal pockets.^{2,3,16,27} They are always associated with gingival inflammation, but research has failed to determine the relationship between microorganisms and gingival inflammation.

Microorganisms may initiate or contribute to an inflammatory response by: (1) primary invasion of the tissues, (2) secondary invasion of the tissues, (3) diffusion of their enzymes and/or toxins into the tissues with or without invasion.

The purpose of this study is to investigate the incidence of microorganisms in chronically inflamed gingival tissues associated with periodontal pockets.

LITERATURE REVIEW

The prevailing view is that microorganisms play no more than a secondary or indirect role in periodontal disease.¹ This suggests that microorganisms do not invade the gingival tissues, but more research is required to clarify this view. However, most investigators agree that, if microorganisms were not present, the clinical picture might be entirely different and the course of the disease of much shorter duration.^{2,3}

Box⁴ described the presence of brushlike and cocklebur formations of organisms in periodontal pockets. These formations are adjacent to fairly large areas of necrotic epithelium and are not observed above or below the epithelial breaks. Similar brushlike formations were observed earlier by Tunnicliff⁵ and Beust.⁶ Dean⁷ and Dean⁸ observed cocklebur formations of bacillary forms associated with the pseudomembrane of necrotic gingivitis.

Shultz-Haudt, Bruce, and Bibby⁹ took smears from the inflamed gingiva of nonspecific marginal gingivitis. The same types of bacteria were present in both clinically healthy and inflamed tissue smears, but smears from inflamed tissue showed an increase in certain types and in total number of organisms. Their study of stained tissues failed to reveal bacteria in the connective tissue corium

of the gingiva. Their conclusion was that bacteria produce inflammation by the release of tissue irritating substances. These substances were identified in a later study by the same investigators as hyaluronidase and collagenase.¹⁰ Neither hyaluronidase nor collagenase could be detected in clinically healthy gingival tissues.

Korn and Schaffer¹¹ have studied bacteremias resulting from gingivectomy procedures. They believed that such bacteremias arose from the gingival sulcus and not from the vital tissues surrounding the teeth. In their opinion, bacteremia was the result of tissue manipulations which alter the integrity of local blood and lymph vessels, allowing bacteria from the sulcus or pocket to enter the blood stream.

Gutverg and Haberman¹² found that bacteremia commonly occurs during gingivectomy procedures. They also found that microorganisms recovered from the gingival surface and periodontal pocket did not always correspond to those isolated from the positive blood cultures. Therefore, they concluded that the sources of microorganisms were not only the epithelial surface and periodontal pocket, but also from microorganisms that were in the connective tissue corium of the periodontium prior to surgery.

Fish¹³ stated that the connective tissues surrounding the teeth may be assumed to be sterile if the epithelium

is intact. However, bacteria may be forced into the connective tissue corium during mastication wherever a break in the epithelium occurs, and form a periodontal abscess. When this occurs, the bacteria will be confined to the necrotic nidus and will not be present among living tissue cells.

More recently, Haberman¹⁴ demonstrated that modified or specialized stains clearly showed microorganisms among living tissue cells in periodontal disease. He suggested that the staining methods used by previous investigators were inadequate. Invading microorganisms were usually seen at or near the epithelial attachment and migrated to the deeper connective tissue by perivascular infiltration.

MATERIALS AND METHODS

Gingival biopsies were performed on tissue specimens obtained from patients at the Graduate periodontics clinic of the Ohio State University. Patients were selected who had advanced periodontal disease requiring surgical correction and who have not had a dental prophylaxis for at least three months prior to the biopsies. The tissue specimens consisted of an interdental papilla and adjacent facial marginal gingiva. The selection of the site from which the tissue specimens were taken was determined by clinical and radiographic evaluation. Eight clinically diseased and eight clinically healthy tissue specimens were selected for this study.

The clinically diseased tissues selected for this study showed chronic inflammation and were associated with periodontal pockets. In the selected cases, occlusal traumatism was not a complicating factor which influenced the periodontal lesion. However, local irritants in the form of dental plaque, materia alba, or calculus were present. Radiographically, some bony defect was observed.

Before obtaining a tissue specimen, the patient rinsed with Cepacol mouthwash. Local anesthesia was infiltrated into the tissues at a point distant to the tissue to be excised. A 1:1000 solution of Zephiran Chloride was applied to the tissue specimen area and the gingiva excised

with a 12-B Bard-Parker blade. The excised tissue was placed immediately in 10% formalin solution. After a minimum of 48 hours for tissue fixation, the specimens were processed and imbedded in paraffin. Slides were prepared from serial buccolingual sections six microns in thickness.

Control tissue specimens were selected from clinically healthy gingiva. Disclosing solution was used to ensure that the selected control tissues were free from local deposits. The adjacent teeth showed no evidence of occlusal disharmonies. Microscopic slides of the control tissues were prepared in the manner described for the diseased tissues.

Staining techniques¹⁵ were selected for their specific capacity to stain the various microorganisms most commonly associated with chronically inflamed gingival tissues and periodontal pockets. Nicholle's stain and the Brown and Brenn stain were used for Gram negative and Gram positive bacteria. Gridley's stain was used for fungi, and Warthin-Starry stain for spirochetes. The hemotoxylin-eosin stain was used as a histological stain to identify the cellular infiltrate due to the inflammatory response.

Serially sectioned slides from the gingival tissues were stained in the following order; the first slide with Nicholle's stain, the second slide with Brown and Brenn stain, the third slide with Gridley's stain, the fourth

slide with Warthin-Starry stain, the fifth slide with hemotoxylin-eosin stain. This cycle was repeated for the remaining slides of the specimen. The same procedure was repeated for all specimens. The stained sections were examined with the light microscope for microorganisms.

This was a blind study. Tissue specimens, after being placed in 10% formalin, were given to a research assistant who recorded and coded them. The specimens were prepared, imbedded, sectioned, stained, and examined under the microscope and all observations recorded under a code number alone.

RESULTS

Microorganisms were not found in the connective tissue or epithelium of any gingival biopsy. In five specimens, microorganisms were demonstrated at the superficial line of incision, on the surface of the crevicular epithelium, or on the surface of the oral epithelium (Figures 1,2,3). Small bacterial clusters were also located contiguous to ulcerations which occurred at the crest of two interdental papillae (Figure 4).

The microorganisms observed were predominately gram positive rods. Most occurred singly, but occasionally were arranged in short chains. In one specimen, larger gram negative rods were intermingled with the gram positive rods. A small number of gram positive cocci were scattered among the predominate rod population. The cocci occurred singly and were of two sizes. No spirochetes or fungi were demonstrated in this study.

The marginal and crevicular epithelium was continuous in all but two specimens. In these two specimens, ulcerations occurred at the crests of the interdental papilla and extended into the connective tissue. At the crests of the non-ulcerated interdental papillae, the surface layers of epithelium were degenerative. The crevicular epithelium showed extensive degenerative changes, particularly

in the apical portions. The integrity of the basement membrane and basal cell layer was intact.

The crevicular epithelium did not show hyperplastic tendencies. Finger-like projections occasionally extended into the connective tissue corium when inflammation was more severe.

Lymphocytes, or lymphocyte-like cells, were observed between epithelial cells in all specimens. They were most frequently seen between the degenerative cells of the crevicular epithelium. Occasionally, a polymorphonuclear leukocyte was evident.

Variable degrees of inflammation were seen in both clinically diseased and control tissues. Lymphocytes and plasma cells were the predominate cell types observed in the inflammatory response. In tissue sections of the interdental papilla, the inflammatory infiltrate extended throughout the connective tissue in four clinically diseased and three control specimens. This was recorded as a severe response. The inflammatory infiltrate in three clinically diseased and five control specimens was observed in the connective tissue papillae at the crest of the interdental papilla, and extended apically to the supra-alveolar region. The infiltrate did not extend buccally into the connective tissue. This was recorded as a moderate

inflammatory response. A slight inflammatory response, in which the inflammatory infiltrate was confined to the connective tissue papillae at the crest of the interdental papilla, was observed in only one clinically diseased specimen.

Tissue sections of interdental papillae showed that inflammatory cells were more dense in the supra-alveolar regions. The inflammatory infiltrate extended laterally and apically in more inflamed sections. In the two ulcerated specimens, almost the entire connective tissue stroma had been replaced by granulation type tissue.

In tissue sections of the facial marginal gingiva, the inflammatory infiltrate was most evident and dense in the connective tissue attachment region. When the infiltrate was confined to this region, it was considered a slight inflammatory response. This was observed in two clinically diseased specimens. In three clinically diseased and seven control specimens, the inflammatory infiltrate extended beneath the crevicular epithelium from the connective tissue attachment region in a coronal direction. This was recorded as a moderate inflammatory response. The inflammatory response in three clinically diseased and one control specimen was severe. In these cases, the inflammatory infiltrate extended throughout the gingival connective tissue.

Inadvertently, one inflamed specimen was imbedded in such a way as to result in transverse rather than bucco-lingual sections. In these interdental papillae sections, the inflammatory infiltrate was more dense in the connective tissue attachment regions. The remaining connective tissue of the interdental papilla had a more limited response with inflammatory cells only in perivascular areas.

The biopsy in which the least amount of inflammatory infiltrate was present was clinically determined to be associated with the greatest pocket depth. There was only a slight inflammatory infiltrate in the connective tissue attachment area and the supra-alveolar area. The bulk of the connective tissue consisted of dense collagen bundles with only a few blood vessels.

DISCUSSION

The absence of microorganisms within the gingival tissues in this study agrees with prevailing opinions that microorganisms do not invade gingival tissues in periodontal disease.^{1,2,13,16,26} Microorganisms were observed contiguous to gingival ulcerations, but were not seen within the exposed underlying connective tissue.

In one inflamed specimen, a small cluster of microorganisms was found within a blood vessel close to the incised surface (Figure 5). However, in following the course of the vessel in serial sections, the vessel directly communicated with the incised surface (Figure 6). This indicated that the microorganisms may have been introduced by tissue manipulation rather than by invasion. Some investigators^{17,26} found that this had occurred in their studies.

Microorganisms could be demonstrated readily on the tissue surface with the Brown and Brenn stain. If microorganisms had been present within the tissue, it would be logical to assume that they would have been as easily detected. Nicholle's stain was less satisfactory because it did not clearly identify microorganisms demonstrated by the Brown and Brenn stain. Wertheimer¹⁷ used the Warthin-Starry silver stain to demonstrate spirochetes. However,

silver impregnation methods using paraffin sections are not dependable.¹⁵ Silver impregnation of an entire tissue specimen is most successful, but this could not be used in this study because serial sections of each biopsy were stained by several staining methods.

The finding of a cellular inflammatory infiltrate in the connective tissue attachment region of all specimens in this study is consistent with current opinion that this may be a common occurrence in both clinically healthy and diseased tissues. Thoma²⁰ stated that inflammation at the dental surface is so common that it may be considered a physiologic process. Others²¹ have found that clinically healthy gingiva frequently showed regions of the connective tissue infiltrated by inflammatory cells. Another study has indicated that inflammation originates at the connective tissue attachment region.¹⁹

An inflammatory infiltrate also was observed consistently within the connective tissue of the interdental papilla. This observation, plus the findings of degenerated epithelium and ulceration of interdental papillae, leads support to the concept that the col of the interdental papilla may be the most vulnerable part of the periodontium during the pathogenesis of periodontal disease.²² The formation of the col has been described as the union of the

interproximal enamel epithelia of two adjacent teeth at the same time of eruption.²³ Since the enamel epithelium is not capable of performing the protective functions of oral epithelium and is at a later time replaced by stratified squamous epithelium, injury occurring before the enamel epithelium is replaced or incomplete fusion with the oral epithelium may result in chronic ulceration and eventual periodontal disease.

The degenerative changes occurring in the crevicular epithelium appeared to depend on the severity of the underlying inflammatory infiltrate. Marwah, Weinmann, and Meyer²¹ found that an underlying inflammatory process acts as an irritant and causes epithelial cells to divide. However, there seems to be an optimum level of irritation because the mitotic rate decreases with increased inflammation and marked degeneration of epithelial cells occurs.

The finding of lymphocytes between epithelial cells appears to be a common occurrence. Cattoni²⁴ found lymphocytes between epithelial cells in all clinically healthy gingival specimens studied. The lymphocytes migrated through the basal layer cells of the epithelium and into the prickle-cell layer, but rarely beyond this. The migration of the lymphocytes into the epithelium was not considered to be accidental, but rather, as an indication

of a defense reaction. Marwah, Weinmann, and Meyer²¹ noted that inflammatory cells migrated into the epithelium only when the underlying inflammatory cells were dense. Grant and Orban²⁵ also have found numerous polymorphonuclear leukocytes between crevicular epithelial cells in chronically inflamed gingival specimens. They believed that the epithelial attachment was a pathway for the penetration of diffusible bacterial products.

SUMMARY AND CONCLUSIONS

Microorganisms have been considered for many years as an important etiological factor in inflammatory periodontal disease. The prevailing view is that microorganisms do not invade the living gingival tissues, but damage the tissues by the action of their toxins or enzymes.

In this study, microorganisms were not observed to have invaded viable gingival tissues. The microorganisms were seen on the incised surface, on the oral and crevicular epithelial surfaces, and on ulcerated surfaces. The Brown and Brenn stain was the most reliable stain used to demonstrate microorganisms; however, the microorganisms were not identified.

Ulceration of the epithelial surfaces was not a notable feature of inflamed gingivae since only two interdental papillae were ulcerated, and the crevicular epithelium was intact in all specimens.

The presence or absence of an inflammatory infiltrate could not be determined clinically. Both clinically diseased and healthy control tissue biopsies demonstrated variable amounts of inflammatory infiltrate in the connective tissues. Lymphocytes, or lymphocyte-like cells, were present between epithelial cells in varying numbers.

BIBLIOGRAPHY

1. Hurst, Valerie: Bacterial Flora of the Mouth, J. Periodont. 27:87 January, 1956.
2. Rosebury, Theodor: Etiological Factors in Periodontal Disease, Oral Surg., Oral Med., & Oral Path. 5:473, 1952.
3. Rosebury, Theodor: The Role of Infection in Periodontal Disease, Oral Surg., Oral Med., & Oral Path. 5:363, 1952.
4. Box, H. K.: Can Specific Infective Factors Operate to Deepen a Pocket? J. Canad. D. A. 10:427, October, 1944.
5. Tunicliff, R.: Fusiform Organisms in the Mouth, J. D. Res. 17:53, 1938.
6. Beust, T. B.: Spirochaetes and Fusiform Bacilli of the Mouth, J.A.D.A. 16:1415, 1929.
7. Dean, M. T.: Summary of our Observations on Cultural Characteristics of Fusospirochaetes, J. Periodont. 2:104, 1931.
8. Dean, R. D.: Summary of our Observations on Clinical Manifestations of Fusospirochaetes, J. Periodont. 2:103, 1931.
9. Shultz-Haudt, S., Bruce, M. A., and Bidby, B. G.: Bacterial Factors in Nonspecific Gingivitis, J. D. Res. 33:454, August, 1954.
10. Shultz-Haudt, S., Bruce, M. A., and Bibby, B. G.: Tissue Destructive Products of Gingival Bacteria from Nonspecific Gingivitis, J. D. Res. 33:624, October, 1954.
11. Korn, N. A., and Schaffer, E. M.: A Comparison of the Post-Operative Bacteremia Induced Following Different Periodontal Procedures, J. Periodont. 33:226, July, 1962.

12. Gutverg, M. and Haberman. S.: Studies of Bacteremia Following Oral Surgery: Some Prophylactic Approaches to Bacteremia and the Results of Tissue Examination of Excised Gingiva, J. Periodont. 33:105, April, 1962.
13. Fish, E. W.: The Location of Bacteria in the Oral Tissues, J. Canad. D. A. 10:385, September, 1944.
14. Haberman, S.: Inflammatory and Non-Inflammatory Responses to Gingival Invasion by Microorganisms, J. Periodont. 30:190, July, 1959.
15. McManus, J. F. A., and Mowry, R. W.: Staining Methods Histologic and Histochemical, New York, Harper & Row, 1963.
16. Bibby, B. G.: The Role of Bacteria in Periodontal Disease, Oral Surg, Oral Med., and Oral Path. 6:318, 1953.
17. Wertheimer, F. W.: A Histologic Study of Microorganisms in Human Periodontal Tissues, J. Periodont. 35:406, September-October, 1964.
18. Robbins, S. L.: Textbook of Pathology, ed. 2, W. B. Saunders Co., Philadelphia & London, 1962.
19. Goldman, H. M.: Extension of Exudate Into Supporting Structures of Teeth in Marginal Periodontitis, J. Periodont. 28:175, July, 1957.
20. Thoma, K. H.: Oral Pathology, ed. 4, St. Louis, C. V. Mosby Co., 1957.
21. Marwah, A. S., Weinmann, J. P., and Meyer, J.: Effect of Chronic Inflammation on the Epithelial Turnover of Human Gingiva, Arch. Path. 69:147, 1960.
22. Cohen, B.: Pathology of the Interdental Tissues, D. Practitioner, 9:167, March, 1959.
23. Cohen, B.: Morphological Factors in the Pathogenesis of Periodontal Disease, Brit. D. J. 107:31, July, 1959.
24. Cattoni, M.: Lymphocytes in the Epithelium of the Healthy Gingiva, J. D. Res. 30:627, October, 1951.

25. Grant, D. A., and Orban, B.: Leukocytes in the Epithelial Attachment, J. Periodont. 31:87, April, 1960.
26. Gibson, W. A., and Shannon, I. L.: Simulation With Carbon Particles of Bacterial Infiltration of Human Gingival Tissues, J.A.S.P. 3:57, Mar 1-April, 1965.
27. Gavin, J. B., and Collins, A.A.: The Occurrence of Bacteria Within the Clinically Healthy Crevice, J. Periodont. 32:198, July, 1961.

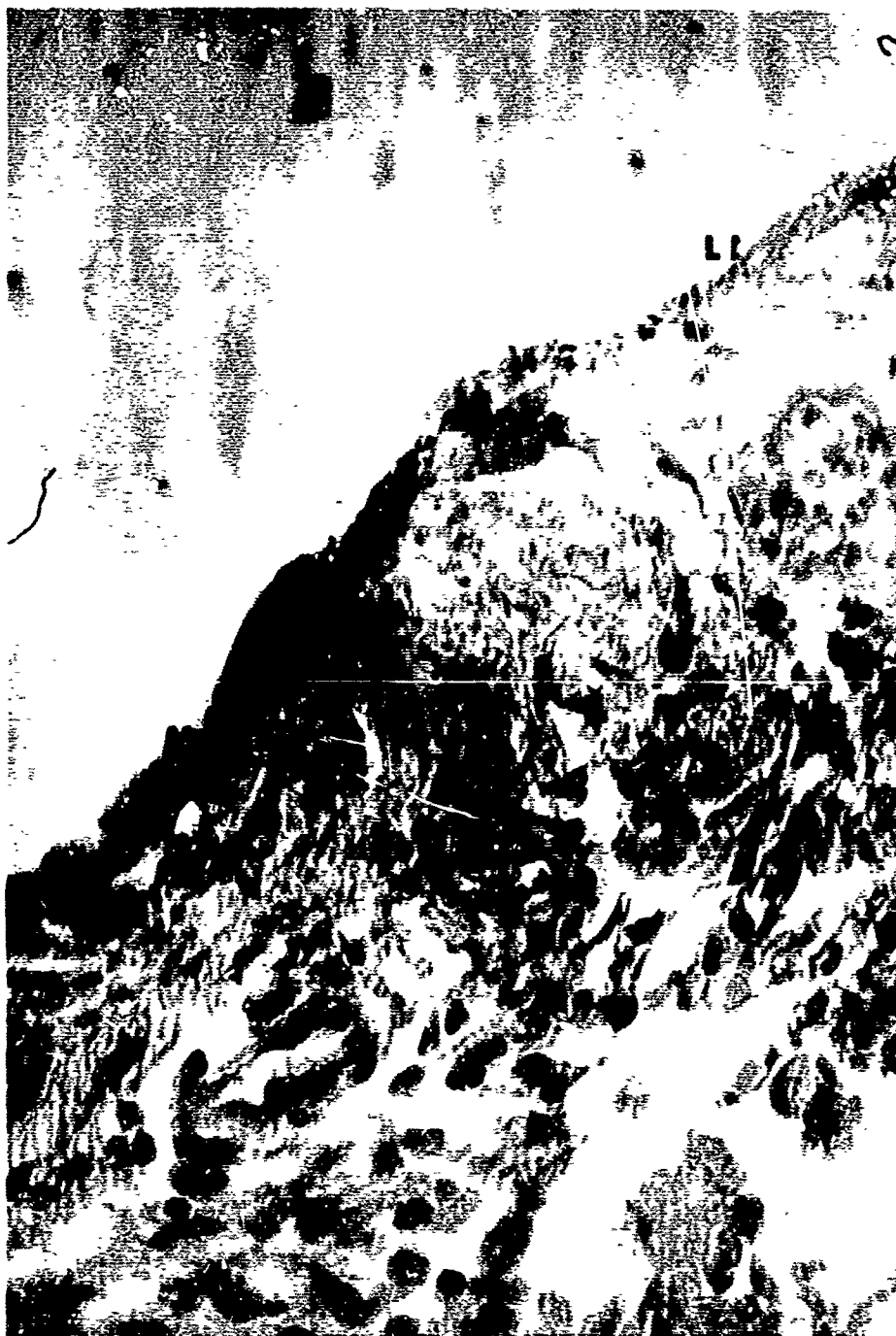

Figure 1. Microorganisms demonstrated along the line of incision. (M) Microorganisms; (LI) Line of Incision; (CT) Connective Tissue of Gingiva. Orig. Mag. 450X




Figure 2. Cluster of microorganisms next to the cut connective tissue surface. (CM) Cluster of Microorganisms; (CT) Cut Connective Tissue Surface; (E) Erythrocytes. Orig. Mag. 450X



Figure 3. Microorganisms near the surface of the crevicular epithelium. (M) Microorganisms; (CE) Crevicular Epithelium. Orig. Mag. 1000X

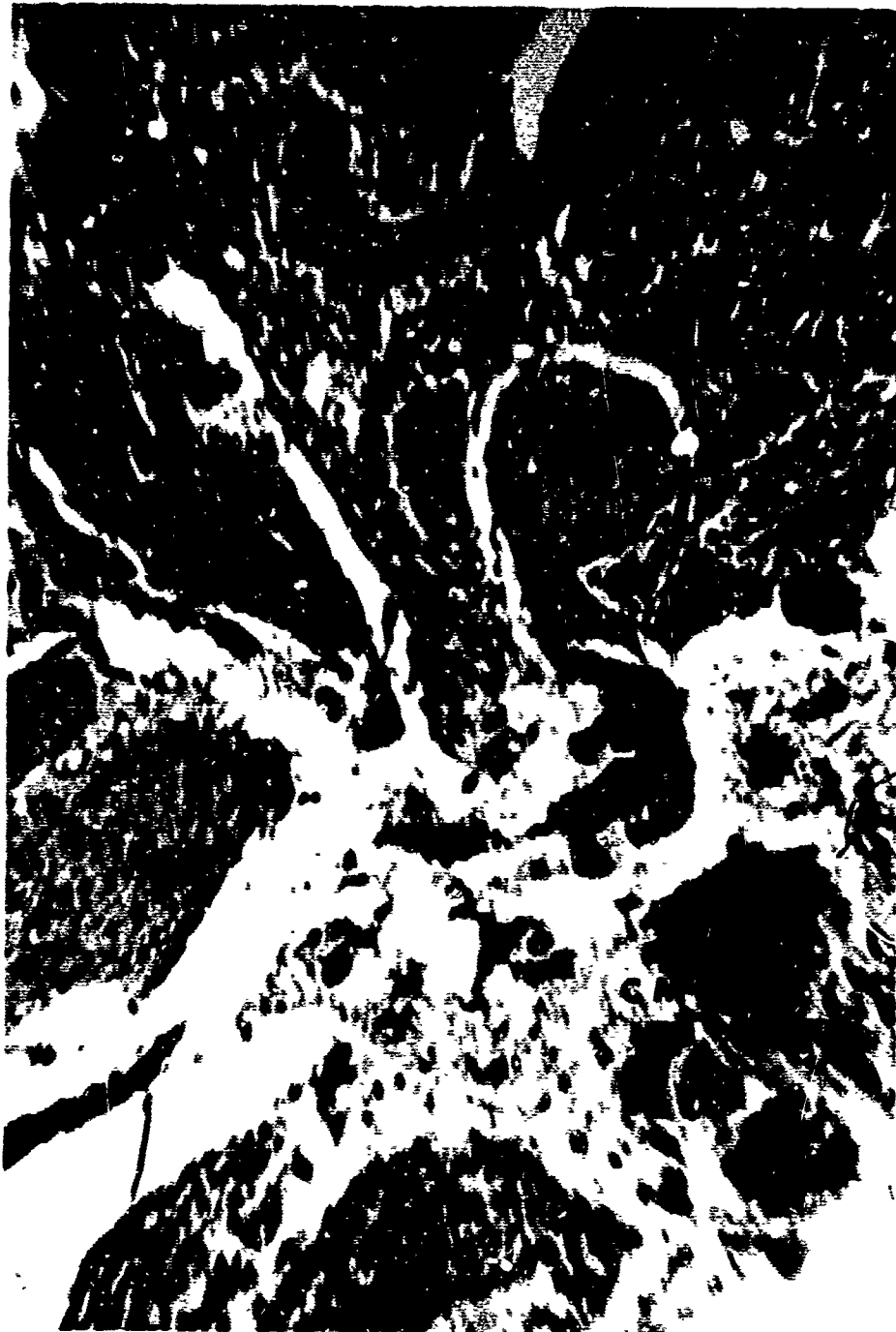

Figure 4. Cluster of Microorganisms contiguous to the ulceration at the crest of an interdental papilla. (CM) Cluster of Microorganisms; (CT) Connective Tissue at Base of Ulcer; (E) Part of the Remaining Epithelium. Orig. Mag. 100X




Figure 5. Cluster of Microorganisms within a blood vessel near the line of incision. (CM)
Cluster of Microorganisms. Orig. Mag. 450X

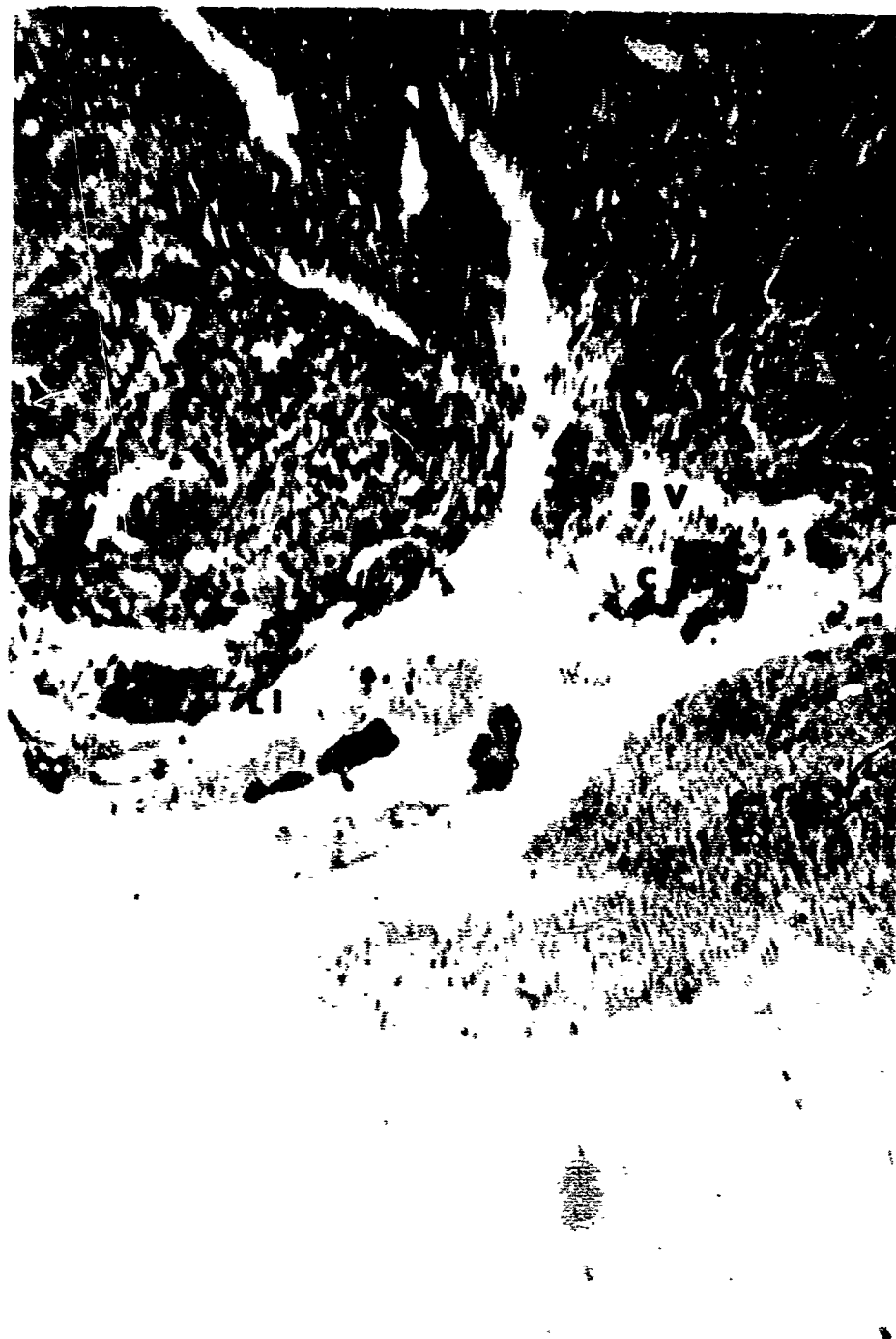

Figure 6. The blood vessel containing microorganisms in Figure 5 directly communicating with the incised surface. (BV) Blood Vessel; (CM) Cluster of Microorganisms; (LI) Line of Incision. Orig. Mag. 100X