

UNCLASSIFIED

AD NUMBER
AD432433
NEW LIMITATION CHANGE
TO Approved for public release, distribution unlimited
FROM Distribution authorized to U.S. Gov't. agencies and their contractors; Administrative/Operational Use; FEB 1964. Other requests shall be referred to U.S. Army Biological Laboratories, Frederick, MD.
AUTHORITY
BORL D/A ltr, 27 Sep 1971

THIS PAGE IS UNCLASSIFIED

UNCLASSIFIED

AD 432433

DEFENSE DOCUMENTATION CENTER

FOR

SCIENTIFIC AND TECHNICAL INFORMATION

CAMERON STATION, ALEXANDRIA, VIRGINIA



UNCLASSIFIED

NOTICE: When government or other drawings, specifications or other data are used for any purpose other than in connection with a definitely related government procurement operation, the U. S. Government thereby incurs no responsibility, nor any obligation whatsoever; and the fact that the Government may have formulated, furnished, or in any way supplied the said drawings, specifications, or other data is not to be regarded by implication or otherwise as in any manner licensing the holder or any other person or corporation, or conveying any rights or permission to manufacture, use or sell any patented invention that may in any way be related thereto.

432433

AS AD NO.

432433

TECHNICAL MANUSCRIPT 124

MYOCARDITIS IN NORMAL
RHESUS (*Macaca mulatta*) MONKEYS

FEBRUARY 1964

DDC
MAR 20 1964
TISH. A

UNITED STATES ARMY
BIOLOGICAL LABORATORIES
FORT DETRICK

NO OTS

U.S. ARMY BIOLOGICAL LABORATORIES
Fort Detrick, Frederick, Maryland

TECHNICAL MANUSCRIPT 124

MYOCARDITIS IN NORMAL RHESUS (MACACA MULATTA) MONKEYS

Peter J. Soto, Jr.

Francis A. Beall

Robert M. Nakamura

Lasarus L. Kupferberg

Pathology Division
DIRECTOR OF MEDICAL RESEARCH

Project 1C622401A072

February 1964

Portions of the work reported here were performed under Project 1C022301A070 "Aerobiological Research," Task -03, "Pathogenesis of BW Aerosol-Induced Infection." Expenditure order was 2037. This material was originally submitted as manuscript 5300.

The information in this document has not been cleared for release to the public.

DDC AVAILABILITY NOTICE

Qualified requestors may obtain copies of this document from DDC.

Foreign announcement and dissemination of this document by DDC is limited.

ACKNOWLEDGMENTS

The authors wish to thank Dr. Melvin Rabstein, Chief of the Animal Farm at Fort Detrick, and his associates for their help and advice during the holding period in which the various examinations were performed. We wish also to thank Major Thomas Smith of the U.S. Army Medical Unit, Fort Detrick, for interpreting the electrocardiograms, and Sp/4 Leonard H. Fivnick and Mr. Richard W. Hill, of Fort Detrick, for excellent technical assistance.

ABSTRACT

A clinical-pathological study was undertaken to ascertain the etiology of myocarditis seen in 18 of 20 normal rhesus monkeys. The results of this study indicate that the myocarditis is not due to a virus that kills suckling mice, nor to bacteria. Moreover, viral inclusion bodies or parasites were not demonstrated morphologically in the myocardium. The myocarditis is most probably idiopathic.

Inclusion bodies of salivary gland virus localized to the kidneys of 6 of the 20 monkeys have been described.

The significance of slightly elevated SGOT and SGPT values and the presence and significance of multinucleated hepatic parenchymal cells are discussed.

Additional hematological and clinical chemistry values are recorded, as are both gross and microscopic anatomical data.

I. INTRODUCTION

The etiologic agents responsible for myocarditis in man are legion.^{1,2} However, in lower animals, chiefly primates, the number of agents is small and is generally limited to viruses and, in some instances, parasites. Specifically, the viruses known to cause myocarditis in monkeys belong to the encephalomyocarditis (EMC) family.³ Although Coxsackie viruses have been used in the experimental production of myocarditis in monkeys,^{4,5} they have not been isolated from the tissues of normal or ill monkeys except in the case of cynomolgus monkeys, where they cause inapparent infection.⁶ In addition, bacteria⁷ have been employed to produce myocarditis and the results indicate that killed streptococci can produce an inflammatory picture similar to that seen with viral agents. The role of stress in the production of myocarditis in primates is difficult to assess, but may be quite important.

During examination of necropsy material from numerous rhesus monkeys, both normal and infected, one of us (P.J.S.) observed the presence of myocarditis in a high percentage of the animals regardless of their condition. Consequently, since the rhesus monkey is a commonly used experimental animal, it seemed both logical and necessary to undertake a study with the specific object of answering the question of whether the myocarditis is secondary to a viral, bacterial, or other infection, or is a spontaneous entity as alluded to by Vanace.⁸ Therefore, a clinical-pathological correlative study was undertaken. To our knowledge, this was the first attempt to determine the etiology of this myocarditis.

II. MATERIAL AND METHODS

Twenty clinically normal rhesus monkeys, estimated to be three years old, were studied.* There were 9 males and 11 females weighing from 2.0 to 3.3 kilograms each. These monkeys had been brought from India by airplane six weeks prior to the start of this investigation and kept by the importer during this time. The studies described here were carried out during the first several weeks after the monkeys were transferred to the Animal Farm at Fort Detrick. During this period, they were housed two per cage, fed commercial monkey chow, and given water *ad libitum*. All monkeys gave negative results when tuberculin-tested with 0.2 milliliter of 1:10 dilution of old tuberculin given intrapebrally. During the study all animals appeared clinically well except Number 20, which had a transient diarrhea for one day and responded well to antibiotics.

The following tests were begun shortly after the tuberculin tests were read. Unless stated otherwise in the text, each monkey was tested three times at weekly intervals: electrocardiograms, standard and augmented leads (Sanborn Model 51); hematocrit (micro-capillary method of Strumia);⁹ hemoglobin (cyanmethemoglobin);¹⁰ white blood count and differential and sedimentation rate (Wintrobe-Landsberg method);¹¹ blood urea nitrogen (method of Fawcett and Scott¹² in UN-test,¹³ Hyland Laboratories); serum glutamic-oxaloacetic transaminase (SGOT) and serum glutamic-pyruvic transaminase (SGPT) (colorimetric method of Reitman and Frankel,¹⁴ Kit Number 505-OP,¹⁵ Sigma Chemical Company); antistreptolysin-O titers (method of Rantz and Randall,¹⁶ Difco Laboratories kit); total plasma proteins (semi-micro modification of the biuret method of Gornall);¹⁷ albumin:globulin ratio (A:G) by means of paper electrophoresis (procedure B, Model R electrophoresis system, Beckman Instruments).¹⁸

All blood samples were drawn from the femoral vein using syringes containing heparin and, consequently, the clinical chemistry tests reflect plasma values rather than serum.

All tests were done in duplicate with appropriate controls except for the white count with differential and sedimentation rate.

Plasma obtained just prior to euthanasia was frozen for use in viral serologic studies.

* In conducting the research reported here, the investigators adhered to "Principles of Laboratory Animal Care" as established by the National Society for Medical Research.

The animals were euthanized with intravenous pentobarbital supplemented on occasions with an intraperitoneal injection. Complete necropsies were performed over a two-day period beginning the day following the last series of tests. The tissues derived therefrom were fixed in buffered formalin and routinely stained with hematoxylin and eosin. Occasionally, reticulin, Giemsa, and periodic acid-Schiff (PAS) stains were employed.

At the time of necropsy, blood and sections of heart, liver, and lung were submitted for bacterial isolations. Sections of the apex of the heart to include the septum and both ventricles were obtained for viral isolations, as were sections of the brain stem.

The individual organs were stripped of extraneous tissue and weighed to within 0.1 gram. The gall bladder was expressed but weighed with the liver. The body weights were determined to within 30 grams.

Tissues submitted for bacterial isolations were triturated with sterile saline (0.85 per cent) in Ten Broeck homogenizers and streaked onto glucose cystine blood agar (GCBA) plates. Blood samples were streaked on GCBA plates and inoculated into B-D vacutainers (Becton, Dickinson and Co., Rutherford, New Jersey) culture bottles containing 50 milliliters of trypticase soy broth (TSB) and carbon dioxide. All cultures were incubated at 37°C and examined daily. GCBA plates not exhibiting growth after 48 hours were considered sterile and were discarded. TSB cultures not exhibiting growth during a two-week period of incubation were considered sterile. Single colonies from GCBA plates were grown on stock agar medium and heart infusion broth (Difco). Isolated organisms were identified by standard microbiological methods.

Since suckling mice are susceptible to a variety of viruses including the strains of Coxsackie, types A and B, and encephalomyocarditis virus, they were used in the isolation attempt. Heart and brain tissue was obtained aseptically from each of the twenty normal monkeys. All tissues were stored in sterile containers at -60°C until used. Tissues for mouse inoculation were thawed, weighed, and triturated in Ten Broeck tissue homogenizers. A ten per cent suspension of tissue was made by dilution with heart infusion broth (Difco) that contained 200 units of penicillin and 200 micrograms of streptomycin per milliliter. The suspension was clarified by centrifugation.

Randomly selected suckling mice less than 48 hours old were inoculated with the heart tissue suspension. Two groups of mice were inoculated for each preparation. One group received 0.02 milliliter intracerebrally and another group was inoculated subcutaneously with 0.03 milliliter. The brain suspension was used similarly to inoculate suckling mice. The mice were returned to the dams and observed daily for 14 days. Deaths occurring on the first or second day after inoculation were considered to be due to trauma.

Sera obtained from five monkeys at the time of necropsy were tested for neutralizing antibodies to strains of Coxsackie B and encephalomyocarditis virus. These monkeys (Numbers 6, 7, 9, 10, and 16) exhibited minimal to severe myocarditis. The viruses used in the test were Coxsackie B3 and B4 obtained from American Type Culture Collection, and encephalomyocarditis virus kindly supplied by the Virology Department of Walter Reed Army Institute of Research.

~~Sera were heated in a water bath at 56°C for one hour prior to testing.~~ Appropriate dilutions of sera were added to samples of virus of constant concentration. The sera-virus mixture was incubated at room temperature for one hour and injected intracerebrally into suckling mice. The mice were returned to dams and observed daily for 14 days.

III. RESULTS

A. ANATOMICAL DATA

Table I depicts anatomical data from the 20 monkeys, including the nutritional state, body weight, individual organ weights, and sex. As indicated, the nutritional state of the animals varied from poor to excellent. This observation is based on general physical appearance and on the amount of fat present in subcutaneous tissue as well as other fat depots.

The individual organ weights are listed and, in general, did not correlate well with the body weights or with the nutritional state of the animals. However, as a group, the weights of the various organs were well within the range of values accepted as normal in the literature.¹⁷

B. PATHOLOGY

1. Gross Observations

The principal gross pathological changes were confined to the lungs and colon. The lungs of 17 of the animals displayed lesions due to mites (Pneumonyssus spp.) located subpleurally and in the parenchyma. These lesions, tan in color, averaged 0.5 centimeter in diameter and on the cut surface appeared cystic. The number of mites varied from one to nine per animal with an average of three. One animal (Number 9) exhibited moderate pulmonary hemorrhage and three had marked pulmonary edema (Numbers 4, 13, and 16).

TABLE I. ANATOMICAL DATA FROM 20 NORMAL RHEBUS MONKEYS

Monkey Number	Sex	Nutritional State	Body Weight, kg	Organ Weights, gm									
				Heart	Liver	L. Lung	R. Lung	Spleen	Kidney ^a	Adrenal	Brain	Pancreas	Thymus
1	M	Fair	2.2	9.5	65.5	5.5	7.0	4.0	6.0	0.9	80.0	4.0	2.0
2	F	Good	3.2	14.2	120.0	10.0	15.0	7.4	9.2	1.5	73.0	4.0	4.2
3	F	Good	2.6	12.0	78.0	8.5	11.0	6.0	7.6	1.0	79.0	6.0	7.0
4	F	Fair	2.6	13.5	75.5	14.3	16.5	4.0	6.5	1.0	80.0	4.0	3.5
5	F	Good	2.4	9.0	64.0	5.7	7.0	3.0	5.4	1.2	72.0	4.0	2.0
6	F	Good	2.6	11.5	84.0	8.0	9.5	4.0	7.0	1.4	79.0	4.0	Absent
7	M	Fair	2.3	8.0	65.0	8.4	8.0	5.0	7.4	1.4	78.0	3.7	2.0
8	F	Fair	2.2	8.0	79.0	9.5	8.0	3.1	5.7	0.7	71.5	3.0	2.0
9	M	Poor	2.8	11.0	80.0	11.5	8.0	5.0	8.0	0.6	87.0	4.2	2.5
10	M	Fair	2.4	12.5	78.0	7.2	8.0	4.0	7.5	1.2	73.5	4.0	2.0
11	F	Good	3.0	13.4	79.0	8.0	9.0	5.0	7.0	1.0	74.0	6.5	2.0
12	M	Fair	2.5	14.4	70.0	5.5	7.2	2.5	5.0	1.0	75.0	3.5	5.0
13	M	Fair	2.2	10.5	61.0	16.0	21.7	3.0	5.0	1.0	75.0	5.4	Absent
14	M	Good	2.9	13.0	76.0	6.0	7.0	5.0	6.5	1.0	79.0	4.5	3.0
15	F	Fair	3.0	11.0	106.0	8.4	12.0	7.5	7.0	0.6	73.0	2.0	3.0
16	M	Fair	2.5	10.5	66.0	23.8	25.0	2.8	5.0	1.2	72.0	3.5	Absent
17	M	Excellent	2.7	9.5	79.0	5.8	7.5	2.2	7.4	1.0	76.0	4.0	1.6
18	F	Good	3.3	14.0	84.2	8.5	10.7	4.5	7.0	1.0	84.0	5.2	Absent
19	F	Fair	2.0	7.5	61.0	7.1	8.0	3.7	5.0	0.7	78.0	3.5	Absent
20	F	Good	2.9	10.0	66.2	8.0	8.0	7.0	7.0	1.0	75.0	4.5	3.0

a. Average weights of both kidneys.

In eight of the monkeys, the colon exhibited numerous purple, slightly raised areas beneath the serosa indicative of Oesophagostomum spp. infestation. The lesions were of varying degrees of severity.

2. Microscopic Observations

Eighteen of the 20 monkeys exhibited myocarditis in varying degrees of severity. Ten were considered minimal, five moderate, and three marked. The basis for this classification was the size and number of individual lesions. The myocarditis, regardless of its severity, was usually focal, but occasionally was interstitial and extensive. The accompanying cellular infiltrate consisted predominantly of lymphocytes, large mononuclear cells, and an occasional plasma cell and eosinophil. Necrosis was not a constant feature but when present was minimal and seen only when the myocarditis was marked (Figure 1). When the cellular accumulations were moderate or interstitial, they were accompanied by edema. Enlargement of many of the nuclei of myocardial fibers was observed in areas adjacent to the most severe degree of myocarditis. Foci of inflammation were seen in the septum and both ventricles, but mainly in the left ventricle. Endocarditis was not seen, but in one animal an inflammatory infiltrate was noted in the adventitia of the pulmonary artery. There was no histologic evidence suggesting repeated episodes of myocarditis. In addition, no bacteria, viral inclusion bodies, or parasites were seen.

The histopathological responses to the presence of lung mites were essentially the same as those described by Innes¹⁴ except that in our study, giant cells of the foreign-body type were seen in two cases (Figure 2). In the few cases without mite lesions, the lungs contained focal collections of lymphocytes, usually in juxtaposition to various divisions of the respiratory tree (Figure 3). Three animals exhibited pulmonary edema and another had pulmonary hemorrhage.

The morphologic changes in the liver were varied. Virtually all animals showed infiltration of the portal areas with lymphocytes and plasma cells. In several instances, this change was accompanied by an increased number of mononuclear cells in the sinusoids and in others by multiple focal collections of lymphocytes within the hepatic lobule, without necrosis. Incipient fatty metamorphosis was seen in four cases. A most interesting but unexplained finding was the presence of multinucleated hepatic parenchymal cells containing from 3 to as many as 15 nuclei (Figure 4). This change, present in seven monkeys (Numbers 4, 9, 12, 13, 16, 17, and 20), was accompanied by congestion and edema of the sinusoids with separation of the individual parenchymal cells. These giant cells were distributed at random throughout the liver and bore no constant relationship to any zone of the lobule. Bile stasis, necrosis, fibrosis, or inclusion bodies were not observed.



Figure 1a. A Typical Field Depicting Marked Myocarditis. Note enlarged nuclei of myocardial fibers. Hematoxylin and eosin; 195X.



Figure 1b. A Higher Magnification of the Inflammatory Infiltrate in Figure 1a. Note minimal necrosis of myocardial fibers. Hematoxylin and eosin; 630X.



Figure 1c. An Example of Moderate Degree of Myocarditis. Hematoxylin and eosin; 195X.




Figure 1d. Minimal Myocarditis. Hematoxylin and eosin; 195X.

The nidus of infestation with Oesophagostomum was located chiefly in the subserosa of the colon and, on occasions, in the submucosa and muscularis. The basic lesion consisted of a localized zone of hemorrhage and necrosis surrounding the nematode larvae, and this in turn was circumscribed by a zone of foreign-body giant cells and chronic inflammatory cells. Sections of small intestine and colon (unassociated with Oesophagostomum infestation) revealed submucosal lymphoid follicles as well as a heavy infiltration of the mucosa with lymphocytes and plasma cells. The stomach depicted similar changes but to a lesser degree.

One of the more interesting findings was the presence of inclusion bodies characteristic of salivary gland virus in the kidneys of six of the monkeys (Numbers 1, 7, 8, 12, 16, and 19). The inclusion bodies located within the nuclei were eosinophilic and were confined to the proximal and distal convoluted tubules. Although no definitive cytoplasmic inclusions were seen, the cytoplasm did contain granular PAS-positive material. The cells containing the inclusions were quite large and lay free in the lumens of the tubules without an associated inflammatory reaction (Figure 5). Inclusion bodies were confined to the kidney and were not seen in other organs, including the salivary glands, although the latter did contain an occasional collection of chronic inflammatory cells. Nonspecific collections of chronic inflammatory cells were also seen in the renal cortices of many animals.

The lymph nodes, regardless of location, usually exhibited reactive hyperplasia and, in some instances, mite pigment and erythrophagocytosis.

The adrenal gland contained small calcium deposits distributed at random in the cortex and/or medulla in 12 of the 20 animals.

The ovaries exhibited evidence of maturation of ova. However, the testes were devoid of spermatogenesis.

Changes in the central nervous system were confined to focal collections of oligodendroglial cells in the lentiform nucleus in two cases. A small single focus of lymphocytes in the parietal cortex and a similar area in the region of the lateral ventricle were observed in two other animals.

Sections of the pectoralis and laryngeal muscles of two monkeys contained the typical cysts of sarcosporidiosis.

In most instances, the bone marrow, vertebral and sternal, was normocellular. It was hypocellular in five (Numbers 2, 5, 9, 10, and 12) and hypercellular in two (Numbers 1 and 11). The remaining organs were not remarkable.

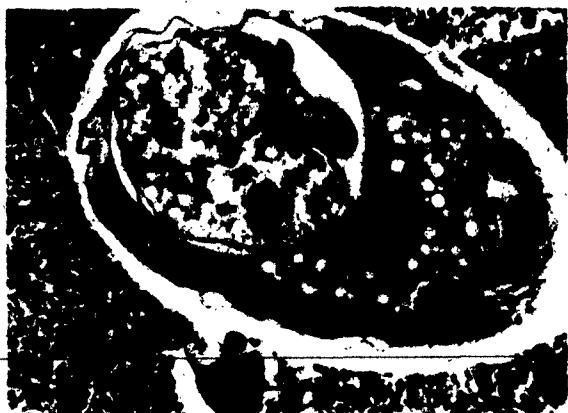

Figure 2. Cross Sections of a Lung Mite with Associated Inflammatory Reaction. Arrow A indicates the presence of a giant cell. Hematoxylin and eosin; 195X.




Figure 3. A Nonspecific Collection of Chronic Inflammatory Cells in the Lungs Adjacent to a Vein. Hematoxylin and eosin; 195X.




Figure 4. A Field Depicting Giant Cell Transformation of the Hepatic Parenchymal Cells. Note early fatty metamorphosis. Hematoxylin and eosin; 630X.




Figure 5. Kidney: Two Unattached Cytomegalic Cells Containing Characteristic Nuclear Inclusions of Salivary Gland Virus. Hematoxylin and eosin; 630X.

C. HEMATOLOGICAL RESULTS

The results of the hematological analyses are summarized in Table II. As indicated, the hematocrit and hemoglobin values did not vary appreciably among the 20 monkeys. These values indicated a mean slightly higher and a standard deviation (SD) smaller than reported in the literature.^{19,20} The white blood cell counts were essentially the same as those previously reported.^{19,20} The initial sample from one monkey (Number 20) was 50,275. All other observations ranged from 5500 to 23,800 with a mean of 13,089 and a SD of 4150. The differential counts revealed a distribution of cell types quite similar to that seen by others. The red cell morphology in all smears was adequate with a slight tendency toward anisocytosis. Platelets were abundant. The only significant variation in the sedimentation rate was observed in the third sample from four animals (Numbers 7, 8, 11, and 19). In these, the rate ranged from 7 to 29 millimeters per hour. In all other samples, the rate ranged from 0 to 3 millimeters per hour. The reported mean is about 0.9 millimeter.^{19,20}

D. CLINICAL CHEMISTRY RESULTS

The results of plasma analyses are given in Table III. There was no apparent difference between monkeys on the basis of urea nitrogen or total protein levels. Three monkeys (Numbers 3, 9, and 11) showed increased plasma globulins and lowered albumin resulting in A:G ratios of less than one. The total protein values were higher than those reported²¹ but it should be mentioned that the latter values were derived from unconditioned animals. The mean A:G ratio is slightly higher than the reported value of one.²²

Of the 49 SGOT observations, 37 ranged from 16 to 56 units with a mean of 41.2 and a SD of 10.8. Eleven monkeys showed no values above this range. Analyses of the plasma from each of the other nine animals (Numbers 4, 10, 11, 12, 14, 16, 17, 19, and 20) yielded one or more results ranging from 64 to 123 units. The mean value from the 20 animals was slightly higher than the reported maximum value of 45 units.²³

Fifty-one SGPT analyses from 17 monkeys yielded values ranging from 5 to 48 units with a mean of 19.2 and a SD of 10.0. Three monkeys (Numbers 1, 14, and 20) had values of 64 to 99 units.

E. SEROLOGIC RESULTS

The first and third samples of plasma from each of 20 monkeys was titered for antistreptolysin-O. Of these 20 animals, ten had titers less than 12 Todd units and five (Numbers 2, 11, 14, 18, and 20) had titers of 125 to 166. These latter values are elevated when compared with the reported normal value of less than 32.

TABLE II. HEMATOLOGICAL VALUES OF 20 NORMAL RHESUS MONKEYS

Analysis	Number of Samples	Mean \pm SD	Range
Hematocrit	57	39.3 \pm 3.6	32.5 - 46.5
Hemoglobin, gm/100 ml	57	12.6 \pm 1.1	10.3 - 14.5
Sedimentation Rate, mm/hr	54	2.0 \pm 4.5	0 - 29
White Blood Count, cells/cu mm	57	13,740 \pm 6,715	5,500 - 50,275
Differential Count, per 100 cells	60		
Neutrophils		45.1	12 - 88
Lymphocytes		53.1	15 - 84
Eosinophils		1.0	0 - 10
Basophils		0.3	0 - 1
Monocytes		0.5	0 - 4
Stabs		0.2	0 - 10

TABLE III. ANALYSES OF PLASMA FROM 20 NORMAL RHESUS MONKEYS

Analysis	Number of Samples	Mean \pm SD	Range
SGOT, units/ml	49 ^a	51.5 \pm 22.0	16 - 123
SGPT, units/ml	60	24.8 \pm 19.9	5 - 99
Urea Nitrogen, mg/100 ml	60	20.6 \pm 5.3	8.8 - 34.8
Total Proteins, gm/100 ml	60	7.3 \pm 0.4	6.3 - 8.3
A:G Ratio	60	1.34 \pm 0.31	0.44 - 2.24

a. Results from 11 grossly hemolyzed samples not included.

F. BACTERIOLOGICAL RESULTS

The results of the bacterial isolations were significant in that no organisms were recovered from the heart in any animal. However, E. bronchiseptica was isolated from the lungs in five instances (Numbers 4, 10, 11, 15, and 17) and of these, the same organism was recovered from the blood (Number 4) and liver (Number 10).

G. VIROLOGICAL RESULTS

The presence of virus was not detected by the means employed in this study. The results of the serologic studies were equally disappointing in that the sera of the five animals (Numbers 4, 10, 11, 15, and 17) with the most serious degree of myocarditis did not contain neutralizing antibodies to Coxsackie B3, B4, and EMC viruses.

H. ELECTROCARDIOGRAPHIC RESULTS

Comparison of sequential electrocardiograms failed to reveal any indication of myocarditis or other pathological cardiac abnormalities.

IV. DISCUSSION

As mentioned earlier, Vanace⁶ has suggested that the myocarditis found in 18 of 36 normal rhesus monkeys he examined was a spontaneous entity. However, it should be stressed that no viral or bacterial isolations were attempted in that study. The results of our studies are in agreement with the concept of spontaneity. However, it should be borne in mind that the viruses we attempted to incriminate belong to the Coxsackie and EMC families. These viruses were selected because EMC is known to cause myocarditis in primates and Coxsackie is a well-documented cause of myocarditis in man. Furthermore, since the myocarditis in man histologically resembles that seen in monkeys, it was suspected that low-grade infection with the Coxsackie virus may have been the cause in the latter animal.

Sera (plasma) from the five monkeys with the most severe degree of myocarditis did not contain neutralizing antibodies to EMC or Coxsackie B3 and B4. These findings correlate with the lack of viral isolations from the heart and brain stem.

The lack of pathologic electrocardiographic changes in those animals with myocarditis is not surprising in light of the studies of Lou,⁵ who found no abnormal tracings in cynomolgus monkeys experimentally infected with B3 Coxsackie virus. These animals showed histological evidence of significant and extensive myocarditis. It should be emphasized further that bacterial cultures of the heart were also negative and that no inclusion bodies or parasites were observed in the cardiac fibers.

Consequently, one can only speculate as to the etiology of the myocarditis. Perhaps it is due to a virus or bacterium that has "hit and run," or perhaps it is due to viruses not sought for in this study. It may be recalled that suckling mice were used in the isolation attempt and these animals are susceptible to Coxsackie, EMC, herpes simplex, lymphocytic choriomeningitis, and certain neurotropic arboviruses. The role of stress as mentioned earlier is difficult to evaluate. It may be that this myocardial change is related in part to conditioning of the animal, as we have seen it to a lesser degree and incidence in monkeys conditioned for 12 to 14 weeks rather than for 6 weeks, as in this study.

One of the values of the observations in this communication lies in the fact that those people in comparative pathology who are responsible for interpreting the tissue of monkeys exposed to various infectious agents are permitted to say with confidence that the myocarditis is most probably not due to the organism to which the animal was exposed.

It seems that the degree of myocarditis is not physiologically significant, as the animals appear to tolerate its presence without obvious signs or symptoms.

An attempt to correlate the degree of myocarditis with levels of transaminases and ASO titers yielded little information except that those animals with the most serious myocarditis, except Number 19, had average transaminases in the normal range for monkeys.²² It should be pointed out that the values cited in that study are for SGOT only. Monkeys 10 and 17, both with minimal myocarditis, had levels of SGOT of 106 and 81 respectively. The two monkeys without myocarditis had levels in the range of 60 units.

The average SGPT levels were less than 50 in all instances except in two animals (Numbers 1 and 20) whose levels were 61 and 82. These animals exhibited marked and minimal myocarditis respectively and neither had hepatic necrosis. The cause of these slight elevations was not evident. Although the ASO titers were elevated in five animals, these changes could not be correlated with any bacterial isolations or morphologic observations.

The presence of multinucleated hepatic cells in several of the animals did not reflect changes in the levels of SGOT or SGPT. The origin of these cells remains enigmatic, as there were no accompanying changes to suggest the entity of giant-cell hepatitis or a reparative response.

The presence of the typical inclusion bodies of salivary gland virus in the kidney was a most interesting finding; they appear to be similar to those described by Cowdry.²⁴ The fact that inclusions were not seen in other organs, including the salivary gland, is difficult to explain, but is in keeping with other published reports. These inclusions appeared in unattached tubular cells and were not numerous enough to cause impairment of renal function, as evidenced by the normal urea nitrogen values. This fact plus the lack of inflammatory reaction suggests that this is most probably a latent infection.

Parasitic infestation of the lungs and colon apparently did not cause any functional embarrassment of these organs. The lesions produced by these parasites are essentially the same as those described in the literature,^{20,25} from the standpoint of both incidence and pathology, except that the incidence of the Oesophagostomum infestation was higher in our cases. The etiology of pulmonary edema and hemorrhage in several monkeys was not evident.

The adrenal glands contained calcium deposits in the cortex and medulla identical with those adequately described by Ross.²⁶ As indicated in that study, these deposits are bland and give no index as to their etiology.

LITERATURE CITED

1. Saphir, O. "Myocarditis. A general review with an analysis of two hundred and forty cases," *A.M.A. Arch. Pathol.* 32:1000-1051, 1941; concluded in 33:88-137, 1942.
2. Woodward, T.E.; McCrumb, F.R., Jr.; Carey, T.N.; and Togo, Y. "Viral and rickettsial causes of cardiac disease, including the Coxsackie virus etiology of pericarditis and myocarditis," *Ann. Intern. Med.* 53:1130-1150, 1960.
3. Warren, J.; Smadel, J.E.; and Russ, S.B. "The family of encephalomyocarditis, Columbia-SK, M.M. and Mengo encephalomyelitis viruses," *J. Immunol.* 62:387-398, 1949.
4. Hamilton, T.R., and Syverton, J.T. "Carditis and pulmonary arteritis in monkeys," *Fed. Proc.* 10:357, 1951.
5. Lou, T.Y.; Wenner, H.A.; and Kamitsuka, B.A. "Experimental infections with Coxsackie viruses, II. Myocarditis in cynomolgus monkeys infected with B4 virus," *Arch. Ges. Virusforsch.* 10:451-464, 1960.
6. Plager, H. "The Coxsackie viruses," *Ann. N.Y. Acad. Sci.* 101:390-397, 1962.
7. Hamilton, T.R., and Syverton, J.T. "Experimental studies in cardiovascular disease, rheumatic type," *Bull. Univ. Minn. Hosp. Med. Found.* 21:173-185, 1950.
8. Vanace, P.W. "Experimental streptococcal infection in the rhesus monkey," *Ann. N.Y. Acad. Sci.* 85:910-930, 1960.
9. Strumia, M.M.; Sample, A.B.; and Hart, E.D. "An improved micro hematocrit method," *Am. J. Clin. Pathol.* 24:1016-1024, 1954.
10. Crosby, W.H.; Munn, J.I.; and Furth, F.W. "Standardizing a method for clinical hemoglobinometry," *U.S. Armed Forces Med. J.* 5:693-703, 1954.
11. Wintrobe, M.M. "Clinical Hematology," 5th ed., Philadelphia, Lea and Febiger, 1961.
12. Fawcett, J.K., and Scott, J.E. "A rapid and precise method for the determination of urea," *J. Clin. Pathol.* 13:156-159, 1960.
13. Reitman, S., and Frankel, S. "Colorimetric method for the determination of serum transaminase activity," *Am. J. Clin. Pathol.* 28:56-63, 1957.

14. Rantz, L.A., and Randall, E. "A modification of the technic for determination of the antistreptolysin titer," *Proc. Soc. Exptl. Biol. Med.* 59:22-25, 1945.
15. Cornall, A.G.; Bardawill, C.J.; and David, M.M. "Determination of serum proteins by means of the biuret reaction," *J. Biol. Chem.* 177: 751-766, 1949.
16. Instruction manual R I M-5, Model R electrophoresis system, Beckman Instruments, Inc., Spinco Division, Palo Alto, California.
17. Fremming, B.D.; Benson, R.E.; and Young, R.J. "Weights of organs in sixty-six male Macaca mulatta monkeys," *J. Appl. Physiol.* 8:155-158, 1955-1956.
18. Innes, J.R.M.; Colton, M.W.; Yevich, P.P.; and Smith, C.L. "Pulmonary acariasis as an enzootic disease caused by Paronychia sinicola in imported monkeys," *Amer. J. Pathol.* 30:813-835, 1954.
19. Krise, G.M., and Wald, N. "Normal blood picture of the Macaca mulatta monkey," *J. Appl. Physiol.* 12:482-484, 1955.
20. Krise, G.M. "Hematology of the normal monkey," *Ann. N.Y. Acad. Sci.* 85:803-810, 1960.
21. Sauer, R.M., and Fegley, H.C. "The roles of infectious and noninfectious diseases in monkey health," *Ann. N.Y. Acad. Sci.* 85:866-888, 1960.
22. Deutsch, H.F., and Goodloe, M.B. "An electrophoretic survey of various animal plasmas," *J. Biol. Chem.* 161:1-20, 1945.
23. Cope, F.W., and Polis, B.D. "Increased plasma glutamic-oxalacetic transaminase activity in monkeys due to nonspecific stress effect," *Aerospace Med.* 30:90-96, 1959.
24. Cowdry, E.V., and Scott, G.H. "Nuclear inclusions in the kidneys of Macaca rhesus monkeys," *Am. J. Pathol.* 11:659-668, 1935.
25. Habermann, R.T., and Williams, F.P., Jr. "Diseases seen at necropsy of 708 Macaca mulatta (rhesus monkeys) and Macaca philippinensis (cynomolgus monkey)," *Amer. J. Vet. Res.* 18:419-426, 1957.
26. Ross, M.A.; Gainer, J.H.; and Innes, J.R.M. "Dystrophic calcification in the adrenal glands of monkeys, cats and dogs," *A.M.A. Arch. Pathol.* 60:655-662, 1955.