

**UNCLASSIFIED**

---

**AD 404 297**

*Reproduced  
by the*

**DEFENSE DOCUMENTATION CENTER**

**FOR**

**SCIENTIFIC AND TECHNICAL INFORMATION**

**CAMERON STATION, ALEXANDRIA, VIRGINIA**



---

**UNCLASSIFIED**

NOTICE: When government or other drawings, specifications or other data are used for any purpose other than in connection with a definitely related government procurement operation, the U. S. Government thereby incurs no responsibility, nor any obligation whatsoever; and the fact that the Government may have formulated, furnished, or in any way supplied the said drawings, specifications, or other data is not to be regarded by implication or otherwise as in any manner licensing the holder or any other person or corporation, or conveying any rights or permission to manufacture, use or sell any patented invention that may in any way be related thereto.

AMRL-TDR-62-99 (II)

CATALOG  
AS AC  
404297

# **CUMULATIVE AUDITORY EFFECTS RESULTING FROM MULTIPLE EXPOSURE TO INTENSE ACOUSTIC STIMULATION**

## **PART II. HISTOLOGICAL EFFECTS OF INTENSE SOUND ON THE INNER EAR**

TECHNICAL DOCUMENTARY REPORT No. AMRL-TDR-62-99 (II)

JANUARY 1963

BIOMEDICAL LABORATORY  
6570th AEROSPACE MEDICAL RESEARCH LABORATORIES  
AEROSPACE MEDICAL DIVISION  
AIR FORCE SYSTEMS COMMAND  
WRIGHT-PATTERSON AIR FORCE BASE, OHIO

Contract Monitor: Joseph R. Mundie  
Project No. 7231, Task No. 71786

(Prepared under Contract No. AF 33(616)-3637  
by  
W. P. Covell, M.D.  
School of Medicine, Washington University,  
Saint Louis, Missouri)

404 297

## NOTICES

When US Government drawings, specifications, or other data are used for any purpose other than a definitely related government procurement operation, the government thereby incurs no responsibility nor any obligation whatsoever; and the fact that the government may have formulated, furnished, or in any way supplied the said drawings, specifications, or other data is not to be regarded by implication or otherwise, as in any manner licensing the holder or any other person or corporation, or conveying any rights or permission to manufacture, use, or sell any patented invention that may in any way be related thereto.

Qualified requesters may obtain copies from ASTIA. Orders will be expedited if placed through the librarian or other person designated to request documents from ASTIA.

Do not return this copy. Retain or destroy.

Stock quantities available at Office of Technical Services, Department of Commerce, \$0.50.

### Change of Address

Organizations receiving reports via the 6570th Aerospace Medical Research Laboratories automatic mailing lists should submit the addressograph plate stamp on the report envelope or refer to the code number when corresponding about change of address.

<p>Aerospace Medical Division, 6570th Aerospace Medical Research Laboratories, Wright-Patterson AFB, Ohio Rpt. No. AMRL-TDR-62-99 (II). CUMULA- TIVE AUDITORY EFFECTS RESULTING FROM MULTIPLE EXPOSURE TO INTENSE ACOUSTIC STIMULATION. PART II. HISTO- LOGICAL EFFECTS OF INTENSE SOUND ON THE INNER EAR. Final report, Jan. 63, v + 12 pp., incl. illus., table, 5 refs.</p> <p>Unclassified report Thirty-three cats were subjected to sound ex- posures, and auditory threshold shift measure- ments are reported in Part I. The animals were subsequently sacrificed and their inner ears prepared for microscopic examination for evidence of tissue injury. The histological find- ings of injuries are reported in this report. Wide band noise at 155 db for one-half hour produced mild injuries;</p>	<p>UNCLASSIFIED</p> <ol style="list-style-type: none"> <li>1. Bioacoustics</li> <li>2. Noise</li> <li>3. Cats</li> <li>4. Histology</li> <li>5. Organ of Corti</li> </ol> <ol style="list-style-type: none"> <li>I. AFSC Project 7231; Task 71786</li> <li>II. Biomedical Labora- tory</li> <li>III. Contract AF 33(616)-3637</li> <li>IV. School of Medicine, Washington Univer- sity, Saint Louis, Missouri</li> <li>V. W. P. Covell</li> </ol> <p>UNCLASSIFIED</p>	<p>Aerospace Medical Division, 6570th Aerospace Medical Research Laboratories, Wright-Patterson AFB, Ohio Rpt. No. AMRL-TDR-62-99 (II). CUMULA- TIVE AUDITORY EFFECTS RESULTING FROM MULTIPLE EXPOSURE TO INTENSE ACOUSTIC STIMULATION. PART II. HISTO- LOGICAL EFFECTS OF INTENSE SOUND ON THE INNER EAR. Final report, Jan. 63, v + 12 pp., incl. illus., table, 5 refs.</p> <p>Unclassified report Thirty-three cats were subjected to sound ex- posures, and auditory threshold shift measure- ments are reported in Part I. The animals were subsequently sacrificed and their inner ears prepared for microscopic examination for evidence of tissue injury. The histological find- ings of injuries are reported in this report. Wide band noise at 155 db for one-half hour produced mild injuries;</p>	<p>UNCLASSIFIED</p> <ol style="list-style-type: none"> <li>1. Bioacoustics</li> <li>2. Noise</li> <li>3. Cats</li> <li>4. Histology</li> <li>5. Organ of Corti</li> </ol> <ol style="list-style-type: none"> <li>I. AFSC Project 7231; Task 71786</li> <li>II. Biomedical Labora- tory</li> <li>III. Contract AF 33(616)-3637</li> <li>IV. School of Medicine, Washington Univer- sity, Saint Louis, Missouri</li> <li>V. W. P. Covell</li> </ol> <p>UNCLASSIFIED</p>	<p>for 2-hour exposures the injuries were moderate to severe; for 8- hour exposures there were severe injuries. Post-exposure lives of these animals were 80 to 90 days. Animals sacrificed 2 to 4 hours after exposure showed essentially the same de- gree of injury with the same 2-hour exposure as above. Two hours total exposure at 115 db divided into 16 doses of 7.5 minutes each, with one hour inter-exposure intervals, resulted in slight to moderate changes. The same total energy in the same number of doses for 7.5 minutes, with an inter-exposure interval of 6 hours, produced comparatively slight injuries. While considerable variability is evident in different specimens subjected to the same ex- posure for the same length of time, there persists a general trend for consist- ency of degree of injury in each group.</p>	<p>UNCLASSIFIED</p> <ol style="list-style-type: none"> <li>VI. In ASTIA collection</li> <li>VII. Aval fr OTS: \$0. 50</li> </ol>
<p>Aerospace Medical Division, 6570th Aerospace Medical Research Laboratories, Wright-Patterson AFB, Ohio Rpt. No. AMRL-TDR-62-99 (II). CUMULA- TIVE AUDITORY EFFECTS RESULTING FROM MULTIPLE EXPOSURE TO INTENSE ACOUSTIC STIMULATION. PART II. HISTO- LOGICAL EFFECTS OF INTENSE SOUND ON THE INNER EAR. Final report, Jan. 63, v + 12 pp., incl. illus., table, 5 refs.</p> <p>Unclassified report Thirty-three cats were subjected to sound ex- posures, and auditory threshold shift measure- ments are reported in Part I. The animals were subsequently sacrificed and their inner ears prepared for microscopic examination for evidence of tissue injury. The histological find- ings of injuries are reported in this report. Wide band noise at 155 db for one-half hour produced mild injuries;</p>	<p>UNCLASSIFIED</p> <ol style="list-style-type: none"> <li>1. Bioacoustics</li> <li>2. Noise</li> <li>3. Cats</li> <li>4. Histology</li> <li>5. Organ of Corti</li> </ol> <ol style="list-style-type: none"> <li>I. AFSC Project 7231; Task 71786</li> <li>II. Biomedical Labora- tory</li> <li>III. Contract AF 33(616)-3637</li> <li>IV. School of Medicine, Washington Univer- sity, Saint Louis, Missouri</li> <li>V. W. P. Covell</li> </ol> <p>UNCLASSIFIED</p>	<p>Aerospace Medical Division, 6570th Aerospace Medical Research Laboratories, Wright-Patterson AFB, Ohio Rpt. No. AMRL-TDR-62-99 (II). CUMULA- TIVE AUDITORY EFFECTS RESULTING FROM MULTIPLE EXPOSURE TO INTENSE ACOUSTIC STIMULATION. PART II. HISTO- LOGICAL EFFECTS OF INTENSE SOUND ON THE INNER EAR. Final report, Jan. 63, v + 12 pp., incl. illus., table, 5 refs.</p> <p>Unclassified report Thirty-three cats were subjected to sound ex- posures, and auditory threshold shift measure- ments are reported in Part I. The animals were subsequently sacrificed and their inner ears prepared for microscopic examination for evidence of tissue injury. The histological find- ings of injuries are reported in this report. Wide band noise at 155 db for one-half hour produced mild injuries;</p>	<p>UNCLASSIFIED</p> <ol style="list-style-type: none"> <li>1. Bioacoustics</li> <li>2. Noise</li> <li>3. Cats</li> <li>4. Histology</li> <li>5. Organ of Corti</li> </ol> <ol style="list-style-type: none"> <li>I. AFSC Project 7231; Task 71786</li> <li>II. Biomedical Labora- tory</li> <li>III. Contract AF 33(616)-3637</li> <li>IV. School of Medicine, Washington Univer- sity, Saint Louis, Missouri</li> <li>V. W. P. Covell</li> </ol> <p>UNCLASSIFIED</p>	<p>for 2-hour exposures the injuries were moderate to severe; for 8- hour exposures there were severe injuries. Post-exposure lives of these animals were 80 to 90 days. Animals sacrificed 2 to 4 hours after exposure showed essentially the same de- gree of injury with the same 2-hour exposure as above. Two hours total exposure at 115 db divided into 16 doses of 7.5 minutes each, with one hour inter-exposure intervals, resulted in slight to moderate changes. The same total energy in the same number of doses for 7.5 minutes, with an inter-exposure interval of 6 hours, produced comparatively slight injuries. While considerable variability is evident in different specimens subjected to the same ex- posure for the same length of time, there persists a general trend for consist- ency of degree of injury in each group.</p>	<p>UNCLASSIFIED</p> <ol style="list-style-type: none"> <li>VI. In ASTIA collection</li> <li>VII. Aval fr OTS: \$0. 50</li> </ol>

## FOREWORD

This is Part II of a two-part report concerning the auditory effects produced by loud noise.

Under Contract No. AF 33(616)-3844, experimental animals were given varying quantities of noise exposure and the effects upon hearing threshold were measured. Following this subjective determination, the same animals were sacrificed and evaluation of the histological findings within the inner ears was made under Contract No. AF 33(616)-3637, "Effects of Intense Sound on Mammalian Ears," Department of Otolaryngology, School of Medicine, Washington University, Saint Louis, Missouri, Dr. Walter P. Covell, Principal Investigator. This report comprises a detailed description of the histological changes produced in the material. Correlation of subjective data and histological findings is given in Part I.

The entire program was conducted in support of Project No. 7231, "Acoustic Energy Control," Task 71786, "Biological Aspects of Vibratory and Acoustic Energy" administered by the Bioacoustics Branch of the Aerospace Medical Laboratories, Wright-Patterson Air Force Base, Ohio.

The experiments reported herein were conducted according to the "Principles of Laboratory Animal Care" established by the National Society for Medical Research.

The Aerospace Medical Laboratories have been transferred to the Aerospace Medical Division and have been renamed the 6570th Aerospace Medical Research Laboratories.

# ABSTRACT

Thirty-three cats were subjected to sound exposures, and auditory threshold shift measurements are reported in Part I. The animals were subsequently sacrificed and their inner ears prepared for microscopic examination for evidence of tissue injury. The histological findings of injuries are reported in this report.

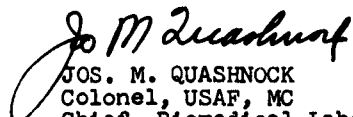
Wide band noise at 115 db for one-half hour produced mild injuries; for 2-hour exposures the injuries were moderate to severe; for 8-hour exposures there were severe injuries. Post-exposure lives of these animals were 80 to 90 days. Animals sacrificed 2 to 4 hours after exposure showed essentially the same degree of injury with the same 2-hour exposure as above.

Two hours total exposure at 115 db divided into 16 doses of 7.5 minutes each, with one hour inter-exposure intervals, resulted in slight to moderate changes. The same total energy in the same number of doses for 7.5 minutes, with an inter-exposure interval of 6 hours, produced comparatively slight injuries.

While considerable variability is evident in different specimens subjected to the same exposure for the same length of time, there persists a general trend for consistency of degree of injury in each group.

## PUBLICATION REVIEW

This technical documentary report has been reviewed and is approved.

  
JOS. M. QUASHNOCK  
Colonel, USAF, MC  
Chief, Biomedical Laboratory

# TABLE OF CONTENTS

<u>Section</u>		<u>Page</u>
I	Introduction. . . . .	1
II	Rating of Injuries. . . . .	2
III	Results . . . . .	6
IV	A Comparison of Findings. . . . .	9
	A. Duration of Exposures . . . . .	9
	B. Intermittency of Exposures. . . . .	9
	C. Prolonged Post-Exposure Life. . . . .	9
V	Summary . . . . .	11
	References. . . . .	12



# LIST OF ILLUSTRATIONS

<u>Figure</u>		<u>Page</u>
1	A Mid-Modiolar Section through a Cat's Cochlea Showing the Different Turns with the Exception of the Lower or Basal Portion of the First Turn . . . . .	3
2	Middle Part of the Second Turn of a Section through the Cochlea of a Cat Showing a Grade 3 Plus Injury. . . . .	4
3	Middle Part of the First Turn of a Section through the Cochlea of a Cat Showing a Grade 3 Plus Injury . . . . .	4
4	Lower Part of the Second Turn of a Section through the Cochlea of a Cat Showing a Grade 4 Injury. . . . .	4

# LIST OF TABLES

<u>Table</u>		<u>Page</u>
I	Grading of Injuries . . . . .	6

## SECTION I

### INTRODUCTION

An auditory sensitivity and histological study of the right ears of nine cats exposed to intense sound has been previously reported (ref. 1). The animals were monaural because the left ear of each had previously been surgically destroyed.

The methods used for exposure of the animals to sound for behavioral audiometry and the audiograms of threshold shifts are contained in Part I of this report. The histological injuries for the cochleas of the tested ears exposed to a wide band of noise at 115 db SPL for 15 minutes were rated as slight to moderate, for 30 minutes as moderate, and for 2 hours as severe. The lesions occurred usually in the upper part of the first turn and lower and middle portions of the second turn. With the prolonged exposures, they moved further into the basal and apical turns.

The present report deals with only the histological findings of injuries in the right cochleas of 33 additional cats subjected to sound exposures and for which threshold shift measurements were made. The histological methods for obtaining stained and mounted sections of the temporal bones were identical to those described for the guinea pigs (ref. 2), except the sections of the cat material were usually 18 to 20 microns in thickness.

## SECTION II

### RATING OF INJURIES

It is justifiable, particularly from results of previous studies, (refs 3 and 4) to ascribe some discrepancies in the findings to variations in susceptibility on the part of different animals' cochleas to intense sound. If this is the only reason, then a rating of histological findings and the audiogram should be in fair agreement. Unfortunately other factors may also be responsible. The experienced microscopist can be at fault in the evaluation of an injury. Hair cell and supporting cell lesions or losses are usually not difficult to judge, but when accompanied by a collapse of the tunnel of Corti, it may become difficult because cellular detail is frequently obscured.

Rupture of Reissner's membrane can occur in the same area as an organ of Corti that shows only mild injuries. Stretching, thinning, or rupture of one of the layers of Reissner's membrane may alter its permeability. Such changes are difficult to grade because we cannot be sure of how they affect the functional state of the sensory cells.

Spiral ganglion cell changes are sometimes difficult to include in an injury rating. If the post-exposure life has been sufficiently long to result in marked degenerative changes or loss of cells and peripheral nerve fibers, the problem is relatively simple. If, however, the animal was sacrificed within a few days or more after the exposure, changes may not be apparent.

Artifacts may be present in sections and can be due to a variety of errors or mishaps in the preparation of the serially sectioned and stained temporal bones. Some of the more common ones are due to poor fixation, improper embedding in celloidin, a dull microtome knife, poor staining, and so forth. Any one of these can add to the difficulty in grading the injury caused by the acoustic stimulus.

Light microscopy definitely has its limitation for use in judging the extremely fine changes. Loss of continuity in bare nerve fibers as they pass through the tunnel of Corti probably occurs with injuries, but cannot be visualized. Neither are changes in the nerve endings on the hair cells seen by the usual methods or changes in enzymes in the organ of Corti. When visible by electron microscopy or similar methods, these and other factors will undoubtedly alter our present judgment of the degree and extent of injuries and change the present grading system.

The separation of injuries into different grades can be considered, at best, only a crude estimation of effects of intense sound on the cochlea. The evaluation used is similar to that described by Davis (ref. 5) for the guinea pig except for some modifications in order to make it more applicable to the cochlea of the cat. The cochlea of the cat has two large turns and only a segment of an additional turn in contrast to the guinea pig's cochlea that has four turns. Figure 1 is a mid-modiolar section through a cat's cochlea showing the various turns. The lower and most basal portion of the first turn is not present in this section.

The following is a description of the different grades of injuries:

Grade 1. No discernible changes.

Grade 1 plus. Slight changes in supporting cells such as Deiter's and internal phalangeal. These are usually found to be cytoplasmic vacuoles or just distinguishable swelling.

- Grade 2. Mild to moderate changes become apparent in the supporting cells. The nuclei may be enlarged and stain poorly or be slightly shrunken and the cytoplasmic changes more pronounced.
- Grade 2 plus. Moderate to severe changes in supporting cells without appreciable injury to external hair cells. The internal hair cell may be somewhat altered and the internal phalangeal markedly swollen. A partial collapse of one of the tunnel rods is sometimes present.
- Grade 3. In addition to the changes listed above, (Grade 2 plus) external hair cell injury of slight degree is apparent. This consists usually of a difference in cytoplasmic changes, but a deeply stained and shrunken nucleus or enlarged and poorly stained nucleus may be present.
- Grade 3 plus. (See Figures 2 and 3.) Nuclear and cytoplasmic changes in Deiter's cells become marked and occasionally they are loosened from the basilar membrane. External hair cell changes are apparent to a moderate degree although the organ of Corti and its reticular lamina are not ruptured. The tunnel of Corti may be almost completely collapsed.
- Grade 4. (See Figure 4.) Supporting cells may show moderate to marked changes. External hair cells are extremely altered in an otherwise intact organ of Corti; an occasional one may be missing. The reticular lamina may show a point of rupture.
- Grade 4 plus. This grade of injury is the greatest that can occur without complete rupture and loss of the organ of Corti from the basilar membrane.
- Grade 5. The external hair cells and Deiters cells have been lifted from the basilar membrane. Sometimes the internal hair cell and internal tunnel rod remain in a relatively unaltered state as may also external and internal sulcus cells. This grade of injury also includes the complete loss of the organ of Corti from the basilar membrane.

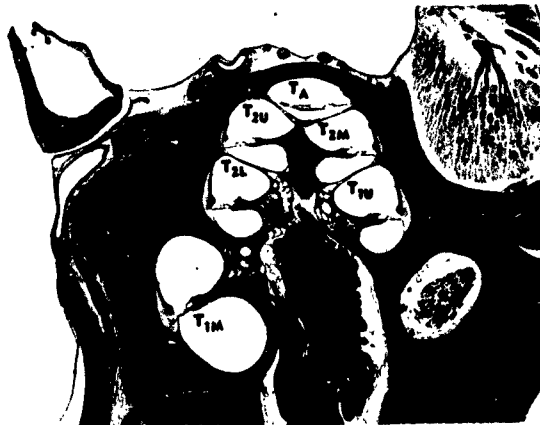

Figure 1. A mid-modiolar section through a cat's cochlea showing the different turns with the exception of the lower or basal portion of the first turn. T<sub>1m</sub>, middle of first turn; T<sub>1u</sub>, upper part of first turn; T<sub>2L</sub>, T<sub>2m</sub>, T<sub>2u</sub>, lower, middle, and upper parts of second turn; T<sub>a</sub>, part of the small apical turn. X 12.



Figure 2. Middle part of the second turn of a section through the cochlea of a cat showing a Grade 3 Plus injury. The tunnel of Corti is completely collapsed and filled with cellular debris. The external and internal hair cells and supporting cells are markedly distorted with moderate changes. There is a loss of some mesothelial cells and degenerative limbic changes. X 90.

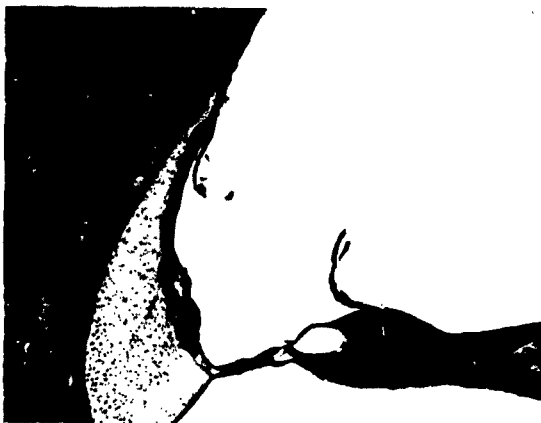

Figure 3. Middle part of the first turn of a section through the cochlea of a cat showing a Grade 3 Plus injury. Reissner's membrane is ruptured. The tunnel of Corti somewhat collapsed. Injury to the hair cells (not apparent at this magnification) could only be considered as moderate although the supporting cell changes were more severe. X 90.



Figure 4. Lower part of the second turn of a section through the cochlea of a cat showing a Grade 4 injury. The external tunnel rod has been fractured. The reticular ruptured and external hair cells and supporting cells markedly altered. The internal hair and supporting cells show less marked changes. There is some loss of mesothelial cells. X 140.

Purposely omitted from any of the grades of injury are such findings as rupture of Reissner's membrane, degeneration of limbic connective tissue, loss of mesothelial cells, and spiral ganglion cell changes. Such findings are more common in Grades 4 through 5 but occasionally may appear in grades representing less pronounced degrees of injury to the organ of Corti. They seem to be less reliable as criteria for judging the amount of injury.

## SECTION III

## RESULTS

TABLE I  
GRADING OF INJURIES

Group	Cat No.	Turn I			Turn II			Turn II Apical
		Low	Middle	Upper	Low	Middle	Upper	
I	109	1	1+	2	2	2+	2	1+
	110	1+	2	2+	2+	2	2	2
	114	1+	2	2	2	2+	2	1+
IIA	54	3+	2	2+	3	2	1+	1+
	64	4	3	3+	4	3+	3	2+
	71	2	3+	4+	4	3	2+	1+
	80	1+	2	3	2	2	1+	1+
	60	4+	4	4+	2+	2	1+	1+
	63	4+	4	3+	4	4	2+	2
	76	1+	2	4	4+	3	2	2
	78	1+	1+	2	3	3+	2	1+
IIB	A(R)	1+	2	2+	3	2	1+	1+
	A(L)	1+	2	2+	3	2+	2	2
	D(R)	2	3+	3	3+	2+	2+	2
	D(L)	1+	2	2	3	2	1+	1+
	E(R)	1+	2	2+	3+	2	1+	1
	E(L)	1+	2	2+	3+	3	2	2
	F(R)	1+	1+	2	3	2+	2	1+
	F(L)	3	5	4	3	2	2	1+
	G(L)	2	4	4	3+	3+	2+	2
III	G(R)	1+	4	3+	3+	3	2+	2
	86	5	4	4+	5	4	3	3
	90	5	5	4+	4	3+	3	2
	92	5	4	4+	3+	2+	2	1+
	107	3	3+	4	4	3	3	2+
	102	1+	3	3+	4	3+	2+	2
IV	112	1+	2+	3	4	3+	3	2
	39	2	3	3+	4	4	2+	2
	50	1+	2	3	3+	3	2+	1+
	69	1	1+	2	2+	2	1+	1+
	72	1	1+	2	3	2	2	1+

Table I (Continued)

V	52	1+	2	2+	2	2	2	1+
	56	1+	1+	2	2+	2+	2	2
	62	1	1+	1+	2+	2+	2	1+
	74	1	1+	2	1+	1	1+	1
VI	61	1	1	1+	2	1+	1	1
	70	1	1	1+	2	2	2	1
	79	1	1+	2	2+	2+	1+	1+
	99	1	1+	2	2+	2+	2	1+
VII	53	1	1+	2	3+	2+	1+	1+
	59	1	1	1	1+	1+	1	1
	98	1	1+	2	3	2	1+	1+
	75	1	1	1+	2	2+	1+	1+

EXPLANATION OF TABLE I

Group I Cats 109, 110, 114.

Exposure: A wide band of noise at 115 db for one-half hour.

Results: Mild injury particularly to supporting cells with some evidence of slight encroachment of injury upon external hair cells in upper part of the first turn and throughout the second turn.

Group II A Cats 54, 64, 71, 80, 60, 63, 76, 78.

Exposure: A wide band of noise at 115 db for 2 hours.

Results: Injuries in lower part of the first turn for four specimens show loss and degeneration of external and internal hair cells and supporting cells with collapse of the tunnel of Corti. The similar areas in four other specimens reveal slight to moderate changes, such as swelling of supporting, with or without some deformation, of external hair cells. In the upper part of the first turn and into the middle of the second turn, the damage is in fair agreement for most specimens.

Group II B Cats A, D, E, F, G.

Exposure: A wide band of noise at 115 db for 2 hours. Animals sacrificed within 2 to 4 hours following exposure. Both ears were exposed.

Results: Only relatively mild changes are usually present in the lower part of the first turn, such as slight swelling of supporting cells. These changes become somewhat greater in the middle and upper part of the first turn and for three specimens severe injuries are present in this location. Definite hair cell and cell injuries of moderate degree are in evidence in the lower part of the second turn for all specimens. These become less in the middle and upper part of the second turn.



- Group III      Cats 86, 90, 92, 102, 107, 112.
- Exposure: A wide band of noise at 115 db for 8 hours.
- Results: In three cochleas the organ of Corti was lifted from the basilar membrane in the lower part of the first turn. In one, there was moderate injury, and in two, there were slight changes at the same location. For all specimens, the damage became more severe or maintained its severity into the middle of the second turn. For the remainder of the apical turn, the injuries were moderate to slight.
- Group IV      Cats 39, 50, 69, 72.
- Exposure: Same total energy doses as Groups II A and II B in 16 doses, 7.5 minutes each (or 2 hours total) with 1 hour inter-exposure interval.
- Results: The extreme ends of the basal and apical turns reveal only slight or mild injuries such as supporting cell changes. In the upper part of the first turn and into the middle of the second turn, there is considerable variation in degree of injury for the different specimens. It ranges from supporting cell changes to marked organ of Corti damage for one specimen.
- Group V      Cats 52, 56, 62, 74.
- Exposure: Same total energy doses as Groups II A and II B in 16 doses, 7.5 minutes each (or 2 hours total) with 6 hours inter-exposure interval.
- Results: The injuries for all specimens are slight or relatively mild. There is a tendency for the greatest degree of injury to occur in the upper part of the first turn and lower and middle parts of the second turn. It is primarily supporting cell changes with some evidence of slightly altered hair cells.
- Group VI      Cats 61, 70, 79, 99.
- Exposure: A narrow band of low frequency noise at 105 db for 8 hours.
- Results: Very mild injuries are present chiefly in the upper part of the first turn and throughout the second turn for each specimen. These are primarily supporting cell changes with slight, if any, hair cell damage. As a group, the findings are fairly consistent.
- Group VII      Cats 53, 59, 75, 98.
- Exposure: A narrow band of low frequency noise at 105 db for 48 hours.
- Results: Moderate external hair and supporting cell injury is present for two specimens in the lower part of the second turn with only mild changes in nearby areas. One specimen is practically within normal limits while the remainder shows slight injuries in the lower and middle parts of the second turn.

## SECTION IV

### A COMPARISON OF FINDINGS

The histological findings for different animals of the same group sometimes show considerable differences. Table I shows the location of injuries along the basilar membrane and indication of their usual localization is present. The upper part of Turn I and into the middle of Turn II are the areas of the cochlea most susceptible to injury by these exposures. The lower part of the first turn is also injured by some of the exposures at 115 db with duration of 2 to 8 hours, respectively. This is also true of the more apical turns for the same exposures, but to a lesser degree.

The results of exposures to wide band noise for the different groups are compared on the basis of duration, intermittent with continuous exposures, and post-exposure lives of 80 to 90 days with those of 2 to 4 hours. The results of a narrow band of low frequency noise exposures at 105 db are compared on the basis of 8-hour and 48-hour exposures.

#### A. Duration of Exposures

The exposures to a wide band of noise at 115 db for one-half hour (Group I), 2 hours (Group IIA), and 8 hours (Group III) increased the amount of injury with increase in length of time. The differences are probably greatest between the one-half hour and the 2 hour-exposures, although the 8-hour exposures continued to become even more severe and extensive. Masked injury occurred in the lower part of the basal turn with some 2 and 8 hour-exposures but was not apparent with one-half hour only. The lesions extended along the basilar membrane into the apical turn, but severity of injury was considerably diminished at this point, particularly for most prolonged exposures.

The findings for the exposures to a narrow band of low frequency noise for 8 hours (Group VI), respectively, showed only a slight increment with increase in duration. This was not apparent in two of the Group VII animals.

#### B. Intermittency of Exposures

The results of Group IV and Group V are compared. The exposures -- wide band noise at 115 db, 7.5 minutes duration, repeated for 16 times (total of 2 hours) -- differed only in inter-exposure interval which was one hour in Group IV and 6 hours in Group V. A greater degree of injury is apparent in most of Group IV specimens that showed slight to moderate changes when compared to the Group V changes that were mild in degree.

The repeated exposures of 7.5 minutes each for 16 times were of the same total energy as the continuous exposures of Group II A. If Groups IV and V are compared with Group II A, it is evident that a continuous exposure of 2 hours duration is usually more detrimental than an intermittent hourly exposure for a total time of 2 hours and certainly more than one of 6 hours interval.

#### C. Prolonged Post-Exposure Life

All of the cats except those of Group II B, which were sacrificed within 2 to 4 hours after exposures to intense sound, were allowed to survive for 80 to 90 days. If the results of Group II B are compared with those of Groups I, II A, and III, it is evident that II B findings are more severe than the one-half hour exposures (Group I). A comparison with Group II A findings shows about the same variability for different specimens in each group except some injuries in Group IIB

are somewhat more severe. On the other hand, it is possible that some of the injuries for some animals in Group II B would be rated as more -- if the exposure lives had been prolonged. The reverse is also true because the mildly injured areas of Group II B findings may show some recovery after a period of time. With few exceptions, the findings for Group III exposures exceed in severity those of Group II B. This is probably less closely related to the length of the post-exposure life than to the difference in exposure time of 6 hours between the two groups.

## SECTION V

### SUMMARY

1. A wide band of noise at 115 db for one-half hour produced mild injuries in the cats' cochlea; for 2-hour exposures the injuries were moderate to severe; for 8-hour exposures there were severe injuries. The post-exposure lives for these animals were 80 to 90 days.
2. The same band of noise at 115 db for 2 hours in animals sacrificed after 2 to 4 hours showed for most of the specimens moderate to severe injuries. There was a tendency for only a few changes in the lower part of the first turn which was more marked in some with 80 to 90 days post-exposure life.
3. Inter-exposure intervals of one hour of the same noise at 115 db in 16 doses for 7.5 minutes each (2 hours total) resulted in slight to moderate changes with marked or severe injuries for one specimen. The same total energy in the same number of doses for 7.5 minutes with an inter-exposure interval of 6 hours produced comparatively slight injuries.
4. A narrow band of low frequency noise at 105 db for 8 hours resulted in slight injuries. The same noise for 48 hours produced changes which were moderate in degree for some specimens and of a slight degree for one specimen.
5. While considerable variability is evident in different specimens subjected to the same exposure for the same length of time, there persists a general trend for consistency of degree of injury in each group.

#### REFERENCES

1. Miller, J. D., C. S. Watson, C. D. Anderson and W. P. Covell, "Temporary and Persistent Threshold Shifts for the Cat," J. Acoust. Soc. Am., Abstr. G5, Vol 31, p 1574, 1959.
2. Covell, W. P. and D. H. Eldredge, Injury to Animal's Ears by Intense Sound, Air Force Technical Report 6561, Part 1, Air Materiel Command, Wright-Patterson Air Force Base, Dayton, Ohio, July 1951.
3. Eldredge, D. H. and W. P. Covell, Injury to Animal's Ears by Intense Sound, Air Force Technical Report 6561, Part 2, Air Materiel Command, Wright-Patterson Air Force Base, Ohio, August 1952.
4. Smith, C. S., W. P. Covell and D. H. Eldredge, The Effects of Intense Sound on the Cochlea, WADC Technical Report 54-21, Wright Air Development Center, Wright-Patterson Air Force Base, Ohio, June 1954.
5. Davis, H., Acoustic Trauma in the Guinea Pig, WADC Technical Report 53-58, Wright Air Development Center, Wright-Patterson Air Force Base, Ohio, March 1953.

<p>Aerospace Medical Division, 6570th Aerospace Medical Research Laboratories, Wright-Patterson AFB, Ohio Rpt. No. AMRL-TDR-62-99 (II). CUMULA- TIVE AUDITORY EFFECTS RESULTING FROM MULTIPLE EXPOSURE TO INTENSE ACOUSTIC STIMULATION. PART II. HISTO- LOGICAL EFFECTS OF INTENSE SOUND ON THE INNER EAR. Final report, Jan. 63, v + 12 pp., incl. illus., table, 5 refs.</p> <p>Unclassified report Thirty-three cats were subjected to sound ex- posures, and auditory threshold shift measure- ments are reported in Part I. The animals were subsequently sacrificed and their inner ears prepared for microscopic examination for evidence of tissue injury. The histological find- ings of injuries are reported in this report. Wide band noise at 155 db for one-half hour produced mild injuries;</p>	<p>UNCLASSIFIED</p> <ol style="list-style-type: none"> <li>1. Biocoustics</li> <li>2. Noise</li> <li>3. Cats</li> <li>4. Histology</li> <li>5. Organ of Corti</li> <li>I. AFSC Project 7231; Task 71786</li> <li>II. Biomedical Labora- tory</li> <li>III. Contract AF 33(616)-3637</li> <li>IV. School of Medicine, Washington Univer- sity, Saint Louis, Missouri</li> <li>V. W. P. Covell</li> </ol> <p>UNCLASSIFIED</p>	<p>Aerospace Medical Division, 6570th Aerospace Medical Research Laboratories, Wright-Patterson AFB, Ohio Rpt. No. AMRL-TDR-62-99 (II). CUMULA- TIVE AUDITORY EFFECTS RESULTING FROM MULTIPLE EXPOSURE TO INTENSE ACOUSTIC STIMULATION. PART II. HISTO- LOGICAL EFFECTS OF INTENSE SOUND ON THE INNER EAR. Final report, Jan. 63, v + 12 pp., incl. illus., table, 5 refs.</p> <p>Unclassified report Thirty-three cats were subjected to sound ex- posures, and auditory threshold shift measure- ments are reported in Part I. The animals were subsequently sacrificed and their inner ears prepared for microscopic examination for evidence of tissue injury. The histological find- ings of injuries are reported in this report. Wide band noise at 155 db for one-half hour produced mild injuries;</p>	<p>UNCLASSIFIED</p> <ol style="list-style-type: none"> <li>1. Biocoustics</li> <li>2. Noise</li> <li>3. Cats</li> <li>4. Histology</li> <li>5. Organ of Corti</li> <li>I. AFSC Project 7231; Task 71786</li> <li>II. Biomedical Labora- tory</li> <li>III. Contract AF 33(616)-3637</li> <li>IV. School of Medicine, Washington Univer- sity, Saint Louis, Missouri</li> <li>V. W. P. Covell</li> </ol> <p>UNCLASSIFIED</p>
<p>for 2-hour exposures the injuries were moderate to severe; for 8- hour exposures there were severe injuries. Post-exposure lives of these animals were 80 to 90 days. Animals sacrificed 2 to 4 hours after exposure showed essentially the same de- gree of injury with the same 2-hour exposure as above. Two hours total exposure at 115 db divided into 16 doses of 7.5 minutes each, with one hour inter-exposure intervals, resulted in slight to moderate changes. The same total energy in the same number of doses for 7.5 minutes, with an inter-exposure interval of 6 hours, produced comparatively slight injuries. While considerable variability is evident in different specimens subjected to the same ex- posure for the same length of time, there persists a general trend for consist- ency of degree of injury in each group.</p>	<p>UNCLASSIFIED</p> <ol style="list-style-type: none"> <li>VI. In ASTIA collection</li> <li>VII. Aval fr OTS: \$0.50</li> </ol>	<p>for 2-hour exposures the injuries were moderate to severe; for 8- hour exposures there were severe injuries. Post-exposure lives of these animals were 80 to 90 days. Animals sacrificed 2 to 4 hours after exposure showed essentially the same de- gree of injury with the same 2-hour exposure as above. Two hours total exposure at 115 db divided into 16 doses of 7.5 minutes each, with one hour inter-exposure intervals, resulted in slight to moderate changes. The same total energy in the same number of doses for 7.5 minutes, with an inter-exposure interval of 6 hours, produced comparatively slight injuries. While considerable variability is evident in different specimens subjected to the same ex- posure for the same length of time, there persists a general trend for consist- ency of degree of injury in each group.</p>	<p>UNCLASSIFIED</p> <ol style="list-style-type: none"> <li>VI. In ASTIA collection</li> <li>VII. Aval fr OTS: \$0.50</li> </ol>