REPORT DOCUMENTATION PAGE

Form Approved
OMB No. 0704-0188

The public reporting burden for this collection of information is estimated to average 1 hour per response, including the time for reviewing instructions, searching existing data sources, gathering and maintaining the data needed, and completing and reviewing the collection of information. Send comments regarding this burden estimate or any other aspect of this collection of information, including suggestions for reducing the burden, to the Department of Defense, Executive Service Directorate (0704-0188). Respondents should be aware that notwithstanding any other provision of law, no person shall be subject to any penalty for failing to comply with a collection of information if it does not display a currently valid OMB control number

PLEASE DO NOT RETURN YOUR FORM TO THE ABOVE ORGANIZATION.

1. REPORT DATE *(DD-MM-YYYY)*	2. REPORT TYPE	3. DATES COVERED *(From - To)*
28-04-2011	Technical report	June 2009 - December 2010

4. TITLE AND SUBTITLE
Trauma Infectious Disease Outcomes Study (TIDOS) Invasive Fungal Infection (IFI) Case Investigation

5a. CONTRACT NUMBER

5b. GRANT NUMBER
Inter-agency Agreement Y1-AI-5072

5c. PROGRAM ELEMENT NUMBER

6. AUTHOR(S)
David Tribble, MD, DrPH

5d. PROJECT NUMBER

5e. TASK NUMBER

5f. WORK UNIT NUMBER

7. PERFORMING ORGANIZATION NAME(S) AND ADDRESS(ES)
Infectious Disease Clinical Research Program,
Department of Preventive Medicine and Biostatistics,
Uniformed University of the Health Sciences,
4301 Jones Bridge Road, Bethesda, MD 20184

8. PERFORMING ORGANIZATION REPORT NUMBER

9. SPONSORING/MONITORING AGENCY NAME(S) AND ADDRESS(ES)
Uniformed University of the Health Sciences,
4301 Jones Bridge Road, Bethesda, MD 20184

10. SPONSOR/MONITOR'S ACRONYM(S)
USU

11. SPONSOR/MONITOR'S REPORT NUMBER(S)

12. DISTRIBUTION/AVAILABILITY STATEMENT
Approved for public release; distribution unlimited

13. SUPPLEMENTARY NOTES
Funding was also received from the Navy Bureau of Medicine & Surgery - Wounded, Ill, and Injured Program

14. ABSTRACT
Beginning in 2009, military physicians noted increasing frequency of casualties from Operation Enduring Freedom diagnosed with the unexpected complication of invasive fungal wound infections (IFI). The Infectious Disease Clinical Research Program at USU studied these cases through TIDOS in conjunction with orthopedic, trauma, and infectious disease services. Findings include a total of 36 cases meeting criteria for proven, probable, or possible infection, with a high of 3.2% of trauma admissions in the fourth quarter of 2010 (progressive rate increase by the number of Landstuhl ICU admission, reaching a peak rate of 8.0% in the 4th quarter of 2010). The majority had suffered blast wounds while on dismounted patrol in Helmand and Kandahar provinces, Afghanistan. Lower extremity amputation occurred in 78% of cases. Patients received massive amounts of blood products. Four patients (11%) died. Recommendations include: 1) heightened index of suspicion based on finding of extensive necrosis on serial debridement and risk factors; 2) early aggressive tissue sampling; 3) aggressive surgical debridement; 4) empiric antifungal therapy if strong suspicion for IFI, discontinue if histopath exam negative; 5) early ID consultation; & 6) coordinate with surgical pathology / clinical microbiology.

15. SUBJECT TERMS
combat trauma, invasive fungal wound infections, TIDOS, trauma-related infections, battlefield infections

16. SECURITY CLASSIFICATION OF:			17. LIMITATION OF ABSTRACT	18. NUMBER OF PAGES	19a. NAME OF RESPONSIBLE PERSON
a. REPORT	b. ABSTRACT	c. THIS PAGE			David Tribble
unclassified	unclassified	unclassified	SAR	56	19b. TELEPHONE NUMBER *(Include area code)* 301-816-8404

TECHNICAL REPORT

Trauma Infectious Disease Outcomes Study (TIDOS)

Invasive Fungal Infection (IFI) Case Investigation

Other requests for this document shall be referred to the Director, Infectious Disease Clinical Research Program (IDCRP), Uniformed Services University of the Health Sciences

Distribution list:

Commanders, Landstuhl Regional Medical Center (LRMC), National Naval Medical Center (NNMC), Walter Reed Army Medical Center (WRAMC), and Brooke Army Medical Center (BAMC)
Director, Joint Theater Trauma System, U.S. Army Institute of Surgical Research
President, Uniformed Services University of the Health Sciences (USU)
U.S. Navy Bureau of Medicine & Surgery - BUMED M3/5 Public Health (POC: CAPT Beltra)
U.S. Navy BUMED - Wounded, Ill, and Injured Program (POC: Dr. Don O'Connor)
Preventive Medicine Officer, Headquarters, U.S. Marine Corps (HS)
Surgeons General Specialty Consultants in Surgery, Orthopedics, Infectious Diseases, Preventive Medicine
Steering Committee, Infectious Disease Clinical Research Program
Director, Military Infectious Diseases Research Program, U.S. Army Materiel Research Management Command
Director, Armed Forces Health Surveillance Center
Commander, Navy Marine Corps Public Health Center
Director, Infectious Disease Clinical Research Program (IDCRP), USU
Site Investigative Teams, Trauma Infectious Disease Outcomes Study

IDCRP
Uniformed Services University

POC David Tribble, M.D., Dr.P.H.
Coordinating Principal Investigator, Trauma Infectious Disease Outcomes Study (TIDOS)
Infectious Disease Clinical Research Program (IDCRP)
Uniformed Services University of the Health Sciences
(301) 816-8404 david.tribble@usuhs.edu

Trauma Infectious Disease Outcome Study (TIDOS)

Invasive Fungal Infection (IFI) Case Investigation

SUMMARY FINDINGS AND RECOMMENDATIONS

Investigation Dates

February-April, 2011 (inclusive period considered - June 2009 to Dec 2010)

Purposes

1. Describe a recent rate increase in invasive fungal infections (IFI) among military personnel hospitalized with combat-related traumatic injury
2. Describe the clinical, microbiological and histopathological characteristics of IFI cases
3. Review IFI-specific surgical and medical management and describe observed outcomes
4. Provide recommendations to inform clinical practice

Investigation Methods

Recognition by clinicians of unusual and unexpected cases of IFI in severely wounded patients from Operation Enduring Freedom, led to the need to systematically assess and understand the frequency and consequences of these infections. The IFI case series was investigated under the auspices of the Department of Defense (DoD)-Veterans Administration (VA) Trauma Infectious Disease Outcomes Study (TIDOS), an observational, longitudinal cohort of infectious disease outcomes following deployment-related traumatic injury in active duty personnel or DoD beneficiaries. Potential IFI cases were identified by reviewing microbiologic data (i.e., positive fungal cultures), histopathological reports, and screening electronic medical records for antifungal prescriptions. Supplemental data was collected through review of surgical notes and pathologist slide review from all cases.

Cases were classified according to the following criteria:

Proven	Traumatic wound plus histopathological evidence of fungal angioinvasion in wound tissue, regardless of culture confirmation
Probable	Traumatic wound with evidence of infected tissue, such as necrosis found on at least two consecutive surgical debridements, plus histopathological evidence of fungi in necrotic tissue without observed angioinvasion (culture confirmation not required)
Possible	Traumatic wound with evidence of infected tissue, such as necrosis found on at least two consecutive surgical debridements, plus potentially pathogenic filamentous fungi recovered from culture but no histological examination obtained (or histological examination negative)

Main Findings

From June 1, 2009 through December 31, 2010, a total of 36 cases of IFI (19 proven, 4 probable, and 13 possible) were identified. All of the cases occurred among Operation Enduring Freedom (OEF) personnel who had suffered blast injuries in Afghanistan (92% of these occurring while dismounted). Of these, 94% received their initial care at a medical facility in the southern provinces of Helmand or Kandahar. IFI rates among OEF personnel medically evacuated to Landstuhl Regional Medical Center (LRMC) have steadily increased during each successive quarter in 2010, to a high of 3.2% in the fourth quarter. The progressive rate increase is also demonstrated when assessing the IFI cases by the number of trauma patient admissions to the LRMC ICU reaching a peak rate of 8.0% in the fourth quarter of 2010. Lower extremity amputations occurred in 78% of IFI cases. Upon admission to LRMC the median injury severity score (ISS) was 20 [interquartile range (IQR):15.5, 24.5] and the median Sequential Organ Failure Assessment (SOFA) score was 7.5 (IQR: 5, 10). The median duration of hospitalization at continental United States (CONUS) medical treatment facilities (MTFs) was 60 days (IQR: 38, 74). Patients received a median of 90.5 total units of blood products (49 units of PRBCs) overall. Of this total transfusion requirement, a median of 29 units of PRBCs (IQR: 17, 37) and 27 units of fresh frozen plasma (IQR: 14.5, 35) were given in theater (levels II and III MTFs).

Among the 36 patients, a total of 53 wounds met criteria for IFI diagnosis. Of these, 41 had tissue sent for histopathology, of which 34 (82.9%) had fungal elements and 26 (63.4%) had angioinvasion. Regarding mycology, 30 patients had 1 or more cultures positive for mold. In 16 patients, a mold from the order Mucorales (9 *Mucor* spp., 6 *Saksenaea vasiformis*, and 2 *Apophysomyces* spp.) was identified. In addition, 6 patients who did not have a documented culture positive for Mucorales mold were noted to have aseptate hyphae consistent with a Mucorales mold on histopathology. Pathogens from the order Mucorales were isolated from 62.5%, 100%, and 38.5% of proven, probable and possible cases, respectively. There were 16 patients with mold identified as *Aspergillus* spp. and nine with *Fusarium* spp. While the majority of patients with proven IFI had positive cultures that grew a Mucorales mold, several with proven infection (angioinvasion) grew other molds only, such as *Aspergillus* spp., so these non-Mucorales filamentous fungi should also be considered IFI causative pathogens. All 53 wounds were also either colonized or infected with a bacterium or yeast by the date of IFI diagnosis, with the most commonly identified organisms being *Enterococcus faecium* (n=10, 18.9%), *Acinetobacter calcoaceticus baumannii* complex (n=9, 17%), and *Escherichia coli* (n=7, 13.2%).

All of the cases required surgical debridement and the majority (n=32, 88.9%) received antifungal agents. Of the 32 patients who received antifungal therapy, 26 (81.3%) received liposomal amphotericin B, and 23 (71.9%) received voriconazole. Combination antifungal regimens were frequently employed, as 13 (40.6%) received liposomal amphotericin B plus a triazole (voriconazole or posaconazole), and 8 (25%) received triple therapy of liposomal amphotericin B, a triazole, and caspofungin. Twelve patients (33.3%) also received topical disinfectant therapy with 0.025% sodium hypochlorite (modified Dakin's solution). The median

number of surgical debridements was 11 (IQR: 7, 16). Twenty-five percent of patients ultimately required an amputation at the level of total hip disarticulation or hemipelvectomy. Four (11%) patients died with 1 death unrelated to IFI diagnosis.

In summary, invasive fungal infections are an increasingly important cause of morbidity and mortality among US military personnel who suffer combat-related traumatic injury. Of the cases in this report, most suffered blast injuries on dismounted patrol in southern Afghanistan. Traumatic lower extremity amputation and massive blood transfusions are typical features noted in these patients. Based on the observed time course, our analysis suggests that IFI results from environmental contamination of large (usually extremity) wounds and occurs despite multiple irrigation and debridements to remove organic debris and non-viable tissue. Diagnosis and clinical management of IFI is complex and requires extensive surgical debridement of infected tissue and systemic antifungal therapy.

Recommendations

1. Recognition of potential risk factors and common clinical findings is critical and should be incorporated into predeployment training. Potential risk factors include dismounted blast injury leading to extensive lower extremity traumatic amputations with associated perineal injury frequently requiring massive blood transfusion (often 2-3 times the commonly used definition of $\geq$ 10 units in the first 24 hours). The majority of these cases have occurred following injury in the Helmand or Kandahar provinces in southern Afghanistan. Ongoing surveillance is needed to determine if regional location is an independent risk factor distinct from mechanism of injury and subsequent wounding pattern. Of particular importance is awareness of what constitutes a suspicious wound. The finding of extensive necrosis on serial debridements should prompt early diagnosis and prompt initiation of therapy. In addition, clinicians should also recognize that the median time from injury to diagnosis is 10 days (IQR: 7, 14).

2. In a patient with the above potential risk factors, clinical features suggestive of IFI suspicious wounds, and appropriate time interval after injury, effort should be made to establish the diagnosis as early as possible. Tissue from surgical debridement of wounds should be sent for histopathology and culture when the diagnosis is considered. Once IFI has been diagnosed in a patient, repeated thorough and aggressive surgical debridement is essential.

3. To ensure appropriate handling of clinical specimens and timely diagnosis, early coordination with infectious disease specialists, surgical pathology and clinical microbiology laboratory staff is encouraged.

4. Aggressive surgical debridement of affected tissue is the primary therapy. Empiric antifungal therapy should also be considered when there is strong suspicion for IFI. Both liposomal amphotericin B and voriconazole should be used initially since many of the cases involve not only Mucorales species, but also *Aspergillus* or *Fusarium* species. There is no

clear role identified in the literature for dual or triple systemic antifungal therapy, so therapy should be tailored to the agent or agents deemed most effective based upon laboratory results (optimally a combination of clinical mycology and fungal morphology available through histopathological examination). Furthermore, there is no guidance in the literature on duration of therapy and no evidence for prolonged courses as most of these cases are soft tissue infections albeit extensive and aggressive. In patients in whom empiric antifungal therapy is initiated based on a strong suspicion of IFI and careful consideration of the risks of antifungal therapy, empiric therapy should be stopped as soon as possible if the suspicion of IFI is no longer being considered. The absence of fungal invasion on histopathology (particularly from serial specimens) is adequate to rule out an IFI diagnosis in low risk wounds and discontinue antifungal therapy in order to limit drug-related toxicity. It is not necessary or advisable to await negative culture results since this can be quite delayed and commonly Mucorales molds have a low isolation recovery. Close clinical monitoring and judgment of experienced clinicians are helpful in this determination.

5. In addition to systemic therapy, topical antimicrobial or disinfectant therapy can be considered; although evidence to support treatment efficacy is lacking. Modified Dakin's solution, 0.025% sodium hypochlorite, instilled through a wound vacuum device, has been an adjunctive therapy used at some U.S. military hospitals. While anecdotally felt to be effective, no difference in outcome was observed in this series when comparing cases who received modified Dakin's solution versus those that did not.

6. Prospective collection of clinical data in trauma patients with high above the knee amputations through the DoD-VA Trauma Infectious Diseases Outcomes Study (TIDOS) should be undertaken to provide ongoing active case surveillance, investigate risk factors, and provide interval assessments to measure impact of clinical practice guidelines.

7. Future strategies for IFI prevention, diagnosis, and treatment should include the refinement of existing clinical practice guidance and effective dissemination among provider communities most likely to care for patients with IFI. Preclinical studies should be pursued to investigate efficacy of preventive and/or therapeutic antifungal regimens on both local and systemic levels. Comparative studies of histopathological techniques should be undertaken to evaluate potentially more rapid and sensitive diagnostic methods. Prospective interventional studies should be considered to investigate the role of antifungal prophylaxis and adjunctive topical therapy with modified Dakin's solution.

Trauma Infectious Disease Outcome Study (TIDOS)

Invasive Fungal Infection (IFI) Case Investigation

Table of Contents

SUMMARY FINDINGS AND RECOMMENDATIONS 2

Investigation Dates 2

Purposes 2

Investigation Methods 2

Main Findings 3

Recommendations 4

CASE INVESTIGATION OBJECTIVES 9

BACKGROUND 9

Study Population 10

Study Design 11

Case Definitions 11

Case Identification 12

FINDINGS 13

Scope of the Problem. 13

Injury pattern and wound description 14

Clinical findings 14

Blood product requirements 15

Selected case histories 15

Characteristics of infected wounds 17

Antimicrobial agents 19

DISCUSSION AND RECOMMENDATIONS 20

Identification of risk factors 21

Diagnosis 23

Management 24

Areas for future research 26

Overview of the Trauma Infectious Disease Outcomes Study (TIDOS) 28

TIDOS Investigative Team 29

Appendix: Figures and Tables 30

Figure 1. Relative proportion of patients diagnosed with invasive fungal wound infections based on the dates of admission to Landstuhl Regional Medical Center (LRMC), June 2009 – December 2010 31

Figure 2. Comparison of selected injury and clinical findings at admission to Landstuhl Regional Medical Center (LRMC) between patients diagnosed with invasive fungal wound infections and patients admitted overall or to the ICU at LRMC, June-November 2009 32

Table 1. Demographic characteristics and circumstances related to injury among patients diagnosed with invasive fungal infections following combat-related trauma, 2009-2010 33

Table 2. Wounding pattern and injury characteristics of patients diagnosed with invasive fungal infections following combat-related traumatic injury, 2009-2010 34

Table 3. Clinical characteristics of patients diagnosed with invasive fungal infections following combat-related traumatic injury, 2009-2010 35

Table 4. Clinical course/interventions in patients diagnosed with invasive fungal infections following combat-related traumatic injury, 2009-2010 36

Table 5. Clinical and laboratory parameters in patients diagnosed with invasive fungal infections following combat-related traumatic injury, 2009-2010 37

Table 6. Blood transfusion requirements by IFI classification, 2009-2010 38

Table 7. Characteristics of wounds infected with invasive mold (N = 53) among patients following combat-related traumatic injury, 2009-2010 39

Figure 3. Intraoperative findings of wound infected with invasive mold (Case 2 described in report) 40

Figure 4. Histopathological findings of selected wounds infected with invasive mold 41

Table 8. Fungal species isolated from wounds in patients diagnosed with invasive fungal infections following combat-related traumatic injury, 2009-2010 42

Table 9. Antifungal therapy in patients diagnosed with invasive fungal infections by IFI classification, 2009-2010 43

Table 10. Clinical events timeline in patients diagnosed with invasive fungal infections following combat-related traumatic injury, 2009-2010 44

Table 11. Clinical outcomes by IFI classification, 2009-2010 45

Table 12. Injury and admission characteristics of patients diagnosed with IFI by fungal pathogen, 2009-2010 46

Table 13. Clinical characteristics, treatment regimens, and characteristics of patients diagnosed with IFI by fungal pathogen, 2009-2010 47

Table 14. Characteristics of patients diagnosed with invasive fungal infections following combat-related traumatic injury (2009-2010) by time period 48

Table 15. Bacterial and/or yeast colonization and/or infection at traumatic wound sites before or at time of diagnosis in patients diagnosed with invasive fungal infections following combat-related traumatic injury, 2009-2010. 49

Table 16. Antimicrobial exposure by drug class prior to invasive fungal infection diagnosis following combat-related traumatic injury, 2009-2010. 50

Table 17. Potential adverse reactions from antifungal agents 51

REFERENCES 52

CASE INVESTIGATION OBJECTIVES

Case investigation entailed a comprehensive review of medical records to identify patients meeting diagnostic criteria for IFI from June 1, 2009 through December 31, 2010. The purposes of this report are as follows:

1. Describe a recent increase of invasive fungal infections (IFI) among military personnel hospitalized with combat-related traumatic injury
2. Describe the clinical, microbiological and histopathological characteristics of IFI cases
3. Review IFI-specific surgical and medical management and describe observed outcomes
4. Provide recommendations to inform clinical practice guidance

BACKGROUND

Individuals with combat-related traumatic injury are known to be at high risk for infectious complications. The nature and severity of injuries inflicted in combat settings (e.g., blast injuries) result in a number of factors, such as breach of physical host defenses, hypoxic tissue damage/necrosis, and implantation of foreign bodies which greatly increase the risk of infection.[1] To date, the majority of reports focusing on infectious outcomes of combat-related traumatic injury have focused on bacterial pathogens, namely *Acinetobacter* spp.[2-10] Increasingly, wounded military personnel have been diagnosed with invasive fungal infections (IFI) prompting the need for an urgent systematic investigation to inform Department of Defense (DoD) clinical approaches to prevention and management.

Infections due to filamentous fungi (i.e., molds) are important causes of invasive disease, including deep skin and soft tissue infection, in both immune compromised and immune competent hosts. Among immune competent individuals, traumatic injury (e.g. agricultural injury, motor vehicle injury, blunt traumatic crush injury) is the most common risk factor for IFI.[11-20] Substantial morbidity and mortality associated with IFI are attributed to the risk of angioinvasion and dissemination, for which systemic antifungal therapy and extensive surgical debridement are often required for control. Rates of IFI in civilian settings have increased in recent years, with fungi from the order Mucorales being a common cause of invasive disease.[21]

Much less is known about the epidemiology and clinical characteristics of IFI among military personnel who have suffered combat-related traumatic injury as compared to bacterial infections. To date, three reports have described the characteristics of post-traumatic injury IFI in the military setting.[22, 23] The initial report from Brooke Army Medical Center (San Antonio, TX) described a fatal case of invasive mucormycosis in a service member injured by an improvised explosive device (IED) in Operation Iraqi Freedom (OIF).[22] Following initial medical evacuation and surgical procedures for the primary injury (e.g., debridement and fixation of pelvic fracture, lower extremity disarticulation), multiple subsequent procedures were required for debridement of necrotic tissue found in the abdomen and pelvis. Histopathological examination of tissue seven days after initial injury suggested mucormycosis, characterized by diffuse invasive fungal infection with frequent lymphovascular invasion. Subsequent culture confirmed the presence of *Actinomucor elegans*. The patient expired nine days after initial injury.

A retrospective cases series conducted at Walter Reed Army Medical Center (Washington, DC) identified six cases of IFI over a 6-year period among military personnel returning from the Iraq theater.[23] An average of 14 (range: 1-27) surgical debridements per patient was performed after diagnosis of IFI; 50% of cases required amputation or revision of a previous amputation. Only 33% of patients were on appropriate antifungal therapy at the initial diagnosis. The average duration of hospitalization was 97 (range: 51-204) days. Recently, a report by British military physicians described the occurrence of fungal soft tissue infections in heavily contaminated combat-related wounds among British military service members injured in Afghanistan.[1] In that report, extensive blast injury, massive blood transfusions, and injuries occurring in the "green zone" of Helmand province were risk factors for IFI.

In response to the observed increase in IFI, internal practice guidance was proposed by the NNMC trauma service in 2010. The guidance emphasizes aggressive surgical debridement as well as the need to send tissue for fungal culture and histopathology in those with greater than expected necrotic tissue at the time of follow-up debridement. Four general principles apply in the management of these cases, including surgical debridement, early diagnosis, reversal of underlying predisposing risk factors, and prompt antifungal therapy. Any fungal cultures unable to be identified by the local mycology laboratory were recommended to be sent to reference lab for further identification and consideration for antifungal susceptibility testing [BAMC has used the University of Texas Health Sciences Center San Antonio (UTHSCSA)].

Rapid diagnosis and treatment of infectious complications is a critical component of the care of military personnel who have suffered combat-related traumatic injuries. The Department of Defense (DoD)-Veterans Administration (VA) Trauma Infectious Disease Outcomes Study (TIDOS) is an observational cohort of infectious disease outcomes following deployment-related traumatic injury in active duty personnel or DoD beneficiaries.[10] Since the initiation of this study in June 2009, data on infectious complications and their treatment/management have been collected on US military members who were injured in support of Operations Iraqi Freedom (OIF)/New Dawn (OND) in Iraq or Operation Enduring Freedom (OEF) in Afghanistan. The recent emergence of IFI among wounded military personnel is a priority focus within the TIDOS project. To our knowledge, this is the largest case series of IFI described to date. Herein we describe the epidemiology, clinical and laboratory characteristics, treatment regimens, and outcomes of IFI cases among US military personnel from June 2009 to December 2010. Data from this report will guide the development of clinical practice guidance regarding the identification, treatment and prevention of these infections in the future.

INVESTIGATION METHODS

Study Population

The population includes US military active duty service members who were injured in combat in support of Operation Iraqi Freedom (OIF)/Operation New Dawn (OND) in Iraq or Operation Enduring Freedom (OEF) in Afghanistan, then medically evacuated through Landstuhl Regional Medical Center (LRMC) in Landstuhl, Germany, and finally admitted to one of three

military treatment facilities (MTFs) in the US. The participating MTFs are Walter Reed Army Medical Center (WRAMC) in Washington DC, the National Naval Medical Center (NNMC) in Bethesda, MD, and Brooke Army Medical Center (BAMC) in San Antonio, TX.

Study Design

This case series investigation has been undertaken under the auspices of the Department of Defense (DoD)-Veterans Administration (VA) Trauma Infectious Disease Outcomes Study (TIDOS). Details of the TIDOS study have been previously described,[10] but in brief, it is designed to evaluate the incidence, risk factors, and outcomes of trauma-associated infections as a result of military combat injuries. Eligible subjects include all service members injured during deployment from June 1, 2009 to present, who are medically evacuated through LRMC to one of the three participating US MTFs. Data regarding the trauma history and infectious disease specific inpatient management are obtained through the Joint Theater Trauma Registry (JTTR) and the Navy/US Marine Corps (USMC) Combat Trauma Registry. Through the TIDOS study design, variables such as vital signs, use of antimicrobial agents, and the occurrence of infectious disease related events, such as sepsis and skin and soft tissue infection (SSTI) are recorded through a supplemental infectious disease (ID) module within the JTTR. In the longitudinal cohort component, consenting participants are contacted periodically by phone for the subsequent five years following discharge and electronic DoD/VA medical records are reviewed.

As part of ongoing TIDOS data collection, additional data were collected to supplement the JTTR ID module. These included data specifically pertinent to IFIs, such as additional laboratory data (glucose, base deficit, pH, galactomannan, beta glucan), additional initial management data, and surgical details. All operative notes for case patients were reviewed, and data including the number of debridements, extent of final amputation(s), procedure(s) performed, and operative site wound description (necrosis, eschar, purulence, etc.) were captured. Finally, additional detailed information from the histopathology specimens was obtained through a thorough review by a surgical pathologist. Data such as presence or absence of fungal elements, presence of angioinvasion, type of staining used, and morphology of fungi seen were all recorded.

Case Definitions

Case definitions were modified from the Mycosis Study Group 2008 definitions[24] and categorized as proven, probable, or possible. The diagnostic criteria required the following setting: traumatic wounds, status post at least one adequate irrigation and debridement to exclude transient surface contamination. Proven IFI was defined as histopathological evidence of fungal angioinvasion of wound tissue, regardless of culture confirmation. Probable IFI required all of the following: 1) traumatic injury with tissue damage; 2) evidence of infected tissue, such as necrosis found on at least two consecutive debridements; and 3) histology with fungi found only in necrotic tissue or fungal elements on smear of necrotic material (culture confirmation not required) without observed angioinvasion. Finally, possible IFI required all of the following: 1) traumatic injury with tissue damage; 2) evidence of infected tissue, such as necrosis found on at least two consecutive surgical debridements; and 3) no histological examination obtained, or histological examination

negative, but filamentous fungi recovered from culture. All cases were reviewed by a pathologist to confirm the diagnostic classification.

Case Identification

Using the TIDOS database, potential cases of invasive fungal infection were identified by reviewing microbiologic data (positive fungal cultures) and screening by antifungal prescriptions during the time frame from June 1, 2009 to January 15, 2011. Fungal cultures were considered positive if at least one culture taken from a deep wound operative site (after the first surgical debridement) was positive for a pathogenic mold (i.e. Mucorales, *Aspergillus*, *Fusarium*). Since some patients with IFI may have positive histopathology but negative culture, surgical histopathology reports for TIDOS eligible patients were also reviewed for presence of fungal elements, with or without angioinvasion. Antifungal prescriptions were also reviewed for prescriptions of five days or longer, and after excluding agents that are not typically prescribed for molds, such as fluconazole, records of remaining patients were reviewed. These charts were then analyzed for clinical and operative evidence of traumatic wound infection (tissue necrosis, fever, leukocytosis). Finally, clinical records of known IFI cases in the infectious disease and trauma surgery departments at the participating medical centers were also reviewed to assure that no cases were missed.

Additional Study Definitions

In an effort to display the natural history, clinical course, and management of these cases, a timeline was created with the following definitions: the "first positive mold culture" was the date the first wound culture growing a mold was sent (not the date the result was available to clinicians). "First positive histopathology" was the date the first histopathology specimen showing fungal elements (regardless of angioinvasion) was sent. Date of IFI diagnosis then, was the earliest date for a positive result from either of these two tests. For those patients with more than one wound, the first wound with a positive result was recorded as the date of IFI diagnosis for that patient, regardless of the total number of wounds that were ultimately positive.

The operative reports were reviewed for documentation of gross evidence of wound infections. Each of the 53 wounds was recorded as having purulence, myonecrosis, liponecrosis, necrosis (without specification of tissue type), fibrinous exudates, or eschar, if at any time during the clinical course such findings were documented in the operative notes. The "time to documented clean wound after IFI diagnosis" was defined as the number of days from IFI diagnosis (see above) to the date of the first documented clean wound (with no documentation of infection in the same wound thereafter). Only 30 wounds (57%) had sufficient documentation stating "clean wound," so only these 30 were included in this particular analysis.

The amputation history was also sought, with efforts to obtain the number of limbs involved, anatomical site, number of revisions, and ultimate amputation level. For purpose of this report, "high level" amputation was defined as proximal lower extremity amputations at the level of the hip (hip disarticulation) or hemipelvectomy.

FINDINGS

Scope of the Problem.

The TIDOS study began on June 1, 2009 and is ongoing. Since the initiation of the study, over 2000 service members have been medically evacuated from OEF to the US, with ~50% being admitted to one of the three medical centers (NNMC, BAMC, WRAMC) participating in the study.[10] From June 2009 to the present, data from almost 1500 patients have been collected at these facilities and 754 (~50%) patients have enrolled in the five-year prospective cohort study.

Among LRMC trauma admissions during June 1, 2009 – December 31, 2010, a total of 41 potential cases of IFI were identified. Of these, five were excluded; two had positive cultures for *Aspergillus* from a respiratory sample, rather than wound culture. One patient had *Aspergillus* isolated from a sterile body site, but did not have traumatic extremity wounds; one patient had *Aspergillus* isolated from the knee synovial fluid six months after his initial injury. Since this pattern was not consistent with IFI associated with traumatic wounds, and was more likely a nosocomial infection, this patient was excluded. Finally, one additional patient was excluded due to lack of operative evidence of infected tissue on at least two subsequent debridements. Laboratory data on this patient only indicated isolation of an "unidentified mold".

The distribution of medical evacuations from OEF to LRMC over time is presented in Figure 1. During June 1, 2009 – December 31, 2010, a total of 2413 patients were admitted to LRMC, an average of 324 (range: 95-509) patients per quarter. The highest number of admissions (n=509) occurred in the 3rd quarter (July-September) of 2010. During the total study period, an average of 5 (range: 0-12) patients per quarter were diagnosed with IFI. The proportion of patients diagnosed with IFI gradually increased over the evaluation period; in fact, the percentage of OEF admissions to LRMC which had combat-related IFI increased during each successive quarter in 2010, the highest number (n=12) occurring in the 4th quarter of 2010. In this quarter, patients with IFI accounted for 3.2% of all admissions to LRMC from OEF. The progressive rate increase is also demonstrated when assessing the IFI cases by the number of trauma patient admissions to the LRMC ICU. Over the investigation period the IFI rate was as follows (based on LRMC JTTS data): 3rd quarter (Jun-Sep) 2009 – 2.6%, 4th quarter 2009 - 1.2%, 1st quarter 2010 – 2.2%, 1st quarter 2010 – 2.2%, 2nd quarter 2010 – 4.2%, 3rd quarter 2010 – 6.2%, and 4th quarter 2010 – 8.0%. The trauma ICU LRMC population includes patients injured during operational deployment (both Iraq and Afghanistan theaters) as well as other patients sustaining traumatic injuries; therefore, the rates are likely to be higher than reported if further restricted to OEF-related injury.

All cases were male and the median age was 23 (IQR: 21-27) years (Table 1). All were enlisted service members; 24 (66.7%) were Marines and 12 (33.3%) were Army. All of the cases returned from combat duty in Afghanistan, and 94% (34/36) received their initial care at a facility in Helmand or Kandahar provinces.

Injury pattern and wound description

Regarding mechanism of injury, all patients suffered blast injuries, three (8.3%) while mounted and 33 (91.7%) while dismounted (Table 1). All of the injury mechanisms were coded as improvised explosive device with the following additional descriptors: IED person-borne (1), mortar, rocket and/or artillery shell (1), motor vehicle collision (1), rocket-propelled grenade (1), and other blunt trauma (1). Notably, perineal and genital wounds were particularly common (Table 2), as the most commonly recorded individual ICD-9 codes included the following: 897.2: amputation above the knee (n=22; 61%); 878.2: open wound scrotum/testes (n=21; 58%); 897.6: amputation leg, bilateral (n=14; 39%); 872.61: open wound of ear drum (n=10; 28%); 879.8: open wound site NOS (n=10; 28%); and 878.0: open wound penis (n=10; 28%).

All of the patients had extremity injuries (Table 2), commonly with lower extremity amputation (78%). Amputation revisions were required in 72% of the cases. In addition to the very significant extremity trauma, 47% had vascular injuries, 33% penetrating abdominal trauma, 17% penetrating thoracic injuries, as well as several other injuries detailed in Table 2. The median injury severity score (ISS) upon admission to LRMC was 20 (IQR: 15.5, 24.5), similar to that of all OEF patients admitted to the intensive care unit (ICU) at LRMC (ISS: 22; IQR: 14, 29) (Figure 2). By contrast, the ISS among OEF patients not admitted to the ICU was 9 (IQR: 5, 18). Figure 2 displays a comparison of OEF patients (overall and ICU admissions at LRMC). This comparison does not cover the entire time period in which the IFI cases occurred but only the initial six months from June-November 2009. The lower extremity (LE) amputation rate among the IFI cases (78%) far exceeds the rates observed even in the patients admitted to the ICU with similar ISS values (19%) and is far above the rates (5%) for the total OEF trauma patient admissions.

Clinical findings

In the 36 IFI cases (Table 3), overall hospitalizations were prolonged, with a median of 2 (IQR: 2, 3) days at level III, 3 (IQR: 2.5, 4) days at level IV, and 60 (IQR: 38, 74) days at level V medical centers (Table 3). Thirty-five (97.2%) were admitted to the ICU at LRMC and 28 (77.8%) to the ICU at a level V center. All were mechanically ventilated in theater with substantial numbers of patients requiring ongoing mechanical ventilation at level IV (83.3%) and level V (55.6%). The Admission Sequential Organ Failure Assessment (SOFA) score[25, 26] had a mean of 7.6 at LRMC and 4.7 at level V centers with the most common abnormalities seen in coagulation disorders (thrombocytopenia), hepatic function (hyperbilirubinemia), respiratory function (reduced alveolar-arterial oxygen gradient), and cardiovascular function (hypotension). Stratifying by the IFI diagnostic classification (Table 3) demonstrated similar overall SOFA scores at time of admission at LRMC; however, higher scores were seen at time of admission in the U.S. hospital as the diagnostic certainty moved toward the proven category with median SOFA scores of 1, 3.5, and 6 for possible, probable, and proven IFI categories, respectively. This may represent a tendency toward more aggressive histopathological diagnostic testing in the more critically ill patients. At LRMC, seven patients (19.4%) required chest tubes and eight (22.2%) received vasopressor

therapy. During the U.S. hospitalization, 10 (27.8%) required chest tubes, six (16.7%) were on vasopressor therapy, and six (16.7%) received total parenteral nutrition (Table 4).

Certain clinical parameters were reviewed from in-theater documentation to assess the level of initial physiologic compromise (Table 5). The median initial documentation of heart rate was 126 (IQR: 114,152), systolic blood pressure was 98 (IQR: 80,119), base deficit on blood gas was -7.5 (IQR: -10.5, -3), and pH was 7.3 (IQR: 7.2, 7.3). Of note, it could not be determined to what extent resuscitation had already occurred prior to the documentation of these variables, therefore the physiologic condition of these patients might very well be much worse than these values indicate. Upon admissions to level IV and level V centers, the median white blood cell (WBC) count was 7.8 (IQR: 5.0, 9.9), and 10.7 (IQR: 7.6, 13.0) respectively. Within the same week of the IFI diagnosis, 94% of all patients had a documented fever with a median maximum oral temperature of 39.3^{o}C (IQR: 39, 40). No significant differences in frequency of fever or the magnitude of the maximal temperature were observed across IFI diagnostic classes. Overall, leukocytosis was present in 97% of patients with median maximum WBC of 23.4 x 10^9 cells/L (IQR: 17.4, 32.4). Patients in the proven category trended toward higher maximal WBC counts. Other selected laboratory data collected within the five days preceding the IFI diagnosis were notable for slightly elevated maximum blood glucose of 140 (IQR: 115, 164), thrombocytopenia in 25%, and hyperbilirubinemia in 42%. There was no evidence of metabolic acidosis (median pH: 7.3; IQR: 7.3, 7.4). The patients in the proven category also more frequently demonstrated renal insufficiency with serum creatinine values exceeding 2.0 mg/dL at the time of IFI diagnosis in 26% as compared to < 10% in the other IFI categories.

Blood product requirements

All but one patient with IFI (97.2%) received ≥10 units of blood at the level II and III MTFs (Table 6). The patient receiving the lowest amount of blood transfusions was classified as proven IFI. The amount of blood products transfused in these cases often far exceeded the threshold of ≥10 units in first 24 hours, often defined as "massive transfusion".[27] The number of blood products given in theater (surrogate for "first 24 hours") had a mean of 26.8 (SD ± 15) units for packed red blood cells (PRBC) and 25.1 (SD ± 12.8) units for fresh frozen plasma (FFP). During the total hospital course, patients received a mean of 97.1 (SD ± 51.5) total units of blood products: 52.7 (SD ± 28.5) units of PRBCs, 7.8 (SD ± 6.3) units of platelets, 29.9 (SD ± 16.4) units of FFP, 6.8 (SD ± 9.4) units cryoprecipitate, and 1.0 (SD ± 2.2) units of whole blood (Table 6). The highest levels of transfusion requirements were seen in the patients in the proven category with a median total requirement of 113 units as compared to 66.5 and 81 units observed in the probable and possible IFI patients which are still extremely high.

Selected case histories

The first case (Case 1) in this series was that of a 24-year old Marine who presented in June of 2009 after suffering multiple injuries from an IED blast while on dismounted patrol in Afghanistan. Initial injuries included traumatic below the knee amputations bilaterally, an open pubic ramus fracture, extensive perineal injury and urethral transection, bladder rupture, sigmoid

colon transection, and multiple fractures of the right upper extremity. At the level III center (Camp Bastion), he underwent thoracotomy and cardiac massage for cardiac arrest, as well as exploratory laparotomy and lower extremity debridements. He was resuscitated with 70 units of blood products (34 units PRBCs, 29 units FFP, 4 units of platelets and 3 units of whole blood) in the first 24 hours. He was transferred to LRMC the following day where he underwent repeated debridements of his lower extremities and abdominal washouts, as well as revision of right lower extremity (RLE) from a below the knee amputation (BKA) to a hip disarticulation. He developed acute kidney injury secondary to rhabdomyolysis and required hemodialysis.

Five days after the date of injury he was admitted to the ICU at NNMC, where dialysis and mechanical ventilation were continued. On the third hospital day he underwent left BKA revision and wound closure, urethral repair, and debridement of the right hip and abdominal wounds. On the fifth hospital day his right hip was again debrided. He became febrile and tachycardic, and on the ninth hospital day he underwent perineal debridement and orchiectomy, and operative tissue examination revealed a necrotic testicle and spermatic cord with angioinvasive fungal elements. On the tenth hospital day he underwent repeat wound debridement of extensively necrotic tissue of the right pelvis, gluteal muscles, and abdominal wall, and ultimately underwent hemipelvectomy. Operative tissue examination again revealed angioinvasive fungal elements, now in the excised right rectus muscle and fungal osteomyelitis in the right innominate bone. Fungal cultures of the wound were not sent. Liposomal amphotericin B was begun. The following day, an extensive amount of tissue which was viable in the OR was now found to be necrotic. He became more hemodynamically unstable over the following day, and after discussion with his family, care was withdrawn and the patient expired on the twelfth hospital day.

A more recent case (Case 2) was that of a 29-year old Marine who also suffered extensive traumatic blast injuries while on dismounted patrol in Afghanistan in December 2010. He suffered traumatic left hip disarticulation, right traumatic through knee amputation with proximal femur fracture, extensive scrotal, bladder, and perineal injuries, colonic rupture, and fractures of the sacral bone and multiple bilateral hand bones. At the Forward Operating Base (FOB) on the day of injury he underwent exploratory laparotomy with ligation of internal and external iliac arteries to obtain hemostasis. He received 87 units of blood products in the first 24 hours (41 units PRBCs, 38 units FFP, and 8 units whole blood). At LRMC, he underwent abdominal wound closure and ostomy placement; debridement of left hip was also performed and large amounts of necrotic tissue were removed (shown in Figure 3). He was admitted to NNMC five days after injury. Repeated debridements of the left hip, right leg, perineum and scrotum were performed on the second, fourth, and sixth hospital days. Angioinvasive fungal elements were seen within the soft tissue and muscle of both the left hip and right leg, and antifungal therapy with liposomal amphotericin B and voriconazole was begun. Upon each visit to the OR, substantial amounts of necrotic muscle, fat, and soft tissue were encountered, despite debridement back to clean wounds by the end of the operation two days prior. Repeated operative cultures grew *Mucor* spp. and *Fusarium* spp. By the seventh hospital day, bilateral ureteral catheters and nephrostomy tubes were placed as cystectomy was anticipated due to extensive necrosis of the bladder wall. The bladder was ultimately spared, but on the tenth hospital day he underwent left hemipelvectomy. After a series of additional tissue debridements, he ultimately underwent right leg revision to AKA and delayed primary wound

closure on 27th hospital day, and received a split thickness skin graft to the left pelvic region on the 39th hospital day.

Patient fatalities

Four (11%) patients died – not solely due to IFI, although these severe infections contributed to their deaths (1 case died secondary to multiorgan failure not temporally connected to IFI diagnosis). One of these cases was described earlier in detail. A second patient was a 33-year old soldier who suffered an IED blast with injuries including extensive shrapnel to the back and right shoulder, and multiple open fractures to the right forearm and hand. He underwent right arm below elbow amputation at the level III center, and also underwent craniotomy for cerebral edema and placed on hemodialysis for rhabdomyolysis. At a level V center, eight days after injury, histopathological exam of debrided right arm tissue showed angioinvasive mold, and culture grew both *Mucor* spp. and *Fusarium* spp. Liposomal amphotericin B and voriconazole were prescribed. Two days later a culture from the right humerus bone grew *Aspergillus terreus*. Liposomal amphotericin B and voriconazole were continued. Seven days after fungal diagnosis, after several additional debridements to right upper extremity, he developed sepsis and hypotension. The following day he underwent disarticulation at the right shoulder. Two days after this operation, new extensive necrosis was observed throughout the shrapnel wounds of his back and both lower extremity wounds. The amount of necrosis was felt to be due to mucormycosis and too extensive for further debridement, so a family meeting was held, the patient transitioned to comfort care, and the patient expired 19 days after time of injury, and 11 days after IFI diagnosis.

A third patient, a 24-year old soldier, was injured by IED blast in March 2010. Initial injuries included bilateral traumatic AKAs, extensive perineal injuries, hypovolemic shock and cardiac arrest which required aortic clamping and open cardiac massage as part of resuscitation measures. He was transferred to WRAMC and complications included renal failure managed with hemodialysis. He was febrile and on multiple antibiotics, but no extensive necrosis was found intraoperatively until the twelfth day after injury, when a right hip disarticulation was planned. Intraoperatively, he was found to have widespread necrosis of the right hip with "fluffy, fungal-like" growth, and also necrosis of the abdominal wall, bladder, ureter, colon, and 90% of small bowel. Upon multidisciplinary meeting, further surgical management was deemed futile, patient transitioned to comfort care, and he expired. The intraoperative cultures, which returned after patient expired, ultimately grew *Apophysomyces*, *Fusarium*, and *Trichosporon mucoides*. Antifungal agents were not started, as he was transitioned to comfort care measures the day of IFI diagnosis.

The fourth patient died due to multi-organ system failure manifesting as acute respiratory distress syndrome, acute renal failure, cardiovascular failure and sepsis/bacteremia. The invasive fungal infection was not listed as a cause of death. The IFI diagnosis preceded death by greater than two months and postmortem cultures did not isolate mold species.

Characteristics of infected wounds

Among the 36 cases, a total of 53 distinct IFI wounds were identified. Of these 53 wounds, 26 (49%) were classified as proven, 8 (15%) were probable, and 19 (36%) were possible invasive

fungal infections (Table 7). In the operative notes, these wounds were described as having myonecrosis in 82%, liponecrosis in 49%, any (nonspecific) necrosis in 75%, eschar in 14%, purulence in 43%, and fibrinous exudates in 18%.

Among these 53 wounds, 41 (77%) had histopathology obtained with 34 (83%) of these with fungal elements detected. Angioinvasion, the basis for meeting proven criteria, was seen in 63% and all wound histopathology was found to have necrosis detected on at least one specimen examined. Selected examples of positive histopathology findings on IFI wounds are included in Figure 4. The morphology of the fungal elements, in the subset of patient wounds sent for pathology, was septate in 13 (38%) and aseptate in 12 (35%); seven (21%) had multiple morphologies in the same wound specimen exam and two (6%) had indeterminate morphology. Eighteen (44%) wounds had fungal elements seen with PAS staining and 21 (51%) with GMS staining. Specimens were always stained with hematoxylin and eosin (H&E) and commonly also with a supplemental stain, either PAS and/or GMS. In circumstances where there was discordance (H&E detected fungal elements but the supplemental stain did not) the PAS staining more commonly failed to detect fungal elements than GMS, 26.8 vs. 7.3%. In 8 of the 11 (72.7%) wound specimens stained with PAS that contained fungal elements visible on H&E staining; aseptate morphology was seen consistent with a Mucorales mold. Although intra-operative frozen section was not commonly obtained, in the 15 (37%) wounds in which frozen sections were evaluated, there were six positive frozen sections (all also found positive for fungal elements on standard histopathology) and nine negative frozen sections (six later found to be positive on definitive staining).

A total of 30 (83%) patients had ≥ 1 mold species isolated on wound cultures (Table 7) with approximately 30% each of order Mucorales (9 *Mucor* spp., 6 *Saksenaea vasiformis*, and 2 *Apophysomyces* spp.) and *Aspergillus* spp., and other molds with *Fusarium* spp. isolated in 17%. Detailed species identification is summarized in Table 8. Additional isolates identified included *Penicillium* spp. (2), *Acrophialophora fusispora* (2), *Beauveria* spp. (2), *Ulocladium* spp. (2), and one each of *Paecilomyces* spp., *Alternaria* spp., *Scedosporium prolificans*, and *Pythium aphanidermatum*. Additionally, seven isolates were documented as unidentified molds. Of note, despite 17 different wounds growing molds of the order Mucorales, there were no cultures positive for *Rhizopus* spp., the most commonly isolated Mucorales organism from the largest mucormycosis case series in the literature.[21] The order Mucorales was more commonly observed among the proven IFI category (Table 12); however, there were 6 IFI cases with documented angioinvasion with non-Mucorales molds. Also seen among the IFI cases with negative mycology there was a similar distribution of histopathological evidence of both septate and aseptate hyphae.

All 53 wounds were also either colonized or infected with a bacterium or yeast by the date of IFI diagnosis, with the most commonly identified organisms being *Enterococcus faecium* (n=10, 18.9%), *Acinetobacter calcoaceticus baumannii* complex (n=9, 17%), and *Escherichia coli* (n=7, 13.2%) (Table 15). Additionally, *Pseudomonas aeruginosa* and *Enterobacter cloacae* were each cultured from six wounds. *Candida albicans* grew from four wounds (7.6%).

Antimicrobial agents

Thirty-two patients (88.9%) received antifungal therapy with all 4 not receiving an antifungal agent in the possible IFI category. The description of antifungal regimens is presented in Table 9. The overall number and percentage receiving specific antifungal agents were as follows: liposomal amphotericin B (n= 29; 80.6%), voriconazole (n= 27; 75.0%), posaconazole (n= 16; 44.4%), caspofungin (n= 12; 33.3%) and micafungin (n= 3; 8.3%). Liposomal amphotericin B was used a median of 21 days, and voriconazole a median of 13 days. When evaluated by antifungal regimen, the distribution was as follows: monotherapy (n= 8; 22%), liposomal amphotericin B plus a triazole (n= 18; 50%), liposomal amphotericin B plus a triazole and caspofungin (n= 5; 14%), and triazole plus micafungin (n=1; 2.8%). Table 9 stratifies antifungal regimen use by IFI diagnostic classification. The highest rates of use of liposomal amphotericin B (94.7%), voriconazole (89.5%), and posaconazole (63.2%) were observed among the patients in the proven IFI category. The highest use of combination antifungal therapy was also seen in this group at 89.5% versus 25.0% in probable and 46.2% in possible cases. No new onset antifungal agent toxicity was documented on review of records; however, renal insufficiency at time of IFI diagnosis was commonly observed among the proven IFI cases highlighting the need to limit empiric therapy to patients with strong suspicion for IFI and prompt discontinuation of antifungal therapy if histopathology returns negative and suspicion of IFI is no longer being considered.

Several topical agents were used, including 0.025% sodium hypochlorite solution (modified Dakin's solution) in 12 (33.3%), amphotericin B beads in 3 (8.3%) and amphotericin peritoneal irrigation in one patient. The median duration from time of injury to the initiation of any antifungal therapy was 12 (IQR: 9, 16) days (Table 10). However, the median time between the IFI diagnosis date and initiation of any antifungal therapy was 3 (IQR: -10, 33) days. Evident in this range is both early empiric initiation of therapy as well as much delayed initiation. The median duration of antifungal therapy was 27 (IQR: 16, 45) days.

A number of patients were treated with antibiotics prior to diagnosis of IFI. The distribution of antibiotic therapy, by drug class, is presented in Table 16. The most frequently used antibiotics were first generation cephalosporins in 35 (97.2%) patients, fluoroquinolones in 34 (94.4%), vancomycin in 27 (75%), aminopenicillins in 23 (63.9%), carbapenems in 22 (61.1%), and aminoglycosides in 21 (58.3%). In addition, eight (22.2%) patients received a course of fluconazole, and eight patients (22.2%) received an echinocandin antifungal agent prior to their IFI diagnosis. In general, the majority of antecedent antimicrobial regimens were of short duration, likely reflecting antimicrobial prophylaxis in many of the cases.

Clinical time course and outcomes

The timeline for hospitalization course and the IFI-specific events is detailed in Table 10. The median duration from time of injury to admission at LRMC was 3 days (IQR: 3, 4) with approximately 3-day LRMC hospitalization. Lengthy hospitalizations (pre-rehabilitation) were

observed with median of 2 months. Diagnosis of IFI most commonly occurred after admission to CONUS facilities; the median (IQR) duration from the time of injury to first diagnosis of IFI, first positive mold culture and first histopathology examination was 10 (7, 14), 10 (8, 14) and 12 (8, 17) days, respectively. The median (IQR) duration from the first diagnosis of IFI to discharge from the CONUS facility was 58 (35, 68) days.

Temporal differences were evaluated by stratifying the case series into the first 12 months (14 cases – 38.9%) and the most recent 6-month time period (22 cases – 61.1%) (Table 14). The more recent time period has higher rates of lower extremity amputations in theater, 81.8 vs. 57.1%, coinciding with higher injury severity scores. The higher percentage of proven IFI cases may reflect heightened efforts and/or improved detection to confirm the diagnosis, although the numbers of patients with wounds being tested for histopathology or microbiology are similar. The time to diagnosis is less (10 vs. 13 days), further supporting increased suspicion and earlier diagnosis. Management approaches, both surgical and medical, appear to be relatively similar across the entire investigation period with the exception of higher rates of combination antifungal therapy (77 vs. 50%) and Dakin's topical therapy (45.5 vs. 14.3%) in the more recent vs. the initial 12-month observation period. A higher case fatality rate was observed in the initial 12-months although this is potentially misleading since the one case with IFI not related to his death fell into the initial period and the total number of deaths is small.

Clinical outcomes are described by IFI diagnostic classification in Table 11. Overall, the median number of surgeries at the IFI wound site after medical evacuation out of theater was 11 (IQR: 7, 16). A subset of the wounds (n= 30; 57%) had documented clean wound beds allowing a median estimation of the time from IFI diagnosis to clean wounds at 21 days (IQR: 18, 35). One quarter of patients ultimately required an amputation at the level of total hip disarticulation or higher. As previously noted, 11% of patients with IFI diagnosis died with 3 of the 4 among the proven IFI category. Other outcome measures such as overall hospitalization, ICU stay, or requirement for further amputation or high level amputations were not observed at significantly higher levels in the proven IFI category.

DISCUSSION AND RECOMMENDATIONS

Invasive fungal infections have emerged as an important cause of morbidity and mortality among US service members who have suffered combat-related traumatic injury in OEF. This case series of IFI among individuals with deployment-related traumatic injury is the largest reported to date. Most patients with IFI were injured by blast injuries on dismounted patrol in Helmand and Kandahar provinces in Afghanistan. These observations are consistent with the earlier British military experience.[1] Traumatic lower extremity amputation and massive blood transfusions are typical features of patients with IFI. The observed temporal trend of increasing number of IFI cases follows the increasing trend in lower extremity amputations, particularly among Marine Corps personnel in Afghanistan. The high case fatality rate exceeds observed mortality among wound infections secondary to bacterial infections, although causes of death are multifactorial in nature and not solely related to IFI diagnosis.

Identification of risk factors

Infection control and prevention begin with recognition of risk factors for the incidence and progression of disease. The identification of certain characteristics that are more commonly seen in combat-related IFI patients is crucial for determining when a diagnostic evaluation and empiric therapy may be warranted. While the data available on these 36 patients are robust, a concurrent comparison group has not been evaluated, so more precise risk factor analysis is not possible through this case series.

The average injury severity score (ISS) from one case series in the literature of mucormycosis post-traumatic injury was 24 (range: 9-41).[19] In our report, the median ISS of cases was 20 (IQR: 15.5, 24.5). The median time from date of injury to date of infection diagnosis was 10 days. The mechanism of injury was similar for all cases, in that most (92%) were on dismounted patrol and all sustained blast injuries. The nature and extent of injuries sustained by military personnel in these conflicts are variable, but among the most severe are blast injuries inflicted by improvised explosive devices (IED).[28, 29] Blast injuries can involve multiple body regions simultaneously, and an increasing proportion of injuries involve the extremities.[30, 31] In this series, injury to the limbs and perineum were extensive, as 75% required amputation in theater, and the two most common individual ICD-9 codes were amputation above the knee (n=22) and open wound to scrotum/testes (n=21). The percentage of major limb injuries during wartime resulting in amputation has historically been 6% over the last seven years. Since June 2009, higher percentages have been observed in soldiers (up to 15% in July 2010) and even greater increases among Marines with rates as high as 36% in June 2009 and 38% in December 2010 (personal communication, LRMC Trauma Department LTC Ray Fang).

The geographic location at time of injury was unable to be obtained, but 94% (34/36) received their initial care at a level III facility in the Helmand or Kandahar provinces of southern Afghanistan. This is consistent with the British report from Evriviades et al. stating that many combat-related traumatic IFIs occur in the "green zone" of Helmand province, where the vegetation is not as sparse as elsewhere in the country.[1] It is unknown whether this observation simply reflects the increase total number of casualties from these southern provinces, or whether the different environment in this geographic region actually plays a role in IFI. Ongoing surveillance is needed to determine if regional location is an independent risk factor distinct from mechanism of injury and subsequent wounding pattern.

Traumatic amputation associated with IED blast is often complicated by gross contamination of wounds with organic material (e.g., soil, vegetation). Cases of IFI associated with traumatic injury often present with soil-contaminated wounds.[11, 19, 32] While most of the reports in the literature involve disruption of an extensive amount of the cutaneous surface,[11, 13, 33] occasionally invasive disease is reported after only a minor insult.[34] Fungi from the order Mucorales have been isolated from patients with combat-related traumatic injury.[1, 22] Pathogens of this order include *Absidia* (now *Lichtheimia*), *Mucor*, *Rhizomucor*, *Rhizopus*, *Cunninghamella*, *Saksenaceae*, *Apophysomyces*, *Actinomucor*, and several others. These fungi are commonly found in the environment, particularly in soil with decaying vegetation.[35] In civilian settings,

mucormycosis occurs as cutaneous or nail infections following the traumatic implantation of fungal spores. In combat settings, particularly those where blast injuries are common, traumatic wounds are more severe, with the vast majority of extremity injuries being soft-tissue wounds or fractures.[29] These types of injuries likely introduce fungal pathogens through open skin.[22] In addition to Mucorales, other environmental molds such as *Aspergillus* spp., *Fusarium* spp., and *Scedosporium* spp. have been documented to cause wound infections.[16, 20, 36] To our knowledge there is no literature documenting which environmental molds populate the soil in Afghanistan. The closest review of studies from nearby geographic regions includes a study from Turkey wherein a total of 110 species from 32 genera of fungi were found. Among those were *Aspergillus* spp., *Fusarium* spp., *Beauveria* spp., *Mucor* spp., and *Rhizopus* spp.[37] In this series, proven cases with documented angioinvasion were observed in both Mucorales and non-Mucorales molds.

In general, patients with mucormycosis and other invasive mold infections have underlying medical (i.e., immunosuppressive) conditions, including hematopoietic stem cell or solid organ transplantation, hematologic malignancy or prolonged neutropenia, diabetes mellitus, acidosis, and prolonged steroid administration.[38] Conversely, patients with cutaneous infections tend to have intact immune systems, and in two case series, account for 50-60% of cases.[12, 21] Unlike the previous case series, the patients in this case series differ due to the extensive nature of the combat-related polytrauma and receipt of transfusion well in excess of the ten units defined as "massive transfusion". In one report of patients with traumatic cutaneous mucormycosis, all received more than five units of blood.[19] In our cohort, all but one patient received ≥10 units of blood; a median (range) of 90 (55-120) units of blood products were transfused. In addition to the relative immunosuppression from extensive trauma, there is evidence that receipt of massive blood transfusions can have immunosuppressive effects and thereby increase the risk for healthcare-associated infections.[39] This may be due to the immunosuppressive activity of the blood transfusions themselves, or perhaps the higher number of transfused blood products is a marker for more extensive traumatic injury. An additional consideration is the iron burden that is received with blood transfusions. There is a clear association between invasive mucormycosis and iron overload states, such as hemochromatosis, and the use of the iron chelator, desferoxamine, which allows iron to become more readily available to the molds as a nutrition source.[36] It is not clear from our report whether the molds which are contaminating the wound from the initial injury are more likely to cause invasive disease by utilizing iron excess as a nutrition source. Serum iron and ferritin levels were not routinely drawn, so although theoretically plausible, no clear correlation can be drawn in this case series between transfusion-related iron overload states and IFI.

With regard to prevention, the use of primary antifungal prophylaxis is supported by evidence-based medicine in certain high risk immune compromised populations, such as those undergoing hematopoetic stem cell transplantation with graft versus host disease and hematologic malignancies.[40] Posaconazole has been shown to have survival advantage and fewer proven and probable invasive fungal infections when compared to fluconazole or itraconazole in these populations.[41, 42] Reductions in the number of invasive fungal infections with amphotericin B as primary prophylaxis in patients with prolonged neutropenia has been observed as well.[43, 44] While the role of antifungal primary prophylaxis of high risk immune compromised patients is well established, there are no studies evaluating their role in immune competent patients with traumatic

injuries. However, from the recently published paper describing management of traumatic wounds suffered during the military conflict in Afghanistan, the authors from the UK suggest the use of liposomal amphotericin B and posaconazole for prophylactic use and empiric therapy in those felt to be at highest risk.[1] While we support the use of early empiric antifungal therapy at the time of diagnostic work up of presumed IFI, prophylactic therapy from time of injury is not recommended, since there is no data showing improved outcomes in this setting, and these are potentially toxic agents (detailed in Table 17), particularly in the critically ill.[45, 46]

The level V MTFs, in addition to caring for wounded warriors, care for many patients with malignancies and other immune compromising conditions. In the past, nosocomial spread of pathogens associated with traumatic wounds such as *Acinetobacter calcoaceticus baumannii* complex has occurred. As the filamentous fungi that cause IFI are ubiquitous in the soil and decaying vegetation, infection is typically acquired by environments outside of the healthcare setting. However, healthcare- associated transmission of IFI has been documented.[47-49] For this reason, the infection control departments at the participating MTFs have heightened surveillance for healthcare-associated infections due to IFI, and to date no such transmission has been observed.

Diagnosis

Due to the angioinvasive nature of these molds, microvascular thrombosis occurs, leading to necrosis of the adjacent tissues[50] and invasive disease.[15] The majority of cases reported in the literature are described as necrotic,[13, 15] as was observed in all 36 cases; although rarely a cottony appearance of the wound is described.[12, 16] Subclavian vein thrombosis[19] and osteomyelitis [37] have also been reported.

Diagnosis of IFI is based upon either histopathology examination or positive culture.[12] Since fungal cultures require several days to grow and may be insensitive,[51] obtaining a surgical sample for histopathology evaluation is essential for prompt and accurate diagnosis. The surgical sample should contain viable tissue, although this can be difficult to obtain with such extensively necrotic wounds. Standard staining with hematoxylin and eosin can be insensitive for detection of fungal elements, so special staining should be use such as GMS and PAS.[35] In this cohort, PAS more commonly failed to stain fungal elements than GMS staining particularly in circumstances where H&E staining detected aseptate hyphae. While focused staining of processed tissue yields high diagnostic accuracy and is timelier than culture results, in cases of potentially invasive disease, real-time intra-operative evidence may help guide the level of surgical debridement, as well as allow for timely institution of targeted antifungal therapy. Frozen section technique is timely, but was not performed in a large percentage of the IFI cases. Positive findings on frozen section were confirmed as positive on routine histopathology; however, 67% of cases with initially negative frozen sections were subsequently found to be positive on definitive staining.

Due to low negative predictive value of frozen sections, efforts have been made to consider additional intraoperative diagnostic techniques at the MTFs. Calcofluor white is a fluorescent whitener that binds to chitin and cellulose and has been used in various settings for rapid detection of fungal elements from clinical samples.[52-54] It has demonstrated higher sensitivity than KOH

preparation or culture for diagnosis of fungal corneal ulcers,[52] but it has not been compared to culture or traditional tissue staining techniques (GMS, PAS) for fungal traumatic wound infections. The calcofluor white staining is technically easy to perform, but ultraviolet fluorescent microscopy experience is necessary for interpretation.[54] This staining technique has been performed in the mycology lab at WRAMC on all specimens ordered as "fungal culture" throughout the study time period (analogous to gram stain for bacteria). Among the 36 cases with IFI, 33 wound cultures that ultimately grew a mold also had tissue stained with calcofluor white. Of these, only 16 out of the 33 were positive for fungal elements on calcofluor white staining. It is therefore possible that intraoperative calcofluor white staining may have low sensitivity, just as frozen sectioning does. A comparison of these two intraoperative diagnostic techniques is currently underway at NNMC.

In addition to obtaining histopathology specimens from surgical debridement, tissue should be sent for fungal culture. All tissue samples sent for fungal culture should be plated on fungal specific media (brain-heart infusion agar [BHI], inhibitory mold agar [IMA] and SabHI agar). Cultures should be reviewed for growth daily for 5 days then weekly for four weeks. Tissue and fluid are preferred over swab samples, since fungi adhere to fibers of the swab and yield is low. Tissue samples should be submitted with damp gauze to keep the sample moist prior to processing. Fungal culturing by traditional technique can be limited. Even on appropriate fungal growth media, molds may not grow fruiting bodies, which are essential to their morphologic diagnosis. Of note, some of the clinical isolates of this case series could not be identified by standard methodologies. Any fungal cultures unable to be identified by the local mycology laboratory are recommended to be sent to a reference lab for further identification and consideration for antifungal susceptibility testing.

Most case series on mucormycosis report *Rhizopus* spp. as the most common agent, but in this case series, *Rhizopus* spp. was not isolated at all. The most commonly isolated agents of mucormycosis in this report were *Mucor* spp., *Saksenaea vasiformis*, and *Apophysomyces elegans*. There are an increasing number of recent reports in the literature of cutaneous IFI caused by both *Saksenaea vasiformis* and *Apophysomyces elegans*.[34] The higher percentage of these organisms seen in this report may be due to culturing technique or geographic variations, but it also supports the observation that these two organisms, tend to occur as invasive cutaneous infections in otherwise immune competent hosts, rather than in those with more traditional risk factors, such as diabetes. [33-35, 55] While the majority of patients with proven IFI who had positive cultures grew a Mucorales, several with proven infection (angioinvasion) grew other molds only, such as *Aspergillus* spp., so these non-Mucorales filamentous fungi should be considered as potential causes of wound IFI as well.

Management

Treatment of traumatic wound IFIs typically includes both surgical debridement and systemic antifungal agents.[12, 16] Debridement of necrotic material is paramount, as the thrombosed blood vessels from the IFI results in poor tissue penetration of antifungal agents.[38] Surgery has been associated with positive outcomes.[21] Frequent debridement is necessary (potentially daily, depending on the amount of necrotic tissue present at each operation); in one series an average of 10 debridements were performed for definitive care.[56] In a literature review of 75 cases of trauma-

associated filamentous fungal wound infections, amputation was necessary in 31%, and mortality was high (25%).[16] A comprehensive literature review of zygomycosis (under which *Mucorales* is an order), encompassing >900 cases from 1940-2003, provides critical information regarding the clinical characteristics, risk factors, treatment strategies and outcome of these infections.[21] Case fatality of zygomycosis among individuals with no underlying medical condition is approximately 35%.[21] Four (36%) of eleven patients with cutaneous mucormycosis in another study died, all with rapidly progressive necrotizing infection of the head or trunk.[19]

The majority of data on antifungal therapy for mucormycosis focuses on the polyenes, amphotericin B deoxycholate (AmB) and lipid formulations of AmB (LFAB).[38] An amphotericin B product should be started as empiric therapy when diagnosis of trauma-related IFI is suspected, and LFAB is preferred due to lower potential for nephrotoxicity. The data regarding combination antifungal regimens to treat mucormycosis is scant. Although one small retrospective study, in diabetic patients with rhinocerebral mucormycosis, showed better outcomes with the combination of caspofungin and AmB compared to AmB monotherapy,[57] there have not been any prospective data to confirm this finding. While mortality rates are quite high in most studies,[46, 58] these patient populations typically have hematologic malignancies or other underlying immune suppression, and there are no data stating to what extent these agents improve outcomes in patients with traumatic wound infections outside of case reports.

Voriconazole is not active against mucormycosis, but is primary therapy for invasive aspergillosis,[59,45] and has efficacy against certain molds such as *Aspergillus terreus* and *Scedosporium prolificans* which are resistant to amphotericin B.[59] This series demonstrates a large percentage of wounds with multiple mold species, many patients with both Mucorales and either *Aspergillus* spp. or *Fusarium* spp., and a few with angioinvasive disease from *Aspergillus* spp. only. Therefore, patients with intraoperative objective evidence of IFI should be started on both LFAB and voriconazole empirically, while awaiting diagnostic results. There are no data on prolonged courses of dual systemic antifungal therapy, so therapy should be tailored to a single agent when possible, based upon mycology and histopathology results. LFAB should be continued if there are histologic morphology or culture results suggestive of mucormycosis (broad, aseptate hyphae), but voriconazole should be continued as well until presence of potentially AmB resistant organisms (*Aspergillus terreus, Scedosporium prolificans, Fusarium* spp.) have been ruled out by these diagnostic means. There is no guidance in the literature on duration of antifungal agents, but close clinical monitoring and judgment of experienced clinicians are helpful in determining appropriate duration. For SSTI only (no dissemination or osteomyelitis), a shorter duration based upon the appearance of the wound is appropriate.

Posaconazole has been shown to have a 60-70% partial response rate as a salvage regimen for mucormycosis,[60, 61] but is not recommended as primary monotherapy due to decreased efficacy in murine model head to head trials versus amphotericin.[38] The authors from the UK describe the use of LFAB and posaconazole for prophylactic use and empiric therapy in high risk injuries.[60] Since posaconazole is only available orally and many of these patients are critically ill, and since it takes several days to achieve effective serum levels, we are recommending posaconazole only as

salvage therapy or oral consolidation therapy after a course of IV LFAB, rather than as part of an initial regimen.

Due to concern that tissue levels of systemically administrated antifungal agents are low in the presence of ongoing necrosis, local therapies can also be considered. Amphotericin B releases from antimicrobial beads *in vitro*,[62] but no clinically proven benefit has been demonstrated. Nevertheless, amphotericin beads were used in three patients in this report. One case report in the literature describes use of amphotericin B drip into a wound,[27] and peritoneal lavage with LFAB was used on one patient with an intra-abdominal IFI in our series as well. Nystatin topical powder has been used in burn patients with angioinvasive fungal wound infections[63] but use with a wound vacuum of polytrauma patients such as those in our report would be problematic, and has not been documented in this setting. Wound based antifungal therapy such as amphotericin beads can be used at the surgeon's discretion, but any topical antifungal use is likely compromised by poor tissue penetration. Therefore, local therapy with a disinfectant that has antifungal properties would be preferred.

Sodium hypochlorite (Dakin's solution) has been known to have disinfectant properties since the turn of the twentieth century, and was used frequently as a topical agent for combat wound infections in the pre-antibiotic era.[64] Heggers et al. found sodium hypochlorite to be bactericidal against methicillin-resistant *Staphylococcus* aureus (MRSA) and multiple gram negative rods (*Enterobacter cloacae*, *Klebsiella pneumoniae*, *Serratia marcescens*, and *Proteus mirabilis*) at various concentrations, including 0.025%.[65] At higher concentrations, they found cytotoxicity of mouse fibroblasts, but no such cytotoxicity was seen at the more dilute "modified" Dakin's solution concentration of 0.025%. Other studies have shown similar bactericidal properties,[66, 67] but there is no published literature on fungicidal properties of modified Dakin's solution. The manufacturer of the commercial product Di-Dak-Sol (Century Pharmaceuticals Inc.) has provided results of an unpublished multi-microbial time challenge study showing a > 6-log reduction in concentration of *Aspergillus niger* and *Candida albicans* with 15 minutes exposure to modified Dakin's solution (unpublished data). Modified Dakin's solution, mixed with saline for 0.025% solution in 3 L bag, then instilled through the wound vacuum Instill device every two hours over 30 seconds, with a five minute dwell time has been an adjunctive therapy used in a number of cases. While anecdotally felt to be effective, no difference in outcome (time from IFI diagnosis to hospital discharge or time to documented clean wound) was observed when comparing cases who received modified Dakin's versus those that did not. Assessment of Dakin's use is available in relatively small numbers and is uncontrolled; therefore, this data should be interpreted cautiously. Dakin's solution can be considered as adjunctive therapy for those with combat trauma-related IFI.

Areas for future research

As is the case for any infectious disease outbreak investigation, ongoing active surveillance for new cases is paramount to understanding disease risk factors, clinical features, and outcomes. This case series investigation of IFI, among a population of military personnel suffering combat-related traumatic injury, suggests one possible mechanism: environmental fungi grossly contaminate large traumatic wounds, particularly of the extremities, then become angioinvasive and cause disease. This report suggests that those with IFI are severely injured (median ISS: 20),

receive a massive amount of blood products (median: 91 units) and have additional parameters of critical illness initially, such as thrombocytopenia, acidemia, and elevated base excess. Prospective collection of clinical data in trauma patients with high above the knee amputations would begin to allow risk factor analyses as well as provide interval assessments to measure impact of clinical practice guidelines. The majority of the cases have occurred following injury in the Helmand or Kandahar provinces in southern Afghanistan. Ongoing surveillance is needed to determine if regional location is an independent risk factor distinct from mechanism of injury and subsequent wounding pattern. Very little is known, however, about which particular molds populate the soil in Afghanistan, namely the "green zone" of the Helmand province where many of the traumatic injuries originated. More detailed environmental information may help determine what etiologic agents military personnel would be at risk for should traumatic injury occur; although the species distribution seen in this case series suggests this is quite diverse.

As previously stated, early diagnosis is critical for effective treatment, which requires aggressive surgical debridement and targeted antifungal therapy. Although the presence of invasive fungal elements on histopathology examination is the standard, additional studies to optimize prompt and sensitive diagnosis should be pursued. For instance, what role does sampling bias play? While processing and staining tissue yields definitive diagnosis, methods such as frozen section and calcofluor white staining may provide intraoperative results. Their diagnostic utility should be further explored. While GMS is traditionally felt to be highly sensitive for detection of fungal elements in tissue,[25] the diagnostic utility of other staining techniques such as H&E and PAS should be compared to GMS. Additional research into what role molecular techniques or mold antigen-based immunohistochemical staining may play in diagnosis of IFIs is warranted, particularly if a more prompt and accurate diagnosis would result. Additional questions that should be applied to this population include looking at the diagnostic utility of serum "biomarkers" like beta glucan and galactomannan, as well as exploring the differences in wound cytokines of these patients compared to others with non-IFI traumatic injuries.

More research is needed in the controversial area of *in vitro* sensitivity testing for antifungal agents and how it corresponds with clinical outcomes. Future research should focus on whether clinical outcomes are improved with the use of *in vitro* sensitivity testing, and if so, for which organisms is such testing is beneficial. In addition, consideration of pre-clinical animal model studies to investigate efficacy of preventive and/or therapeutic strategies both at local and systemic level may add further support to apply to clinical settings.

Prospective interventional studies should be considered to investigate the role of antifungal prophylaxis and adjunctive topical therapy with modified Dakin's solution. Regarding future research into management of IFI cases, there is no guidance currently on appropriate duration of antifungal therapy in these cases. Further analysis of antifungal regimen duration as well as empiric dual therapy (LFAB + triazole) versus monotherapy with associated outcomes among the current and future cases could be pursued in effort to refine practice guidance.

Overview of the Trauma Infectious Disease Outcomes Study (TIDOS)

Advances in battlefield surgical practice and technology, including rapid evacuation, have resulted in increased survival following battlefield traumatic injuries during Operations Iraqi Freedom (OIF) and Enduring Freedom (OEF). As a result, the number of complex poly-trauma cases being managed in military treatment facilities (MTF) has increased dramatically. Infection is a complication of battlefield injuries that can lead to significant morbidity and mortality. Infections due to multidrug resistant (MDR) *Acinetobacter* species and other multidrug-resistant organisms (MDRO) are increasingly common in this population necessitating broad-spectrum coverage, which in turn, is likely contributing to the increasing prevalence of these MDR organisms. Most of the war wounded patients are status post blast injury. Many of these patients are amputees undergoing multiple surgeries and prolonged courses of antibiotics for wound infections. Treatment of these infections is both clinically challenging and resource intense. The burden and long-term impact of these infections is poorly understood coupled by a lack of evidence-based practice guidelines for clinicians managing these infections.

The Departments of Defense and Veterans' Affairs Multicenter Cohort Study evaluating Infection-Associated Clinical Outcomes in Hospitalized Medical Evacuees following Traumatic Injury (TIDOS, for short) has the following objectives:

1. Establish a cohort of Department of Defense (DoD) beneficiaries and active duty personnel with trauma-related injuries to determine short and long-term outcomes and potential risk factors associated with infections.

2. Describe the infectious disease epidemiology of trauma-related injuries or other nosocomial infections in the cohort population.

3. Establish a database and bacterial and fungal isolate repository to support future approved sub-studies focused on informing clinical management, disease prevention, or clinical trial design.

4. Inform DoD efforts to develop real-time tools for combat-related health event/outcome analysis secondary to trauma-related infections during wartime.

The eligible study population includes DoD beneficiaries and active duty personnel receiving inpatient treatment at one of three tertiary care facilities (NNMC, WRAMC and BAMC) for a traumatic injury experienced during an overseas deployment. The observational cohort design targets informed consent and enrollment prior to discharge or transfer during a subject's initial CONUS (continental United States) hospitalization. The longitudinal follow-up period for each subject is estimated at a minimum of five years. Trauma history, post-injury hospital management, potential risk factors associated with infections, and clinical outcomes will be determined through the cohort study using various follow-up approaches (as appropriate): in-person and telephonic interviews, interaction with healthcare providers, medical record review, and query of electronic healthcare databases (such as the Joint Theater Trauma Registry [JTTR], the U.S. Navy-Marine Corps Combat Trauma Registry [CTR], or the National Department of Veterans Affairs Healthcare Databases).

TIDOS Investigative Team

Infectious Disease Clinical Research Program (IDCRP), USU, Bethesda, Maryland

David Tribble, MD DrPH, Coordinating Principal Investigator
Eugene Millar, PhD, Epidemiologist
Françoise Seillier-Moiseiwitsch, PhD, Statistician
Ken Wilkins, PhD, Statistician
Ping Li, MS, Statistician
Kisha Gaskins, MHS, Project Manager

IDCRP, Data Coordinating and Analysis Center (DCAC)

Chip Bradley, MS, Senior Programmer
Chris Olsen, Senior Programmer

Landstuhl Regional Medical Center (LRMC), Landstuhl, Germany

Lt Col Brad Lloyd, Infectious Disease, Site Principal Investigator
MAJ Kate Hinkle, Infectious Disease
LTC John Oh, Surgery

Brooke Army Medical Center (BAMC), San Antonio, Texas

LTC Clint Murray, Infectious Disease, Site Principal Investigator
COL Duane Hospenthal, Infectious Disease
Michael Landrum, MD, Infectious Disease
LTC Joseph Hsu, Orthopedic Surgery
COL James Ficke, Orthopedic Surgery

National Naval Medical Center (NNMC), Bethesda, Maryland

LT Tyler Warkentien, Infectious Disease, Site Principal Investigator
Anu Ganesan, MD, Infectious Disease
CAPT James Dunne, Trauma and Surgical Critical Care
LTC Romney Andersen, Orthopedic Surgery
CDR Mark Fleming, Orthopedic Surgery
Col (s) Debra Malone, Trauma and Surgical Critical Care
CDR Carlos Rodriguez, Trauma and Surgical Critical Care
CPT Justin Wells, Surgical Pathology
LCDR Bryan Keenan, Surgical Pathology

Walter Reed Army Medical Center (WRAMC), Washington, DC

COL Susan Fraser, Infectious Disease, Site Principal Investigator
COL Glenn Wortmann, Infectious Disease
Amy Weintrob, MD, Infectious Disease
MAJ Kristopher Paolino, Infectious Disease
MAJ Kyle Potter, Orthopedic Surgery

St. Louis Veterans Affairs Medical Center, St. Louis, Missouri

Jay McDonald, MD

Walter Reed Army Institute of Research (WRAIR), Silver Spring, Maryland

COL David Craft, Microbiologist

United States Army Institute of Surgical Research (USAISR), San Antonio, Texas

COL Lorne Blackbourne, Trauma and Surgical Critical Care

Trauma Infectious Disease Outcome Study (TIDOS)

Invasive Fungal Infection (IFI) Case Investigation

Technical Report

Appendix: Figures and Tables

Figure 1. Relative proportion of patients diagnosed with invasive fungal wound infections based on the dates of admission to Landstuhl Regional Medical Center (LRMC), June 2009 – December 2010

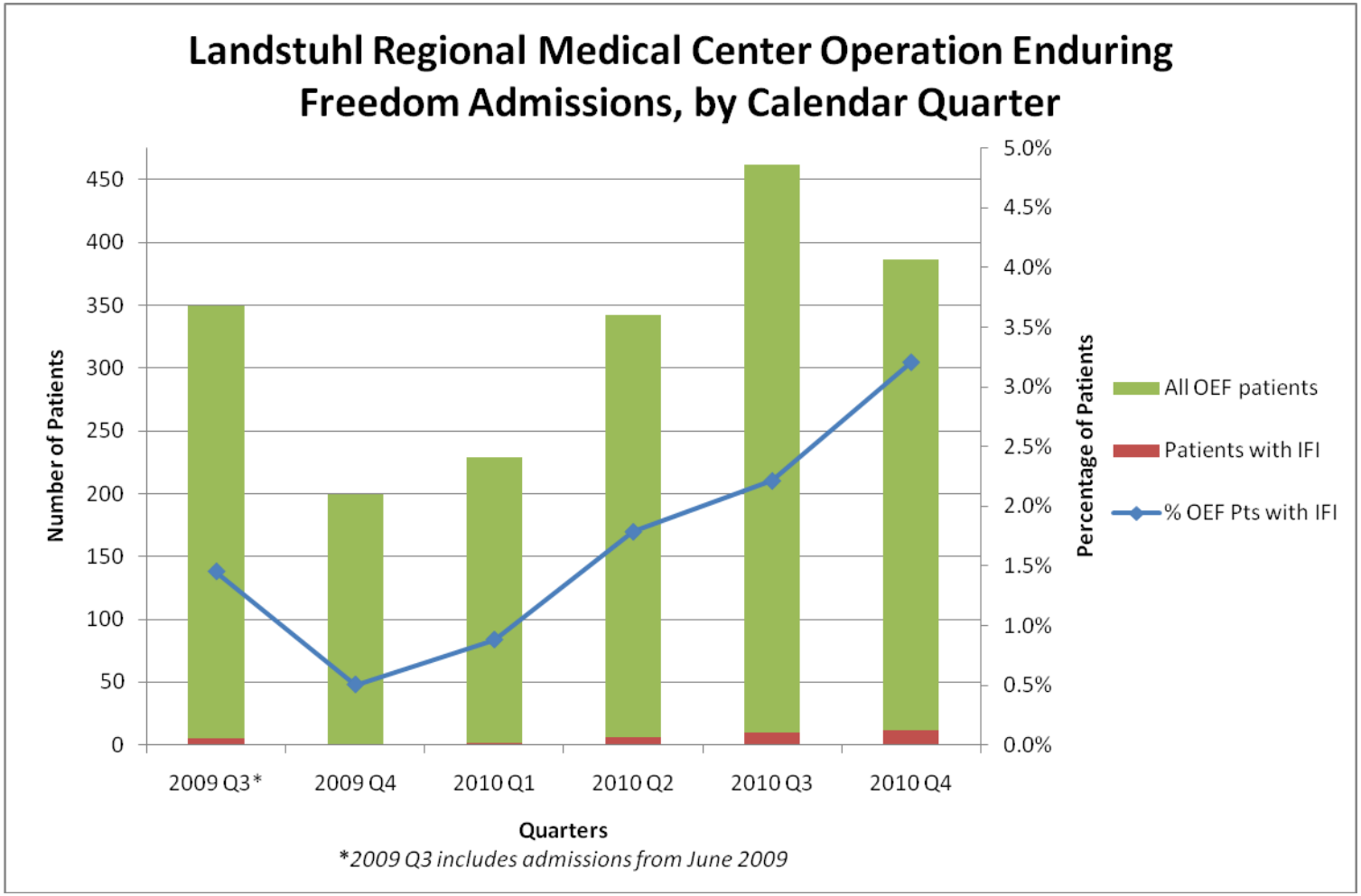

Figure 2. Comparison of selected injury and clinical findings at admission to Landstuhl Regional Medical Center (LRMC) between patients diagnosed with invasive fungal wound infections and patients admitted overall or to the ICU at LRMC, June-November 2009

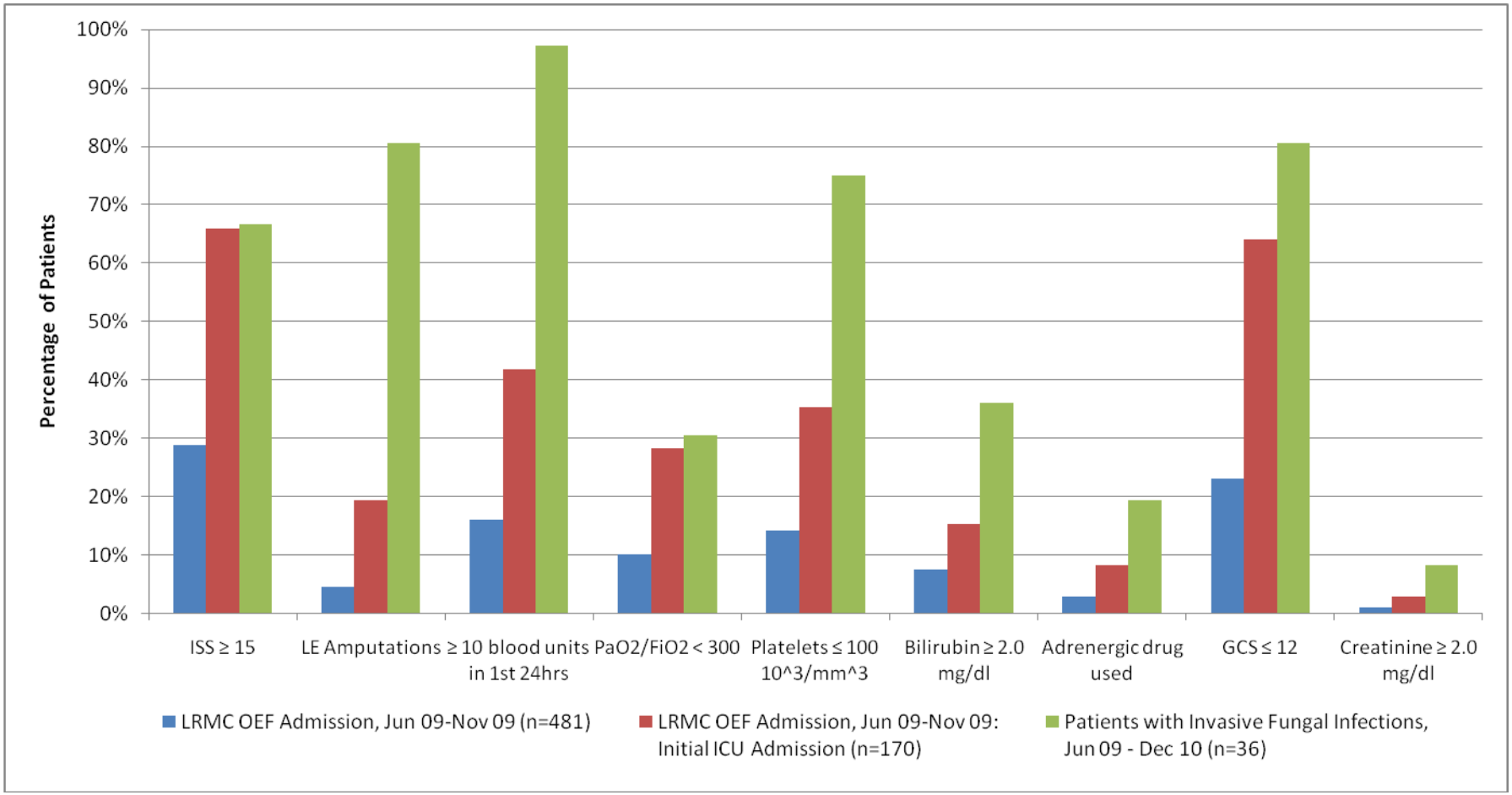

ICU: intensive care unit; ISS: injury severity score; LE: lower extremity; GCS: Glasgow Coma Score; OEF: Operation Enduring Freedom; Note: The overall LRMC patient admission period (Jun-Nov2009) does not cover the entire period for the IFI case series (Jun2009 - Dec2010).

Table 1. Demographic characteristics and circumstances related to injury among patients diagnosed with invasive fungal infections following combat-related trauma, 2009-2010

Characteristic		N (%)
IFI diagnostic classification		
Proven		19 (52.8)
Probable		4 (11.1)
Possible		13 (36.1)
Operational theater: Operation Enduring Freedom		36 (100)
Male		36 (100)
Age, years – median (IQR; range)		22.9 (21.4, 26.7) [19.8-46.9]
Branch of service		
Marines		24 (66.7)
Army		12 (33.3)
Enlisted grade		36 (100)
Mechanism of injury		
Blast[1]		35 (97.2)
Blast+ motor vehicle collision		1 (2.8)
Dismounted at time of injury		33 (91.7)
Initial medical facility[3]		
Bastion		19 (52.8)
Kandahar		8 (22.2)
Dwyer		3 (8.3)
FOB Edinburgh		2 (5.6)
469th MED		1 (2.8)
FOB Fenty		1 (2.8)
FOB Nolay		1 (2.8)
Kandalay		1 (2.8)
Calendar year quarter when injury occurred		
2009	3rd QTR[2]	5 (13.9)
	4th QTR	1 (2.8)
2010	1st QTR	2 (5.6)
	2nd QTR	6 (16.7)
	3rd QTR	10 (27.8)
	4th QTR	12 (33.3)

[1] Blast injury coded as improvised explosive device (IED) (not further specified in all cases) plus the following additional descriptions: IED person-borne (1), mortar, rocket and/or artillery shell (1), motor vehicle collision (1), rocket-propelled grenade (1), other blunt trauma (1)
[2] Includes month of June plus 3rd QTR 2009
[3] Forward Operating Base (FOB)

Table 2. Wounding pattern and injury characteristics of patients diagnosed with invasive fungal infections following combat-related traumatic injury, 2009-2010

Characteristics	N (%)
Injury severity scores at LRMC – median [IQR; range]	20 [15.5, 24.5; 10-50]
Injury categories (%)[1]	
Open fracture(s) plus additional open soft tissue wounds	36 (100)
Other closed fracture(s)	26 (72.2)
Other musculoskeletal injury (not an open wound)	12 (33.3)
Thoracic cavity (penetrating)	6 (16.7)
Non-penetrating thoracic injury	8 (22.2)
Abdomen (penetrating)	12 (33.3)
Non-penetrating abdominal injury	12 (33.3)
Maxillofacial - Open fracture/closed fracture with foreign body	3 (8.3)
Central nervous system - Penetrating brain injury	3 (8.3)
Central nervous system - Penetrating spinal cord injury	7 (19.4)
Closed skull/facial bone fracture	6 (16.7)
Eye injury, burn, or abrasion	5 (13.9)
Eye injury (penetrating)	2 (2.8)
Burns	3 (8.3)
Vascular injury	17 (47.2)
Other injury	29 (80.6)
Amputations (%)[2]	
Documented in theater, n=27 (75)	
Lower extremity	20 (74.1)
Upper extremity	1 (3.7)
Both	6 (22.2)
Occurring at Level IV or V, n=9 (25)	
Lower extremity	5 (45.5)
Upper extremity	3 (27.3)
Both	1 (9.1)
Amputation revision procedures at Level IV or V, n=26 (72.2)	
Lower extremity	20 (76.9)
Upper extremity	3 (11.5)
Both	3 (11.5)
Amputation across all Levels	
Lower extremity	22 (61.1)
Upper extremity	4 (11.1)
Both	6 (16.7)
No amputation	4 (11.1)

[1] Based on JTTR in theater ICD-9 codes. Most common individual ICD-9 codes: 897.2-amputation above the knee (22), 878.2 – open wound scrotum/testes (21), 897.6 – amputation leg, bilateral (14), 872.61 – open wound of ear drum (10), 879.8 – open wound site NOS (10), 878.0 – open wound penis (10)
[2] Excludes digit amputations

Table 3. Clinical characteristics of patients diagnosed with invasive fungal infections following combat-related traumatic injury, 2009-2010

Characteristics	Mean ± SD or N (%)	Median (IQR; range)
Days hospitalized[1]		
At level III	2.5 ± 1.0	2 (2, 3; 1-5)
At level IV	3.6 ± 1.6	3 (2.5, 4; 1-10)
At level V[1]	66.9 ± 48.6	60 (38, 74; 11-275)
ICU admission (%)		
LRMC ICU	35 (97.2)	
Ward	1 (2.8)	
CONUS ICU	28 (77.8)	
Ward	8 (22.2)	
Mechanical ventilation (%)		
At level III	36 (100)	
At level IV	30 (83.3)	
At level V	20 (55.6)	
OR events (any surgeries)		
Both level IV and V	12.3 (6.1)	11 (9, 14; 1, 26)

	IFI Classification			
	Proven N=19	Probable N=4	Possible N=13	All N=36
Admission SOFA score[2]				
LRMC - overall median score (IQR)	8 (7, 11)	8.5 (7.5, 9.5)	6 (4, 8)	8.0 (5, 10)
Respiration ($PaO_2/FiO_2 < 400$)	7 (36.8)	1 (25)	3 (23.1)	17 (47.2)
Coagulation (platelets < 150 x 10^3 /mm^3)	15 (78.9)	3 (75)	9 (69.2)	33 (91.7)
Hepatic Function (bilirubin ≥ 1.2 mg/dl)	9 (47.4)	1 (25)	3 (23.1)	23 (63.9)
Cardiovascular (mean arterial pressure < 70 mmHg)	3 (15.8)	2 (50)	2 (15.4)	15 (41.7)
Neurological Function (GCS < 15)	15 (78.9)	4 (100)	10 (76.9)	29 (80.6)
Renal Function (creatinine > 1.2 mg/dl)	3 (15.8)	0 (0)	0 (0)	9 (25.0)
CONUS MTF – overall median score (IQR)	6 (4, 8.5)	3.5 (0, 7)	1 (0, 7)	5.0 (1, 8)
Respiration ($PaO_2/FiO_2 < 400$)	9 (47.4)	1 (25)	3 (23.1)	15 (41.7)
Coagulation (platelets < 150 x 10^3 /mm^3)	5 (26.3)	1 (25)	3 (23.1)	19 (52.8)
Hepatic Function (bilirubin ≥ 1.2 mg/dl)	6 (31.6)	0 (0)	1 (7.7)	16 (44.4)
Cardiovascular (mean arterial pressure < 70 mmHg)	0 (0)	0 (0)	0 (0)	7 (19.4)
Neurological Function (GCS < 15)	13 (68.4)	2 (50)	5 (38.5)	23 (63.9)
Renal Function (creatinine > 1.2 mg/dl)	3 (15.8)	0 (0)	0 (0)	3 (8.3)

[1] Five patients currently have pending discharge dates with data censored at last available follow-up date
[2] Sequential Organ Failure Assessment (SOFA); individual score components listed as no. patients (%) with abnormal finding

Table 4. Clinical course/interventions in patients diagnosed with invasive fungal infections following combat-related traumatic injury, 2009-2010

Characteristics	N (%)
Clinical course/intervention	
At Landstuhl Regional Medical Center	
Central line	36 (100)
Enteric feeding tube	17 (47.2)
Chest tube	7 (19.4)
Ventriculostomy	1 (2.8)
Total parenteral nutrition	0 (0)
Vasopressor therapy	8 (22.2)
At CONUS hospital	
Central line	34 (94.4)
Enteric feeding tube	23 (63.9)
Chest tube	10 (27.8)
Ventriculostomy	1 (2.8)
Total parenteral nutrition	6 (16.7)
Vasopressor therapy	6 (16.7)
At time of transfer or discharge	
At Landstuhl Regional Medical Center	
Indwelling orthopedic hardware	14 (38.9)
Indwelling intravascular line	31 (86.1)
At CONUS hospital	
Indwelling orthopedic hardware	11 (47.3)
Indwelling intravascular line	9 (39.3)

Table 5. Clinical and laboratory parameters in patients diagnosed with invasive fungal infections following combat-related traumatic injury, 2009-2010

Clinical or laboratory parameter (No. tested)	**Median (IQR)**
Theater (at first facility)	
Heart rate, n=35	126 (114, 152)
Systolic blood pressure, n=35	98 (80, 119)
Blood gas - base deficit[1] , n=32	-7.5 (-10.5, -3.0)
Blood gas – pH, n=32	7.3 (7.2, 7.3)
Landstuhl Regional Medical Center (admission)	
White blood cell total (10^9 cells/L), n=36	7.8 (5.0, 9.9)
Absolute Neutrophil Count (10^9 cells/L)n=36	5.9 (3.9, 8.0)
Blood Urea Nitrogen (mg/dl), n=36	12.5 (8.0, 17.5)
Creatinine (mg/dl), n=36	0.9 (0.8, 1.2)
Aspartate aminotransferase (AST) (U/L), n=36	104.0 (72.0, 141.5)
Alanine aminotransferase (ALT) (U/L), n=36	37.5 (29.5, 50.5)
CONUS hospital (admission)	
White blood cell total (10^9 cells/L), n=36	10.7 (7.6, 13.0)
Absolute Neutrophil Count (10^9 cells/L), n=33	8.0 (6.4, 17.0)
Blood Urea Nitrogen (mg/dl), n=36	12.0 (7.5, 16.3)
Creatinine (mg/dl), n=36	0.7 (0.5, 0.9)
Aspartate aminotransferase (AST) (U/L), n=30	77 (57, 124)
Alanine aminotransferase (ALT) (U/L), n=30	43.5 (35.0, 64.0)

Selected clinical or laboratory findings within 5 days of IFI diagnosis	IFI Classification			
	Proven (N=19)	Probable (N=4)	Possible (N=13)	All (N=36)
Fever (temperature > 38° C) (%)	16 (84.2)	3 (75.0)	13 (100)	32 (88.9)
Maximum oral temperature, °C	39.5 (39.2, 40.1)	38.9 (38.9, 39.5)	39.3 (38.8, 39.7)	39.3 (39, 40)
Elevated white blood cell (WBC) count (%)	17 (89.5)	3 (75.0)	13 (100)	33 (97.1)
Maximum WBC, 10^9 cells/L	27.3 (17.4, 33.1)	16.5 (14.9, 46)	22.4 (19.8, 28.7)	23.4 (17.4, 32.4)
Platelets < 100 x 10^3 /mm^3 (%)	6 (31.6)	0	3 (23.1)	9 (26.5)
Bilirubin ≥ 2.0 mg/dl (%)	10 (52.6)	0	5 (38.5)	15 (44.1)
Serum creatinine > 2.0 mg/dl (%)	5 (26.3)	0	1 (7.7)	6 (17.6)
Serum glucose, median (IQR)	145 (119.5, 167)	131.5 (114, 149)	121.5 (100.5, 165)	140 (115, 164)
Serum lactate, median (IQR)	2.2 (1.3, 3)	-	1.2 (0.8, 2.5)	1.8 (1.2, 3.0)
Base deficit, median (IQR)	5.5 (1, 9.8)	5.6 (5.6, 5.6)	0 (-1, 2)	3.4 (0.0, 8.6)
Arterial blood pH, median (IQR)	7.3 (7.3, 7.4)	7.3 (7.3, 7.3)	7.3 (7.3, 7.4)	7.3 (7.3, 7.4)
Galactomannan (EIA index), median (IQR)[2]	0.1 (0.1, 0.8)	-	-	0.1 (0.1, 0.8)

[1] Excludes one patient due to an outlying value in blood gas base deficit (value=34.9)
[2] Fungal serology only obtained in 5 patients in 'proven' IFI category (no Beta D Glucan assay testing performed)

Table 6. Blood transfusion requirements by IFI classification, 2009-2010

Characteristics	IFI Classification			
	Proven N=19	Probable N=4	Possible N=13	All N=36
Blood transfusion, median (IQR), range				
All blood products over all care levels	113 (80, 169) [10, 212]	66.5 (37, 108) [31, 126]	81 (53, 93) [21, 153]	90.5 (58.5, 120.5) [10-212]
Packed red blood cells	62 (35, 81) [2, 140]	36 (20.5, 60.5) [16, 74]	48 (28, 51) [17, 74]	49 (30, 70) [2-140]
Platelets	8 (5, 16) [4, 26]	5.5 (3.5, 8) [2, 10]	3 (2, 9) [0, 12]	6 (3.5, 10) [0-26]
Fresh frozen plasma	35 (25, 45) [4, 66]	24 (11.5, 37.5) [11, 39]	19 (13, 31) [4, 54]	30 (17, 40) [4-66]
Cryoprecipitate	3 (1, 16) [0, 41]	1.5 (1, 2.5) [1, 3]	3 (1, 11) [0, 15]	3 (1, 10.5) [0-41]
Whole blood	0 (0, 2) [0, 10]	0 (0, 0.5) [0, 1]	0 (0, 0) [0, 4]	0 (0, 0.5) [0-10]
Blood products in theater				
Packed red blood cells	31 (22, 40) [2, 62]	23 (10.5, 41) [10, 47]	17 (11, 22) [2, 55]	29 (17, 37) [2-62]
Platelets	6 (4, 8) [0, 23]	3.5 (2, 7.5) [2, 10]	3 (1, 7) [0, 11]	5 (2.5, 8) [0-23]
Fresh frozen plasma	30 (25, 35) [4, 41]	23.5 (11.5, 37) [11, 39]	16 (9, 29) [2, 54]	27 (14.5, 35) [2-54]
Cryoprecipitate	3 (1, 12) [0, 40]	1.5 (1, 2.5) [1, 3]	3 (1, 10) [0, 13]	2 (1, 7.5) [0-40]
Whole blood	0 (0, 2) [0, 10]	0 (0, 0.5) [0, 1]	0 (0, 0) [0, 4]	0 (0, 0.5) [0-10]

Table 7. Characteristics of wounds infected with invasive mold (N = 53) among patients following combat-related traumatic injury, 2009-2010

Finding	N (%)
No. of wounds meeting IFI criteria	53
Invasive Fungal Infection criteria[1]	
Proven	26 (49.1)
Probable	8 (15.1)
Possible	19 (35.8)
Overall operative findings at any surgery, n=51	
Myonecrosis	42 (82.4)
Necrosis (unspecified)	38 (74.5)
Liponecrosis	25 (49.0)
Purulence	22 (43.1)
Fibrinous exudates	9 (17.7)
Eschar	7 (13.7)
Histopathology [patients, n=29 (80.6); wounds, n=41 (77.4)]	
Necrosis	41 (100)
Fungal elements (any)	34 (82.9)
Angioinvasion	26 (63.4)
Morphology, n=34[2]	
Septate	13 (38.2)
Aseptate	12 (35.3)
Multiple	7 (20.6)
Unknown	2 (5.9)
Periodic acid Schiff stain (PAS), n=41	
No fungal elements	6 (14.6)
Fungal elements with PAS staining	18 (43.9)
Fungal elements no PAS staining	11 (26.8)
PAS not performed	6 (14.6)
Gomori methenamine silver stain (GMS),n=41	
No fungal elements	5 (12.2)
Fungal elements with GMS staining	21 (51.2)
Fungal elements no GMS staining	3 (7.3)
GMS not performed	12 (29.3)
Mycology (No. of patients ≥ 1 positive culture, n=30)	
Mucorales	16 (30.2)
Aspergillus	16 (30.2)
Fusarium	9 (17.0)
Other mold	17 (32.1)

[1] 17 patients (24 wounds) met IFI criteria proven or probable and have positive mold culture

[2] Fungal morphology seen on histopathology by IFI class categories as follows: proven [septate only 3 (15.8%), aseptate only 9 (47.4%), both 7 (36.8%)], probable [septate only 3 (75.0%), unknown (25.0%)], and possible (no fungal elements on histopathology or not done)

Figure 3. Intraoperative findings of wound infected with invasive mold (Case 2 described in report)

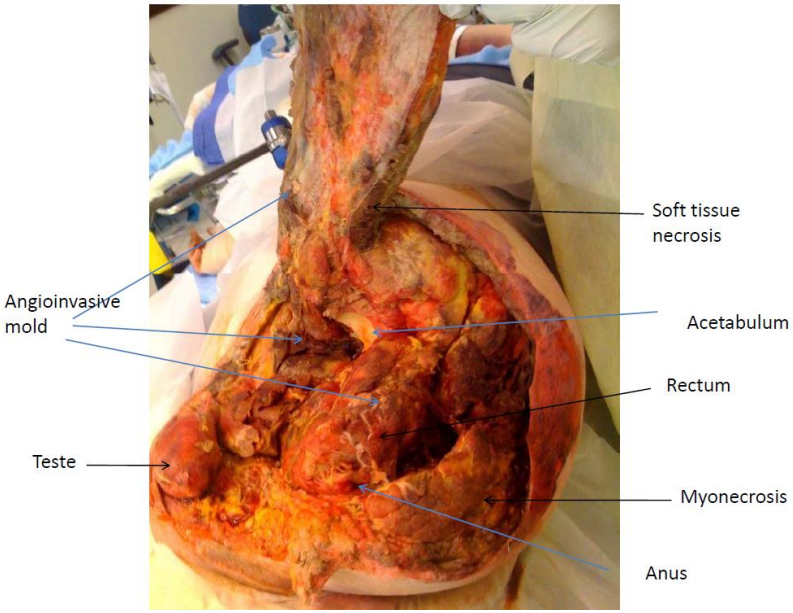

A. High level lower extremity amputation with necrotic fibrinous material documented on histopathology with aseptate invasive mold angioinvasion (initial presentation)

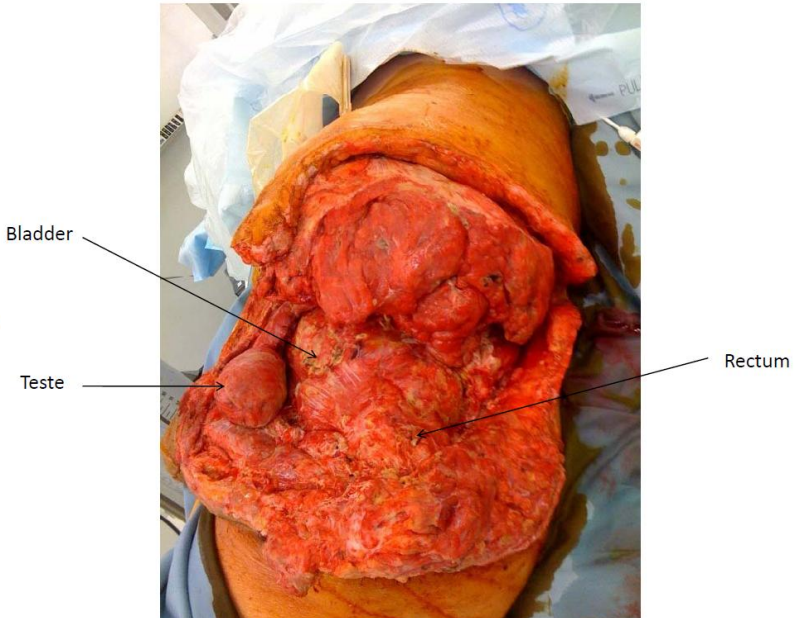

B. Hemipelvectomy s/p serial debridements and antifungal therapy (8 days later)

Figure 4. Histopathological findings of selected wounds infected with invasive mold

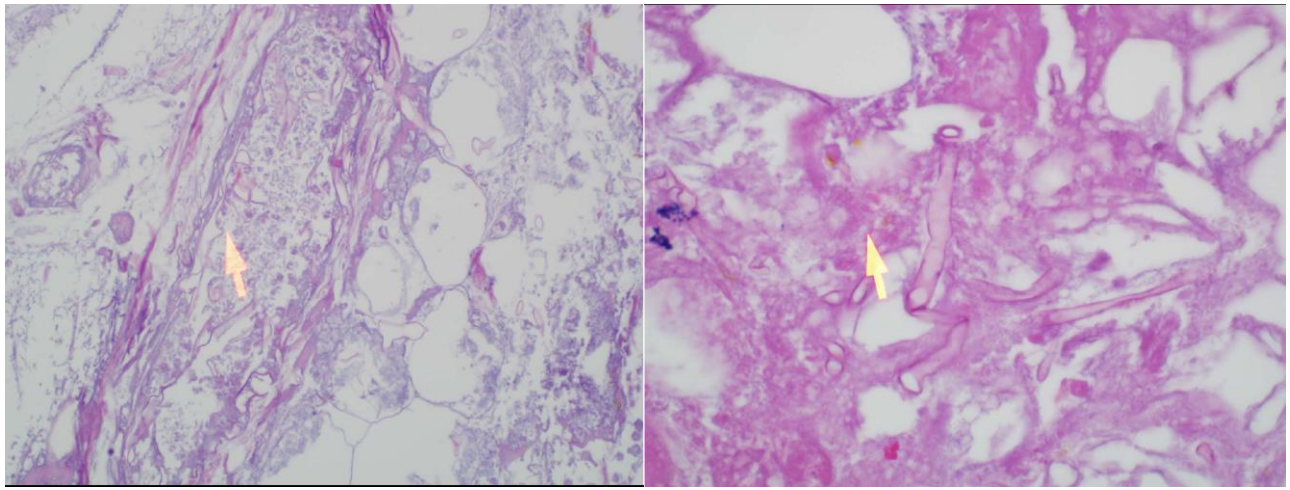

A) Hematoxylin and eosin staining of tissue showing angioinvasive mold with broad aseptate hyphae.

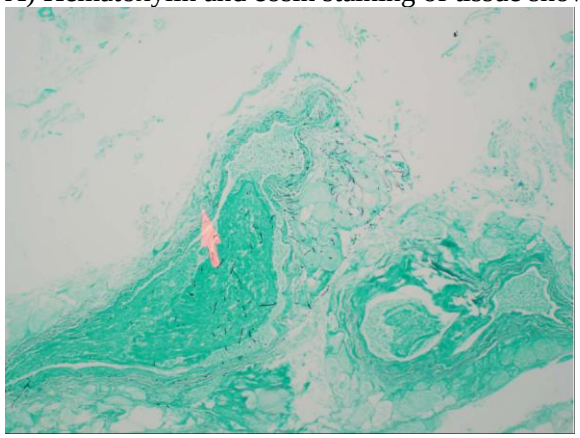

B) Gomori methenamine silver staining showing angioinvasive mold with septate hyphae.

Table 8. Fungal species isolated from wounds in patients diagnosed with invasive fungal infections following combat-related traumatic injury, 2009-2010

Pathogen, by order and genus/species		N (%)
Eurotiales		
	Aspergillus spp.	20 (29)
	Pencillium spp.	2 (3)
	Paecilomyces spp.	1 (1)
Mucorales		
	Mucor spp.	9 (13)
	Saksenaea vasiformis	6 (9)
	Apophysomyces spp.	2 (3)
Hypocreales		
	Fusarium spp.	9 (13)
	Beauveria spp.	2 (3)
Pleosporales		
	Ulocladium spp.	2 (3)
	Alternaria spp.	1 (1)
Acrophialophora fusispora		2 (3)
Microascales		
	Scedosporium prolificans	1 (1)
Pythiales		
	Pythium aphanidermatum	1 (1)
Fungus, unidentified		7 (10)

Note: overall numbers based on 30 patients with wound cultures positive for mold species; proportions based on 68 mold cultures with complete information

Table 9. Antifungal therapy in patients diagnosed with invasive fungal infections by IFI classification, 2009-2010

Systemic antifungal agents	**Median duration of use, days (IQR)** [1]						
	IFI Classification						
	Proven (N=19)		Probable (N=4)		Possible (N=13)		All (N=36)
	n		n		n		
Liposomal Amphotericin B[2] (N=29)	18	23.5 (14, 30)	3	12 (7, 34)	8	18 (5, 21.5)	21 (13, 27)
Voriconazole (N=27)	17	14 (7, 25)	2	9 (8, 10)	8	14.5 (3.5, 23)	13 (4, 25)
Posaconazole (N=16)	12	11.5 (3.5, 25.5)	1	31 (31, 31)	3	16 (6, 42)	16 (5.5, 30.0)
Micafungin (N=3)	1	1 (1, 1)	0	0 (0)	2	18 (10, 26)	10 (1, 26)
Caspofungin (N=12)	9	6 (4, 14)	0	0 (0)	3	13 (3, 14)	6 (3.5, 14)
Common regimens, number of patients (%)[3]							
Single agent		2 (10.5)		3 (75)		3 (23.1)	8 (22.2)
Combination (Ampho B + Triazole)		14 (73.7)		1 (25)		3 (23.1)	18 (50.0)
Combination (Ampho B + Triazole + Caspofungin)		3 (15.8)		0 (0)		2 (15.4)	5 (13.9)
Combination (Triazole + Micafungin)		0 (0)		0 (0)		1 (7.7)	1 (2.8)

Note: A total of 32 patients (88.9%) received antifungal agents

[1] Duration of use censors on date of hospital discharge if ongoing or on Jan 15, 2011 (last date of data collection).

[2] Amphotericin B liposomal formulation – starting dose median 4.60 (IQR 4.2, 5.2) mg/kg; median cumulative dose 7375 mg (IQR 4850, 10785). One patient excluded due to multiple conflicting drug start dates and overall duration of approximately 100 days.

[3] Regimen duration (excluding starting drug caspofungin and drugs with less than 3 days course) - median 27 days (IQR 16, 45); this also excludes 4 patients who did not receive antifungal therapy and 1 patient whose antifungal therapy < 3 days.

Table 10. Clinical events timeline in patients diagnosed with invasive fungal infections following combat-related traumatic injury, 2009-2010

Clinical timeline	Median (IQR); (range)
Hospitalization timeline (no. days)	
Injury to LRMC admission	3.0 (3, 4); (2, 6)
LRMC hospitalization	3.0 (2.5, 4.0); (1, 10)
Injury to first CONUS admission	6.0 (5, 7); (4, 14)
CONUS MTF hospitalization	60 (38, 74); (11, 275)
IFI-related timeline (no. days)	
Injury to IFI diagnosis (first wound if > 1 per patient)	10 (7.5, 14); (3, 28)
Injury to first positive mold culture	10 (8, 14); (3, 22)
Injury to first positive IFI histopathology	12 (8, 17); (7, 34)
Injury to first antifungal treatment[1]	12 (9, 16); (5, 52)
IFI diagnosis to first antifungal drug	3 (0, 6); (-10, 33)
Total duration of antifungal treatments	27 (16, 45); (9, 107)

Table 11. Clinical outcomes by IFI classification, 2009-2010

Characteristics	**Proven** N=19	**Probable** N=4	**Possible** N=13	**All** N=36
Deaths, no. (%)	3 (15.8)	0 (0)	1 (7.7)	4 (11.1)
Duration of hospitalization after injury, median (IQR)[1]	72.5 (43, 99)	78.5 (66, 97)	56 (43, 73)	67 (43, 82)
Duration of ICU stay (Level 4 and 5), median (IQR)	2 (1, 18.5)	3 (2.5, 13)	3 (2, 10)	3 (2,10)
No. (%) amputations occurring after theater evacuation[2]	4 (21.1)	1 (25)	4 (30.8)	9 (25.0)
No. (%) patients requiring high level amputation[3]	6 (31.6)	0 (0)	3 (23.1)	9 (25.0)
Amputation revisions after theater evacuation, no. patients, median no. revisions (IQR)	15, 2 (1, 3)	3, 2 (1, 3)	8, 2.5 (1, 3)	26, 1.5 (0, 3)

[1] Excludes extended inpatient period related to transfer to rehabilitation service

[2] Excludes digit amputations

[3] High level amputations defined as proximal lower extremity at the level of the hip or higher (hemipelvectomy)

Table 12. Injury and admission characteristics of patients diagnosed with IFI by fungal pathogen, 2009-2010

Characteristics	Mucorales (N=16)	Mold non-Mucorales (N=14)	No mold isolates (N=6)
IFI diagnostic classification			
Proven	10 (62.5)	6 (42.9)	3 (50.0)
Probable	1 (6.3)	0 (0)	3 (50.0)
Possible	5 (31.3)	8 (57.1)	0 (0)
Histopathology morphology			
Septate only	0 (0)	3 (21.4)	3 (50.0)
Aseptate only	7 (43.8)	0 (0)	2 (33.3)
Both septate and aseptate	3 (18.8)	3 (21.4)	1 (16.7)
Unknown	6 (37.5)	8 (57.1)	0 (0)
Period when injury occurred			
Jun 2009 –June 2009	8 (50.0)	3 (21.4)	3 (50.0)
July – Dec 2010	8 (50.0)	11 (78.6)	3 (50.0)
Injured while dismounted	15 (93.8)	12 (85.7)	6 (100)
Lower Extremity Amputation (%)	13 (81.3)	11 (78.6)	4 (66.7)
ISS at LRMC – median (IQR; range)	20 (17, 22) [10, 41]	20 (14, 25) [11, 50]	21 (20, 24) [14, 34]
Admitted to ICU			
LRMC	15 (93.7)	14 (100)	6 (100)
CONUS	12 (75)	11 (78.6)	5 (83.3)
Blood transfusion, median (IQR)			
All blood products over all care levels	96 (63.5, 155.5)	88.5 (55.0, 116.0)	85.0 (68.0, 126.0)
Packed red blood cells	61.5 (33.5, 76.0)	49.0 (25.0, 62.0)	41.0 (31.0, 74.0)
Platelets	6.5 (4.0, 14.0)	4.5 (2.0, 9.0)	6.5 (5.0, 10.0)
Fresh frozen plasma	30.5 (21.0, 42.5)	23.0 (16.0, 40.0)	35.5 (29.0, 39.0)
Cryoprecipitate	2.0 (0.5, 14.0)	4.0 (1.0, 11.0)	2.5 (2.0, 3.0)
Blood products (Level II and III)			
Packed red blood cells	25.5 (17.0, 35.5)	19.0 (13.0, 33.0)	34.0 (29.0, 39.0)
Platelets	6.0 (2.5, 9.0)	4.0 (2.0, 7.0)	5.0 (5.0, 8.0)
Fresh frozen plasma	27.0 (17.5, 34.0)	17.0 (13.0, 36.0)	33.0 (27.0, 35.0)
Cryoprecipitate	2.0 (0.5, 8.5)	3.5 (1.0, 11.0)	2.5 (2.0, 3.0)
Whole blood	0.0 (0.0, 0.0)	0.0 (0.0, 2.0)	0.0 (0.0, 1.0)
Admission SOFA, median (IQR)			
LRMC	7.0 (4.0, 11.0)	7.0 (5.0, 9.0)	9.0 (7.0, 10.0)
CONUS MTF	4.5 (1.5, 7.5)	6.0 (1.0, 7.0)	10.0 (7.0, 13.0)

Table 13. Clinical characteristics, treatment regimens, and characteristics of patients diagnosed with IFI by fungal pathogen, 2009-2010

Characteristics		Mucorales (N=16)		Mold non-Mucorales (N=14)		No mold isolates (N=6)
Selected clinical/ lab findings within 5 days of IFI diagnosis	n		n		n	
Fever (%) (Temperature > 38° C), n (%)	15	14 (93.0)	14	14 (100)	5	4 (80)
Maximum oral temperature, °C (N=32)		39.3 (39.0, 40.0)		39.4 (39.0, 39.7)		39.4 (39.1, 40.2)
Elevated white blood cell (WBC) count (%) (N=34)	15	15 (100)	14	14 (100)	4	4 (100)
Maximum WBC, 10^9 cells/L (N=33)		27.3 (16.5, 33.1)		23.5 (19.8, 32.4)		17.9 (14.5, 33.4)
Systemic antifungal agents, median days (IQR)						
Liposomal Amphotericin B	13	23.0 (21.0, 34.0)	11	22.0 (8.0, 25.0)	5	12.0 (7.0, 15.0)
Voriconazole	11	8.0 (3.0, 14.0)	12	19.0 (14.5, 30.0)	4	9.0 (5.0, 12.0)
Posaconazole	9	16.0 (6.0, 19.0)	3	22.0 (6.0, 42.0)	4	16.5 (1.5, 36.5)
Micafungin	2	5.5 (1.0, 10.0)	1	26.0 (26.0, 26.0)	0	
Caspofungin	5	6.0 (4.0, 14.0)	5	4.0 (3.0, 13.0)	2	10.5 (6.0, 15.0)
Common regimens[3] (%)						
Single agent		3 (18.8)		2 (14.3)		3 (50)
Combination (Ampho B + Triazole)		11 (68.8)		5 (35.7)		2 (33.3)
Combination (Ampho B + Triazole + Caspofungin)		0 (0)		4 (28.6)		1 (16.7)
Combination (Triazole + Micafungin)		0 (0)		1 (7.1)		0 (0)
Outcomes						
Deaths, no. (%)		3 (18.8)		0 (0)		1 (16.7)
Duration of hospitalization after injury[1] - median days (IQR)		72.5 (44.0, 86.0)		62.0 (43.0, 73.0)		63.0 (49.0, 88.0)
Median (IQR) duration of ICU stay (Level IV and V)		3.0 (2.0, 14.0)		2.0 (1.0, 7.0)		2.5 (2.0, 4.0)
Amputations occurring after theater evacuation (%)		3 (18.8)		5 (35.7)		1 (16.7)
High level amputation (%)		4 (25)		4 (28.6)		1 (16.7)
Amputation revision procedures - median no. (IQR)		2 (0.5, 3.0)		1.0 (0.0, 2.0)		1.0 (0.0, 2.0)

[1] Excludes extended inpatient period related to transfer to rehabilitation service

Table 14. Characteristics of patients diagnosed with invasive fungal infections following combat-related traumatic injury (2009-2010) by time period

Characteristics	Landstuhl Regional Medical Center Admission	
	June 2009 - June 2010 N=14	July 2010 - Dec 2010 N=22
Injury severity scores at LRMC – median [IQR; range]	17 (14, 20), [10, 41]	21 (20,25), [11, 50]
Lower extremity amputations in theater (%)	8 (57.1)	18 (81.8)
Overall blood transfusion requirement, median (IQR)	92 (62, 153)	89.5 (55, 120)
Admission SOFA score		
LRMC - overall median score (IQR)	8 (7, 11)	7 (5, 10)
CONUS MTF – overall median score (IQR)	4 (0, 8)	5.5 (2.5, 7)
IFI diagnostic classification (%)		
Proven	6 (42.9)	13 (59.1)
Probable	3 (21.4)	1 (4.5)
Possible	5 (35.7)	8 (36.4)
Diagnostic testing – No. patients with wounds tested (%); median number specimens (IQR)		
Histopathology	12 (85.7); 3.5 (2, 6)	17 (77.3); 2 (1, 3)
Microbiology	13(92.9); 4 (3, 9)	22 (100); 5.5 (2, 7)
IFI-related timeline, median no. days (IQR)		
Time from injury to IFI diagnosis	13 (10, 15), [6, 28]	10 (7, 14), [3, 29]
Time from IFI diagnosis to first antifungal drug	5 (3, 7), [-9, 34]	4 (1, 7), [-3, 22]
Time to clean wound after IFI diagnosis (per wound)	23 (15.5, 36.5)	21 (18, 33)
Clinical management		
No. of surgeries at wound site, median (IQR)	15 (13.5, 16.5)	10 (8, 12)
Dakin's solution use (%)	2 (14.3)	10 (45.5)
Antifungal therapy (%)	12 (85.7)	20 (90.9)
Regimen overall duration, median days (IQR)	38 (12, 47)	25.5 (16, 39)
Single agent	5 (41.7)	3 (15)
Combination (Ampho B + Triazole)	5 (41.7)	13 (65)
Combination (Ampho B + Triazole + Caspofungin)	1 (8.3)	4 (20)
Combination (Triazole + Micafungin)	1 (8.3)	0
Clinical outcome		
Deaths (%)	3 (21.4)	1 (4.6)
Amputation revisions after theater evacuation (%)	0.5 (0, 3)	2 (1, 3)
Amputation occurring after theater evacuation (%)	3 (21.4)	6 (27.3)
High level amputation (%)	3 (21.4)	6 (27.3)
Total ICU days (Level 4 and 5), median (IQR)	3.5 (2, 11)	2 (1, 7)
Hospitalization after injury, median days (IQR)	74.5 (63, 88)	52 (43, 73)

Table 15. Bacterial and/or yeast colonization and/or infection at traumatic wound sites before or at time of diagnosis in patients diagnosed with invasive fungal infections following combat-related traumatic injury, 2009-2010.

Microbial isolate	**N (%)**
Overall number of wounds	53 (100)
Organism-specific	
Enterococcus faecium	10 (18.9)
Acinetobacter calcoaceticus baumannii	9 (17.0)
Escherichia coli	7 (13.2)
Pseudomonas aeruginosa	6 (11.3)
Enterobacter cloacae	6 (11.3)
Candida albicans	4 (7.6)
Klebsiella pneumoniae	3 (5.7)
Coagulase negative *Staphylococcus*	2 (3.8)
Staphylococcus aureus	0
Enterobacter aerogenes	0

Table 16. Antimicrobial exposure by drug class prior to invasive fungal infection diagnosis following combat-related traumatic injury, 2009-2010.

Antimicrobial class/drug	**N (%)**	**Duration (days) Median (IQR)**
Cephalosporin – 1st generation	35 (97.2)	5.0 (2.0, 7.5)
Fluoroquinolone	34 (94.4)	3.5 (2.0, 6.5)
Vancomycin	27 (75.0)	3.0 (0.5, 6.0)
Aminopenicillin	23 (63.9)	1.0 (0, 2)
Carbapenem	22 (61.1)	3.0 (0, 5)
Aminoglycoside	21 (58.3)	1.0 (0, 2)
Anti-Pseudomonal Penicillin	13 (36.1)	0 (0.0, 1.5)
Miscellaneous[1]	12 (33.3)	0 (0, 1)
Echinocandin antifungal	8 (22.2)	0 (0, 0)
Triazole antifungal	8 (22.2)	0 (0, 0)
Clindamycin	6 (16.7)	0 (0, 0)
Polymyxin	3 (8.3)	0 (0, 0)
Tetracycline	2 (5.6)	0 (0, 0)
TMP-Sulfa	2 (5.6)	0 (0, 0)
Penicillin	1 (2.8)	0 (0, 0)
Cephalosporin – 2nd generation	1 (2.8)	0 (0, 0)
Linezolid	1 (2.8)	0 (0, 0)
Penicillinase-resistant Penicillin	0	-
Cephalosporin – 3rd generation	0	-
Macrolide	0	-

[1]Miscellaneous includes Rifampin, Daptomycin, Metronidazole

Table 17. Potential adverse reactions from antifungal agents

Antifungal Agent	Standard Dose	Adverse Effects and Comments
Amphotericin B deoxycholate	0.3-1 mg/kg IV per day	Infusional fever/chills and myalgias, rigors; nephrotoxicity; hypokalemia; renal tubular acidosis; anemia; hypomagnesemia.
Liposomal Amphotericin B	3-5 mg/kg IV per day	Nausea and vomiting. Nephrotoxicity and infusional reactions less common than with amphotericin B deoxycholate
Caspofungin	70 mg IV X 1, then 50 mg IV daily	Low toxicity profile. Infusion site pruritus, vomiting and diarrhea are possible.
Micafungin	100 mg (or 150 mg) IV daily	Low toxicity profile. Most common adverse events are nausea, vomiting, and headache
Voriconazole	IV: loading dose 6 mg/kg IV q12H X 2 doses, then 4 mg/kg IV q12h. PO: 400 mg q12h X 2 doses, then 200-300 mg po q12h (need to monitor levels in severe infection)	Hepatotoxicity, rash, photosensitivity & transient visual disturbance, and rarely, Stevens-Johnson syndrome or hallucinations. IV formulation is Contraindicated with creatinine clearance <50 mL/min due to accumulation of vehicle (cyclodextrin). Many drug-drug interactions.
Posaconazole	400 mg PO BID with meals (or if not eating, 200 mg PO four times daily).	Takes 7-10 days to achieve steady state & should be taken with high fat meal to increase absorption. Common reactions: nausea, abdominal pain, increase in ALT/AST; Rarely (if > 6 mo therapy): nephrotoxicity, QTc prolongation, adrenal insufficiency.

Adapted from Gilbert et al. The Sanford Guide to Antimicrobial Therapy 2010[68]

REFERENCES

1. Evriviades D, Jeffery S, Cubison T, Lawton G, Gill M, Mortiboy D. Shaping the military wound: issues surrounding the reconstruction of injured servicemen at the Royal Centre for Defence Medicine. Philos Trans R Soc Lond B Biol Sci 2011;366:219-30.
2. Albrecht MC, Griffith ME, Murray CK, et al. Impact of Acinetobacter infection on the mortality of burn patients. J Am Coll Surg 2006;203:546-50.
3. Scott P, Deye G, Srinivasan A, et al. An outbreak of multidrug-resistant Acinetobacter baumannii-calcoaceticus complex infection in the US military health care system associated with military operations in Iraq. Clin Infect Dis 2007;44:1577-84.
4. Yun HC, Branstetter JG, Murray CK. Osteomyelitis in military personnel wounded in Iraq and Afghanistan. J Trauma 2008;64:S163-8; discussion S8.
5. Petersen K, Riddle MS, Danko JR, et al. Trauma-related infections in battlefield casualties from Iraq. Ann Surg 2007;245:803-11.
6. Brown KV, Murray CK, Clasper JC. Infectious complications of combat-releated mangled extremity injuries in the British military. J Trauma 2010;69:S109-15.
7. Murray CK. Infectious disease complications of combat-related injuries. Crit Care Med 2008;36:S358-64.
8. Murray CK. Epidemiology of infections associated with combat-related injuries in Iraq and Afghanistan. J Trauma 2008;64:S232-8.
9. Murray CK, Wilkins K, Molter NC, et al. Infections in combat casualties during Operations Iraqi and Enduring Freedom. J Trauma 2009;66:S138-44.
10. Tribble DR, Conger, N.G., Fraser, S., Gleeson, T.D., Wilkins, K., Antonille, T., Weintrob, A., Ganesan, A., Gaskins, L.J., Li, P., Grandits, G., Landrum, M.L., Hospenthal, D.R., Millar, E.V., Blackbourne, L.H., Dunne, J.R., Craft, D., Mende, K., Wortmann, G.W., Herlihy, R., McDonald, J., Murray, C.K. Infection-Associated Clinical Outcomes in Hospitalized Medical Evacuees following Traumatic Injury- Trauma Infectious Disease Outcome Study (TIDOS) J Trauma 2011;accepted.
11. Gordon G, Indeck M, Bross J, Kapoor DA, Brotman S. Injury from silage wagon accident complicated by mucormycosis. J Trauma 1988;28:866-7.
12. Skiada A, Petrikkos G. Cutaneous zygomycosis. Clin Microbiol Infect 2009;15 Suppl 5:41-5.
13. Andresen D, Donaldson A, Choo L, et al. Multifocal cutaneous mucormycosis complicating polymicrobial wound infections in a tsunami survivor from Sri Lanka. Lancet 2005;365:876-8.
14. Kontogiorgi M, Floros I, Koroneos A, et al. Fatal post-traumatic zygomycosis in an immunocompetent young patient. J Med Microbiol 2007;56:1243-5.
15. Taams M, Bade PG, Thomson SR. Post-traumatic abdominal mucormycosis. Injury 1992;23:390-2.
16. Vitrat-Hincky V, Lebeau B, Bozonnet E, et al. Severe filamentous fungal infections after widespread tissue damage due to traumatic injury: six cases and review of the literature. Scand J Infect Dis 2009;41:491-500.
17. Patino JF, Castro D, Valencia A, Morales P. Necrotizing soft tissue lesions after a volcanic cataclysm. World J Surg 1991;15:240-7.
18. Horvath EE, Murray CK, Vaughan GM, et al. Fungal wound infection (not colonization) is independently associated with mortality in burn patients. Ann Surg 2007;245:978-85.
19. Cocanour CS, Miller-Crotchett P, Reed RL, 2nd, Johnson PC, Fischer RP. Mucormycosis in trauma patients. J Trauma 1992;32:12-5.

20. Hajdu S, Obradovic A, Presterl E, Vecsei V. Invasive mycoses following trauma. Injury 2009;40:548-54.
21. Roden MM, Zaoutis TE, Buchanan WL, et al. Epidemiology and outcome of zygomycosis: a review of 929 reported cases. Clin Infect Dis 2005;41:634-53.
22. Tully CC, Romanelli AM, Sutton DA, Wickes BL, Hospenthal DR. Fatal Actinomucor elegans var. kuwaitiensis infection following combat trauma. J Clin Microbiol 2009;47:3394-9.
23. Paolino K, Henry JA, Hospenthal DR, Wortmann GW, Hartzell J. Invasive fungal infections following combat-related injury. In: Infectious Diseases Society of America 2010 Annual Meeting. Vancouver, British Columbia; 2010.
24. De Pauw B, Walsh TJ, Donnelly JP, et al. Revised definitions of invasive fungal disease from the European Organization for Research and Treatment of Cancer/Invasive Fungal Infections Cooperative Group and the National Institute of Allergy and Infectious Diseases Mycoses Study Group (EORTC/MSG) Consensus Group. Clin Infect Dis 2008;46:1813-21.
25. Vincent JL, Moreno R, Takala J, et al. The SOFA (Sepsis-related Organ Failure Assessment) score to describe organ dysfunction/failure. On behalf of the Working Group on Sepsis-Related Problems of the European Society of Intensive Care Medicine. Intensive Care Med 1996;22:707-10.
26. Antonelli M, Moreno R, Vincent JL, et al. Application of SOFA score to trauma patients. Sequential Organ Failure Assessment. Intensive Care Med 1999;25:389-94.
27. Dunne JR, Riddle MS, Danko J, Hayden R, Petersen K. Blood transfusion is associated with infection and increased resource utilization in combat casualties. Am Surg 2006;72:619-25; discussion 25-6.
28. Champion HR, Bellamy RF, Roberts CP, Leppaniemi A. A profile of combat injury. J Trauma 2003;54:S13-9.
29. Owens BD, Kragh JF, Jr., Macaitis J, Svoboda SJ, Wenke JC. Characterization of extremity wounds in Operation Iraqi Freedom and Operation Enduring Freedom. J Orthop Trauma 2007;21:254-7.
30. Belmont PJ, Jr., Goodman GP, Zacchilli M, Posner M, Evans C, Owens BD. Incidence and epidemiology of combat injuries sustained during "the surge" portion of operation Iraqi Freedom by a U.S. Army brigade combat team. J Trauma;68:204-10.
31. Belmont PJ, Schoenfeld AJ, Goodman G. Epidemiology of combat wounds in Operation Iraqi Freedom and Operation Enduring Freedom: orthopaedic burden of disease. J Surg Orthop Adv;19:2-7.
32. Vainrub B, Macareno A, Mandel S, Musher DM. Wound zygomycosis (mucormycosis) in otherwise healthy adults. Am J Med 1988;84:546-8.
33. Kordy FN, Al-Mohsen IZ, Hashem F, Almodovar E, Al Hajjar S, Walsh TJ. Successful treatment of a child with posttraumatic necrotizing fasciitis caused by Apophysomyces elegans: case report and review of literature. Pediatr Infect Dis J 2004;23:877-9.
34. Blair JE, Fredrikson LJ, Pockaj BA, Lucaire CS. Locally invasive cutaneous Apophysomyces elegans infection acquired from snapdragon patch test. Mayo Clin Proc 2002;77:717-20.
35. Ribes JA, Vanover-Sams CL, Baker DJ. Zygomycetes in human disease. Clin Microbiol Rev 2000;13:236-301.
36. Gettleman LK, Shetty AK, Prober CG. Posttraumatic invasive Aspergillus fumigatus wound infection. Pediatr Infect Dis J 1999;18:745-7.
37. Demirel R, Ilhan S, Asan A, Kinaci E, Oner S. Microfungi in cultivated fields in Eskisehir provience (Turkey). J Basic Microbiol 2005;45:279-93.
38. Spellberg B, Walsh TJ, Kontoyiannis DP, Edwards J, Jr., Ibrahim AS. Recent advances in the management of mucormycosis: from bench to bedside. Clin Infect Dis 2009;48:1743-51.

39. Taylor RW, Manganaro L, O'Brien J, Trottier SJ, Parkar N, Veremakis C. Impact of allogenic packed red blood cell transfusion on nosocomial infection rates in the critically ill patient. Crit Care Med 2002;30:2249-54.
40. Segal BH, Almyroudis NG, Battiwalla M, et al. Prevention and early treatment of invasive fungal infection in patients with cancer and neutropenia and in stem cell transplant recipients in the era of newer broad-spectrum antifungal agents and diagnostic adjuncts. Clin Infect Dis 2007;44:402-9.
41. Ullmann AJ, Lipton JH, Vesole DH, et al. Posaconazole or fluconazole for prophylaxis in severe graft-versus-host disease. N Engl J Med 2007;356:335-47.
42. Cornely OA, Maertens J, Winston DJ, et al. Posaconazole vs. fluconazole or itraconazole prophylaxis in patients with neutropenia. N Engl J Med 2007;356:348-59.
43. De Laurenzi A, Matteocci A, Lanti A, Pescador L, Blandino F, Papetti C. Amphotericin B prophylaxis against invasive fungal infections in neutropenic patients: a single center experience from 1980 to 1995. Infection 1996;24:361-6.
44. Perfect JR, Klotman ME, Gilbert CC, et al. Prophylactic intravenous amphotericin B in neutropenic autologous bone marrow transplant recipients. J Infect Dis 1992;165:891-7.
45. Walsh TJ, Anaissie EJ, Denning DW, et al. Treatment of aspergillosis: clinical practice guidelines of the Infectious Diseases Society of America. Clin Infect Dis 2008;46:327-60.
46. Walsh TJ, Hiemenz JW, Seibel NL, et al. Amphotericin B lipid complex for invasive fungal infections: analysis of safety and efficacy in 556 cases. Clin Infect Dis 1998;26:1383-96.
47. Christiaens G, Hayette MP, Jacquemin D, Melin P, Mutsers J, De Mol P. An outbreak of Absidia corymbifera infection associated with bandage contamination in a burns unit. J Hosp Infect 2005;61:88.
48. Fisher J, Tuazon CU, Geelhoed GW. Mucormycosis in transplant patients. Am Surg 1980;46:315-22.
49. Garg J, Sujatha S, Garg A, Parija SC. Nosocomial cutaneous zygomycosis in a patient with diabetic ketoacidosis. Int J Infect Dis 2009;13:e508-10.
50. Spellberg B, Edwards J, Jr., Ibrahim A. Novel perspectives on mucormycosis: pathophysiology, presentation, and management. Clin Microbiol Rev 2005;18:556-69.
51. Tarrand JJ, Lichterfeld M, Warraich I, et al. Diagnosis of invasive septate mold infections. A correlation of microbiological culture and histologic or cytologic examination. Am J Clin Pathol 2003;119:854-8.
52. Chander J, Chakrabarti A, Sharma A, Saini JS, Panigarhi D. Evaluation of Calcofluor staining in the diagnosis of fungal corneal ulcer. Mycoses 1993;36:243-5.
53. Hamer EC, Moore CB, Denning DW. Comparison of two fluorescent whiteners, Calcofluor and Blankophor, for the detection of fungal elements in clinical specimens in the diagnostic laboratory. Clin Microbiol Infect 2006;12:181-4.
54. Maymind M, Thomas JG, Abrons HL, Riley RS. Laboratory implementation of a rapid three-stain technique for detection of microorganisms from lower respiratory specimens. J Clin Lab Anal 1996;10:104-9.
55. Chakrabarti A, Kumar P, Padhye AA, et al. Primary cutaneous zygomycosis due to Saksenaea vasiformis and Apophysomyces elegans. Clin Infect Dis 1997;24:580-3.
56. Moran SL, Strickland J, Shin AY. Upper-extremity mucormycosis infections in immunocompetent patients. J Hand Surg Am 2006;31:1201-5.
57. Reed C, Bryant R, Ibrahim AS, et al. Combination polyene-caspofungin treatment of rhino-orbital-cerebral mucormycosis. Clin Infect Dis 2008;47:364-71.
58. Gleissner B, Schilling A, Anagnostopolous I, Siehl I, Thiel E. Improved outcome of zygomycosis in patients with hematological diseases? Leuk Lymphoma 2004;45:1351-60.

59. Meletiadis J, Antachopoulos C, Stergiopoulou T, Pournaras S, Roilides E, Walsh TJ. Differential fungicidal activities of amphotericin B and voriconazole against Aspergillus species determined by microbroth methodology. Antimicrob Agents Chemother 2007;51:3329-37.
60. Greenberg RN, Mullane K, van Burik JA, et al. Posaconazole as salvage therapy for zygomycosis. Antimicrob Agents Chemother 2006;50:126-33.
61. van Burik JA, Hare RS, Solomon HF, Corrado ML, Kontoyiannis DP. Posaconazole is effective as salvage therapy in zygomycosis: a retrospective summary of 91 cases. Clin Infect Dis 2006;42:e61-5.
62. Sealy PI, Nguyen C, Tucci M, Benghuzzi H, Cleary JD. Delivery of antifungal agents using bioactive and nonbioactive bone cements. Ann Pharmacother 2009;43:1606-15.
63. Barret JP, Ramzy PI, Heggers JP, Villareal C, Herndon DN, Desai MH. Topical nystatin powder in severe burns: a new treatment for angioinvasive fungal infections refractory to other topical and systemic agents. Burns 1999;25:505-8.
64. Hirsch EF. "The Treatment of Infected Wounds," Alexis Carrel's contribution to the care of wounded soldiers during World War I. J Trauma 2008;64:S209-10.
65. Heggers JP, Barnes ST, Robson MC, Ristroph JD, Omer GE, Jr. Microbial flora of orthopaedic war wounds. Mil Med 1969;134:602-3.
66. McKenna PJ, Lehr GS, Leist P, Welling RE. Antiseptic effectiveness with fibroblast preservation. Ann Plast Surg 1991;27:265-8.
67. Lineaweaver W, Howard R, Soucy D, et al. Topical antimicrobial toxicity. Arch Surg 1985;120:267-70.
68. Gilbert DN, Moellering RC, Eliopoulos GM, Chambers HF, Saag MS. The Sanford Guide to Antimicrobial Therapy, 2010: Antimicrobial Therapy; 2010.